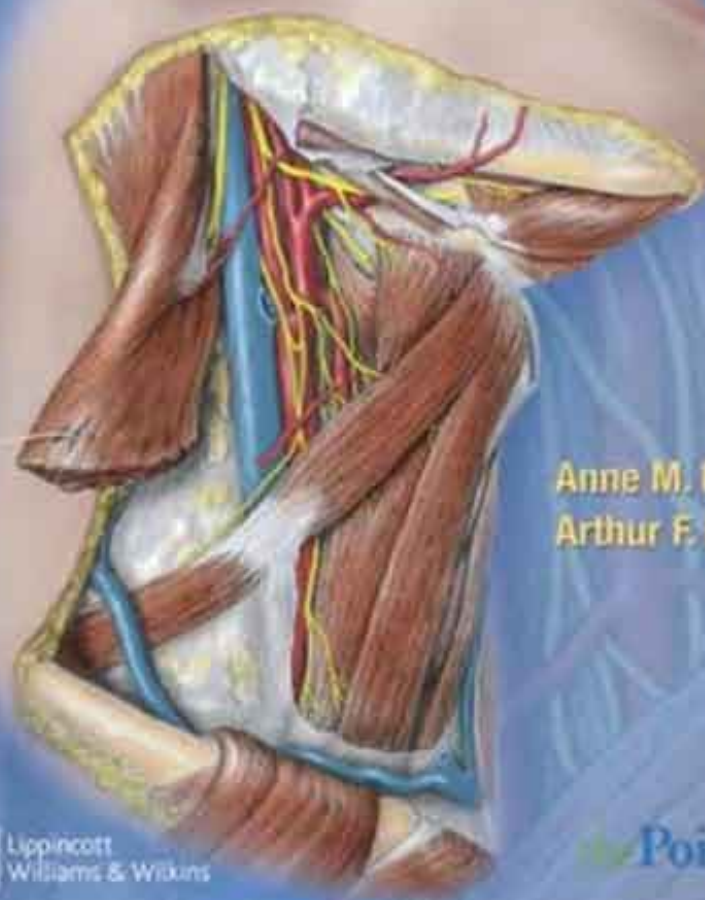


# *Grant's*

## **Atlas of Anatomy** Twelfth Edition



Anne M. R. Agur  
Arthur F. Dalley

Wolters Kluwer | Lippincott  
Williams & Wilkins

Point

Authors: Agur, Anne M.R.; Dalley, Arthur F.

Title: *Grant's Atlas of Anatomy, 12th Edition*

Copyright ©2009 Lippincott Williams & Wilkins

> Front of Book > Authors

---

## *Authors*

Anne M.R. Agur B.Sc. (OT), M.Sc.

Professor

*Division of Anatomy, Department of Surgery; Faculty of Medicine, Department of Physical Therapy, Department of Occupational Therapy, Division of Biomedical Communications, Institute of Medical Science, Graduate Department of Rehabilitation Science, Graduate Department of Dentistry, University of Toronto, Toronto, Ontario, Canada*

Arthur F. Dalley II Ph.D.

Professor

*Department of Cell & Developmental Biology; Adjunct Professor, Department of Orthopaedics and Rehabilitation, Vanderbilt University School of Medicine, Adjunct Professor of Anatomy, Belmont University School of Physical Therapy, Nashville, Tennessee, U.S.A.*



Authors: Agur, Anne M.R.; Dalley, Arthur F.

Title: *Grant's Atlas of Anatomy, 12th Edition*

Copyright ©2009 Lippincott Williams & Wilkins

> Front of Book > Dedication

---

## Dedication

*To my husband Enno and my children Erik and Kristina for their support and encouragement*

*(A.M.R.A.)*

*To Muriel*

*My bride, best friend, counselor, and mother of our sons;*

*To my family*

*Tristan, Lana, Elijah Grey, and Finley*

*Denver and Skyler*

*With great appreciation for their support, humor and patience*

*(A.F.D.)*

Authors: Agur, Anne M.R.; Dalley, Arthur F.


Title: *Grant's Atlas of Anatomy, 12th Edition*

Copyright ©2009 Lippincott Williams & Wilkins

> Front of Book > Dr. John Charles Boileau Grant 1886–1973

---

## Dr. John Charles Boileau Grant 1886–1973



*Dr. J.C.B. Grant in his office, McMurrich Building, University of Toronto, 1946. Through his textbooks, Dr. Grant made an indelible impression on the teaching of anatomy throughout the world.*

by Dr. Carlton G. Smith, M.D., P H. D.

(1905–2003)

Professor Emeritus, Division of Anatomy, Department of Surgery

Faculty of Medicine

University of Toronto, Canada

The life of J.C. Boileau Grant has been likened to the course of the seventh cranial nerve as it passes out of the skull: complicated, but purposeful.<sup>1</sup> He was born in the parish of Lasswade in Edinburgh, Scotland, on February 6, 1886. Dr. Grant studied medicine at the University of Edinburgh from 1903 to 1908. Here, his skill as a dissector in the laboratory of the renowned anatomist, Dr. Daniel John Cunningham (1850–1909), earned him a number of awards.

Following graduation, Dr. Grant was appointed the resident house officer at the Infirmary in Whitehaven, Cumberland. From 1909 to 1911, Dr. Grant demonstrated anatomy in the University of Edinburgh, followed by two years at the University of Durham, at Newcastle-on-Tyne in England, in the laboratory of Professor Robert Howden, editor of *Gray's Anatomy*.

With the outbreak of World War I in 1914, Dr. Grant joined the Royal Army Medical Corps and served with distinction. He was mentioned in dispatches in September 1916, received the Military Cross in September 1917 for “conspicuous gallantry and devotion to duty during attack,” and received a bar to the Military Cross in August 1918.<sup>1</sup>

In October 1919, released from the Royal Army, he accepted the position of Professor of Anatomy at the University of Manitoba in Winnipeg, Canada. With the frontline medical practitioner in mind, he endeavored to “bring up a generation of surgeons who knew exactly what they were doing once an operation had begun.”<sup>1</sup> Devoted to research and learning, Dr. Grant took interest in other projects, such as performing anthropometric studies of Indian tribes in northern Manitoba during the 1920s. In Winnipeg, Dr. Grant met Catriona Christie, whom he married in 1922.

Dr. Grant was known for his reliance on logic, analysis, and deduction as opposed to rote memory. While at the University of Manitoba, Dr. Grant began writing *A Method of Anatomy, Descriptive and Deductive*, which was published in 1937.<sup>2</sup>

In 1930, Dr. Grant accepted the position of Chair of Anatomy at the University of Toronto. He stressed the value of a “clean” dissection, with the structures well defined. This required the delicate touch of a sharp scalpel, and students soon learned that a dull tool was anathema. Instructive dissections were made available

in the Anatomy Museum, a means of student review on which Dr. Grant placed a high priority. Many of these illustrations have been included in *Grant's Atlas of Anatomy*.

The first edition of the *Atlas*, published in 1943, was the first anatomical atlas to be published in North America.<sup>3</sup> *Grant's Dissector* preceded the *Atlas* in 1940.<sup>4</sup>

Dr. Grant remained at the University of Toronto until his retirement in 1956. At that time, he became Curator of the Anatomy Museum in the University. He also served as Visiting Professor of Anatomy at the University of California at Los Angeles, where he taught for 10 years.

Dr. Grant died in 1973 of cancer. Through his teaching method, still presented in the Grant's textbooks, Dr. Grant's life interest in "human anatomy" lives on. In their eulogy, colleagues and friends Ross MacKenzie and J. S. Thompson said: "Dr. Grant's knowledge of anatomical fact was encyclopedic, and he enjoyed nothing better than sharing his knowledge with others, whether they were junior students or senior staff. While somewhat strict as a teacher, his quiet wit and boundless humanity never failed to impress. He was, in the very finest sense, a scholar and a gentleman."<sup>1</sup>

Authors: Agur, Anne M.R.; Dalley, Arthur F.

Title: *Grant's Atlas of Anatomy, 12th Edition*

Copyright ©2009 Lippincott Williams & Wilkins

> Front of Book > Preface

---

## Preface

This edition of *Grant's Atlas* has, like its predecessors, required intense research, market input, and creativity. It is not enough to rely on a solid reputation; with each new edition, we have adapted and changed many aspects of the *Atlas* while maintaining the commitment to pedagogical excellence and anatomical realism that has enriched its long history. Medical and health sciences education, and the role of anatomy instruction and application within it, continually evolve to reflect new teaching approaches and educational models. The health care system itself is changing, and the skills and knowledge that future health care practitioners must master are changing along with it. Finally, technologic advances in publishing, particularly in online resources and electronic media, have transformed the way students access content and the methods by which educators teach content. All of these developments have shaped the vision and directed the execution of this twelfth edition of *Grant's Atlas*, as evidenced by the following key features:

Classic “Grant’s” images updated for today’s students. A unique feature of *Grant's Atlas* is that, rather than providing an idealized view of human anatomy, the classic illustrations represent actual dissections that the student can directly compare with specimens in the lab. Because the original models used for these illustrations were real cadavers, the accuracy of these illustrations is unparalleled, offering students the best introduction to anatomy possible. Over the years we have made many changes to the illustrations to match the shifting expectations of students, adding more vibrant colors and updating the style from the original carbon-dust renderings. In this edition, at the suggestion of reviewers, we have continued this trend by introducing more lifelike skin tones to provide a more realistic “but no less accurate” depiction of anatomy. In addition, almost all of

these dissection figures were carefully analyzed to ensure that label placement remained effective and that the illustration's relevance was still clear. Almost every figure in this edition of *Grant's Atlas* was altered, from simple label changes to full-scale revision.

Schematic illustrations to facilitate learning. Full-color schematic illustrations supplement the dissection figures to clarify anatomical concepts, show the relationships of structures, and give an overview of the body region being studied. Many new schematic illustrations have been added to this edition; others have been revised to refine their pedagogical aspects. All conform to Dr. Grant's admonition to "keep it simple": extraneous labels were deleted, and some labels were added to identify key structures and make the illustrations as useful as possible to students. In addition, many new, simple orientation drawings were added for ease of identifying dissected regions.

Legends with easy-to-find clinical applications. Admittedly, artwork is the focus of any atlas; however, the *Grant's* legends have long been considered a unique and valuable feature of the *Atlas*. The observations and comments that accompany the illustrations draw attention to salient points and significant structures that might otherwise escape notice. Their purpose is to interpret the illustrations without providing exhaustive description. Readability, clarity, and practicality were emphasized in the editing of this edition. For the first time, clinical comments, which deliver practical "pearls" that link anatomic features with their significance in health care practice, are highlighted in blue within the figure legends. The clinical comments have also been expanded in this edition, providing even more relevance for students searching for medical application of anatomical concepts.

Enhanced diagnostic and surface anatomy and images. Because medical imaging have taken on increased importance in the diagnosis and treatment of injuries and illnesses, diagnostic images are used liberally throughout the chapters, and a special imaging section appears at the end of each chapter. Over 100 clinically relevant magnetic resonance images (MRIs), computed tomography (CT) scans, ultrasound scans, and corresponding orientation drawings are included in this edition. We have also increased the number of labeled surface anatomy photographs and introduced greater ethnic diversity in the surface anatomy



representations.

Tables—updated, expanded, and improved. Another feature unique to *Grant's Atlas* is the use of tables to help students organize complex information in an easy-to-use format ideal for review and study. The eleventh edition saw the introduction of muscle tables. In this edition, we have expanded the tables to include those for nerves, arteries, veins, and other relevant structures. The table format in this edition also received a substantial update; a consistent color code is used to clearly demarcate columns. Many tables are also strategically placed on the same page as the illustrations that demonstrate the structures listed in the tables.

Logical organization and layout. The organization and layout of the *Atlas* has always been determined with ease-of-use as the goal. Although the basic organization by body region was maintained in this edition, the order of plates within every chapter was scrutinized to ensure that it is logical and pedagogically effective. Sections within each chapter further organize the region into discrete subregions; these subregions appear as “titles” on the pages. Readers need only glance at these titles to orient themselves to the region and subregion that the figures on the page belong to. All sections also appear as a “table of contents” on the first page of each chapter.

Helpful learning and teaching tools. For the first time in its history, the twelfth edition of *Grant's Atlas* offers a wide range of electronic ancillaries for both student and teacher on Lippincott Williams & Wilkins' online ancillary site “thePoint” (<http://thepoint.lww.com/grantsatlas>). Students are given access to an interactive electronic atlas containing all of the atlas images with full search capabilities as well as zoom and compare features, as well as selected video clips from the best-selling *Acland's DVD Atlas of Human Anatomy* collection. Students can test themselves with 300 multiple choice questions, 95 “drag-and-drop” labeling exercises, and a sampling of *Clinical Anatomy Flash Cards*. For instructors, electronic ancillaries include an interactive atlas with slideshow and image-export functions, an image bank, and selected “dissection sequences” of plates.

We hope that you enjoy using this twelfth edition of *Grant's Atlas* and that it becomes a trusted partner in your educational experience. We believe that this new edition safeguards the *Atlas's* historical strengths while enhancing its usefulness to today's students.

Anne M.R. Agur  
Arthur F. Dalley II

Authors: Agur, Anne M.R.; Dalley, Arthur F.

Title: *Grant's Atlas of Anatomy, 12th Edition*

Copyright ©2009 Lippincott Williams & Wilkins

> Front of Book > Acknowledgments

---

## Acknowledgments

Starting with the first edition of this *Atlas* published in 1943, many people have given generously of their talents and expertise and we acknowledge their participation with heartfelt gratitude. Most of the original carbon-dust halftones on which this book is based were created by Dorothy Foster Chubb, a pupil of Max BrÅ¶del and one of Canada's first professionally trained medical illustrators. She was later joined by Nancy Joy, who is Professor Emeritus in the Division of Biomedical Communications, University of Toronto. Mrs. Chubb was mainly responsible for the artwork of the first two editions and the sixth edition; Miss Joy for those in between. In subsequent editions, additional line and half-tone illustrations by Elizabeth Blackstock, Elia Hopper Ross, and Marguerite Drummond were added. In recent editions, the artwork of Valerie Oxorn, Caitlin Duckwall, and Rob Duckwall, and the surface anatomy photography of Anne Rayner of Vanderbilt University Medical Center's Medical Art Group, have augmented the modern look and feel of the atlas.

Much credit is also due to Charles E. Storton for his role in the preparation of the majority of the original dissections and preliminary photographic work. We also wish to acknowledge the work of Dr. James Anderson, a pupil of Dr. Grant, under whose stewardship the seventh and eighth editions were published.

The following individuals also provided invaluable contributions to previous editions of the atlas, and are gratefully acknowledged: C.A. Armstrong, P.G. Ashmore, D. Baker, D.A. Barr, J.V. Basmajian, S. Bensley, D. Bilbey, J. Bottos, W. Boyd, J. Callagan, H.A. Cates, S.A. Crooks, M. Dickie, J.W.A. Duckworth, F.B. Fallis, J.B. Francis, J.S. Fraser, P. George, R.K. George, M.G. Gray, B.L. Guyatt, C.W. Hill, W.J. Horsey, B.S. Jaden, M.J. Lee, G.F. Lewis, I.B. MacDonald, D.L. MacIntosh,

R.G. MacKenzie, S. Mader, K.O. McCuaig, D. Mazierski, W.R. Mitchell, K. Nancekivell, A.J.A. Noronha, S. O'Sullivan, W. Pallie, W.M. Paul, D. Rini, C. Sandone, C.H. Sawyer, A.I. Scott, J.S. Simpkins, J.S. Simpson, C.G. Smith, I.M. Thompson, J.S. Thompson, N.A. Watters, R.W. Wilson, B. Vallecoccia, and K. Yu.

## Twelfth Edition

We are indebted to our colleagues and former professors for their encouragement—especially Dr. Keith L. Moore for his expert advice and Drs. Daniel O. Graney, Lawrence Ross, Warwick Gorman, and Douglas J. Gould for their invaluable input.

We extend our gratitude to the medical artists who worked on this edition: Valerie Oxorn, and Caitlin and Rob Duckwall of Dragonfly Media Group, who contributed new and modified illustrations. We would also like to acknowledge Wayne Hubbel, former Art Coordinator at Lippincott Williams & Wilkins and now a freelancer, who helped size and label art for this edition.

Special thanks go to everyone at Lippincott Williams & Wilkins—especially Crystal Taylor, Acquisitions Editor; Kathleen Scogna, Senior Developmental Editor; and Eve Malakoff-Klein, Managing Editor, Production. All of your efforts and expertise are much appreciated.

We would like to thank the hundreds of instructors and students who have over the years communicated via the publisher and directly with the editor their suggestions for how this *Atlas* might be improved. Finally, we would like to acknowledge the reviewers who reviewed previous editions of the *Atlas* as well as the following reviewers who reviewed the eleventh edition and provided expert advice on the development of this edition in particular:

## Faculty Reviewers

Diana Alagna, BS, Branford Hall Career Institute, Southington, Connecticut

Gary Allen, PhD, Dalhousie University, Halifax, Nova Scotia, Canada

Gail Amort-Larson, MS, University of Alberta, Edmonton, Alberta, Canada

Alan W. Budenz, DDS, MS, MBA, Arthur A. Dugoni School of Dentistry, University of

the Pacific, San Francisco, California

Anne Burrows, PhD, Duquesne University, Pittsburgh, Pennsylvania

Donald Fletcher, PhD, The Brody School of Medicine, East Carolina University,  
Greenville, South Carolina

Patricia Jordan, PhD, St. George's University, Grenada, West Indies

Elizabeth Julian, Augusta Technical Institute, Augusta, Georgia

H. Wayne Lambert, PhD, University Of Louisville, Louisville, Kentucky

Hector Lopez, DO, University of North Texas Health Science Center, Texas College  
of Osteopathic Medicine, Fort Worth, Texas

Brian MacPherson, PhD, University of Kentucky College of Medicine, Lexington,  
Kentucky

Helen Pearson, PhD, Temple University School of Medicine, Philadelphia,  
Pennsylvania

Chellapilla Rao, PhD, St. George's University School of Medicine, Grenada, West  
Indies

Darlene Redenbach, PhD, University of British Columbia, Vancouver, Canada

Heather Roberts, PhD, Sierra College, Rocklin, California

R. Shane Tubbs, PhD, University of Alabama, Birmingham, Alabama

Brad Wright, PhD, University of Vermont College of Medicine, Burlington, Vermont

## Student Reviewers

Geoffrey Barbary, Texas A and M University, College Station, Texas

Himanshu Bhatia, University Of Texas Health Sciences, Houston, Texas

Joseph Feuerstein, Boston University School of Medicine, Boston, Massachusetts

David Ficco, Life University, Marietta, Georgia

Eric Gross, Medical College of Wisconsin, Milwaukee, Wisconsin

Kathleen Hong, Boston University School of Medicine, Boston, Massachusetts

Patricia Johnson, Southwest College, Tempe, Arizona

Richy Lee, Medical University of the Americas, Charlestown, Nevis, West Indies

Sharon Phillips, University of Massachusetts Medical School, Worcester,  
Massachusetts

Karen Weinshelbaum, Mount Sinai School of Medicine, New York, New York

Joshua Weissman, Boston University School of Medicine, Boston, Massachusetts

Heather Willis, The Brody School of Medicine, East Carolina University, Greenville,  
South Carolina

We hope that readers and reviewers will find many of their suggestions  
incorporated into the twelfth edition and will continue to provide their valuable  
input.

Anne M.R. Agur

Arthur F. Dalley II



Authors: Agur, Anne M.R.; Dalley, Arthur F.

Title: *Grant's Atlas of Anatomy, 12th Edition*

Copyright ©2009 Lippincott Williams & Wilkins

> Front of Book > Table and Figure Credits

---

## Table and Figure Credits

Note: A list of the table and figure sources for this book from previous editions of *Clinically Oriented Anatomy*, *Grant's Atlas*, and *Essential Clinical Anatomy* can be found online at <http://thepoint.lww.com/grantsatlas>.

### Chapter 1

1.5AB Courtesy of Dr. K. Bukhanov, University of Toronto, Canada

1.5C Dean D, Herbener TE. Cross-Sectional Human Anatomy, 2000:25 (Plate 2.9).

1.23 Courtesy of Dr. E.L. Lansdown, University of Toronto, Canada

1.33A Courtesy of Dr. D.E. Sanders, University of Toronto, Canada

1.33B Courtesy of Dr. S. Herman, University of Toronto, Canada

1.33C Courtesy of Dr. E.L. Lansdown, University of Toronto, Canada

1.36 Courtesy of I. Verschuur, Joint Department of Medical Imaging, UHN/Mount Sinai Hospital, Toronto, Canada

1.41B&D Courtesy of I. Verschuur, Joint Department of Medical Imaging, UHN/Mount Sinai Hospital, Toronto, Canada

1.46C Courtesy of I. Verschuur, Joint Department of Medical Imaging, UHN/Mount Sinai Hospital, Toronto, Canada

1.47B&D Courtesy of I. Morrow, University of Manitoba, Canada

1.48B Courtesy of Dr. J. Heslin, Toronto, Canada

1.52B Courtesy of I. Verschuur, Joint Department of Medical Imaging, UHN/Mount

Sinai Hospital, Toronto, Canada

1.55AB Moore KL, Dalley AF. Clinically Oriented Anatomy. 5th ed, 2006:170 (Fig. 1.55). A is based on Torrent-Guasp F, Buckberg GD, Clemente C et al. The Structure and Function of the Helical Heart and Its Buttress Wrapping. I. The normal macroscopic structure of the heart. Sem. Thor. Cardiovasc Surgery. 13 (4): 301-319, 2001.

1.58B Feigenbaum H, Armstrong WF, Ryan T. Feigenbaum's Echocardiography. 5th ed, 2005:116.

1.66B Courtesy of Dr. E.L. Lansdown, University of Toronto, Canada

1.81A-F MRIs courtesy of Dr. M.A. Haider, University of Toronto, Canada

1.82A-C MRIs courtesy of Dr. M.A. Haider, University of Toronto, Canada

1.83AB MRIs courtesy of Dr. M.A. Haider, University of Toronto, Canada

1.85A-F Courtesy of I. Verschuur, Joint Department of Medical Imaging, UHN/Mount Sinai Hospital, Toronto, Canada

## Chapter 2

2.22B MRI courtesy of Dr. M.A. Haider, University of Toronto, Canada

2.31 Courtesy of Dr. J. Heslin, Toronto, Canada

2.32A, C, D Courtesy of Dr. E.L. Lansdown, University of Toronto, Canada

2.32B Courtesy of Dr. J. Heslin, Toronto, Canada

2.37A Courtesy of Dr. C.S. Ho, University of Toronto, Canada

2.37B Courtesy of Dr. E.L. Lansdown, University of Toronto, Canada

2.40A Courtesy of Dr. E.L. Lansdown, University of Toronto, Canada

2.40B Courtesy of Dr. J. Heslin, Toronto, Canada

2.42 Courtesy of Dr. K. Sniderman, University of Toronto, Canada

2.48B Courtesy of A. M. Arenson, University of Toronto, Canada

2.54D Courtesy of Dr. G.B. Haber, University of Toronto, Canada

2.56AB Courtesy of Dr. J. Heslin, Toronto, Canada

2.58AB Courtesy of Dr. G.B. Haber, University of Toronto, Canada

2.61B Radiograph courtesy of G.B.Haber, University of Toronto, Canada; photo courtesy of Mission Hospital Regional Center, Mission Viejo, California

2.65B Courtesy of M. Asch, University of Toronto, Canada

2.67B Courtesy of E.L. Lansdown, University of Toronto, Canada

2.68B (right) Courtesy of M. Asch, University of Toronto, Canada

2.85A, C, D Courtesy of Dr. M.A. Haider, University of Toronto, Canada

2.85B The Visible Human Project; National Library of Medicine; Visible Man Image number 1499.

2.86A, B, C Courtesy of Dr. M.A. Haider, University of Toronto, Canada

2.86D The Visible Human Project; National Library of Medicine; Visible Man Image number 1625.

2.87A-D Courtesy of Dr. M.A. Haider, University of Toronto, Canada

2.88A-D Courtesy of Dr. M.A. Haider, University of Toronto, Canada

2.89A-C Ultrasounds courtesy of A.M. Arenson, University of Toronto, Canada.

2.89D, F Courtesy of J. Lai, University of Toronto, Canada

2.86E, G Dean D, Herbener TE. Cross Sectional Human Anatomy, 2000:45,53 (Plates 3.9, 3.13)

## Chapter 3

3.26A-C Ultrasounds courtesy of Dr. A. Toi, University of Toronto, Canada

3.36D Courtesy of E.L. Lansdown, University of Toronto, Canada

3.36E From Sadler TW. Langman's Medical Embryology. 10th ed, 2006:92 (Fig. 7.5)

3.66A-D Courtesy of Dr. M.A. Haider, University of Toronto, Canada

3.66E Courtesy of The Visible Human Project; National Library of Medicine; Visible Man Image number 1940

- 3.67 Uflacker R. Atlas of Vascular Anatomy: An Angiographic Approach, 1997:611.
- 3.68A-C Courtesy of Dr. M.A. Haider, University of Toronto, Canada
- 3.69 MRIs courtesy of Dr. M.A. Haider, University of Toronto, Canada
- 3.70A-G MRIs courtesy of Dr. M.A. Haider, University of Toronto, Canada; sectioned specimens from The Visible Human Project; National Library of Medicine; Visible Woman Image numbers 1870 and 1895
- 3.71AB Courtesy of Dr. M.A. Haider, University of Toronto, Canada.
- 3.72A-D Ultrasounds courtesy of A.M. Arenson, University of Toronto, Canada
- 3.73D Reprinted with permission from Stuart GCE, Reid DF. Diagnostic studies. In Copeland LJ (ed.): Textbook of Gynecology. Philadelphia, WB Saunders, 1993.

## Chapter 4

- 4.1B Courtesy of D. Salonen, University of Toronto, Canada
- 4.7B, D, F, 4.8E Courtesy of Drs. E. Becker and P. Bobechko, University of Toronto, Canada
- 4.8C&D Courtesy of E. Becker, University of Toronto, Canada
- 4.11A, B Courtesy of J. Heslin, University of Toronto, Canada
- 4.11C, D Courtesy of D. Armstrong, University of Toronto, Canada
- 4.12C Courtesy of D. Salonen, University of Toronto, Canada
- 4.40C Clay JH, Pounds DM. Basic Clinical Massage Therapy: Integrating Anatomy and Treatment. 2003:92 (Fig. 3.40)
- 4.49B Courtesy of D. Salonen, University of Toronto, Canada
- 4.54AB Courtesy of The Visible Human Project; National Library of Medicine; Visible Man 1168.
- 4.54C Courtesy of D. Armstrong, University of Toronto, Canada
- 4.55A, B Courtesy of The Visible Human Project; National Library of Medicine; Visible Man 1715.

4.56A, B Courtesy of The Visible Human Project; National Library of Medicine; Visible Man 1805.

4.57A-D Courtesy of D. Salonen, University of Toronto, Canada

## Chapter 5

5.7A-D A and B are based on Fender FA. Foerster's scheme of the dermatomes. Arch Neurol Psychiatry 1939; 41:699. C and D are based on Keefan JJ, Garrett FD. The segmental distribution of the cutaneous nerves in the limbs of man. Anat Rec 1948;102:409

5.11B Roche Lexicon Medizin. 4th Ed. Munich: Urban & Schwarzenberg, 1998. (Appeared in Moore KL, Dalley AF. Clinically Oriented Anatomy. 4th Ed., 1999:527.)

5.13B Courtesy of Dr. E.L. Lansdown, University of Toronto, Canada

5.32A Courtesy of E. Becker, University of Toronto, Canada

5.32 C Daffner RH. Clinical Radiology: The Essentials. Baltimore: Williams & Wilkins, 1993:491 (Fig. 11.99)

5.33B Courtesy of Dr. D. Salonen, University of Toronto, Canada

5.46 (inset at page bottom) Roche Lexicon Medizin. 4th Ed. Munich: Urban & Schwarzenberg, 1998. (Appeared in Moore KL, Dalley AF. and Clinically Oriented Anatomy. 5 Ed., 2006:699.)

5.49A, B Courtesy of Dr. P. Bobechko, University of Toronto, Canada

5.49C Courtesy of Dr. D. Salonen, University of Toronto, Canada

5.50B&C Courtesy of Dr. D. Salonen, University of Toronto, Canada

5.51 Courtesy of Dr. P. Bobechko, University of Toronto, Canada

5.52B, C Courtesy of Dr. D. Salonen, University of Toronto, Canada

5.57C, D Clay JH, Pounds DM. Basic Clinical Massage Therapy: Integrating Anatomy and Treatment. 2002:352,354 (Figs. 10.16 & 10.18)

5.64A Courtesy of Dr. D. K. Sniderman, University of Toronto, Canada

5.71B, 5.76A Courtesy of Dr. E. Becker, University of Toronto, Canada

5.76B Courtesy of Dr. P. Bobechko, University of Toronto, Canada

5.77B Courtesy of E. Becker, University of Toronto, Canada

5.79B Courtesy of Dr. W. Kucharczyk, University of Toronto, Canada

5.80B Courtesy of Dr. W. Kucharczyk, University of Toronto, Canada

5.88C Courtesy of Dr. P. Bobechko, University of Toronto, Canada

5.89B, D Courtesy of P. Babyn, University of Toronto, Canada

5.90C Courtesy of The Visible Human Project; National Library of Medicine; Visible Man 2105.

5.90D, E, F MRIs courtesy of Dr. D. Salonen, University of Toronto, Canada

5.91C Courtesy of The Visible Human Project; National Library of Medicine; Visible Man 2551.

5.91D, E, F MRIs courtesy of Dr. D. Salonen, University of Toronto, Canada

Table 5.2 A-D Modified from Clay JH, Pounds DM. Basic Clinical Massage Therapy: Integrating Anatomy and Treatment. 2002:301 (Plate 9.2).

Table 5.2 E, H Modified from Clay JH, Pounds DM. Basic Clinical Massage Therapy: Integrating Anatomy and Treatment. 2002:280,312 (Figs. 8.10, 9.10)

Table 5.13 Clay JH and Pounds DM. Basic Clinical Massage Therapy: Integrating Anatomy and Treatment. 2002:362,364 (Figs. 10.28, 10.30)

## Chapter 6

6.5A, B Based on Fender FA. Foerster's scheme of the dermatomes. Arch Neurol Psychiatry 1939;41:688. (Appeared in Moore KL, Dalley AF. Clinically Oriented Anatomy. 4th ed, 1999:682,683.)

6.5C, D Based on Keegan JJ, Garrett FD. The segmental distribution of the cutaneous nerves in the limbs of man. Anat Rec 1948;102:409

6.17A-E Modified from Clay JH, Pounds DM. Basic Clinical Massage Therapy: Integrating Anatomy and Treatment. 2002:120,124,119,149 (Figs. 4.4, 4.9, 4.1, 4.49)



6.22C Courtesy of D. Armstrong, University of Toronto, Canada

6.30B&D Clay JH, Pounds DM. Basic Clinical Massage Therapy: Integrating Anatomy and Treatment. 2002:144,138 (Figs. 4.44, 4.33)

6.44A Courtesy of E. Becker, University of Toronto, Canada

6.44 C, E Courtesy of D. Salonen, University of Toronto, Canada

6.44 D Courtesy of R. Leekam, University of Toronto and West End Diagnostic Imaging, Canada

6.49C Courtesy of E. Becker, University of Toronto, Canada

6.50 Radiographs courtesy of J. Heslin, Toronto, Canada;

6.51B Courtesy of D. Salonen, University of Toronto, Canada

6.52B Courtesy of E. Becker, University of Toronto, Canada

6.55A Courtesy of K. Sniderman, University of Toronto, Canada

6.57A, 6.58A, 6.59A, 6.60A Clay JH, Pounds DM. Basic Clinical Massage Therapy: Integrating Anatomy and Treatment. 2002:170 (Plate 5.3)

6.66ABCD Clay JH, Pounds DM. Basic Clinical Massage Therapy: Integrating Anatomy and Treatment. 2002:174 (Plate 5.55)

6.72A Courtesy of D. Armstrong, University of Toronto, Canada

6.78F Courtesy of E. Becker, University of Toronto, Canada

6.81A, B Courtesy of E. Becker, University of Toronto, Canada

6.82B Courtesy of D. Armstrong, University of Toronto, Canada

6.89L Courtesy of D. Armstrong, University of Toronto, Canada

6.90B-D Courtesy of D. Salonen, University of Toronto, Canada

6.91C-E Courtesy of D. Salonen, University of Toronto, Canada

6.92A-C Courtesy of D. Salonen, University of Toronto, Canada

6.93 B Courtesy of R. Leekam, University of Toronto and West End Diagnostic Imaging, Canada

Table 6.5 Clay JH, Pounds DM. Basic Clinical Massage Therapy: Integrating Anatomy and Treatment. 2002:113,136,132 (Plates 4.4, 4.31, 4.24)

Table 6.8 Clay JH, Pounds DM. Basic Clinical Massage Therapy: Integrating Anatomy and Treatment. 2002:170,171,173,179 (Plates 5.3, 5.4, 5.6, and Fig. 5.1)

Table 6.13 3&4 Clay JH, Pounds DM. Basic Clinical Massage Therapy: Integrating Anatomy and Treatment. 2002:127 (Plate 5.5)

## Chapter 7

7.1B, E&F Courtesy of Dr. D. Armstrong, University of Toronto, Canada

7.7A, B Courtesy of Dr. E. Becker, University of Toronto, Canada

7.29A-C Courtesy of Dr. D. Armstrong, University of Toronto, Canada

7.30A&B Courtesy of I. Verschuur, Joint Department of Medical Imaging, UHN/Mount Sinai Hospital, Toronto, Canada

7.33C Courtesy of Dr. W. Kucharczyk, University of Toronto, Canada

7.35C Courtesy of Dr. W. Kucharczyk, University of Toronto, Canada

7.38A Courtesy of J.R. Buncic, University of Toronto, Canada

7.46 CTs and MRIs from Langland OE, Langlais RP, Preece JW. Principles of Dental Imaging, 2002:278 (Figs. 11.32A, B; 11.33A, B).

7.53A Langland OE, Langlais RP, Preece JW. Principles of Dental Imaging, 2002:334 (Fig. 14.1).

7.53B Courtesy of M.J. Phatoah, University of Toronto, Canada.

7.54E Courtesy of Dr. B. Libgott, Division of Anatomy/Department of Surgery, University of Toronto, Ontario, Canada

7.55B, C Woelfel JB, Scheid RC. Dental Anatomy: Its Relevance to Dentistry. 6th ed, 2002:86,46 (Figs. 3.5, 1.29).

7.64B Courtesy of D. Armstrong, University of Toronto, Canada

7.64C Courtesy of E. Becker, University of Toronto, Canada

7.65C Courtesy of E. Becker, University of Toronto, Canada

7.67D Courtesy of Dr. E. Becker, University of Toronto, Canada

7.71D Courtesy of Welch Allen, Inc. Skaneateles Falls, NY. (Appeared in Moore KL, Dalley AF. Clinically Oriented Anatomy. 4th ed, 1999:966 (Fig. 8.2)

7.81B Courtesy of W. Kucharczyk, University of Toronto, Canada

7.81C, D Courtesy of W. Kucharczyk, University of Toronto, Canada

7.82B Courtesy of Dr. W. Kucharczyk, University of Toronto, Canada

7.83A-E All photos courtesy of The Visible Human Project; National Library of Medicine; Visible Man 1107 and 1168.

7.86, 7.87, 7.88, 7.89, 7.91, 7.92B, C, 7.93 Colorized from photographs provided courtesy of Dr. C.G. Smith, which appears in Smith CG. Serial Dissections of the Human Brain. Baltimore: Urban & Schwarzenber, Inc. and Toronto: Gage Publishing Ltd., 1981 (© Carlton G. Smith)

7.90A-F MRIs courtesy of Dr. D. Armstrong, University of Toronto, Canada

7.94A-E MRIs courtesy of Dr. D. Armstrong, University of Toronto, Canada

7.95A-F MRIs courtesy of Dr. D. Armstrong, University of Toronto, Canada

7.96A-C MRIs courtesy of Dr. D. Armstrong, University of Toronto, Canada

Table 7.9 Illustrations from Clay JH, Pounds DM. Basic Clinical Massage Therapy: Integrating Anatomy and Treatment. 2002:76,74,79 (Figs.3.17, 3.15, 3.19).

Table 7.12 (bottom left illustration) Clay JH, Pounds DM. Basic Clinical Massage Therapy: Integrating Anatomy and Treatment, 2002:80 (Fig. 3.22).

## Chapter 8

8.4B Courtesy of J. Heslin, University of Toronto, Canada

8.18B Modified from Clay JH, Pounds DM. Basic Clinical Massage Therapy: Integrating Anatomy and Treatment. 2003:92 (Fig. 3.40)

8.25B From Liebgott B. The Anatomical Basis of Dentistry. Philadelphia, PA: Mosby, 1982.

8.31A Rohen JW, Yokochi C, Lutjen-Drecolle, Romrell LJ. Color Atlas of Anatomy: A Photographic Study of the Human Body. 5th ed, 2002.

8.31C Courtesy of Dr. D. Salonen, University of Toronto, Canada.

8.34A-C Courtesy of Dr. D. Salonen, University of Toronto, Canada;

8.36B Courtesy of Dr. E. Becker, University of Toronto, Canada

8.37 Photo courtesy of Acuson Corporation, Mt. View, California

Table 8.3 Modified from Clay JH, Pounds DM. Basic Clinical Massage Therapy: Integrating Anatomy and Treatment. 2003:90,91 (Figs. 3.36, 3.48)

Table 8.4 Modified from Clay JH, Pounds DM. Basic Clinical Massage Therapy: Integrating Anatomy and Treatment. 2003:88 (Fig. 3.34)

Table 8.5B Courtesy of Dr. D. Armstrong, University of Toronto, Canada

Table 8.7 Clay JH, Pounds DM. Basic Clinical Massage Therapy: Integrating Anatomy and Treatment. 2003:101,128 (Figs. 3.53, 4.17)

Table 8.8A-D Clay JH, Pounds DM. Basic Clinical Massage Therapy: Integrating Anatomy and Treatment. 2003:96,100,104 (Figs. 3.48, 3.52, 3.56)

## Chapter 9

9.6A-F Courtesy of Dr. W. Kucharczyk, University of Toronto, Canada

9.7A-C Photos courtesy of Dr. W. Kucharczyk, University of Toronto, Canada

Authors: Agur, Anne M.R.; Dalley, Arthur F.

Title: *Grant's Atlas of Anatomy, 12th Edition*

Copyright ©2009 Lippincott Williams & Wilkins

> Front of Book > References

---

## References

Photograph of Dr. J. C. B. Grant courtesy of Dr. C. G. Smith.

## References

### Tribute to Dr. Grant

1. Robinson C. Canadian Medical Lives: J.C. Boileau Grant: Anatomist Extraordinary. Markham, Ontario, Canada: Associated Medical Services Inc./Fithzenry & Whiteside, 1993.

---

2. Grant JCB. A Method of Anatomy, Descriptive and Deductive. Baltimore: Williams & Wilkins Co., 1937. (11th edition, J. Basmajian and C. Slonecker, 1989)

---

3. Grant JCB. Grant's Atlas of Anatomy. Baltimore: Williams & Wilkins Co., 1943 (10th Edition, A. Agur and L. Ming, 1999)

---

4. Grant JCB, Cates HA. Grant's Dissector (A Handbook for Dissectors). Baltimore: Williams & Wilkins Co., 1940 (12th edition, E.K. Sauerland, 1999)

---

## Chapter 1

(Fig. 1.51) Anson BH. The aortic arch and its branches. *Cardiology*. New York: McGraw-Hill, vol 1: 1963.

---

## Chapter 2

(Fig. 2.49) Couinaud C. Lobes et segments hepatiques: Note sur l'architecture anatomique et chirurgicale du foie. *Presse Med* 1954;62:709.

---

(Fig. 2.49) Healy JE, Schroy PC. Anatomy of the biliary ducts within the human liver: Analysis of the prevailing pattern of branchings and the major variations of the biliary ducts. *Arch Surg* 1953;66:599.

---

(Fig. 2.89B) Campbell M. Ureteral reduplication (double ureter). *Urology*. Vol.1. Philadelphia: WB Saunders, 1954:309.

---

## Chapter 3

(Fig. 3.43A) Oelrich TM. The urethral sphincter muscle in the male. *Am J Anat* 1980;158:229.

---

(Fig. 3.43B) Oelrich TM. The striated urogenital sphincter muscle in the female. *Anat Rec* 1983;205:223.

---

## Chapter 4

(Fig. 4.48A) Jit I, Charnakia VM. The vertebral level of the termination of the spinal cord. *J Anat Soc India* 1959;8:93.

---



Authors: Agur, Anne M.R.; Dalley, Arthur F.

Title: *Grant's Atlas of Anatomy, 12th Edition*

Copyright ©2009 Lippincott Williams & Wilkins

> Table of Contents > Chapter 1 - Thorax > Chapter 1 - Thorax

---

# Chapter 1

## Thorax

---

P.2

- 1.1 Surface anatomy of male pectoral region
- 1.2 Superficial dissection, male pectoral region
- 1.3 Superficial dissection, female pectoral region
- 1.4 Female mammary gland
- 1.5 Imaging of breast
- 1.6 Bed of breast
- 1.7 Arterial supply of the breast
- 1.8 Lymphatic drainage of breast
- 1.9 Bony thorax
- 1.10 Sternum and associated joints
- 1.11 Ribs
- 1.12 Costovertebral articulations
- 1.13 Ligaments of costovertebral articulations
- 1.14 Rib and sternum anomalies
- 1.15 Vertebral ends of internal aspect of intercostal spaces

- 1.16 Vertebral ends of external aspect of inferior intercostal spaces
- 1.17 Anterior ends of inferior intercostal spaces
- 1.18 Contents of intercostal space, transverse section
- 1.19 External aspect of thoracic wall
- 1.20 Internal aspect of the anterior thoracic wall
- 1.21 Thoracic contents in situ
- 1.22 Topography of the lungs and mediastinum
- 1.23 Radiograph of chest
- 1.24 Respiratory system
- 1.25 Mediastinum and pericardium
- 1.26 Extent of parietal pleura and lungs
- 1.27 Lungs
- 1.28 Bronchi, pulmonary veins, and pulmonary arteries
- 1.29 Mediastinal (medial) surface and hilum of right lung
- 1.30 Mediastinal (medial) surface and hilum of left lung
- 1.31 Segmental bronchi and bronchopulmonary segments
- 1.32 Trachea and bronchi in situ
- 1.33 Bronchograms
- 1.34 Pulmonary artery, lungs retracted (inferior lobes not included)
- 1.35 Relationship of bronchi and pulmonary arteries
- 1.36 3-D volume reconstruction (3DVR) of pulmonary arteries and veins and left atrium
- 1.37 Innervation of lungs
- 1.38 Lymphatic drainage of lungs
- 1.39 Surface markings of the heart, heart valves, and their auscultation

areas

- 1.40 Surface markings of the heart, lungs, and diaphragm
- 1.41 Heart and great vessels
- 1.42 Pericardium in relation to sternum
- 1.43 Sternocostal (anterior) surface of heart and great vessels in situ
- 1.44 Heart and pericardium
- 1.45 Coronary arteries
- 1.46 Cardiac veins
- 1.47 Coronary arteriograms with orientation drawings
- 1.48 Coronary circulation
- 1.49 Right atrium
- 1.50 Right ventricle
- 1.51 Left atrium and left ventricle
- 1.52 Left ventricle
- 1.53 Excised heart
- 1.54 Pulmonary and aortic valve names
- 1.55 Arrangement of the myocardium and the fibrous skeleton of the heart.
- 1.56 Cardiac cycle
- 1.57 Valves of the heart
- 1.58 Conduction system of heart, coronal section
- 1.59 Posterior relationships of heart and pericardium
- 1.60 Superior mediastinum I: superficial dissection
- 1.61 Relations of great vessels and trachea
- 1.62 Superior mediastinum II: root of neck

- 1.63 Relationship of recurrent laryngeal nerve to the aortic arches
- 1.64 Superior mediastinum III: cardiac plexus and pulmonary arteries
- 1.65 Superior mediastinum IV: tracheal bifurcation and bronchi
- 1.66 Branches of aortic arch
- 1.67 Variations in origins of branches of aortic arch
- 1.68 Scheme of varieties of aortic arches
- 1.69 Superior mediastinum and roof of pleural cavity
- 1.70 Diaphragm and pericardial sac
- 1.71 Esophagus, trachea, and aorta
- 1.72 Arterial supply to trachea and esophagus
- 1.73 Thoracic duct
- 1.74 Lymphatic system
- 1.75 Azygos system of veins
- 1.76 Mediastinum, right side
- 1.77 Mediastinum, left side
- 1.78 Structures of posterior mediastinum
- 1.79 Overview of autonomic innervation of thorax
- 1.80 Overview of lymphatic drainage of thorax
- 1.81 Transverse (axial) MRIs of the thorax (Aâ€F)
- 1.82 Coronal MRIs of the thorax
- 1.83 Sagittal MRIs of the thorax
- 1.84 Transverse or horizontal (axial) 3-D volume reconstructions (on left side of page) and CT angiograms of the thorax (Aâ€F)

Authors: Agur, Anne M.R.; Dalley, Arthur F.

Title: *Grant's Atlas of Anatomy, 12th Edition*

Copyright ©2009 Lippincott Williams & Wilkins

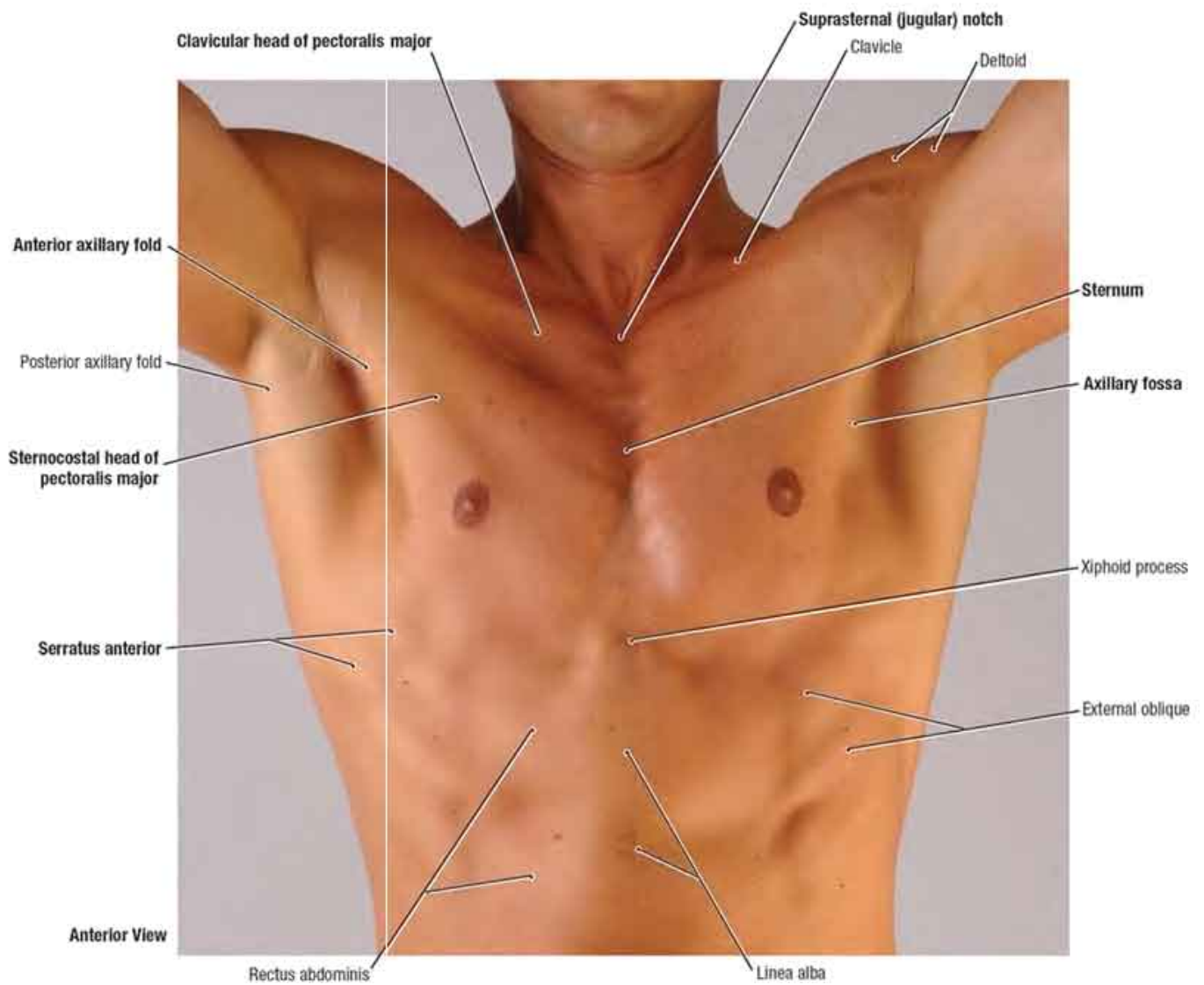
> Table of Contents > Chapter 1 - Thorax > 1.1 Surface anatomy of male pectoral region

---

## 1.1 Surface anatomy of male pectoral region

*Part of* "Chapter 1 - Thorax "

- The subject is adducting the shoulders against resistance to demonstrate the pectoralis major muscle.
- The pectoralis major muscle has two parts, the sternocostal and clavicular heads.
- The anterior axillary fold is formed by the inferior border of the sternocostal head of the pectoralis major muscle.
- The axillary fossa (â€œarmpitâ€•) is a surface feature overlying a fat-filled space, the axilla.



Authors: Agur, Anne M.R.; Dalley, Arthur F.

Title: *Grant's Atlas of Anatomy, 12th Edition*

Copyright ©2009 Lippincott Williams & Wilkins

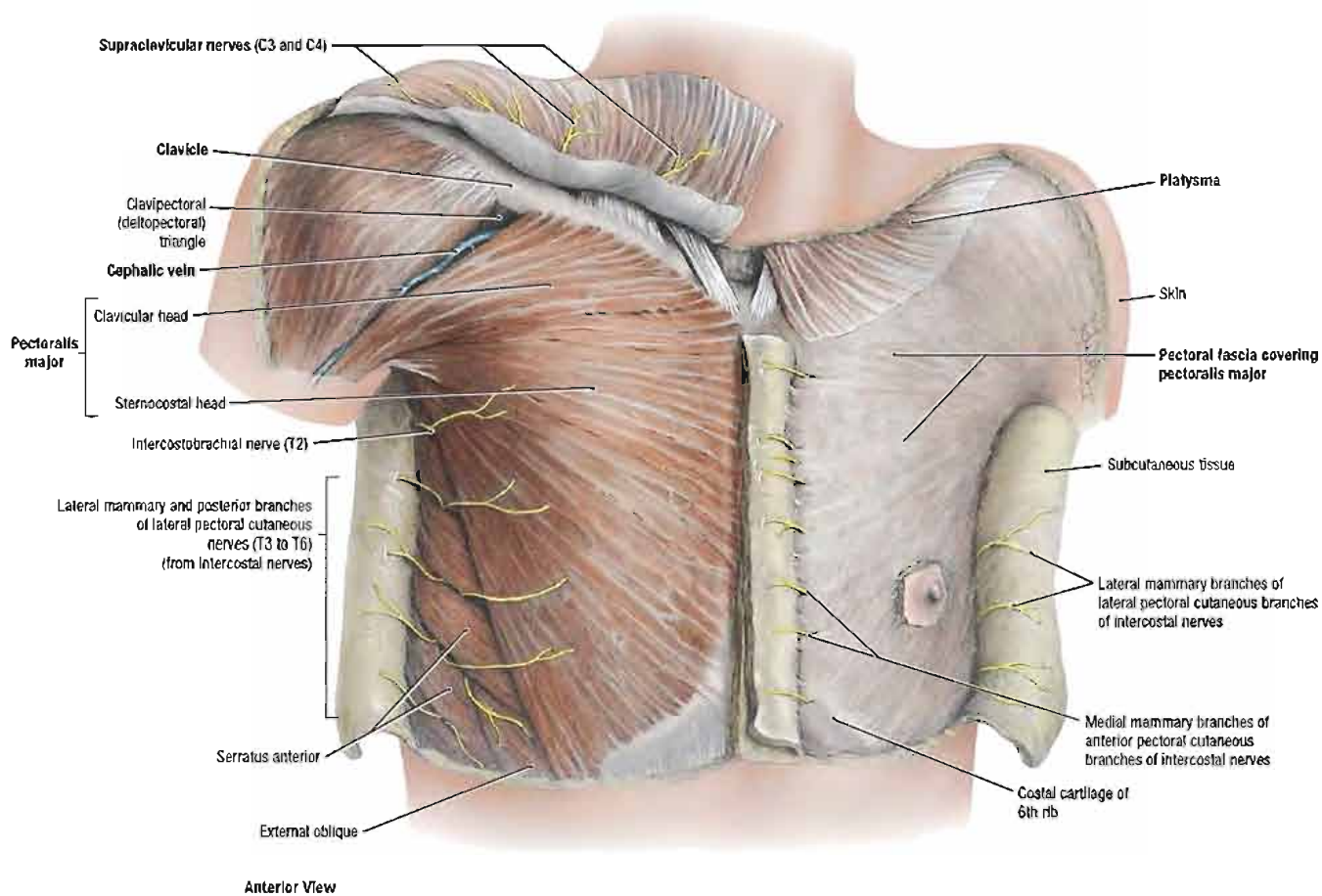
> Table of Contents > Chapter 1 - Thorax > 1.2 Superficial dissection, male pectoral region

---

## 1.2 Superficial dissection, male pectoral region

*Part of* "Chapter 1 - Thorax "

- The platysma muscle, which descends to the 2nd or 3rd rib, is cut short on the right side of the specimen; together with the supraclavicular nerves, it is reflected on the left side.
- The thin pectoral fascia covers the pectoralis major.
- The clavicle lies deep to the subcutaneous tissue and the platysma muscle.
- The cephalic vein passes deeply in the clavipectoral (deltopectoral) triangle to join the axillary vein.
- Supraclavicular (C3 and C4) and upper thoracic nerves (T2 to T6) supply cutaneous innervation to the pectoral region.
- The clavipectoral (deltopectoral) triangle, bounded by the clavicle superiorly, the deltoid muscle laterally, and the clavicular head of the pectoralis major muscle medially, underlies a surface depression called the infraclavicular fossa.





Authors: Agur, Anne M.R.; Dalley, Arthur F.

Title: *Grant's Atlas of Anatomy, 12th Edition*

Copyright ©2009 Lippincott Williams & Wilkins

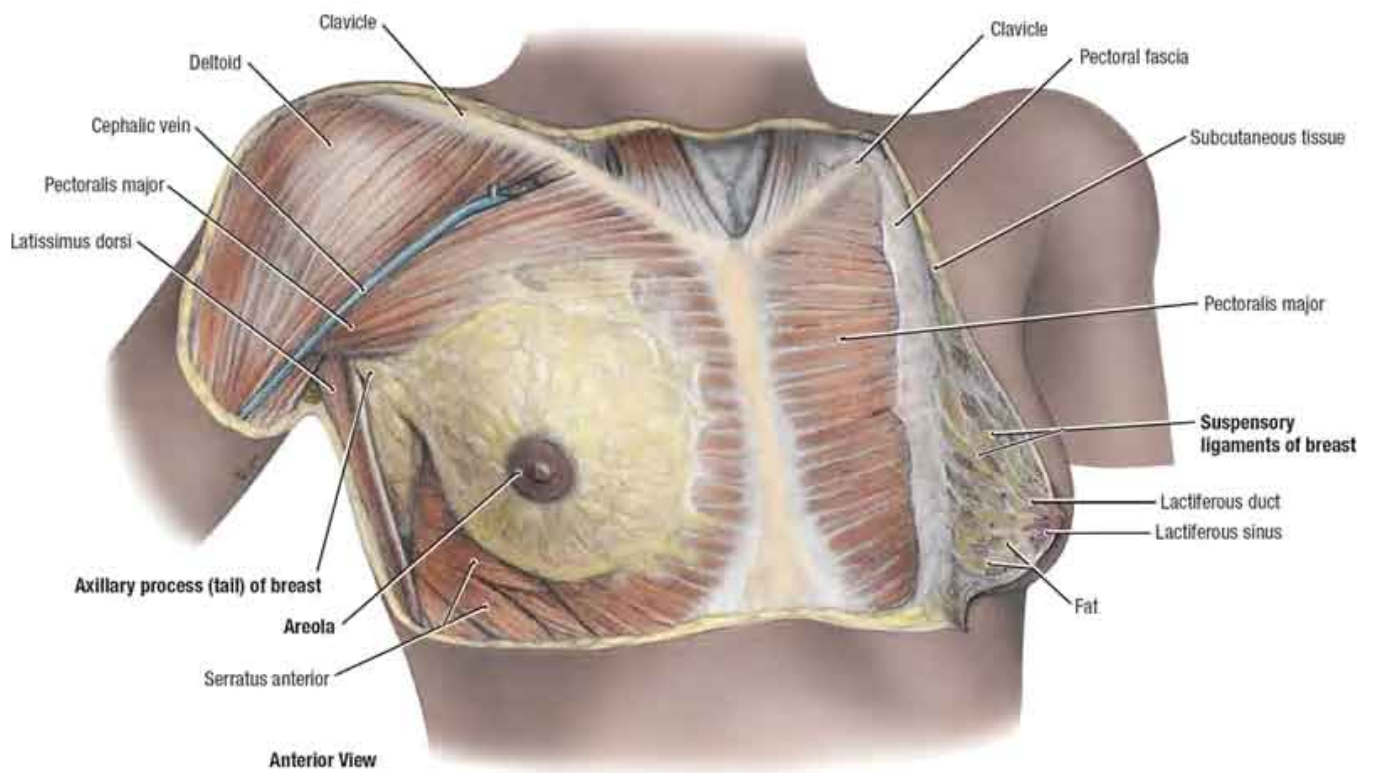
> Table of Contents > Chapter 1 - Thorax > 1.3 Superficial dissection, female pectoral region

---

## 1.3 Superficial dissection, female pectoral region

Part of "Chapter 1 - Thorax "

- On the specimen's right side, the skin is removed; on the left side, the breast is sagittally sectioned.
  - The breast extends from the 2nd to the 6th ribs. The axillary process (tail) of the breast consists of glandular tissue projecting toward the axilla.
  - The region of loose connective tissue between the pectoral fascia and the deep surface of the breast, the retromammary bursa, permits the breast to move on the deep fascia.
- Interference with the lymphatic drainage by cancer may cause lymphedema (edema, excess fluid in the subcutaneous tissue), which in turn may result in deviation of the nipple and a leathery, thickened appearance of the breast skin. Prominent (puffy) skin between dimpled pores may develop, which gives the skin an orange-peel appearance (*peau d'orange sign*). Larger dimples may form if pulled by cancerous invasion of the suspensory ligaments of the breast.



Authors: Agur, Anne M.R.; Dalley, Arthur F.

Title: *Grant's Atlas of Anatomy, 12th Edition*

Copyright ©2009 Lippincott Williams & Wilkins

> Table of Contents > Chapter 1 - Thorax > 1.4 Female mammary gland

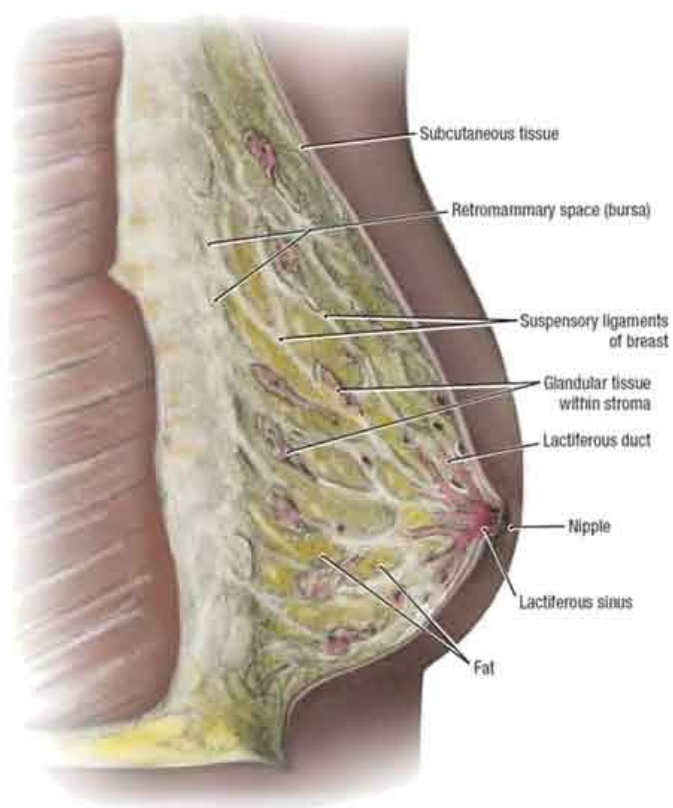
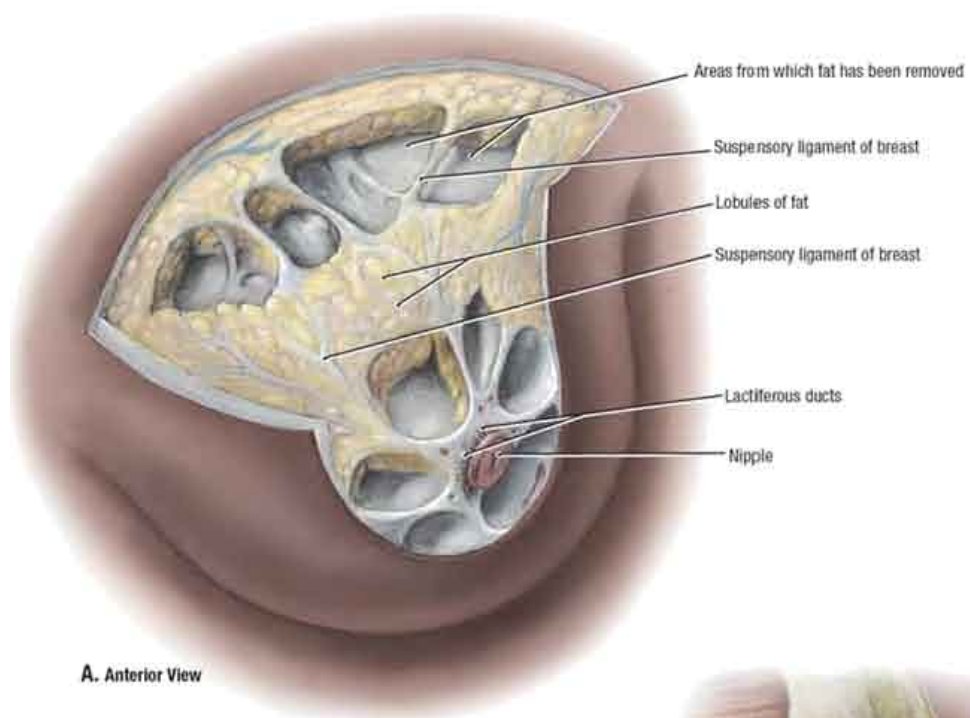
---

## 1.4 Female mammary gland

*Part of* "Chapter 1 - Thorax "

A. The breast consists primarily of fat compartmentalized between connective and glandular tissue septa. The lactiferous ducts (usually 15 to 20 in number) expand to form subareolar lactiferous sinuses and then open on the nipple; the glandular tissue lies within a dense (fibro-) areolar stroma, from which suspensory ligaments extend to the deeper layers of the skin. Areas of superficial fat were scooped out from some compartments between the septa. B. Structure of the breast revealed by sagittal section.

Cancer can spread by contiguity (invasion of adjacent tissue). When breast cancer cells invade the retromammary space, attach to or invade the pectoral fascia overlaying the pectoralis major muscle, or metastasize to the interpectoral nodes (Fig. 1.8 ), the breast elevates when the muscle contracts. This movement is a clinical sign of advanced breast cancer.



Authors: Agur, Anne M.R.; Dalley, Arthur F.

Title: *Grant's Atlas of Anatomy, 12th Edition*

Copyright ©2009 Lippincott Williams & Wilkins

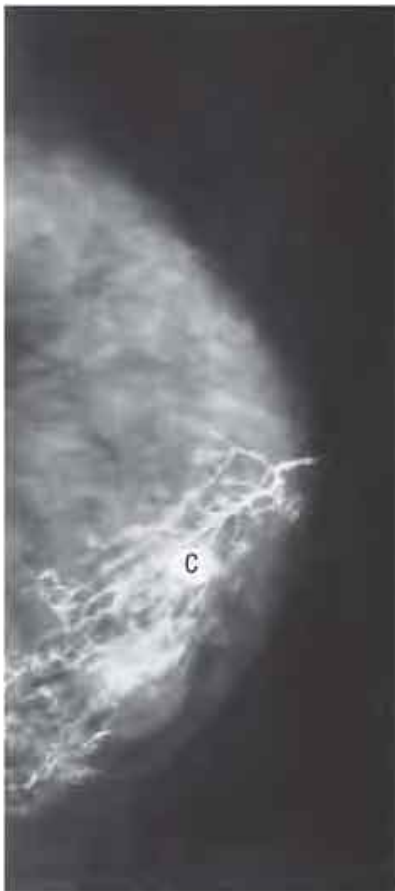
> Table of Contents > Chapter 1 - Thorax > 1.5 Imaging of breast

---

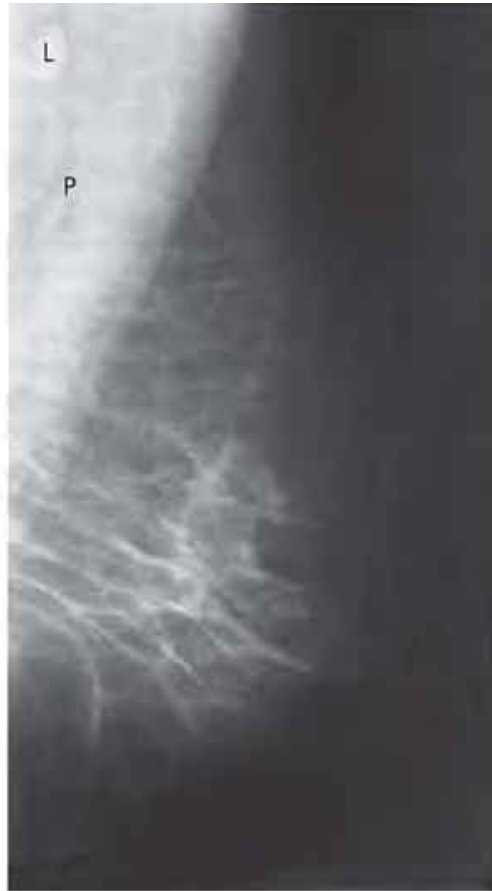## 1.5 Imaging of breast

*Part of* "Chapter 1 - Thorax "

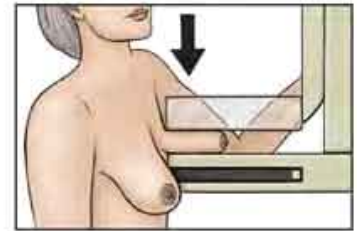
A. Galactogram. Contrast has been injected into a lactiferous duct, outlining the branching pattern of its tributaries. Note the presence of a ductal cyst (*C*). B. Normal mammogram. Observe the connective tissue network of the breast. The stroma is radiopaque and changes with age and during lactation. Pectoralis major muscle (*P*) and an axillary lymph node (*L*) can also be seen. C. Axial computed tomographic (CT) scan at the level of the female breasts (T9 level).



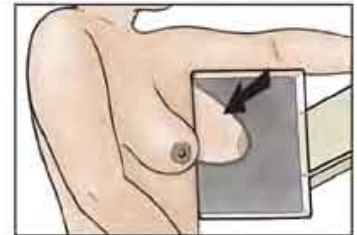A. Superior View



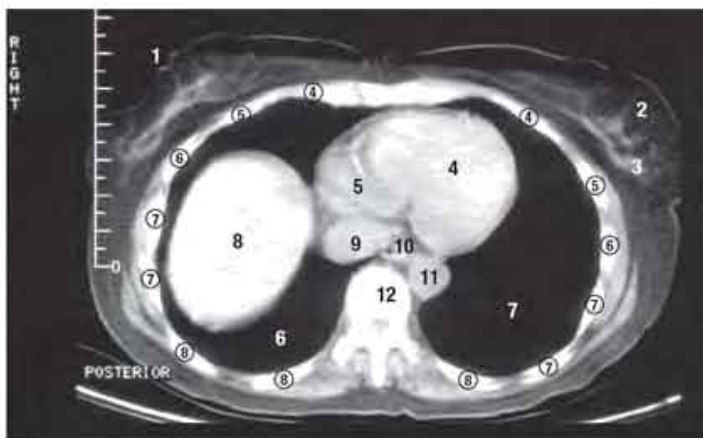
B. Lateral View



Orientation for Part A



Orientation for Part B



C. Inferior View

**Structures in Part C:**

- 1 Nipple
- 2 Lactiferous ducts
- 3 Suspensory ligaments
- 4 Left ventricle
- 5 Right atrium
- 6 Right lung
- 7 Left lung
- 8 Liver
- 9 Inferior vena cava
- 10 Esophagus
- 11 Descending aorta
- 12 T9 vertebra
- ⑥ Corresponding rib numbers
- ⑦ Corresponding rib numbers

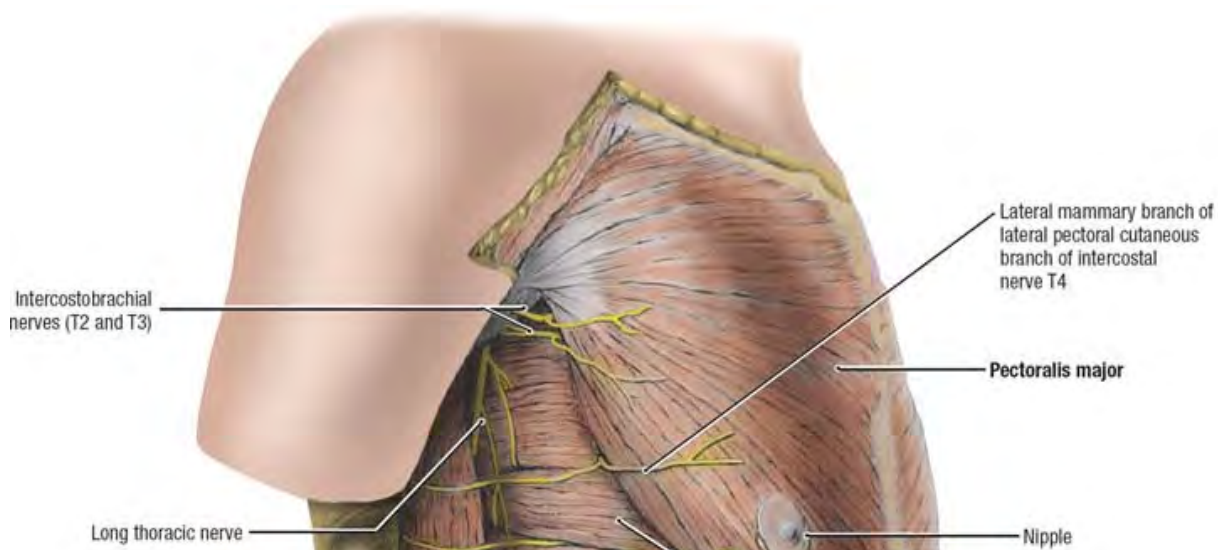
## 1.6 Bed of breast

Part of "Chapter 1 - Thorax "

A. Muscles comprising bed of breast and cutaneous nerves. B. Dermatomes extending across bed of breast.

Local anesthesia of an intercostal space (intercostal nerve block) is produced by injecting a local anesthetic agent around the intercostal nerves between the paravertebral line and the area of required anesthesia. Because any particular area of skin usually receives innervation from two adjacent nerves, considerable overlapping of contiguous dermatomes occurs. Therefore, complete loss of sensation usually does not occur unless two or more intercostal nerves are anesthetized.

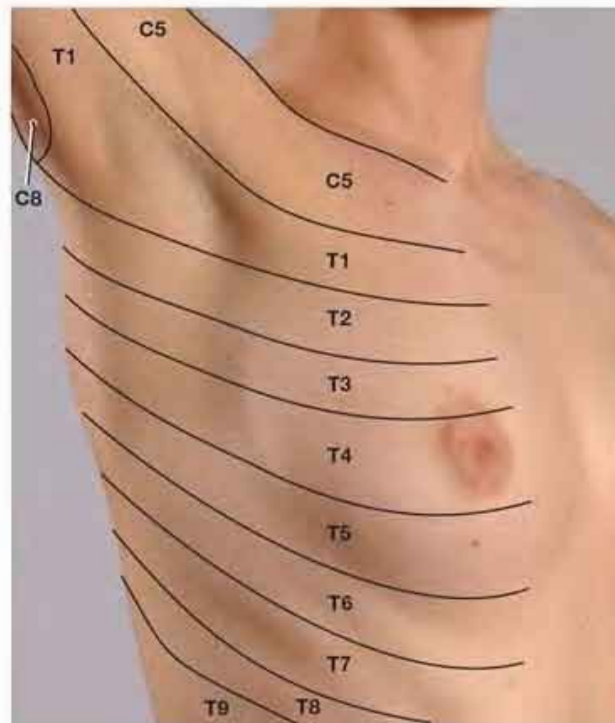
P.8







**A. Anterolateral View**



**B. Anterolateral View**



Authors: Agur, Anne M.R.; Dalley, Arthur F.

Title: *Grant's Atlas of Anatomy, 12th Edition*

Copyright ©2009 Lippincott Williams & Wilkins

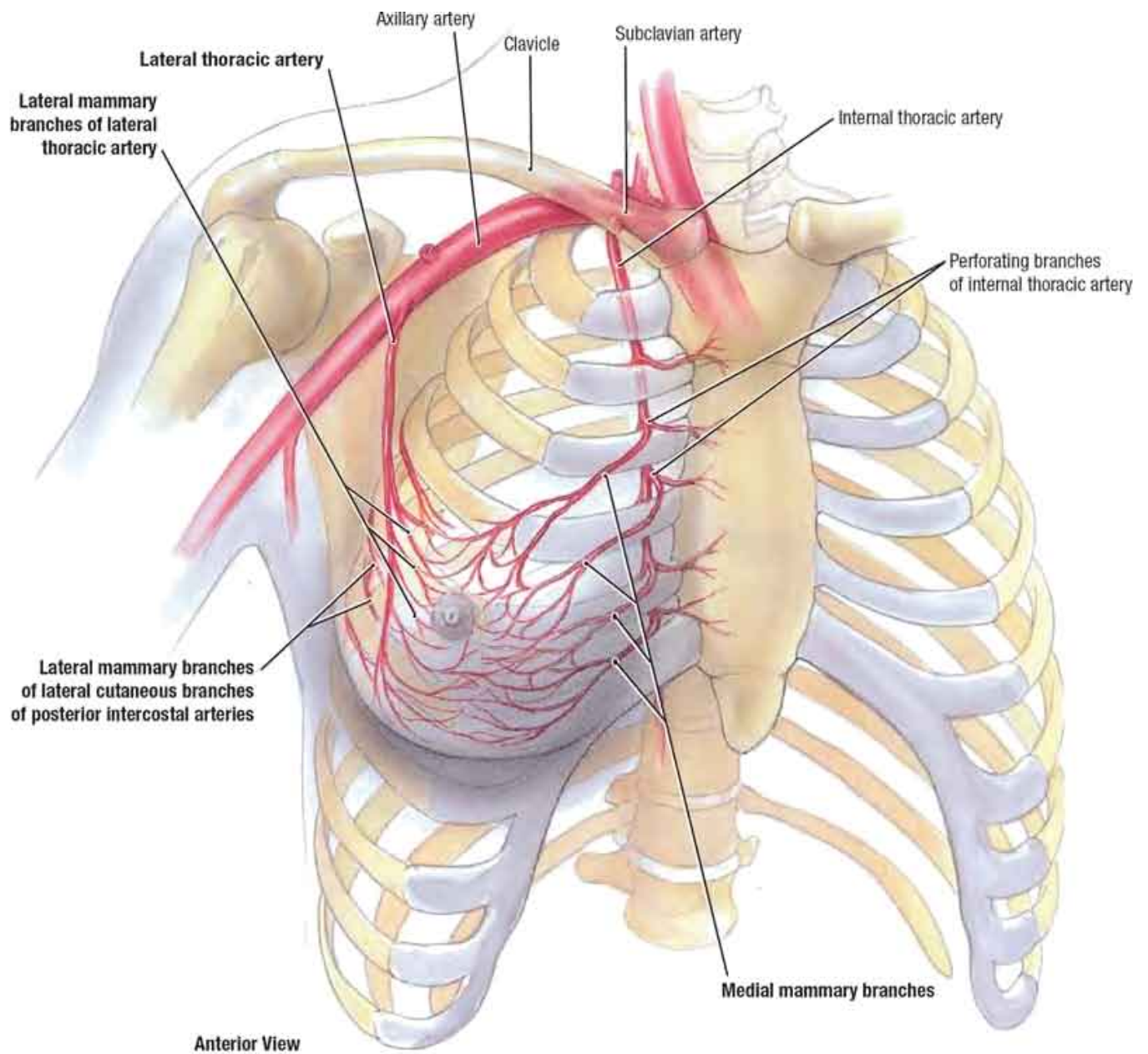
> Table of Contents > Chapter 1 - Thorax > 1.7 Arterial supply of the breast

---

## 1.7 Arterial supply of the breast

*Part of* "Chapter 1 - Thorax "

Arteries enter the breast from its superomedial and superolateral aspects; vessels also penetrate the deep surface of the breast. The blood supply is from the medial mammary branches of the internal thoracic artery, lateral mammary branches from the lateral thoracic artery, and lateral mammary branches of lateral cutaneous branches of the posterior intercostal arteries. The arteries branch profusely and anastomose with each other.



Authors: Agur, Anne M.R.; Dalley, Arthur F.

Title: *Grant's Atlas of Anatomy, 12th Edition*

Copyright ©2009 Lippincott Williams & Wilkins

> Table of Contents > Chapter 1 - Thorax > 1.8 Lymphatic drainage of breast

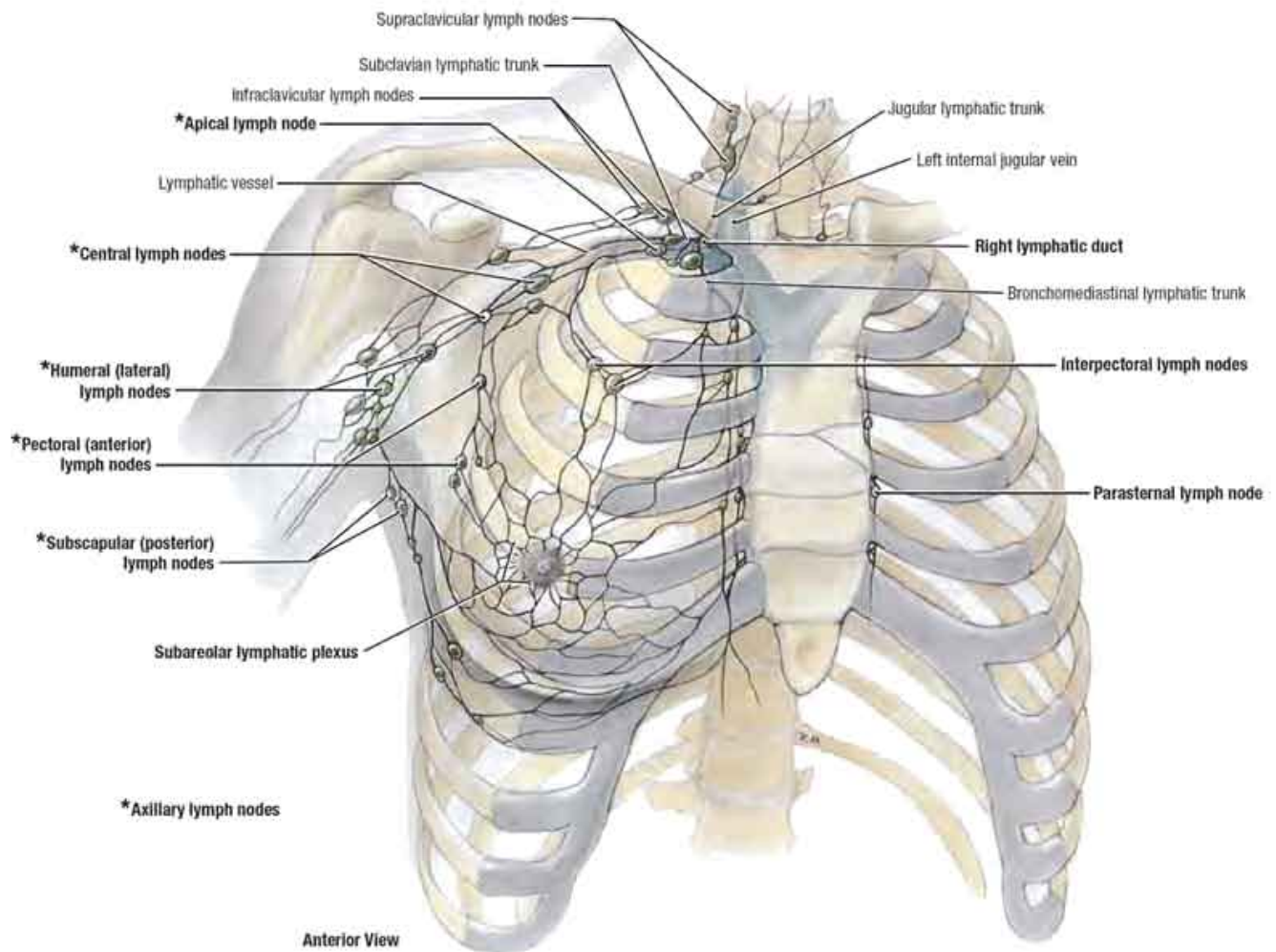
---

## 1.8 Lymphatic drainage of breast

*Part of* "Chapter 1 - Thorax "

Lymph drained from the upper limb and breast passes through nodes arranged irregularly in groups of axillary lymph nodes: (a) pectoral, along the inferior border of the pectoralis minor muscle; (b) subscapular, along the subscapular artery and veins; (c) humeral, along the distal part of the axillary vein; (d) central, at the base of the axilla, embedded in axillary fat; and (e) apical, along the axillary vein between the clavicle and the pectoralis minor muscle. Most of the breast drains via the pectoral, central, and apical axillary nodes to the subclavian lymph trunk, which joins the venous system at the junction of the subclavian and internal jugular veins. The medial part of the breast drains to the parasternal nodes, which are located along the internal thoracic vessels.

Breast cancer typically spreads by means of lymphatic vessels (lymphogenic metastasis), which carry cancer cells from the breast to the lymph nodes, chiefly those in the axilla. The cells lodge in the nodes, producing nests of tumor cells (metastases). Abundant communications among lymphatic pathways and among axillary, cervical, and parasternal nodes may also cause metastases from the breast to develop in the supraclavicular lymph nodes, the opposite breast, or the abdomen.



Authors: Agur, Anne M.R.; Dalley, Arthur F.

Title: *Grant's Atlas of Anatomy, 12th Edition*

Copyright ©2009 Lippincott Williams & Wilkins

> Table of Contents > Chapter 1 - Thorax > 1.9 Bony thorax

---

## 1.9 Bony thorax

*Part of* "Chapter 1 - Thorax "

- The skeleton of the thorax consists of 12 thoracic vertebrae, 12 pairs of ribs and costal cartilages, and the sternum.
- Anteriorly, forming the costal margin, the superior seven costal cartilages articulate with the sternum; the 8th, 9th, and 10th cartilages articulate with the cartilage above; the 11th and 12th are "floating" ribs, i.e., their cartilages do not articulate anteriorly.
- The clavicle lies over the anterosuperior aspect of the 1st rib, making it difficult to palpate.
- The 2nd rib is easy to locate because its costal cartilage articulates with the sternum at the sternal angle, located at the junction of the manubrium and body of the sternum.
- The 3rd to 10th ribs can be palpated in sequence inferolaterally from the 2nd rib; the fused costal cartilages of the 7th to 10th ribs form the costal arch (margin), and the tips of the 11th and 12th ribs can be palpated posterolaterally.

---

P.11

- The superior thoracic aperture (thoracic inlet) is the doorway between the thoracic cavity and the neck region; it is bounded by the 1st thoracic vertebra, the 1st ribs and their cartilages, and the manubrium of the sternum.
- Each rib articulates posteriorly with the vertebral column.
- Posteriorly, all ribs angle inferiorly; anteriorly, the 3rd to 10th costal cartilages

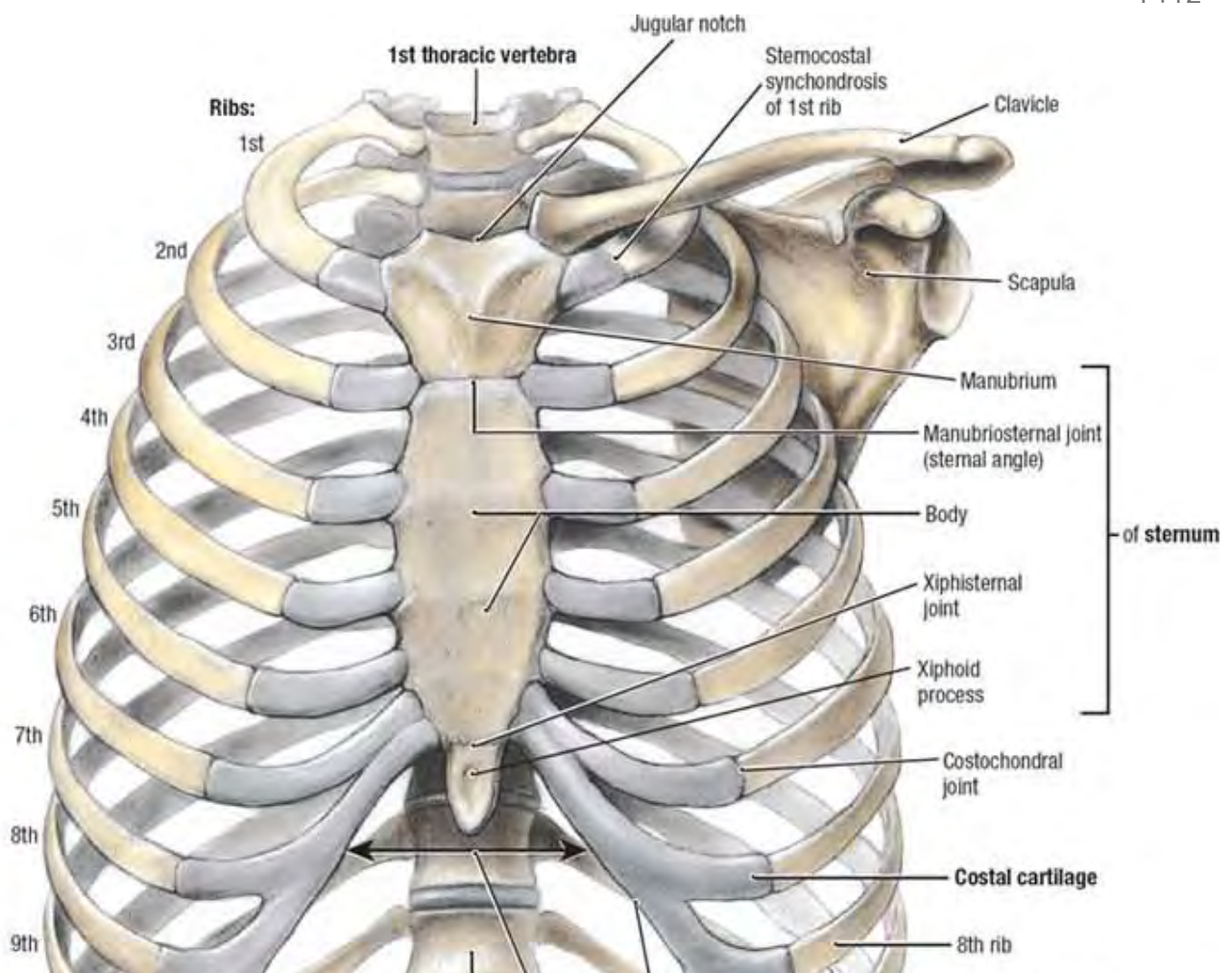


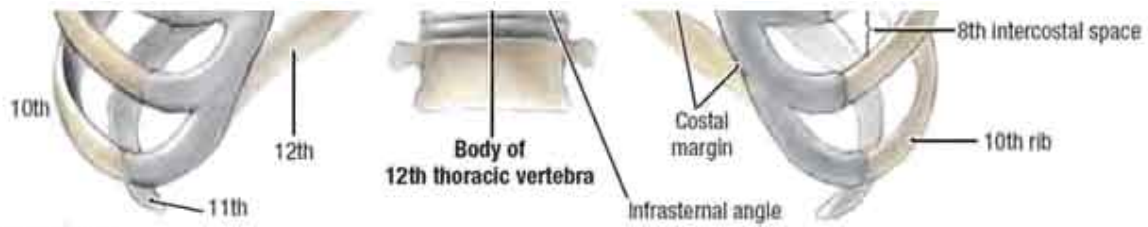
angle superiorly.

- The scapula is suspended from the clavicle and crosses the 2nd to 7th ribs.

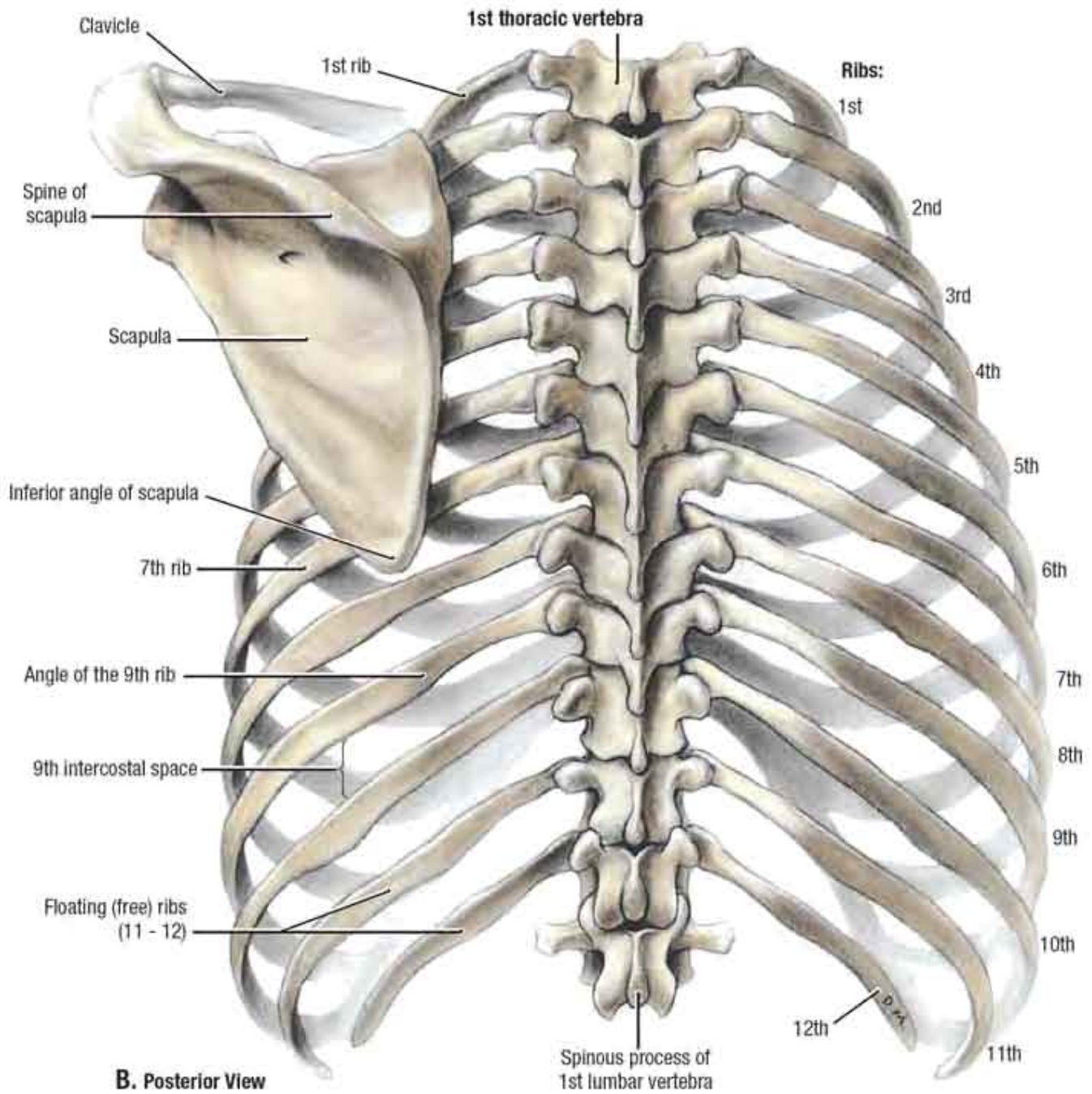
- When clinicians refer to the superior thoracic aperture as the thoracic “outlet,” they are emphasizing the important nerves and arteries that pass through this aperture into the lower neck and upper limb. Hence, various types of thoracic outlet syndromes exist, such as the costoclavicular syndrome “pallor and coldness of the skin of the upper limb and diminished radial pulse” resulting from compression of the subclavian artery between the clavicle and the 1st rib.

P.12





**A. Anterior View**



**B. Posterior View**

Authors: Agur, Anne M.R.; Dalley, Arthur F.

Title: *Grant's Atlas of Anatomy, 12th Edition*

Copyright ©2009 Lippincott Williams & Wilkins

> Table of Contents > Chapter 1 - Thorax > 1.10 Sternum and associated joints

---

## 1.10 Sternum and associated joints

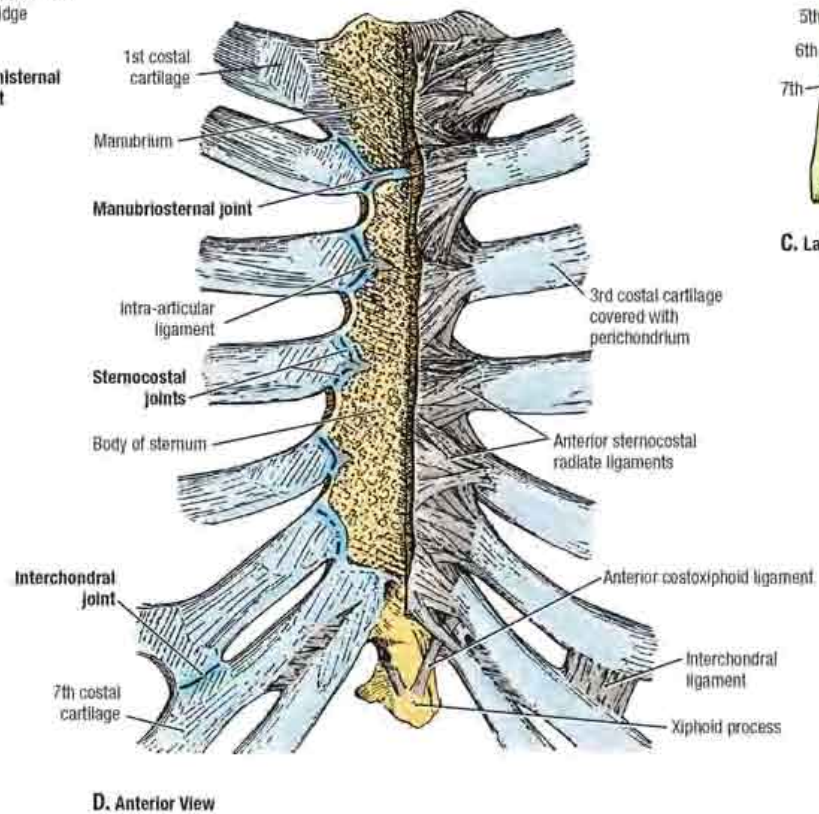
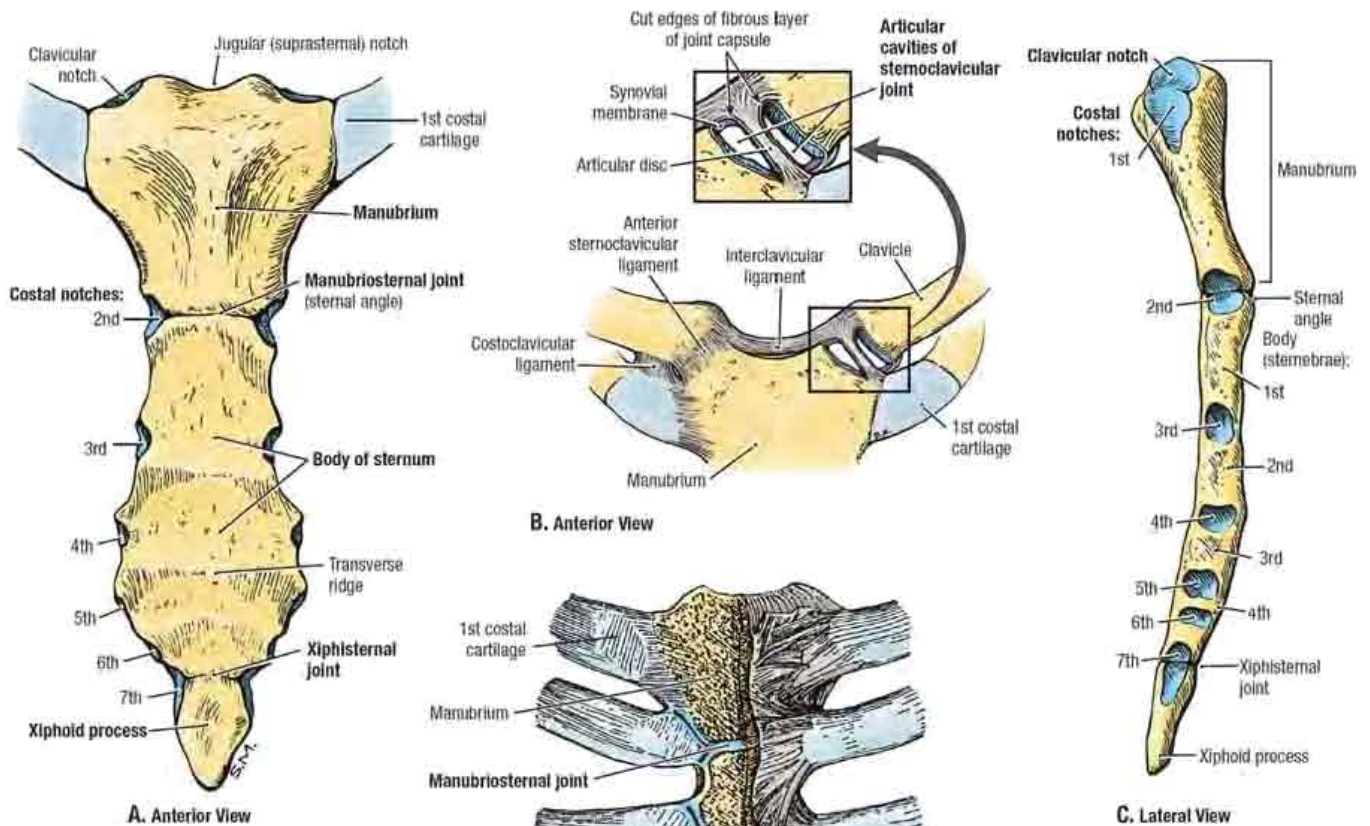
*Part of* "Chapter 1 - Thorax "

A. Parts of the anterior aspect of the sternum. B. Sternoclavicular joint. C. Features of the lateral aspect of the sternum. D. Sternocostal, manubriosternal, and interchondral joints. On the right side of the specimen, the cortex of the sternum and the external surface of the costal cartilages have been shaved away.

---

P.13





Authors: Agur, Anne M.R.; Dalley, Arthur F.

Title: *Grant's Atlas of Anatomy, 12th Edition*

Copyright ©2009 Lippincott Williams & Wilkins

> Table of Contents > Chapter 1 - Thorax > 1.11 Ribs

---

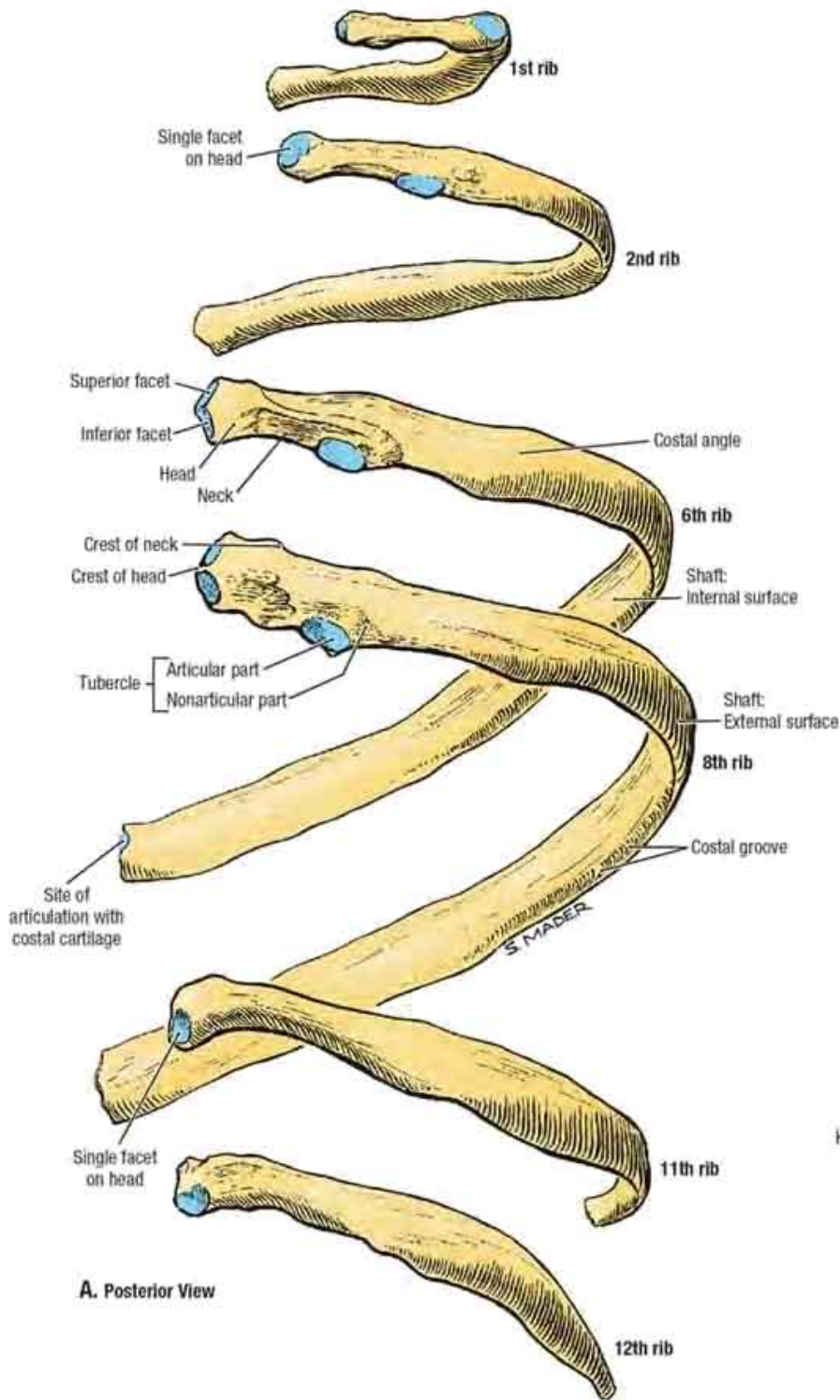
## 1.11 Ribs

*Part of* "Chapter 1 - Thorax "

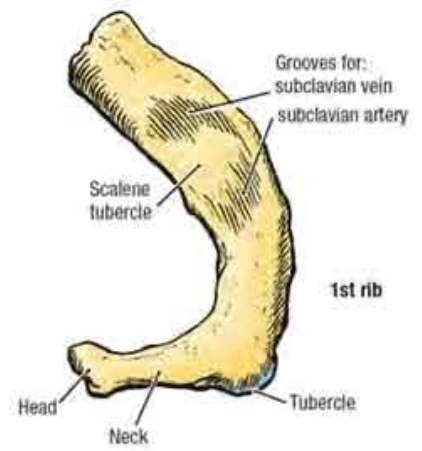
A. "Typical" (6th and 8th) and "atypical" (1st and 2nd, 11th and 12th) ribs. B. First rib. C. Second rib.

---

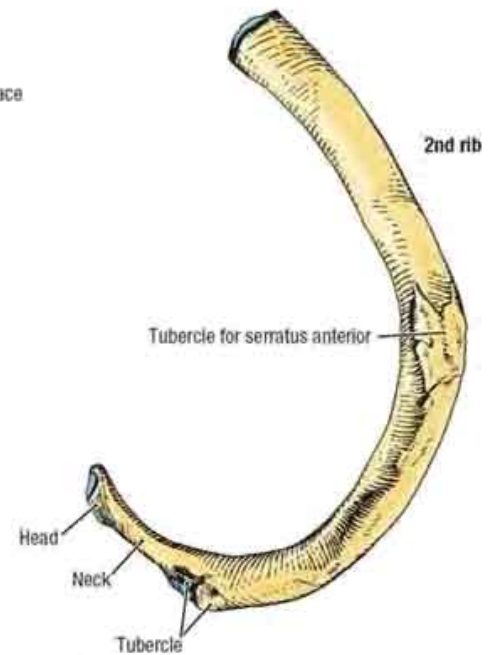
P.14



**A. Posterior View**



**B. Superior View**



**C. Superior View**

Authors: Agur, Anne M.R.; Dalley, Arthur F.

Title: *Grant's Atlas of Anatomy, 12th Edition*

Copyright ©2009 Lippincott Williams & Wilkins

> Table of Contents > Chapter 1 - Thorax > 1.12 Costovertebral articulations

---

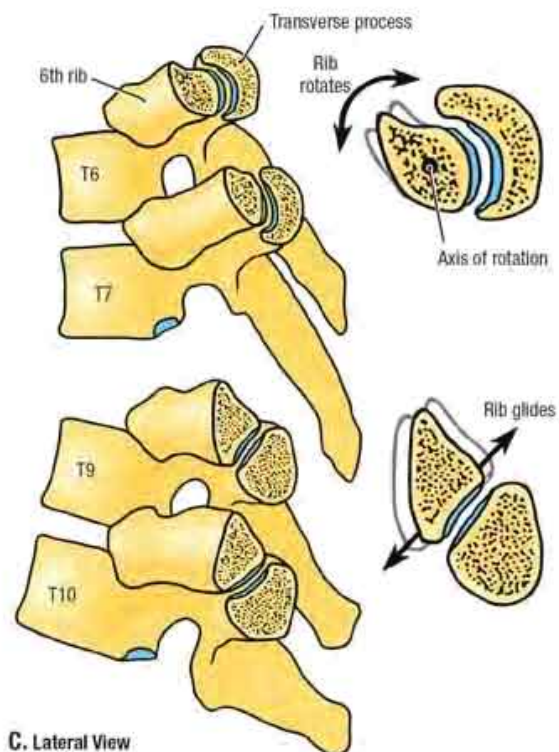
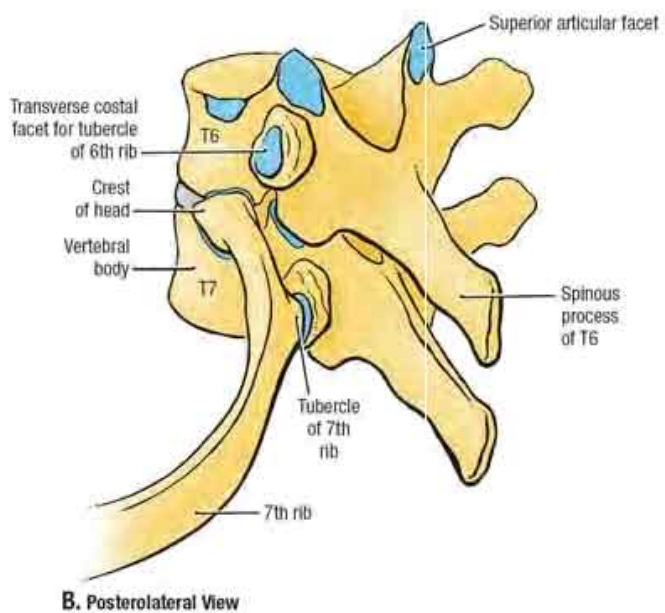
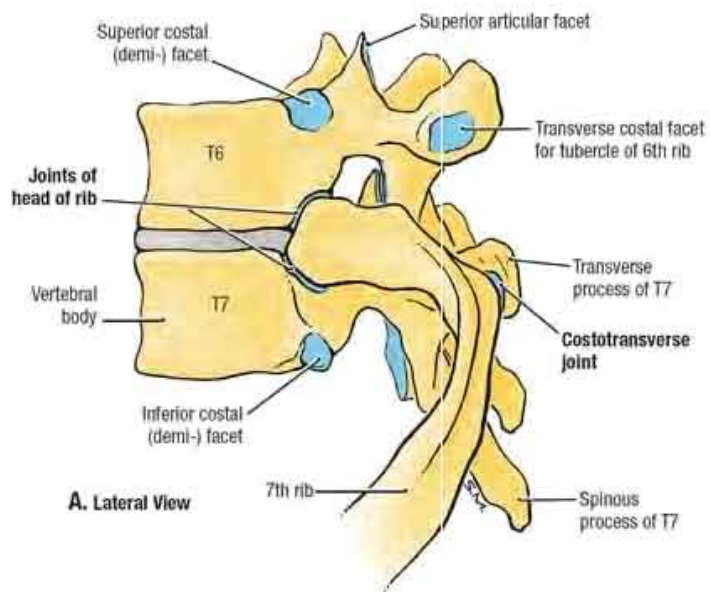
## 1.12 Costovertebral articulations

*Part of* "Chapter 1 - Thorax "

A and B. Articulating structures

- The costovertebral articulations include the joints of the head of the rib with two adjacent vertebral bodies and the tubercle of the rib with the transverse process of a vertebra.
- There are two articular facets on the head of the rib: a larger, inferior costal facet for articulation with the vertebral body of its own number, and a smaller, superior costal facet for articulation with the vertebral body of the vertebra superior to the rib.
- The crest of the head of the rib separates the superior and inferior costal facets.
- The smooth articular part of the tubercle of the rib, the transverse costal facet, articulates with the transverse process of the same numbered vertebra at the costotransverse joint.
- C. Movements at the costotransverse joints: At the 1st to 7th costotransverse joints, the ribs rotate, increasing the anteroposterior diameter of the thorax; at the 8th, 9th, and 10th, they glide, increasing the transverse diameter of the upper abdomen.





Authors: Agur, Anne M.R.; Dalley, Arthur F.

Title: *Grant's Atlas of Anatomy, 12th Edition*

Copyright ©2009 Lippincott Williams & Wilkins

> Table of Contents > Chapter 1 - Thorax > 1.13 Ligaments of costovertebral articulations

---

## 1.13 Ligaments of costovertebral articulations

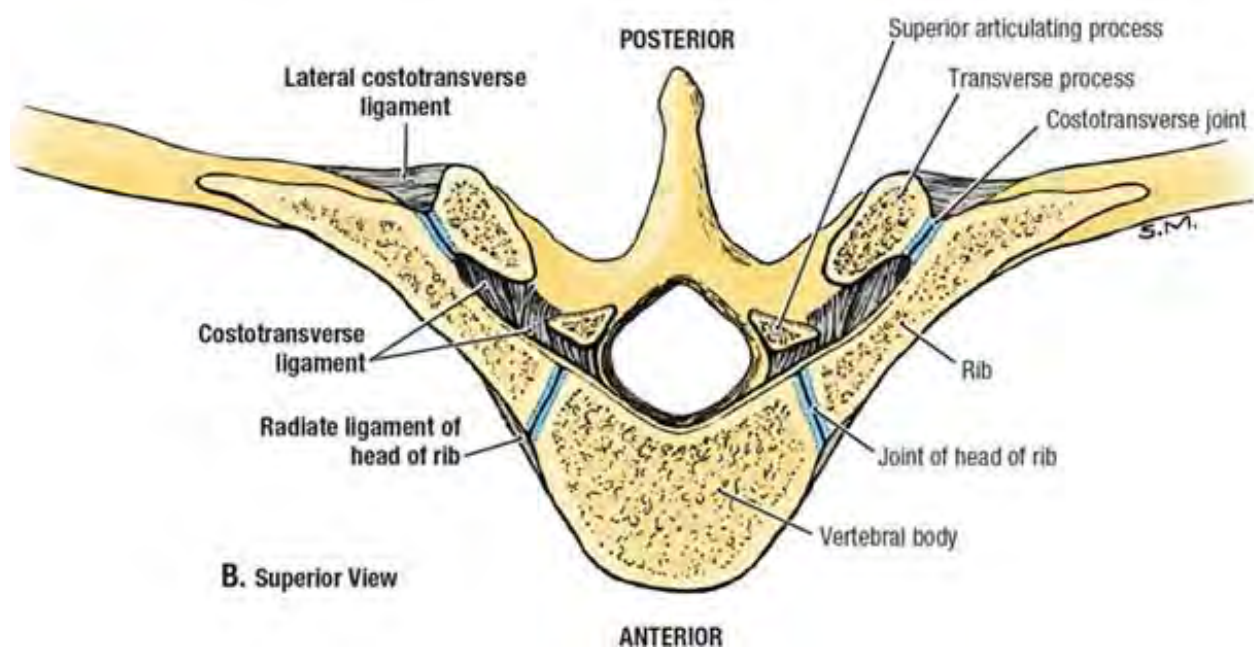
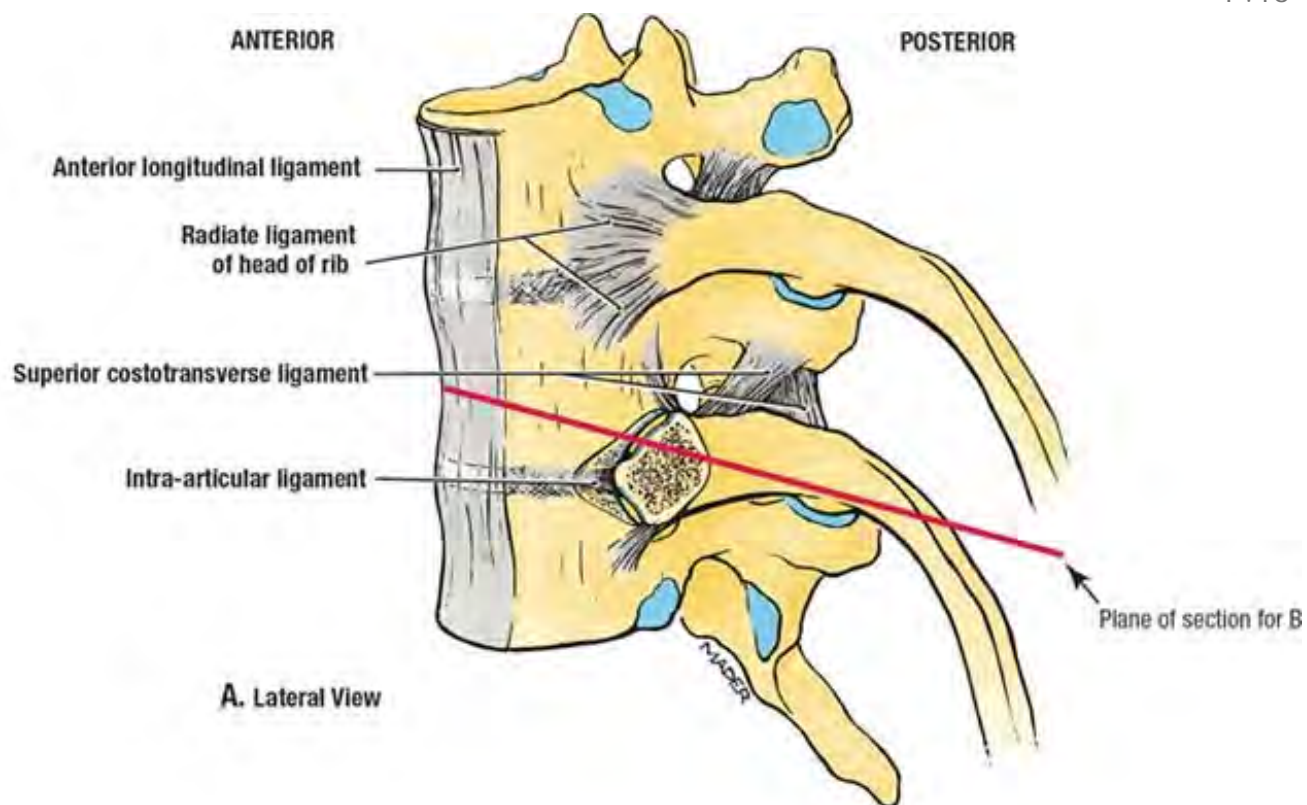
*Part of* "Chapter 1 - Thorax "

A.

- The radiate ligament joins the head of the rib to two vertebral bodies and the interposed intervertebral disc.
- The superior costotransverse ligament joins the crest of the neck of the rib to the transverse process above.
- The intra-articular ligament joins the crest of the head of the rib to the intervertebral disc.

B.

- The vertebral body, transverse processes, superior articulating processes, and posterior elements of the articulating ribs have been transversely sectioned to visualize the joint surfaces and ligaments.
- The costotransverse ligament joins the posterior aspect of the neck of the rib to the adjacent transverse process.
- The lateral costotransverse ligament joins the nonarticulating part of the tubercle of the rib to the tip (apex) of the transverse process.
- The articular surfaces of the synovial plane costovertebral joints are colored blue.



Authors: Agur, Anne M.R.; Dalley, Arthur F.

Title: *Grant's Atlas of Anatomy, 12th Edition*

Copyright ©2009 Lippincott Williams & Wilkins

> Table of Contents > Chapter 1 - Thorax > 1.14 Rib and sternum anomalies

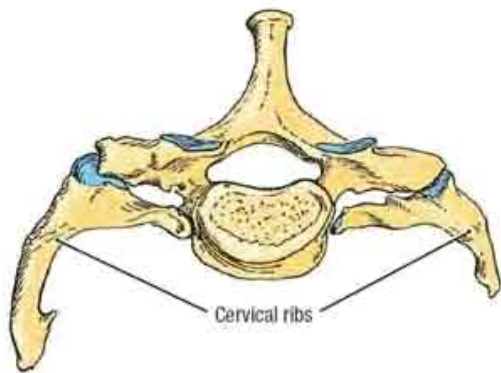
---

## 1.14 Rib and sternum anomalies

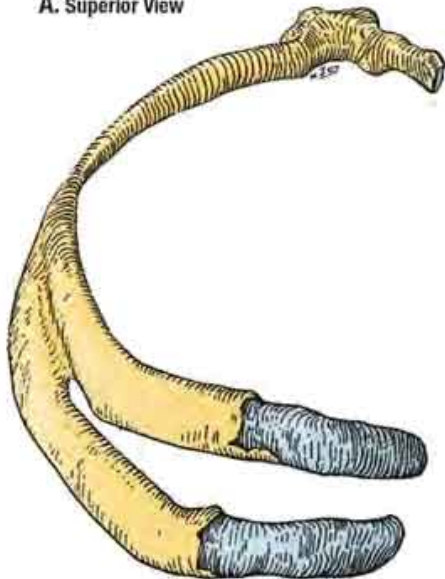
*Part of* "Chapter 1 - Thorax "

A. Cervical ribs. This is an enlarged costal element of the 7th cervical vertebra. (Compare with diagrammatic cervical vertebra in D. ) Cervical ribs can be unilateral or bilateral, and large and palpable or detectable only radiologically. It can be asymptomatic or, through pressure on the most inferior root of the brachial plexus, can produce sensory and motor changes over the distribution of the ulnar nerve. B. Bifid rib. The superior component of this 3rd rib is supernumerary and articulated with the lateral aspect of the 1st sternebra. The inferior component articulated at the junction of the 1st and 2nd sternebrae. C. Bicipital rib. In this specimen, there has been partial fusion of the first two thoracic ribs. E. Sternal foramen. F. Ossification of sternum.

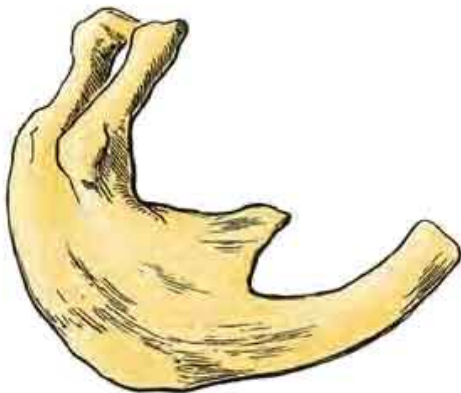




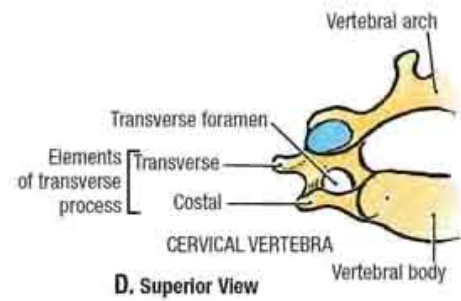
**A. Superior View**



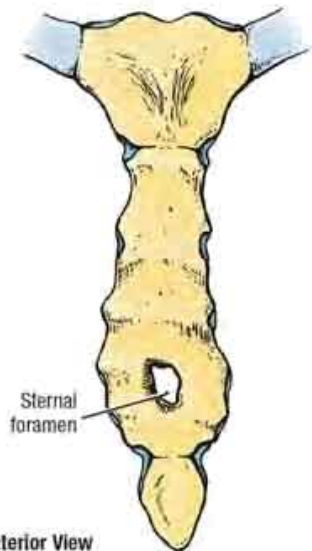
**B. Anterior View**



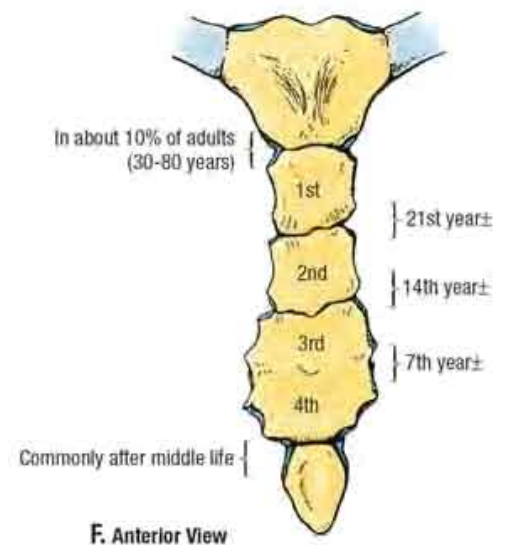**C. Superior View**



**D. Superior View**



**E. Anterior View**



**F. Anterior View**

Authors: Agur, Anne M.R.; Dalley, Arthur F.

Title: *Grant's Atlas of Anatomy, 12th Edition*

Copyright ©2009 Lippincott Williams & Wilkins

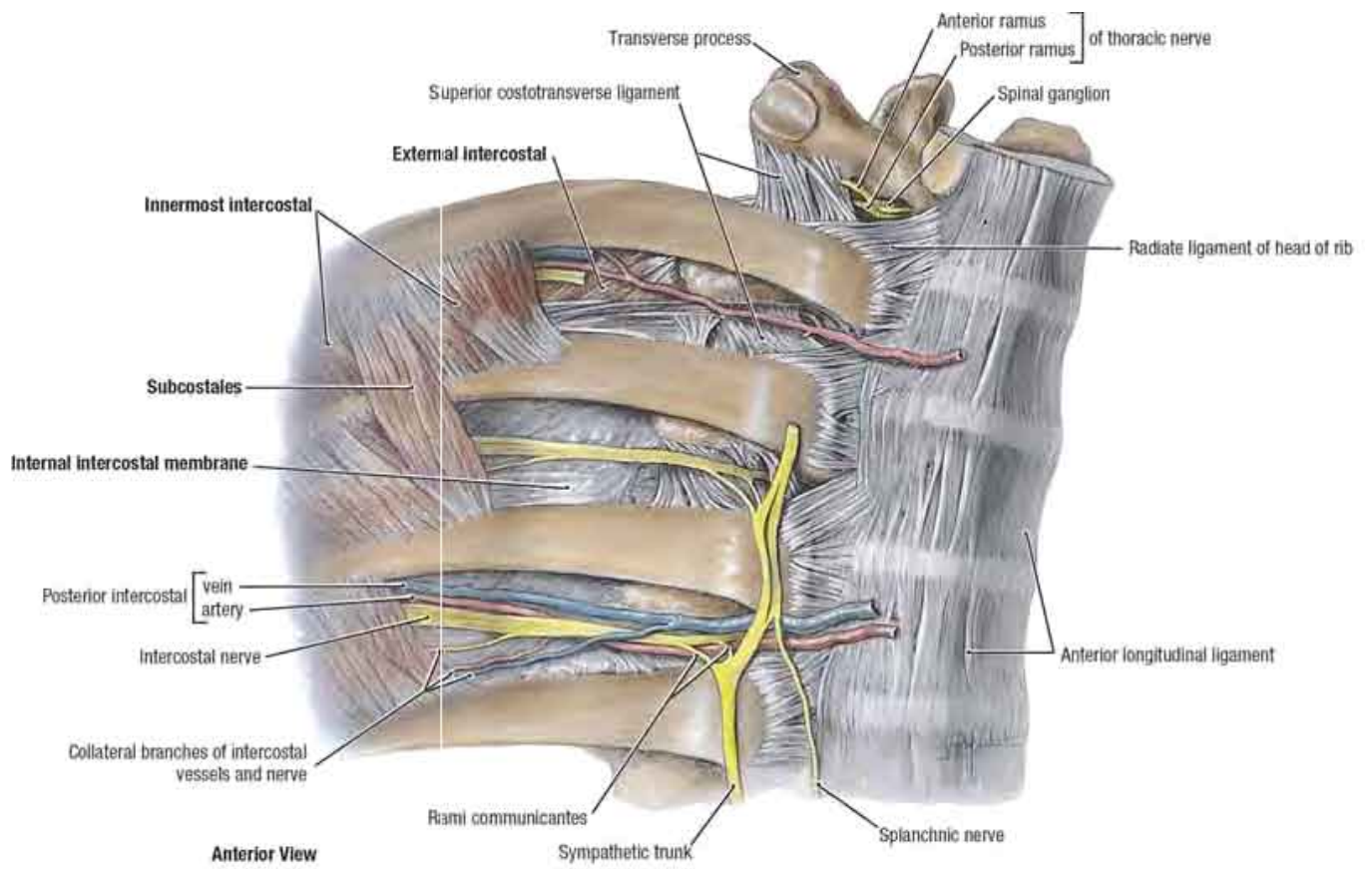
> Table of Contents > Chapter 1 - Thorax > 1.15 Vertebral ends of internal aspect of intercostal spaces

---

## 1.15 Vertebral ends of internal aspect of intercostal spaces

*Part of "Chapter 1 - Thorax "*

- Portions of the innermost intercostal muscle that bridge two intercostal spaces are called subcostales muscles.
- The internal intercostal membrane, in the middle space, is continuous medially with the superior costotransverse ligament.
- Note the order of the structures in the most inferior space: posterior intercostal vein and artery, and intercostal nerve; note also their collateral branches.
- The anterior ramus crosses anterior to the superior costotransverse ligament; the posterior ramus is posterior to it.
- The intercostal nerves attach to the sympathetic trunk by rami communicantes; the splanchnic nerve is a visceral branch of the trunk.



Authors: Agur, Anne M.R.; Dalley, Arthur F.

Title: *Grant's Atlas of Anatomy, 12th Edition*

Copyright ©2009 Lippincott Williams & Wilkins

> Table of Contents > Chapter 1 - Thorax > 1.16 Vertebral ends of external aspect of inferior intercostal spaces

---

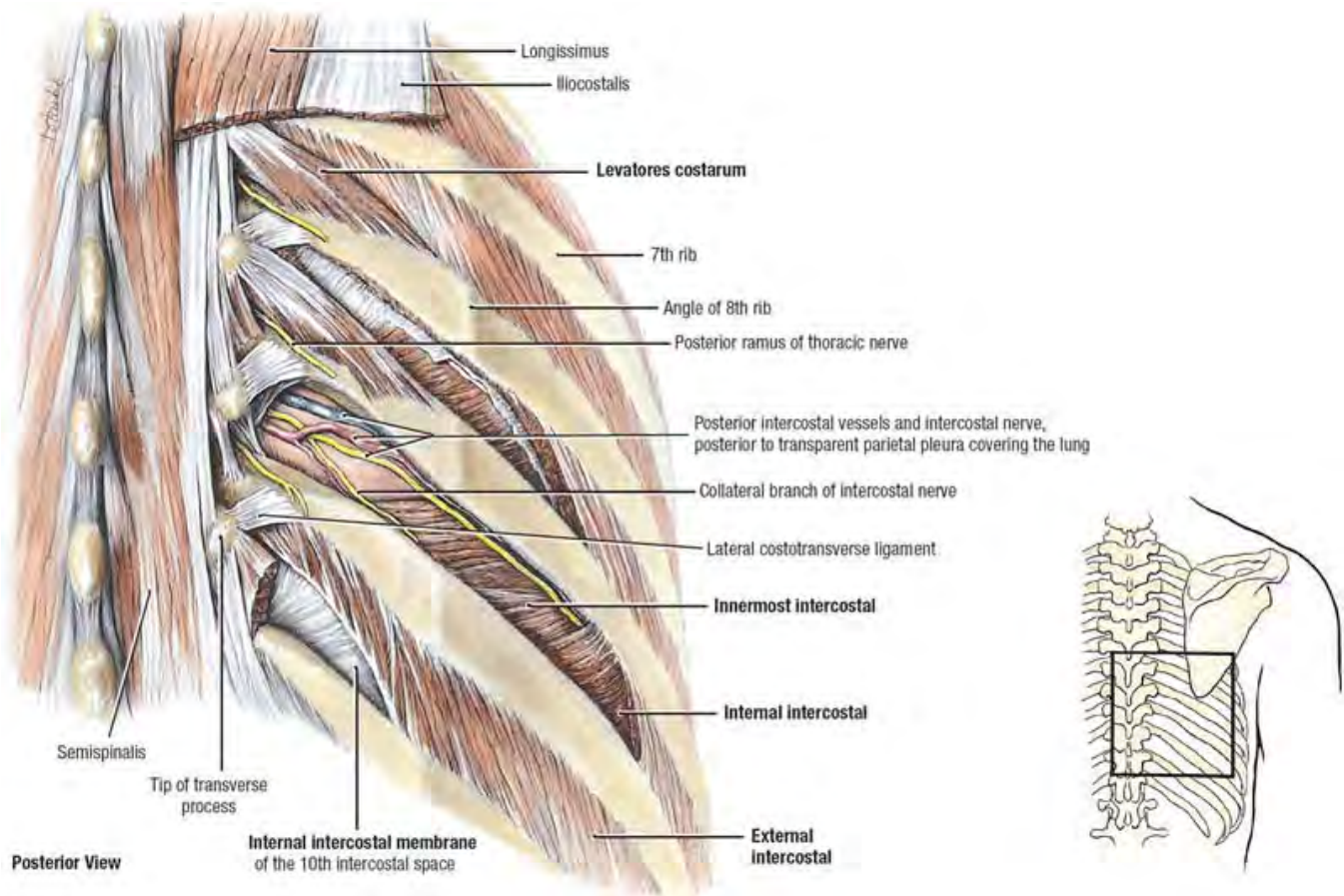
## 1.16 Vertebral ends of external aspect of inferior intercostal spaces

*Part of* "Chapter 1 - Thorax "

- The iliocostalis and longissimus muscles have been removed, exposing the levatores costarum muscle. Of the five intercostal spaces shown, the superior two (6th and 7th) are intact. In the 8th and 10th spaces, varying portions of the external intercostal muscle have been removed to reveal the underlying internal intercostal membrane, which is continuous with the internal intercostal muscle. In the 9th space, the levatores costarum muscle has been removed to show the posterior intercostal vessels and intercostal nerve.
  - The intercostal vessels and nerve disappear laterally between the internal and innermost intercostal muscles.
  - The intercostal nerve is the most inferior of the neurovascular trio (posterior intercostal vein and artery and intercostal nerve) and the least sheltered in the intercostal groove; a collateral branch arises near the angle of the rib.
- Sometimes it is necessary to insert a hypodermic needle through an intercostal space into the pleural cavity (See Fig. 1.24 ) to obtain a sample of pleural fluid or to remove blood or pus (thoracocentesis). To avoid damage to the intercostal nerve and vessels, the needle is inserted superior to the rib, high enough to avoid the collateral

branches.

P.19



Authors: Agur, Anne M.R.; Dalley, Arthur F.

Title: *Grant's Atlas of Anatomy, 12th Edition*

Copyright ©2009 Lippincott Williams & Wilkins

> Table of Contents > Chapter 1 - Thorax > 1.17 Anterior ends of inferior intercostal spaces

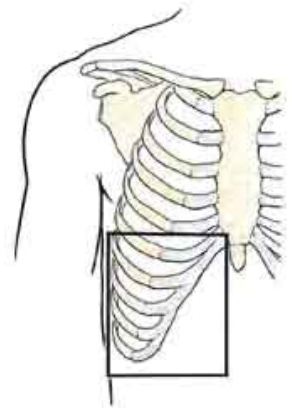
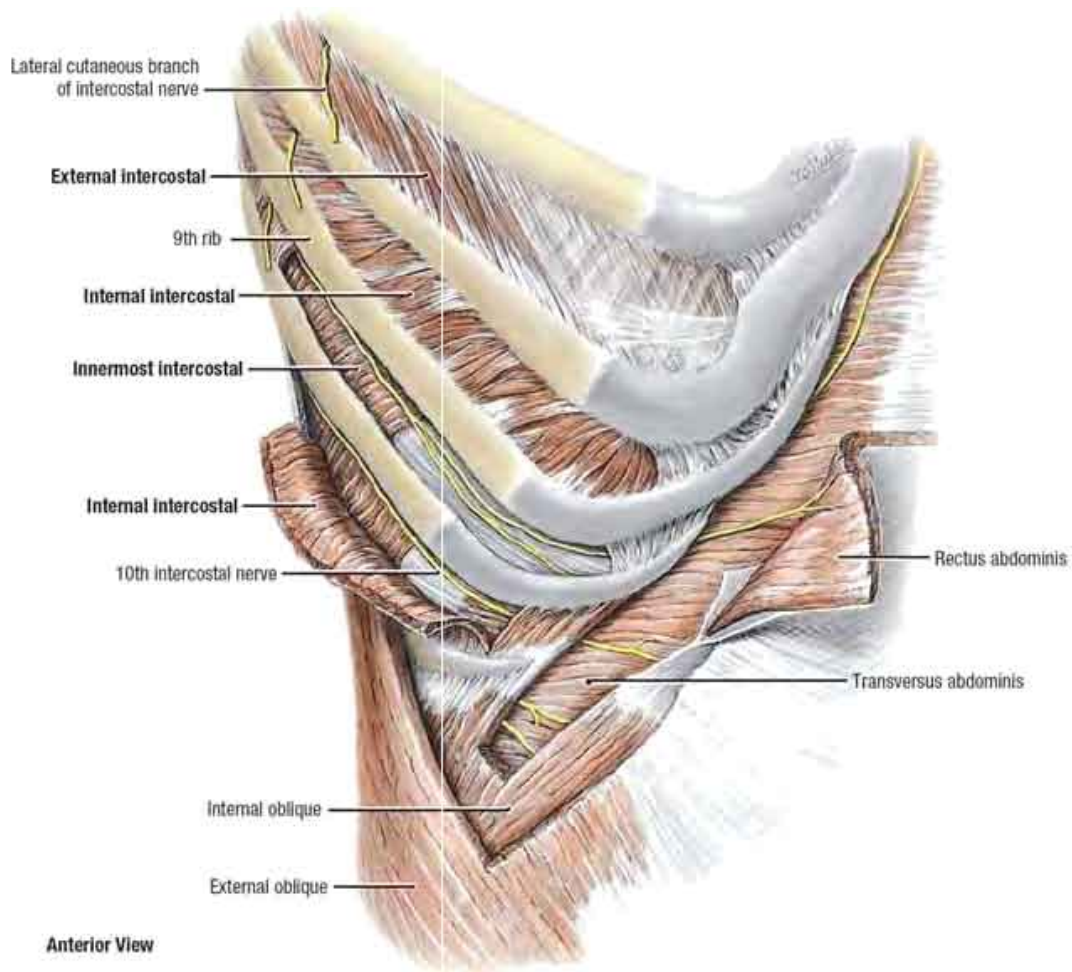
---

## 1.17 Anterior ends of inferior intercostal spaces

*Part of* "Chapter 1 - Thorax "

- The fibers of the external intercostal and external oblique muscles run inferomedially.
- The internal intercostal and internal oblique muscles are in continuity at the ends of the 9th, 10th, and 11th intercostal spaces.
- The intercostal nerves lie deep to the internal intercostal muscle but superficial to the innermost intercostal muscle; anteriorly, these nerves lie superficial to the transversus thoracis or transversus abdominis muscles.
- Intercostal nerves run parallel to the ribs and costal cartilages; on reaching the abdominal wall, nerves T7 and T8 continue superiorly, T9 continues nearly horizontally, and T10 continues inferomedially toward the umbilicus. These nerves provide cutaneous innervation in overlapping segmental bands.





Authors: Agur, Anne M.R.; Dalley, Arthur F.

Title: *Grant's Atlas of Anatomy, 12th Edition*

Copyright ©2009 Lippincott Williams & Wilkins

> Table of Contents > Chapter 1 - Thorax > 1.18 Contents of intercostal space, transverse section

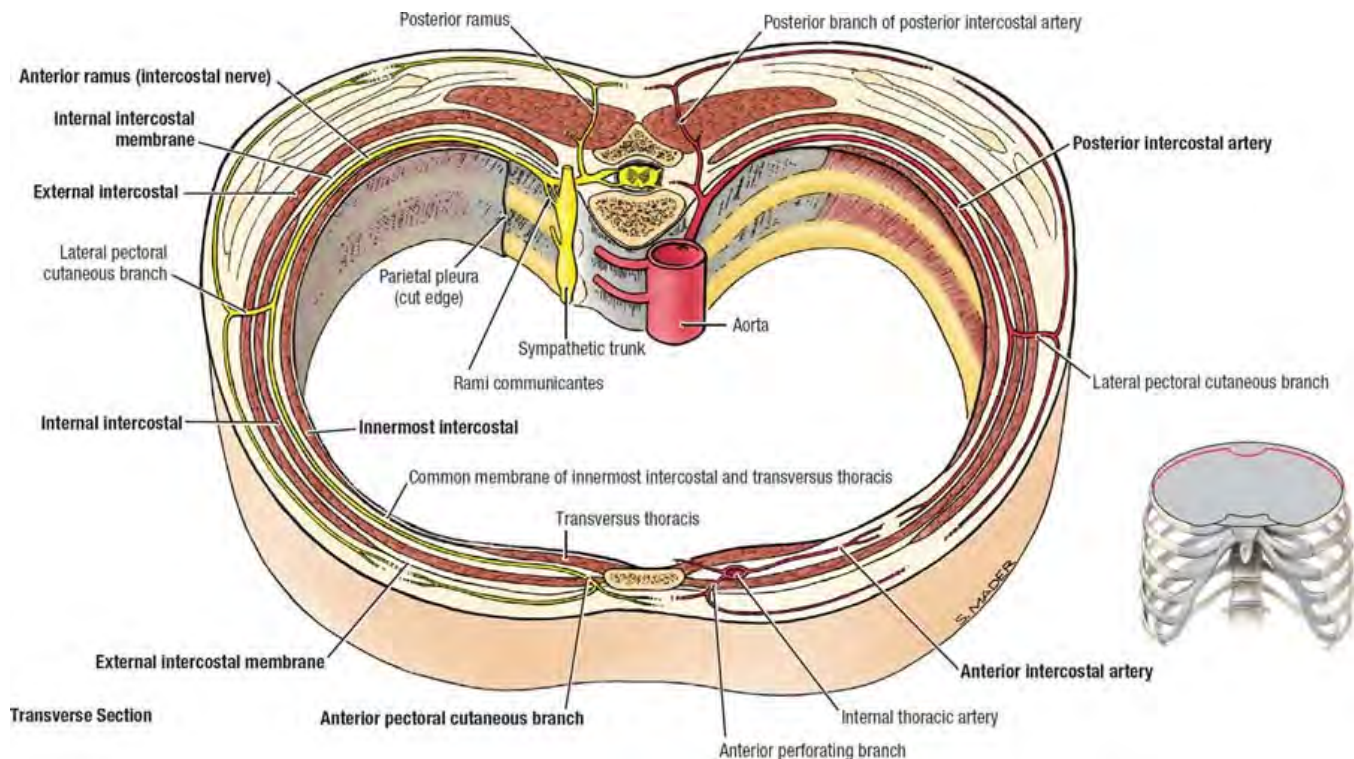
---

## 1.18 Contents of intercostal space, transverse section

*Part of* "Chapter 1 - Thorax "

- The diagram is simplified by showing nerves on the right and arteries on the left.
- The three musculomembranous layers are the external intercostal muscle and membrane, internal intercostal muscle and membrane, and the innermost intercostal muscle, transversus thoracis muscle, and the membrane connecting them.
- The intercostal nerves are the anterior rami of spinal nerves T1 to T11; the anterior ramus of T12 is the subcostal nerve.
- Posterior intercostal arteries are branches of the aorta (the superior two spaces are supplied from the superior intercostal branch of the costocervical trunk); the anterior intercostal arteries are branches of the internal thoracic artery or its branch, the musculophrenic artery.
- The posterior rami innervate the deep back muscles and skin adjacent to the vertebral column.





External intercostal

Elevate ribs

Internal intercostal

Inferior border of ribs

Superior border of ribs below

Depress ribs

Innermost intercostal

Probably elevate ribs

Transversus thoracis

Posterior surface of lower sternum

Internal surface of costal cartilages 2-6

Intercostal nerve  
 Depress ribs  
 Subcostales  
 Internal surface of lower ribs near their angles  
 Superior borders of 2nd or 3rd ribs below

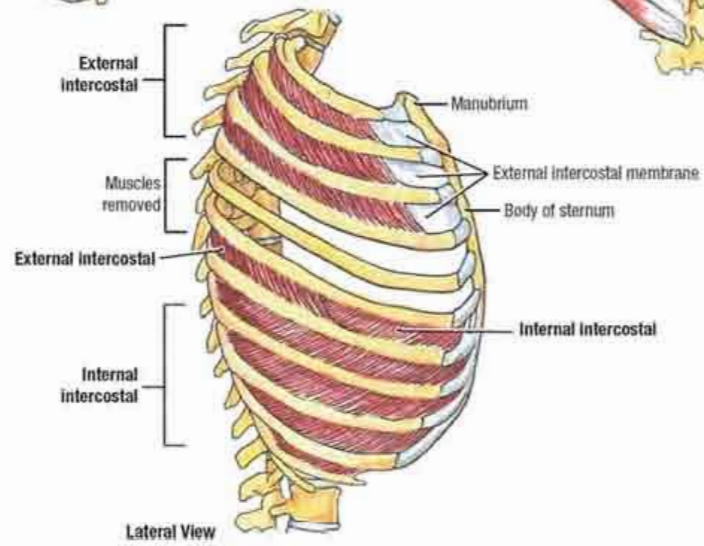
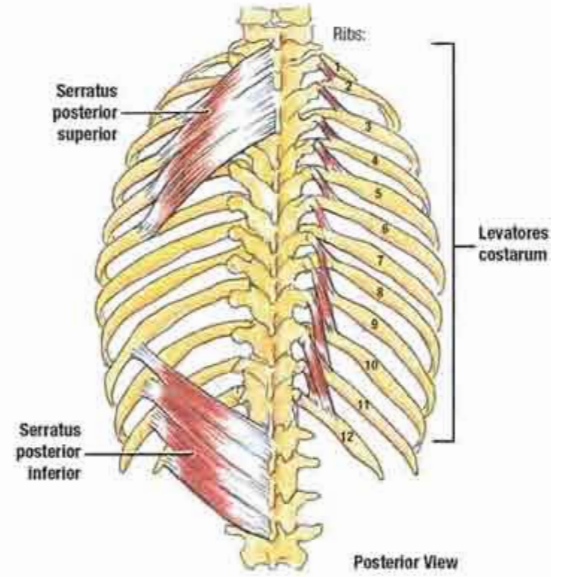
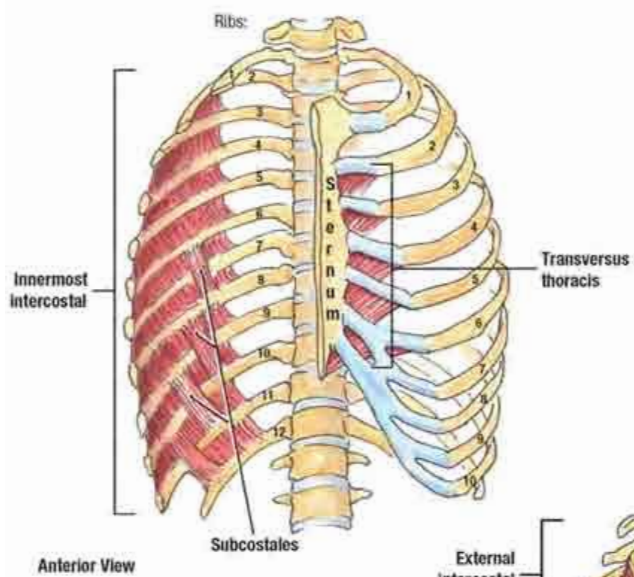
Levatores costarum  
 Transverse processes of T7–T11  
 Subjacent ribs between tubercle and angle  
 Posterior rami of C8–T11 nerves  
 Elevate ribs  
 Serratus posterior superior  
 Nuchal ligament, spinous processes of C7–T3  
 Superior borders of 2nd–4th ribs  
 Second to fifth intercostal nerves

Serratus posterior inferior  
 Spinous processes of T11–L2  
 Inferior borders of 8th–12th ribs near their angles  
 Anterior rami of T9–T12 nerves  
 Depress ribs

<sup>a</sup> All intercostal muscles keep intercostal spaces rigid, thereby preventing them from bulging out during expiration and from being drawn in during inspiration. Role of individual intercostal muscles and accessory muscles of respiration in moving the ribs is difficult to interpret despite many electromyographic studies.

Muscle	Superior attachment	Inferior attachment	Innervation	Action <sup>a</sup>
--------	---------------------	---------------------	-------------	---------------------

Table 1.1 Muscles Of Thoracic Wall



Authors: Agur, Anne M.R.; Dalley, Arthur F.

Title: *Grant's Atlas of Anatomy, 12th Edition*

Copyright ©2009 Lippincott Williams & Wilkins

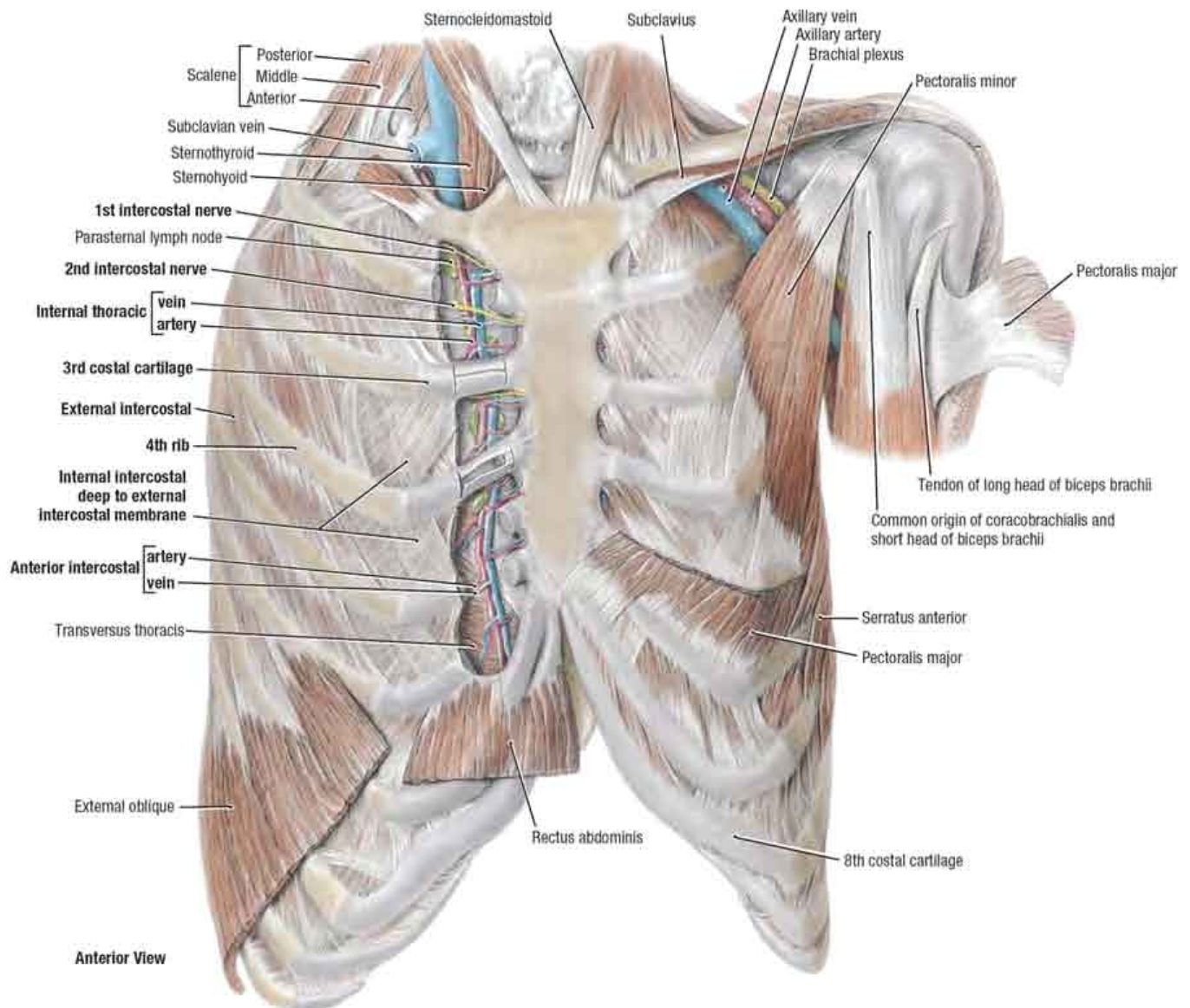
> Table of Contents > Chapter 1 - Thorax > 1.19 External aspect of thoracic wall

---

## 1.19 External aspect of thoracic wall

*Part of* "Chapter 1 - Thorax "

- H-shaped cuts were made through the perichondrium of the 3rd and 4th costal cartilages to shell out segments of cartilage.
- The internal thoracic (internal mammary) vessels run inferiorly deep to the costal cartilages and just lateral to the edge of the sternum, providing anterior intercostal branches.
- The parasternal lymph nodes (*green*) receive lymphatic vessels from the anterior parts of intercostal spaces, the costal pleura and diaphragm, and the medial part of the breast.
- The subclavian vessels are "sandwiched" between the 1st rib and clavicle and are "padded" by the subclavius.



Authors: Agur, Anne M.R.; Dalley, Arthur F.

Title: *Grant's Atlas of Anatomy, 12th Edition*

Copyright ©2009 Lippincott Williams & Wilkins

> Table of Contents > Chapter 1 - Thorax > 1.20 Internal aspect of the anterior thoracic wall

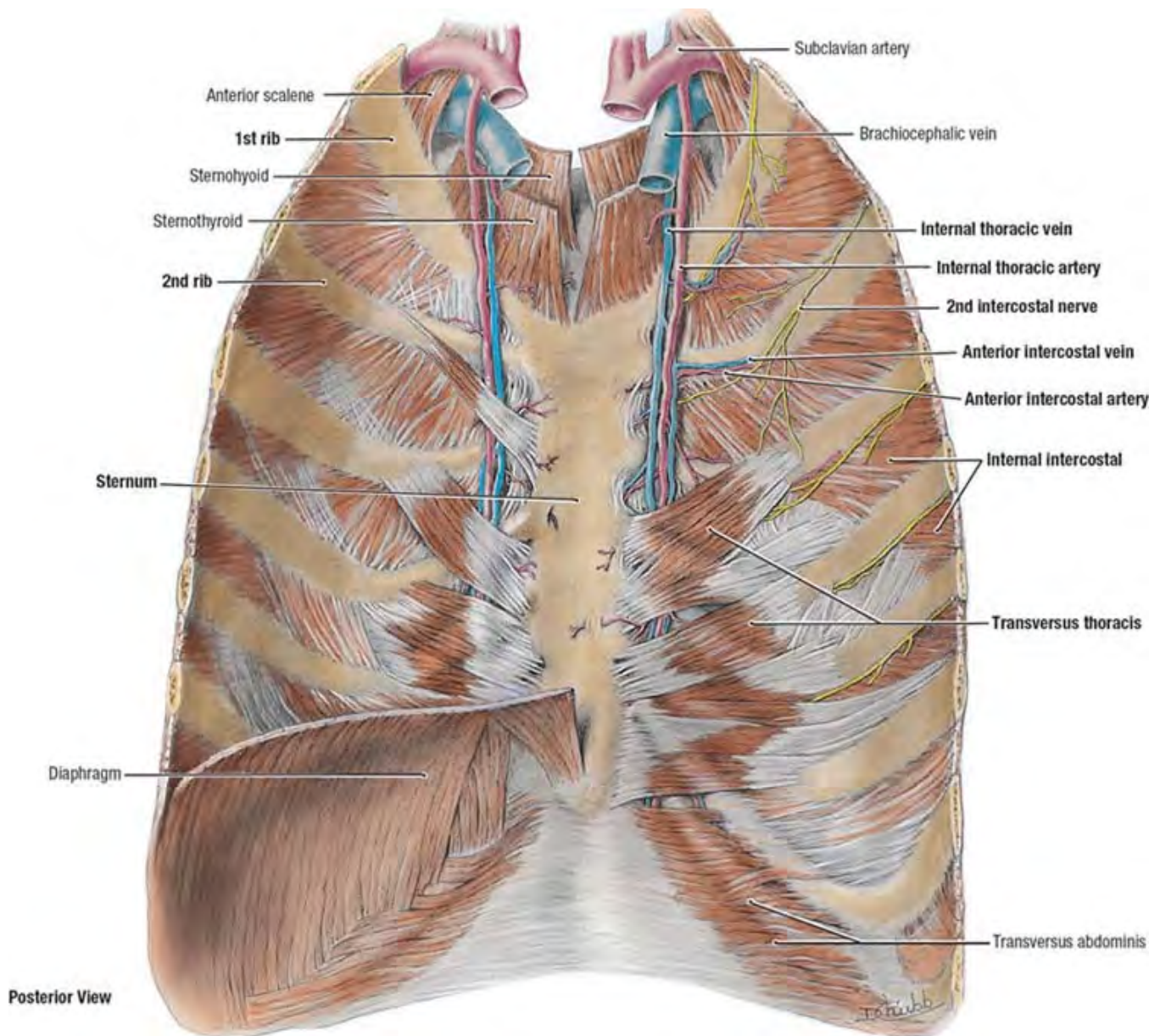
---

## 1.20 Internal aspect of the anterior thoracic wall

*Part of* "Chapter 1 - Thorax "

- The inferior portions of the internal thoracic vessels are covered posteriorly by the transversus thoracis muscle; the superior portions are in contact with the parietal pleura (removed).
- The transversus thoracis muscle is continuous with the transversus abdominis muscle; these form the innermost layer of the three flat muscles of the thoracoabdominal wall.
- The internal thoracic (internal mammary) artery arises from the subclavian artery and is accompanied by two venae comitantes up to the 2nd costal cartilage in this specimen and, superior to this, by the single internal thoracic vein, which drains into the brachiocephalic vein.





Normal (Quiet)

Major

Diaphragm (active contraction)

Passive (elastic) recoil of lungs and thoracic cage

Minor

*Tonic contraction* of external intercostals and interchondral portion of internal intercostals to resist negative pressure

*Tonic contraction* of muscles of anterolateral abdominal walls (rectus abdominis, external



and internal obliques, transversus abdominis) to antagonize diaphragm by maintaining intra-abdominal pressure

Active (Forced)

In addition to the above, *active contraction* of

In addition to the above, *active contraction* of

Sternocleidomastoid, descending (superior) trapezius, pectoralis minor, and scalenes, to elevate and fix upper rib cage

Muscles of anterolateral abdominal wall (antagonizing diaphragm by increasing intra-abdominal pressure and by pulling inferiorly and fixing inferior costal margin): rectus abdominis, external and internal obliques, and transversus abdominis

External intercostals, interchondral portion of internal intercostals, subcostales, levatores costarum, and serratus posterior superior<sup>a</sup> to elevate ribs

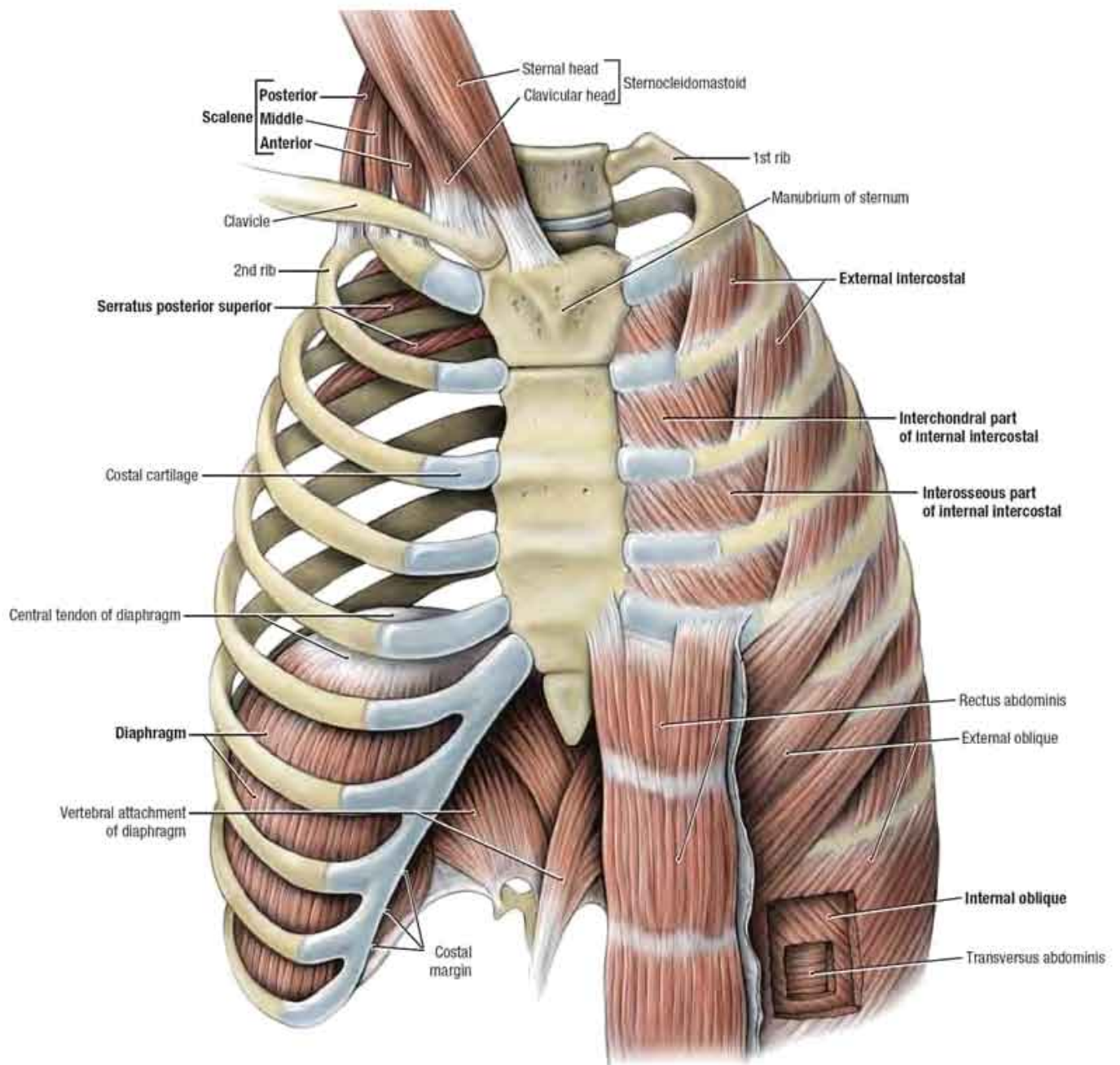
Internal intercostal (interosseous part) and serratus posterior inferior<sup>a</sup> to depress ribs

<sup>a</sup> Recent studies indicate that the serratus posterior superior and inferior muscles may serve primarily as organs of proprioception rather than motion.

Inspiration

Expiration

## Table 1.2 Muscles Of Respiration



Authors: Agur, Anne M.R.; Dalley, Arthur F.

Title: *Grant's Atlas of Anatomy, 12th Edition*

Copyright ©2009 Lippincott Williams & Wilkins

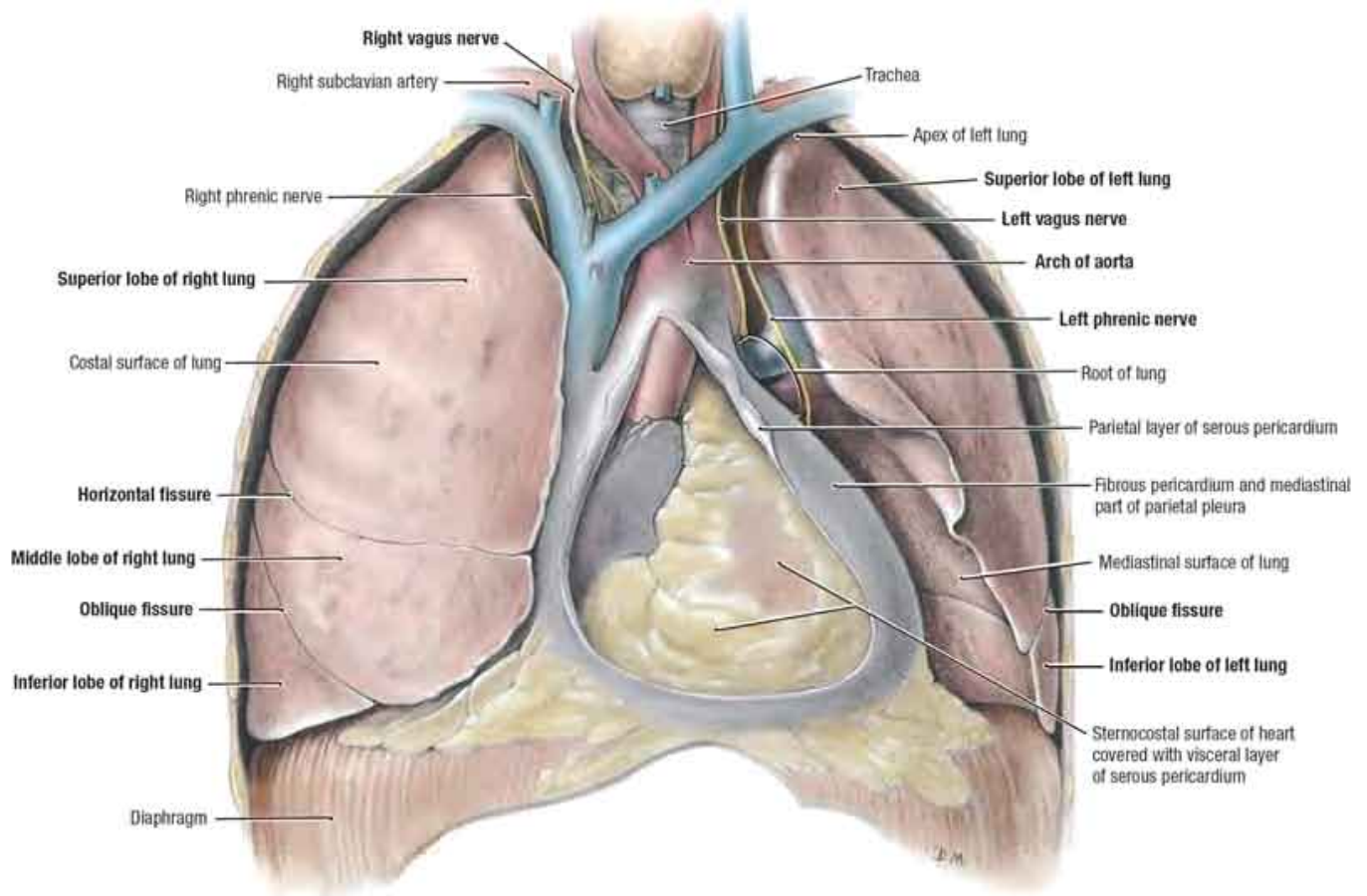
> Table of Contents > Chapter 1 - Thorax > 1.21 Thoracic contents in situ

---

## 1.21 Thoracic contents in situ

*Part of "Chapter 1 - Thorax "*

- The fibrous pericardium, lined by the parietal layer of serous pericardium, is removed anteriorly to expose the heart and great vessels.
- The right lung has three lobes; the superior lobe is separated from the middle lobe by the horizontal fissure, and the middle lobe is separated from the inferior lobe by the oblique fissure. The left lung has two lobes, superior and inferior, separated by the oblique fissure.
- The anterior border of the left lung is reflected laterally to visualize the phrenic nerve passing anterior to the root of the lung and the vagus nerve lying anterior to the arch of the aorta and then passing posterior to the root of the lung.
- As the right vagus nerve passes anterior to the right subclavian artery, it gives rise to the recurrent branch and then divides to contribute fibers to the esophageal, cardiac, and pulmonary plexuses.



Authors: Agur, Anne M.R.; Dalley, Arthur F.

Title: *Grant's Atlas of Anatomy, 12th Edition*

Copyright ©2009 Lippincott Williams & Wilkins

> Table of Contents > Chapter 1 - Thorax > 1.22 Topography of the lungs and mediastinum

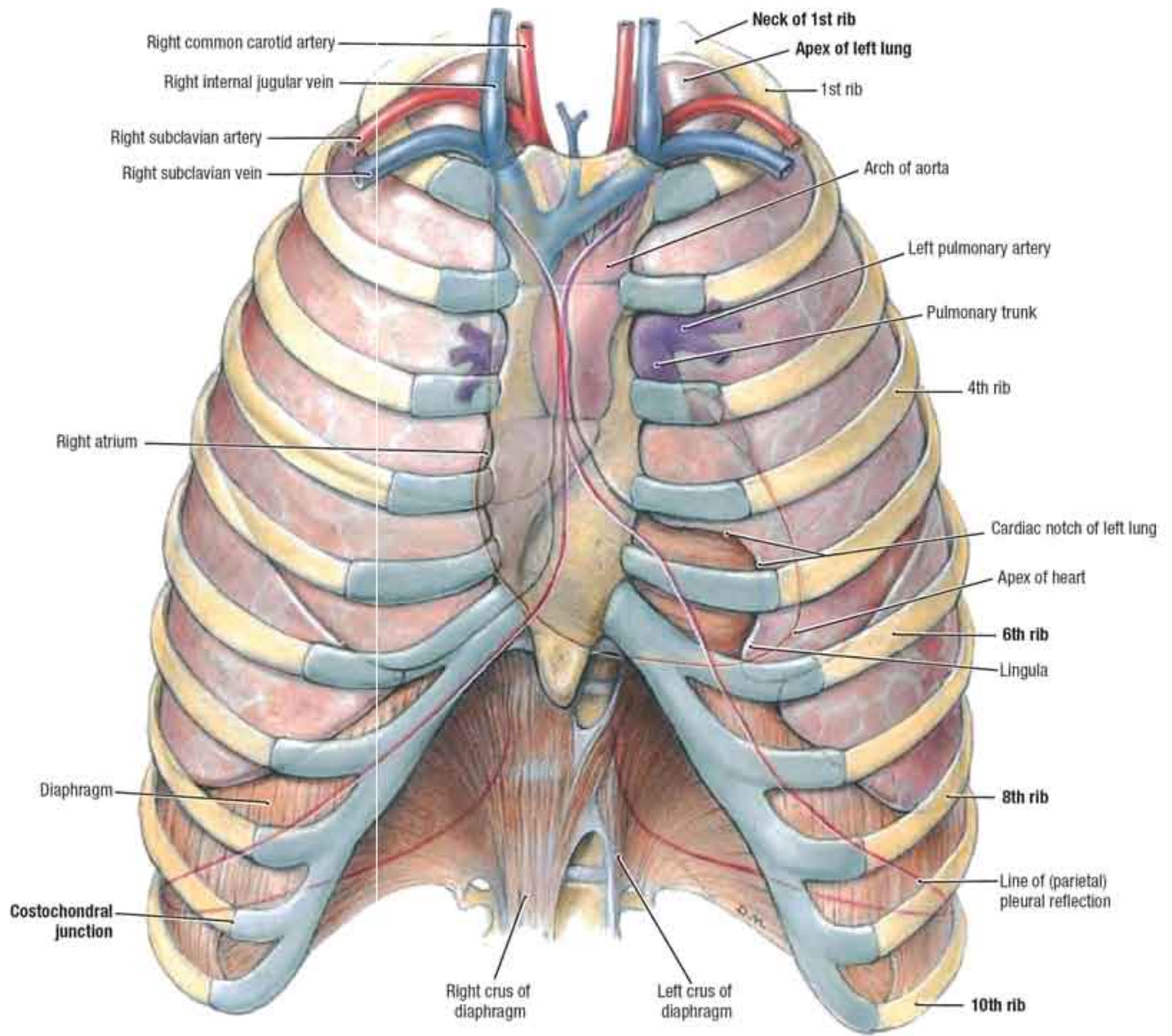
---

## 1.22 Topography of the lungs and mediastinum

*Part of* "Chapter 1 - Thorax "

- The mediastinum is located between the pleural cavities and is occupied by the heart and the tissues anterior, posterior, and superior to the heart.
- The apex of the lungs is at the level of the neck of the 1st rib, and the inferior border of the lungs is at the 6th rib in the left midclavicular line and the 8th rib at the lateral aspect of the bony thorax at the midaxillary line.
- The cardiac notch of the left lung and the deviation of the parietal pleura is away from the median plane toward the left side in the region of the cardiac notch.
- The inferior reflection of parietal pleura is at the 8th costochondral junction in the midclavicular line, at the 10th rib in the midaxillary line.
- The apex of the heart is in the 5th intercostal space at the left midclavicular line.
- The right atrium forms the right border of the heart and extends just beyond the lateral margin of the sternum.
- The branches of the great vessels pass through the superior thoracic aperture.





Authors: Agur, Anne M.R.; Dalley, Arthur F.

Title: *Grant's Atlas of Anatomy, 12th Edition*

Copyright ©2009 Lippincott Williams & Wilkins

> Table of Contents > Chapter 1 - Thorax > 1.23 Radiograph of chest

---

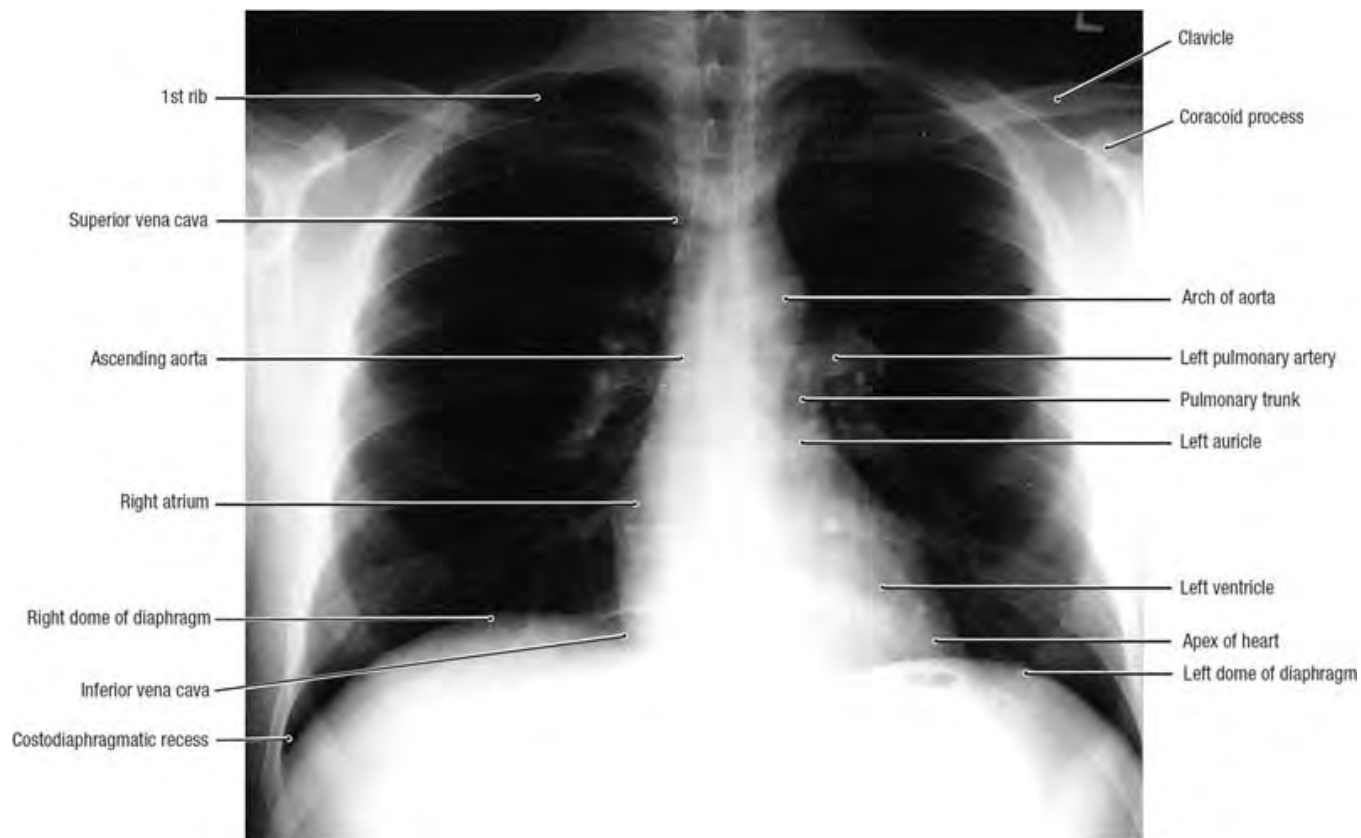
## 1.23 Radiograph of chest

*Part of* "Chapter 1 - Thorax "

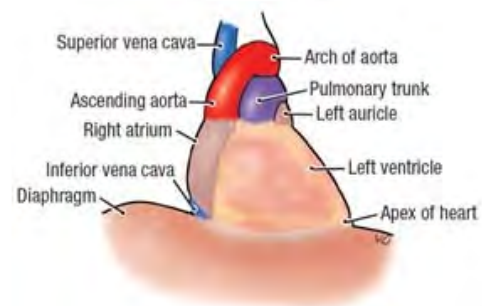
- The right dome of the diaphragm is higher than the left dome due primarily to the large underlying liver.
- The convex right mediastinal border of the heart is formed by the right atrium; above this, the superior vena cava and ascending aorta produce less convex borders.
- The left border of the mediastinal silhouette is formed by the arch of the aorta, pulmonary trunk, left auricle (normally not prominent), and left ventricle.
- Follow the 1st rib to where it curves laterally and then medially to cross the clavicle.

- Any structure in the mediastinum may contribute to pathological widening of the mediastinal silhouette. It is often observed after trauma resulting from a head-on collision, for example, which produces hemorrhage into the mediastinum from lacerated great vessels such as the aorta or SVC. Frequently, malignant lymphoma (cancer of lymphatic tissue) produces massive enlargement of mediastinal lymph nodes and widening of the mediastinum. Enlargement (hypertrophy) of the heart (occurring with congestive heart failure) is a common cause of widening of the inferior mediastinum.





Posteroanterior View



Authors: Agur, Anne M.R.; Dalley, Arthur F.

Title: *Grant's Atlas of Anatomy, 12th Edition*

Copyright ©2009 Lippincott Williams & Wilkins

> Table of Contents > Chapter 1 - Thorax > 1.24 Respiratory system

---

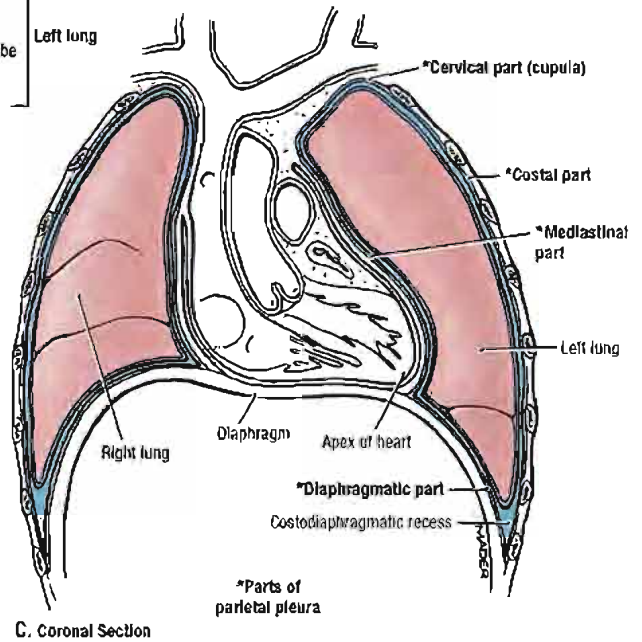
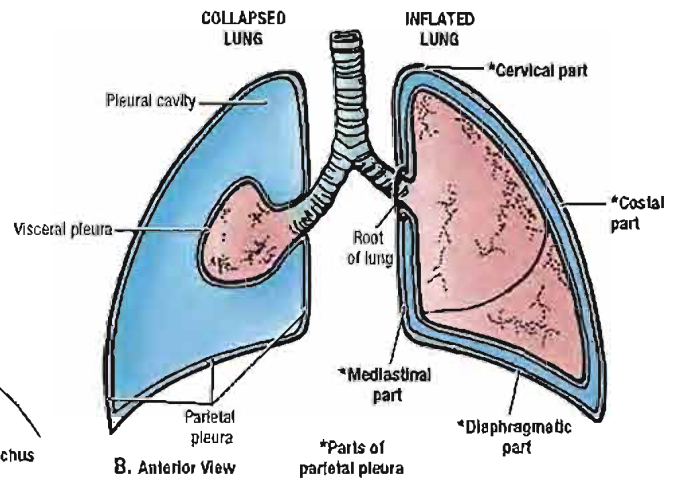
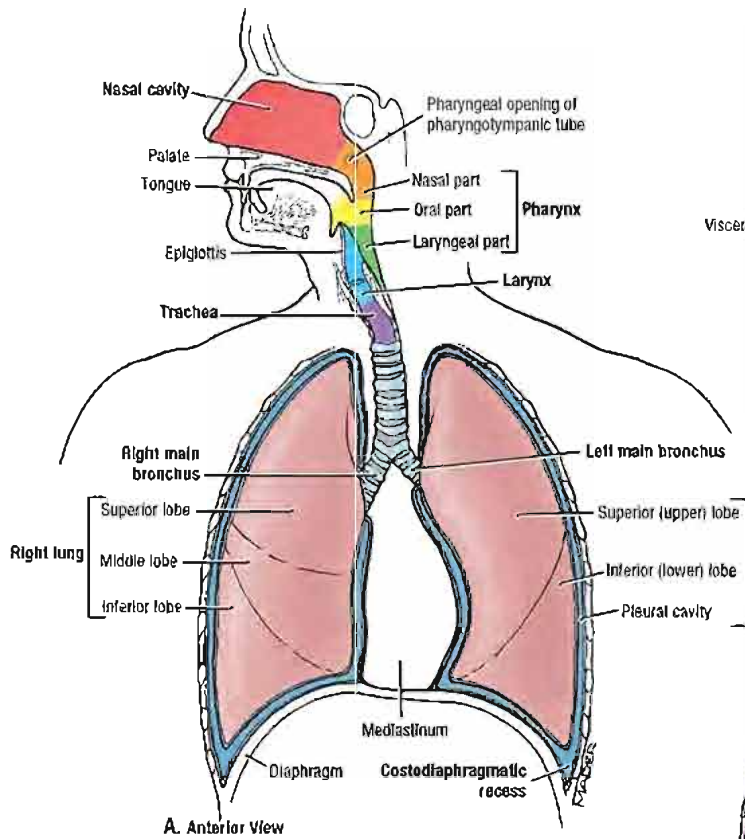
## 1.24 Respiratory system

*Part of* "Chapter 1 - Thorax "

A. Overview. B. Pleural cavity and pleura. C. Coronal section through heart and lungs.

- The lungs invaginate a continuous membranous pleural sac; the visceral (pulmonary) pleura covers the lungs, and the parietal pleura lines the thoracic cavity; the visceral and parietal pleurae are continuous around the root of the lung.
- The parietal pleura can be divided regionally into the costal, diaphragmatic, mediastinal, and cervical parts; note the costodiaphragmatic recess.

- The pleural cavity is a potential space between the visceral and parietal pleurae that contains a thin layer of fluid. If a sufficient amount of air enters the pleural cavity, the surface tension adhering visceral to parietal pleura (lung to thoracic wall) is broken, and the lung collapses because of its inherent elasticity (elastic recoil). When a lung collapses, the pleural cavity—normally a potential space—becomes a real space (B ) and may contain air (pneumothorax), blood (hemothorax), etc.



Authors: Agur, Anne M.R.; Dalley, Arthur F.

Title: *Grant's Atlas of Anatomy, 12th Edition*

Copyright ©2009 Lippincott Williams & Wilkins

> Table of Contents > Chapter 1 - Thorax > 1.25 Mediastinum and pericardium

---

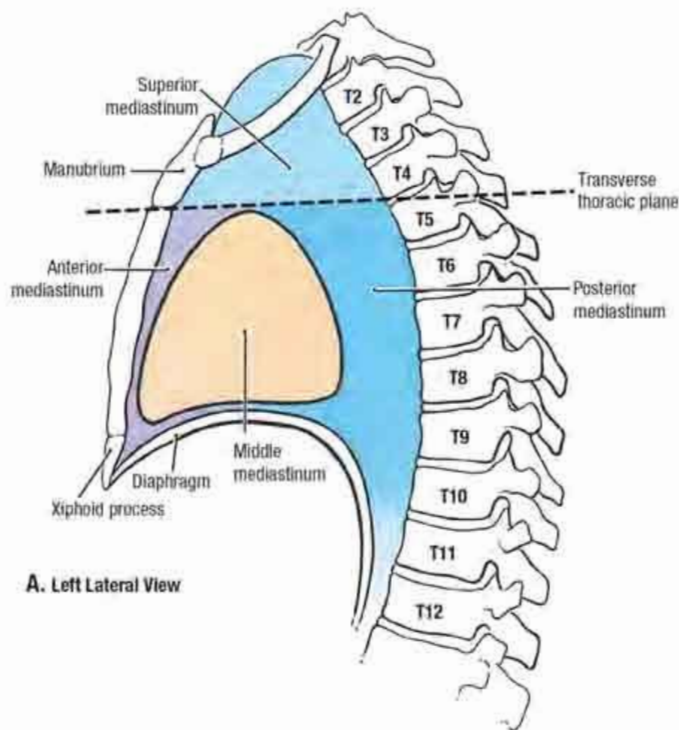
## 1.25 Mediastinum and pericardium

*Part of* "Chapter 1 - Thorax "

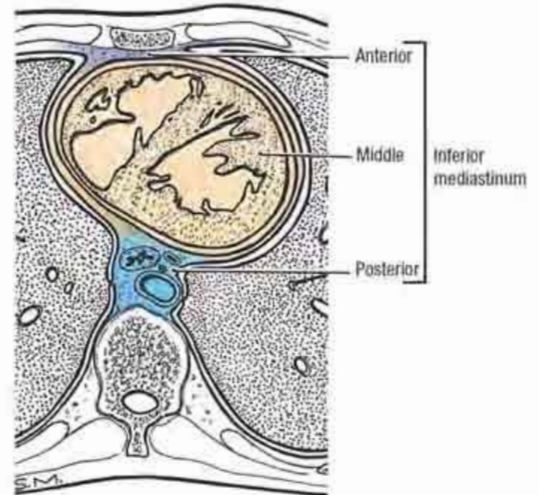
A and B. Subdivisions of mediastinum. C. Layers of pericardium and heart.

---

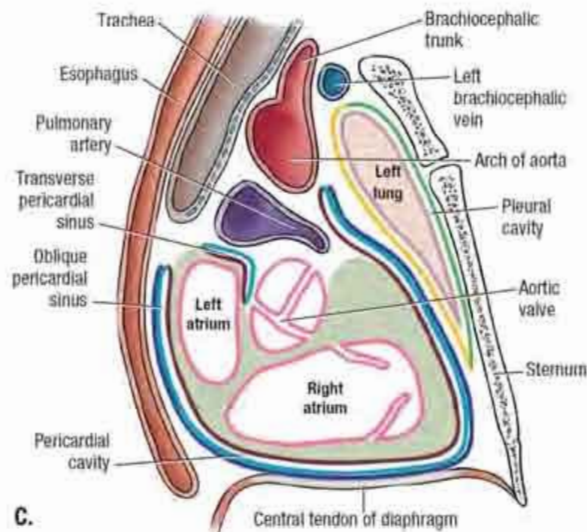
P.30



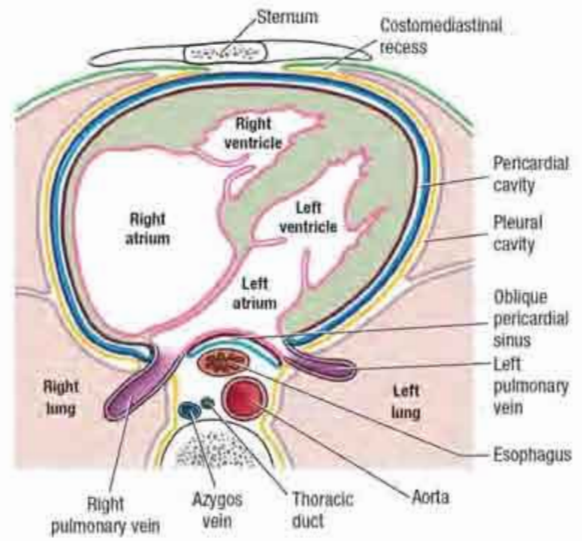
A. Left Lateral View



B. Transverse Section, Inferior View



C. Median Section, Right Lateral View



Transverse Section, Inferior View

#### Key for C.

##### Pericardium

■ Fibrous pericardium

Serous pericardium:

■ Parietal layer of serous pericardium (lines fibrous pericardium)

■ Visceral layer of serous pericardium (outermost layer of heart wall)

Thin film of fluid in pericardial cavity between visceral and parietal layers allows the heart to move freely within the pericardial sac.

##### Heart

■ Epicardium (visceral layer of serous pericardium)

■ Myocardium

■ Endocardium

##### Pleurae

■ Visceral pleura

Parietal pleura:

■ Mediastinal

■ Costal



Authors: Agur, Anne M.R.; Dalley, Arthur F.

Title: *Grant's Atlas of Anatomy, 12th Edition*

Copyright ©2009 Lippincott Williams & Wilkins

> Table of Contents > Chapter 1 - Thorax > 1.26 Extent of parietal pleura and lungs

---

## 1.26 Extent of parietal pleura and lungs

*Part of* "Chapter 1 - Thorax "

---

P.31

Apex

About 4 cm superior to middle of clavicle

About 4 cm superior to middle of clavicle

4th costal cartilage

Midline (anteriorly)

Midline (anteriorly)

6th costal cartilage

Lateral margin of sternum

Midline (anteriorly)

8th costal cartilage

Midclavicular line

Midclavicular line

10th rib

Midaxillary line

Midaxillary line

11th rib

Line of inferior angle of scapula

Line of inferior angle of scapula

12th rib

Lateral border of erector spinae to T12 spinous process (slightly lower level than right pleura)

Lateral border of erector spinae to T12 spinous process



Table 1.3 Surface Markings Of Parietal Pleura (Blue)

## Surface Markings of Lungs Covered with Visceral Pleura (Pink)

Apex

About 4 cm superior to middle of clavicle

About 4 cm superior to middle of clavicle

2nd costal cartilage

Midline (anteriorly)

Midline (anteriorly)

4th costal cartilage

Lateral margin of sternum

Lateral margin of sternum

6th costal cartilage  
Follows 4th costal cartilage, turns inferiorly to 6th costal cartilage in the midclavicular line (cardiac notch)

Midclavicular line

8th rib

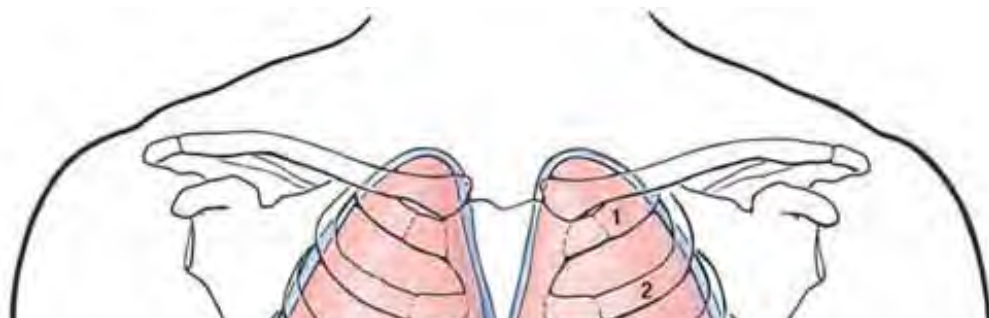
Midaxillary line

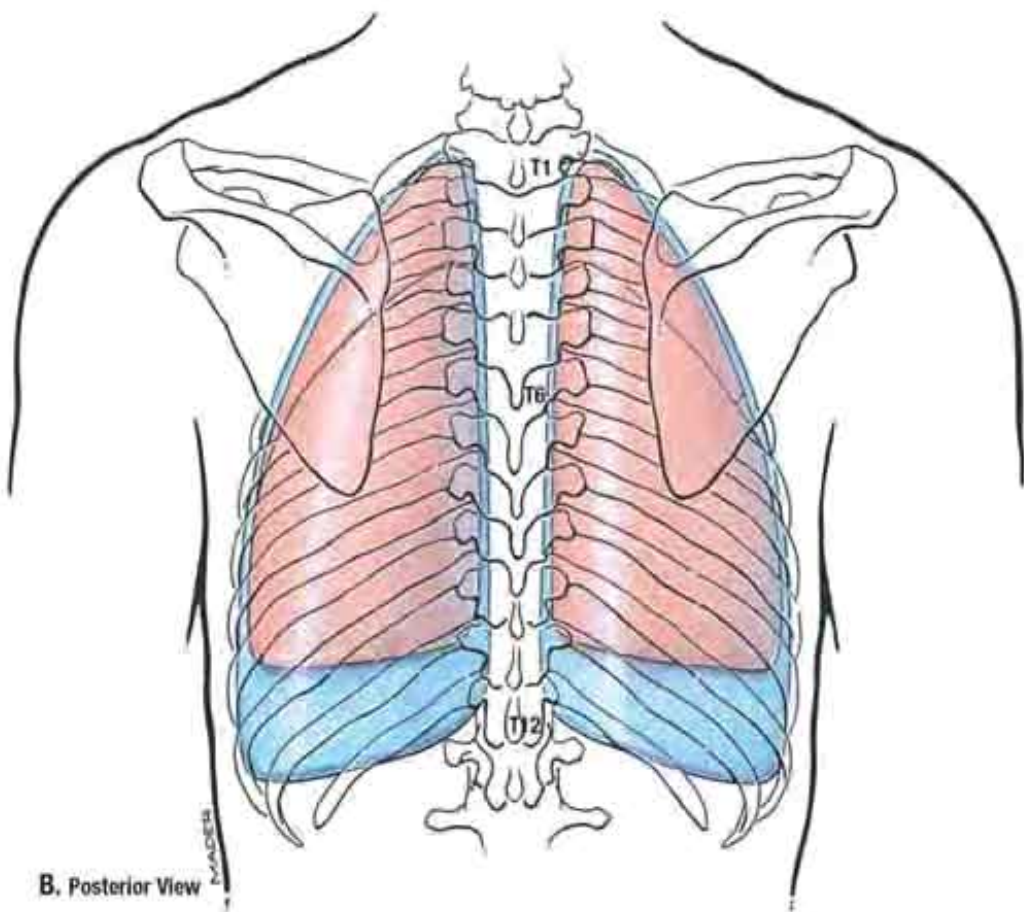
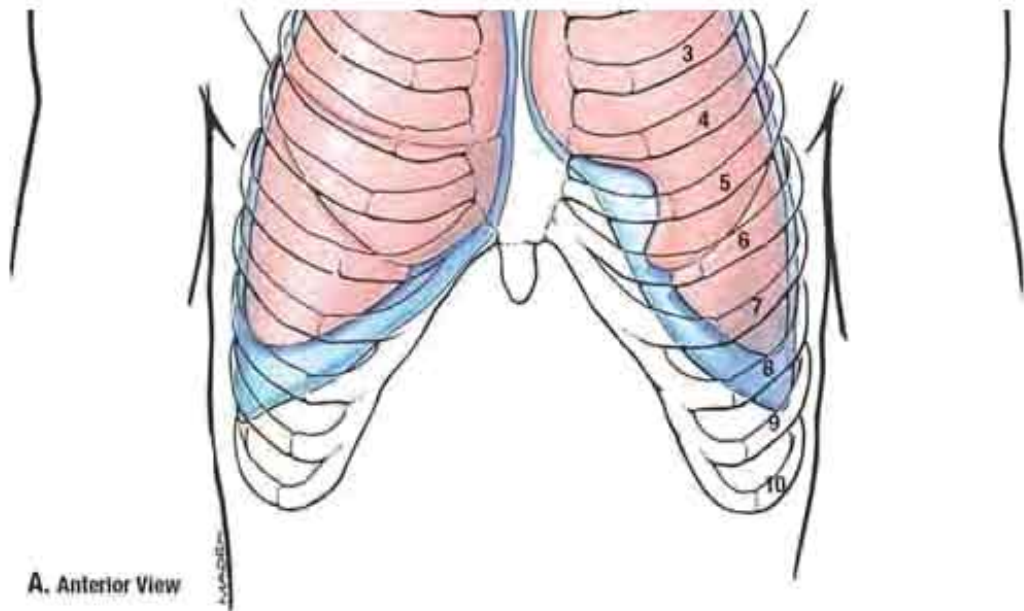
Midaxillary line

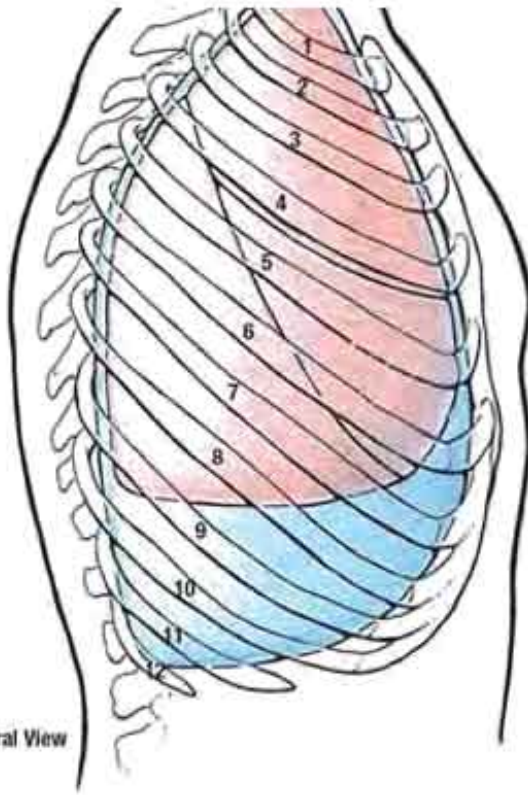
10th rib

Line of inferior angle of scapula to T10 spinous process

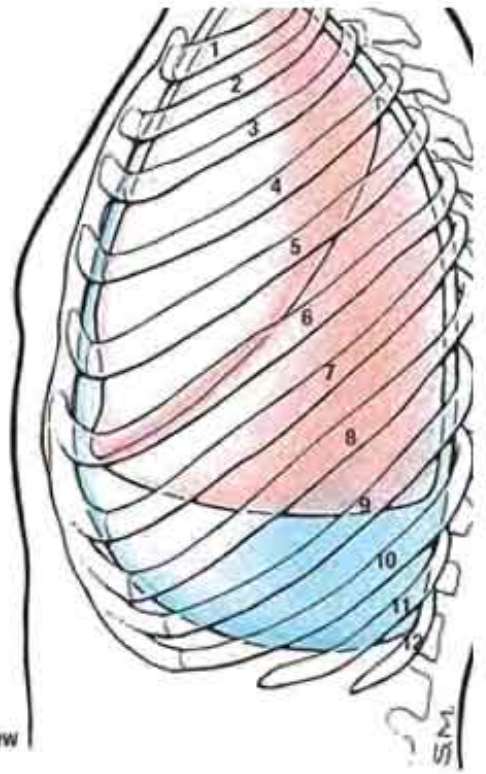
Line of inferior angle of scapula to T10 spinous process







C. Right Lateral View



D. Left Lateral View

Authors: Agur, Anne M.R.; Dalley, Arthur F.

Title: *Grant's Atlas of Anatomy, 12th Edition*

Copyright ©2009 Lippincott Williams & Wilkins

> Table of Contents > Chapter 1 - Thorax > 1.27 Lungs

---

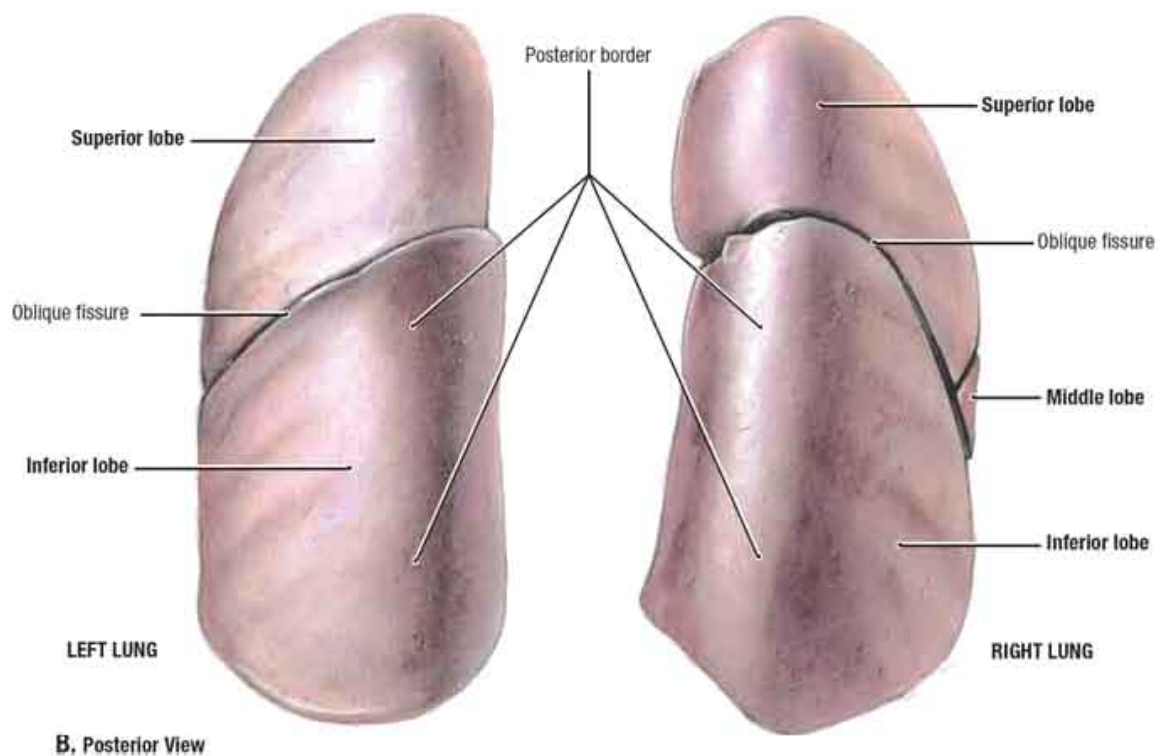
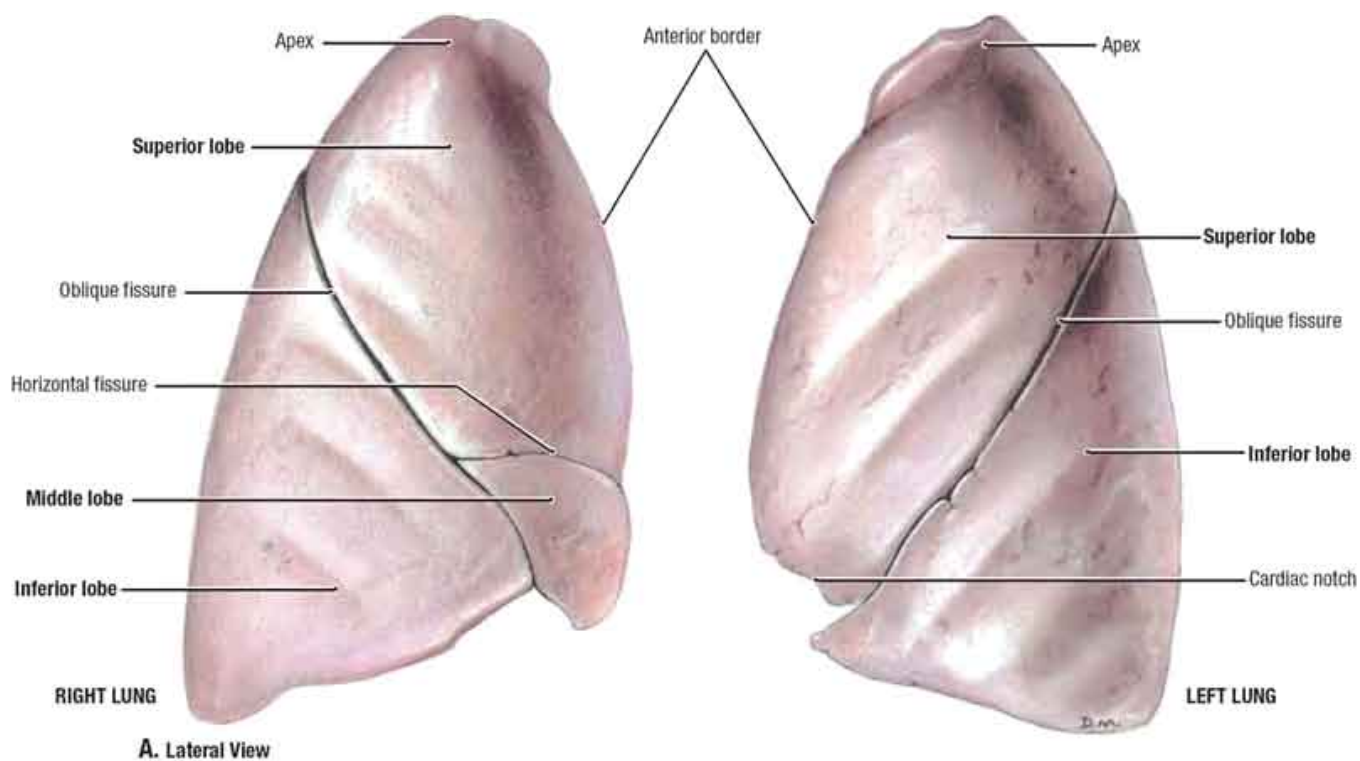
## 1.27 Lungs

*Part of* "Chapter 1 - Thorax "

The right lung usually has three lobes, and the left lung, two lobes. The oblique and horizontal fissures of the right lung and the oblique fissure of the left lung may be incomplete or absent in some specimens.

---

P.33



Authors: Agur, Anne M.R.; Dalley, Arthur F.

Title: *Grant's Atlas of Anatomy, 12th Edition*

Copyright ©2009 Lippincott Williams & Wilkins

> Table of Contents > Chapter 1 - Thorax > 1.28 Bronchi, pulmonary veins, and pulmonary arteries

---

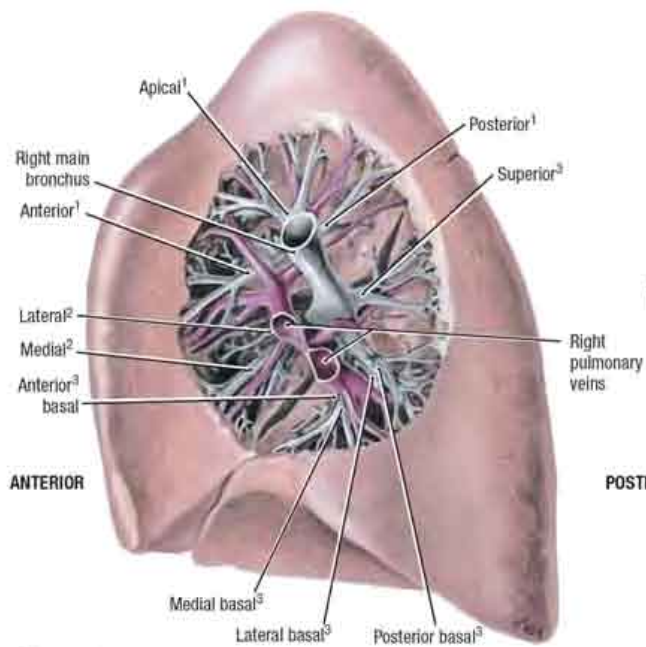
## 1.28 Bronchi, pulmonary veins, and pulmonary arteries

*Part of* "Chapter 1 - Thorax "

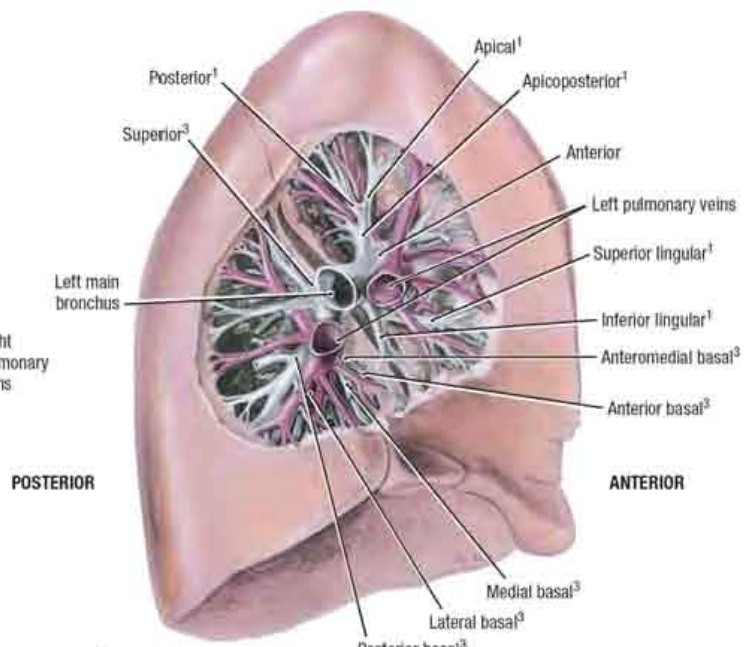
A and C. Right lungs. B and D. Left lungs. Superscripts indicate segmental bronchi to the <sup>1</sup> superior lobe, <sup>2</sup> middle lobe, and <sup>3</sup> inferior lobe. The pulmonary veins and arteries of fresh lungs were filled with latex, the bronchi were inflated with air. The tissues surrounding the bronchi and vessels were removed.

Obstruction of a pulmonary artery by a blood clot (embolism) results in partial or complete obstruction of blood flow to the lung.



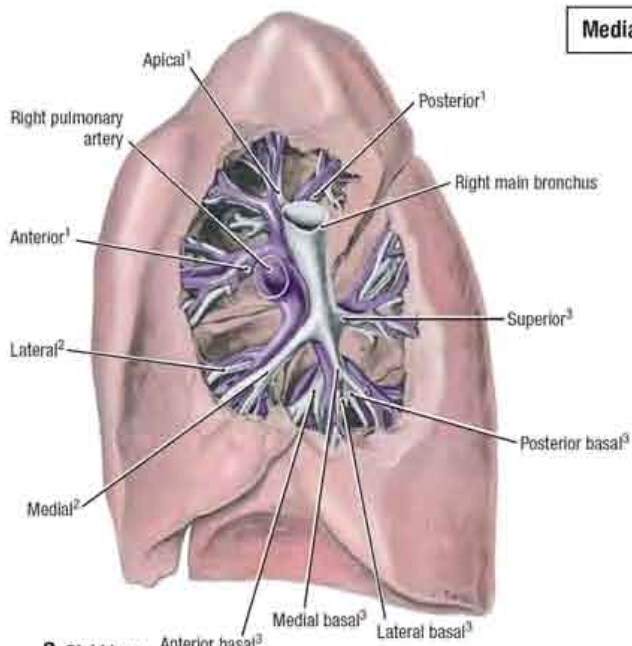


**A. Right Lung**

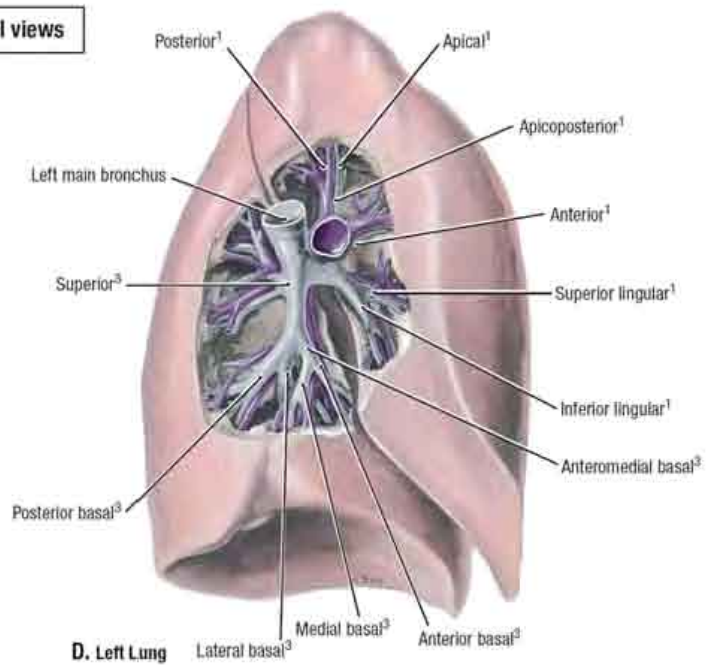


**B. Left Lung**

**Medial views**



**C. Right Lung**



**D. Left Lung**



Authors: Agur, Anne M.R.; Dalley, Arthur F.

Title: *Grant's Atlas of Anatomy, 12th Edition*

Copyright ©2009 Lippincott Williams & Wilkins

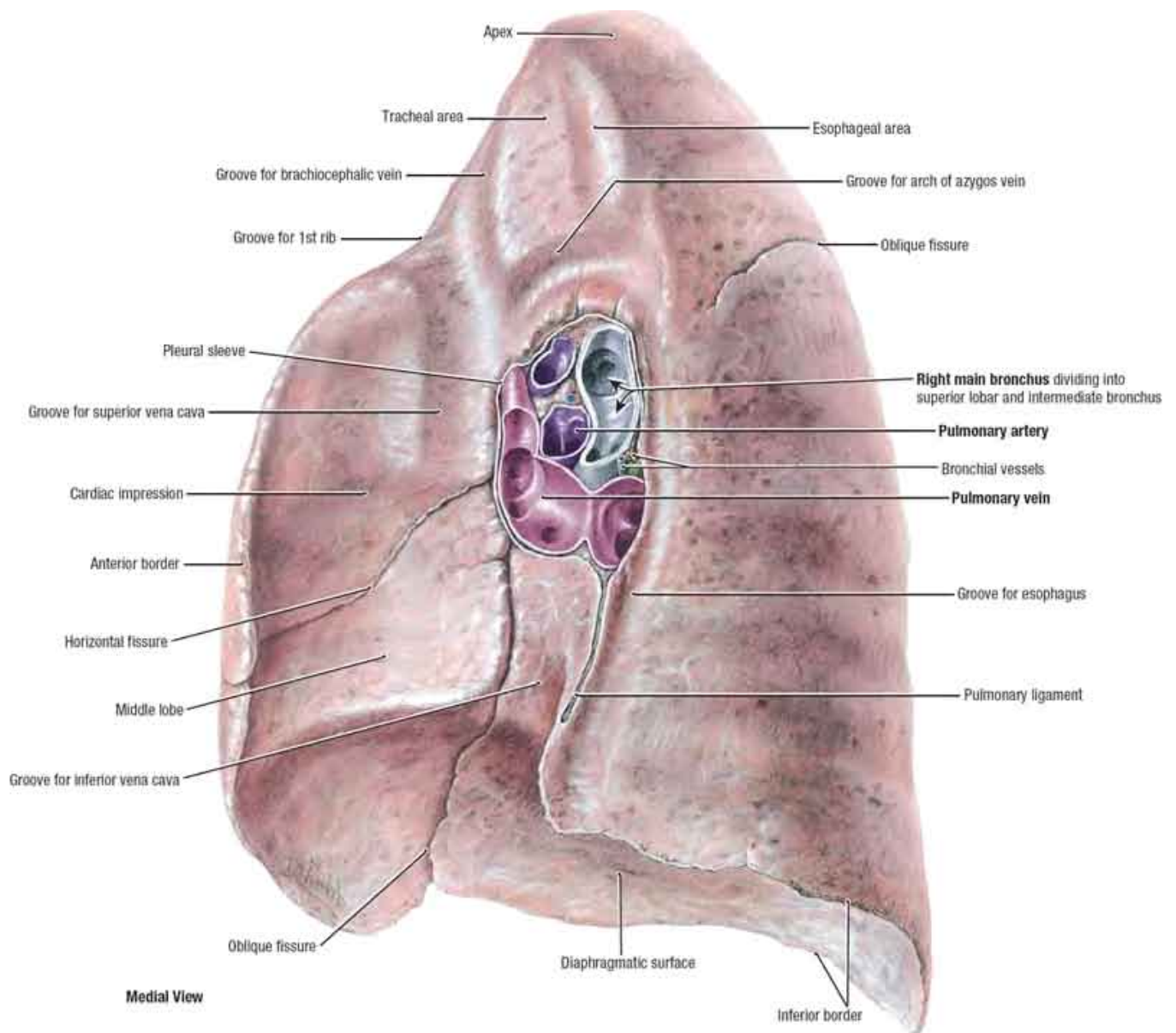
> Table of Contents > Chapter 1 - Thorax > 1.29 Mediastinal (medial) surface and hilum of right lung

---

## 1.29 Mediastinal (medial) surface and hilum of right lung

*Part of* "Chapter 1 - Thorax "

The embalmed lung shows impressions of the structures with which it comes into contact, clearly demarcated as surface features; the base is contoured by the domes of the diaphragm; the costal surface bears the impressions of the ribs; distended vessels leave their mark, but nerves do not. The oblique fissure is incomplete here.



Authors: Agur, Anne M.R.; Dalley, Arthur F.

Title: *Grant's Atlas of Anatomy, 12th Edition*

Copyright ©2009 Lippincott Williams & Wilkins

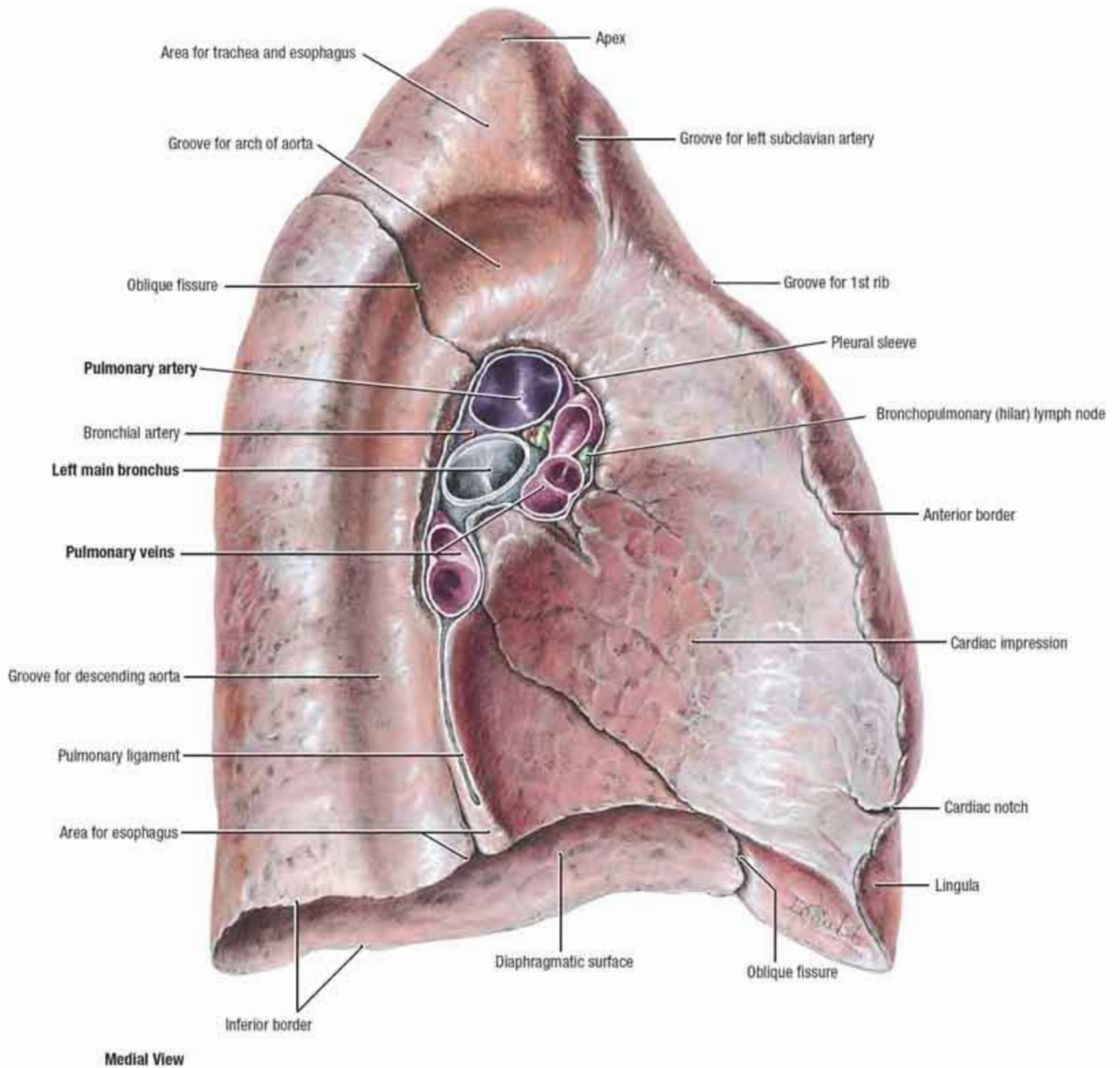
> Table of Contents > Chapter 1 - Thorax > 1.30 Mediastinal (medial) surface and hilum of left lung

---

## 1.30 Mediastinal (medial) surface and hilum of left lung

*Part of* "Chapter 1 - Thorax "

Note the site of contact with esophagus, between the descending aorta and the inferior end of the pulmonary ligament. In the right and left roots, the artery is superior, the bronchus is posterior, one vein is anterior, and the other is inferior; in the right root, the bronchus to the superior lobe (also called the *eparterial bronchus*) is the most superior structure.



Authors: Agur, Anne M.R.; Dalley, Arthur F.

Title: *Grant's Atlas of Anatomy, 12th Edition*

Copyright ©2009 Lippincott Williams & Wilkins

> Table of Contents > Chapter 1 - Thorax > 1.31 Segmental bronchi and bronchopulmonary segments

---

## 1.31 Segmental bronchi and bronchopulmonary segments

*Part of* "Chapter 1 - Thorax "

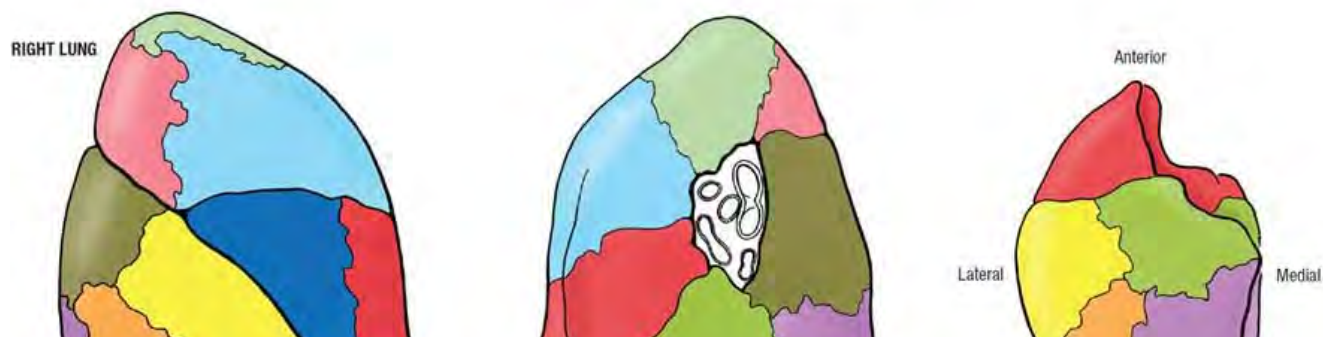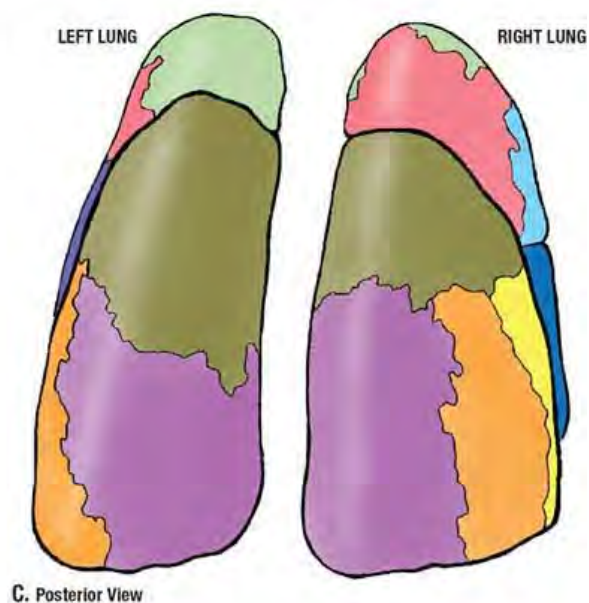
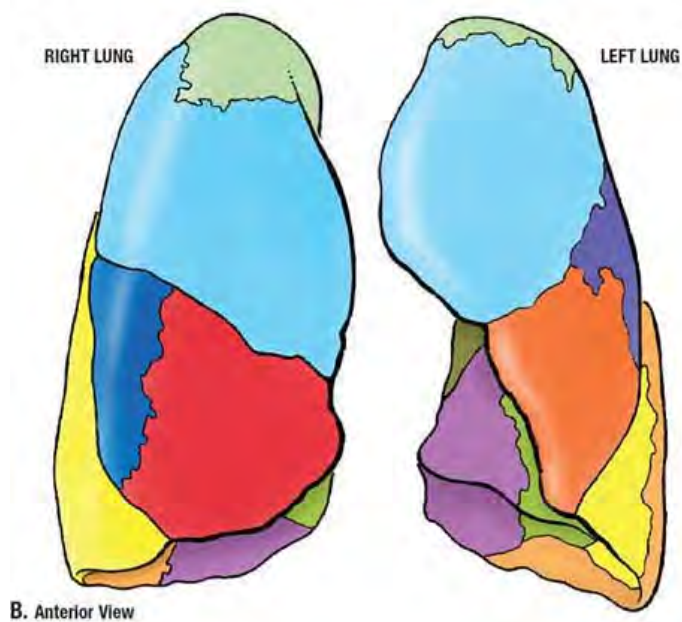
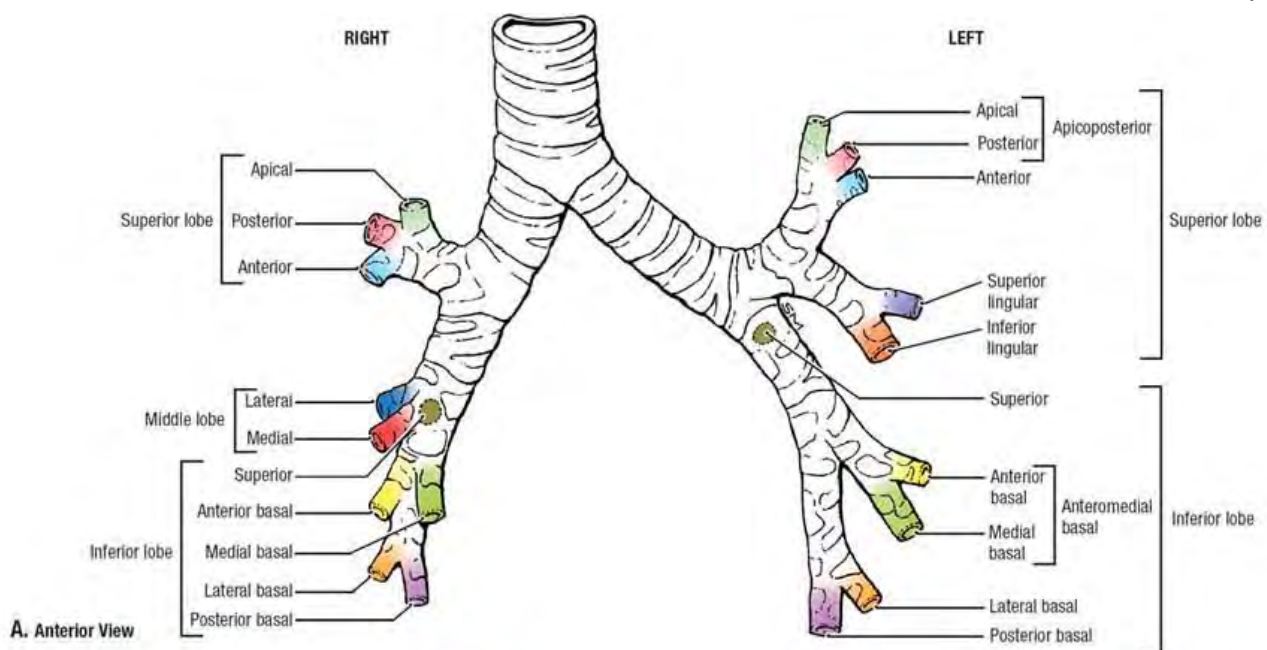
A. There are 10 tertiary or segmental bronchi on the right, and 8 on the left. Note that on the left, the apical and posterior bronchi arise from a single stem, as do the anterior basal and medial basal. B to F. A bronchopulmonary segment consists of a tertiary bronchus, pulmonary vein and artery, and the portion of lung they serve. These structures are surgically separable to allow segmental resection of the lung. To prepare these specimens, the tertiary bronchi of fresh lungs were isolated within the hilum and injected with latex of various colors. Minor variations in the branching of the bronchi result in variations in the surface patterns.

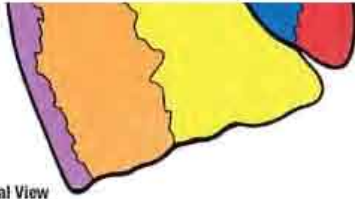
---

P.37

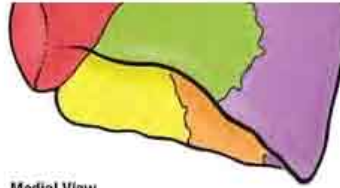
Knowledge of the anatomy of the bronchopulmonary segments is essential for precise interpretations of diagnostic images of the lungs and for surgical resection (removal) of diseased segments. During the treatment of lung cancer, the surgeon may remove a whole lung (*pneumonectomy*), a lobe (*lobectomy*), or one or more bronchopulmonary segments (*segmentectomy*). Knowledge and understanding of the bronchopulmonary segments and their relationship to the bronchial tree are also essential for planning drainage and clearance techniques used in physical therapy for enhancing drainage from specific areas (e.g., in patients with pneumonia or cystic fibrosis).



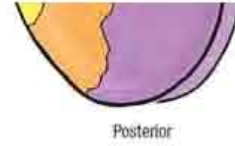




Lateral View



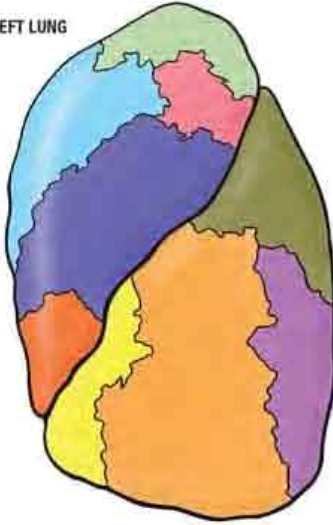
Medial View



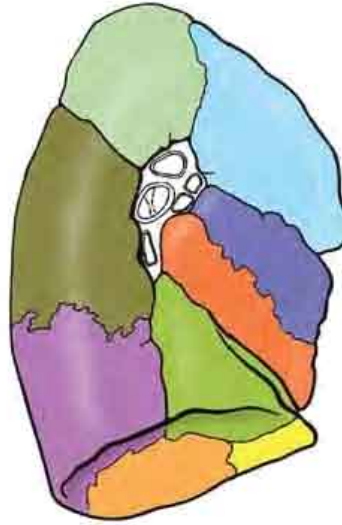
Posterior

Inferior View

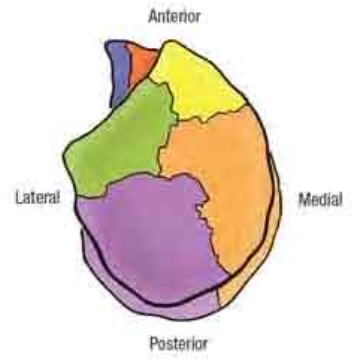
LEFT LUNG



D. Lateral View



E. Medial View



F. Inferior View



Authors: Agur, Anne M.R.; Dalley, Arthur F.

Title: *Grant's Atlas of Anatomy, 12th Edition*

Copyright ©2009 Lippincott Williams & Wilkins

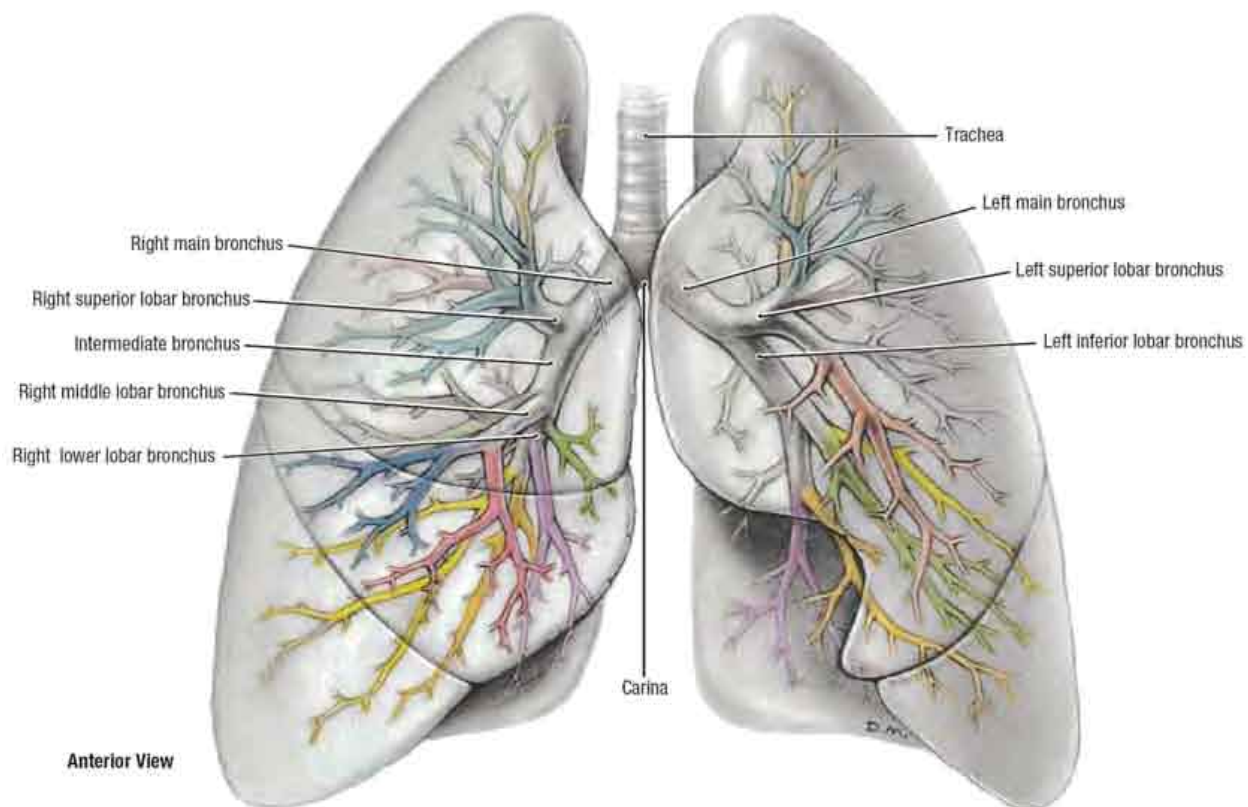
> Table of Contents > Chapter 1 - Thorax > 1.32 Trachea and bronchi in situ

---






















## 1.32 Trachea and bronchi in situ

Part of "Chapter 1 - Thorax "

- The segmental (tertiary) bronchi are color coded.
  - The trachea bifurcates into right and left main (primary) bronchi; the right main bronchus is shorter, wider, and more vertical than the left. Therefore, it is more likely that foreign objects will become lodged in the right main bronchus.
  - The right main bronchus gives off the right superior lobe bronchus (eparterial bronchus) before entering the hilum (hilus) of the lung; after entering the hilum, the right middle and inferior lobar bronchi branch off.
  - The left main bronchus divides into the left superior and left inferior lobar bronchi; the lobar bronchi further divide into segmental (tertiary) bronchi.
- When examining the bronchi with a *bronchoscope*—an endoscope for inspecting the interior of the tracheobronchial tree for diagnostic purposes—one can observe a ridge, the *carina*, between the orifices of the main bronchi. If the tracheobronchial lymph nodes in the angle between the main bronchi are enlarged because cancer cells have metastasized from a bronchogenic carcinoma, for example, the carina is distorted, widened posteriorly, and immobile.



#### Segmental bronchi:

RIGHT LUNG		LEFT LUNG	
Superior Lobe		Superior Lobe	
	Apical		Apical
	Posterior		Posterior
	Anterior		Anterior
			Superior lingular
			Inferior lingular
Middle Lobe		Inferior Lobe	
	Lateral		Superior
	Medial		Anterior basal
			Medial basal
			Lateral basal
			Posterior basal
Inferior Lobe			
	Superior	 Anteromedial basal	
	Anterior basal		
	Medial basal		
	Lateral basal		
	Posterior basal		

## 1.33 Bronchograms

*Part of* "Chapter 1 - Thorax "

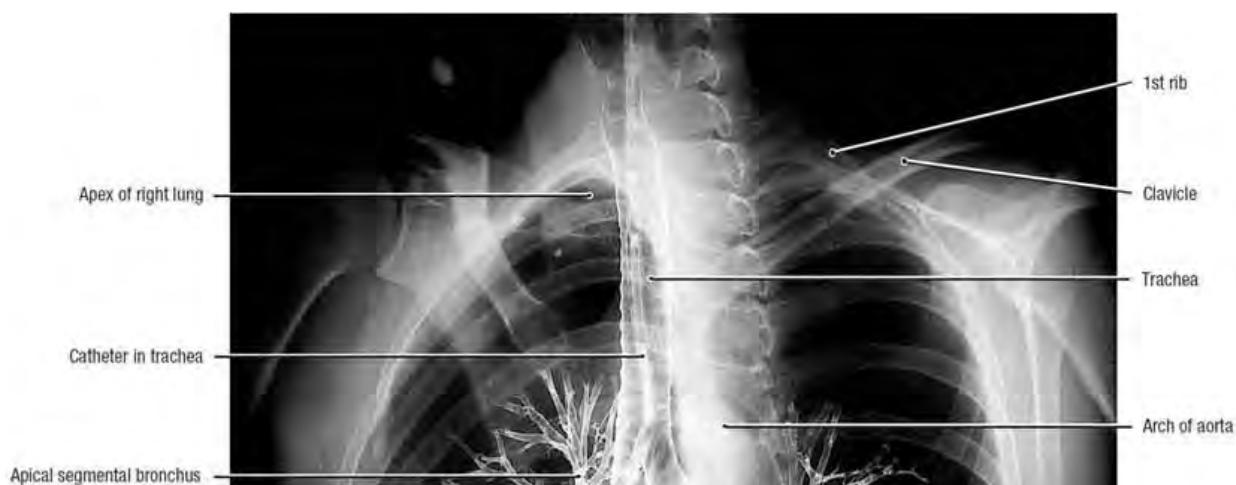### A. Bronchogram of tracheobronchial tree.

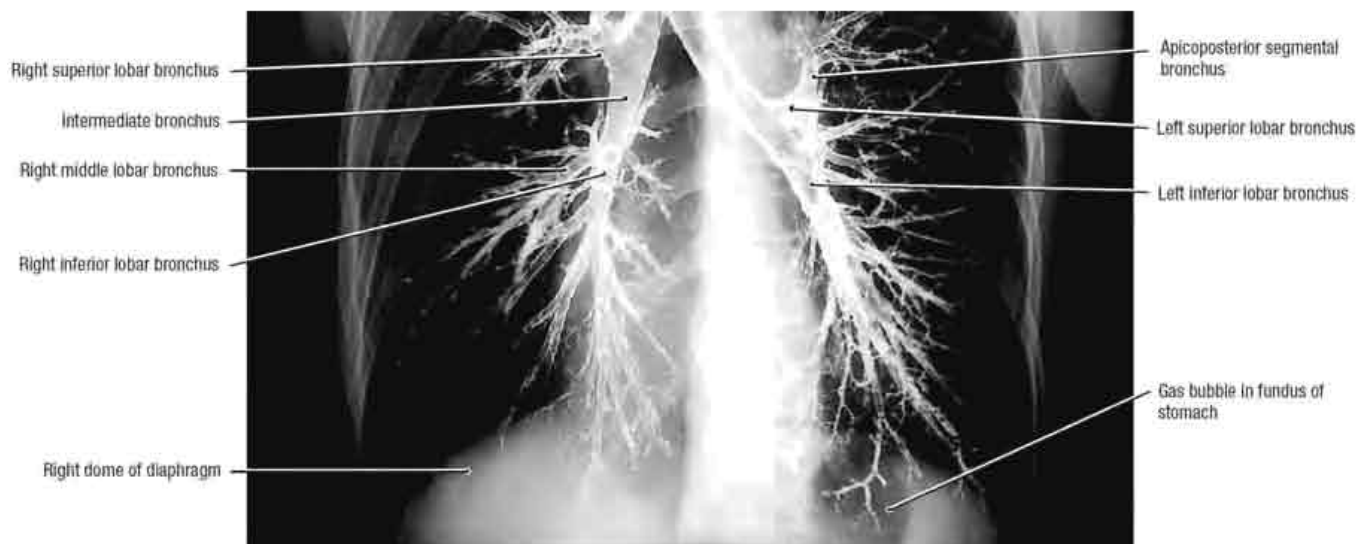
Because the right bronchus is wider and shorter and runs more vertically than the left bronchus, aspirated foreign bodies are more likely to enter and lodge in it or one of its branches. A potential hazard encountered by dentists is an aspirated foreign body, such as a piece of tooth, filling material, or a small instrument. Such objects are also most likely to enter the right main bronchus.

P.40

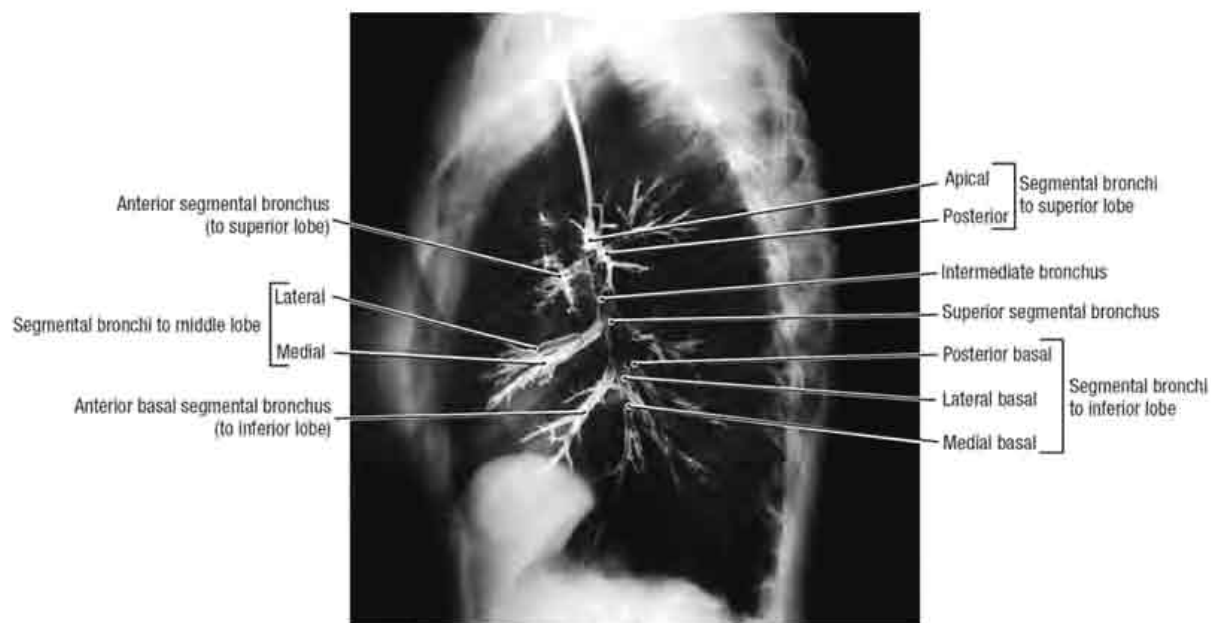
B. Right lateral bronchogram, showing segmental bronchi. C. Left lateral bronchogram, showing segmental bronchi.

P.41

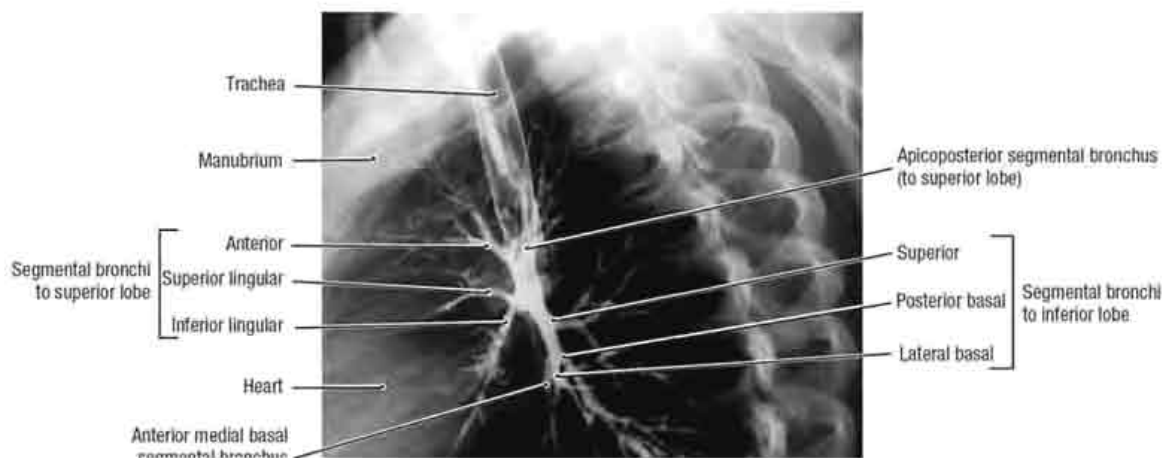




**A. Slightly Oblique Anteroposterior View**

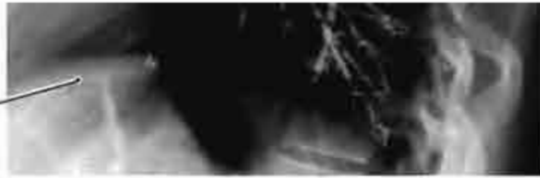

**B. Right Segmental Bronchi, Right Lateral View**



segmental bronchus  
(to inferior lobe)

Diaphragm



**C. Left Segmental Bronchi, Left Lateral View**

Authors: Agur, Anne M.R.; Dalley, Arthur F.

Title: *Grant's Atlas of Anatomy, 12th Edition*

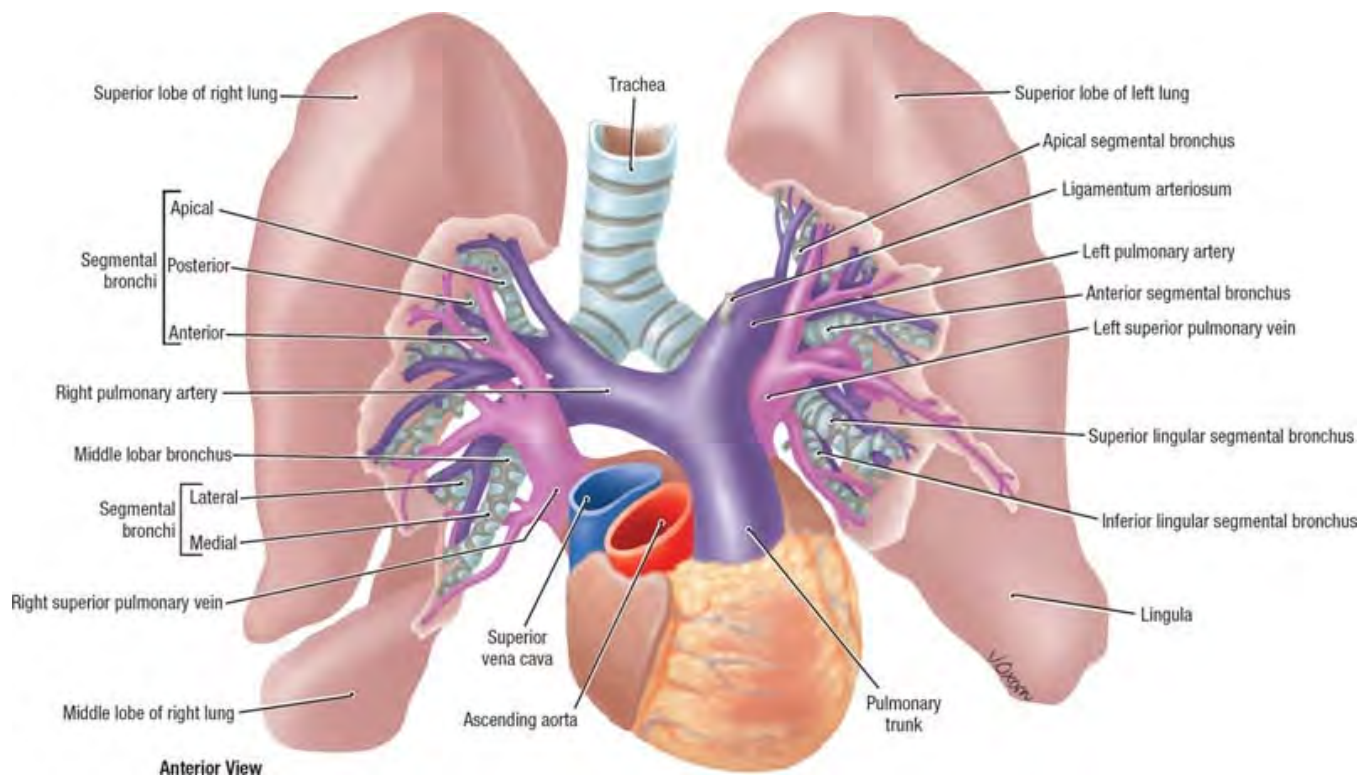
Copyright ©2009 Lippincott Williams & Wilkins

> Table of Contents > Chapter 1 - Thorax > 1.34 Pulmonary artery, lungs retracted (inferior lobes not included)

## 1.34 Pulmonary artery, lungs retracted (inferior lobes not included)

Part of "Chapter 1 - Thorax "

The middle lobe of the right lung is drained by the right superior pulmonary vein.



Authors: Agur, Anne M.R.; Dalley, Arthur F.

Title: *Grant's Atlas of Anatomy, 12th Edition*

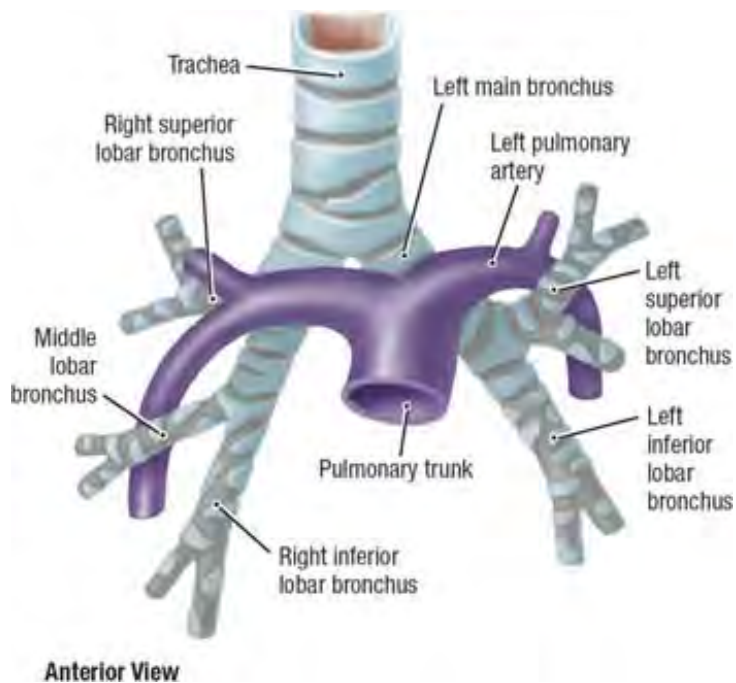
Copyright ©2009 Lippincott Williams & Wilkins

> Table of Contents > Chapter 1 - Thorax > 1.35 Relationship of bronchi and pulmonary arteries

---

## 1.35 Relationship of bronchi and pulmonary arteries

*Part of* "Chapter 1 - Thorax"





Authors: Agur, Anne M.R.; Dalley, Arthur F.

Title: *Grant's Atlas of Anatomy, 12th Edition*

Copyright ©2009 Lippincott Williams & Wilkins

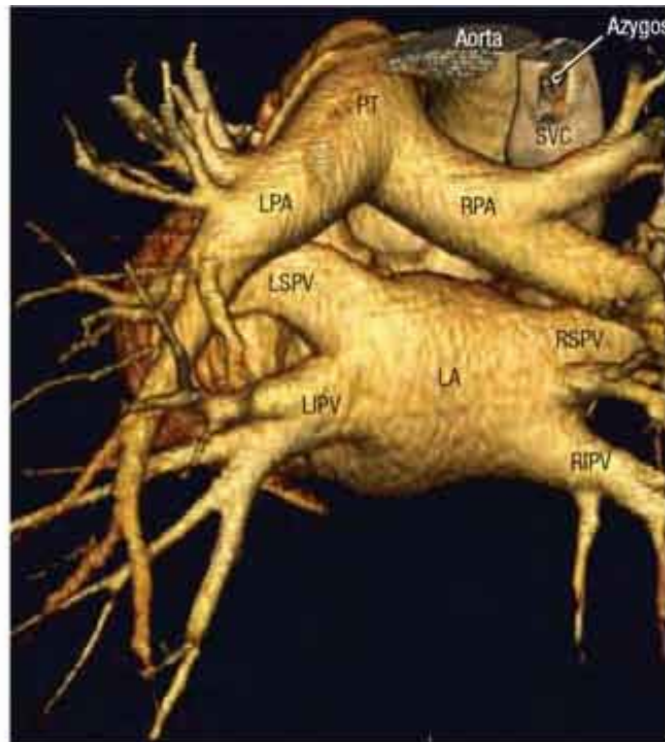
> Table of Contents > Chapter 1 - Thorax > 1.36 3-D volume reconstruction (3DVR) of pulmonary arteries and veins and left atrium

---

## 1.36 3-D volume reconstruction (3DVR) of pulmonary arteries and veins and left atrium

*Part of* "Chapter 1 - Thorax"

The pulmonary trunk (*PT*) divides into a longer right pulmonary artery (*RPA*) and shorter left pulmonary artery (*LPA*); the left superior (*LSPV*) and inferior (*LIPV*) and the right superior (*RSPV*) and inferior (*RIPV*) pulmonary veins drain into the left atrium (*LA*). Superior vena cava (*SVC*).



Posterior View

Authors: Agur, Anne M.R.; Dalley, Arthur F.

Title: *Grant's Atlas of Anatomy, 12th Edition*

Copyright ©2009 Lippincott Williams & Wilkins

> Table of Contents > Chapter 1 - Thorax > 1.37 Innervation of lungs

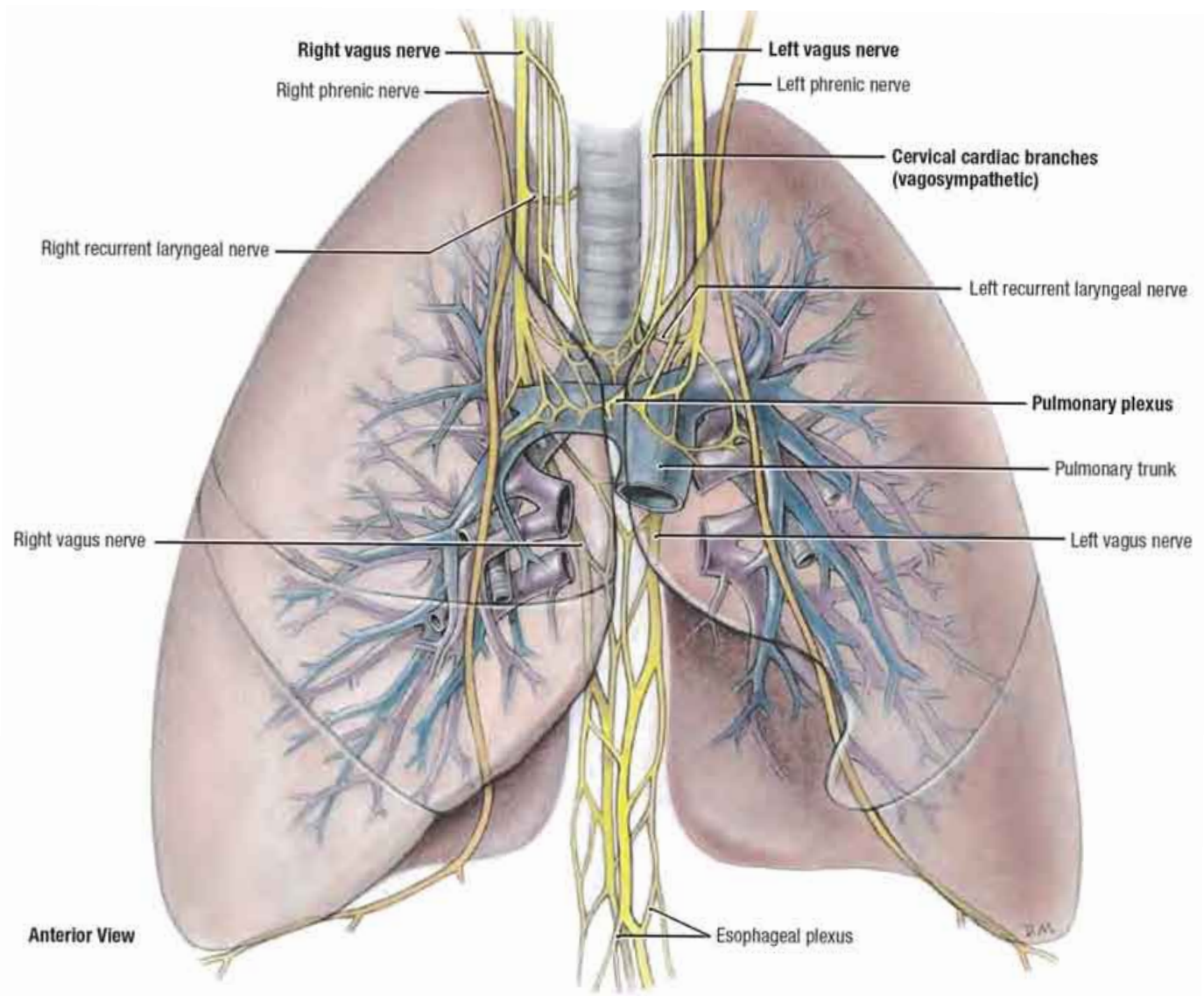
---

## 1.37 Innervation of lungs

*Part of* "Chapter 1 - Thorax "

- The pulmonary plexuses, located anterior and posterior to the roots of the lungs, receive sympathetic contributions from the right and left sympathetic trunks (2nd to 5th thoracic ganglia, not shown) and parasympathetic contributions from the right and left vagus nerves; cell bodies of postsynaptic parasympathetic neurons are in the pulmonary plexuses and along the branches of the pulmonary tree.
- The right and left vagus nerves continue inferiorly from the posterior pulmonary plexus to contribute fibers to the esophageal plexus.
- The phrenic nerves pass anterior to the root of the lung on their way to the diaphragm.

- The visceral pleura is insensitive to pain because its innervation is autonomic. The autonomic nerves reach the visceral pleura in company with the bronchial vessels. The visceral pleura receives no nerves of general sensation.
- The parietal pleura is sensitive to pain because it is richly supplied by branches of the somatic intercostal and phrenic nerves. Irritation of the parietal pleura produces local pain and referred pain to the areas sharing innervation by the same segments of the spinal cord.



Authors: Agur, Anne M.R.; Dalley, Arthur F.

Title: *Grant's Atlas of Anatomy, 12th Edition*

Copyright ©2009 Lippincott Williams & Wilkins

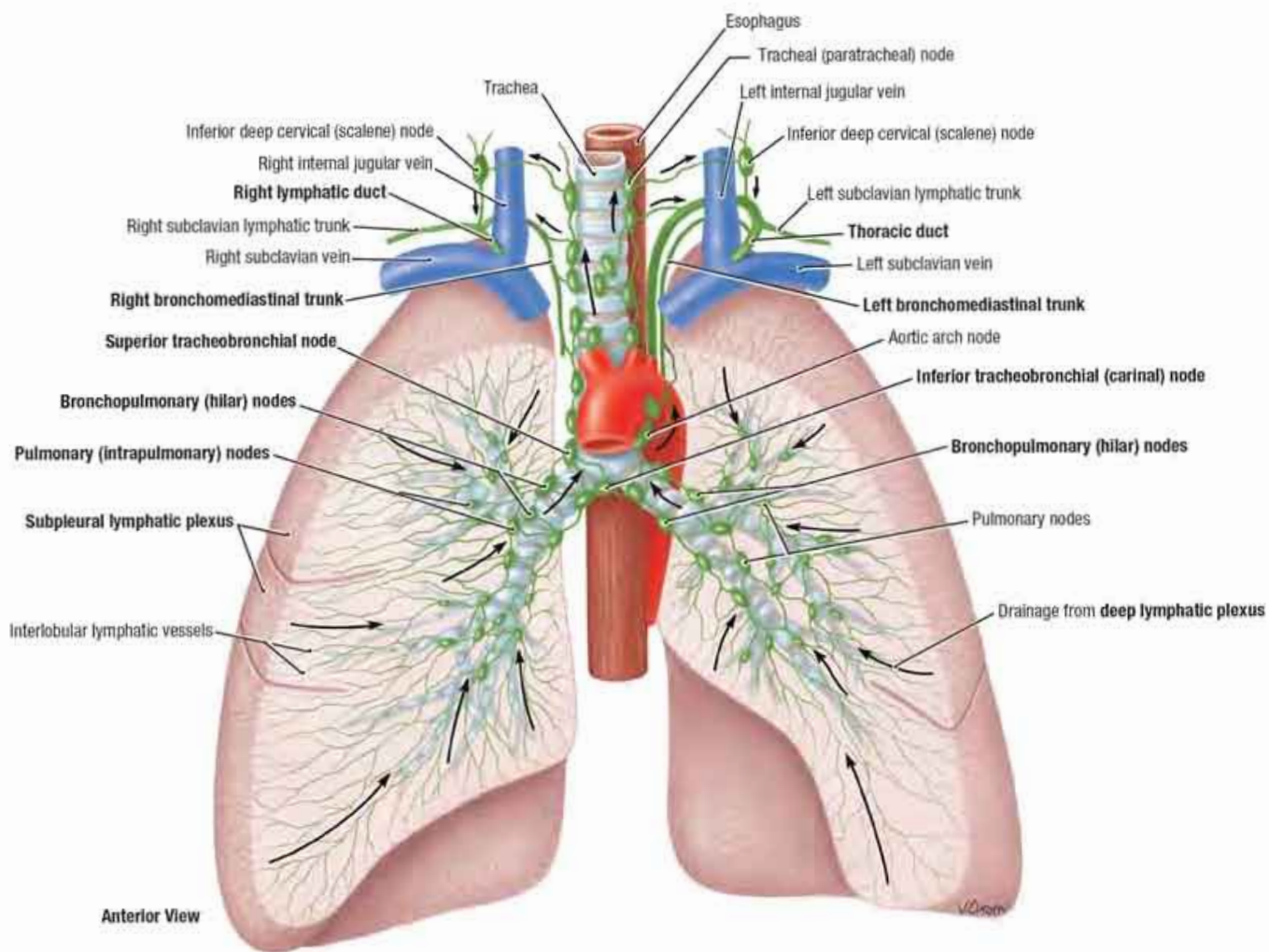
> Table of Contents > Chapter 1 - Thorax > 1.38 Lymphatic drainage of lungs

---

## 1.38 Lymphatic drainage of lungs

*Part of* "Chapter 1 - Thorax "

- Lymphatic vessels originate in the subpleural (superficial) and deep lymphatic plexuses.
- The subpleural lymphatic plexus is superficial, lying deep to the visceral pleura, and drains lymph from the surface of the lung to the bronchopulmonary (hilar) nodes.
- The deep lymphatic plexus is in the lung and follows the bronchi and pulmonary vessels to the pulmonary, and then bronchopulmonary, nodes located at the root of the lung.
- All lymph from the lungs enters the inferior (carinal) and superior tracheobronchial nodes and then continues to the right and left bronchomediastinal trunks to drain into the venous system via the right lymphatic and thoracic ducts; lymph from the left inferior lobe passes largely to the right side.
- Lymph from the parietal pleura drains into lymph nodes of the thoracic wall (Fig. 1.74 ).



Authors: Agur, Anne M.R.; Dalley, Arthur F.

Title: *Grant's Atlas of Anatomy, 12th Edition*

Copyright ©2009 Lippincott Williams & Wilkins

> Table of Contents > Chapter 1 - Thorax > 1.39 Surface markings of the heart, heart valves, and their auscultation areas

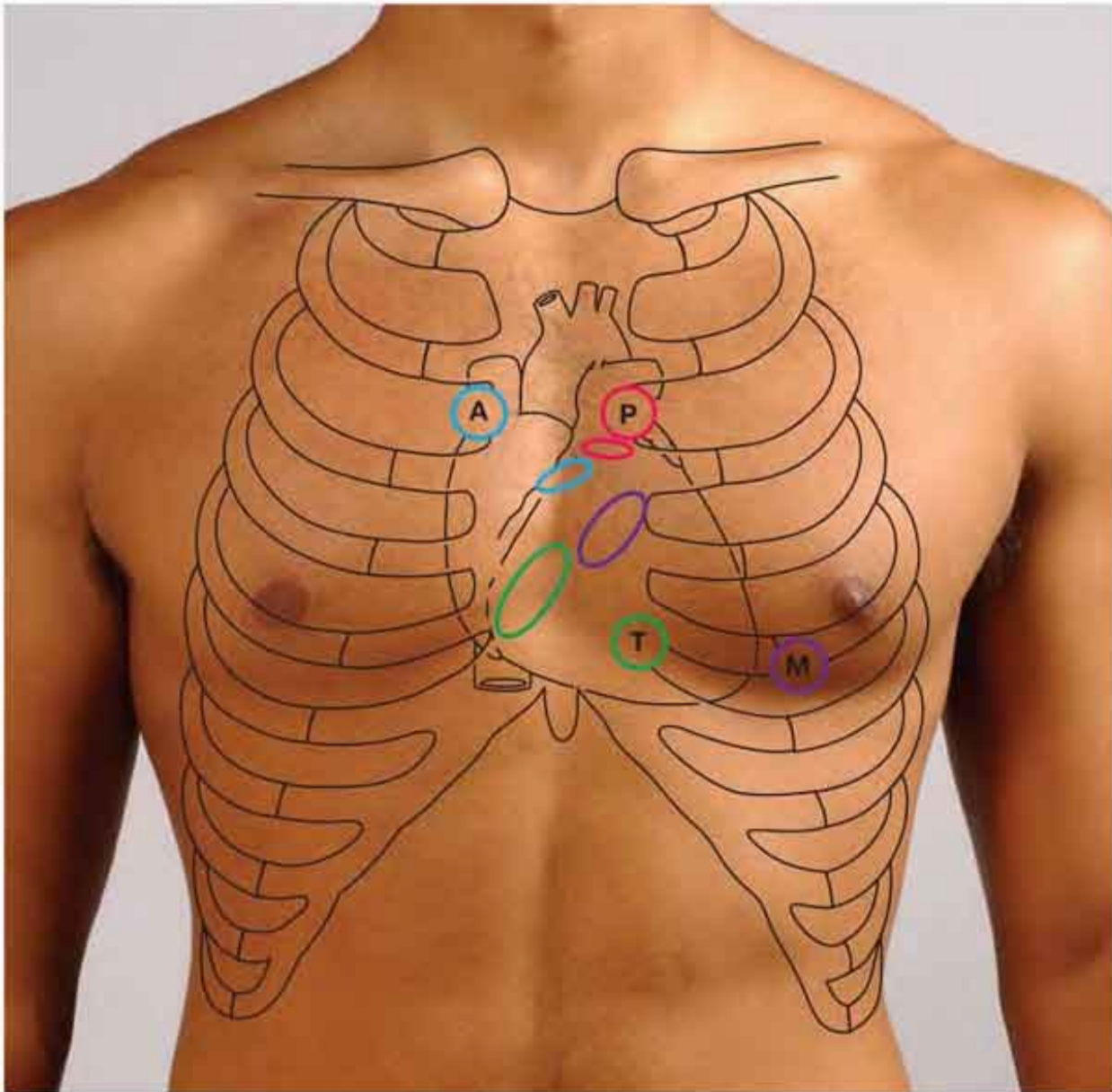
---

## 1.39 Surface markings of the heart, heart valves, and their auscultation areas

*Part of* "Chapter 1 - Thorax"

- The location of each heart valve in situ is indicated by a colored oval and the area of auscultation of the valve is indicated as a circle of the same color containing the first letter of the valve name: the tricuspid valve (*T*) is green, the mitral valve (*M*) is purple, the pulmonary valve (*P*) is pink and the aortic valve (*A*) is blue.
- The auscultation areas are sites where the sounds of each of the heart's valves can be heard most distinctly through a stethoscope.
- The aortic (*A*) and pulmonary (*P*) auscultation areas are in the 2nd intercostal space to the right and left of the sternal border; the tricuspid area (*T*) is near the left sternal border in the 5th or 6th intercostal space; the mitral valve (*M*) is heard best near the apex of the heart in the 5th intercostal space in the midclavicular line.





Anterior View

Authors: Agur, Anne M.R.; Dalley, Arthur F.

Title: *Grant's Atlas of Anatomy, 12th Edition*

Copyright ©2009 Lippincott Williams & Wilkins

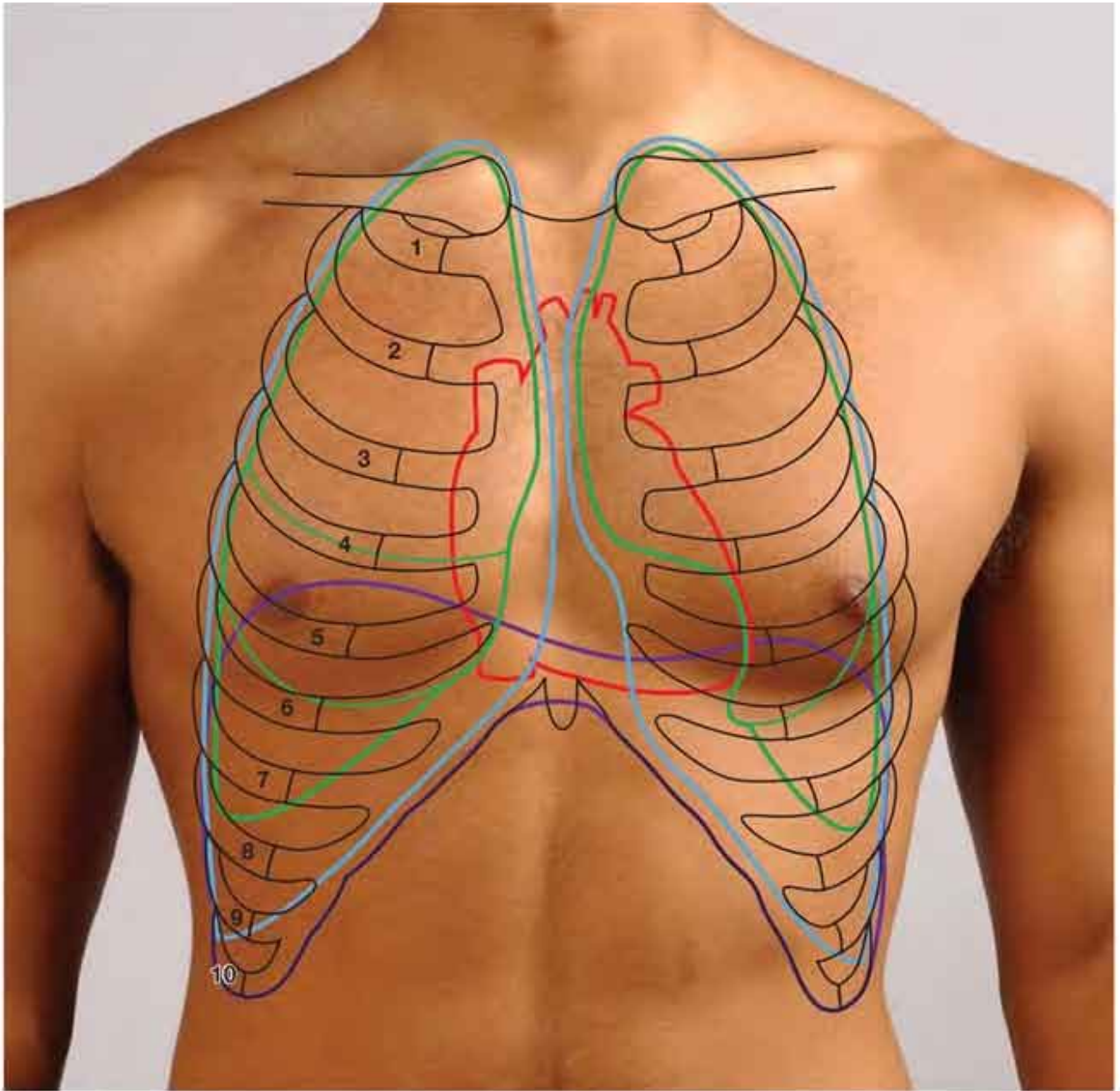
> Table of Contents > Chapter 1 - Thorax > 1.40 Surface markings of the heart, lungs, and diaphragm

---

## 1.40 Surface markings of the heart, lungs, and diaphragm

*Part of "Chapter 1 - Thorax "*

- Outlined are the heart (*red*), lungs (*green*), parietal pleura (*blue*), and diaphragm (*purple*).
- The superior border of the heart is represented by a slightly oblique line joining the 3rd costal cartilages; the convex right side of the heart projects lateral to the sternum and inferiorly, lying at the 6th or 7th costochondral junction; the inferior border of the heart lying superior to the central tendon of the diaphragm and sloping slightly inferiorly to the apex at the 5th interspace at the midclavicular line.
- The right dome of the diaphragm is higher than the left because of the large size of the liver inferior to the dome; during expiration the right dome reaches as high as the 5th rib and the left dome ascends to the 5th intercostal space.
- The left pleural cavity is smaller than the right because of the projection of the heart to the left side.



Anterior View

Authors: Agur, Anne M.R.; Dalley, Arthur F.

Title: *Grant's Atlas of Anatomy, 12th Edition*

Copyright ©2009 Lippincott Williams & Wilkins

> Table of Contents > Chapter 1 - Thorax > 1.41 Heart and great vessels

---

## 1.41 Heart and great vessels

*Part of* "Chapter 1 - Thorax "

A.

- The right border of the heart, formed by the right atrium, is slightly convex and almost in line with the superior vena cava.
- The inferior border is formed primarily by the right ventricle and part of the left ventricle.
- The left border is formed primarily by the left ventricle and part of the left auricle.

B.

- 3-D volume reconstruction of heart and coronary vessels. Numbers refer to structures in A.

---

P.47

C.

- Most of the left atrium and left ventricle are visible in this posteroinferior view.
- The right and left pulmonary veins open into the left atrium.
- The right and left pulmonary arteries are just superior and parallel to the

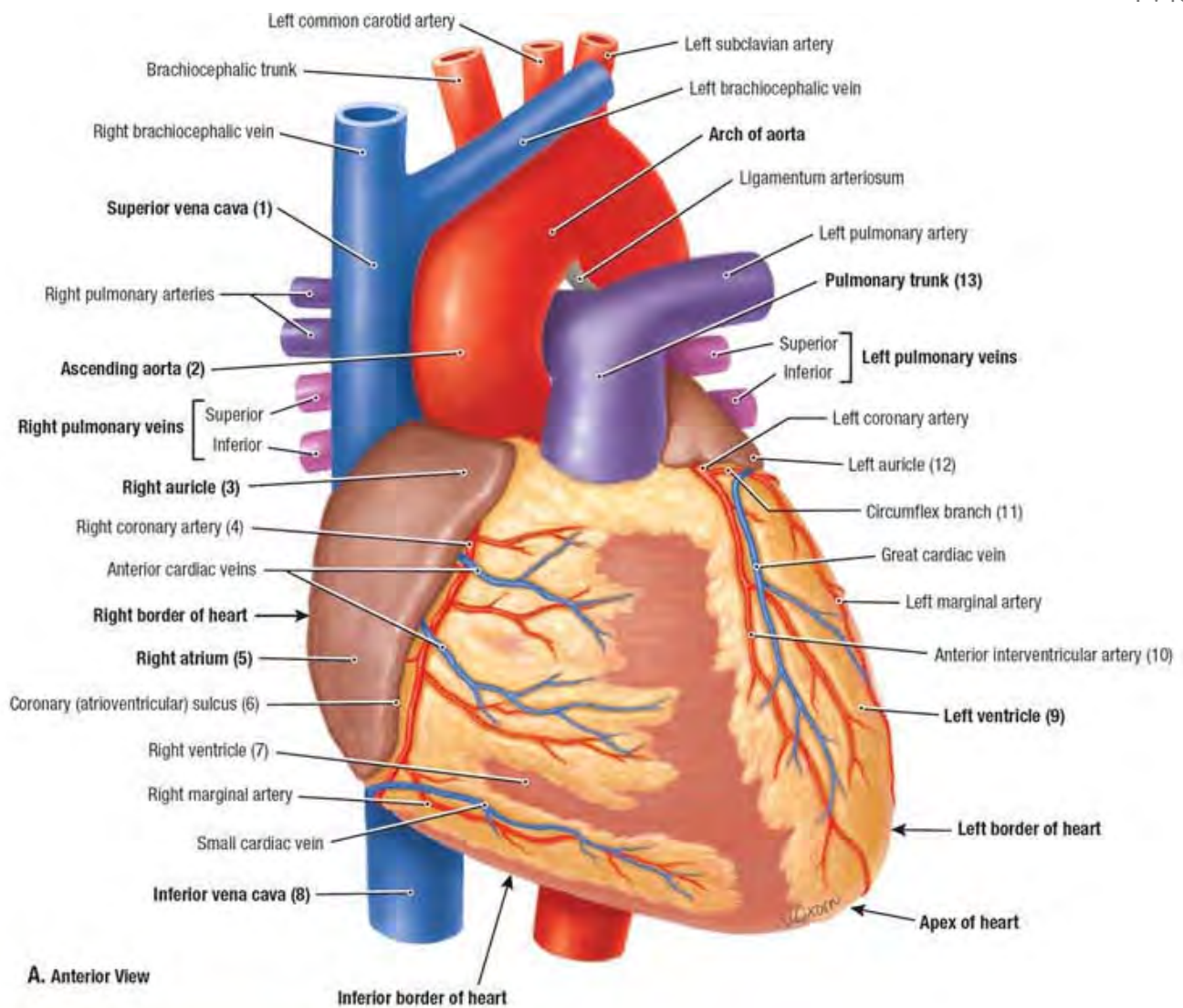
pulmonary veins.

- The arch of the aorta is arched in two planes: superiorly and to the left.
- The azygos vein arches over the right pulmonary vessels (and bronchus).

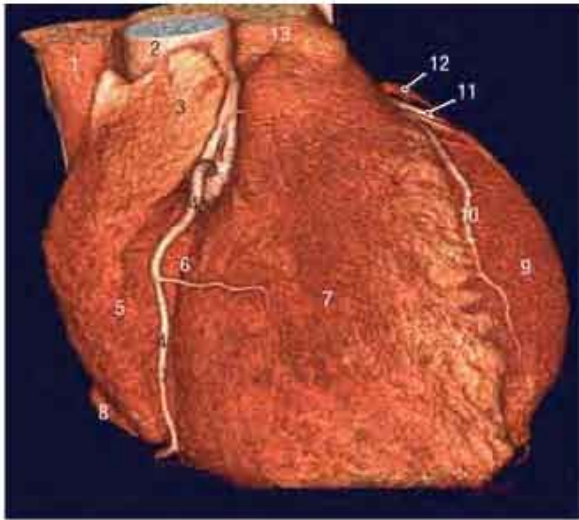
D.

- 3-D volume reconstruction of heart and coronary vessels. Numbers refer to structures in C.

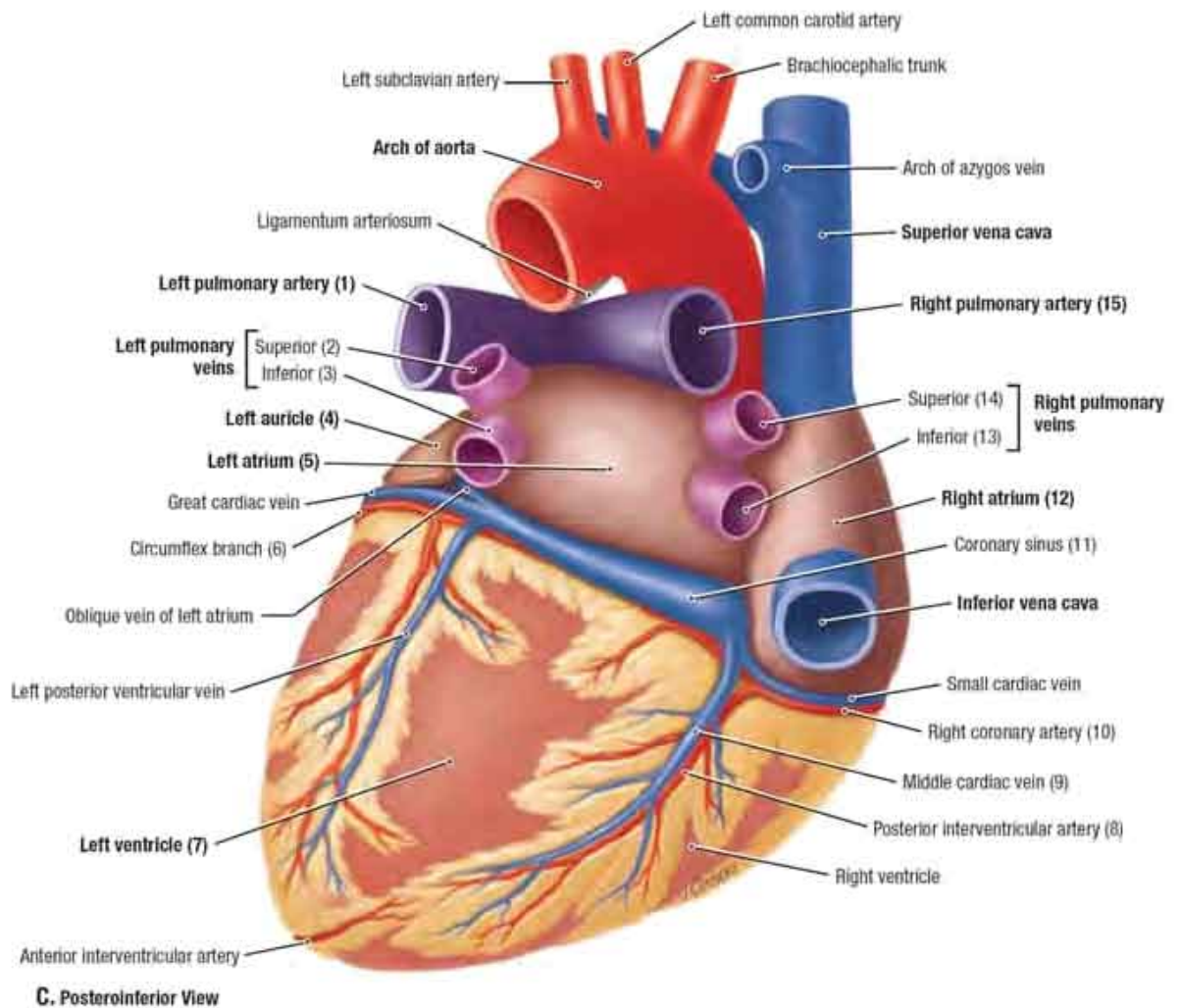
P.48







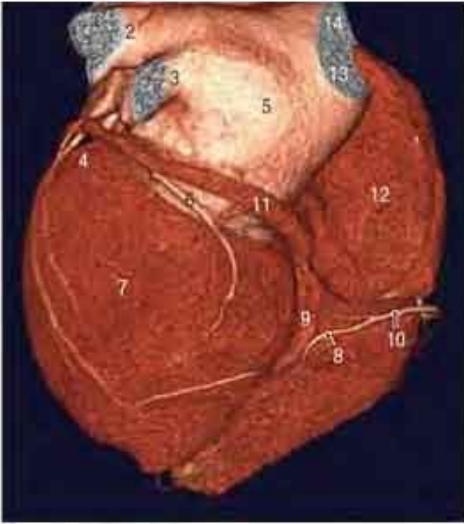
**B. Anterior View**



**C. Posteroinferior View**







D. Posteroinferior View

Authors: Agur, Anne M.R.; Dalley, Arthur F.

Title: *Grant's Atlas of Anatomy, 12th Edition*

Copyright ©2009 Lippincott Williams & Wilkins

> Table of Contents > Chapter 1 - Thorax > 1.42 Pericardium in relation to sternum

---

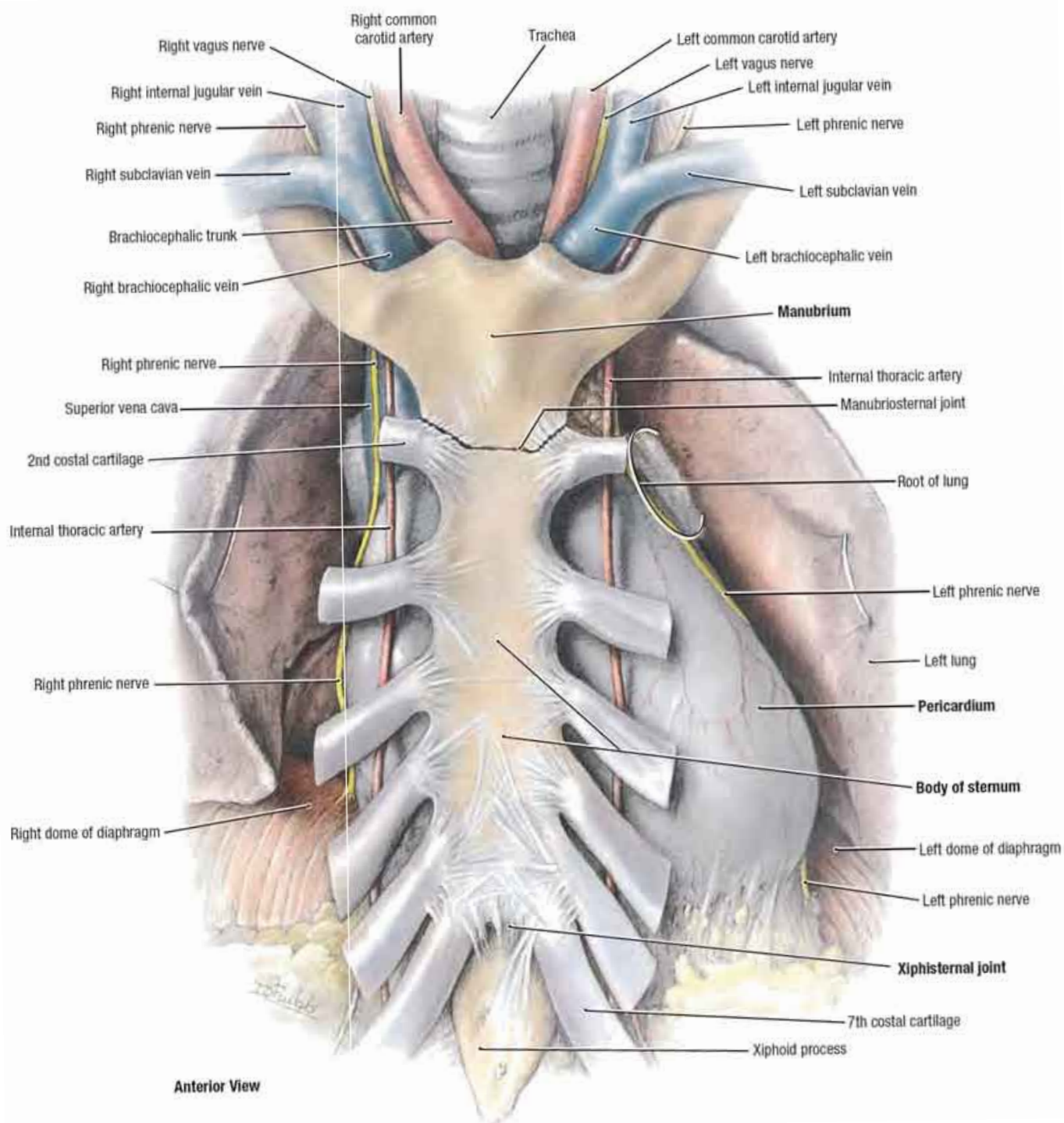
## 1.42 Pericardium in relation to sternum

*Part of* "Chapter 1 - Thorax "

- The pericardium lies posterior to the body of the sternum, extending from just superior to the sternal angle to the level of the xiphisternal joint; approximately two thirds lies to the left of the median plane.
- The heart lies between the sternum and the anterior mediastinum anteriorly and the vertebral column and the posterior mediastinum posteriorly;

in cardiac compression, the sternum is depressed 4 to 5 cm, forcing blood out of the heart and into the great vessels.

- Internal thoracic arteries arise from the subclavian arteries and descend posterior to the costal cartilages, running lateral to the sternum and anterior to the pleura.



Authors: Agur, Anne M.R.; Dalley, Arthur F.

Title: *Grant's Atlas of Anatomy, 12th Edition*

Copyright ©2009 Lippincott Williams & Wilkins

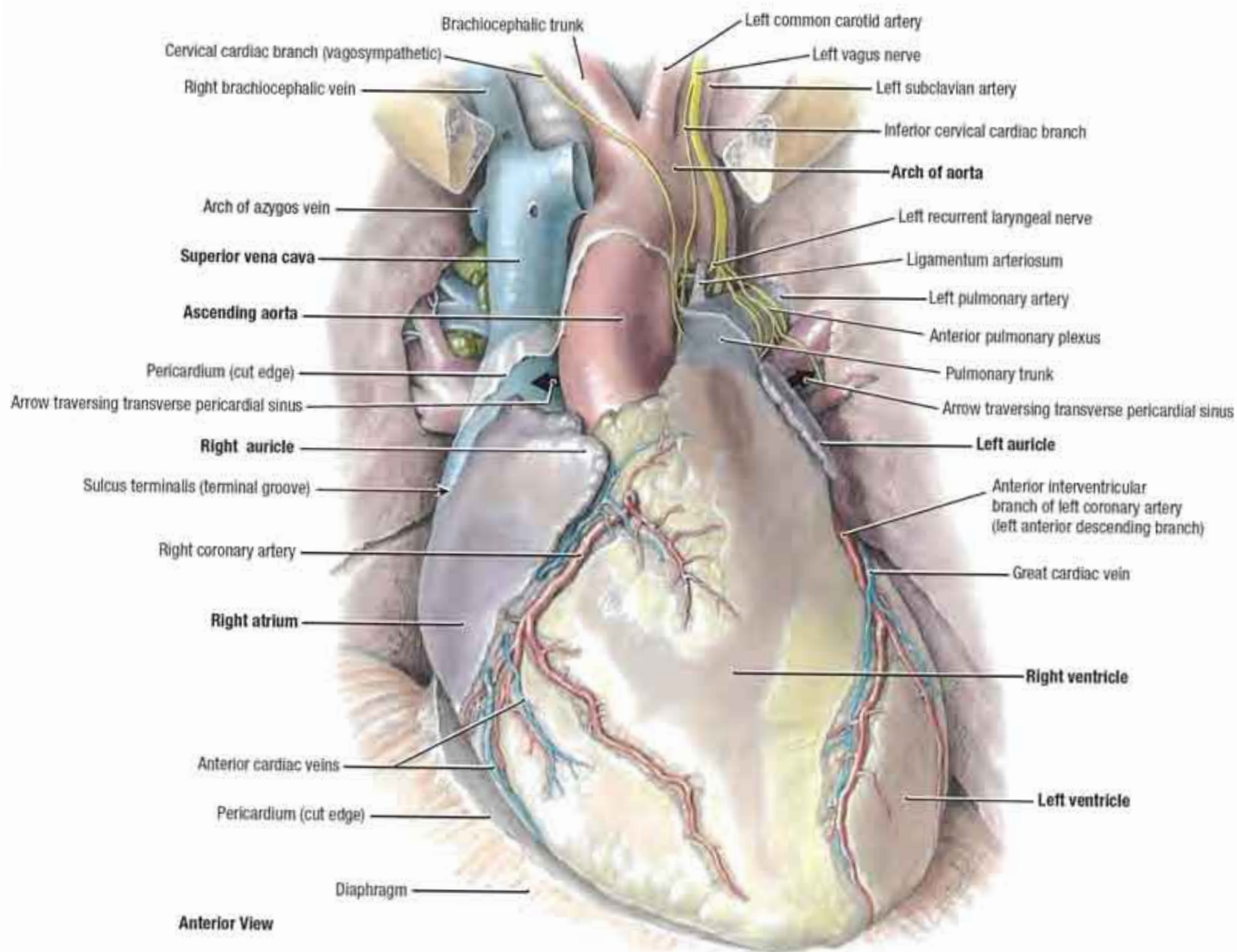
> Table of Contents > Chapter 1 - Thorax > 1.43 Sternocostal (anterior) surface of heart and great vessels in situ

---

## 1.43 Sternocostal (anterior) surface of heart and great vessels in situ

*Part of* "Chapter 1 - Thorax "

- The right ventricle forms most of the sternocostal surface.
- The entire right auricle and much of the right atrium are visible anteriorly, but only a small portion of the left auricle is visible; the auricles, like a closing claw, grasp the origins of the pulmonary trunk and ascending aorta from a posterior approach.
- The ligamentum arteriosum passes from the origin of the left pulmonary artery to the arch of the aorta.
- The right coronary artery courses in the anterior atrioventricular groove, and the anterior interventricular branch of the left coronary artery (anterior descending branch) courses in the anterior interventricular groove.
- The left vagus nerve passes lateral to the arch of the aorta and then posterior to the root of the lung; the left recurrent laryngeal nerve passes inferior to the arch of the aorta posterior to the ligamentum arteriosum.
- The great cardiac vein ascends beside the anterior interventricular branch of the left coronary artery to drain into the coronary sinus posteriorly.



Authors: Agur, Anne M.R.; Dalley, Arthur F.

Title: *Grant's Atlas of Anatomy, 12th Edition*

Copyright ©2009 Lippincott Williams & Wilkins

> Table of Contents > Chapter 1 - Thorax > 1.44 Heart and pericardium

---

## 1.44 Heart and pericardium

*Part of* "Chapter 1 - Thorax "

- This heart (A) was removed from the interior of the pericardial sac (B).
- The entire base, or posterior surface, and part of the diaphragmatic or inferior surface of the heart are in view.
- The superior vena cava and larger inferior vena cava join the superior and inferior aspects of the right atrium.
- The left atrium forms the greater part of the base (posterior surface) of the heart.
- The left coronary artery in this specimen is dominant, since it supplies the posterior interventricular branch.
- Most branches of cardiac veins cross branches of the coronary arteries superficially.
- The visceral layer of serous pericardium (epicardium) covers the surface of the heart and reflects onto the great vessels; from around the great vessels, the serous pericardium reflects to line the internal aspect of the fibrous pericardium as the parietal layer of serous pericardium. The fibrous pericardium and the parietal layer of serous pericardium form the pericardial sac that encases the heart.
- Note the cut edges of the reflections of serous pericardia around the arterial vessels (the pulmonary trunk and aorta) and venous vessels (the superior and inferior venae cavae and the pulmonary veins).



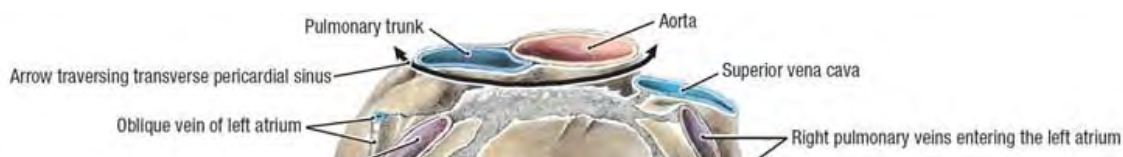- The transverse pericardial sinus is especially important to cardiac surgeons. After the pericardial sac has been opened anteriorly, a finger can be passed through the transverse pericardial sinus posterior to the aorta and pulmonary trunk. By passing a surgical clamp or placing a ligature around these vessels, inserting the tubes of a coronary bypass machine, and then tightening the ligature, surgeons can stop or divert the circulation of blood in these large arteries while performing cardiac surgery.

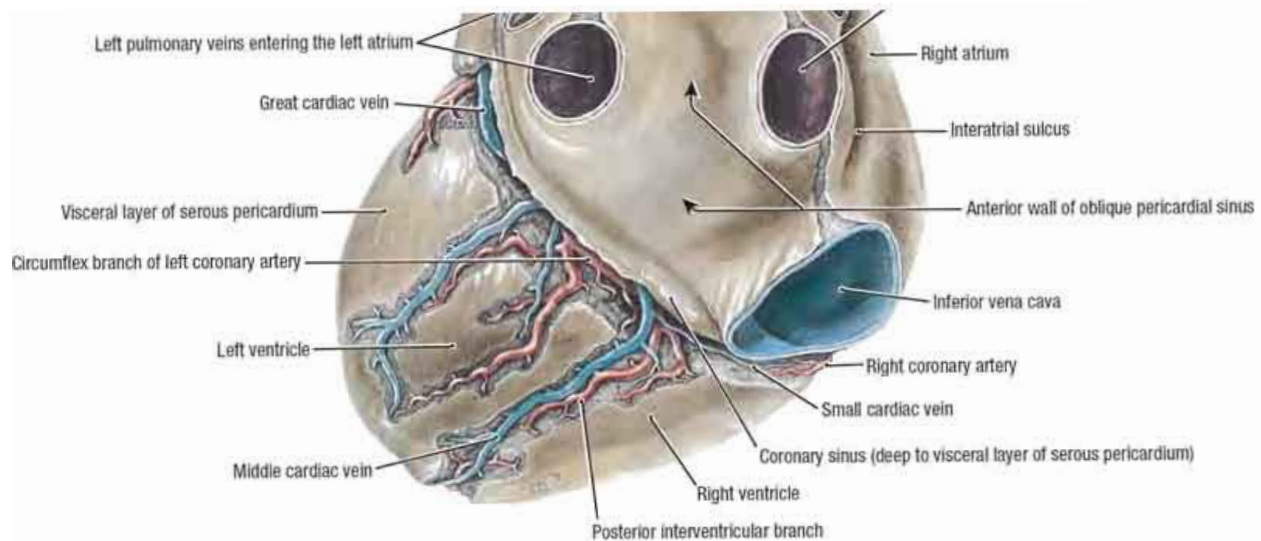
P.51

- Interior of pericardial sac. Eight vessels were severed to excise the heart: superior and inferior venae cavae, four pulmonary veins, and two pulmonary arteries.
- The oblique sinus is bounded anteriorly by the visceral layer of serous pericardium covering the left atrium (Fig. 1.44A ), posteriorly by the parietal layer of serous pericardium lining the fibrous pericardium, and superiorly and laterally by the reflection of serous pericardium around the four pulmonary veins and the superior and inferior venae cavae (Fig. 1.44B ).
- The transverse sinus is bounded anteriorly by the serous pericardium covering the posterior aspect of the pulmonary trunk and aorta, and posteriorly by the visceral pericardium covering the atria (A) .

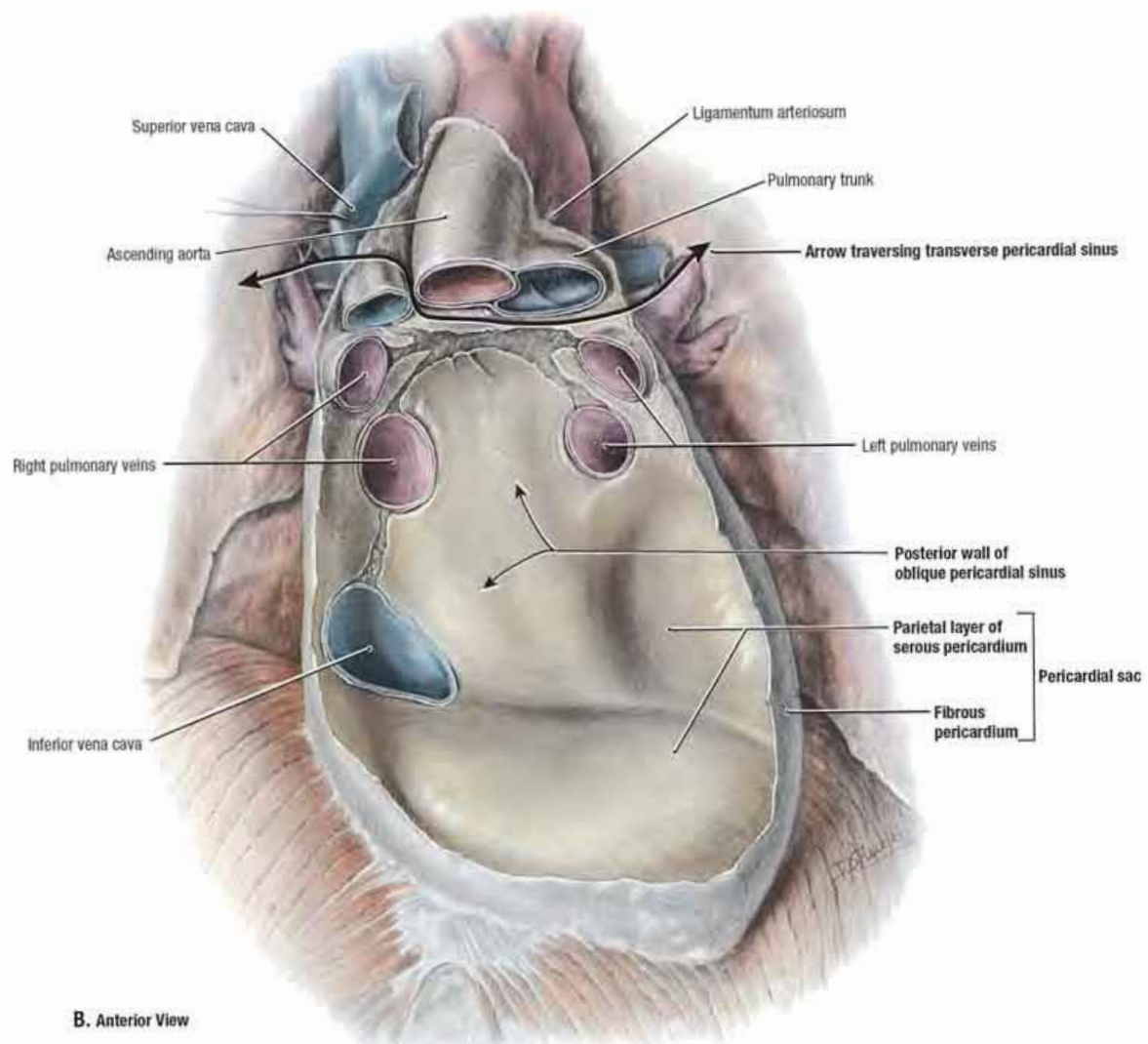
- Cardiac tamponade (heart compression) is due to critically increased volume of fluid outside the heart but inside the pericardial cavity; e.g., due to stab wounds or from perforation of a weakened area of the heart muscle after heart attack (hemopericardium).

P.52





**A. Posterior View**



**B. Anterior View**

Authors: Agur, Anne M.R.; Dalley, Arthur F.

Title: *Grant's Atlas of Anatomy, 12th Edition*

Copyright ©2009 Lippincott Williams & Wilkins

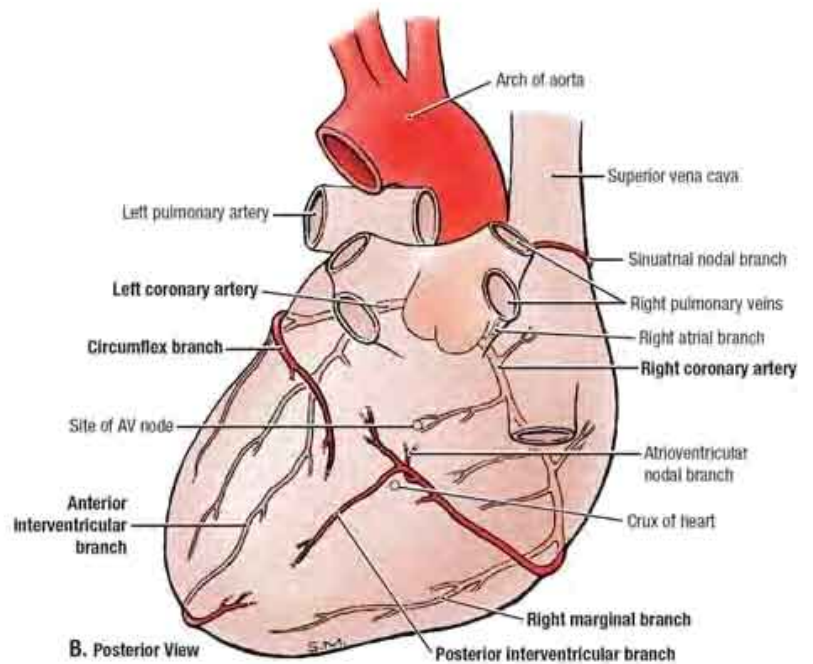
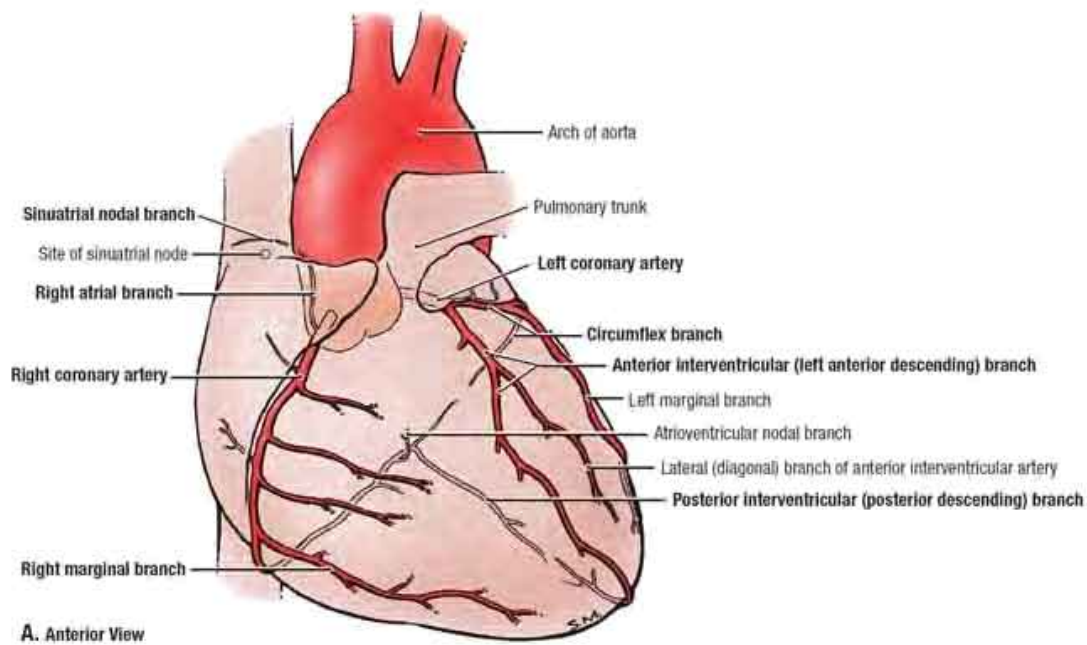
> Table of Contents > Chapter 1 - Thorax > 1.45 Coronary arteries

---

## 1.45 Coronary arteries

*Part of "Chapter 1 - Thorax "*

- The right coronary artery travels in the coronary sulcus to reach the posterior surface of the heart, where it anastomoses with the circumflex branch of the left coronary artery. Early in its course, it gives off the right atrial branch, which supplies the sinuatrial (SA) node via the sinuatrial nodal artery; major branches are a marginal branch supplying much of the anterior wall of the right ventricle, an atrioventricular (AV) nodal artery given off near the posterior border of the interventricular septum, and a posterior interventricular artery in the interventricular groove that anastomoses with the anterior interventricular artery, a branch of the left coronary artery.
- The left coronary artery divides into a circumflex branch that passes posteriorly to anastomose with the right coronary on the posterior aspect of the heart and an anterior descending branch in the interventricular groove; the origin of the SA nodal artery is variable and may be a branch of the left coronary artery.
- The interventricular septum receives its blood supply from septal branches of the two interventricular (descending) branches: typically the anterior two thirds from the left coronary, and the posterior one third from the right (see Fig. 1.48A ).



Authors: Agur, Anne M.R.; Dalley, Arthur F.

Title: *Grant's Atlas of Anatomy, 12th Edition*

Copyright ©2009 Lippincott Williams & Wilkins

> Table of Contents > Chapter 1 - Thorax > 1.46 Cardiac veins

---

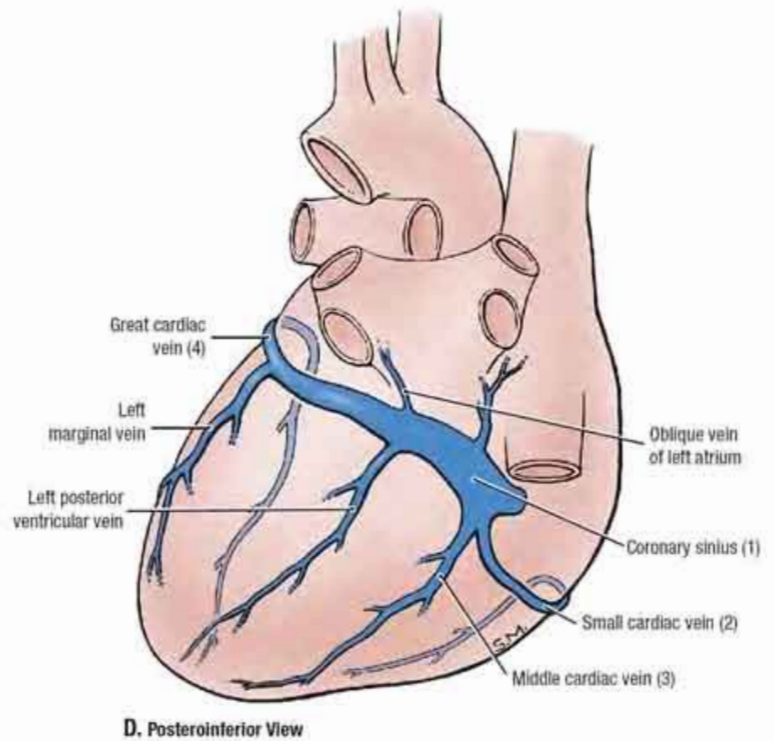
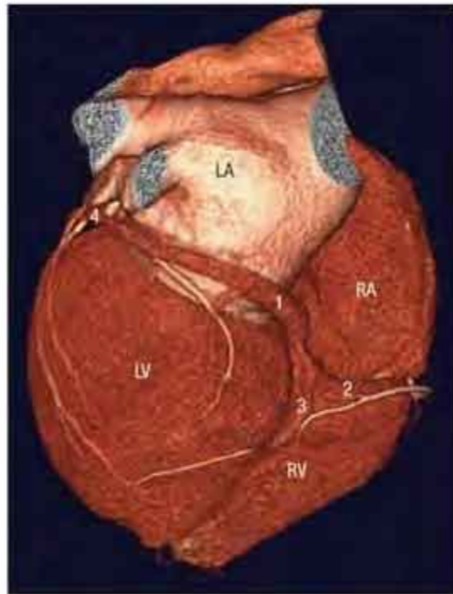
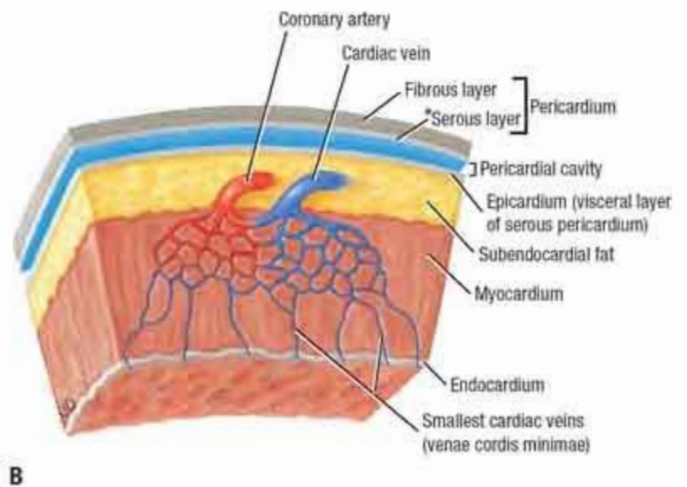
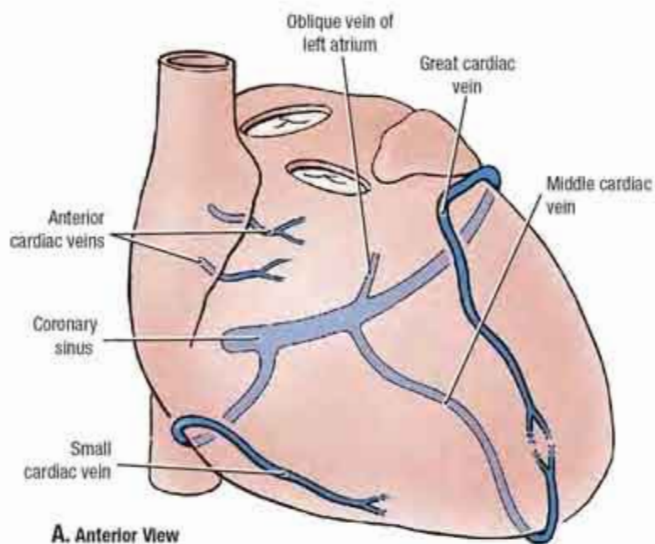
## 1.46 Cardiac veins

*Part of* "Chapter 1 - Thorax "

A. Anterior aspect. B. Smallest cardiac veins. C. 3-D volume reconstruction. Numbers refer to veins in D. Left atrium (*LA*). Right atrium (*RA*). Left ventricle (*LV*); right ventricle (*RV*). D. Posteroinferior aspect.

The coronary sinus is the major venous drainage vessel of the heart; it is located posteriorly in the atrioventricular (coronary) groove and drains into the right atrium. The great, middle, and small cardiac veins; the oblique vein of the left atrium; and the posterior vein of the left ventricle are the principal vessels draining into the coronary sinus. The anterior cardiac veins drain directly into the right atrium. The smallest cardiac veins (venae cordis minimae) drain the myocardium directly into the atria and ventricles (B). In B, the *asterisk* (\*) indicates the parietal layer of serous pericardium (epicardium). The cardiac veins accompany the coronary arteries and their branches.







Authors: Agur, Anne M.R.; Dalley, Arthur F.

Title: *Grant's Atlas of Anatomy, 12th Edition*

Copyright ©2009 Lippincott Williams & Wilkins

> Table of Contents > Chapter 1 - Thorax > 1.47 Coronary arteriograms with orientation drawings

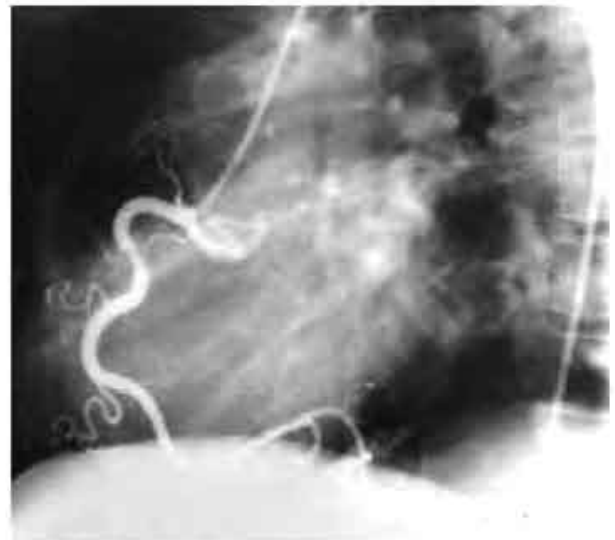
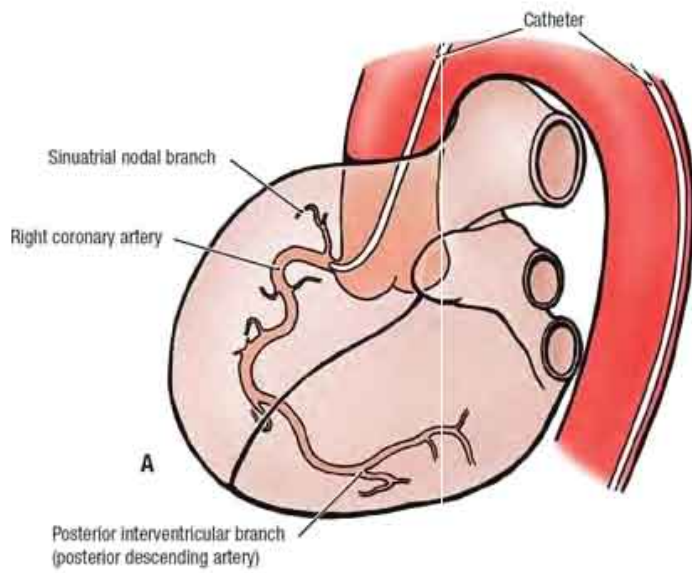
---

## 1.47 Coronary arteriograms with orientation drawings

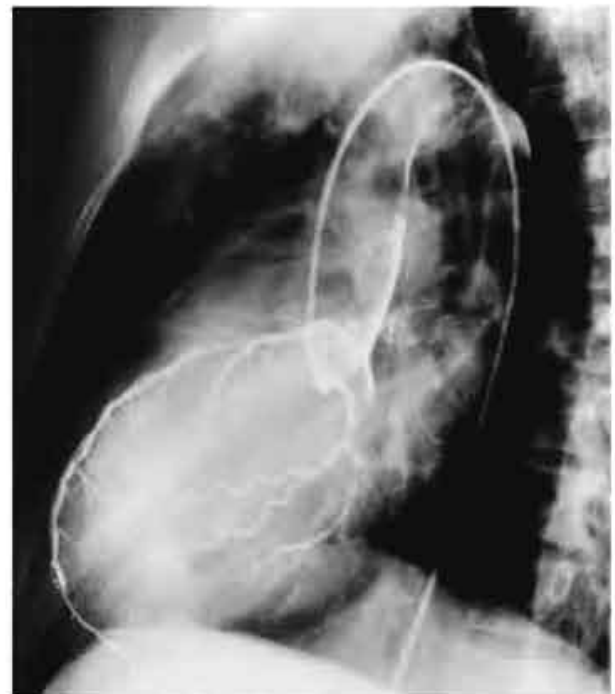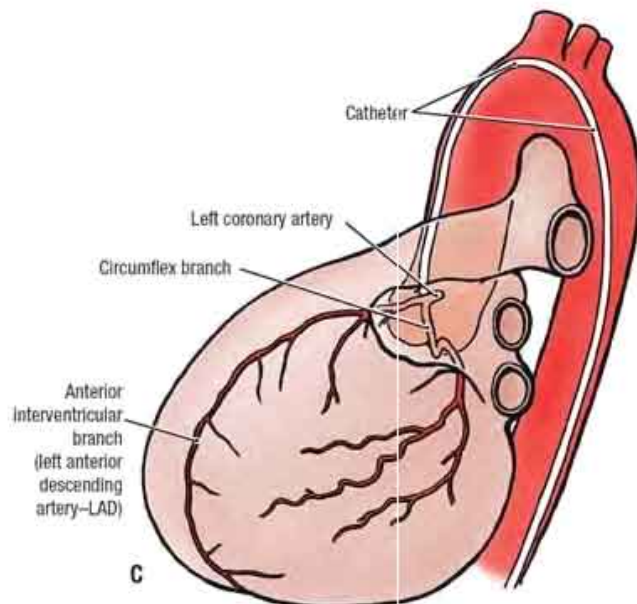
*Part of* "Chapter 1 - Thorax "

Right (A and B ) and left (C and D ) coronary arteriograms.

Coronary artery disease (CAD) is one of the leading causes of death. CAD has many causes, all of which result in a reduced blood supply to the vital myocardial tissue. The three most common sites of coronary artery occlusion and the percentage of occlusions involving each artery are the (1) Anterior interventricular (clinically referred to as LAD) branch of the left coronary artery (LCA) (40–50%); (2) Right coronary artery (RCA), (30–40%); (3) Circumflex branch of the LCA (15–20%).



**B. Left Anterior Oblique View**



**D. Left Anterior Oblique View**

Authors: Agur, Anne M.R.; Dalley, Arthur F.

Title: *Grant's Atlas of Anatomy, 12th Edition*

Copyright ©2009 Lippincott Williams & Wilkins

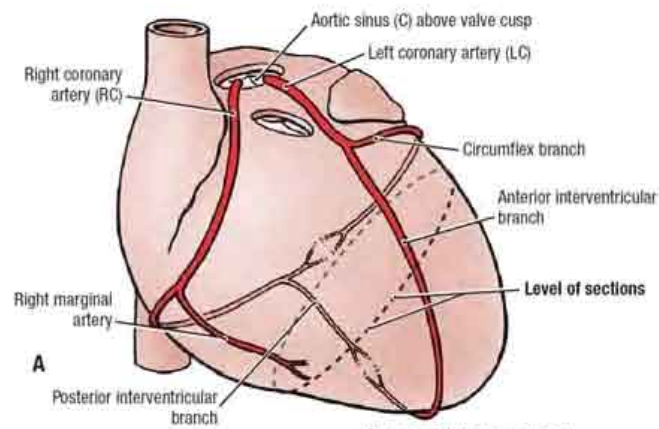
> Table of Contents > Chapter 1 - Thorax > 1.48 Coronary circulation

---

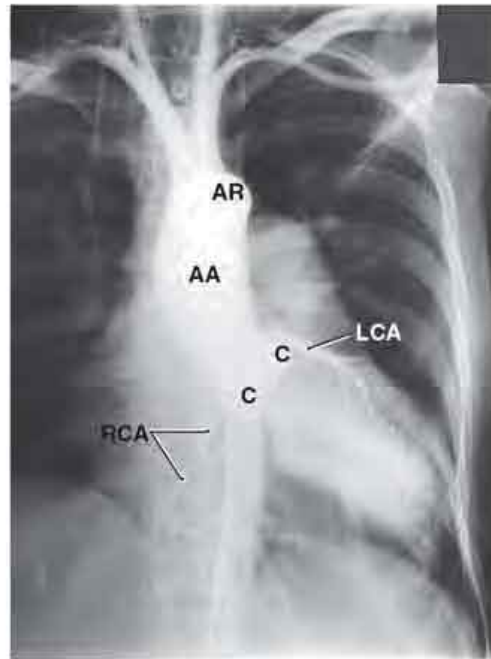
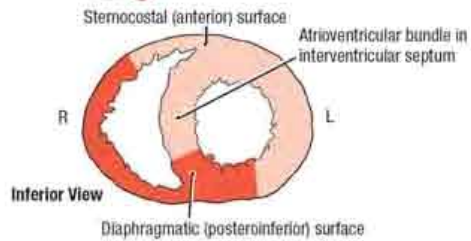
## 1.48 Coronary circulation

*Part of* "Chapter 1 - Thorax "


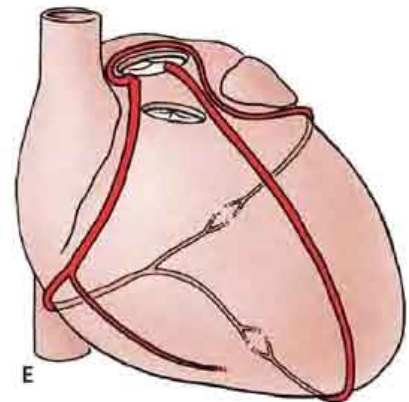
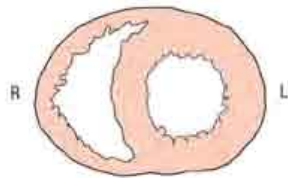
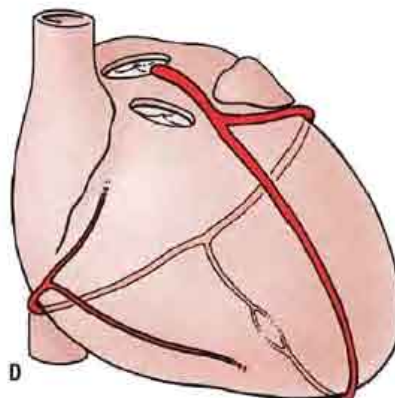
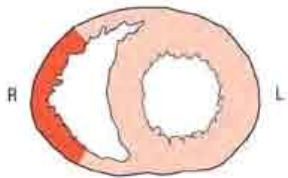
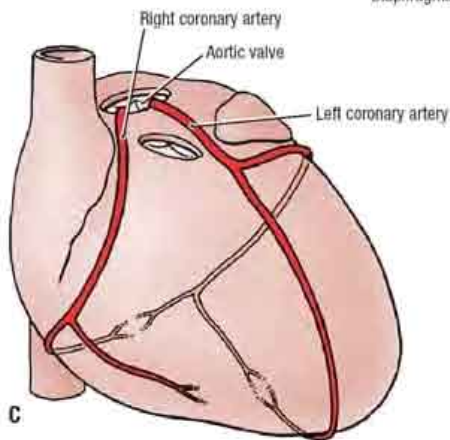
A. In most cases, the right and left coronary arteries share equally in the blood supply to the heart. The *dotted line* indicates the plane of the cross-section demonstrating the parts of the myocardium supplied by the right and left coronary arteries. B. Aortic angiogram. Observe arch of aorta (*AR*), ascending aorta (*AA*), cusp of aortic valve (*C*), left coronary artery (*LCA*), and right coronary artery (*RCA*). C. Dominant left coronary artery (about 15% of hearts). The posterior interventricular branch comes off the circumflex branch. D. Single coronary artery. E. Circumflex branch emerging from the right coronary sinus.



Myocardium supplied by:  
 ■ Right coronary artery  
 ■ Left coronary artery



B. Anteroposterior View



Anterior Views of Heart with Transverse Section of Ventricles Viewed Inferiorly

Authors: Agur, Anne M.R.; Dalley, Arthur F.

Title: *Grant's Atlas of Anatomy, 12th Edition*

Copyright ©2009 Lippincott Williams & Wilkins

> Table of Contents > Chapter 1 - Thorax > 1.49 Right atrium

---

## 1.49 Right atrium

*Part of* "Chapter 1 - Thorax "

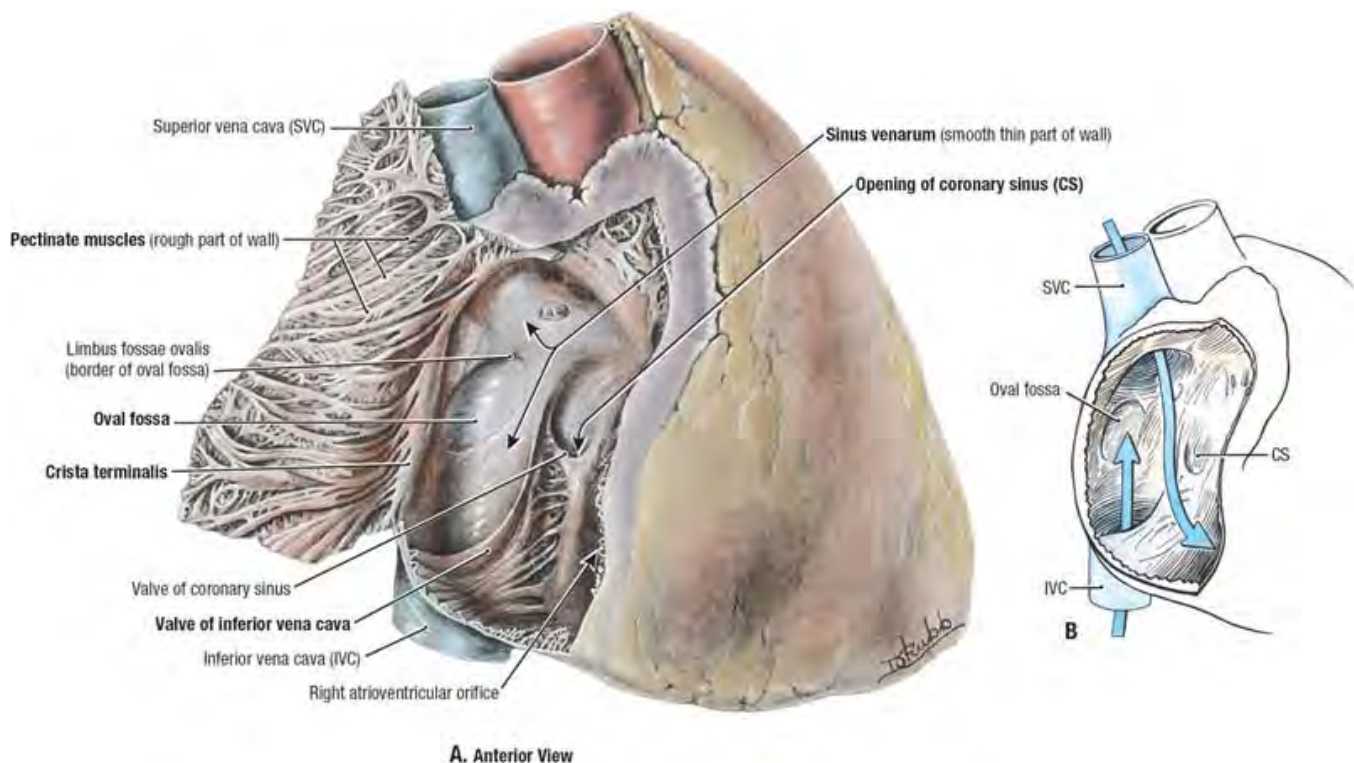
A. Interior of right atrium. The anterior wall of the right atrium is reflected. B. Blood flow into atrium from the superior and inferior vena cavae.

- The smooth part of the atrial wall is formed by the absorption of the right horn of the sinus venosus, and the rough part is formed from the primitive atrium.
- Crista terminalis, the valve of the inferior vena cava, and the valve of the coronary sinus separate the smooth part from the rough part.
- The pectinate muscle passes anteriorly from the crista terminalis; the crista underlies the sulcus terminalis (not shown), a groove visible externally on the posterolateral surface of the right atrium between the superior and inferior venae cavae.
- The superior and inferior venae cavae and the coronary sinus open onto the smooth part of the right atrium; the anterior cardiac veins and venae cordis minimae (not visible) also open into the atrium.
- The floor of the fossa is the remnant of the fetal septum primum; the crescent-shaped ridge (limbus fossae ovalis) partially surrounding the fossa is the remnant of the septum secundum.
- In B , the inflow from the superior vena cava is directed toward the tricuspid orifice, whereas blood from the inferior vena cava is directed toward the fossa ovalis.



- A congenital anomaly of the interatrial septum, usually incomplete closure of the oval foramen, is an atrial septal defect (ASD). A probe-size patency is present in the superior part of the oval fossa in 15–25% of adults (Moore and Persaud, 2003). These small openings, by themselves, cause no hemodynamic abnormalities. Large ASDs allow oxygenated blood from the lungs to be shunted from the left atrium through the ASD into the right atrium, causing enlargement of the right atrium and ventricle and dilation of the pulmonary trunk.

P.57





Authors: Agur, Anne M.R.; Dalley, Arthur F.

Title: *Grant's Atlas of Anatomy, 12th Edition*

Copyright ©2009 Lippincott Williams & Wilkins

> Table of Contents > Chapter 1 - Thorax > 1.50 Right ventricle

---

## 1.50 Right ventricle

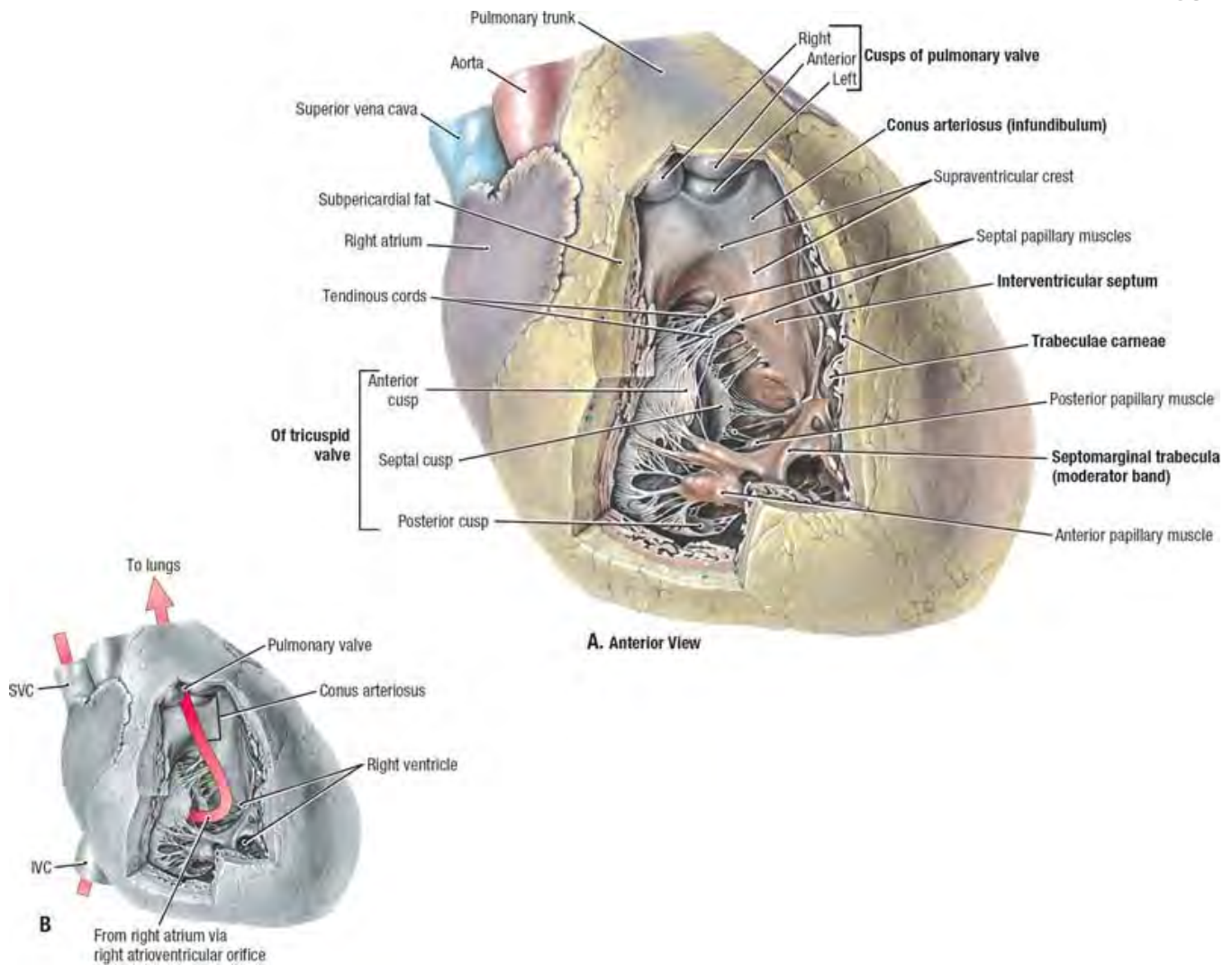
*Part of* "Chapter 1 - Thorax "

A. Interior of right ventricle. B. Blood flow through right heart.

- The entrance to this chamber, the right atrioventricular or tricuspid orifice, is situated posteriorly; the exit, the orifice of the pulmonary trunk, is superior.
  - The outflow portion of the chamber inferior to the pulmonary orifice (conus arteriosus or infundibulum) has a smooth, funnel-shaped wall; the remainder of the ventricle is rough with fleshy trabeculae.
  - There are three types of trabeculae: mere ridges, bridges attached only at each end, and fingerlike projections called papillary muscles. The anterior papillary muscle rises from the anterior wall, the posterior (papillary muscle) from the posterior wall, and a series of small septal papillae from the septal wall.
  - The septomarginal trabecula, here thick, extends from the septum to the base of the anterior papillary muscle.
- 
- The membranous part of the interventricular septum develops separately from the muscular part and has a complex embryological origin (Moore and Persaud, 2003). Consequently, this part is the common site of ventricular septal defects (VSDs), although defects also occur in the muscular part, VSDs rank first on all lists of cardiac defects. The size of the defect varies from 1 to 25 mm. A VSD causes

a left-to-right shunt of blood through the defect. A large shunt increases pulmonary blood flow, which causes severe pulmonary disease (*hypertension*, or increased blood pressure) and may cause *cardiac failure*.

P.58



Authors: Agur, Anne M.R.; Dalley, Arthur F.

Title: *Grant's Atlas of Anatomy, 12th Edition*

Copyright ©2009 Lippincott Williams & Wilkins

> Table of Contents > Chapter 1 - Thorax > 1.51 Left atrium and left ventricle

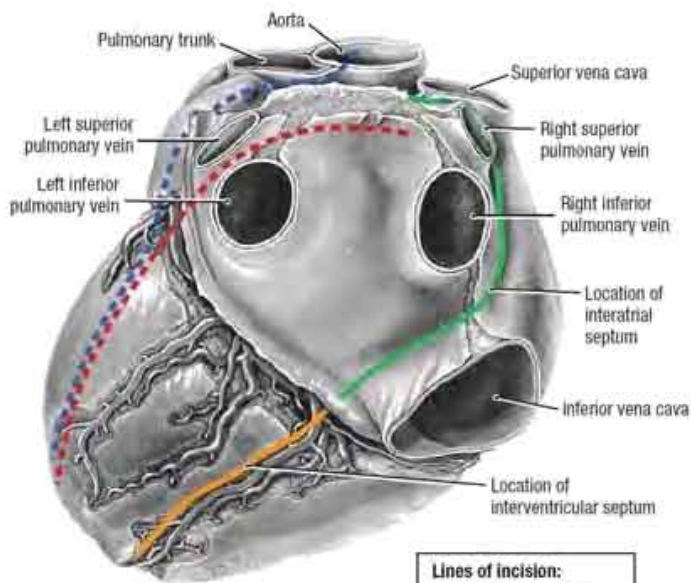
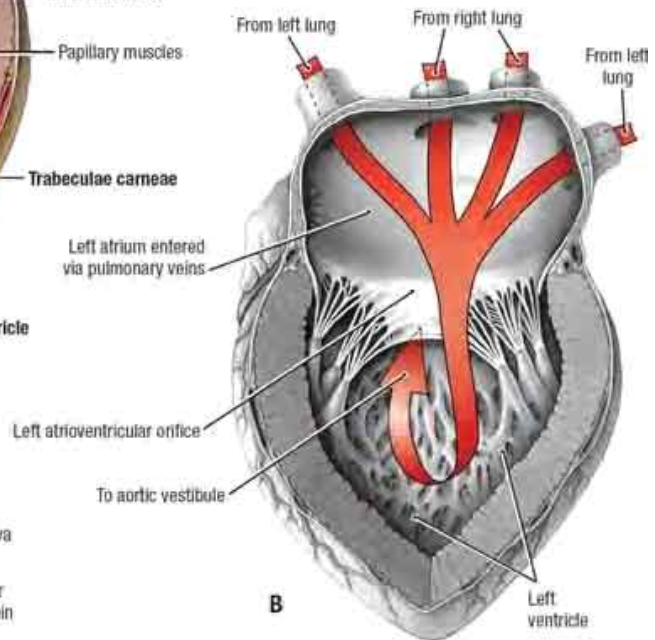
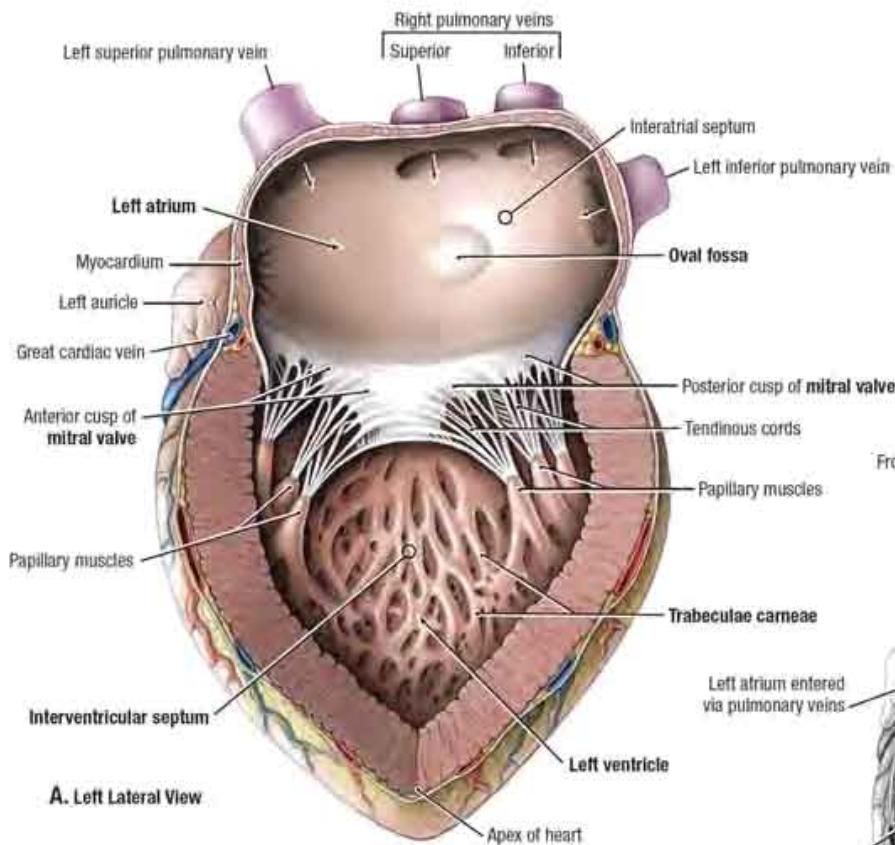
---

## 1.51 Left atrium and left ventricle

*Part of* "Chapter 1 - Thorax "

A. Interior of left heart. B. Blood flow through the left heart.

- A diagonal cut was made from the base of the heart to the apex, passing between the superior and inferior pulmonary veins and through the posterior cusp of the mitral valve, followed by retraction (spreading) of the left heart wall on each side of the incision.
- The entrances (pulmonary veins) to the left atrium are posterior, and the exit (left atrioventricular or mitral orifice) is anterior.
- The left side of the oval fossa is also seen on the left side of the interatrial septum, although the left side is not usually as distinct as the right side is within the right atrium.
- Except for that of the auricle, the atrial wall is smooth.



**Lines of incision:**

- Figure 1.51 A & B
- Figure 1.52 A & B

Authors: Agur, Anne M.R.; Dalley, Arthur F.

Title: *Grant's Atlas of Anatomy, 12th Edition*

Copyright ©2009 Lippincott Williams & Wilkins

> Table of Contents > Chapter 1 - Thorax > 1.52 Left ventricle

---

## 1.52 Left ventricle

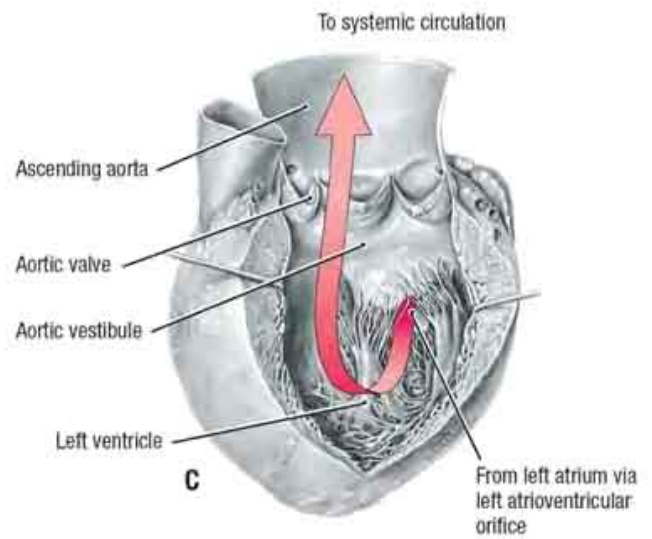
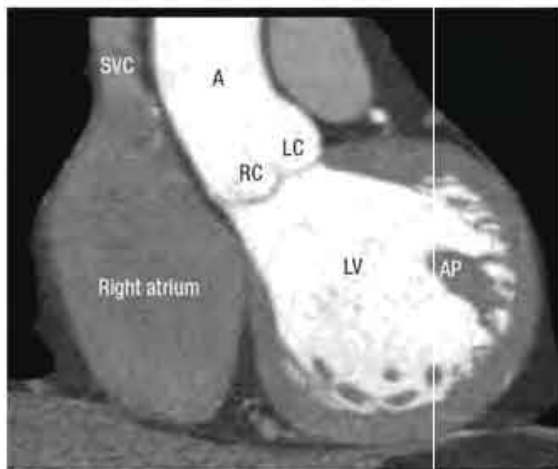
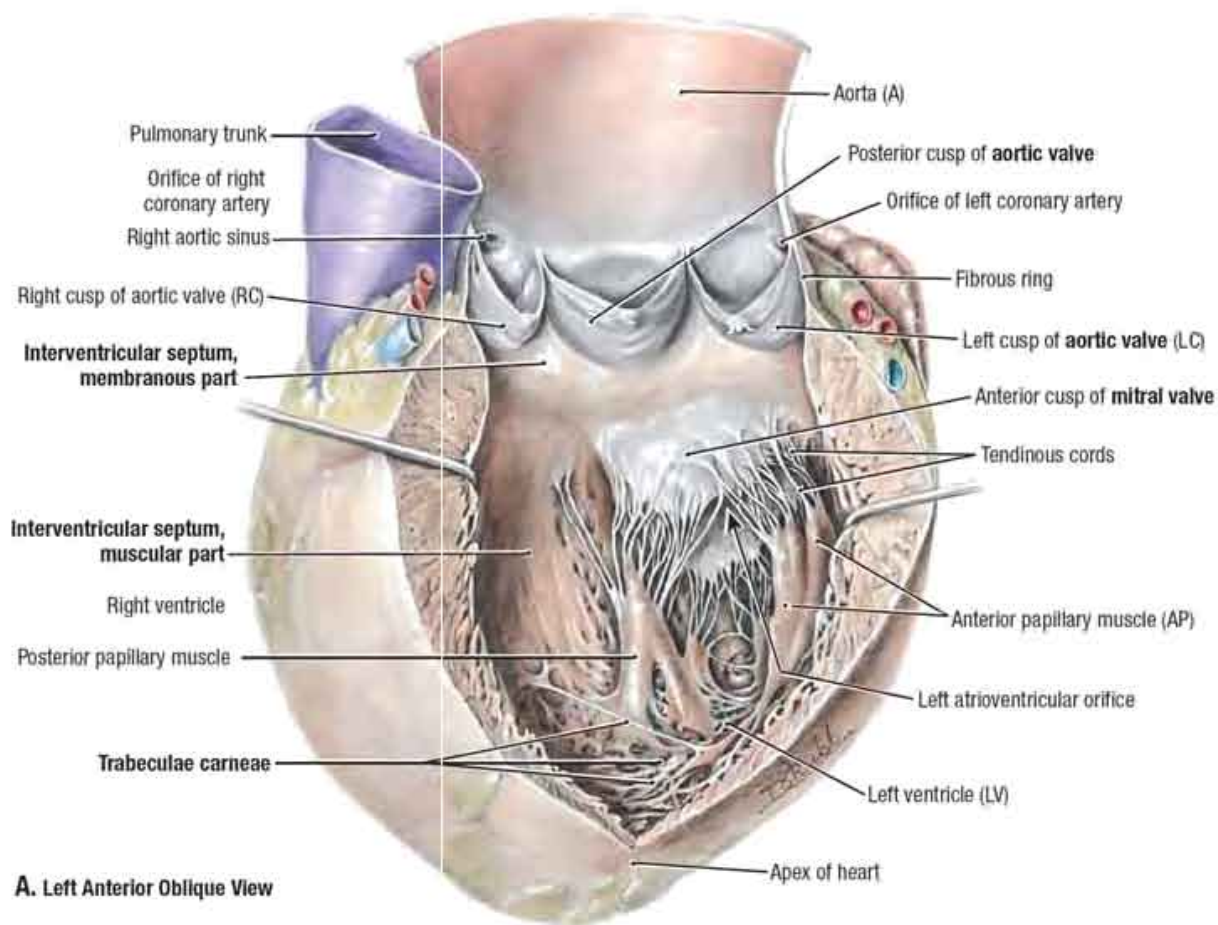
*Part of* "Chapter 1 - Thorax "

A cut was made from the apex along the left margin of the heart, passing posterior to the pulmonary trunk, to open the aortic vestibule and ascending aorta.

A. Interior of left ventricle. B. Coronal CT angiogram. Letters refer to structures in A. C. Blood flow through the left ventricle.

- The chamber has a conical shape.
- The entrance (left atrioventricular, bicuspid, or mitral orifice) is situated posteriorly, and the exit (aortic orifice) is superior.
- The left ventricular wall is thin and muscular near the apex, thick and muscular superiorly, and thin and fibrous (nonelastic) at the aortic orifice.
- Two large papillary muscles, the anterior from the anterior wall and the posterior from the posterior wall, control the adjacent halves of two cusps of the mitral valve with tendinous cords (chordae tendineae).
- The anterior cusp of the mitral valve lies between the inlet (mitral orifice) and the outlet (aortic orifice).







Authors: Agur, Anne M.R.; Dalley, Arthur F.

Title: *Grant's Atlas of Anatomy, 12th Edition*

Copyright ©2009 Lippincott Williams & Wilkins

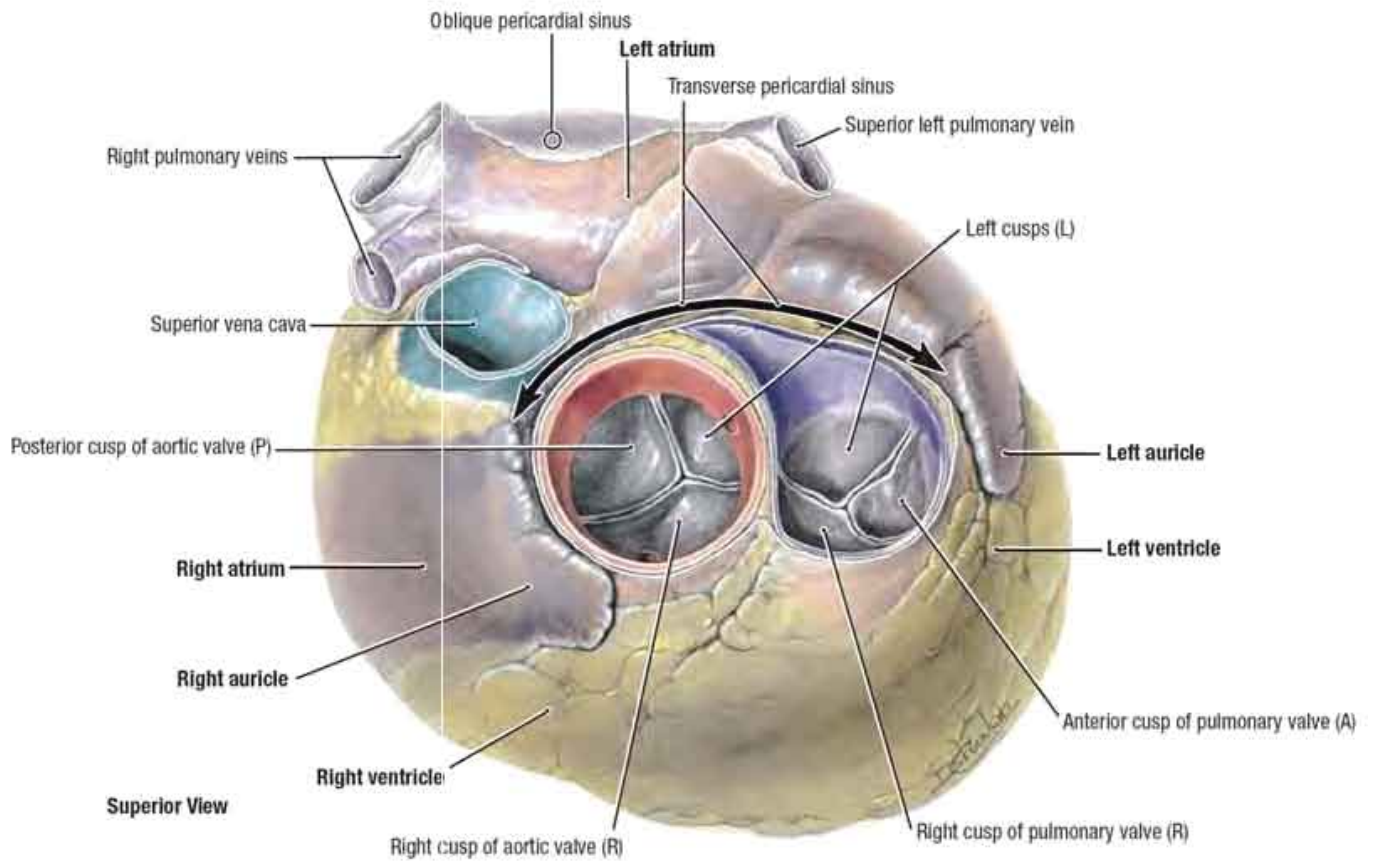
> Table of Contents > Chapter 1 - Thorax > 1.53 Excised heart

---

## 1.53 Excised heart

*Part of* "Chapter 1 - Thorax "

- The ventricles are positioned anteriorly and to the left, the atria posteriorly and to the right.
- The roots of the aorta and pulmonary artery, which conduct blood from the ventricles, are placed anterior to the atria and their incoming blood vessels (the superior vena cava and pulmonary veins).
- The aorta and pulmonary artery are enclosed within a common tube of serous pericardium and partly embraced by the auricles of the atria.
- The transverse pericardial sinus curves posterior to the enclosed stems of the aorta and pulmonary trunk and anterior to the superior vena cava and upper limits of the atria.
- The three cusps of the aortic and pulmonary valves and the names of the cusps have a developmental origin, as explained in Figure 1.54 .

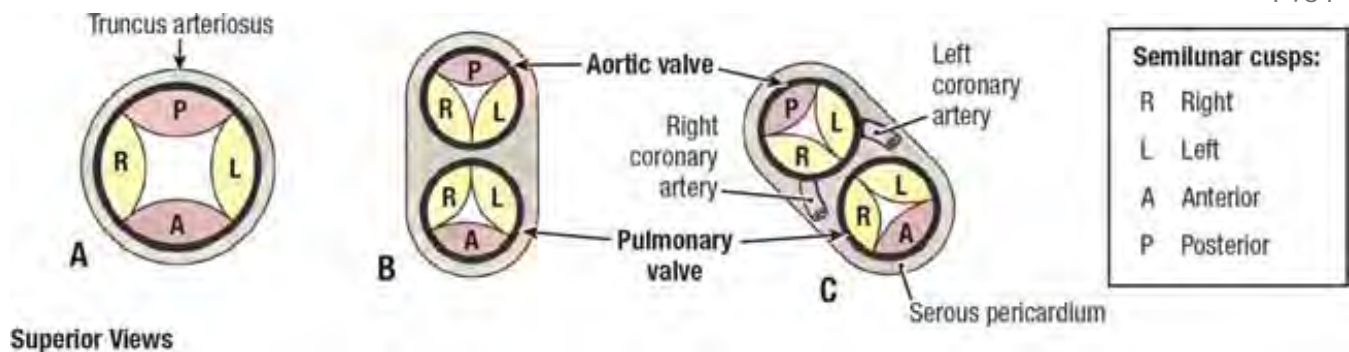


## 1.54 Pulmonary and aortic valve names

Part of "Chapter 1 - Thorax "

The names of these cusps have a developmental origin: the truncus arteriosus with four cusps (A) splits to form two valves, each with three cusps (B). The heart undergoes partial rotation to the left on its axis, resulting in the arrangement of cusps shown in C and in Figure 1.53 .

P.61



Authors: Agur, Anne M.R.; Dalley, Arthur F.

Title: *Grant's Atlas of Anatomy, 12th Edition*

Copyright ©2009 Lippincott Williams & Wilkins

> Table of Contents > Chapter 1 - Thorax > 1.55 Arrangement of the myocardium and the fibrous skeleton of the heart.

---

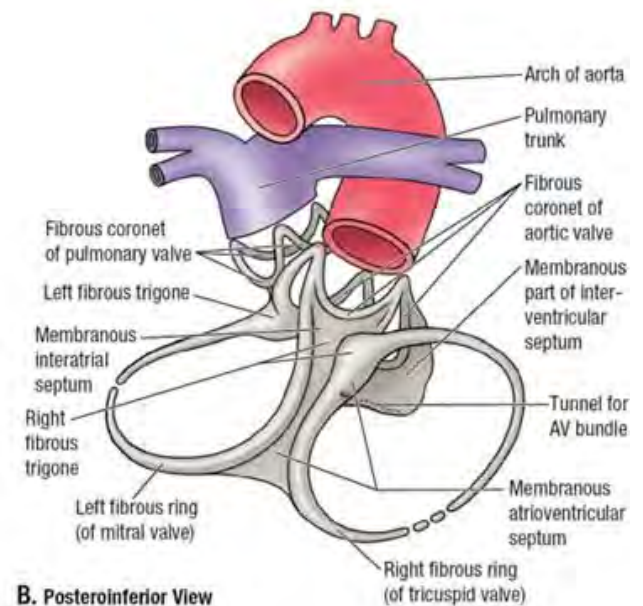
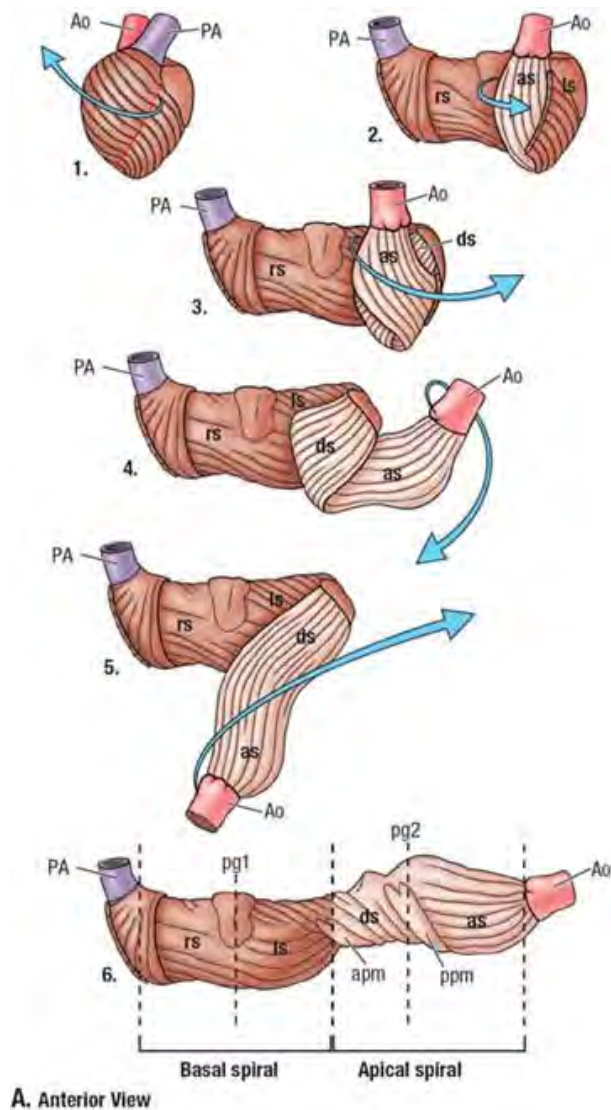
## 1.55 Arrangement of the myocardium and the fibrous skeleton of the heart.

*Part of "Chapter 1 - Thorax "*

A . The helical (double spiral) arrangement of the myocardium. (Modified from Torrent-Guasp et al., 2001). 1. When the superficial myocardium is incised along the anterior interventricular groove (*dashed red line*) and peeled back starting at its origin from the fibrous ring of the pulmonary artery (*PA*), the thick double spirals of the ventricular myocardial band are revealed 2. A band of nearly horizontal fibers forms an outer basal spiral (*dark brown*) that comprises the outer wall of the right ventricle (right segment; *rs*) and an external layer of the outer wall of the left ventricle (left segment; *ls*). 3. When the left ventricle is rotated to bring the interventricular septum anteriorly, it can be seen that the myocardium then abruptly turns more vertically, descending to the apex (descending segment; *ds*) and then ascends (ascending segment; *as*) to insert onto the fibrous ring of the aorta (*Ao*). The *ds* and *as* form the deeper apical spiral (*light brown*), which comprises the internal layer of the outer wall of the left ventricle, while the crisscrossing *as* and *ds* fibers make up the interventricular septum. Thus the septum, like the outer wall of the left ventricle, is also double layered. 4 and 5. The ventricular myocardial band is progressively unwrapped. 6. The myocardium is completely uncoiled, and its segments are identified. The sequential contraction of the myocardial band enables the ventricles to function as parallel sucking and propelling pumps; on contraction, the ventricles do not merely collapse inward but rather wring themselves out. *apm*, anterior papillary muscles; *pg1* and *pg2*, posterior interventricular groove; *ppm*, posterior papillary muscles. B. The isolated fibrous skeleton is composed of four

fibrous rings (or two rings and two “coronets”), each encircling a valve; two trigones; and the membranous portions of the interatrial, interventricular, and atrioventricular septa.

P.62



Authors: Agur, Anne M.R.; Dalley, Arthur F.

Title: *Grant's Atlas of Anatomy, 12th Edition*

Copyright ©2009 Lippincott Williams & Wilkins

> Table of Contents > Chapter 1 - Thorax > 1.56 Cardiac cycle

---

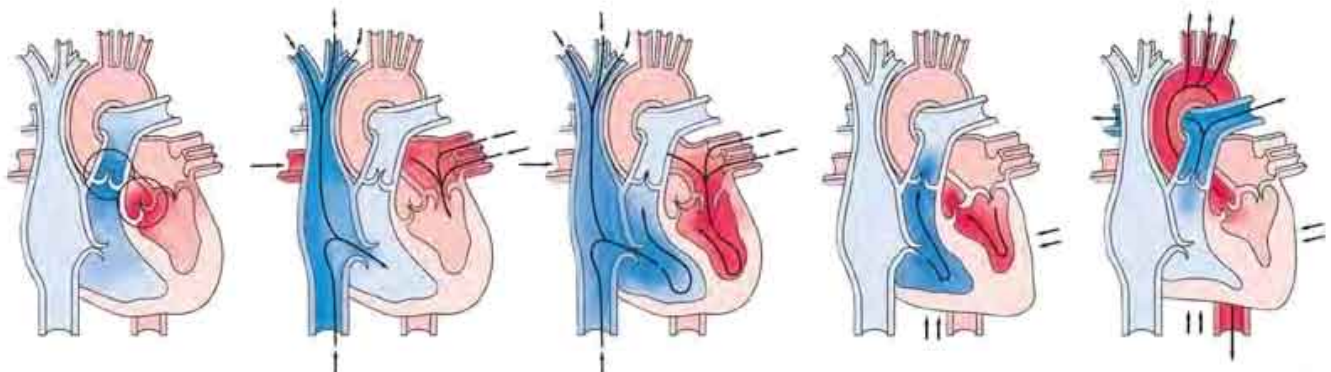
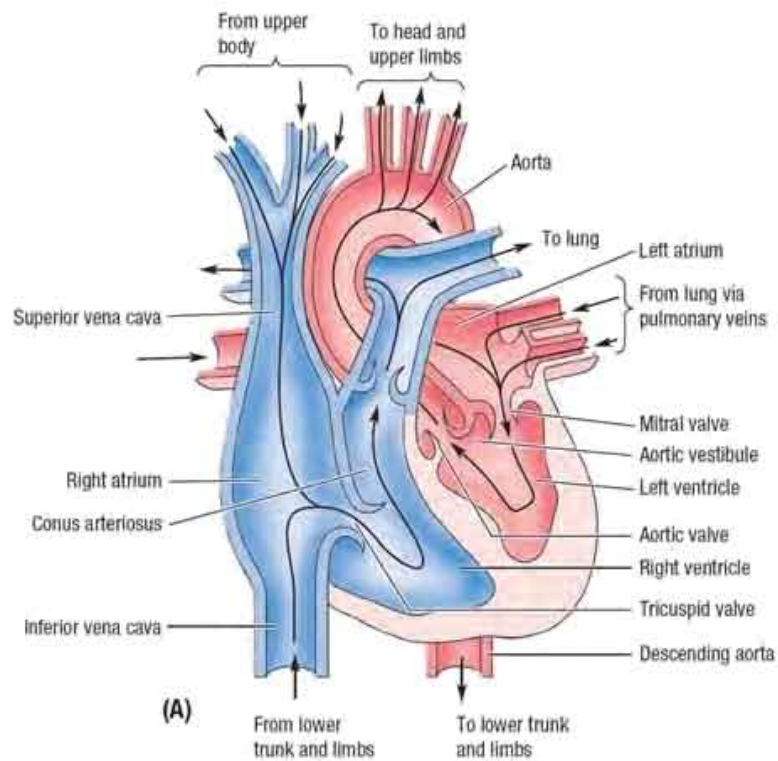
## 1.56 Cardiac cycle

*Part of* "Chapter 1 - Thorax "

The cardiac cycle describes the complete movement of the heart or heartbeat and includes the period from the beginning of one heartbeat to the beginning of the next one. The cycle consists of diastole (ventricular relaxation and filling) and systole (ventricular contraction and emptying). The right heart (*blue side*) is the pump for the pulmonary circuit; the left heart (*red side*) is the pump for the systemic circuit.

Disorders involving the valves of the heart disturb the pumping efficiency of the heart. Valvular heart disease produces either stenosis (narrowing) or insufficiency. Valvular stenosis is the failure of a valve to open fully, slowing blood flow from a chamber. Valvular insufficiency, or regurgitation, on the other hand, is failure of the valve to close completely, usually owing to nodule formation on (or scarring and contraction of) the cusps so that the edges do not meet or align. This allows a variable amount of blood (depending on the severity) to flow back into the chamber it was just ejected from. Both stenosis and insufficiency result in an increased workload for the heart. Because valvular diseases are mechanical problems, damaged or defective cardiac valves are often replaced surgically in a procedure called valvuloplasty. Most commonly, artificial valve prostheses made of synthetic materials are used in these valve replacement procedures, but xenografted valves (valves transplanted from other species, such as pigs) are also used.





(B) Beginning of diastole upon closure of aortic and pulmonary valves

(C) Opening of atrio-ventricular valves during early moments of diastole

(D) Atrial contraction during final moments of diastole

(E) Closure of atrioventricular valves (tricuspid and mitral) very soon after systole begins

(F) Opening of aortic and pulmonary valves during systole

Anterior views

Authors: Agur, Anne M.R.; Dalley, Arthur F.

Title: *Grant's Atlas of Anatomy, 12th Edition*

Copyright ©2009 Lippincott Williams & Wilkins

> Table of Contents > Chapter 1 - Thorax > 1.57 Valves of the heart

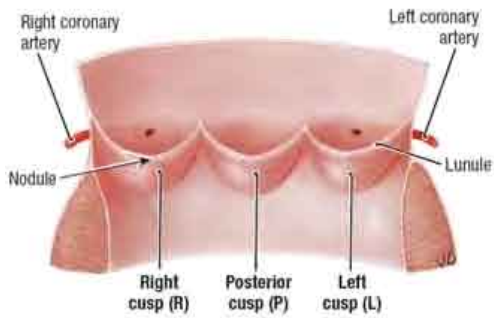
---

## 1.57 Valves of the heart

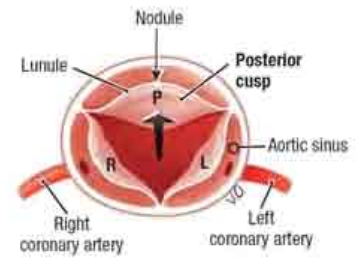
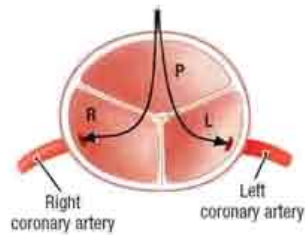
*Part of* "Chapter 1 - Thorax "

A and B. Semilunar valves. C and D. Atrioventricular valves.

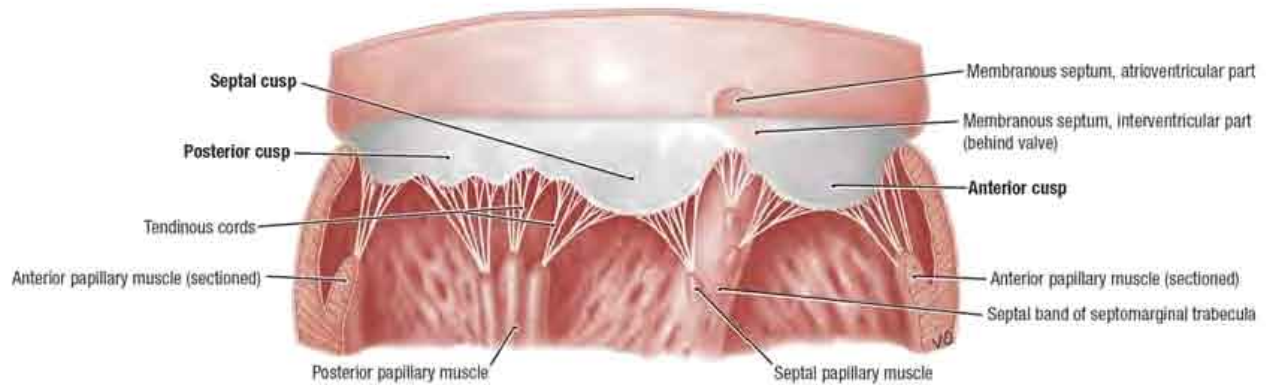
In (A) , as in Figure 1.52A , the anulus of the aortic valve has been incised between the right and left cusps and spread open. Each cusp of the semilunar valves bears a nodule in the midpoint of its free edge, flanked by thin connective tissue areas (lunules). When the ventricles relax to fill (diastole), backflow of blood from aortic recoil or pulmonary resistance fills the sinus (space between cusp and dilated part of the aortic or pulmonary wall), causing the nodules and lunules to meet centrally, closing the valve (B). Filling of the coronary arteries occurs during diastole (when ventricular walls are relaxed) as backflow "inflates" the cusps to close the valve. Tendinous cords pass from the tips of the papillary muscles to the free margins and ventricular surfaces of the cusps of the tricuspid (C) and mitral (D) valves. Each papillary muscle or muscle group controls the adjacent sides of two cusps, resisting valve prolapse during systole.



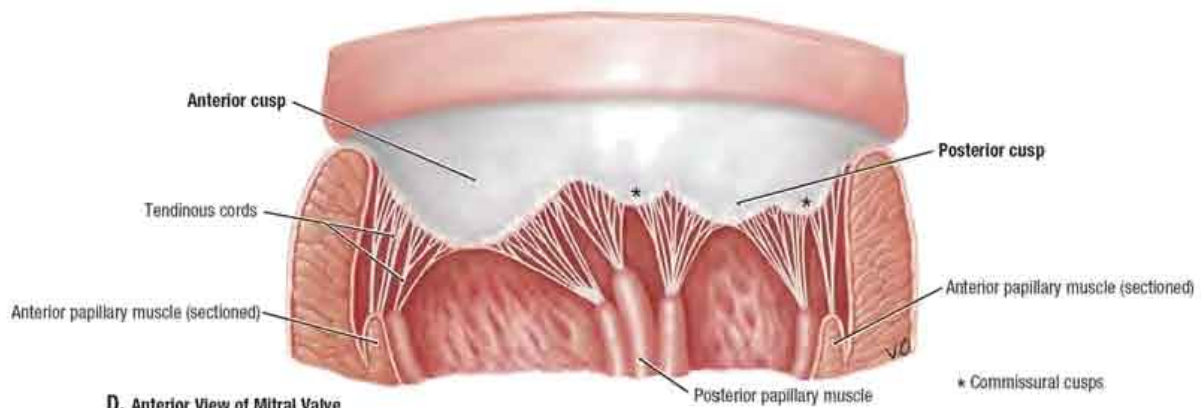
**A. Left Posterior Oblique View of Aortic Valve**



**B. Superior Views of Aortic Valve (Arrows indicate direction of blood flow)**



**C. Anterior View of Tricuspid Valve**



**D. Anterior View of Mitral Valve**

Authors: Agur, Anne M.R.; Dalley, Arthur F.

Title: *Grant's Atlas of Anatomy, 12th Edition*

Copyright ©2009 Lippincott Williams & Wilkins

> Table of Contents > Chapter 1 - Thorax > 1.58 Conduction system of heart, coronal section

---

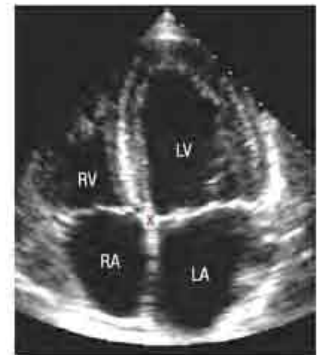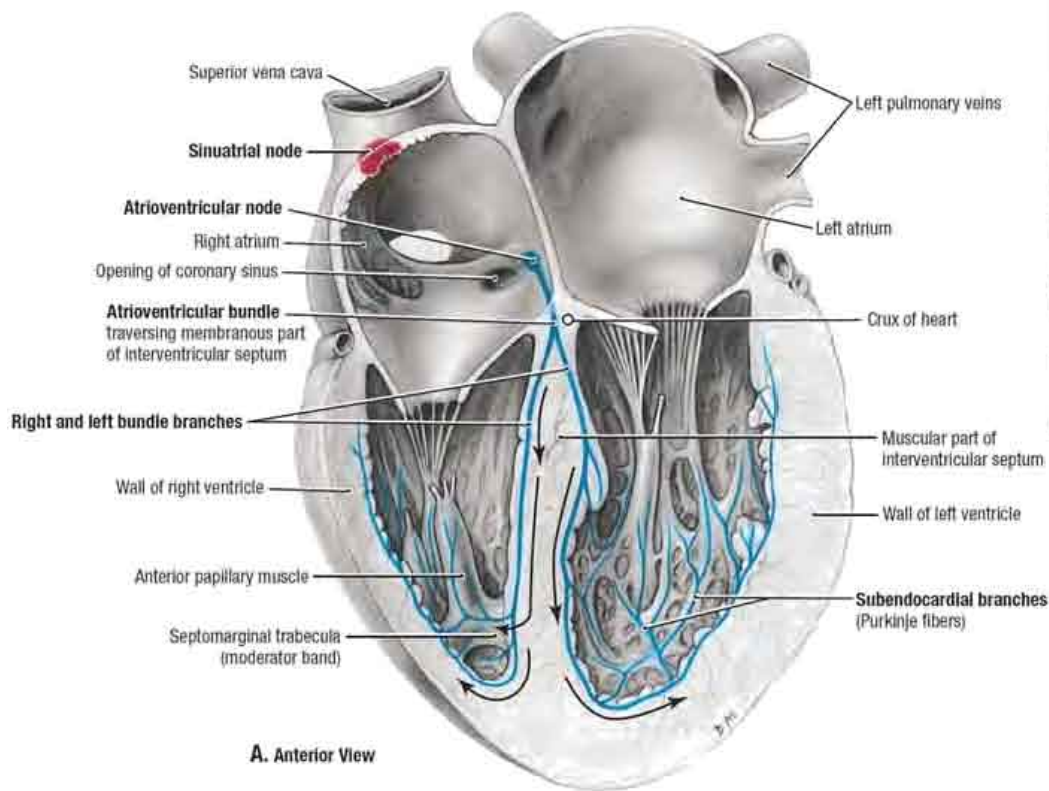
## 1.58 Conduction system of heart, coronal section

*Part of* "Chapter 1 - Thorax "

- The sinuatrial (SA) node in the wall of the right atrium near the superior end of the sulcus terminalis extends over the opening of the superior vena cava. The SA node is the "pacemaker" of the heart because it initiates muscle contraction and determines the heart rate. It is supplied by the sinuatrial nodal artery, usually a branch of the right atrial branch of the right coronary artery (see Fig. 1.45A-B), but it may arise from the left coronary artery.
- Contraction spreads through the atrial wall (myogenic induction) until it reaches the atrioventricular (AV) node in the interatrial septum superomedial to the opening of the coronary sinus. The AV node is supplied by the atrioventricular nodal artery, usually arising from the right coronary artery posteriorly at the inferior margin of the interatrial septum.
- The AV bundle, usually supplied by the right coronary artery, passes from the AV node in the membranous part of the interventricular septum, dividing into right and left bundle branches on either side of the muscular part of the interventricular septum.
- The right bundle branch travels inferiorly in the interventricular septum to the anterior wall of the ventricle, with part passing via the septomarginal trabecula to the anterior papillary muscle; excitation spreads throughout the right ventricular wall through a network of subendocardial branches from the right bundle (Purkinje fibers).

- The left bundle branch lies beneath the endocardium on the left side of the interventricular septum and branches to enter the anterior and posterior papillary muscles and the wall of the left ventricle; further branching into a plexus of subendocardial branches (Purkinje fibers) allows the impulses to be conveyed throughout the left ventricular wall. The bundle branches are mostly supplied by the left coronary, except the posterior limb of the left bundle branch, which is supplied by both coronary arteries.

- Damage to the cardiac conduction system (often by compromised blood supply as in coronary artery disease) leads to disturbances of muscle contraction. Damage to the AV node results in “heart block” because the atrial excitation wave does not reach the ventricles, which begin to contract independently at their own slower rate. Damage to one of the branches results in “bundle branch block,” in which excitation goes down the unaffected branch to cause systole of that ventricle; the impulse then spreads to the other ventricle, producing later, asynchronous contraction.



RV	Right ventricle	LV	Left ventricle
		x	Crux of heart
RA	Right atrium	LA	Left atrium



Authors: Agur, Anne M.R.; Dalley, Arthur F.

Title: *Grant's Atlas of Anatomy, 12th Edition*

Copyright ©2009 Lippincott Williams & Wilkins

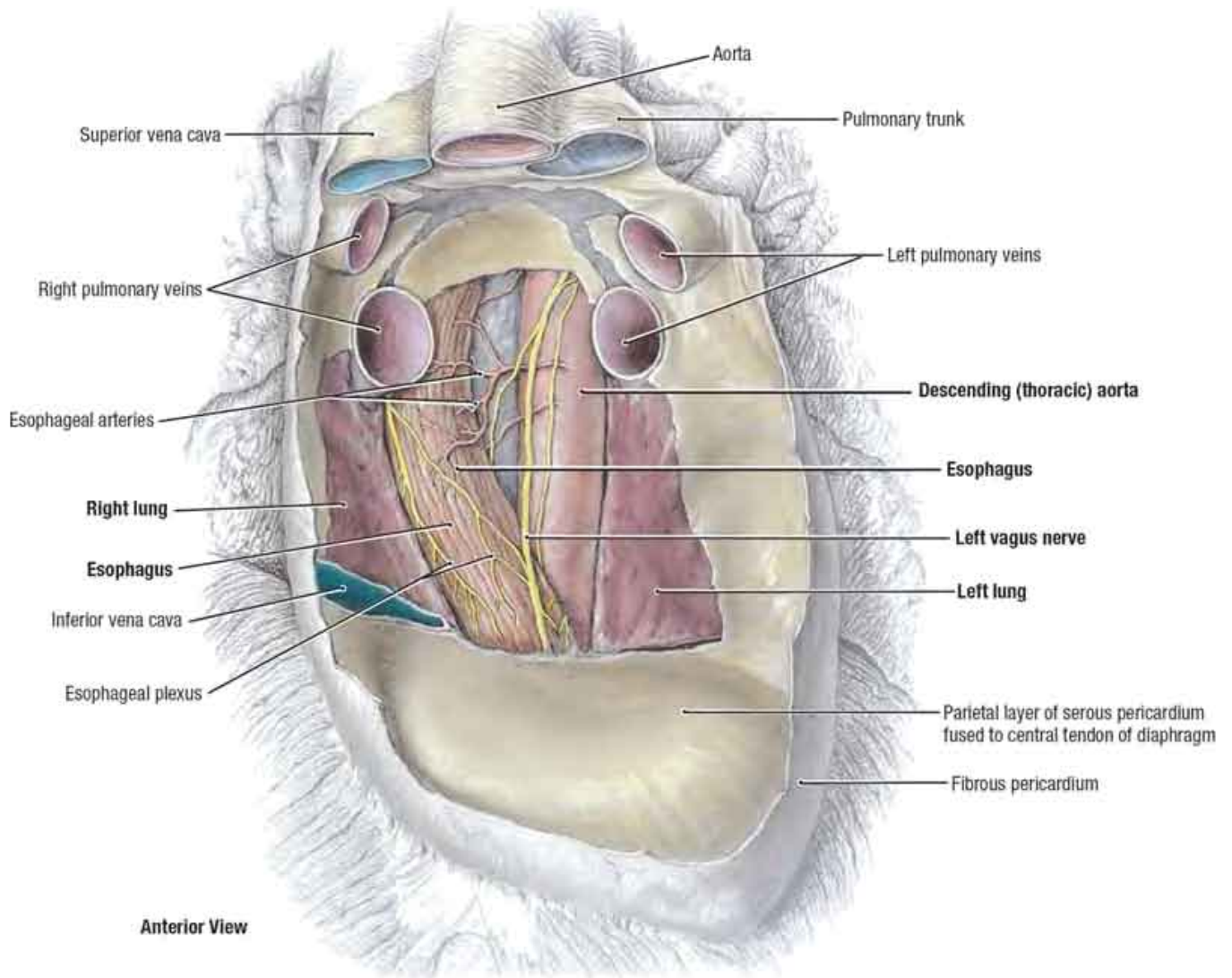
> Table of Contents > Chapter 1 - Thorax > 1.59 Posterior relationships of heart and pericardium

---

## 1.59 Posterior relationships of heart and pericardium

*Part of* "Chapter 1 - Thorax "

Posterior relationships. The fibrous and parietal layers of serous pericardium have been removed from posterior and lateral to the oblique sinus. The esophagus in this specimen is deflected to the right; it usually lies in contact with the aorta. Compare with Figure 1.44 .



Authors: Agur, Anne M.R.; Dalley, Arthur F.

Title: *Grant's Atlas of Anatomy, 12th Edition*

Copyright ©2009 Lippincott Williams & Wilkins

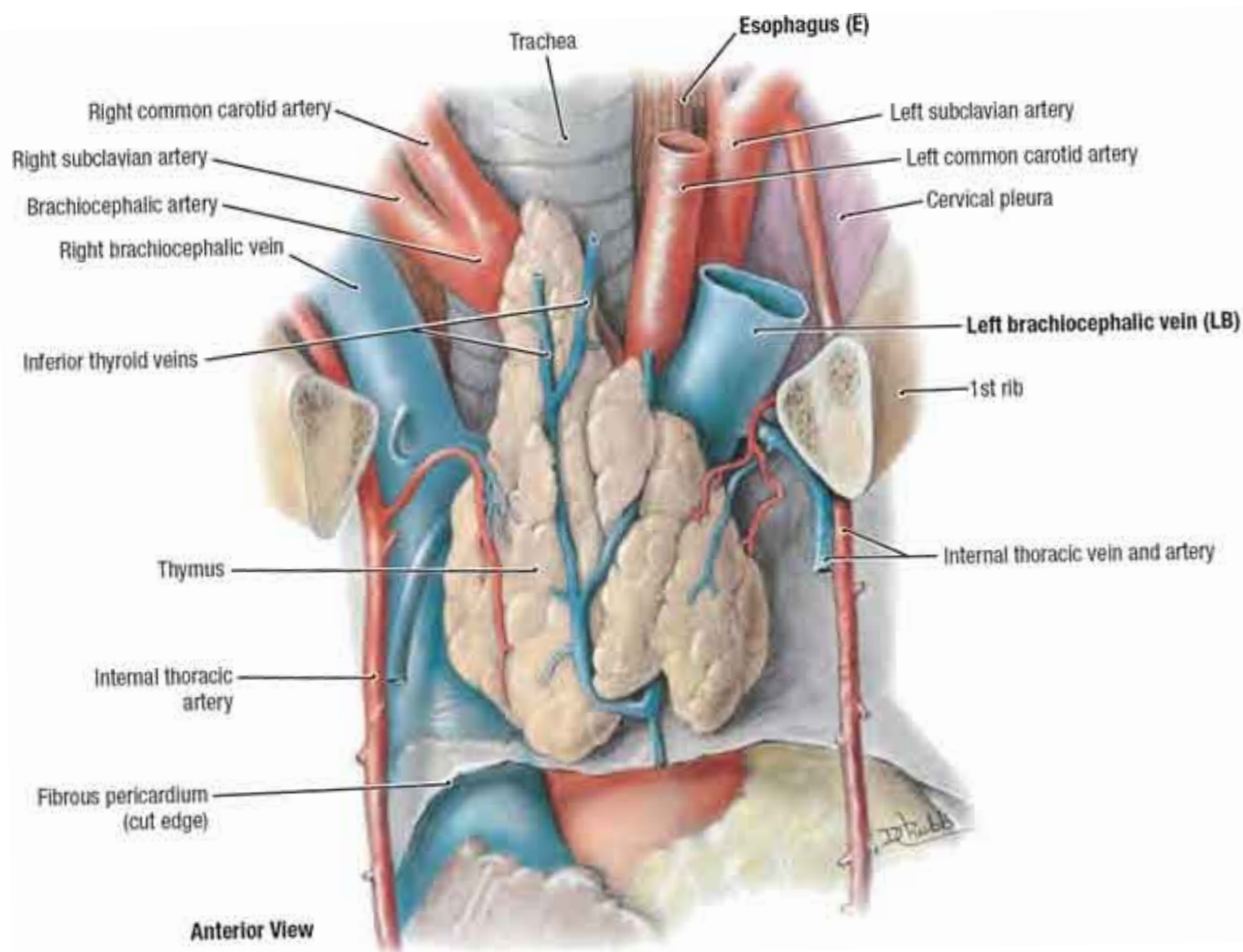
> Table of Contents > Chapter 1 - Thorax > 1.60 Superior mediastinum I: superficial dissection

---

## 1.60 Superior mediastinum I: superficial dissection

*Part of* "Chapter 1 - Thorax "

The sternum and ribs have been excised and the pleurae removed. It is unusual in an adult to see such a discrete thymus, which is impressive during puberty but subsequently regresses and is largely replaced by fat and fibrous tissue.



Authors: Agur, Anne M.R.; Dalley, Arthur F.

Title: *Grant's Atlas of Anatomy, 12th Edition*

Copyright ©2009 Lippincott Williams & Wilkins

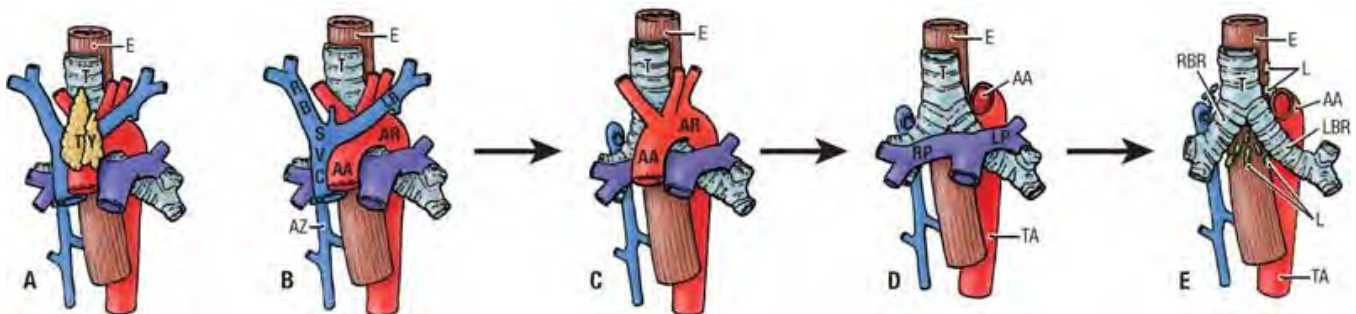
> Table of Contents > Chapter 1 - Thorax > 1.61 Relations of great vessels and trachea

## 1.61 Relations of great vessels and trachea

Part of "Chapter 1 - Thorax "

Observe, from superficial to deep: (A) Thymus (*TY*); (B) the right (*RB*) and left (*LB*) brachiocephalic veins form the superior vena cava (*SVC*) and receive the arch of the azygos vein (*AZ*) posteriorly; (C) the ascending aorta (*AA*) and arch of the aorta (*AR*) arch over the right pulmonary artery and left main bronchus; (D) the pulmonary arteries (*RP* and *LP*); and (E) the tracheobronchial lymph nodes (*L*) at the tracheal bifurcation (*T*).

P.67



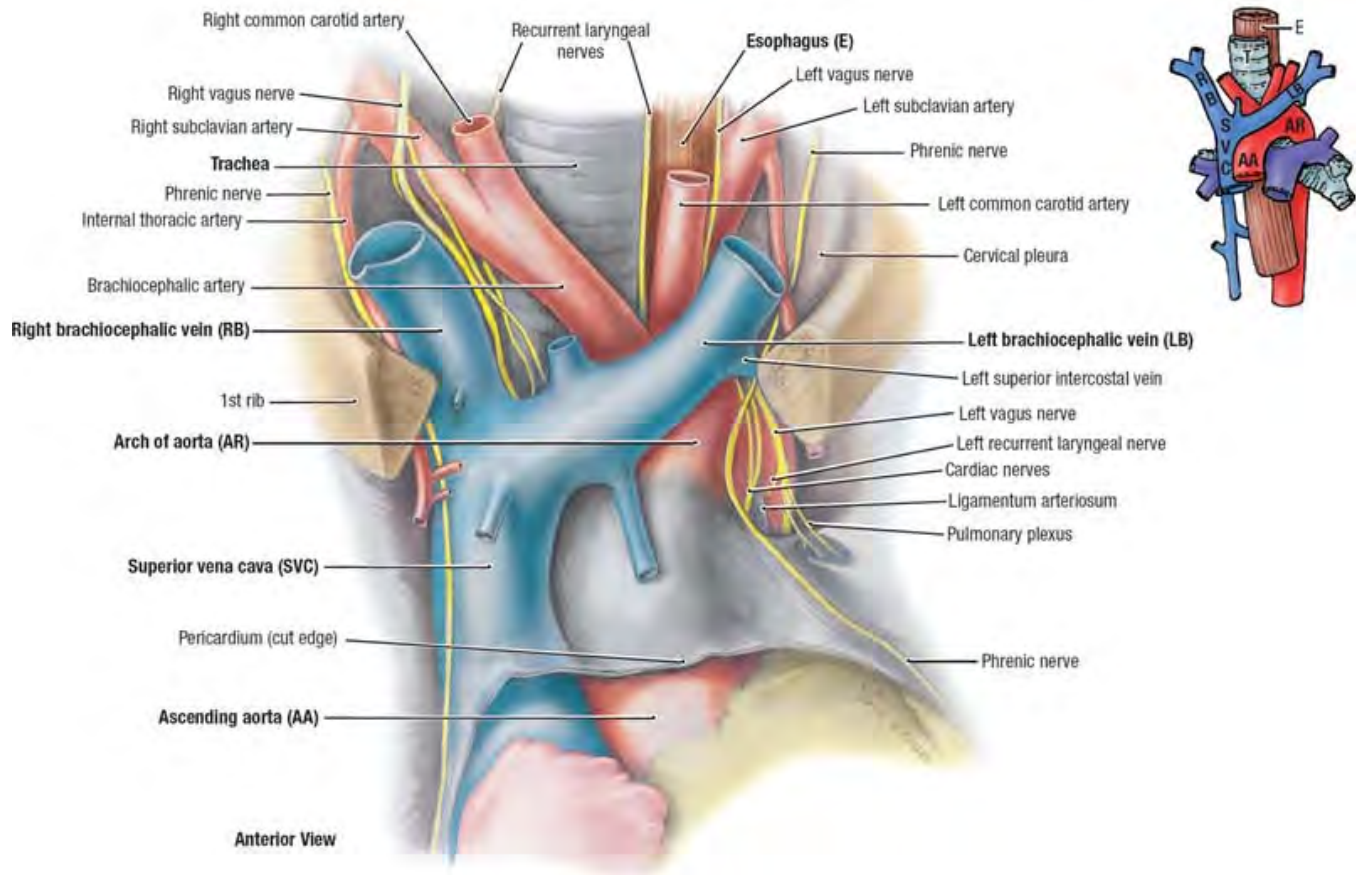
Authors: Agur, Anne M.R.; Dalley, Arthur F.  
Title: *Grant's Atlas of Anatomy, 12th Edition*  
Copyright ©2009 Lippincott Williams & Wilkins

> Table of Contents > Chapter 1 - Thorax > 1.62 Superior mediastinum II: root of neck

## 1.62 Superior mediastinum II: root of neck

Part of "Chapter 1 - Thorax "

The thymus gland has been removed.





Authors: Agur, Anne M.R.; Dalley, Arthur F.  
Title: *Grant's Atlas of Anatomy, 12th Edition*  
Copyright ©2009 Lippincott Williams & Wilkins

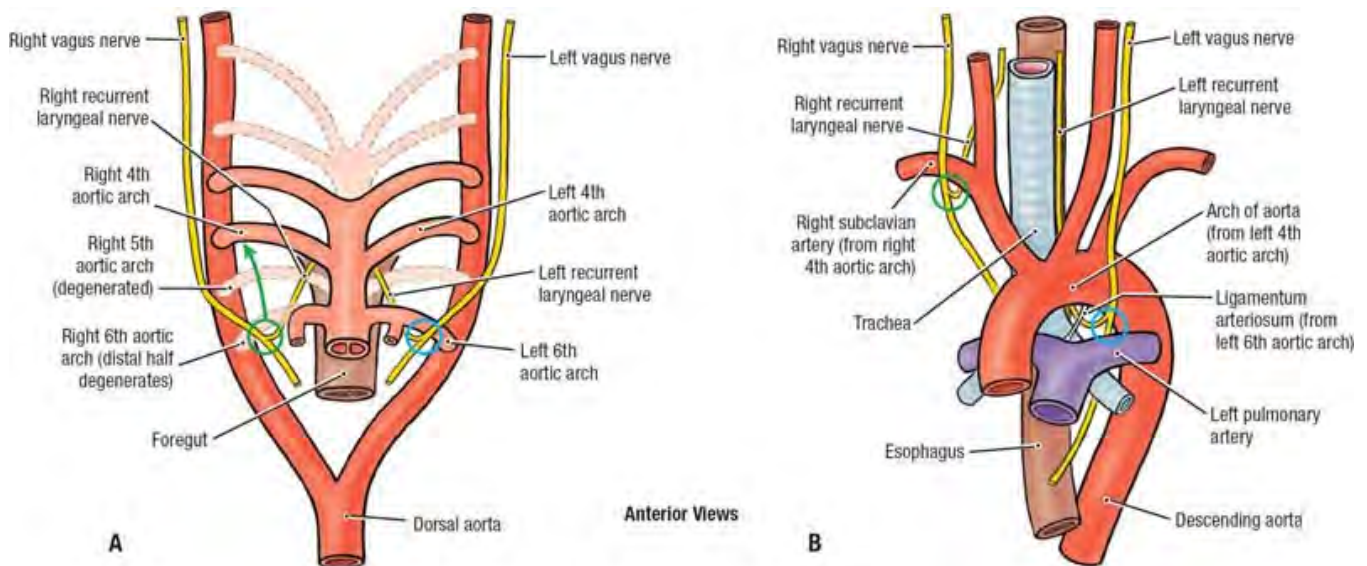
> Table of Contents > Chapter 1 - Thorax > 1.63 Relationship of recurrent laryngeal nerve to the aortic arches

## 1.63 Relationship of recurrent laryngeal nerve to the aortic arches

Part of "Chapter 1 - Thorax "

A. Six weeks. B. Child.

P.68



Authors: Agur, Anne M.R.; Dalley, Arthur F.

Title: *Grant's Atlas of Anatomy, 12th Edition*

Copyright ©2009 Lippincott Williams & Wilkins

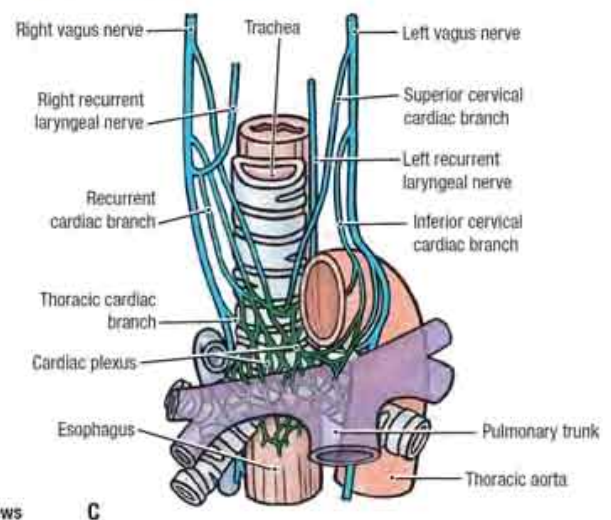
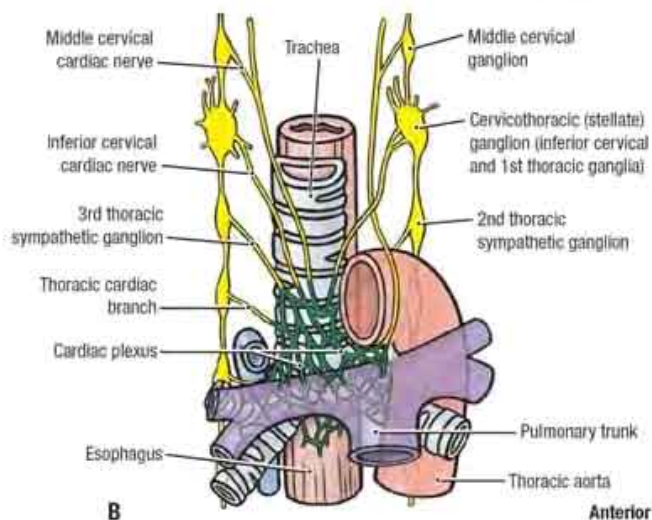
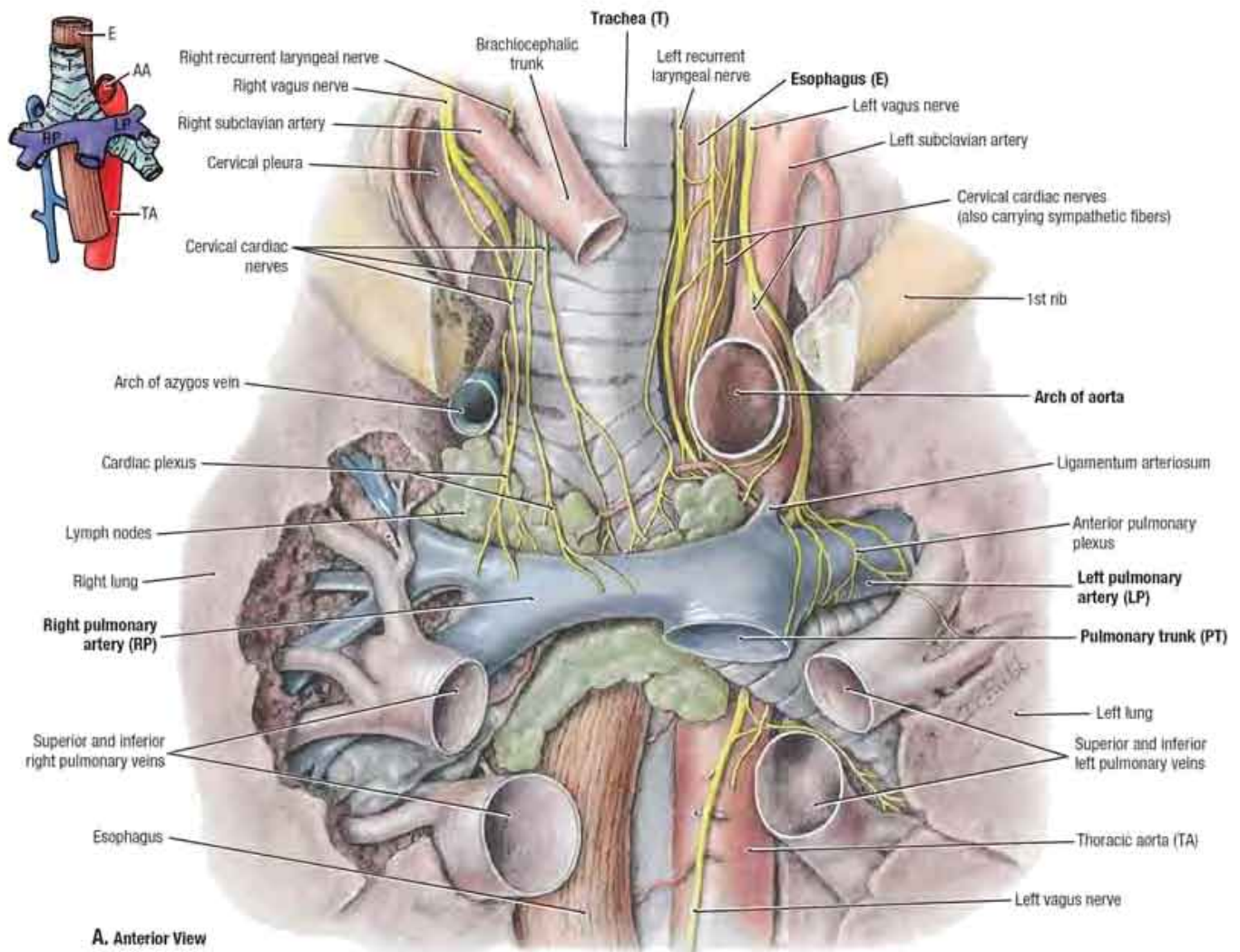
> Table of Contents > Chapter 1 - Thorax > 1.64 Superior mediastinum III: cardiac plexus and pulmonary arteries

---

## 1.64 Superior mediastinum III: cardiac plexus and pulmonary arteries

*Part of* "Chapter 1 - Thorax "

A. Dissection. B. Sympathetic and (C) parasympathetic contribution to the cardiac plexus.  
*Yellow*, sympathetic; *blue*, parasympathetic; *green*, mixed sympathetic and parasympathetic nerves.



Anterior Views

Authors: Agur, Anne M.R.; Dalley, Arthur F.

Title: *Grant's Atlas of Anatomy, 12th Edition*

Copyright ©2009 Lippincott Williams & Wilkins

> Table of Contents > Chapter 1 - Thorax > 1.65 Superior mediastinum IV: tracheal bifurcation and bronchi

---

## 1.65 Superior mediastinum IV: tracheal bifurcation and bronchi

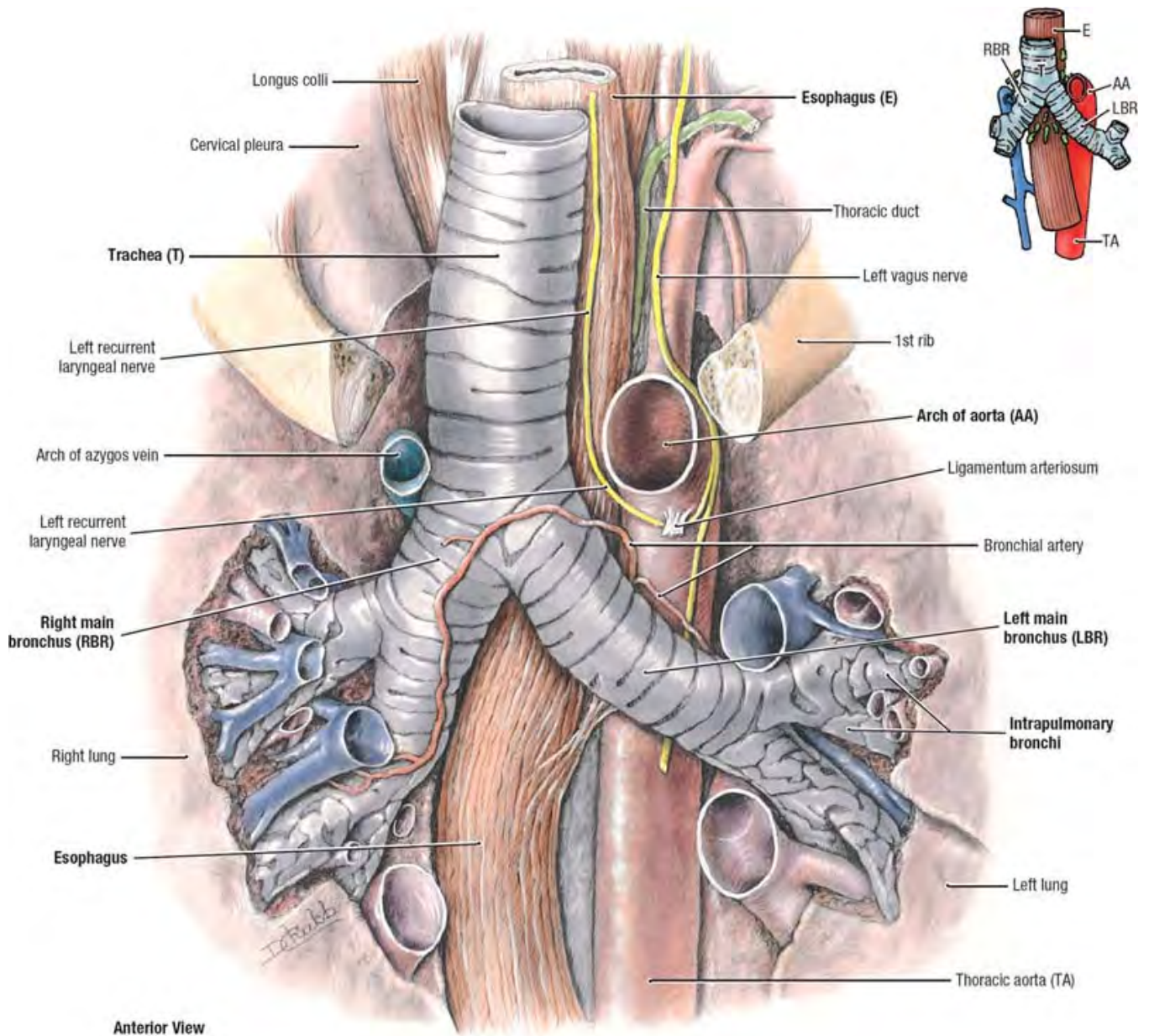
*Part of* "Chapter 1 - Thorax "

- Note the four parallel structures: the trachea, esophagus, left recurrent laryngeal nerve, and thoracic duct. The esophagus bulges to the left of the trachea, the recurrent nerve lies in the angle between the trachea and esophagus, and the duct is at the left side of the esophagus. The trachea bifurcates at the level of the sternal angle.
  - The arch of the aorta passes posterior to the left of these four structures as it arches over the left main bronchus; the arch of the azygos vein passes anterior to their right as it arches over the right main bronchus.
  - The right main bronchus is (1) more vertical, (2) of greater caliber, and (3) shorter than the left main bronchus.
- The recurrent laryngeal nerves supply all the intrinsic muscles of the larynx, except one. Consequently, any investigative procedure or disease process in the superior mediastinum may involve these nerves and affect the voice. Because the left recurrent laryngeal nerve hooks around the arch of the aorta and ascends between the trachea and the esophagus, it may be involved when there is a bronchial or esophageal carcinoma, enlargement of mediastinal



lymph nodes, or an aneurysm of the arch of the aorta.

P. 70



Authors: Agur, Anne M.R.; Dalley, Arthur F.

Title: *Grant's Atlas of Anatomy, 12th Edition*

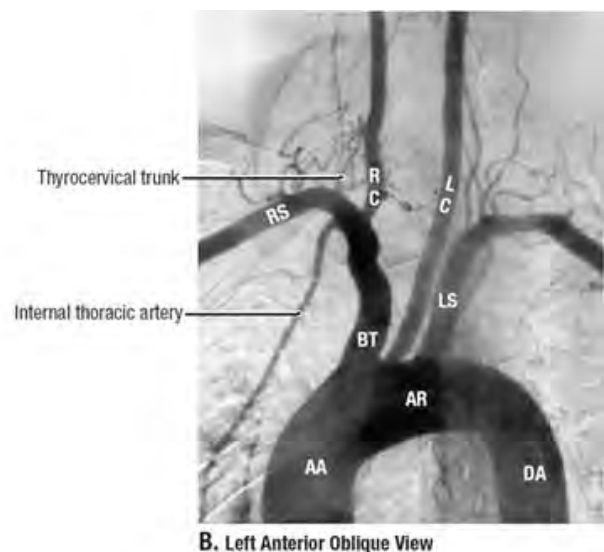
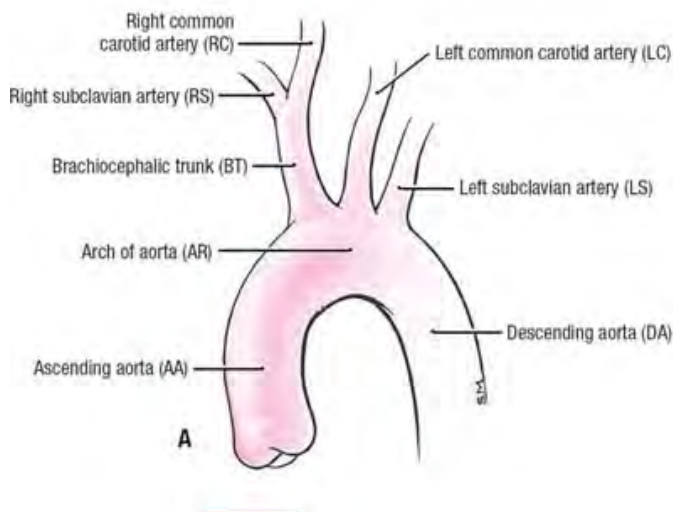
Copyright ©2009 Lippincott Williams & Wilkins

> Table of Contents > Chapter 1 - Thorax > 1.66 Branches of aortic arch

## 1.66 Branches of aortic arch

Part of "Chapter 1 - Thorax "

A. Aortic arch. B. Aortic angiogram. Observe the ascending aorta (*AA*), the arch of the aorta (*AR*), the descending aorta (*DA*), the brachiocephalic (*BT*) trunk (artery) branching into the right subclavian (*RS*) and right common carotid (*RC*) arteries, and the left subclavian (*LS*) and left common carotid (*LC*) arteries arising directly from the aorta.





Authors: Agur, Anne M.R.; Dalley, Arthur F.

Title: *Grant's Atlas of Anatomy, 12th Edition*

Copyright ©2009 Lippincott Williams & Wilkins

> Table of Contents > Chapter 1 - Thorax > 1.67 Variations in origins of branches of aortic arch

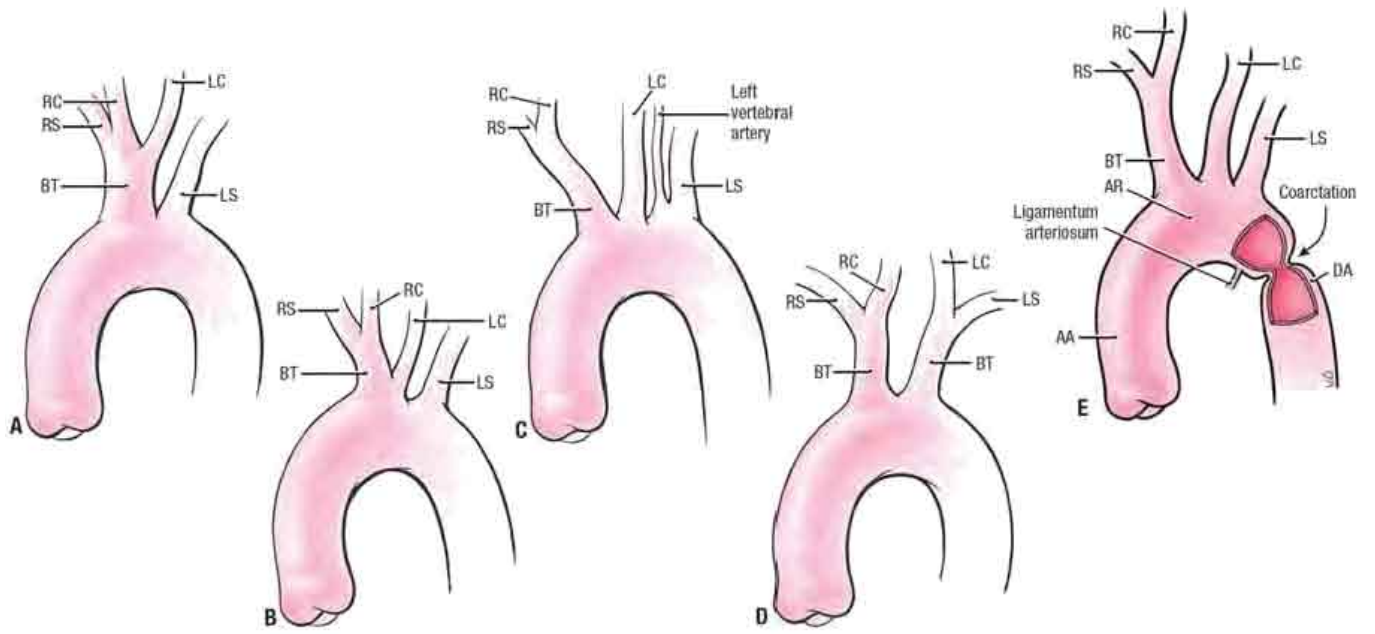
---

## 1.67 Variations in origins of branches of aortic arch

*Part of* "Chapter 1 - Thorax "

The most common pattern (65%) is shown in Figure 1.66 . Less common variations include (A and B ) left common carotid artery originating from the brachiocephalic trunk (27%); (C) each of the four arteries originating independently from the arch of the aorta (2.5%); (D) right and left brachiocephalic trunks originating from the arch of the aorta (1.2%); (E) Coarctation of aorta.

In coarctation of the aorta, the arch or descending aorta has an abnormal narrowing (stenosis) that diminishes the caliber of the aortic lumen, producing an obstruction to blood flow. The most common site is near the ligamentum arteriosum. When the coarctation is inferior to this site (postuctal coarctation), a good collateral circulation usually develops between the proximal and distal parts of the aorta through the intercostal and internal thoracic arteries.



Authors: Agur, Anne M.R.; Dalley, Arthur F.

Title: *Grant's Atlas of Anatomy, 12th Edition*

Copyright ©2009 Lippincott Williams & Wilkins

> Table of Contents > Chapter 1 - Thorax > 1.68 Scheme of varieties of aortic arches

---

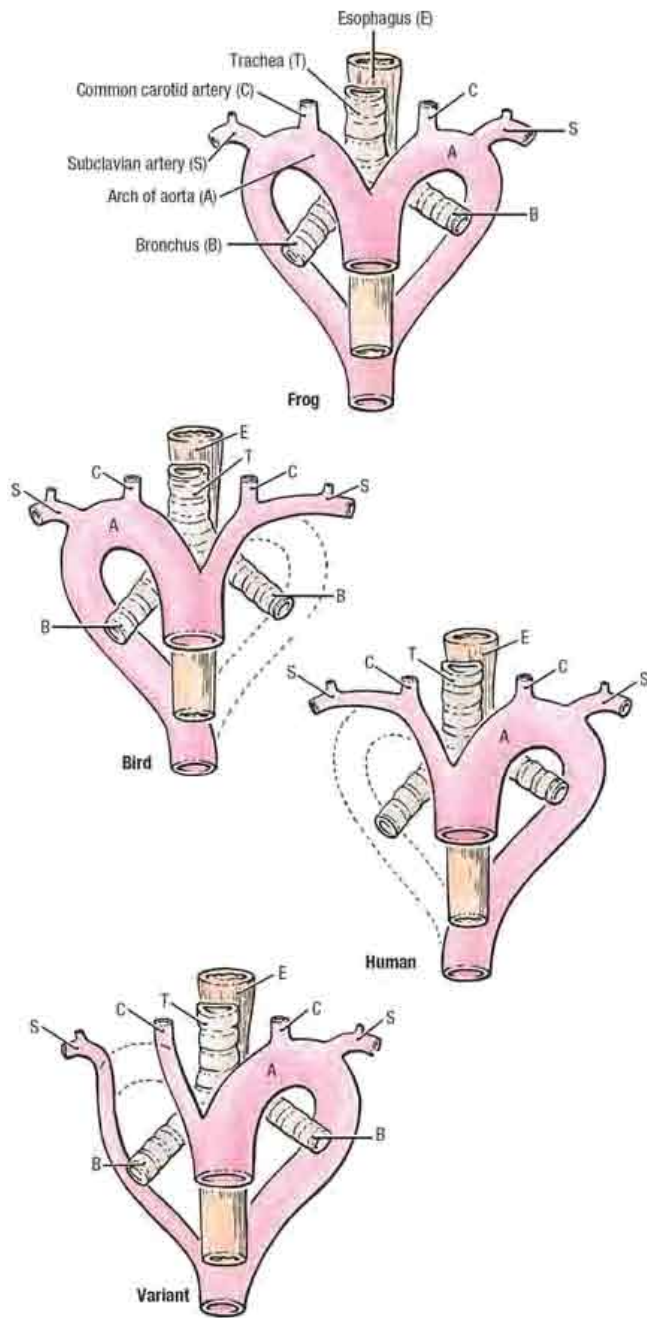
## 1.68 Scheme of varieties of aortic arches

*Part of* "Chapter 1 - Thorax "

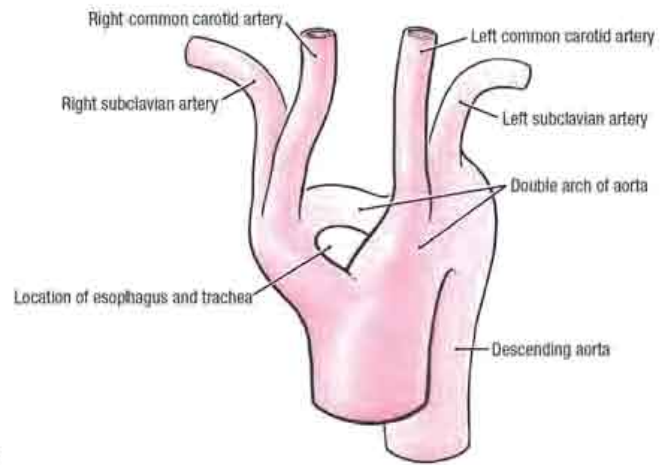
A. Comparative anatomy. The double aortic arch of the frog; the right aortic arch of the bird; the left aortic arch of the mammal, including man, and a variant. B. Double aortic arch. The right and left aortic arches persist completely, as in the frog. In this rare condition, the esophagus and trachea pass through the so-formed "aortic ring." C. Retroesophageal right subclavian artery. The artery arises as the last branch of the arch of the aorta, passing posterior to the esophagus and trachea.

---

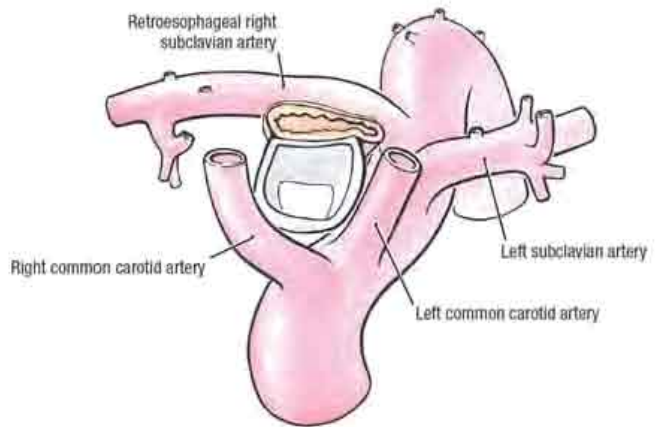
P.72



**A. Anterior Views**



**B. Anterior View**



**C. Anterior Superior View**

Authors: Agur, Anne M.R.; Dalley, Arthur F.

Title: *Grant's Atlas of Anatomy, 12th Edition*

Copyright ©2009 Lippincott Williams & Wilkins

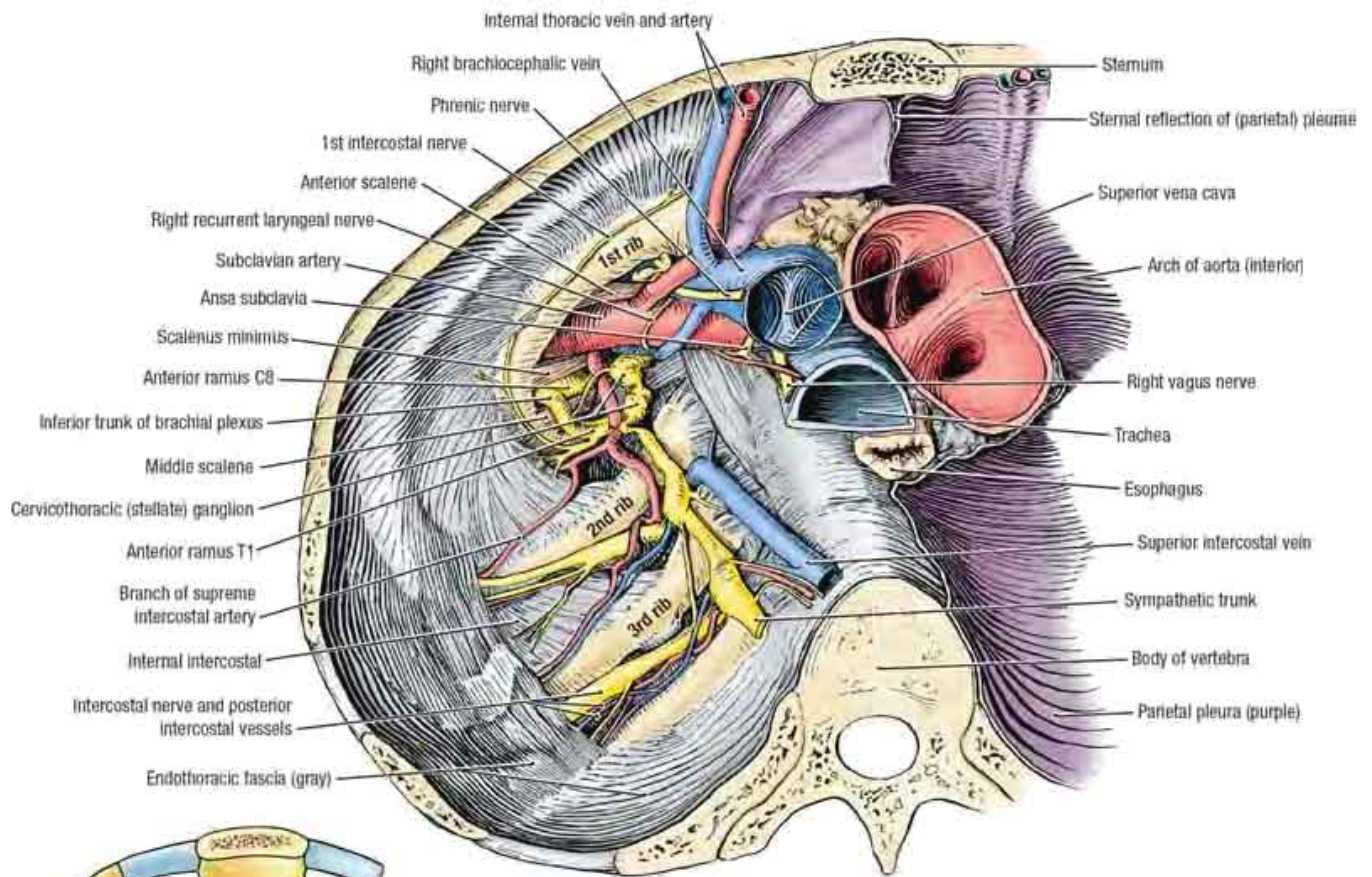
> Table of Contents > Chapter 1 - Thorax > 1.69 Superior mediastinum and roof of pleural cavity

---

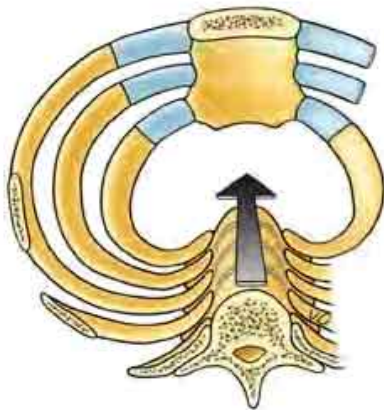## 1.69 Superior mediastinum and roof of pleural cavity

*Part of* "Chapter 1 - Thorax "

- The cervical, costal, and mediastinal parietal pleura (*purple*) and portions of the endothoracic fascia (*gray*) have been removed from the right side of the specimen to demonstrate structures traversing the superior thoracic aperture.
- The first part of the subclavian artery disappears as it crosses the first rib anterior to the anterior scalene muscle.
- The ansa subclavian from the sympathetic trunk and right recurrent laryngeal nerve from the vagus are seen looping inferior to the subclavian artery.
- The anterior rami of C8 and T1 merge to form the inferior trunk of the brachial plexus, which crosses the first rib posterior to the anterior scalene muscle.



Inferior View





Authors: Agur, Anne M.R.; Dalley, Arthur F.

Title: *Grant's Atlas of Anatomy, 12th Edition*

Copyright ©2009 Lippincott Williams & Wilkins

> Table of Contents > Chapter 1 - Thorax > 1.70 Diaphragm and pericardial sac

---

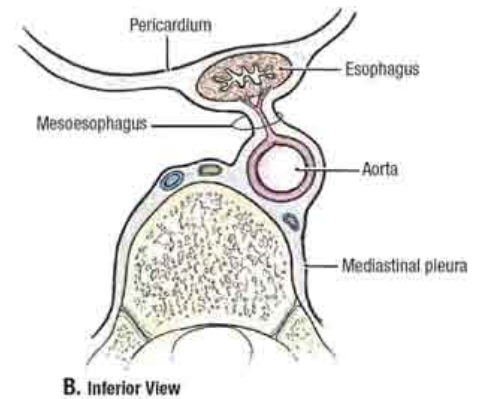
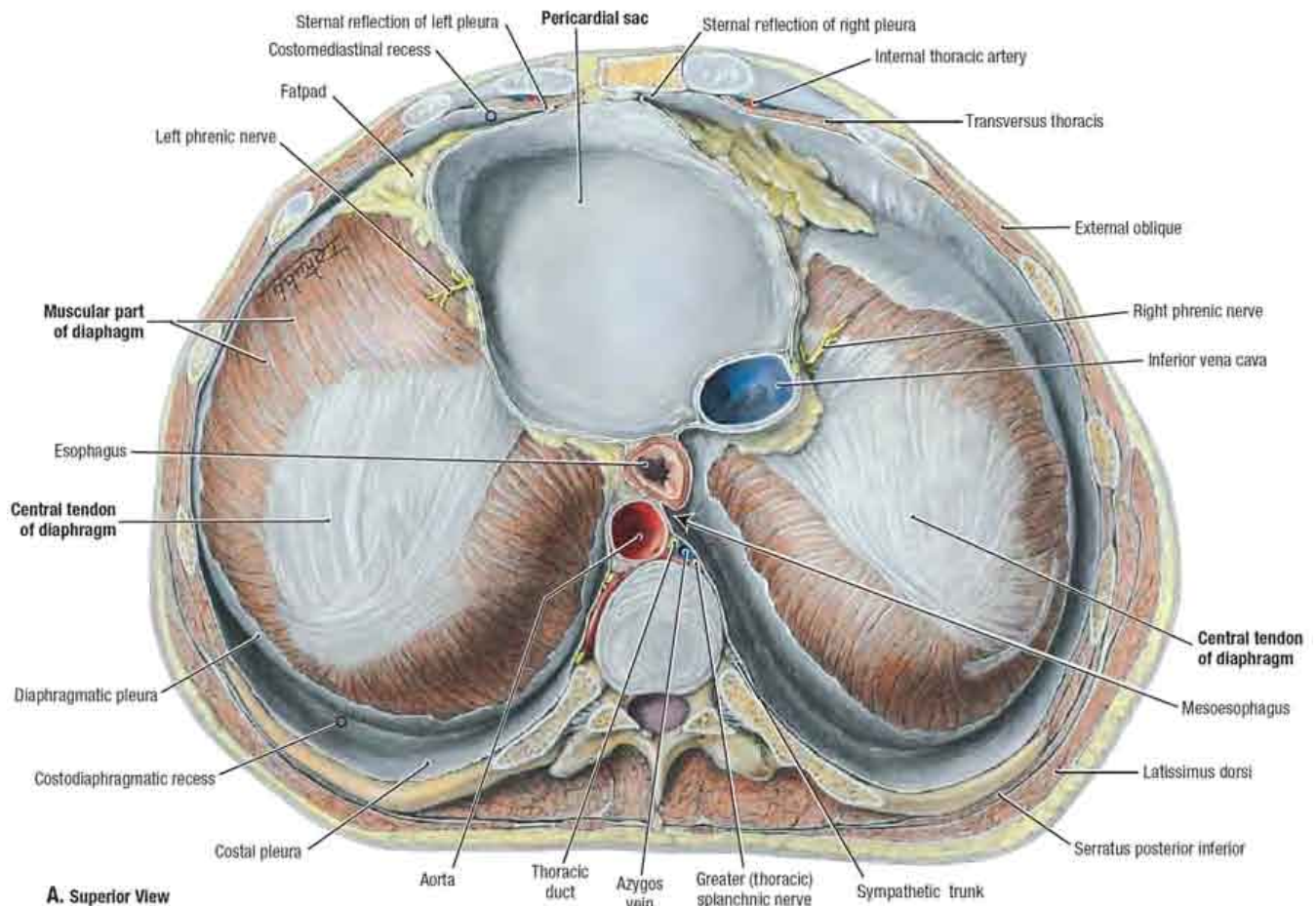
## 1.70 Diaphragm and pericardial sac

*Part of* "Chapter 1 - Thorax "

A. The diaphragmatic pleura is mostly removed. The pericardial sac is situated on the anterior half of the diaphragm; one third is to the right of the median plane, and two thirds to the left. Note also that anterior to the pericardium, the sternal reflection of the left pleural sac approaches but fails to meet that of the right sac in the median plane; and on reaching the vertebral column, the costal pleura becomes the mediastinal pleura.

Irritation of the parietal pleura produces local pain and referred pain to the areas sharing innervation by the same segments of the spinal cord. Irritation of the costal and peripheral parts of the diaphragmatic pleura results in local pain and referred pain along the intercostal nerves to the thoracic and abdominal walls. Irritation of the mediastinal and central diaphragmatic areas of the parietal pleura results in pain that is referred to the root of the neck and over the shoulder (C3–C5 dermatomes).

B. Between the inferior part of the esophagus and the aorta, the right and left layers of mediastinal pleura form a dorsal mesoesophagus.



Authors: Agur, Anne M.R.; Dalley, Arthur F.

Title: *Grant's Atlas of Anatomy, 12th Edition*

Copyright ©2009 Lippincott Williams & Wilkins

> Table of Contents > Chapter 1 - Thorax > 1.71 Esophagus, trachea, and aorta

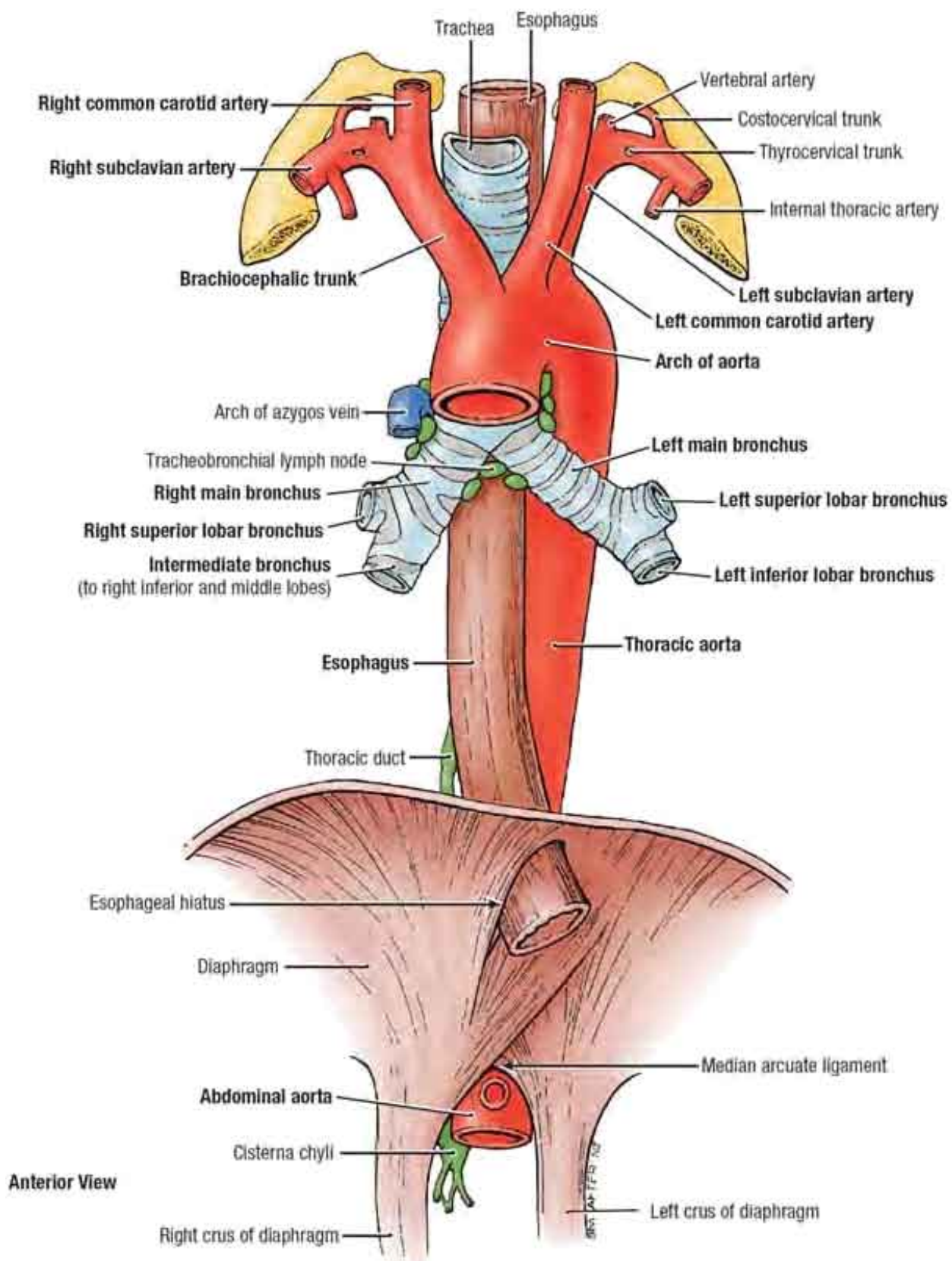
---

## 1.71 Esophagus, trachea, and aorta

*Part of* "Chapter 1 - Thorax"

- The anterior relations of the thoracic part of the esophagus from superior to inferior are the trachea (from origin at cricoid cartilage to bifurcation), right and left bronchi, inferior tracheobronchial lymph nodes, pericardium (not shown) and, finally, the diaphragm.
- The arch of the aorta passes posterior to the left of these four structures as it arches over the left main bronchus; the arch of the azygos vein passes anterior to their right as it arches over the right main bronchus.

- The impressions produced in the esophagus by adjacent structures (aorta, left main bronchus) are of clinical interest because of the slower passage of substances at these sites. The impressions indicate where swallowed foreign objects are most likely to lodge and where a stricture may develop after the accidental drinking of a caustic liquid such as lye.





Authors: Agur, Anne M.R.; Dalley, Arthur F.

Title: *Grant's Atlas of Anatomy, 12th Edition*

Copyright ©2009 Lippincott Williams & Wilkins

> Table of Contents > Chapter 1 - Thorax > 1.72 Arterial supply to trachea and esophagus

---

## 1.72 Arterial supply to trachea and esophagus

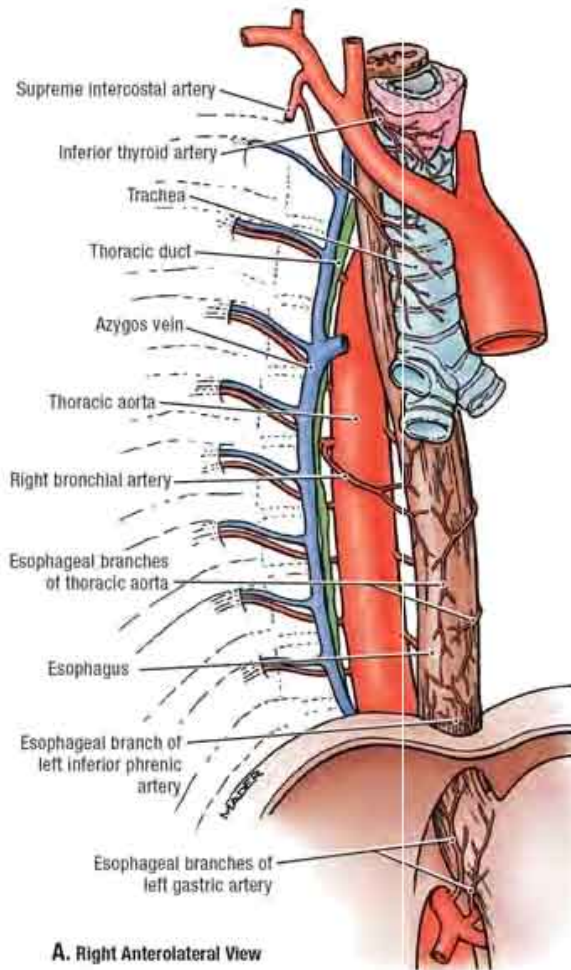
*Part of* "Chapter 1 - Thorax "

A and B. The continuous anastomotic chain of arteries on the esophagus is formed (a) by branches of the right and left inferior thyroid and right supreme intercostal arteries superiorly, (b) by the unpaired median aortic (bronchial and esophageal) branches, and (c) by branches of the left gastric and left inferior phrenic arteries inferiorly. The right bronchial artery usually arises from the superior left bronchial or 3rd right posterior intercostal artery (here the 5th) or from the aorta directly. The unpaired median aortic branches also supply the trachea and bronchi. C. Branches of the thoracic aorta.

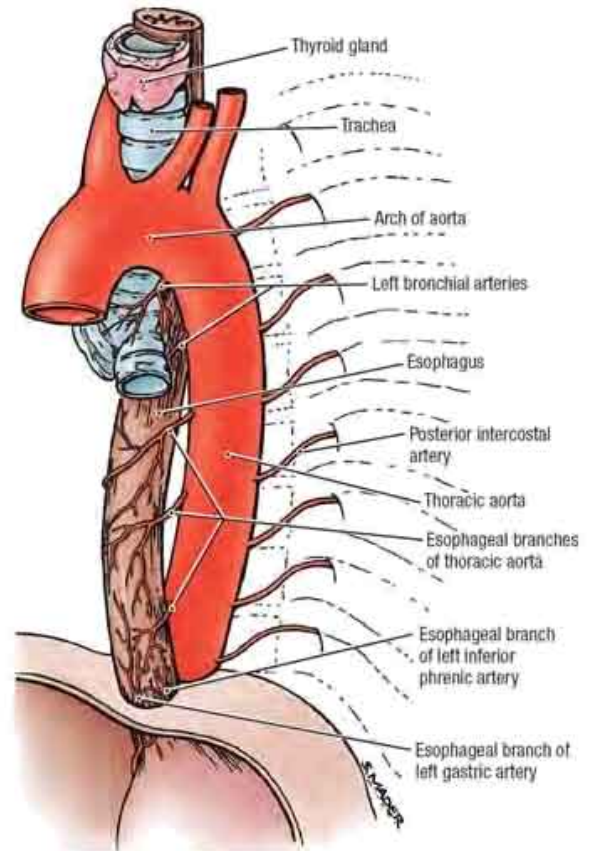
---

P.76

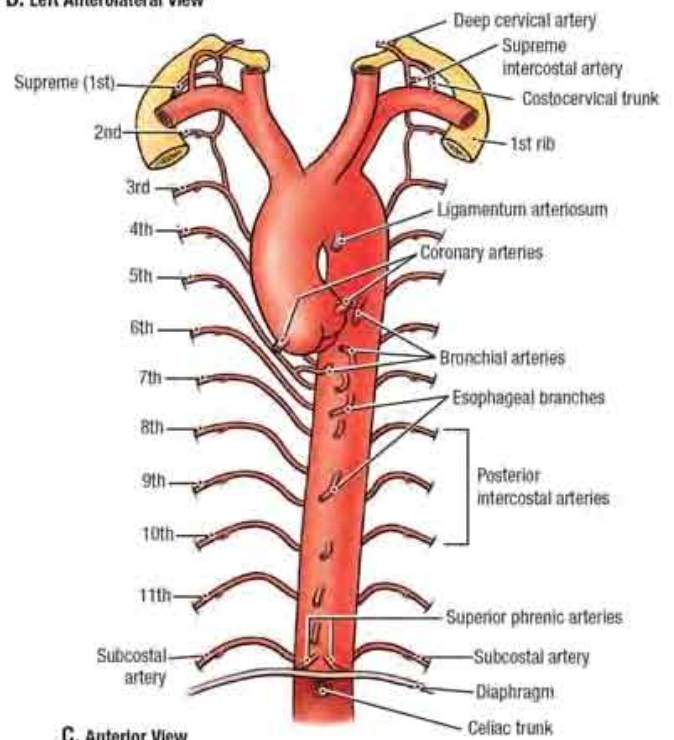




**A. Right Anterolateral View**



**B. Left Anterolateral View**



**C. Anterior View**

Authors: Agur, Anne M.R.; Dalley, Arthur F.

Title: *Grant's Atlas of Anatomy, 12th Edition*

Copyright ©2009 Lippincott Williams & Wilkins

> Table of Contents > Chapter 1 - Thorax > 1.73 Thoracic duct

---

## 1.73 Thoracic duct

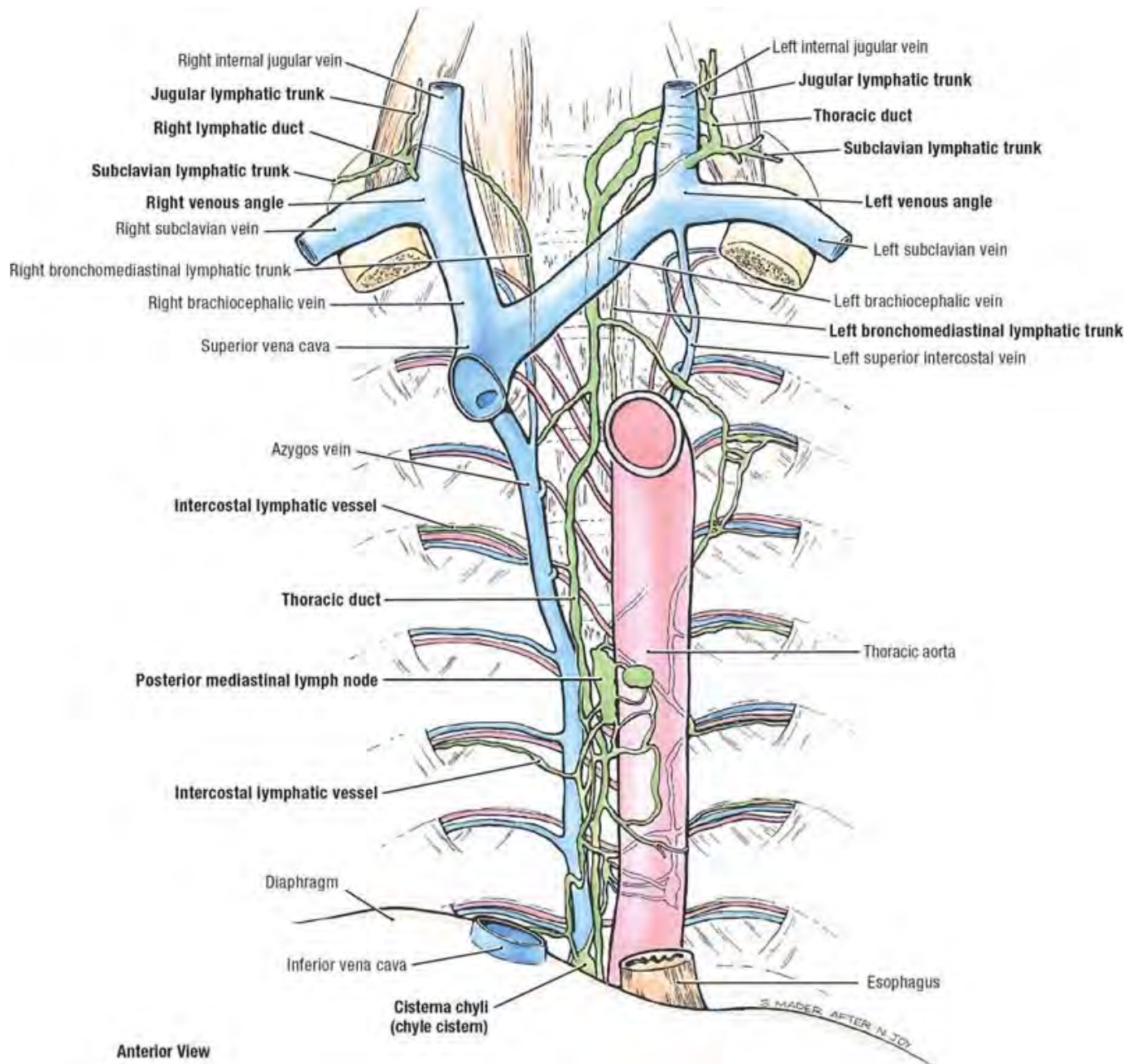
*Part of* "Chapter 1 - Thorax "

- The descending aorta is located to the left, and the azygos vein slightly to the right of the midline.
- The thoracic duct (a) originates from the cisterna chyli at the T12 vertebral level, (b) ascends on the vertebral column between the azygos vein and the descending aorta, (c) passes to the left at the junction of the posterior and superior mediastina, and continues its ascent to the neck, where (d) it arches laterally to enter the venous system near or at the angle of union of the left internal jugular and subclavian veins (left venous angle).
- The thoracic duct is commonly plexiform (resembling a network) in the posterior mediastinum.
- The termination of the thoracic duct typically receives the jugular, subclavian, and bronchomediastinal trunks.
- The right lymph duct is short and formed by the union of the right jugular, subclavian, and bronchomediastinal trunks.

- Because the thoracic duct is thin walled and may be colorless, it may not be easily identified. Consequently, it is vulnerable to inadvertent injury during investigative and/or surgical procedures in the posterior mediastinum. Laceration of the thoracic duct results in chyle escaping into the thoracic cavity. Chyle may also enter the pleural

cavity, producing chylothorax.

P.77



Authors: Agur, Anne M.R.; Dalley, Arthur F.

Title: *Grant's Atlas of Anatomy, 12th Edition*

Copyright ©2009 Lippincott Williams & Wilkins

> Table of Contents > Chapter 1 - Thorax > 1.74 Lymphatic system

---

## 1.74 Lymphatic system

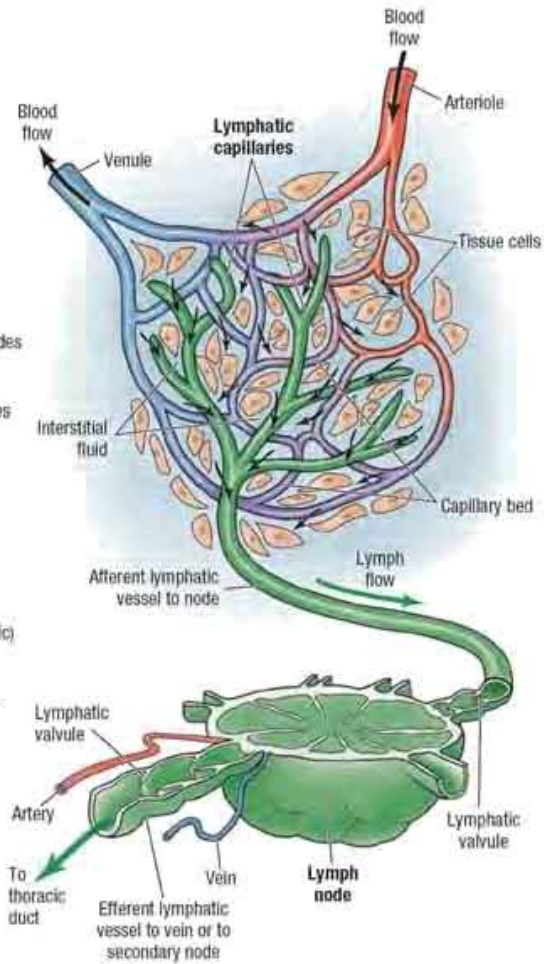
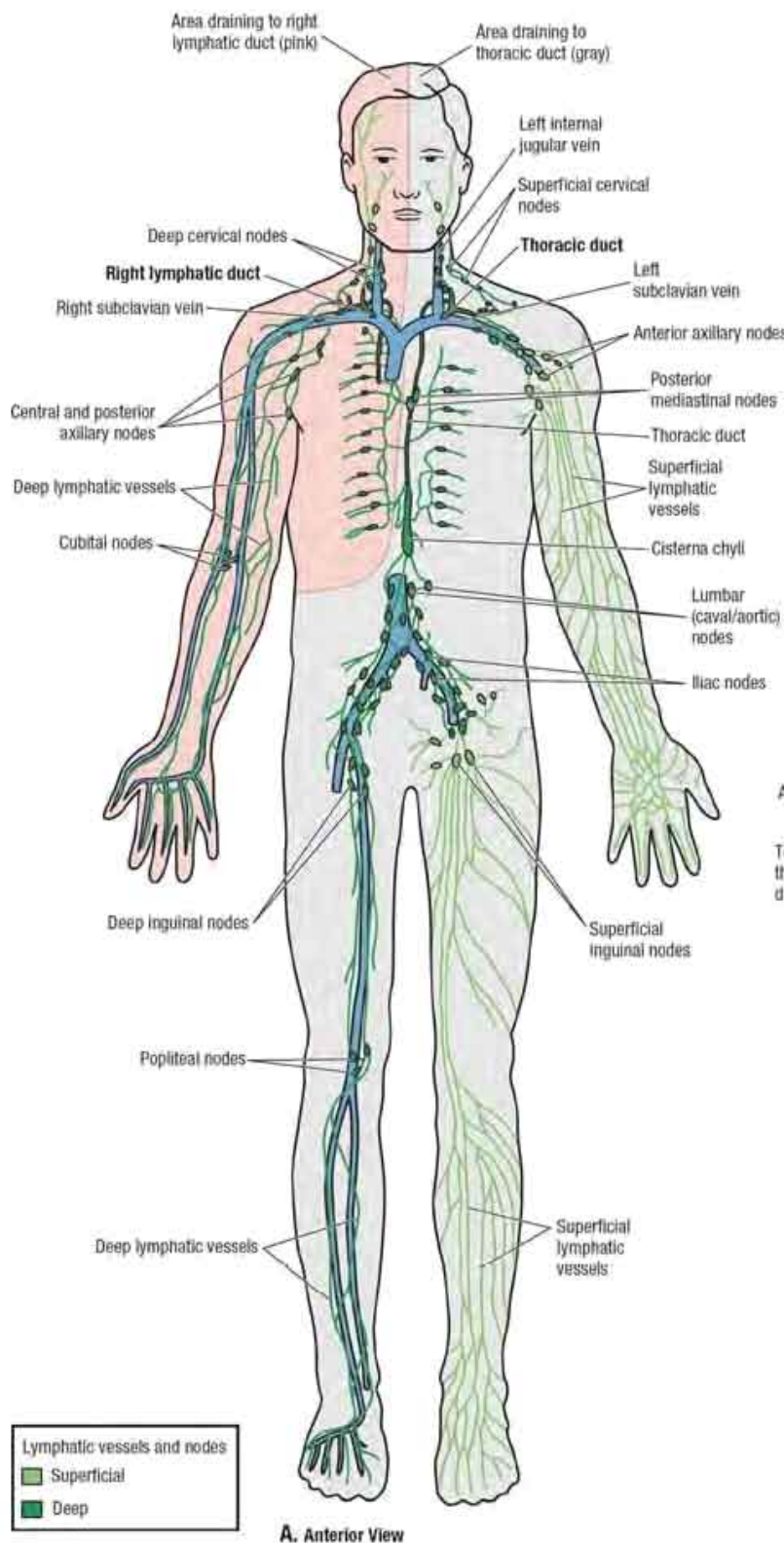
*Part of* "Chapter 1 - Thorax "

A. Overview of superficial and deep lymphatics. B. Lymphatic capillaries, vessels, and nodes. *Black arrows* indicate the flow (leaking of interstitial fluid out of blood vessels and absorption) into the lymphatic capillaries.

---

P.78





Authors: Agur, Anne M.R.; Dalley, Arthur F.

Title: *Grant's Atlas of Anatomy, 12th Edition*

Copyright ©2009 Lippincott Williams & Wilkins

> Table of Contents > Chapter 1 - Thorax > 1.75 Azygos system of veins

---

## 1.75 Azygos system of veins

*Part of* "Chapter 1 - Thorax "

The ascending lumbar veins connect the common iliac veins to the lumbar veins and join the subcostal veins to become the lateral roots of the azygos and hemiazygos veins; the medial roots of the azygos and hemiazygos veins are usually from the inferior vena cava and left renal vein, if present. Typically the upper four left posterior intercostal veins drain into the left brachiocephalic vein, directly and via the left superior intercostal veins.

In A , the hemiazygos, accessory hemiazygos, and left superior intercostals veins are continuous, but commonly they are discontinuous. The hemiazygos vein crosses the vertebral column at approximately T9, and the accessory hemiazygos vein crosses at T8, to enter the azygos vein. In A , there are four cross-connecting channels between the azygos and hemiazygos systems. The azygos vein arches superior to the root of the right lung at T4 to drain into the superior vena cava.

---

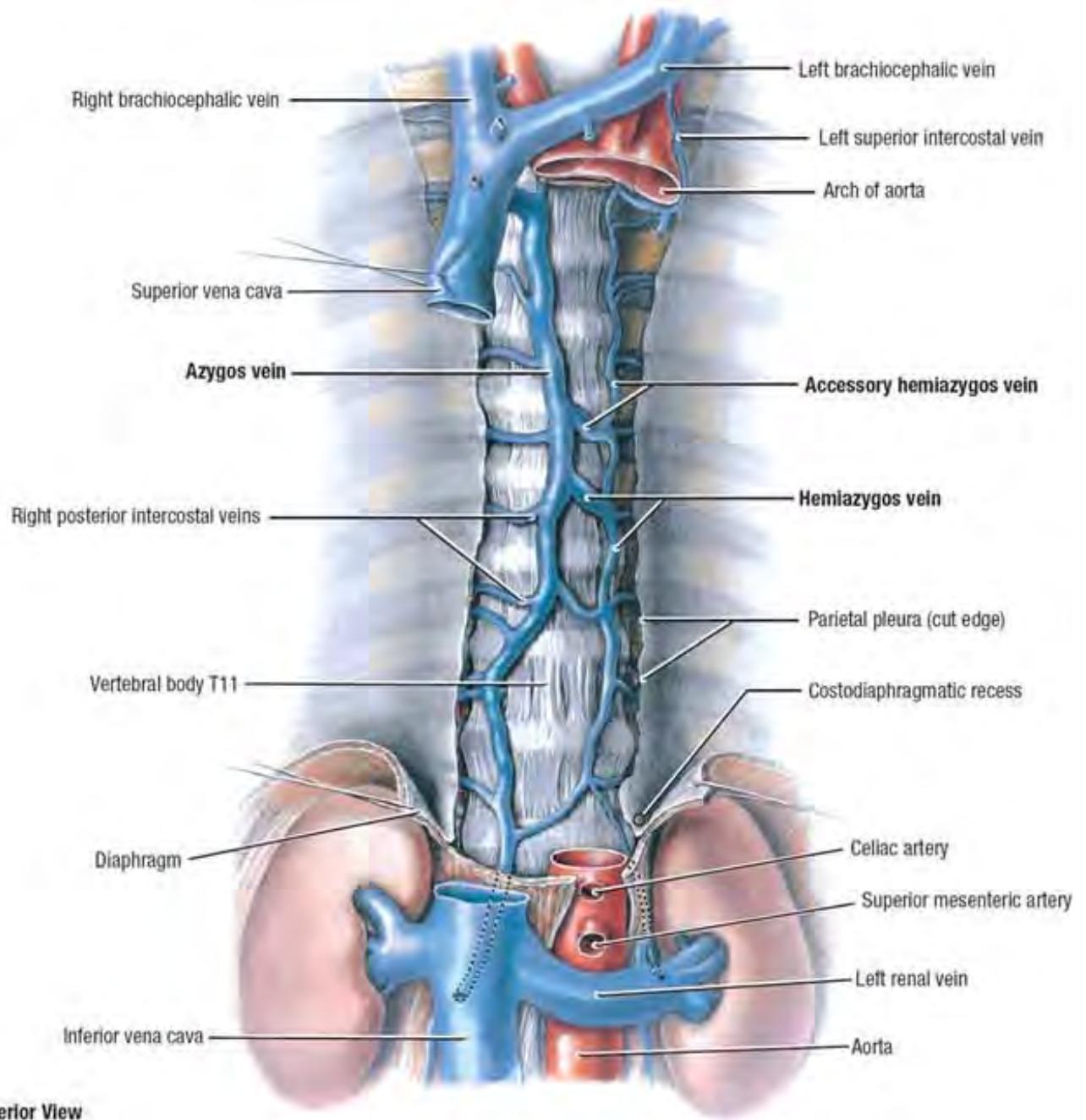
P.79

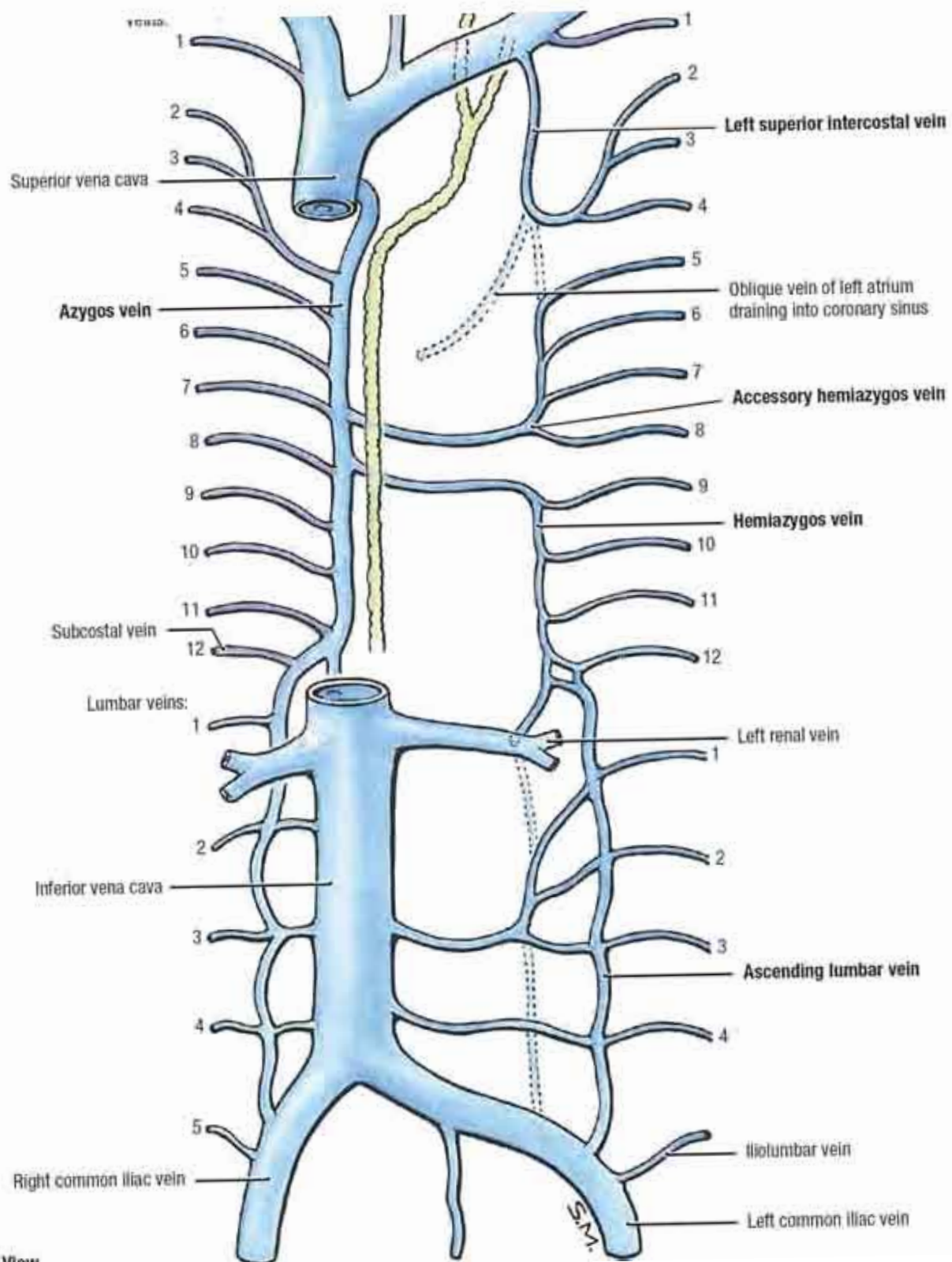
The azygos, hemiazygos, and accessory hemiazygos veins offer alternate means of venous drainage from the thoracic, abdominal, and back regions when *obstruction of the IVC* occurs. In some people, an accessory azygos vein parallels the main azygos vein on the right side. Other people have no hemiazygos system of veins. A clinically important variation, although uncommon, is when the azygos system receives all the blood from the IVC, except that from the liver. In these people, the azygos system drains nearly all the blood inferior to the diaphragm, except that from the digestive tract. When *obstruction of the SVC* occurs superior to the entrance of the



azygos vein, blood can drain inferiorly into the veins of the abdominal wall and return to the right atrium through the IVC and azygos system of veins.

P.80





**B. Anterior View**

Authors: Agur, Anne M.R.; Dalley, Arthur F.

Title: *Grant's Atlas of Anatomy, 12th Edition*

Copyright ©2009 Lippincott Williams & Wilkins

> Table of Contents > Chapter 1 - Thorax > 1.75 Azygos system of veins

---

## 1.75 Azygos system of veins

*Part of* "Chapter 1 - Thorax "

The ascending lumbar veins connect the common iliac veins to the lumbar veins and join the subcostal veins to become the lateral roots of the azygos and hemiazygos veins; the medial roots of the azygos and hemiazygos veins are usually from the inferior vena cava and left renal vein, if present. Typically the upper four left posterior intercostal veins drain into the left brachiocephalic vein, directly and via the left superior intercostal veins.

In A , the hemiazygos, accessory hemiazygos, and left superior intercostals veins are continuous, but commonly they are discontinuous. The hemiazygos vein crosses the vertebral column at approximately T9, and the accessory hemiazygos vein crosses at T8, to enter the azygos vein. In A , there are four cross-connecting channels between the azygos and hemiazygos systems. The azygos vein arches superior to the root of the right lung at T4 to drain into the superior vena cava.

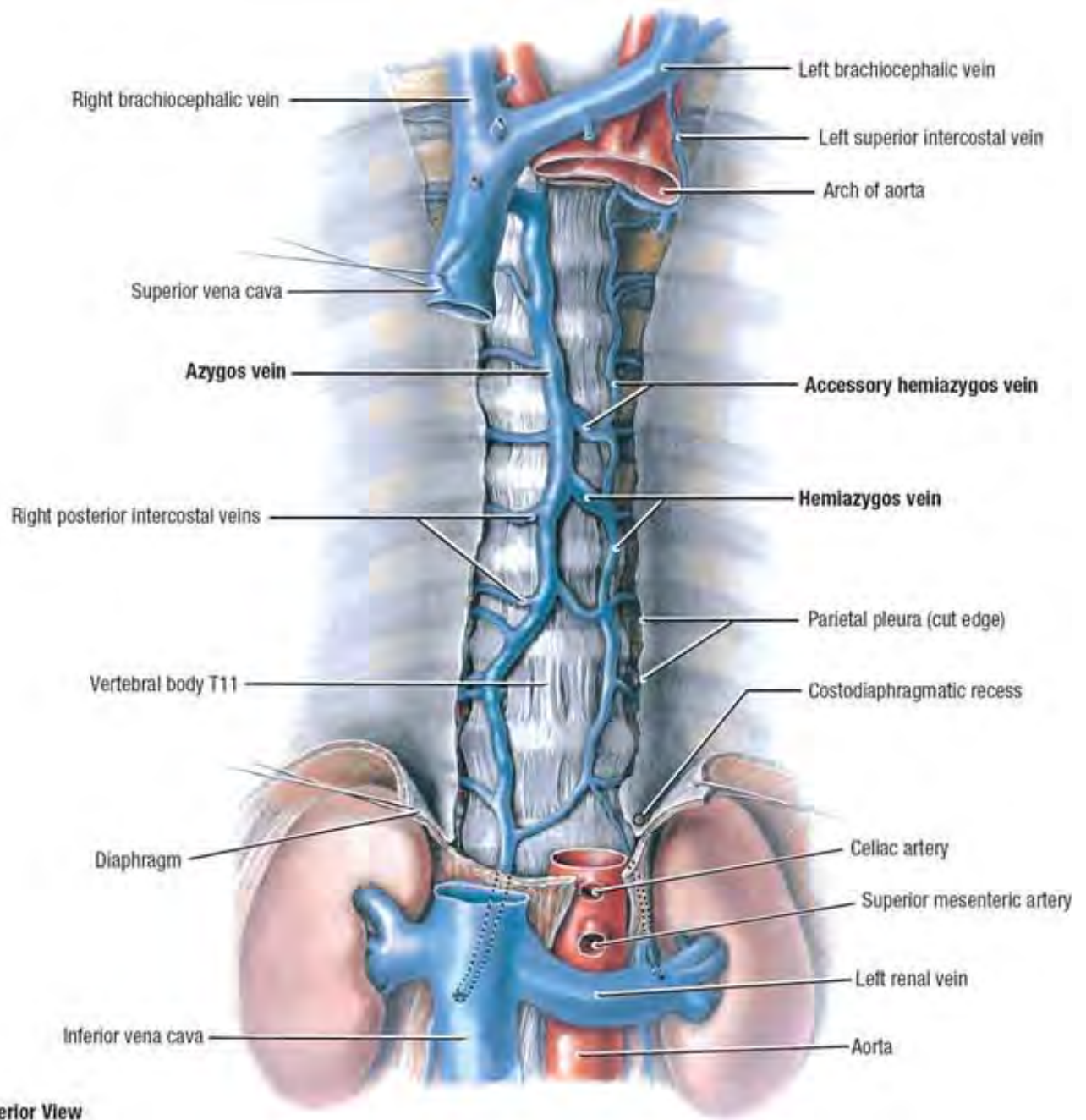
---

P.79

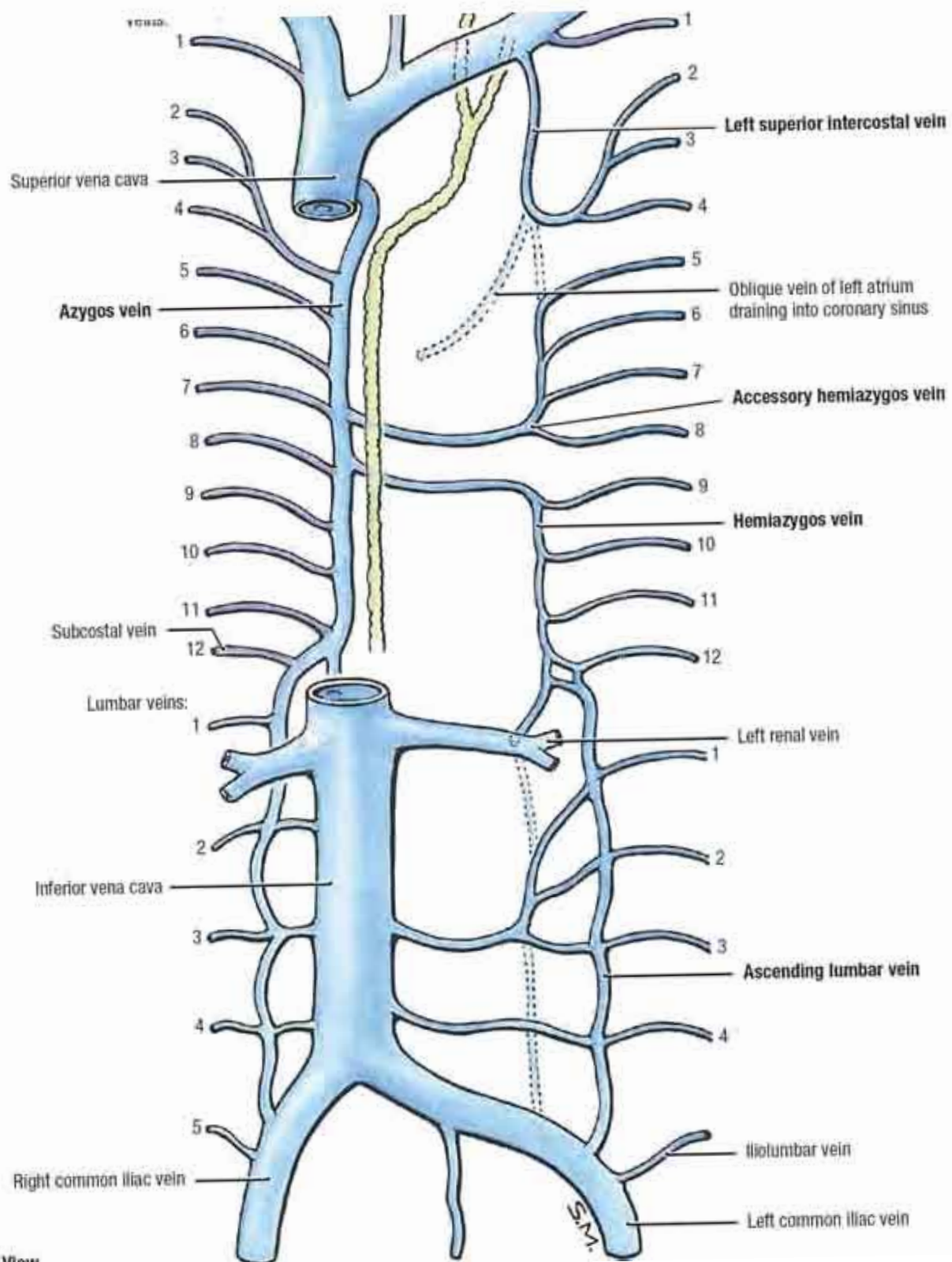
The azygos, hemiazygos, and accessory hemiazygos veins offer alternate means of venous drainage from the thoracic, abdominal, and back regions when *obstruction of the IVC* occurs. In some people, an accessory azygos vein parallels the main azygos vein on the right side. Other people have no hemiazygos system of veins. A clinically important variation, although uncommon, is when the azygos system receives all the blood from the IVC, except that from the liver. In these people, the azygos system drains nearly all the blood inferior to the diaphragm, except that from the digestive tract. When *obstruction of the SVC* occurs superior to the entrance of the

azygos vein, blood can drain inferiorly into the veins of the abdominal wall and return to the right atrium through the IVC and azygos system of veins.

P.80







**B. Anterior View**

Authors: Agur, Anne M.R.; Dalley, Arthur F.

Title: *Grant's Atlas of Anatomy, 12th Edition*

Copyright ©2009 Lippincott Williams & Wilkins

> Table of Contents > Chapter 1 - Thorax > 1.77 Mediastinum, left side

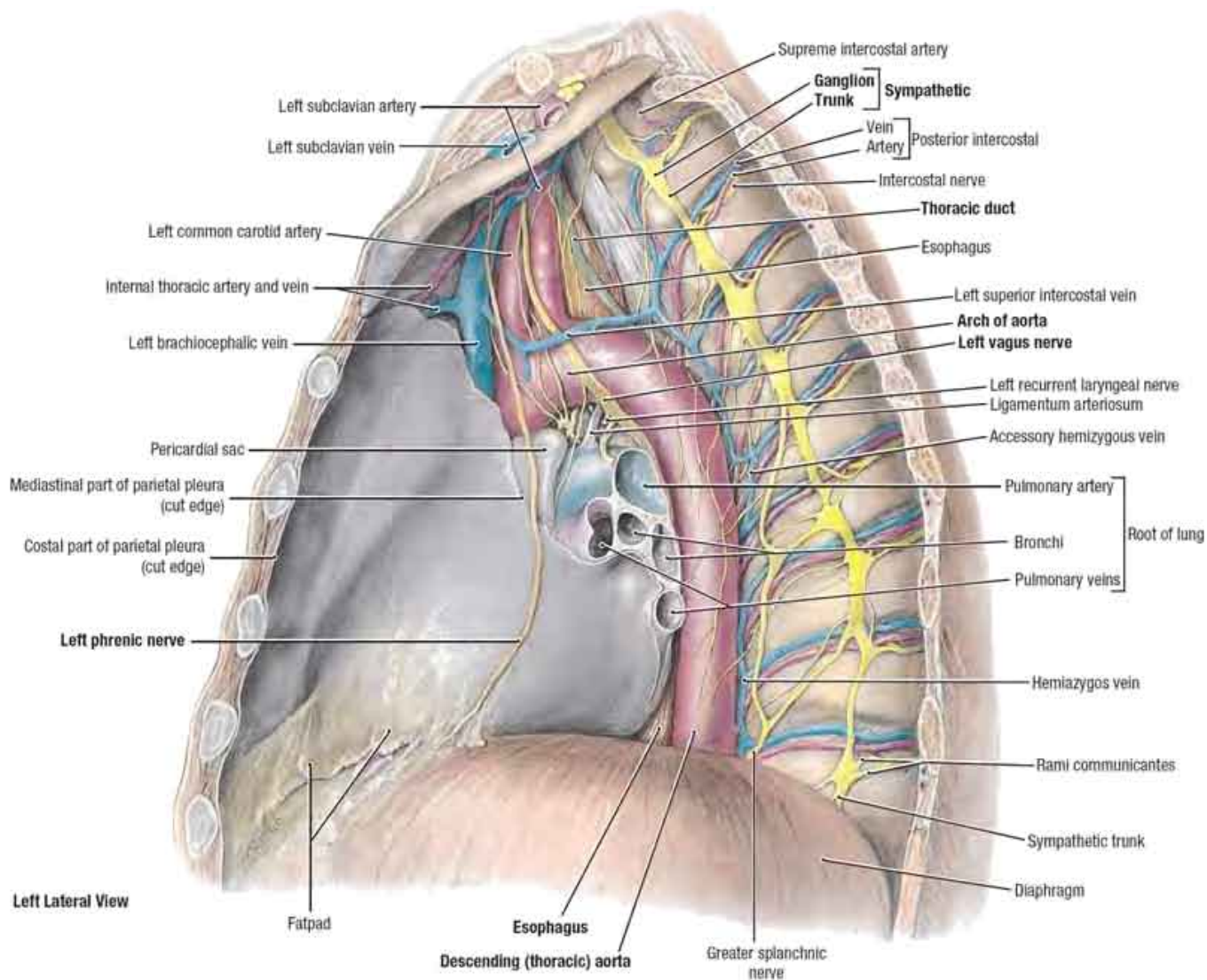
---

## 1.77 Mediastinum, left side

*Part of* "Chapter 1 - Thorax "

- Compare with the mediastinal surface of the left lung in Figure 1.30 .
- The left side of the mediastinum is the "œered side," dominated by the arch and descending portion of the aorta, the left common carotid and subclavian arteries; the latter obscure the trachea from view.
- The thoracic duct can be seen on the left side of the esophagus.
- The left vagus nerve passes posterior to the root of the lung, sending its recurrent laryngeal branch around the ligamentum arteriosum inferior, then medial to the aortic arch.
- The phrenic nerve passes anterior to the root of the lung and penetrates the diaphragm more anteriorly than on the right side.





Authors: Agur, Anne M.R.; Dalley, Arthur F.

Title: *Grant's Atlas of Anatomy, 12th Edition*

Copyright ©2009 Lippincott Williams & Wilkins

> Table of Contents > Chapter 1 - Thorax > 1.78 Structures of posterior mediastinum

---

## 1.78 Structures of posterior mediastinum

*Part of* "Chapter 1 - Thorax "

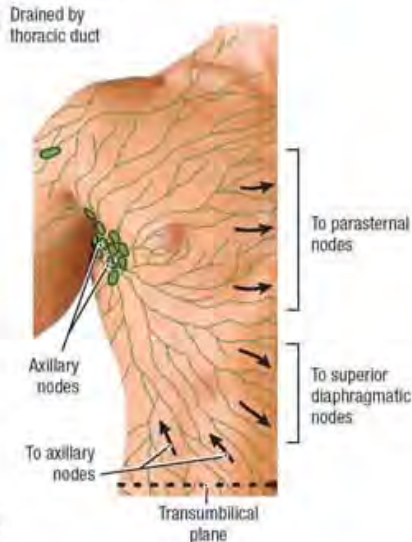
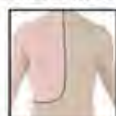- In this specimen, the parietal pleura is intact on the left side and partially removed on the right side. A portion of the esophagus, between the bifurcation of the trachea and the diaphragm, is also removed.
- The thoracic sympathetic trunk is connected to each intercostal nerve by rami communicantes.
- The greater splanchnic nerve is formed by fibers from the 5th to 10th thoracic ganglia, and the lesser splanchnic nerve receives fibers from the 10th and 11th thoracic ganglia. Both nerves contain presynaptic and visceral afferent fibers.
- The azygos vein ascends anterior to the intercostal vessels and to the right of the thoracic duct and aorta.

---

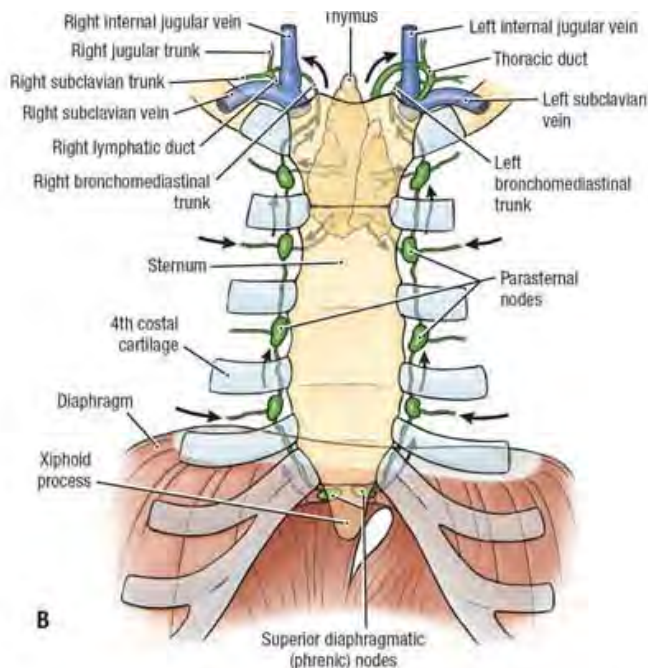
P.83

- The thoracic vertebral column and thoracic cage are removed on the right. On the left, the ribs and intercostal musculature are removed posteriorly as far laterally as the angles of the ribs. The parietal pleura is intact on the left side but partially removed on the right to reveal the visceral pleura covering the right lung.
  - The azygos vein is on the right side, and the hemiazygos vein is on the left, crossing the midline (usually at T9, but higher in this specimen) to join the azygos vein. The accessory hemiazygos vein is absent in this specimen; instead, three most superior posterior intercostal veins drain directly into the azygos vein.
-

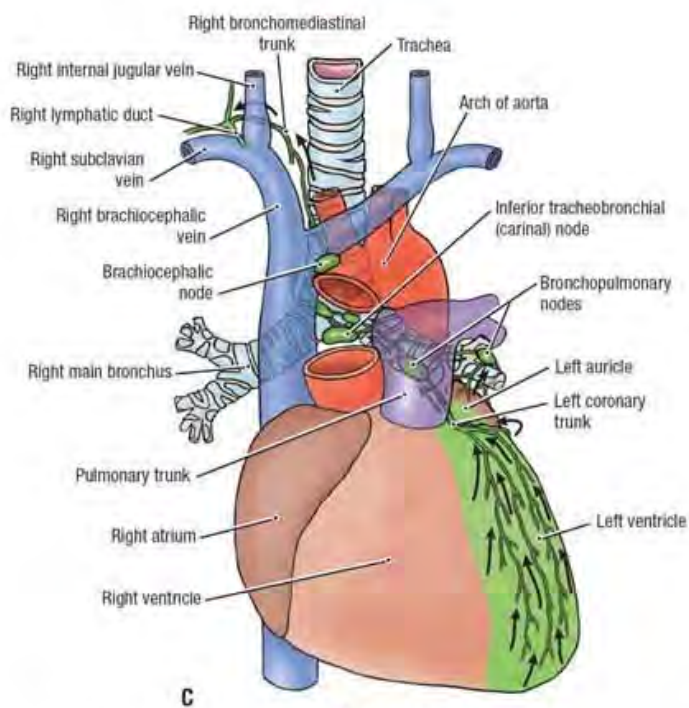
Areas of thorax (superficial and deep):



A



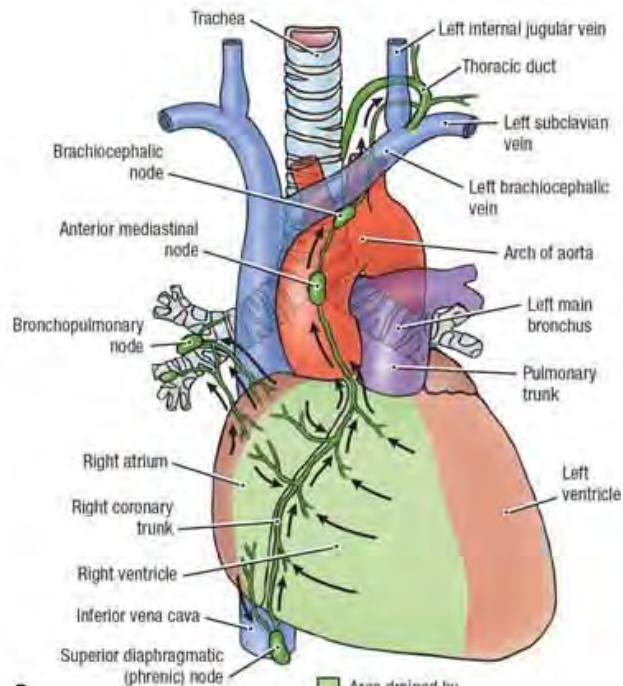
B



C

Anterior Views

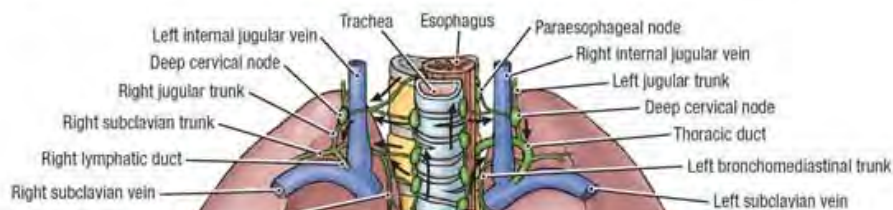
Area drained by left coronary trunk



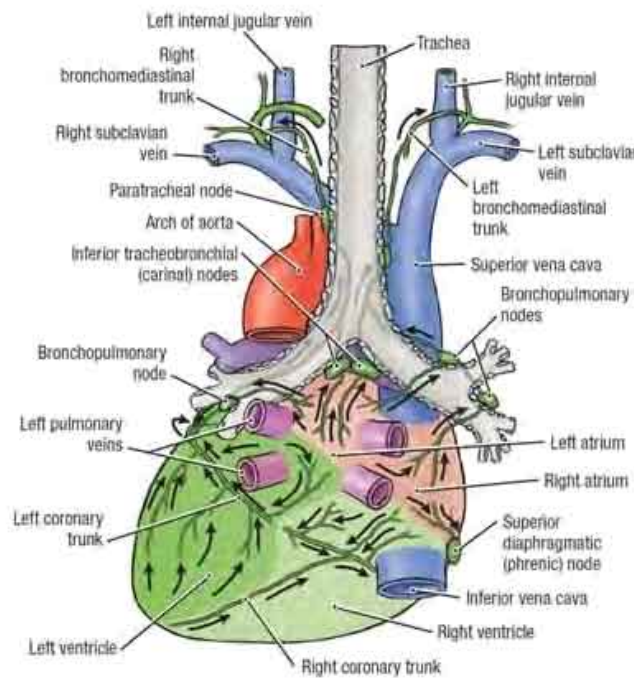
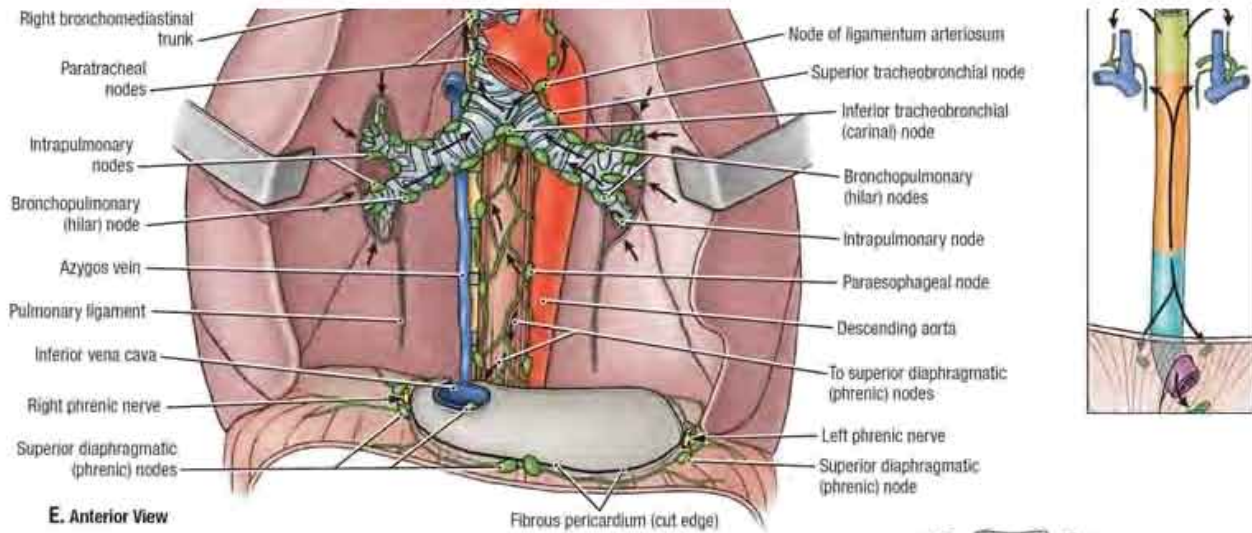
D

Lymphatic drainage of esophagus to

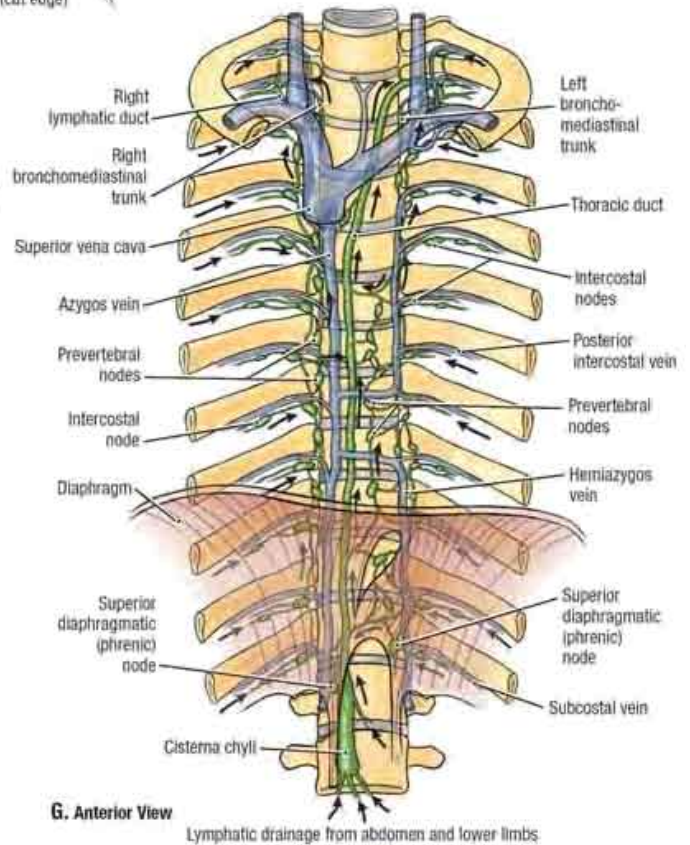
- Jugular trunks
- Bronchomediastinal trunks
- Superior diaphragmatic nodes
- Celiac (abdominal) nodes







Area drained by left coronary trunk  
 Area drained by right coronary trunk



Authors: Agur, Anne M.R.; Dalley, Arthur F.  
Title: *Grant's Atlas of Anatomy, 12th Edition*  
Copyright ©2009 Lippincott Williams & Wilkins

> Table of Contents > Chapter 1 - Thorax > 1.79 Overview of autonomic innervation of thorax

## 1.79 Overview of autonomic innervation of thorax

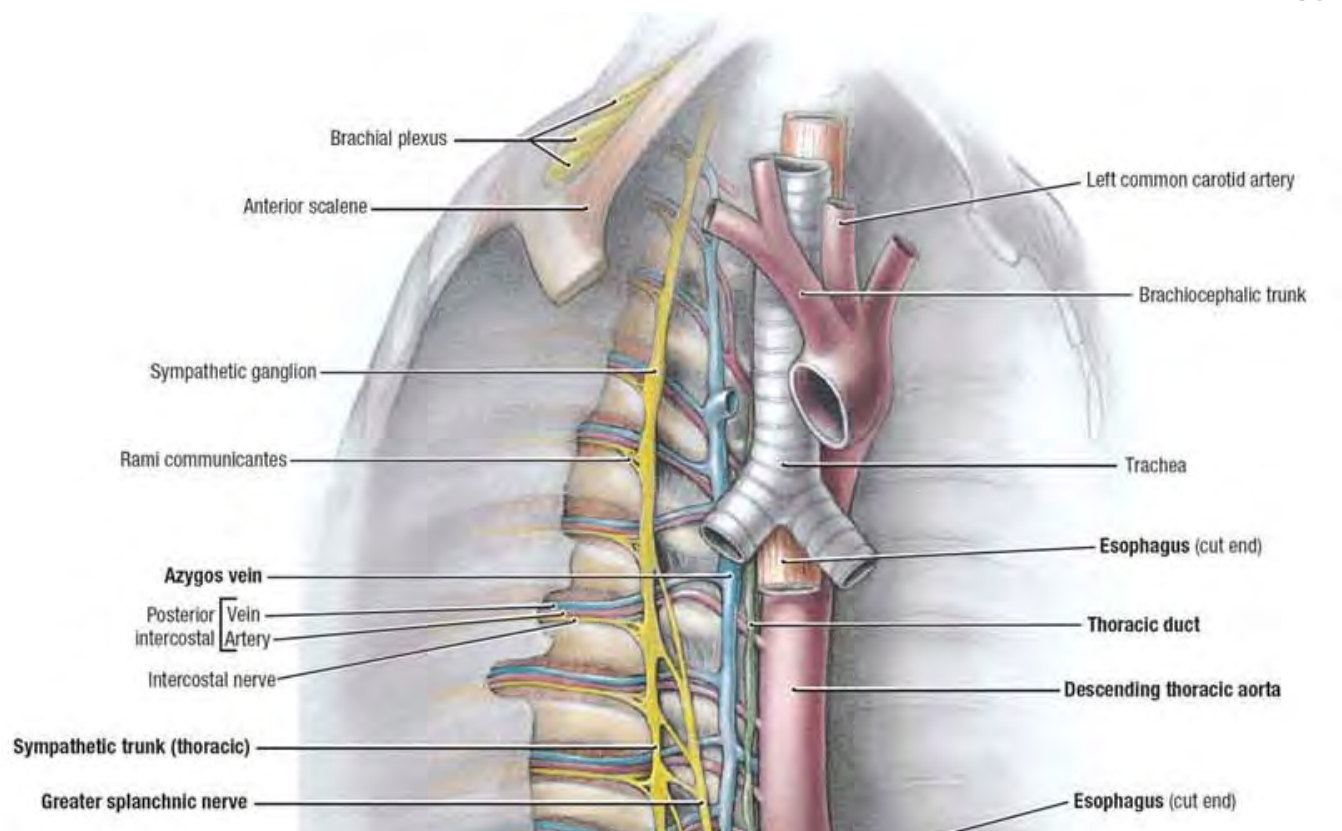
*Part of* "Chapter 1 - Thorax "

A. Innervation of heart. B. Innervation of trachea and bronchial tree.

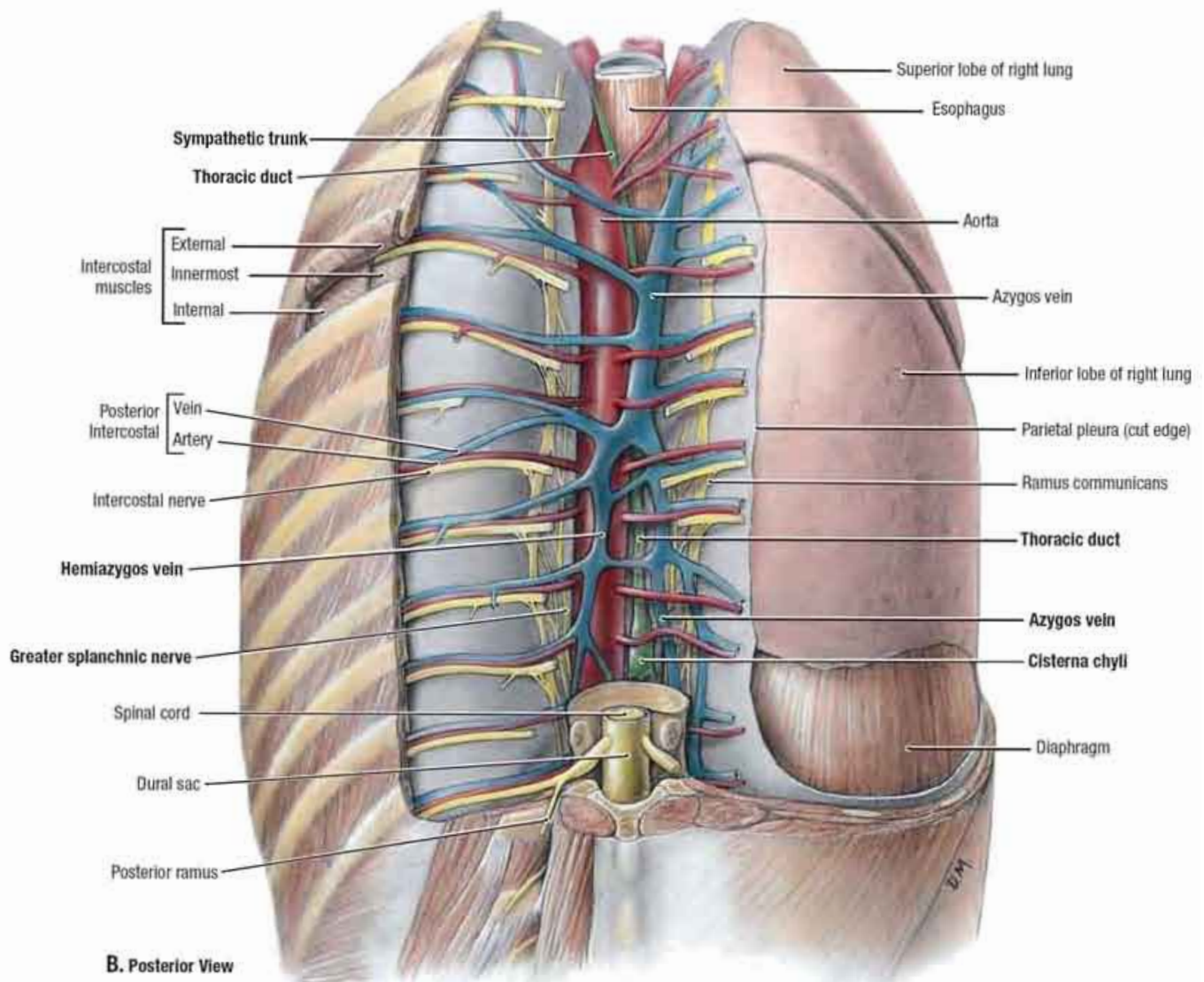
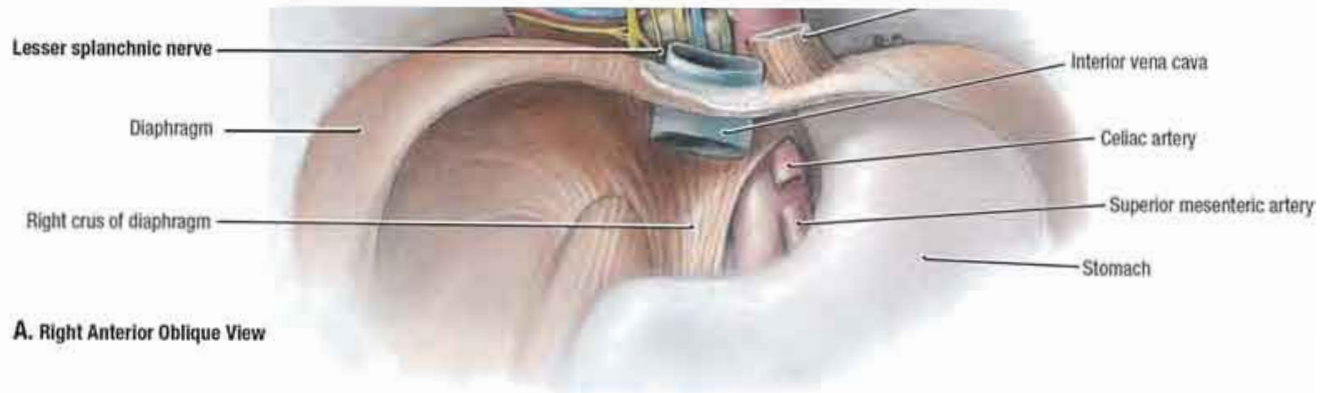
P.85

C. Innervation of posterior and superior mediastina.

P.86









## 1.80 Overview of lymphatic drainage of thorax

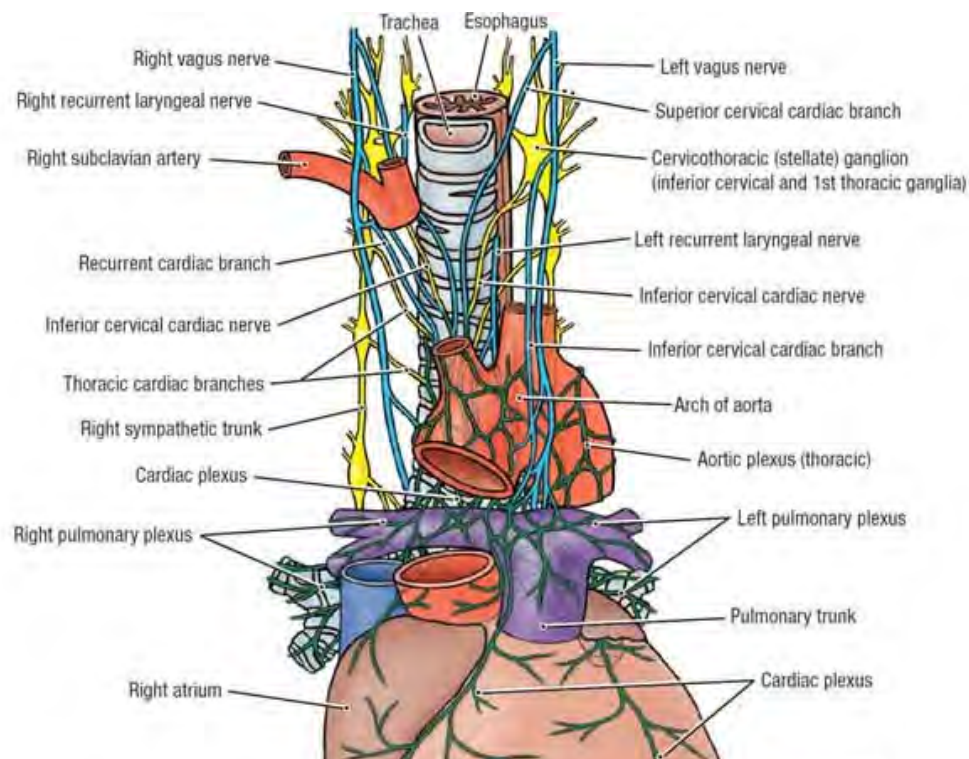
Part of "Chapter 1 - Thorax "

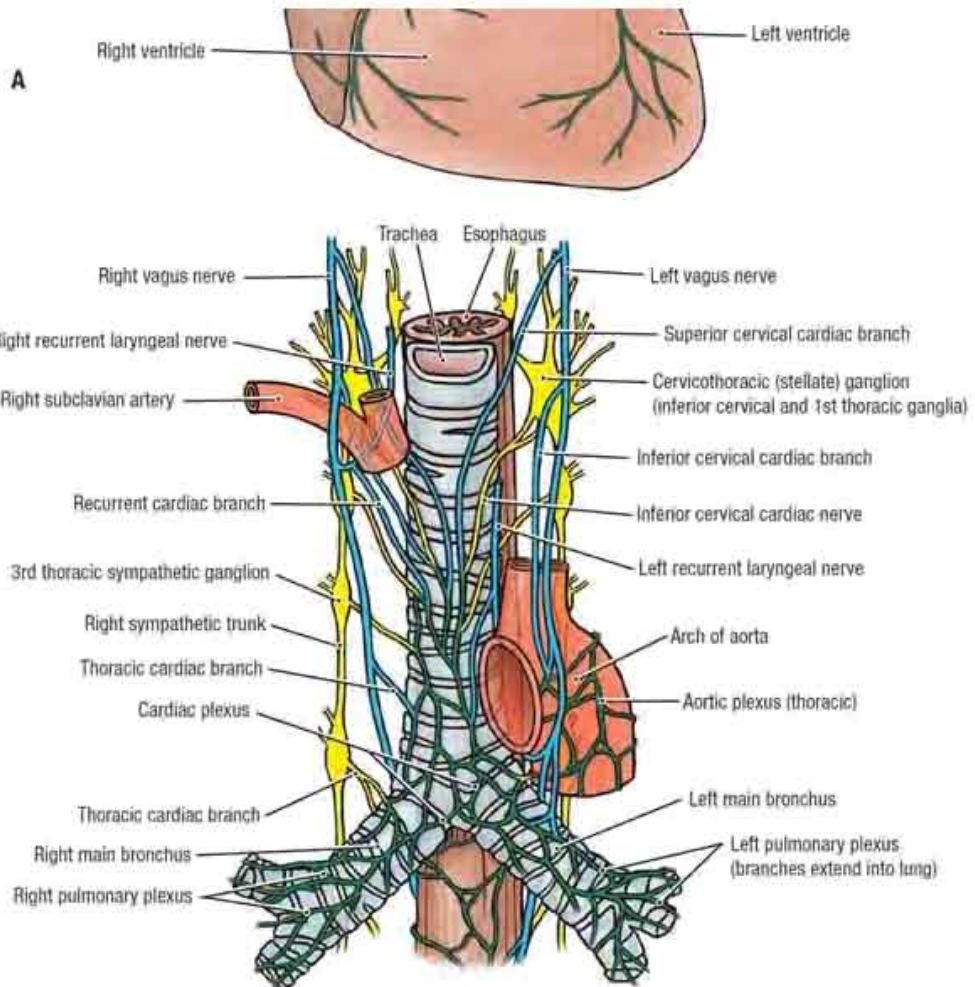
A. Superficial lymphatic drainage. B. Lymphatic drainage of parasternal nodes. C. Lymphatic drainage of left side of heart. D. Lymphatic drainage of right side of heart.

P.87

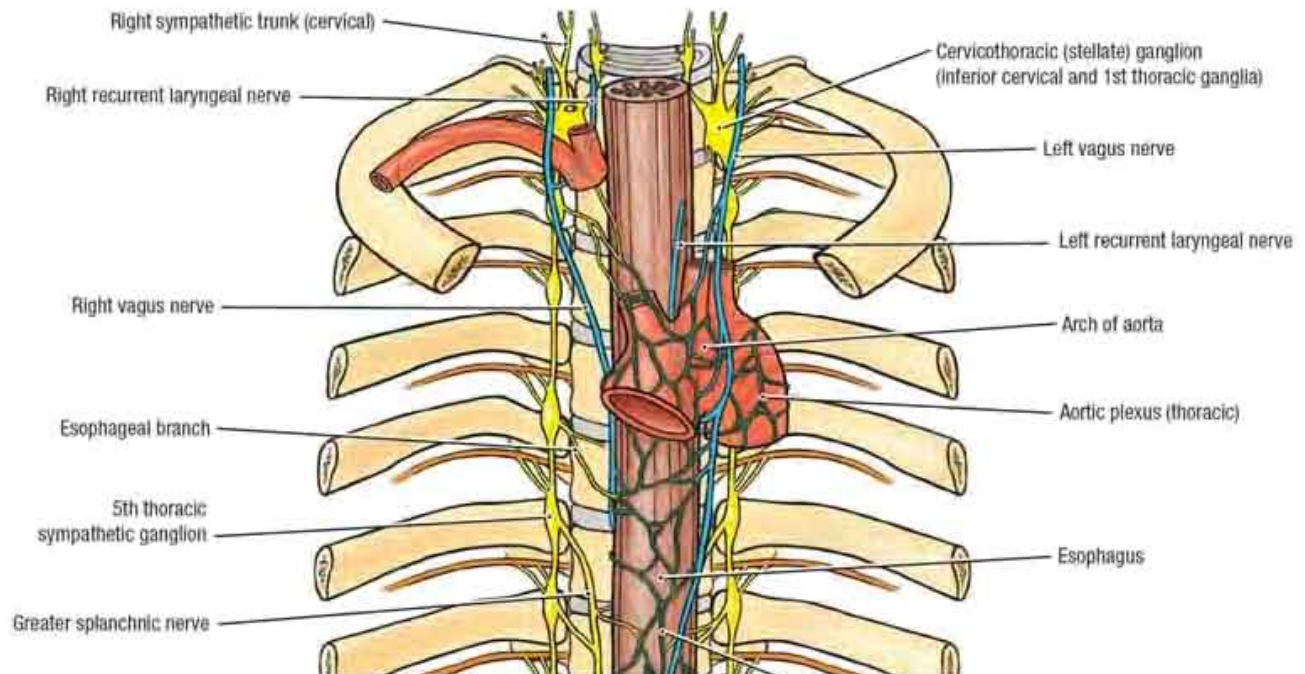
E. Lymphatic drainage of lungs, esophagus, and superior surface of diaphragm. F. Lymphatic drainage of posterior and inferior surfaces of heart. G. Lymphatic drainage of posterior mediastinum.

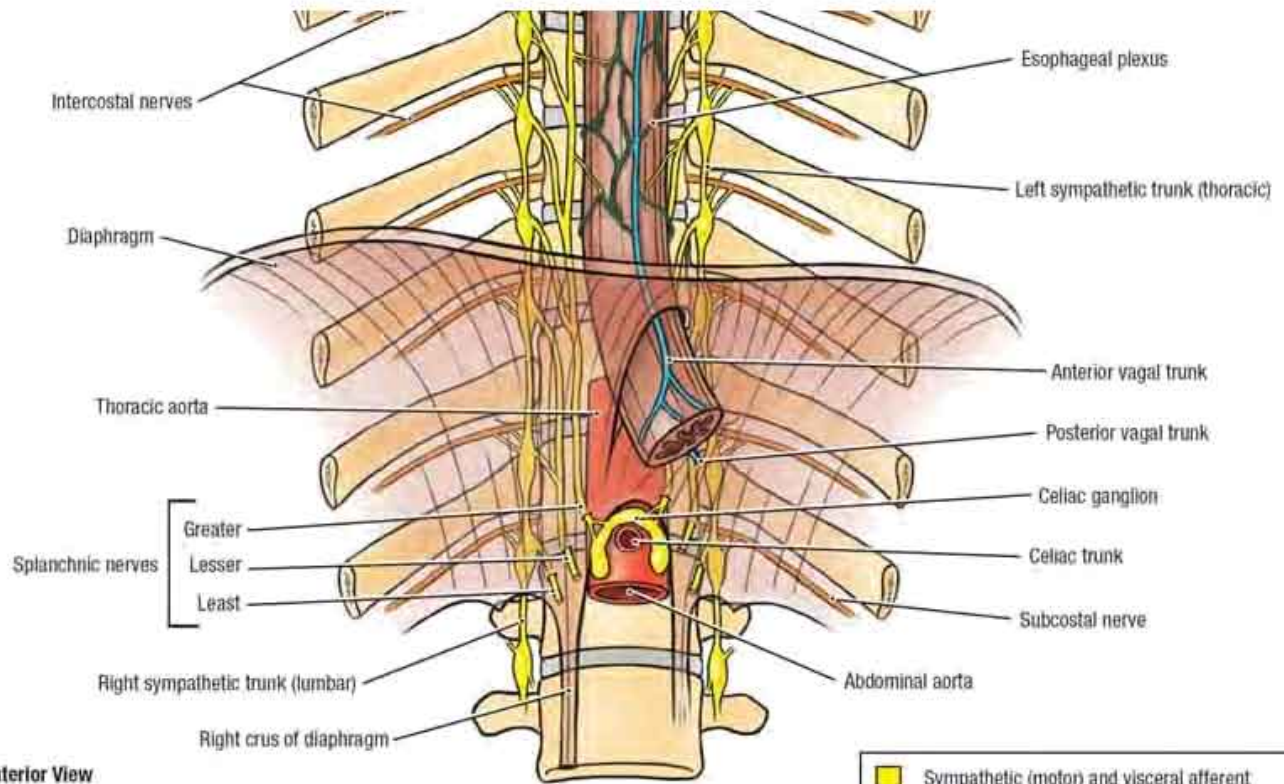
P.88





**Anterior Views**





**C. Anterior View**

Yellow	Sympathetic (motor) and visceral afferent
Blue	Parasympathetic (motor) and visceral afferent
Green	Mixed sympathetic and parasympathetic
Orange	Somatic

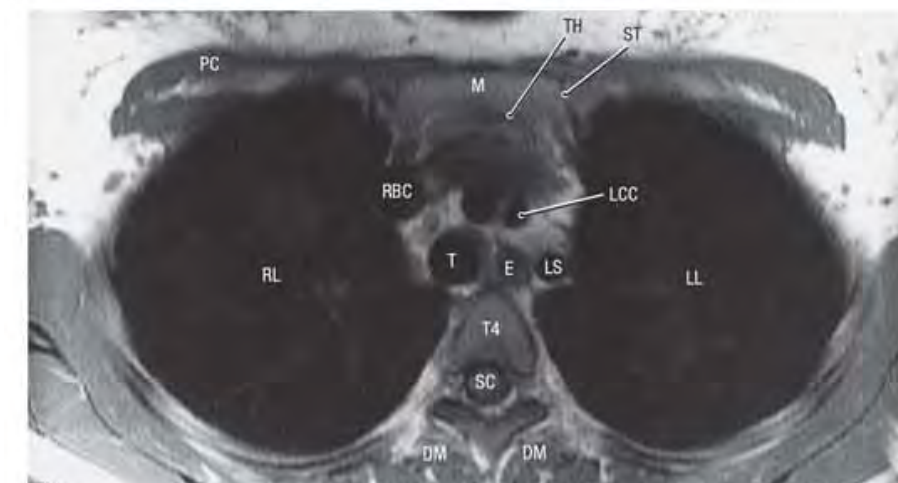
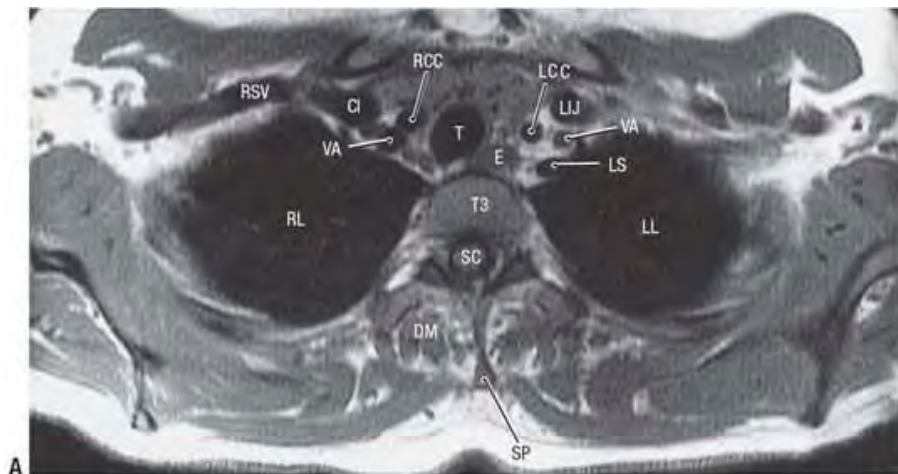


## 1.81 Transverse (axial) MRIs of the thorax (A–F)

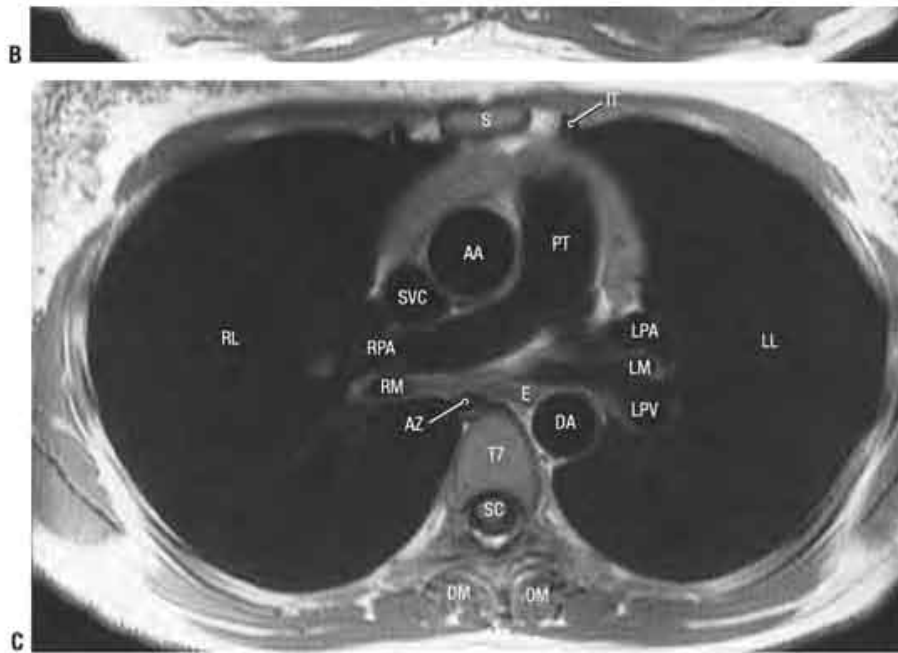
Part of "Chapter 1 - Thorax "

P.89

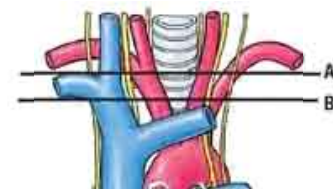
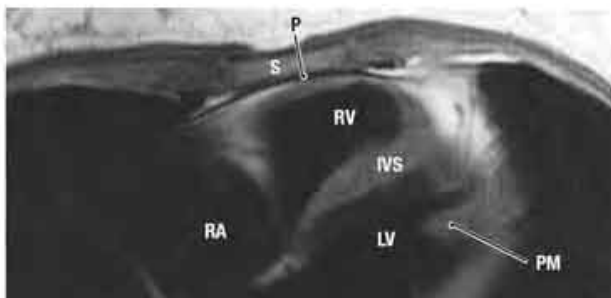
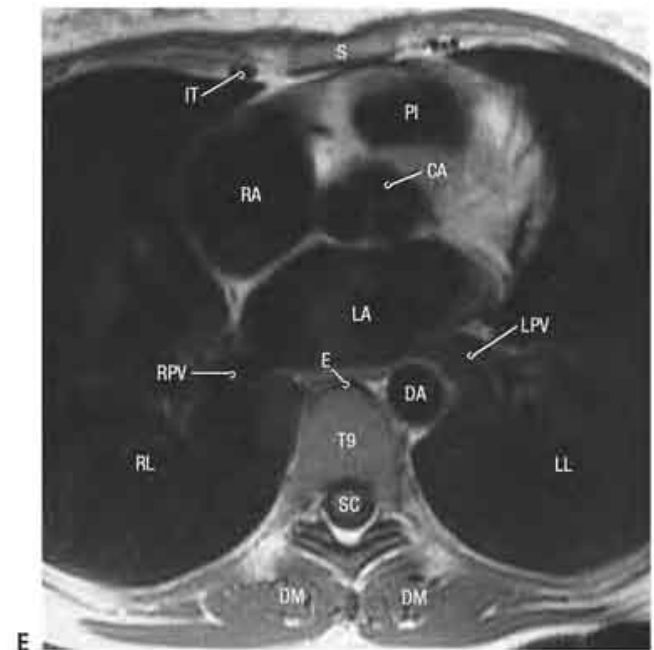
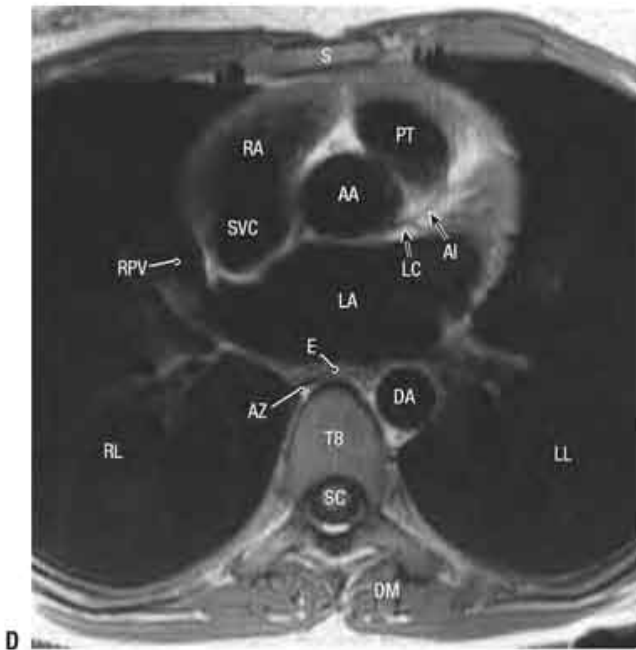
P.90

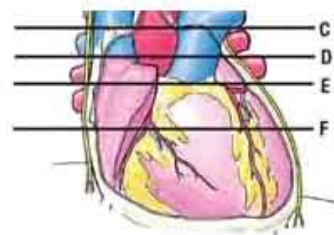
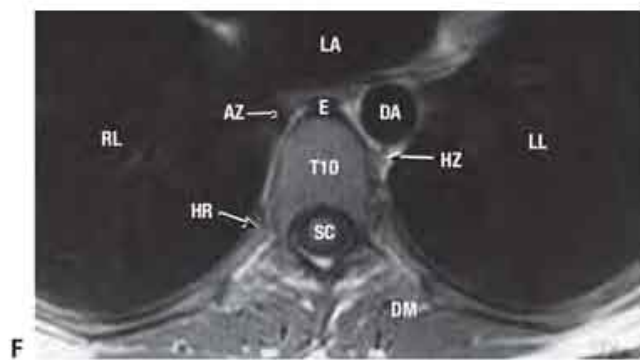


AA	Ascending aorta
AI	Anterior interventricular artery
AZ	Azygos vein
CA	Cusp of aortic valve
CI	Confluence of internal jugular vein
DA	Descending aorta
DM	Deep back muscles
E	Esophagus
HR	Head of rib
HZ	Hemiazygos vein
IT	Internal thoracic vessels
IVS	Interventricular septum
LA	Left atrium
LC	Left coronary artery
LCC	Left common carotid artery
LJ	Left internal jugular vein
LL	Left lung
LM	Left main bronchus
LPA	Left pulmonary artery
LPV	Left pulmonary vein
LS	Left subclavian artery
LV	Left vertebral artery
M	Manubrium
P	Pericardium
PC	Pectoralis major
PI	Pulmonary infundibulum
PM	Papillary muscle
PT	Pulmonary trunk
RA	Right atrium



RL	Right lung
RBC	Right brachiocephalic vein
RCC	Right common carotid artery
RL	Right lung
RM	Right middle lobar bronchus
RPA	Right pulmonary artery
RPV	Right pulmonary vein
RSV	Right subclavian vein
RV	Right vertebral artery
S	Sternum
SC	Spinal cord
SP	Spinous process
ST	Sternoclavicular joint
SVC	Superior vena cava
T3-T10	Vertebral body
T	Trachea
TH	Thymus
VA	Vertebral artery







Authors: Agur, Anne M.R.; Dalley, Arthur F.

Title: *Grant's Atlas of Anatomy, 12th Edition*

Copyright ©2009 Lippincott Williams & Wilkins

> Table of Contents > Chapter 1 - Thorax > 1.82 Coronal MRIs of the thorax

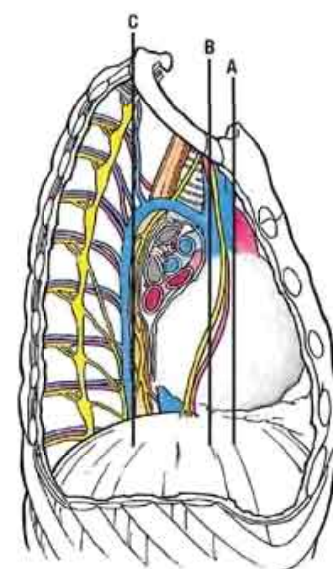
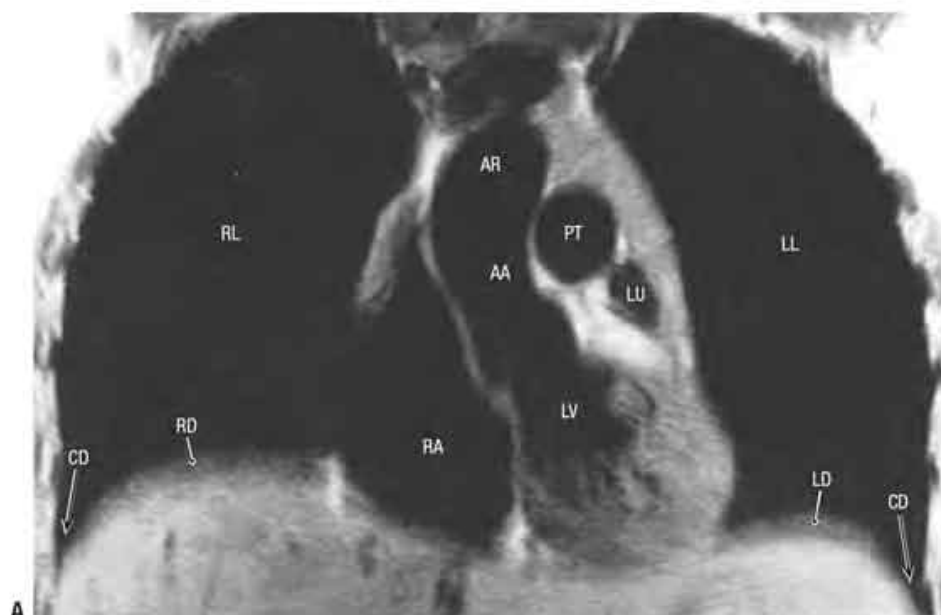
---

## 1.82 Coronal MRIs of the thorax

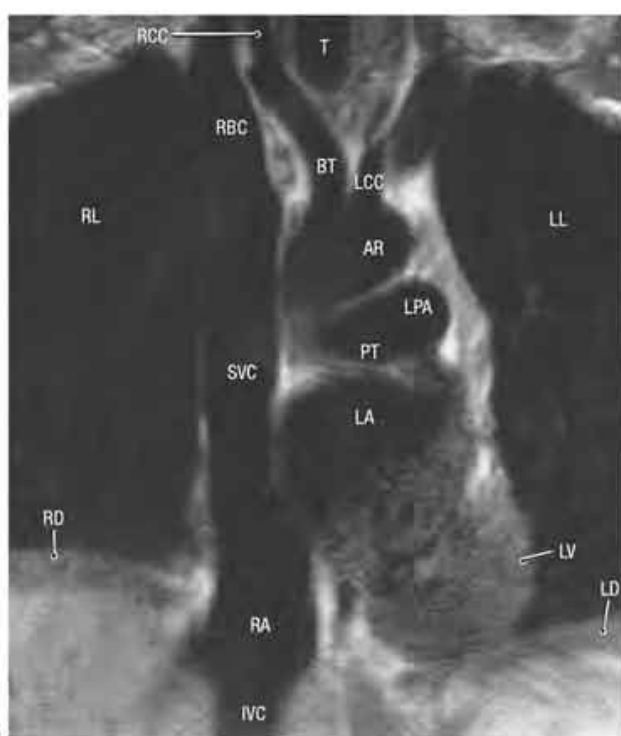
*Part of* "Chapter 1 - Thorax "

---

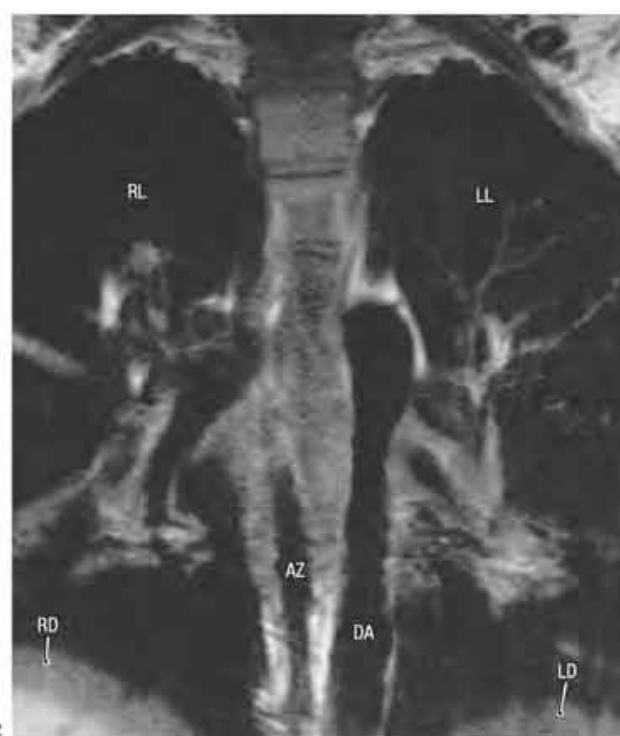P.91



A



B



C

AA	Ascending aorta	IVC	Inferior vena cava	LU	Left auricle	RD	Right dome of diaphragm
AR	Arch of aorta	LA	Left atrium	LV	Left ventricle	RL	Right lung
AZ	Azygos vein	LCC	Left common carotid artery	PT	Pulmonary trunk	RV	Right ventricle
BT	Brachiocephalic trunk	LD	Left dome of diaphragm	RA	Right atrium	SVC	Superior vena cava
CD	Costodiaphragmatic recess	LL	Left lung	RBC	Right brachiocephalic vein	T	Trachea
DA	Descending aorta	LPA	Left pulmonary artery	RCC	Right common carotid artery	V	Vertebral body

Authors: Agur, Anne M.R.; Dalley, Arthur F.

Title: *Grant's Atlas of Anatomy, 12th Edition*

Copyright ©2009 Lippincott Williams & Wilkins

> Table of Contents > Chapter 1 - Thorax > 1.83 Sagittal MRIs of the thorax

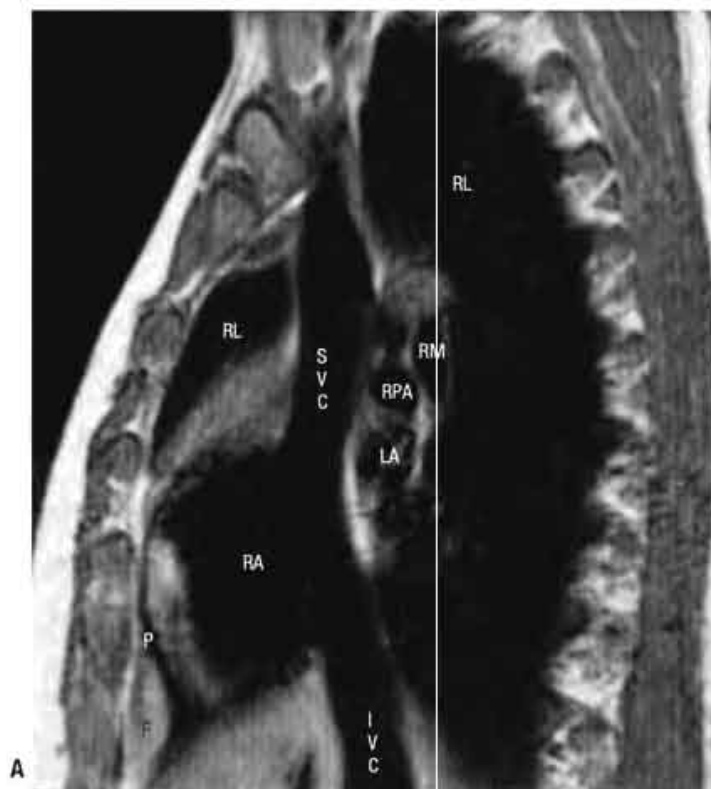
---

## 1.83 Sagittal MRIs of the thorax

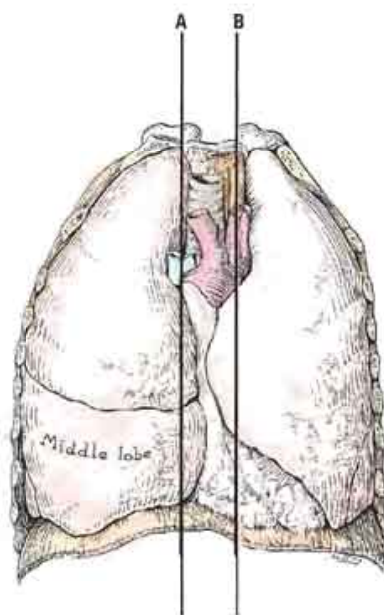
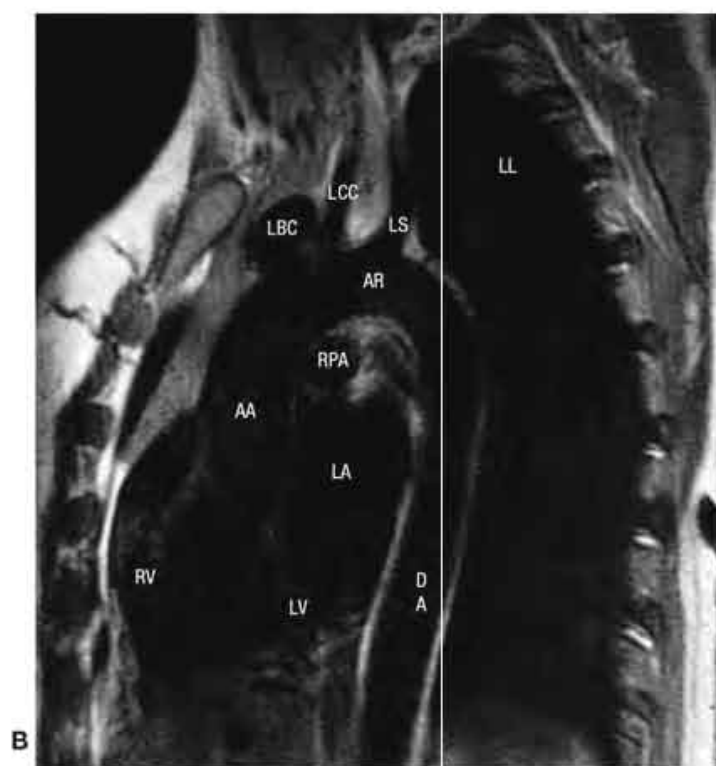
*Part of* "Chapter 1 - Thorax "

---

P.92



AR	Arch of aorta
AA	Ascending aorta
DA	Descending aorta
F	Fat
IVC	Inferior vena cava
LA	Left atrium
LBC	Left brachiocephalic vein
LCC	Left common carotid artery
LL	Left lung
LS	Left subclavian artery
LV	Left ventricle
P	Pericardium
RA	Right atrium
RL	Right lung
RM	Right main bronchus
RPA	Right pulmonary artery
RV	Right ventricle
SVC	Superior vena cava



Authors: Agur, Anne M.R.; Dalley, Arthur F.

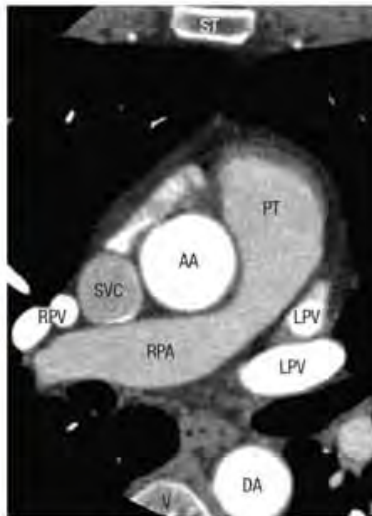
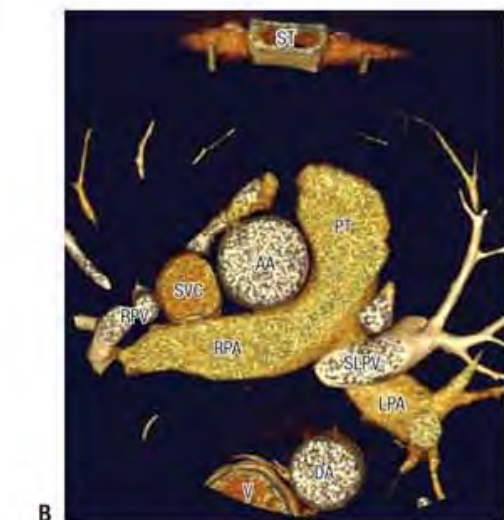
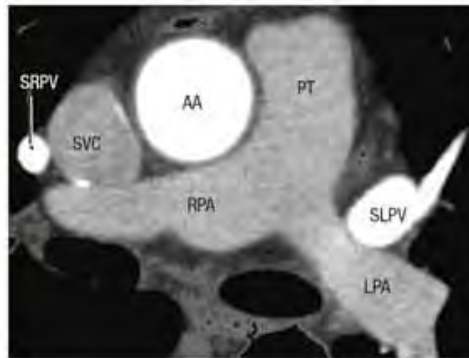
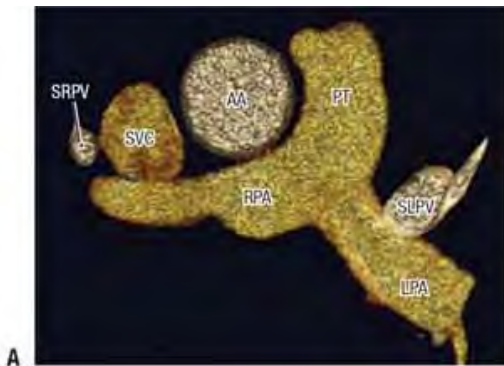
Title: *Grant's Atlas of Anatomy, 12th Edition*

Copyright ©2009 Lippincott Williams & Wilkins

> Table of Contents > Chapter 1 - Thorax > 1.84 Transverse or horizontal (axial) 3-D volume reconstructions (on left side of page) and CT angiograms of the thorax (A–F)

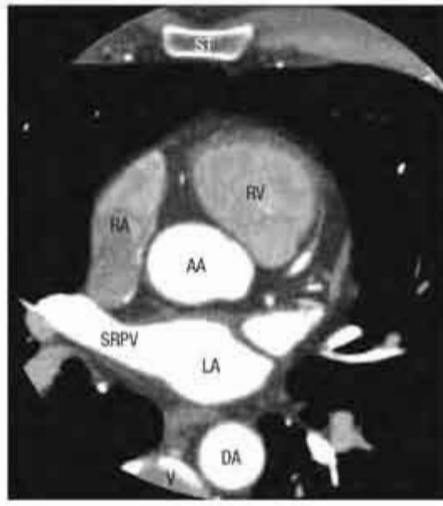
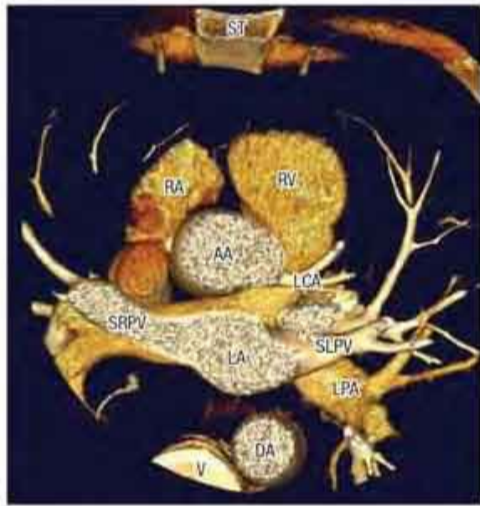
## 1.84 Transverse or horizontal (axial) 3-D volume reconstructions (on left side of page) and CT angiograms of the thorax (A–F)

Part of "Chapter 1 - Thorax "

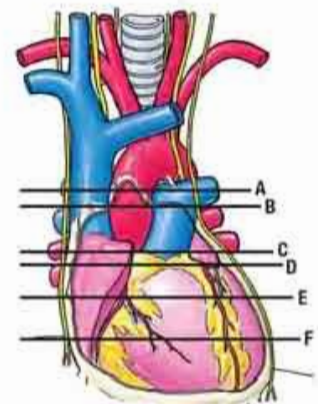
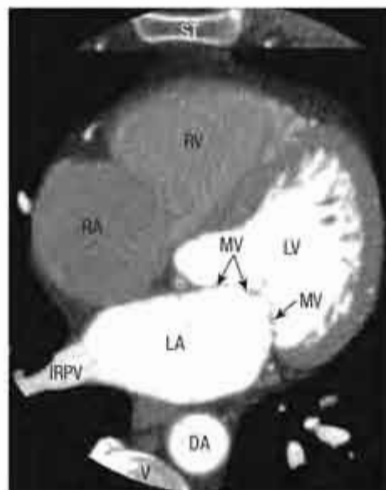
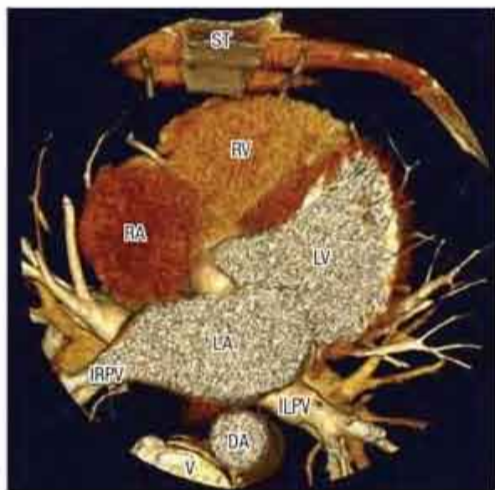
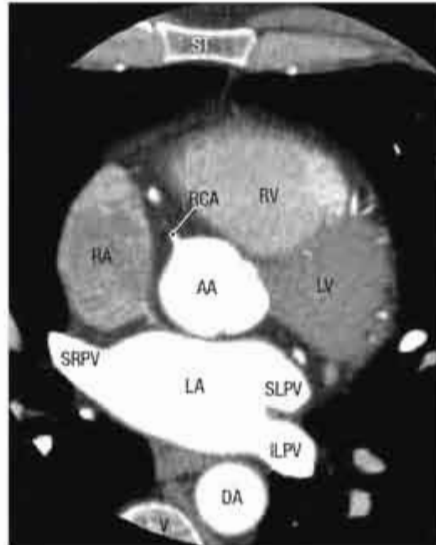
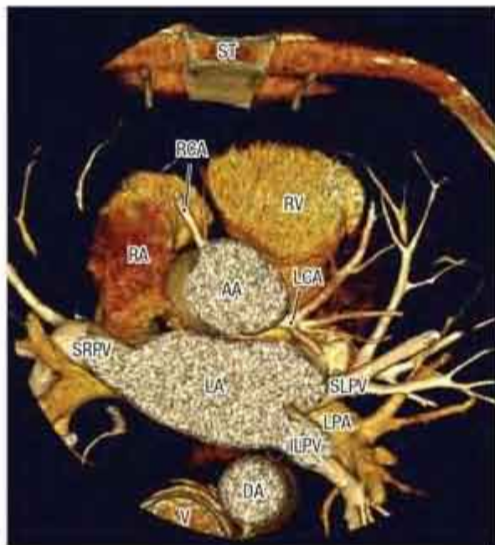


AA	Ascending aorta
AZ	Azygos vein
DA	Descending aorta
E	Esophagus
ILPV	Inferior left pulmonary vein
IRPV	Inferior right pulmonary vein
IS	Interventricular septum
LA	Left atrium
LCA	Left coronary artery
LPA	Left pulmonary artery
LPV	Left pulmonary vein
LV	Left ventricle
MV	Mitral valve
PT	Pulmonary trunk
RA	Right atrium
RCA	Right coronary artery





RPA	Right pulmonary artery
RPV	Right pulmonary vein
RV	Right ventricle
SLPV	Superior left pulmonary vein
SRPV	Superior right pulmonary vein
SVC	Superior vena cava
V	Vertebra
ST	Sternum



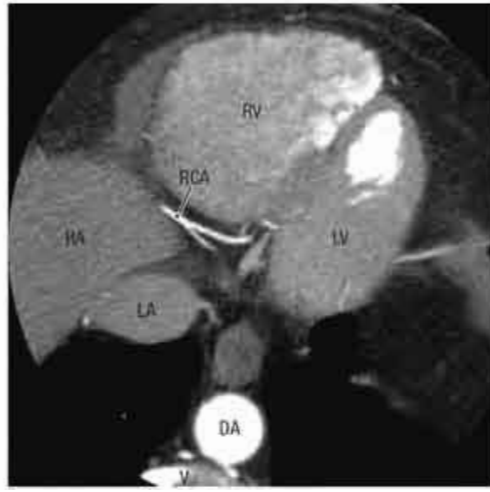
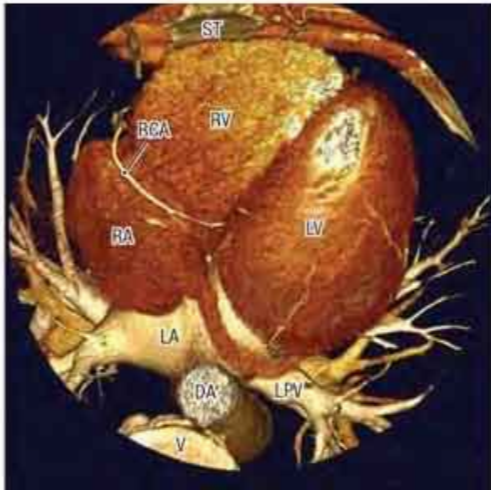
C

D

E

F





F

Authors: Agur, Anne M.R.; Dalley, Arthur F.

Title: *Grant's Atlas of Anatomy, 12th Edition*

Copyright ©2009 Lippincott Williams & Wilkins

> Table of Contents > Chapter 2 - Abdomen > Chapter 2 - Abdomen

---

# Chapter 2

## Abdomen

---

P.96

- 2.1 Abdominal and thoracic viscera in situ
- 2.2 Surface anatomy
- 2.3 Anterolateral abdominal wall, superficial dissection
- 2.4 Arteries and nerves of anterolateral abdominal wall
- 2.5 Anterior abdominal wall
- 2.6 Structure of the anterolateral abdominal wall
- 2.7 Inguinal region of male-I
- 2.8 Inguinal region of maleâ€”II
- 2.9 Inguinal region of maleâ€”III
- 2.10 Inguinal region of maleâ€”IV
- 2.11 Inguinal canal of female
- 2.12 Inguinal canal, spermatic cord, and testis
- 2.13 Descent of gonads
- 2.15 Spermatic cord, testis, and epididymis
- 2.16 Blood supply and lymphatic drainage of testis

- 2.17 Posterior aspect of the anterolateral abdominal wall
- 2.18 Abdominal contents and peritoneum
- 2.19 Peritoneal formations and bare areas
- 2.20 Subdivisions of peritoneal cavity
- 2.21 Posterior wall of peritoneal cavity
- 2.22 Transverse sections through greater sac and omental bursa.
- 2.23 Stomach and omenta
- 2.24 Posterior relationships of omental bursa (lesser sac)
- 2.25 Omental bursa (lesser sac), opened
- 2.26 Posterior wall of omental bursa
- 2.27 Digestive system
- 2.28 Stomach
- 2.29 Celiac artery
- 2.30 Spleen
- 2.31 Celiac arteriogram
- 2.32 Radiographs of esophagus, stomach, duodenum (barium swallow)
- 2.33 Parts and relationships of pancreas and duodenum
- 2.34 Blood supply to the pancreas, duodenum, and spleen
- 2.35 Intestines in situ, interior of small intestine
- 2.36 Sigmoid mesocolon and mesentery of small intestine, interior of transverse colon
- 2.37 Barium enema and colonoscopy of colon
- 2.38 Ileocecal region and appendix
- 2.39 Superior mesenteric artery and arterial arcades
- 2.40 Superior mesenteric arteriograms

- 2.41 Inferior mesenteric artery
- 2.42 Inferior mesenteric arteriogram
- 2.43 Peritoneum of posterior abdominal cavity
- 2.44 Posterior abdominal cavity with peritoneum removed
- 2.45 Diaphragmatic (anterior and superior) surface of liver
- 2.46 Visceral (posteroinferior) surface of liver
- 2.47 Liver and its posterior relations, schematic illustration
- 2.48 Hepatic veins
- 2.49 Hepatic segmentation
- 2.50 Flow of blood and bile in the liver
- 2.51 Exposure of the portal triad
- 2.52 Gallbladder and structures of porta hepatis
- 2.53 Vessels in porta hepatis
- 2.54 Bile and pancreatic ducts
- 2.55 Development and variability of the pancreatic ducts
- 2.56 Radiographs of biliary passages
- 2.57 Variations in hepatic and cystic arteries
- 2.58 Endoscopic retrograde cholangiography of gallbladder and biliary passages
- 2.59 Variations of cystic and hepatic ducts and gallbladder
- 2.60 Portal venous system
- 2.61 Portacaval system
- 2.62 Posterior abdominal viscera and their anterior relations
- 2.63 Viscera and vessels of posterior abdominal wall
- 2.64 Exposure of the left kidney and suprarenal gland

- 2.65 Kidneys and suprarenal glands
- 2.66 Structure of kidney
- 2.67 Segments of the kidneys
- 2.68 Anomalies of kidney and ureter
- 2.69 Exposure of kidney
- 2.70 Exposure of kidneyâ€™ II
- 2.71 Exposure of kidneyâ€™ III and renal fascia
- 2.72 Lumbar plexus and vertebral attachment of diaphragm
- 2.73 Nerves of the lumbar plexus
- 2.74 Diaphragm
- 2.75 Abdominal aorta and inferior vena cava and their branches
- 2.76 Abdominopelvic nerve plexuses and ganglia
- 2.77 Overview of autonomic nervous system
- 2.78 Origin and distribution of presynaptic and postsynaptic sympathetic and parasympathetic fibers, and the ganglia involved in supplying abdominal viscera
- 2.79 Abdominal nerve plexuses and ganglia
- 2.80 Surface projections of visceral pain
- 2.81 Vagus nerves in abdomen
- 2.82 Lymphatic drainage of suprarenal glands, kidneys, and ureters
- 2.83 Lumbar lymph nodes, sympathetic trunk, nerves, and ganglia
- 2.84 Lymphatic drainage
- 2.85 Transverse or horizontal (axial) MRIs of the abdomen
- 2.86 Coronal MRIs of the abdomen
- 2.87 Sagittal MRIs of the abdomen

- 2.88 Ultrasound scans and MR angiogram of the abdomen



Authors: Agur, Anne M.R.; Dalley, Arthur F.  
Title: *Grant's Atlas of Anatomy, 12th Edition*  
Copyright ©2009 Lippincott Williams & Wilkins

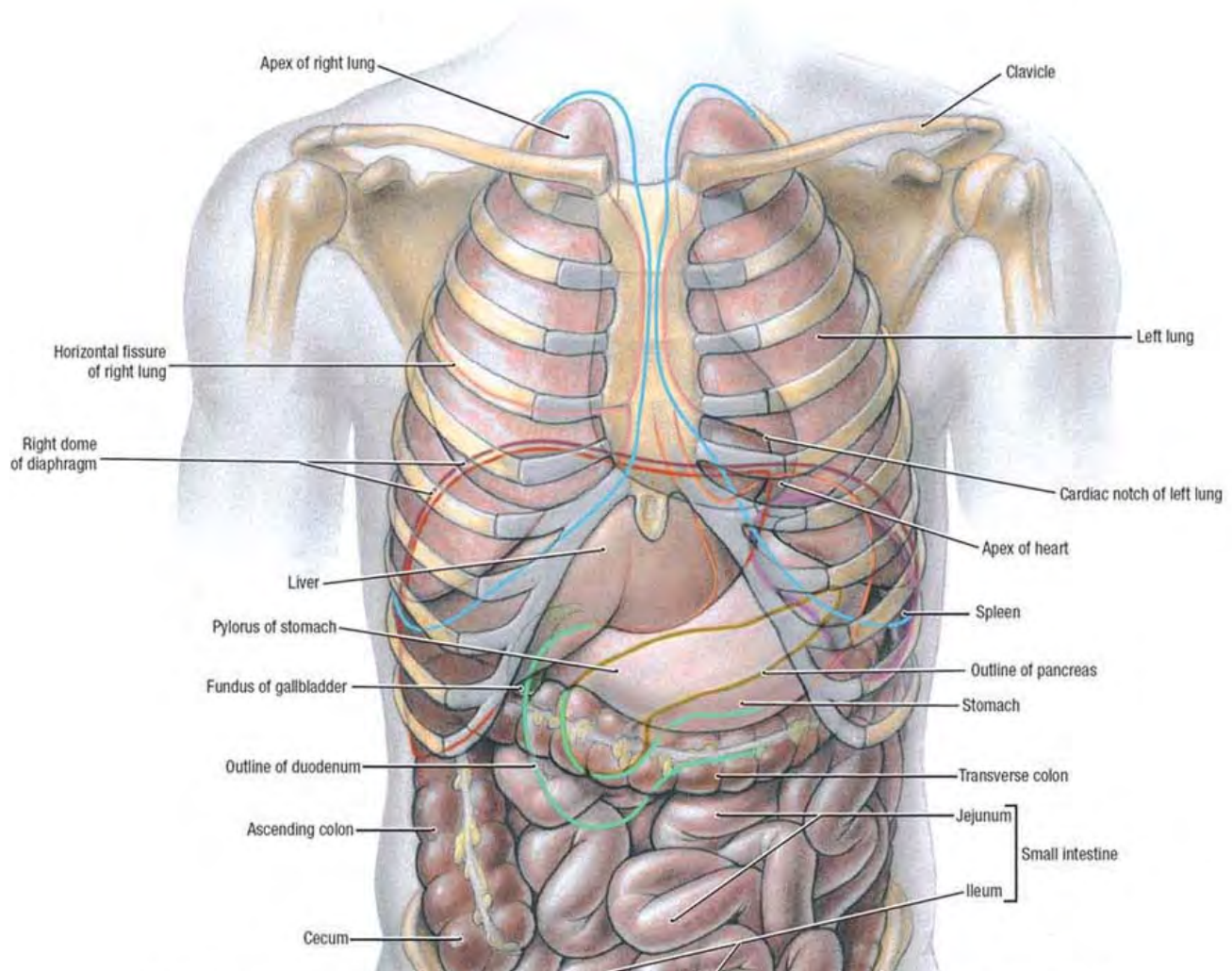
> Table of Contents > Chapter 2 - Abdomen > 2.1 Abdominal and thoracic viscera in situ

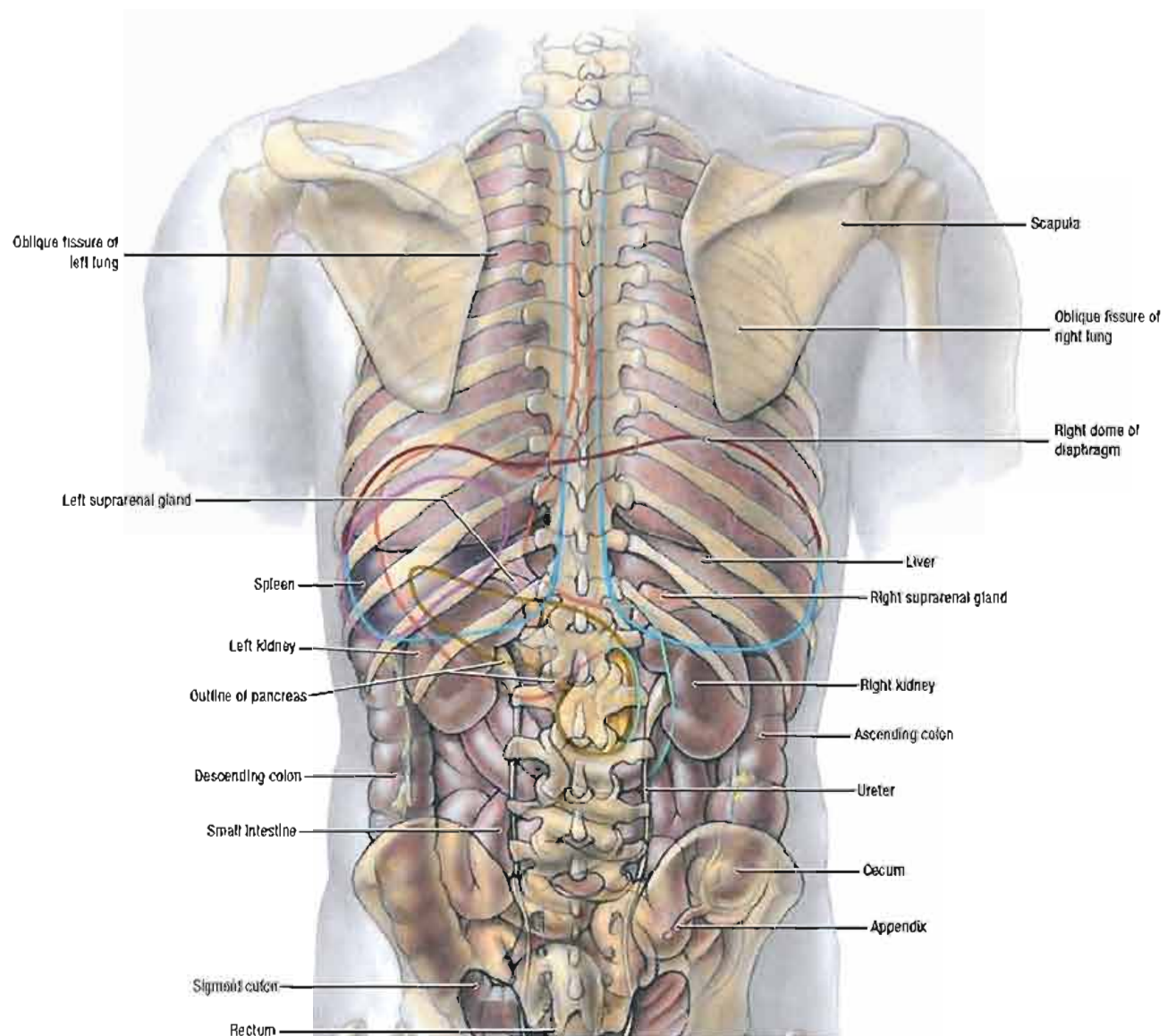
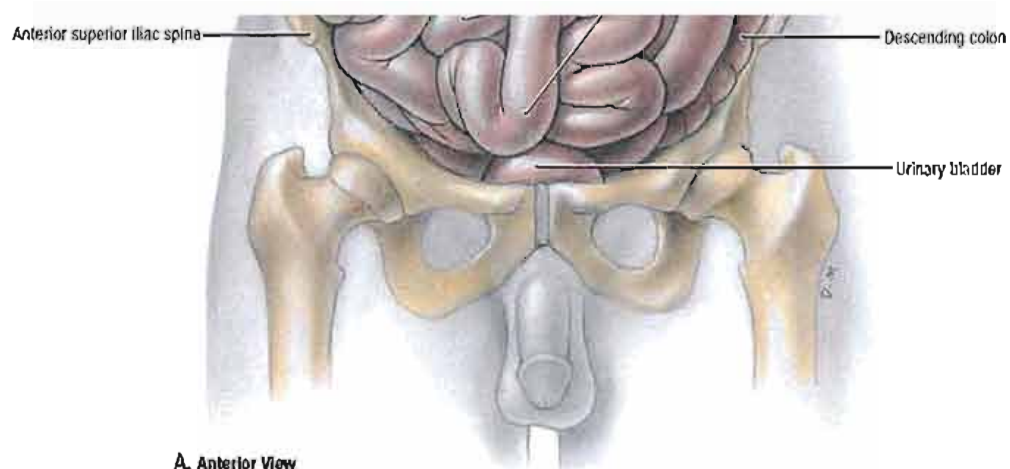
## 2.1 Abdominal and thoracic viscera in situ

Part of "Chapter 2 - Abdomen "

P.97

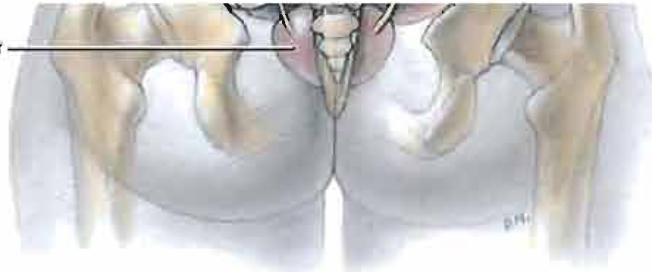
P.98





Urinary bladder

B. Posterior View



**KEY for A and B:**

- Esophagus/stomach
- Parietal pleura
- Diaphragm
- Pancreas
- Duodenum
- Spleen

Authors: Agur, Anne M.R.; Dalley, Arthur F.

Title: *Grant's Atlas of Anatomy, 12th Edition*

Copyright ©2009 Lippincott Williams & Wilkins

> Table of Contents > Chapter 2 - Abdomen > 2.2 Surface anatomy

---

## 2.2 Surface anatomy

*Part of* "Chapter 2 - Abdomen "

### A. Surface features.

- The umbilicus is where the umbilical cord entered into the fetus and indicates the level of the T10 dermatome, typically at the level of the IV disc between the L3 and L4 vertebrae.
- The linea alba is a subcutaneous fibrous band extending from the xiphoid process to the pubic symphysis that is demarcated by a midline vertical skin groove as far inferiorly as the umbilicus.
- Curved skin grooves, the linea semilunaris, demarcate the lateral borders of the rectus abdominis muscle and rectus sheath.
- Three transverse skin grooves overlie the tendinous intersections of the rectus abdominis muscle.
- The site of the inguinal ligament is indicated by a skin crease, the inguinal groove, just inferior and parallel to the ligament, marking the division between the anterolateral abdominal wall and the thigh.

---

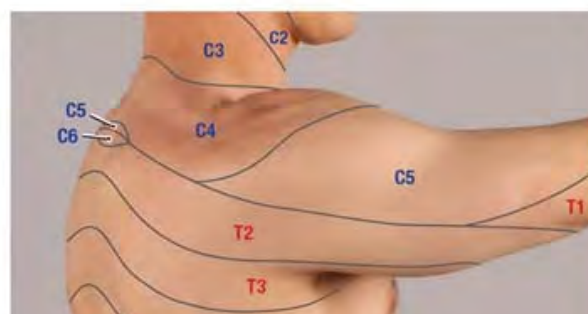
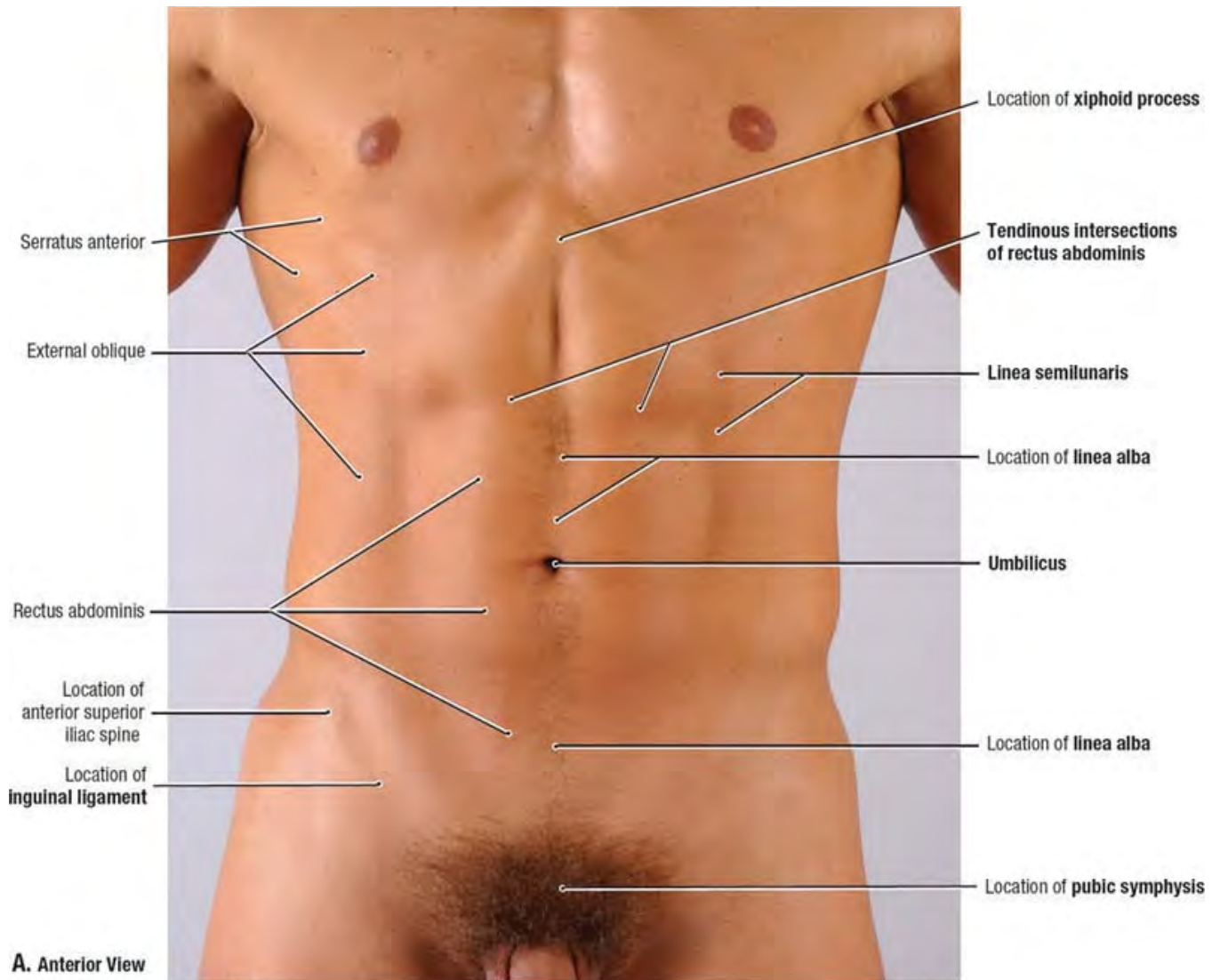
P.99

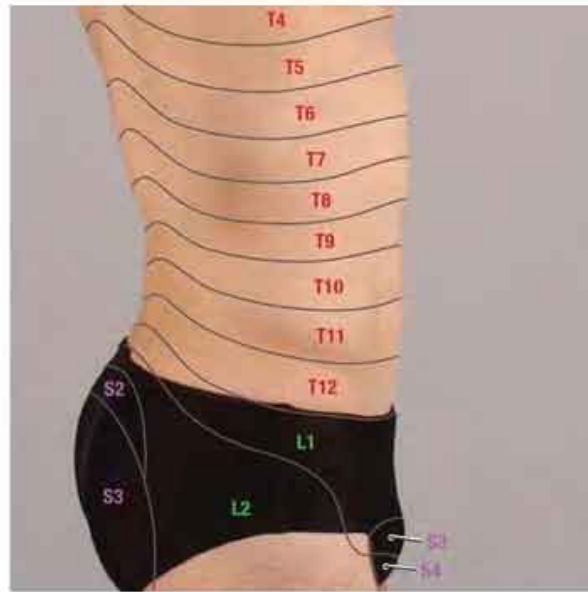
B. Dermatomes. The thoracoabdominal (T7–T11) nerves run between the external and internal oblique muscles to supply sensory innervation to the overlying skin. The T10 nerve supplies the region of the umbilicus. The subcostal nerve (T12) runs along the inferior border of the 12th rib to supply the skin over the anterior superior iliac spine and



hip. The iliohypogastric nerve (L1) innervates the skin over the iliac crest and hypogastric region and the ilioinguinal nerve (L1), the skin of the medial aspect of the thigh, the scrotum or labium majus and mons pubis.

P.100





B. Lateral View



Authors: Agur, Anne M.R.; Dalley, Arthur F.

Title: *Grant's Atlas of Anatomy, 12th Edition*

Copyright ©2009 Lippincott Williams & Wilkins

> Table of Contents > Chapter 2 - Abdomen > 2.3 Anterolateral abdominal wall, superficial dissection

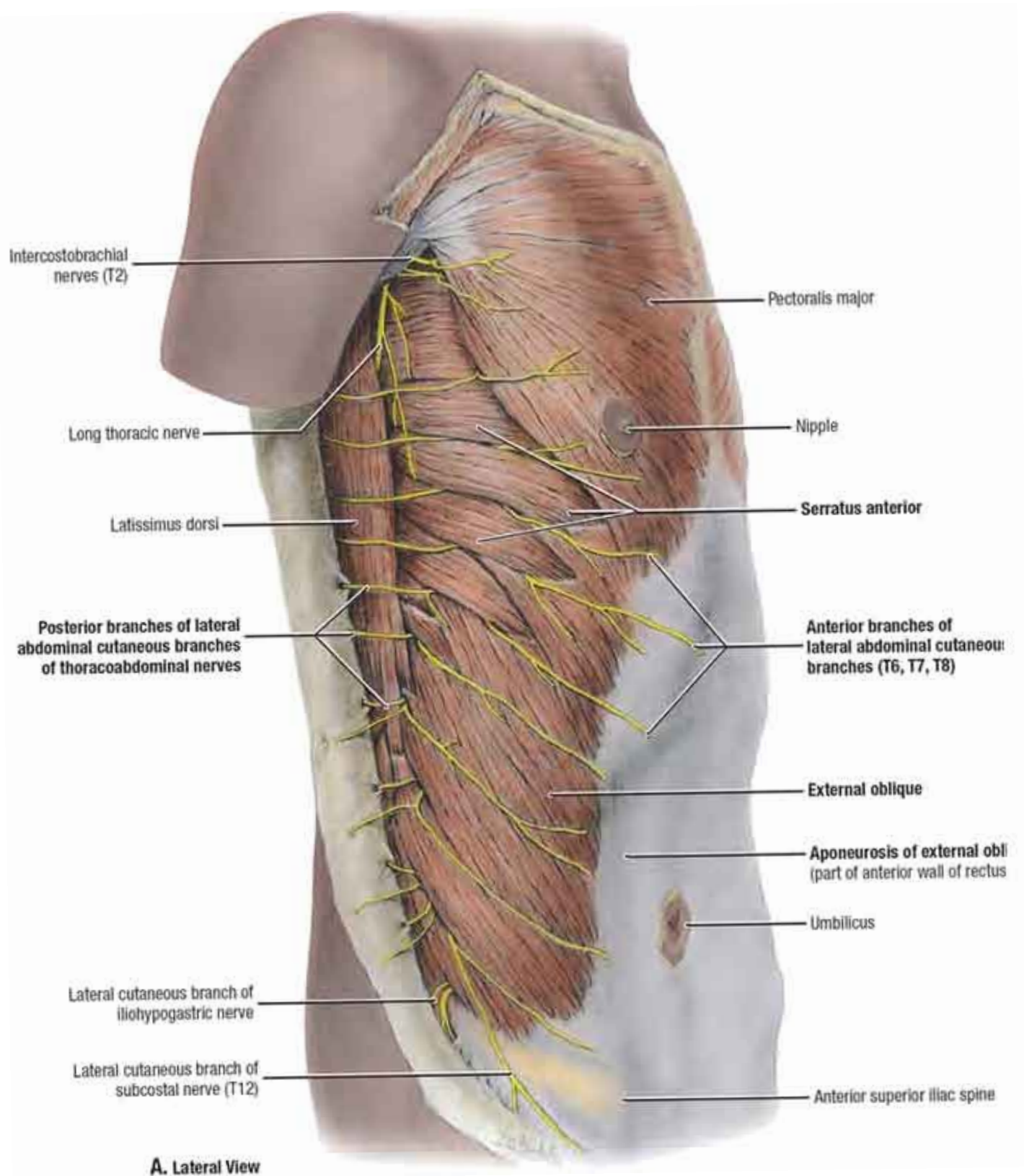
---

## 2.3 Anterolateral abdominal wall, superficial dissection

*Part of* "Chapter 2 - Abdomen "

The muscular portion of the external oblique muscle interdigitates with slips of the serratus anterior muscle, and the aponeurotic portion contributes to the anterior wall of the rectus sheath. The anterior and posterior branches of the lateral abdominal cutaneous branches of thoracoabdominal nerves course superficially in the subcutaneous tissue.

- Umbilical hernias are usually small protrusions of extraperitoneal fat and/or peritoneum and omentum and sometimes bowel. They result from increased intraabdominal pressure in the presence of weakness or incomplete closure of the anterior abdominal wall after ligation of the umbilical cord at birth, or may be acquired later, most commonly in women and obese people.
- The lines along which the fibers of the abdominal aponeurosis interlace (see Fig. 2.6A, B & D ) are also potential sites of herniation. These gaps may be congenital, the result of the stresses of obesity and aging, or the consequence of surgical or traumatic wounds.



Authors: Agur, Anne M.R.; Dalley, Arthur F.

Title: *Grant's Atlas of Anatomy, 12th Edition*

Copyright ©2009 Lippincott Williams & Wilkins

> Table of Contents > Chapter 2 - Abdomen > 2.4 Arteries and nerves of anterolateral abdominal wall

---

## 2.4 Arteries and nerves of anterolateral abdominal wall

*Part of* "Chapter 2 - Abdomen "

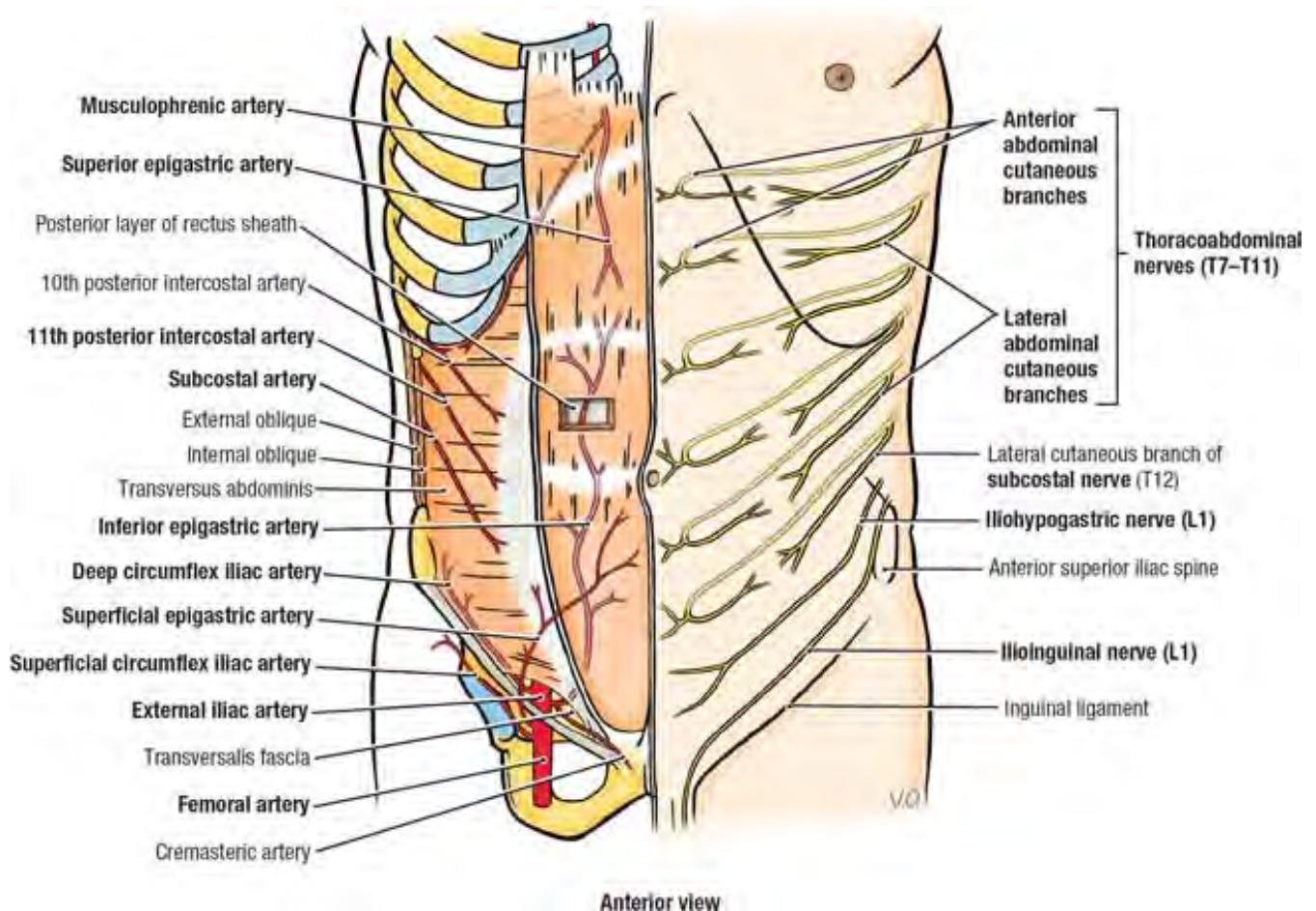
The skin and muscles of the anterolateral abdominal wall are supplied mainly by the:

- Thoracoabdominal nerves: distal, abdominal parts of the anterior rami of the inferior six thoracic spinal nerves (T7–T11), which have muscular branches and anterior and lateral abdominal cutaneous branches. The anterior abdominal cutaneous branches pierce the rectus sheath a short distance from the median plane, after the rectus abdominis muscle has been supplied. Spinal nerves T7–T9 supply the skin superior to the umbilicus; T10 innervates the skin around the umbilicus.
- Subcostal nerve: large anterior ramus of spinal nerve T12.
- Iliohypogastric and ilioinguinal nerves: terminal branches of the anterior ramus of spinal nerve L1.
- Spinal nerve T11, plus the cutaneous branches of the subcostal (T12), iliohypogastric, and ilioinguinal (L1) nerves: supply the skin inferior to the umbilicus.

The blood vessels of the anterolateral abdominal wall are the:

- Superior epigastric vessels and branches of the musculophrenic vessels from the internal thoracic vessels.
- Inferior epigastric and deep circumflex iliac vessels from the external iliac vessels.
- Superficial circumflex iliac and superficial epigastric vessels from the femoral artery and great saphenous vein.
- Posterior intercostal vessels in the 11th intercostal space and anterior branches of subcostal vessels.

P.102



Authors: Agur, Anne M.R.; Dalley, Arthur F.

Title: *Grant's Atlas of Anatomy, 12th Edition*

Copyright ©2009 Lippincott Williams & Wilkins

> Table of Contents > Chapter 2 - Abdomen > 2.5 Anterior abdominal wall

---

## 2.5 Anterior abdominal wall

*Part of* "Chapter 2 - Abdomen "

A. Superficial dissection demonstrating the relationship of the cutaneous nerves and superficial vessels to the musculoaponeurotic structures. The anterior wall of the left rectus sheath is reflected, revealing the rectus abdominis muscle, segmented by tendinous intersections.

- After the T7 to T12 spinal nerves supply the muscles, their anterior abdominal cutaneous branches emerge from the rectus abdominis muscle and pierce the anterior wall of its sheath.
- The three superficial inguinal branches of the femoral artery (superficial circumflex iliac artery, superficial epigastric artery, and external pudendal artery) and the great saphenous vein lie in the fatty layer of subcutaneous tissue.
- The fibers of the external oblique aponeurosis separate into medial and lateral crura which, with the intercrural fibers that unite them, form the superficial inguinal ring. The spermatic cord of the male (shown here), or round ligament of the female, exit the inguinal canal through the superficial inguinal ring along with the ilioinguinal nerve.

---

P.103

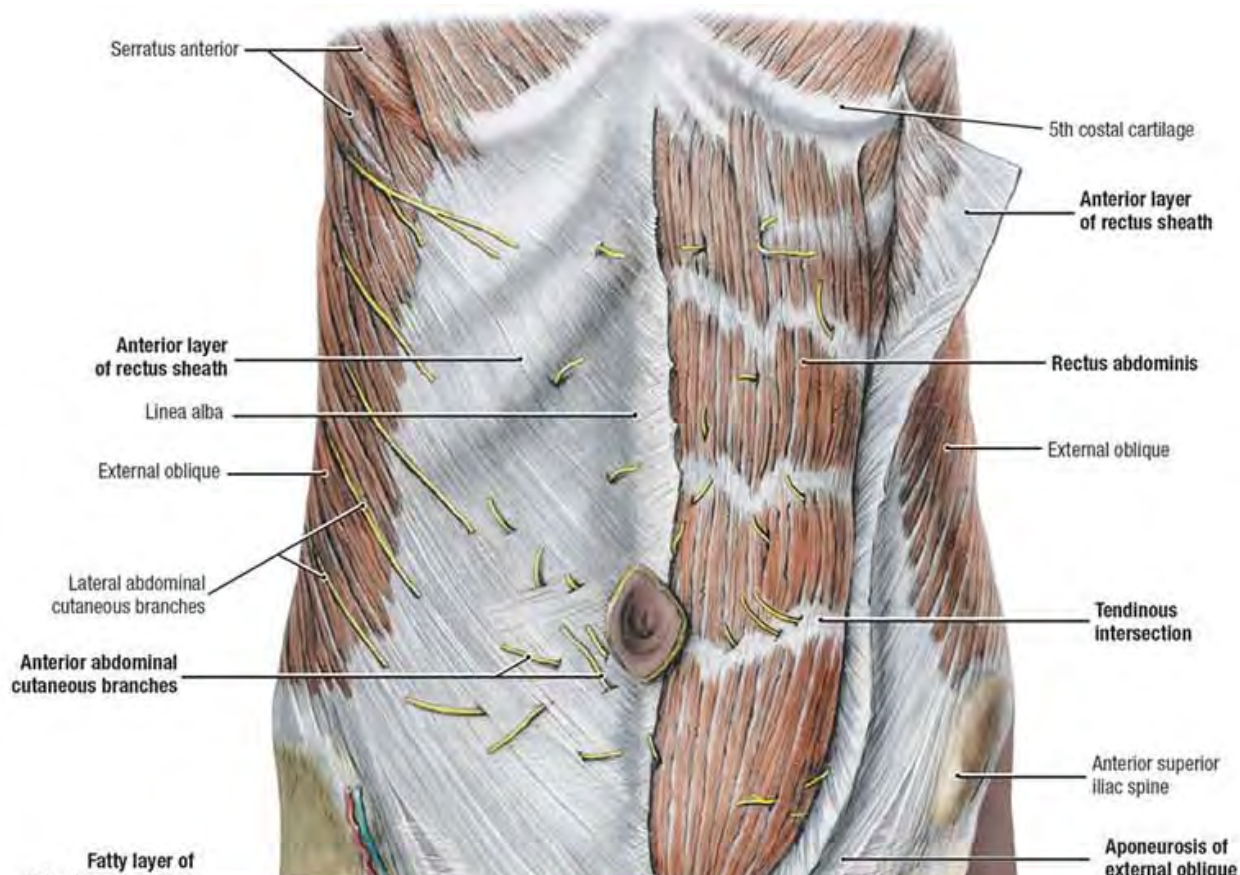
B. Deep dissection. On the right side of the specimen, most of the external oblique muscle is excised. On the left, the internal oblique muscle is divided and the rectus abdominis muscle is excised, revealing the posterior wall of the rectus sheath.



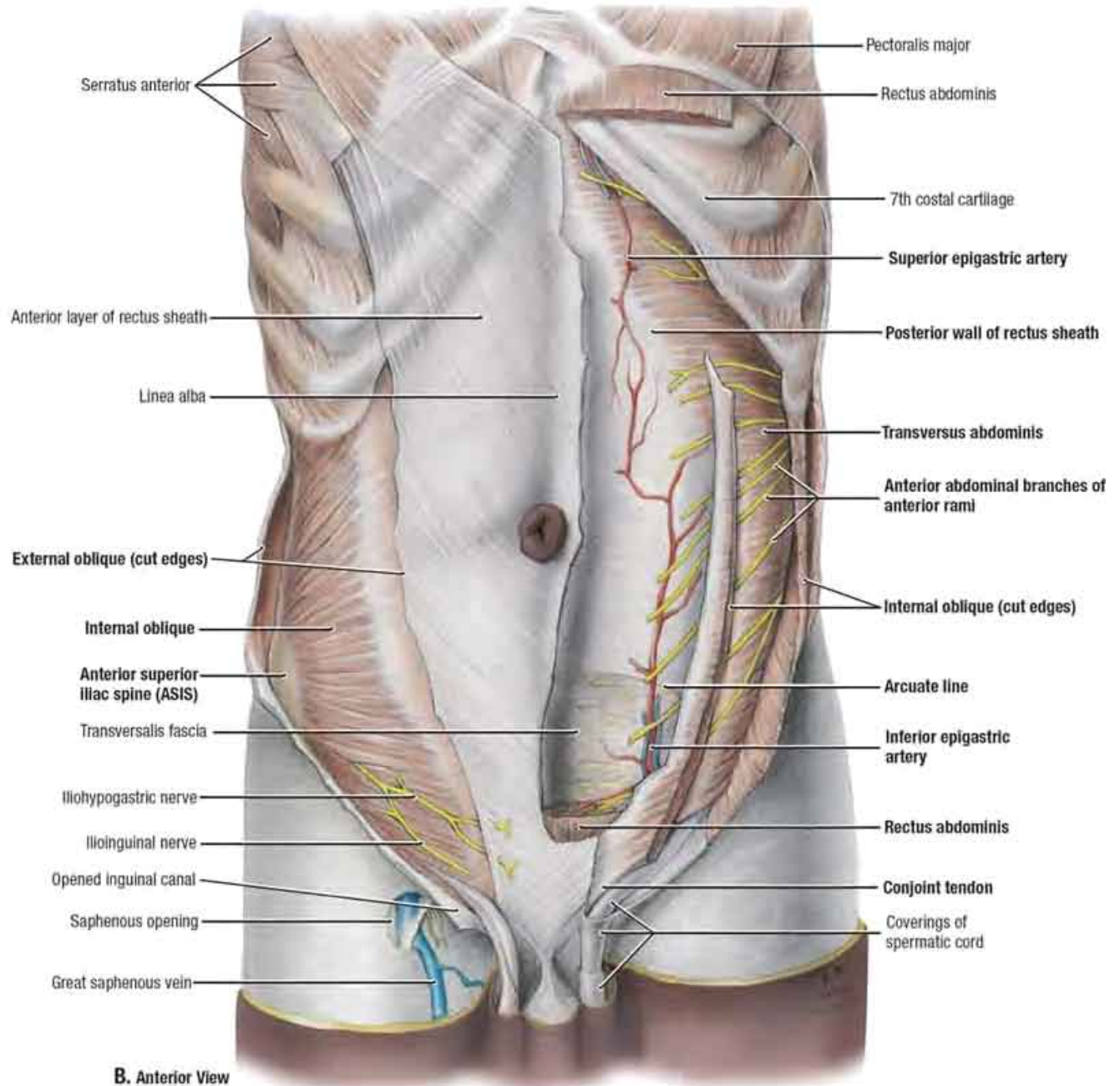
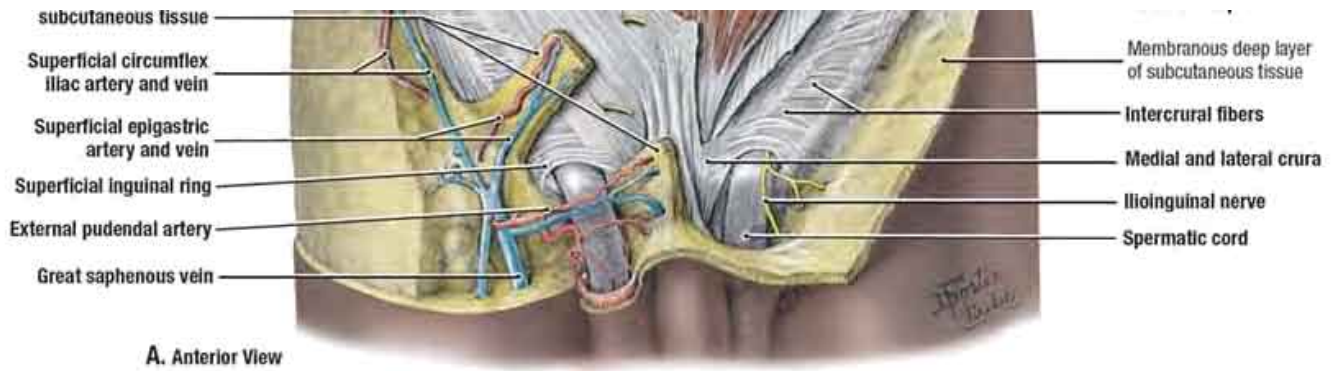
- The fibers of the internal oblique muscle run horizontally at the level of the anterior superior iliac spine (ASIS), obliquely upward superior to the ASIS, and obliquely downward inferior to the ASIS.
- The arcuate line is at the level of the ASIS; inferior to the line, only transversalis fascia lies posterior to the rectus abdominis muscle.
- Initially, the anterior abdominal branches of the anterior rami course between the internal oblique and transversus abdominis muscles.

- The anastomosis between the superior and inferior epigastric arteries indirectly unites the subclavian artery of the upper limb to the external iliac arteries of the lower limb. The anastomosis can become functionally patent in response to slowly developing occlusion of the aorta.

P.104







External oblique (A)

External surfaces of 5th–12th ribs

Linea alba, pubic tubercle, and anterior half of iliac crest

Thoracoabdominal nerves (T7–T11) and subcostal nerve

Compresses and supports abdominal viscera<sup>b</sup> ; flexes and rotates trunk

Internal oblique (B)

Thoracolumbar fascia, anterior two thirds of iliac crest

Inferior borders of 10th–12th ribs, linea alba, and pubis via conjoint tendon

Transversus abdominis (C)

Internal surfaces of 7th–12th costal cartilages, thoraco-lumbar fascia, iliac crest, and lateral third of inguinal ligament

Linea alba with aponeurosis of internal oblique, pubic crest, and pecten pubis via conjoint tendon

Thoracoabdominal (T7–T11), subcostal and first lumbar nerves

Compresses and supports abdomiabdnominal viscera<sup>b</sup>

Rectus abdominis (D)

Pubic symphysis and pubic crest

Xiphoid process and 5th–7th costal cartilages

Thoracoabdominal nerves and anterior rami of inferior thoracic nerves

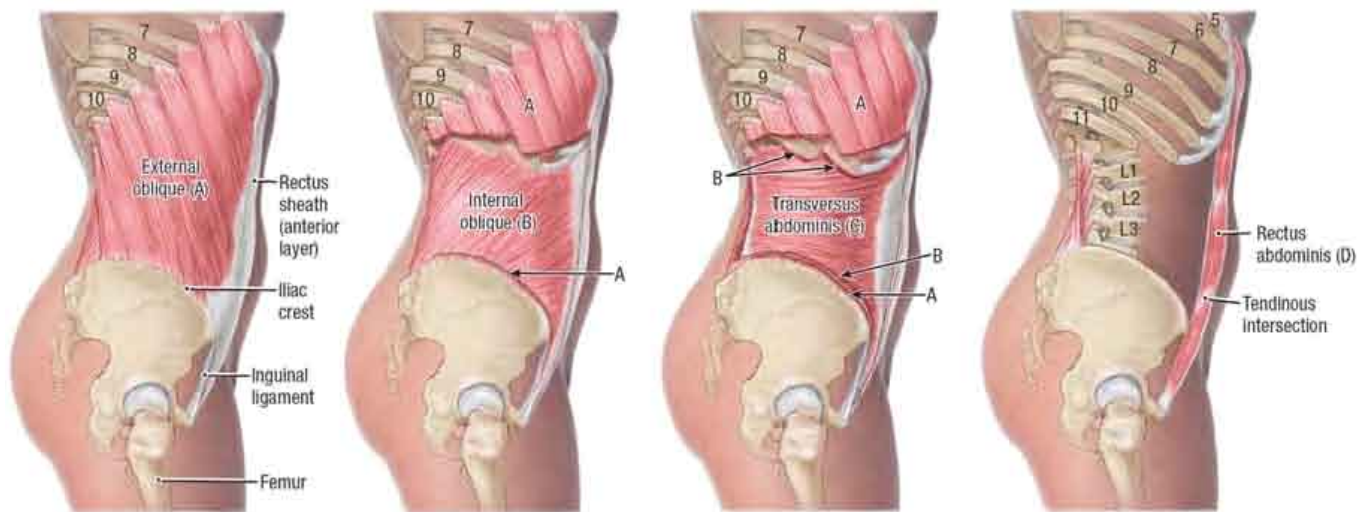
Flexes trunk (lumbar vertebrae) and compresses abdominal viscera<sup>b</sup> ; stabilizes and controls tilt of pelvis (antilordosis)

<sup>a</sup> Approximately 80% of people have a pyramidal muscle, which is located in the rectus sheath anterior to the most inferior part of the rectus abdominis. It extends from the pubic crest of the hip bone to the linea alba. This small muscle draws down on the linea alba.

<sup>b</sup> In so doing, these muscles act as antagonists of the diaphragm to produce expiration.

Muscles<sup>a</sup>    Origin    Insertion    Innervation    Action(s)

Table 2.1 Principal Muscles of Anterolateral Abdominal Wall



Authors: Agur, Anne M.R.; Dalley, Arthur F.

Title: *Grant's Atlas of Anatomy, 12th Edition*

Copyright ©2009 Lippincott Williams & Wilkins

> Table of Contents > Chapter 2 - Abdomen > 2.6 Structure of the anterolateral abdominal wall

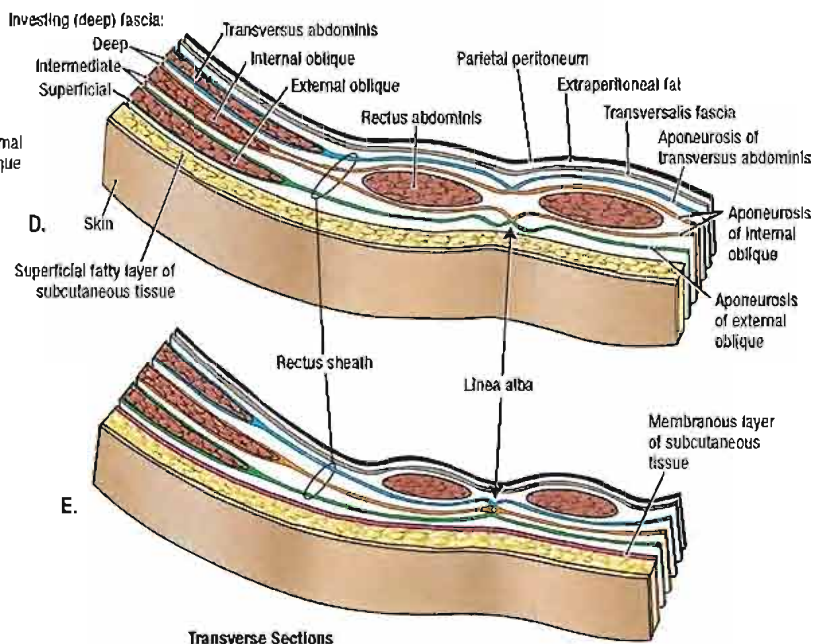
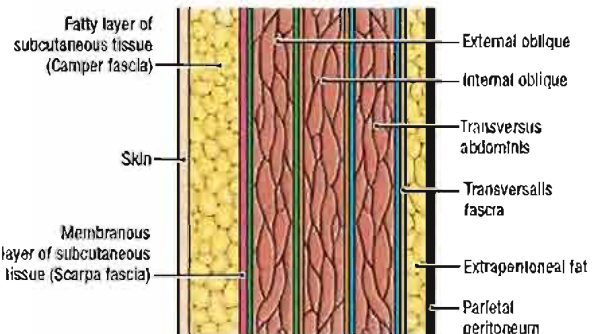
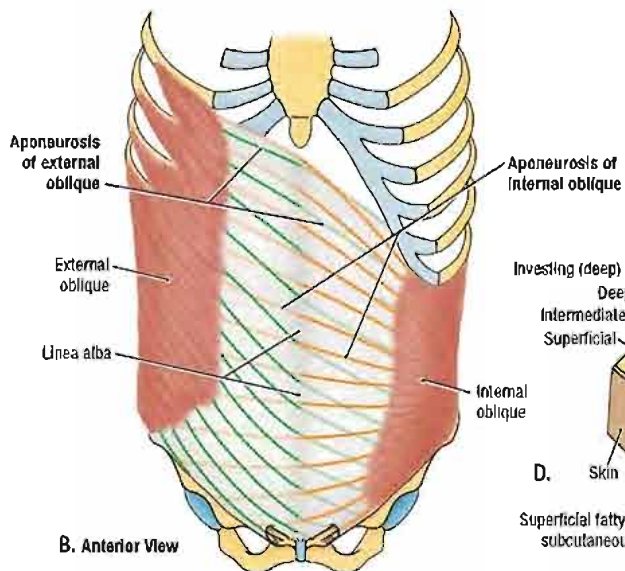
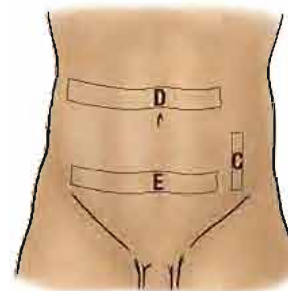
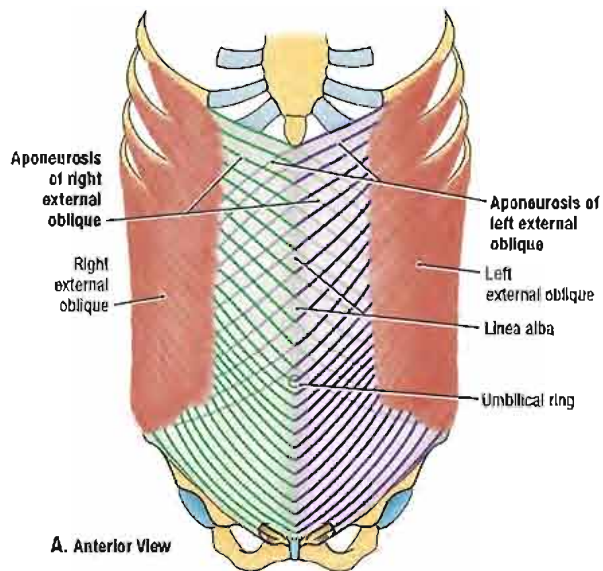
---

## 2.6 Structure of the anterolateral abdominal wall

*Part of* "Chapter 2 - Abdomen "

A. Interdigitation of the aponeuroses of the right and left external oblique muscles. B. Interdigitation of the aponeuroses of the contralateral external and internal oblique muscles. C. Layers of the abdominal wall and the rectus sheath.





Authors: Agur, Anne M.R.; Dalley, Arthur F.

Title: *Grant's Atlas of Anatomy, 12th Edition*

Copyright ©2009 Lippincott Williams & Wilkins

> Table of Contents > Chapter 2 - Abdomen > 2.7 Inguinal region of male-I

---

## 2.7 Inguinal region of male-I

*Part of "Chapter 2 - Abdomen "*

A. Formations of the aponeurosis of the external oblique muscle. B and C. Membranous (deep) layer of subcutaneous tissue. Inferior to the umbilicus, the subcutaneous tissue is composed of two layers: a superficial fatty layer and a deep membranous layer. Laterally, the membranous layer fuses with the fascia lata of the thigh about a finger's breadth inferior to the inguinal ligament. Medially, it fuses with the linea alba and pubic symphysis in the midline, and inferiorly, it continues as the membranous layer of the subcutaneous tissue of the perineum and penis and the dartos fascia of the scrotum. The inferior margin of the external oblique aponeurosis is thickened and turned internally forming the inguinal ligament. The superior surface of the in-turning inguinal ligament forms a shallow trough or "œgutter" that is the floor of the inguinal canal.





Authors: Agur, Anne M.R.; Dalley, Arthur F.

Title: *Grant's Atlas of Anatomy, 12th Edition*

Copyright ©2009 Lippincott Williams & Wilkins

> Table of Contents > Chapter 2 - Abdomen > 2.8 Inguinal region of male "II

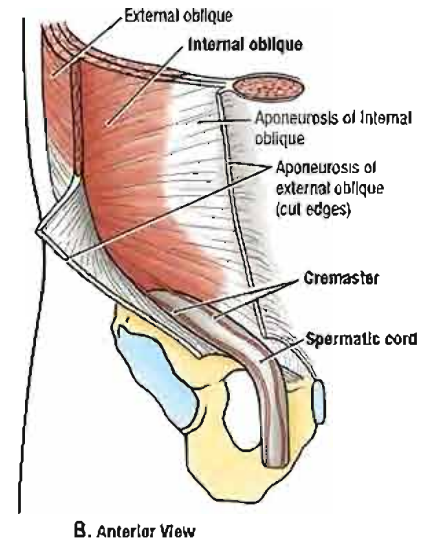
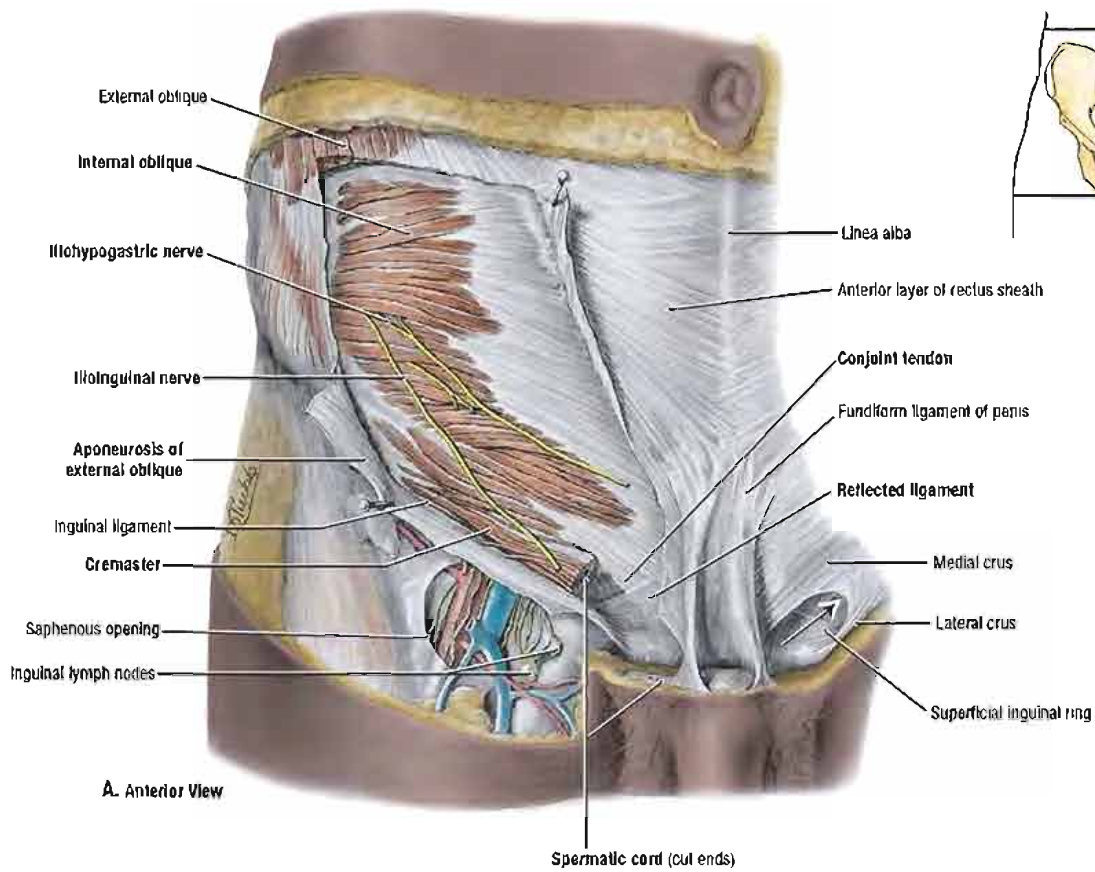
---

## 2.8 Inguinal region of male "II

*Part of "Chapter 2 - Abdomen "*

A. Internal oblique and cremaster muscle. Part of the aponeurosis of the external oblique muscle is cut away, and the spermatic cord is cut short. B. Schematic illustration.

- The cremaster muscle covers the spermatic cord.
  - The reflected ligament is formed by aponeurotic fibers of the external oblique muscle and lies anterior to the conjoint tendon. The conjoint tendon is formed by the fusion of the aponeurosis of the internal oblique and transversus abdominis muscles.
- The cutaneous branches of the iliohypogastric and ilioinguinal nerves (L1) course between the internal and external oblique muscles and must be avoided when an appendectomy incision is made in this region.



Authors: Agur, Anne M.R.; Dalley, Arthur F.

Title: *Grant's Atlas of Anatomy, 12th Edition*

Copyright ©2009 Lippincott Williams & Wilkins

> Table of Contents > Chapter 2 - Abdomen > 2.9 Inguinal region of male " III

---

## 2.9 Inguinal region of male " III

*Part of* "Chapter 2 - Abdomen "

The internal oblique muscle is reflected, and the spermatic cord is retracted.

- The internal oblique muscle portion of the conjoint tendon is attached to the pubic crest, and the transversus abdominis portion to the pectineal line.
- The iliohypogastric and ilioinguinal nerves (L1) supply the internal oblique and transversus abdominis muscles.
- The transversalis fascia is evaginated to form the tubular internal spermatic fascia. The mouth of the tube, called the deep inguinal ring, is situated lateral to the inferior epigastric vessels.

Posterior wall

Transversalis fascia including deep inguinal ring

Transversalis fascia

Transversalis fascia Conjoint tendon

Anterior wall

Aponeurosis of external oblique Internal oblique

Aponeurosis of external oblique

Aponeurosis of external oblique Superficial inguinal ring

Roof

Arching fibers of internal oblique and transversus abdominis

Floor

Inguinal ligament

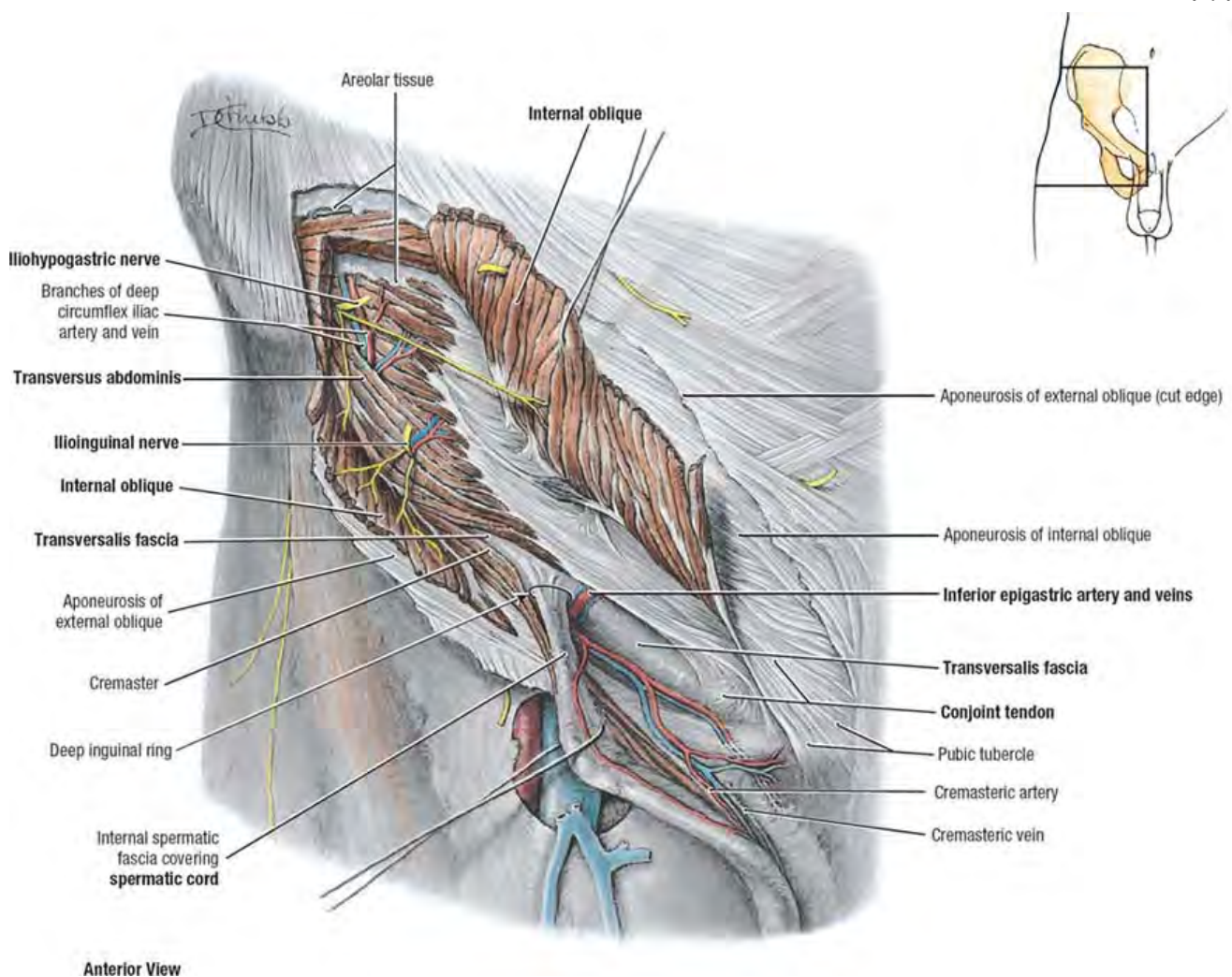
Inguinal ligament

Inguinal ligament Lacunar ligament

Boundaries    Lateral Third    Middle Third    Medial Third

## Table 2.2 Structures Forming The Inguinal Canal

P.109



Authors: Agur, Anne M.R.; Dalley, Arthur F.

Title: *Grant's Atlas of Anatomy, 12th Edition*

Copyright ©2009 Lippincott Williams & Wilkins

> Table of Contents > Chapter 2 - Abdomen > 2.10 Inguinal region of male "IV"

---

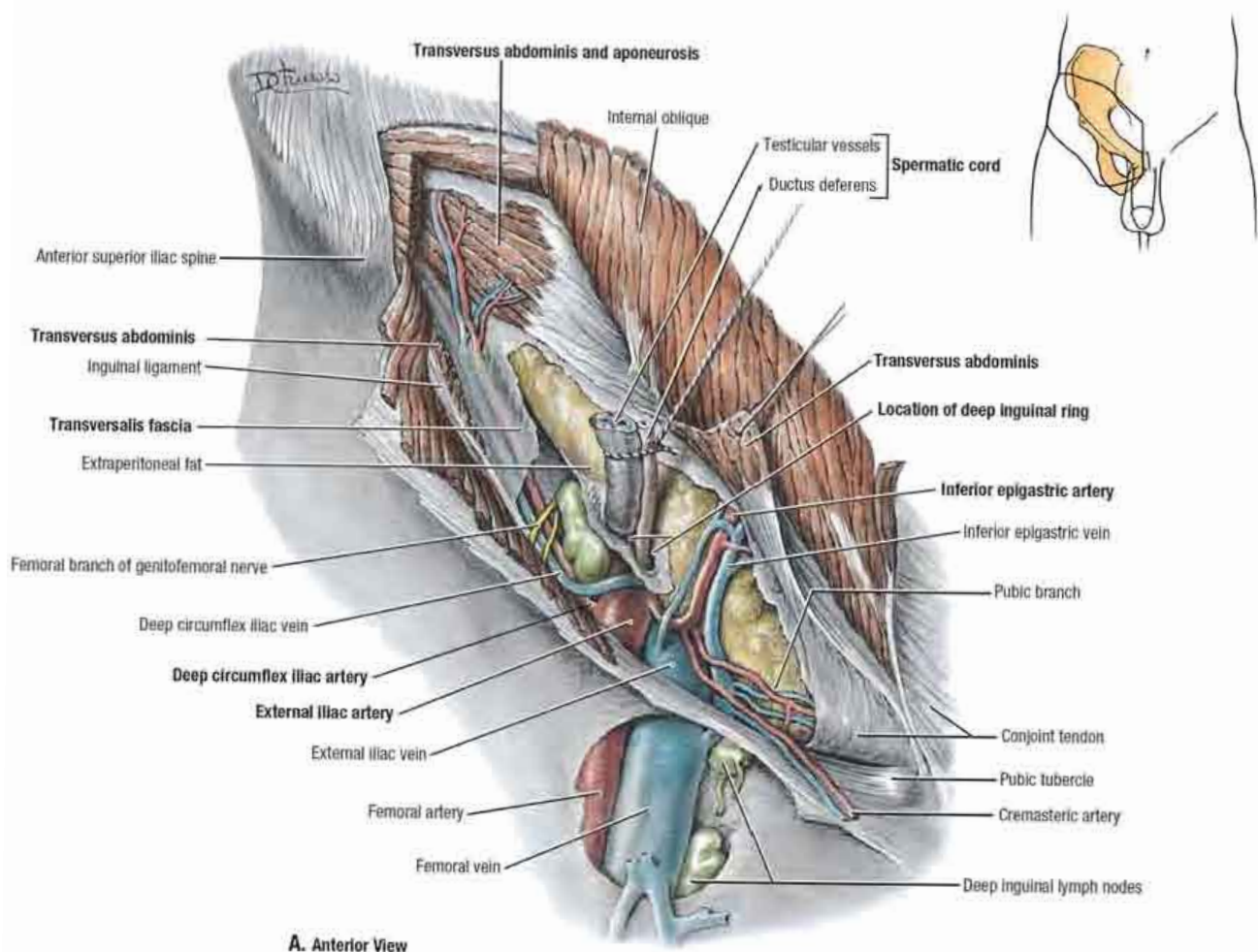
## 2.10 Inguinal region of male "IV"

*Part of "Chapter 2 - Abdomen"*

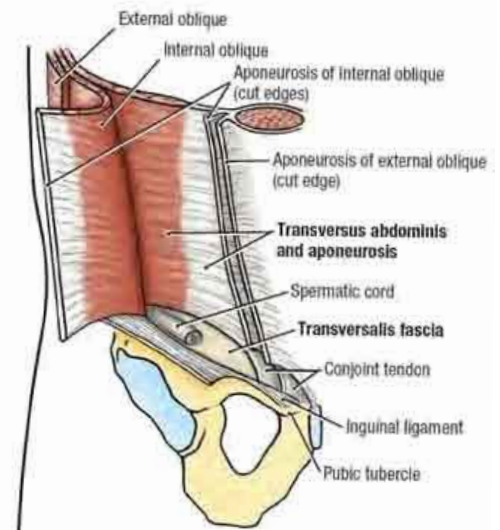
A. The inguinal part of the transversus abdominis muscle and transversalis fascia is partially cut away, the spermatic cord is excised, and the ductus deferens is retracted. B. Schematic illustration.

- The deep inguinal ring is located superior to the inguinal ligament at the midpoint between the anterior superior iliac spine and pubic tubercle.
- The external iliac artery has two branches, the deep circumflex iliac and inferior epigastric arteries. Note also the cremasteric artery and pubic branch arising from the latter.





**A. Anterior View**



**B. Anterior View**

## 2.11 Inguinal canal of female

Part of "Chapter 2 - Abdomen "

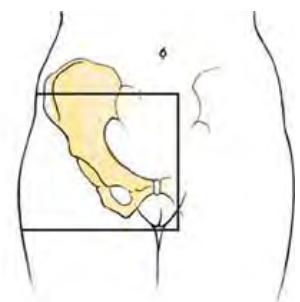
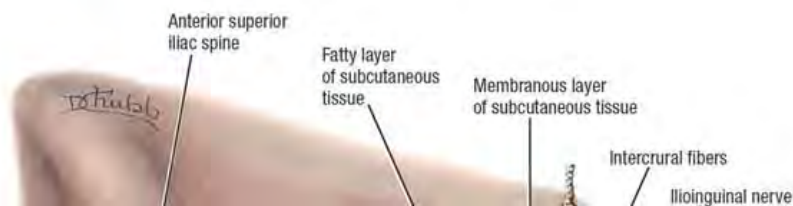Progressive dissections of the female inguinal canal (A–D).

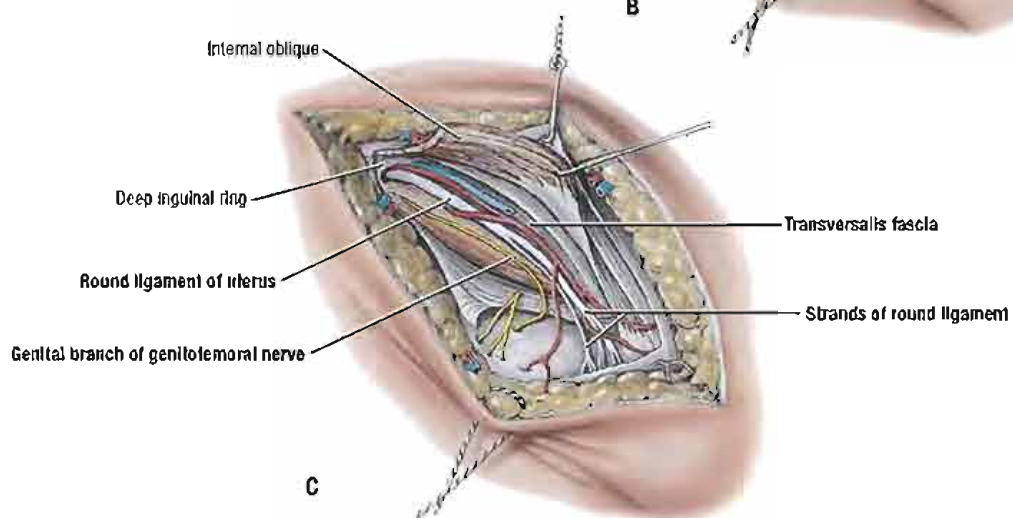
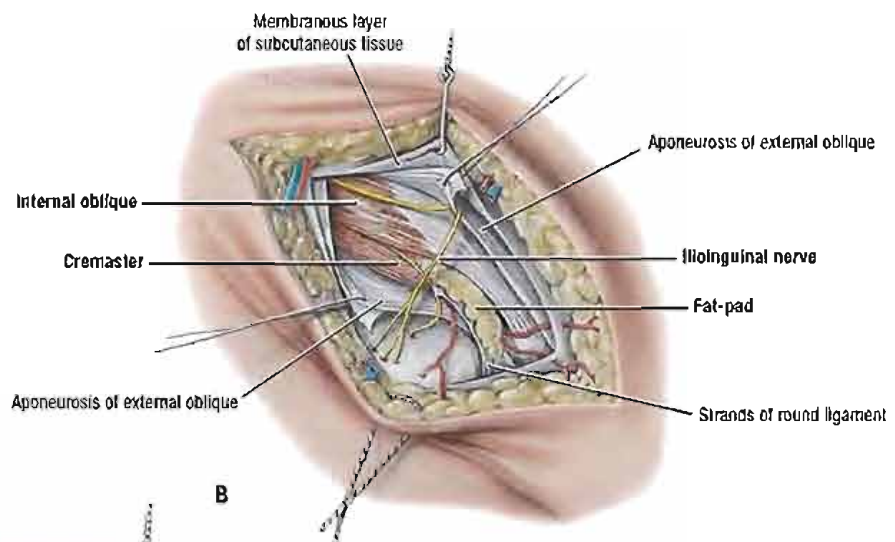
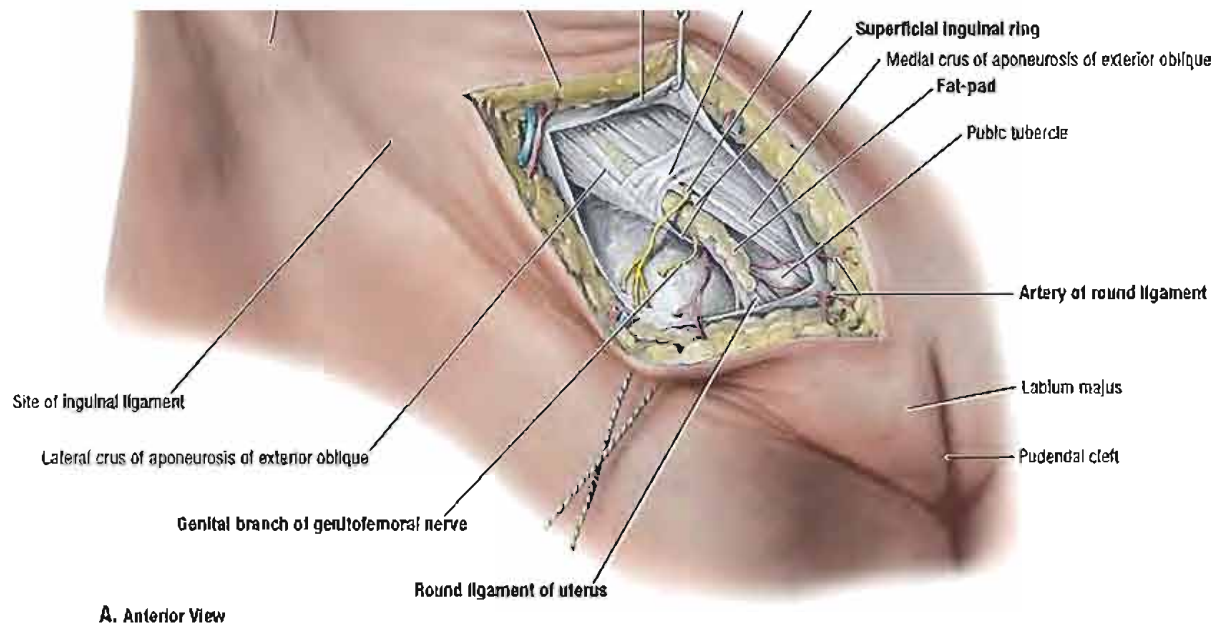
- In A , the superficial inguinal ring is small. Passing through the superficial inguinal ring are the round ligament of the uterus, a closely applied fat-pad, the genital branch of the genitofemoral nerve, and the artery of the round ligament of the uterus. The ilioinguinal nerve may also pass through the ring.
- The cremaster muscle does not extend beyond the superficial inguinal ring (B).
- The round ligament breaks up into strands as it leaves the inguinal canal and approaches the labium majus (C).
- The external iliac artery and vein are exposed deep to the inguinal canal by excising the transversalis fascia (D).

---

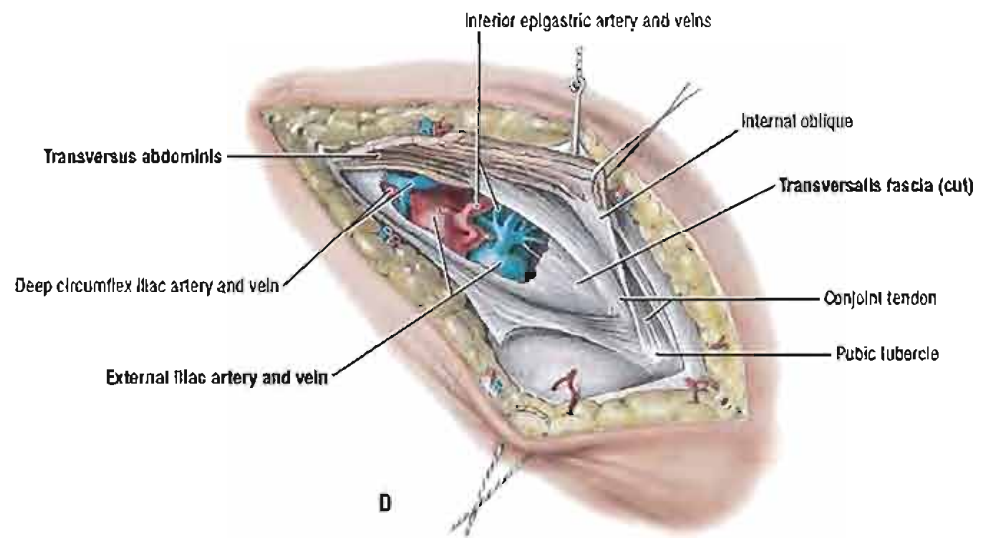
P.111

P.112





**Anterior Views**





Authors: Agur, Anne M.R.; Dalley, Arthur F.  
Title: *Grant's Atlas of Anatomy, 12th Edition*  
Copyright ©2009 Lippincott Williams & Wilkins

> Table of Contents > Chapter 2 - Abdomen > 2.12 Inguinal canal, spermatic cord, and testis

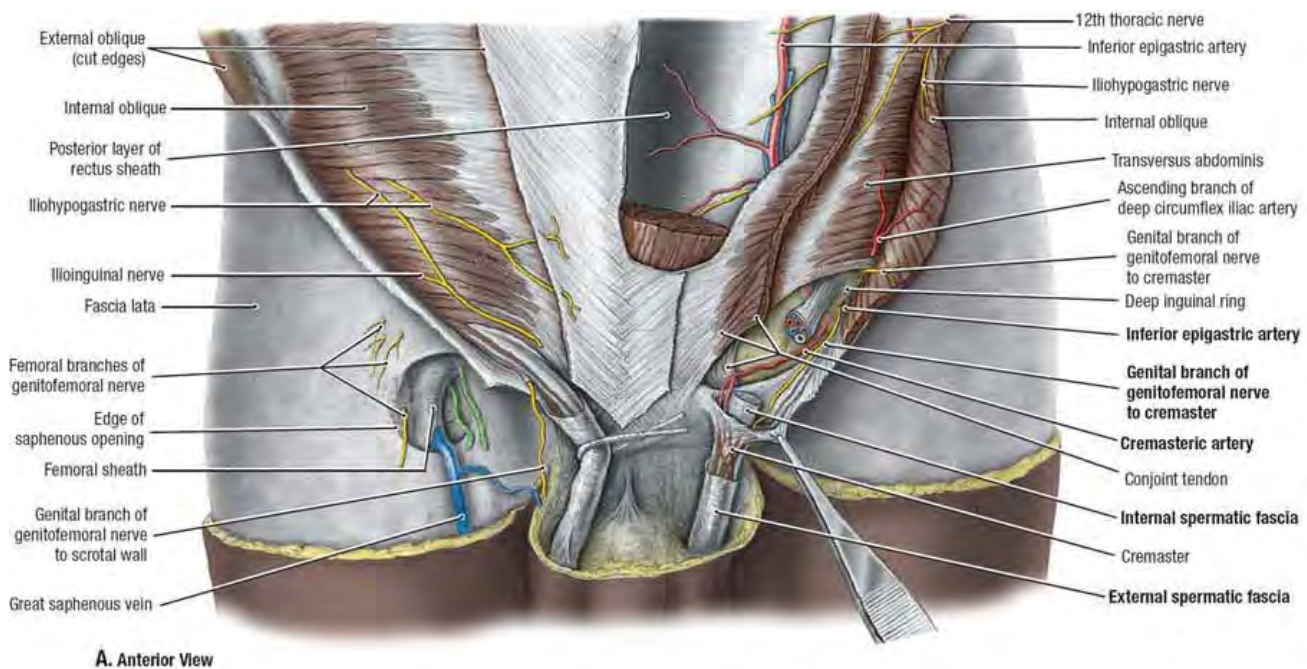
## 2.12 Inguinal canal, spermatic cord, and testis

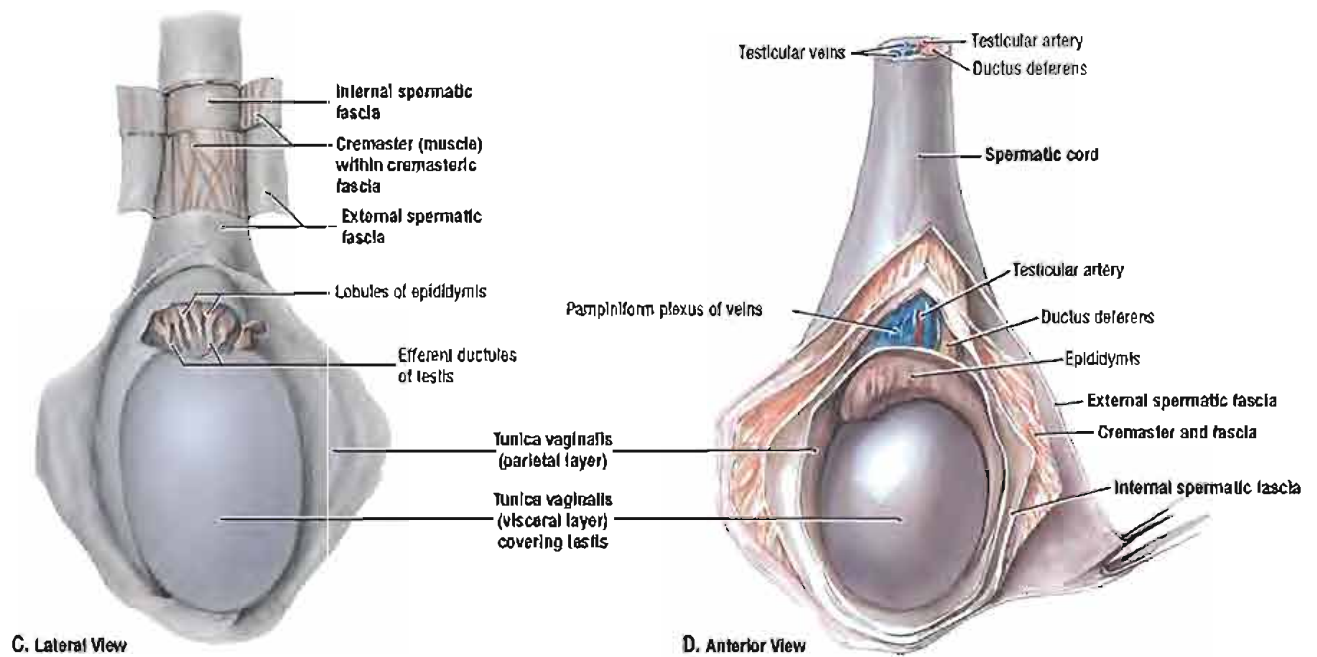
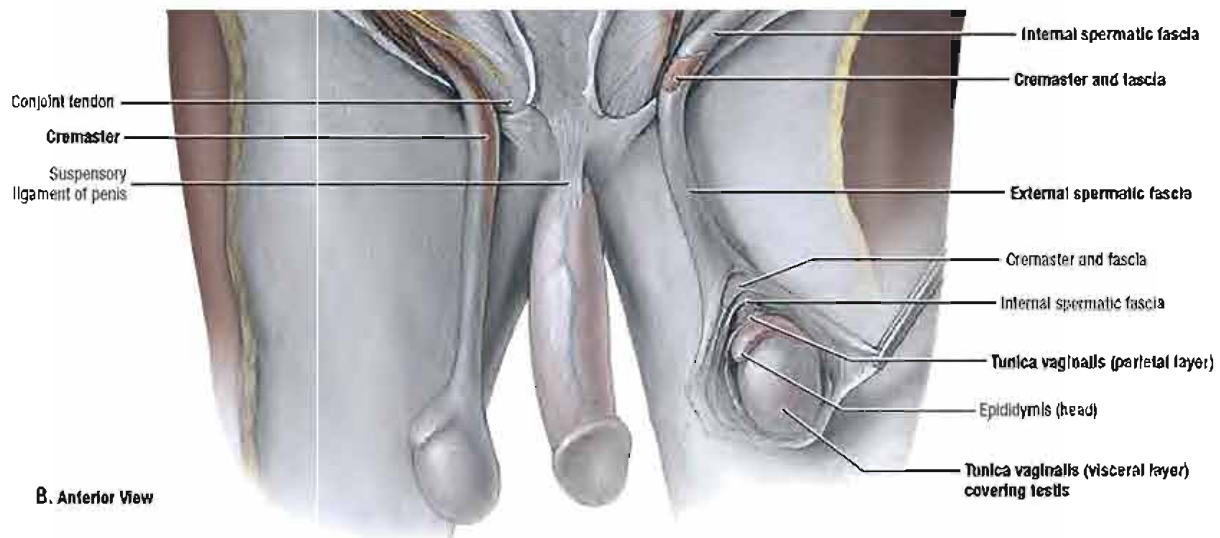
Part of "Chapter 2 - Abdomen "

P.113

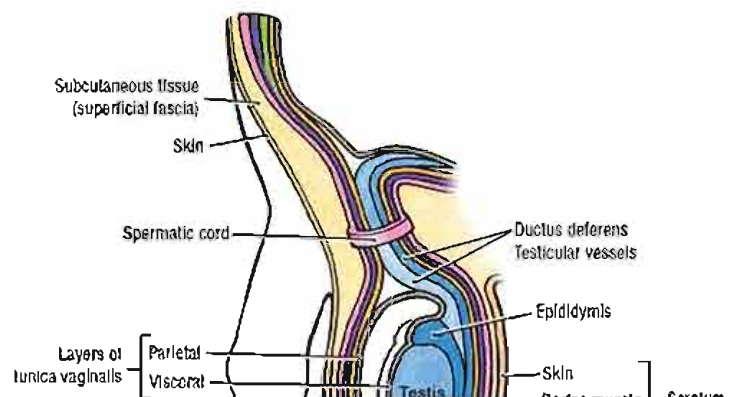
A. Dissection of inguinal canal. B. Dissection of inguinal region and coverings of the spermatic cord and testis. C. D. E. Coverings of spermatic cord and testis.

P.114



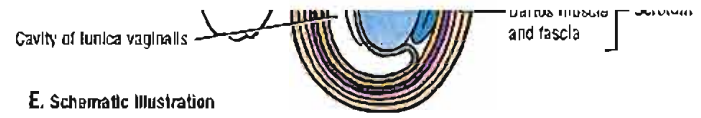

<span style="display: inline-block; width: 10px; height: 10px; background-color: pink; border: 1px solid black;"></span>	External oblique External spermatic fascia
<span style="display: inline-block; width: 10px; height: 10px; background-color: black; border: 1px solid black;"></span>	Internal oblique Cremaster muscle & cremasteric fascia
<span style="display: inline-block; width: 10px; height: 10px; background-color: green; border: 1px solid black;"></span>	Transversus abdominis
<span style="display: inline-block; width: 10px; height: 10px; background-color: orange; border: 1px solid black;"></span>	Transversalis fascia Internal spermatic fascia





☐ Parietal peritoneum  
Tunica vaginalis (parietal  
and visceral layers)



**E. Schematic Illustration**

Authors: Agur, Anne M.R.; Dalley, Arthur F.

Title: *Grant's Atlas of Anatomy, 12th Edition*

Copyright ©2009 Lippincott Williams & Wilkins

> Table of Contents > Chapter 2 - Abdomen > 2.13 Descent of gonads

---

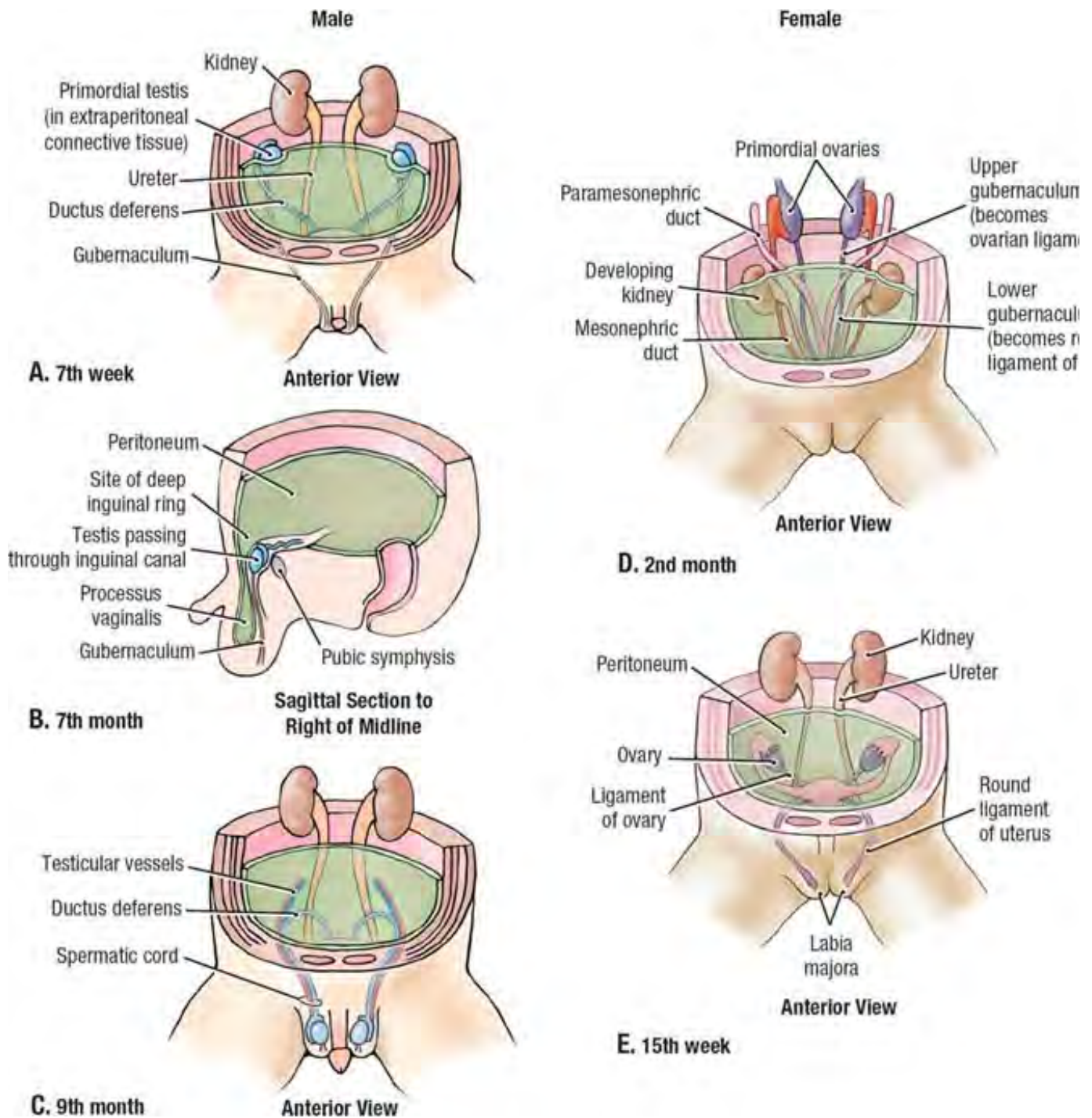
## 2.13 Descent of gonads

*Part of "Chapter 2 - Abdomen "*

The inguinal canals in females are narrower than those in males, and the canals in infants of both sexes are shorter and much less oblique than in adults. For a complete description of the embryology of the inguinal region, see Moore and Persaud (2003).

The fetal testes descend from the dorsal abdominal wall in the superior lumbar region to the deep inguinal rings during the 9th–12th fetal weeks. This movement probably results from growth of the vertebral column and pelvis. The male gubernaculum, attached to the caudal pole of the testis and accompanied by an outpouching of peritoneum, the processus vaginalis, projects into the scrotum. The testis descends posterior to the processus vaginalis. The inferior remnant of the processus vaginalis forms the tunica vaginalis covering the testis. The ductus deferens, testicular vessels, nerves, and lymphatics accompany the testis. The final descent of the testis usually occurs before or shortly after birth.

The fetal ovaries also descend from the dorsal abdominal wall in the superior lumbar region during the 12th week but pass into the lesser pelvis. The female gubernaculum attaches to the caudal pole of the ovary and projects into the labia majora, attaching en route to the uterus. The part passing from the uterus to the ovary forms the ovarian ligament, and the remainder becomes the round ligament of the uterus. Because of the attachment of the ovarian ligaments to the uterus, the ovaries do not descend to the inguinal region; however, the round ligament passes through the inguinal canal and attaches to the subcutaneous tissue of the labium majus.



## 2.14 Inguinal hernias

An inguinal hernia is a protrusion of parietal peritoneum and viscera, such as small intestine, through the abdominal wall in the inguinal region. There are two major categories of inguinal hernia: indirect and direct. More than two-thirds

indirect hernias, most commonly occurring in males.

#### Predisposing factors

Weakness of anterior abdominal wall in inguinal triangle (e.g., owing to distended superficial ring, narrow conjoint tendon, or attenuation of aponeurosis in males > 40 years of age)

Patency of processus vaginalis (complete or at least of superior part) in young persons, the great majority of whom are males

#### Frequency

Less common (1/3 to 1/4 of inguinal hernias)

More common (2/3 to 3/4 of inguinal hernias)

#### Coverings at exit from abdominal cavity (A and B )

Peritoneum plus transversalis fascia (lies outside inner one or two fascial coverings of cord)

Peritoneum of persistent processus vaginalis plus all three fascial coverings of cord/round ligament

#### Course (C)

Usually traverses only medial third of inguinal canal, external and parallel to vestige of processus vaginalis

Traverses inguinal canal (entire canal if it is sufficient size) within processus vaginalis

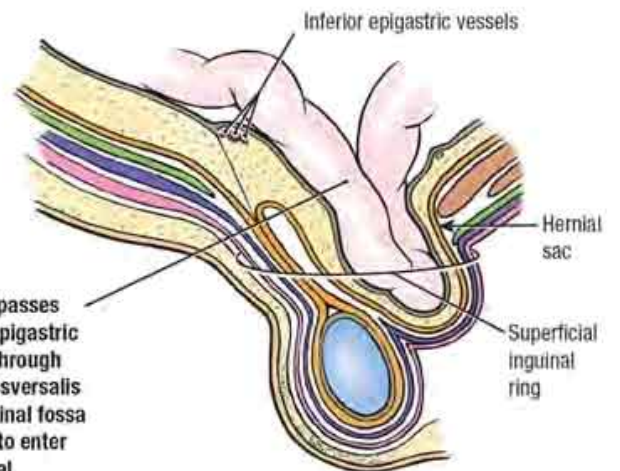
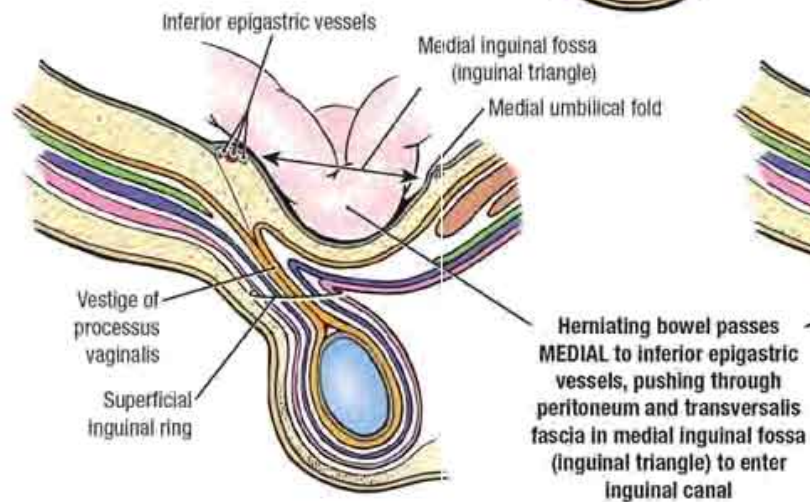
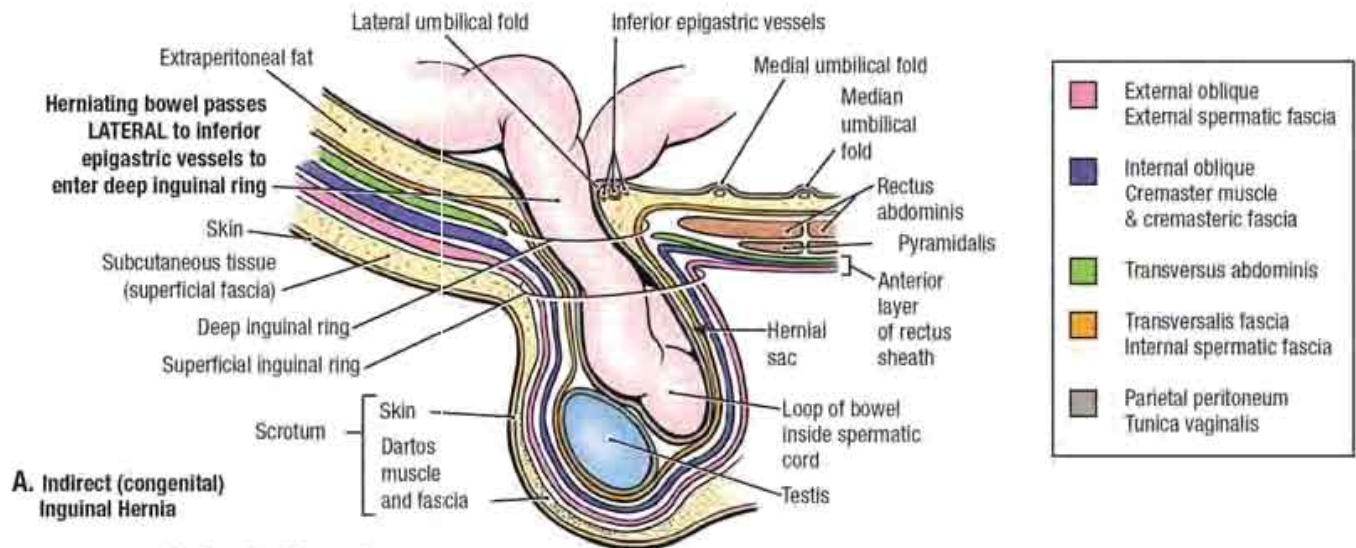
#### Exit from anterior abdominal wall

Via superficial ring, lateral to cord; rarely enters scrotum

Via superficial ring inside cord, commonly passing into scrotum/labium majus

<sup>a</sup> Letters in parentheses refer to the figure parts.

Characteristics <sup>a</sup>	Direct (Acquired)	Indirect (Congenital)
------------------------------	-------------------	-----------------------



Authors: Agur, Anne M.R.; Dalley, Arthur F.

Title: *Grant's Atlas of Anatomy, 12th Edition*

Copyright ©2009 Lippincott Williams & Wilkins

> Table of Contents > Chapter 2 - Abdomen > 2.15 Spermatic cord, testis, and epididymis

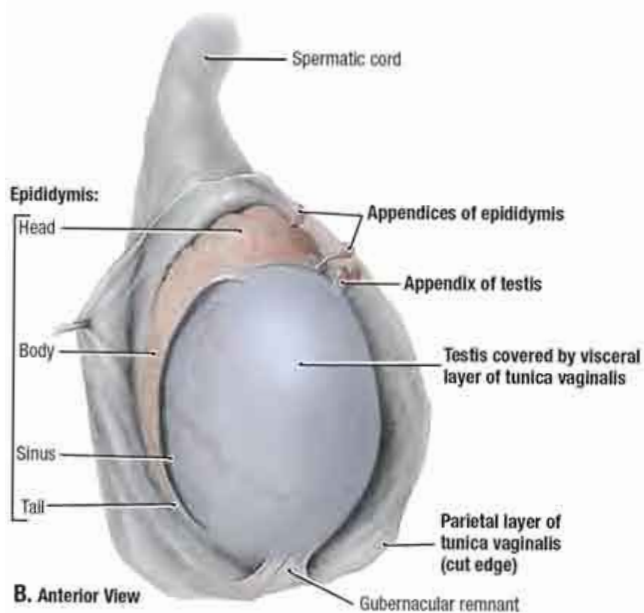
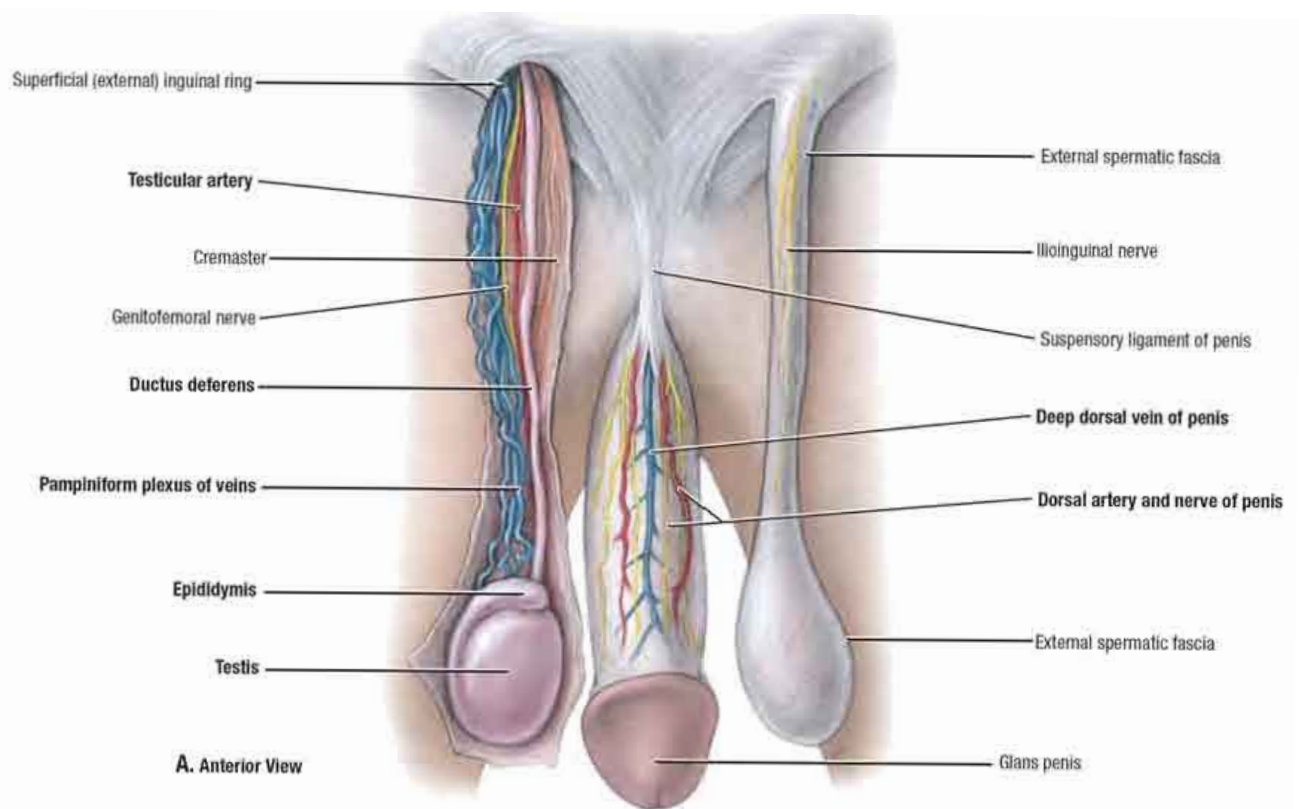
---

## 2.15 Spermatic cord, testis, and epididymis

*Part of "Chapter 2 - Abdomen "*

A. Dissection of spermatic cord. The subcutaneous tissue (dartos fascia) covering the penis has been removed and the deep fascia rendered transparent to demonstrate the median deep dorsal vein and the bilateral dorsal arteries and nerves of the penis. On the specimen's right, the coverings of the spermatic cord and testis are reflected, and the contents of the cord are separated. The testicular artery has been separated from the pampiniform plexus of veins that surrounds it as it courses parallel to the ductus deferens. Lymphatic vessels and autonomic nerve fibers (not shown) are also present. B. The tunica vaginalis has been incised longitudinally to expose its cavity, surrounding the testis anteriorly and laterally, and extending between the testis and epididymis at the sinus of the epididymis. The epididymis is located posterolateral to the left testis, i.e., on the right side of the right testis and on the left side of the left testis. The appendices of the testis and epididymis may be observed in some specimens. These structures are small remnants of the embryonic genital (paramesonephric) duct.





Authors: Agur, Anne M.R.; Dalley, Arthur F.

Title: *Grant's Atlas of Anatomy, 12th Edition*

Copyright ©2009 Lippincott Williams & Wilkins

> Table of Contents > Chapter 2 - Abdomen > 2.16 Blood supply and lymphatic drainage of testis

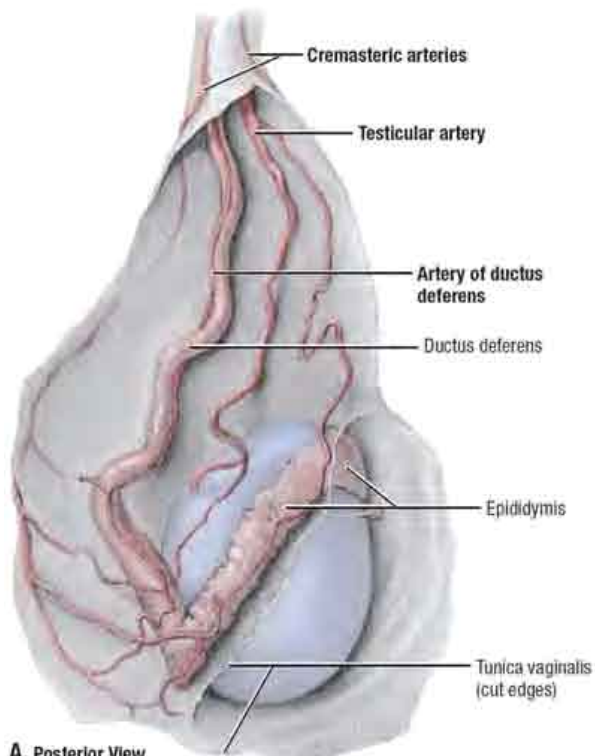
---

## 2.16 Blood supply and lymphatic drainage of testis

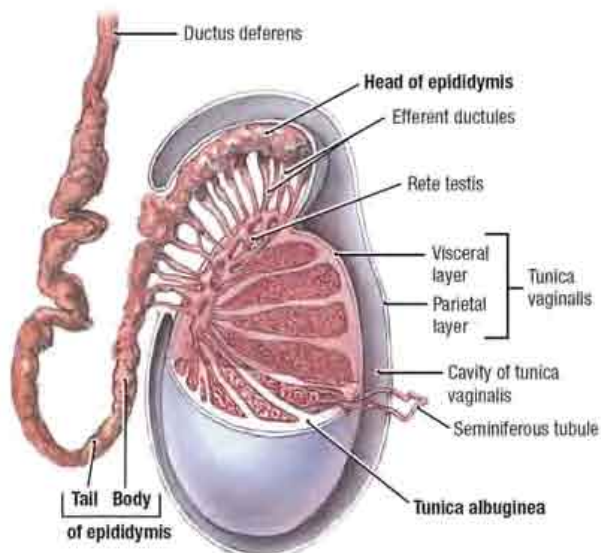
*Part of* "Chapter 2 - Abdomen "

A. Blood supply. B. Internal structure. C. Lymphatic drainage.

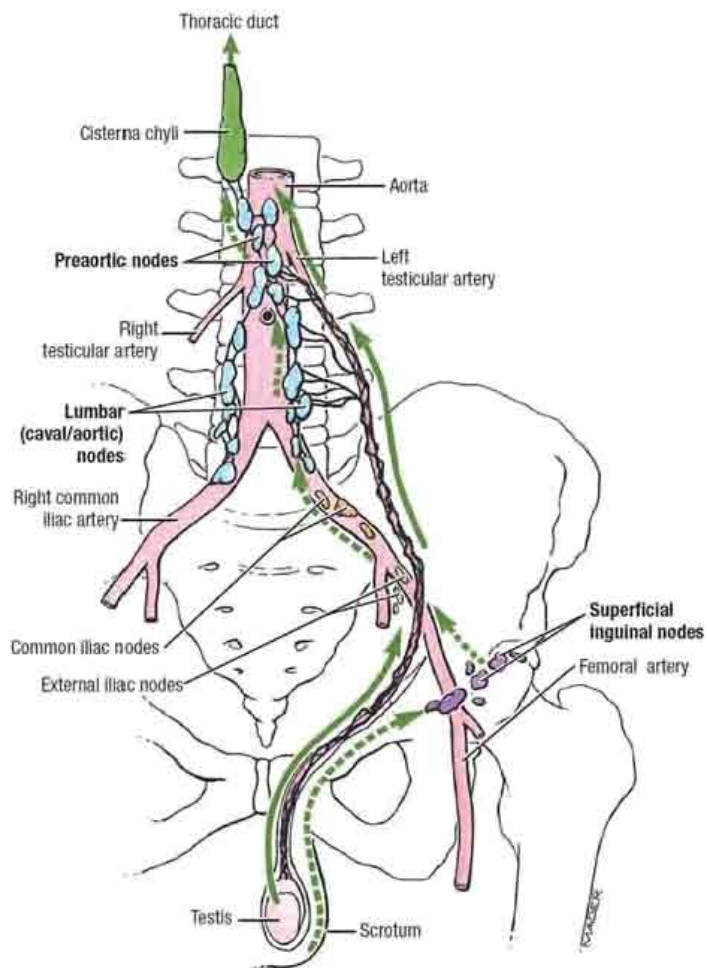
Because the testes descend from the posterior abdominal wall into the scrotum during fetal development, their lymphatic drainage differs from that of the scrotum, which is an outpouching of the abdominal skin. Consequently, cancer of the testis metastasizes initially to the lumbar lymph nodes and cancer of the scrotum metastasizes initially to the superficial inguinal lymph nodes.



**A. Posterior View**



**B. Longitudinal Section of Tunica Vaginalis;  
Testis Sectioned in Sagittal and Transverse Planes**



**C. Anterior View**

Authors: Agur, Anne M.R.; Dalley, Arthur F.

Title: *Grant's Atlas of Anatomy, 12th Edition*

Copyright ©2009 Lippincott Williams & Wilkins

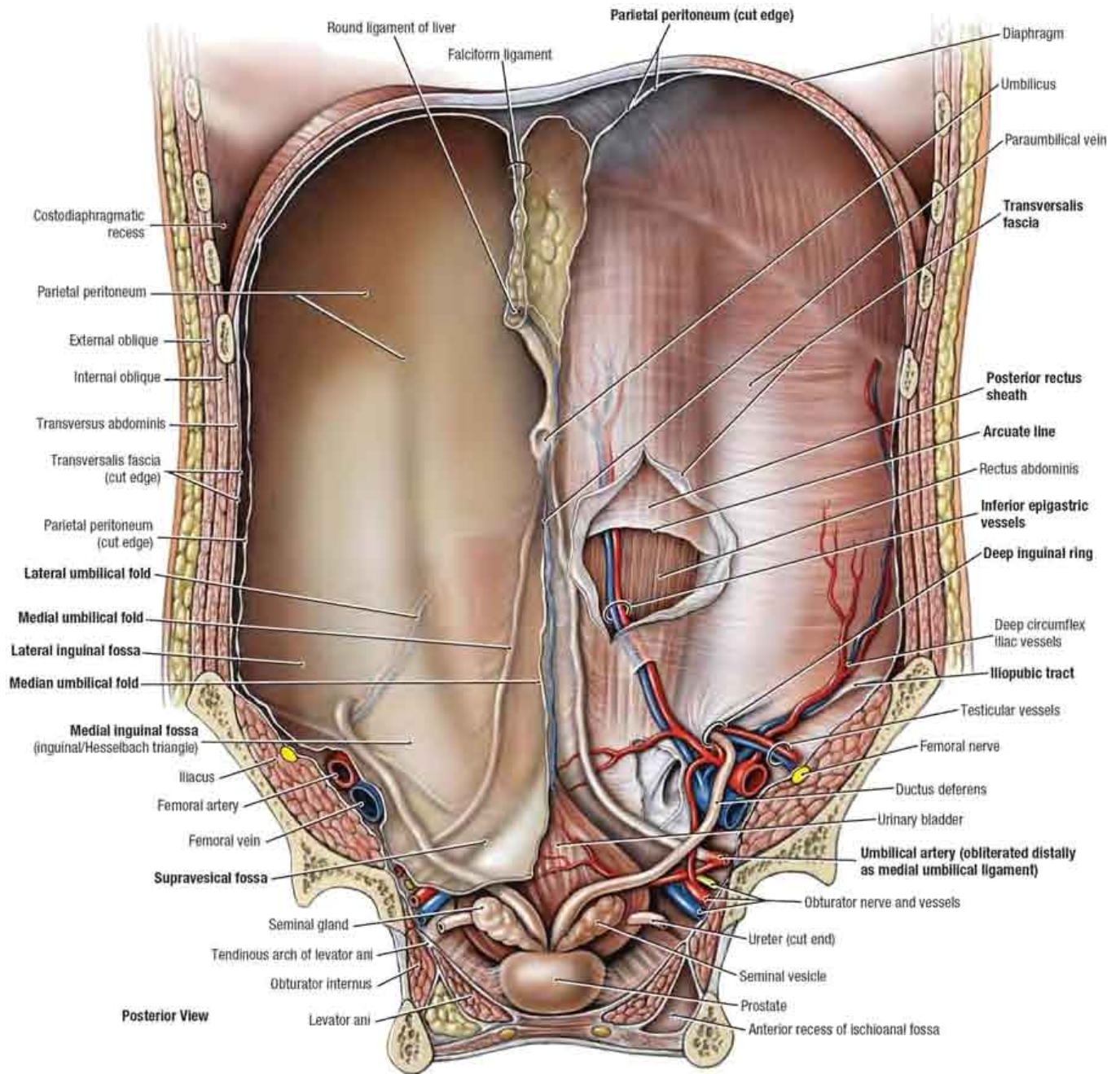
> Table of Contents > Chapter 2 - Abdomen > 2.17 Posterior aspect of the anterolateral abdominal wall

---

## 2.17 Posterior aspect of the anterolateral abdominal wall

*Part of "Chapter 2 - Abdomen "*

Umbilical folds (median, medial, and lateral) are reflections of the parietal peritoneum that are raised from the body wall by underlying structures. The median umbilical fold extends from the urinary bladder to the umbilicus and covers the median umbilical ligament (the remnant of the urachus). The two medial umbilical folds cover the medial umbilical ligaments (occluded remnants of the fetal umbilical arteries). Two lateral umbilical folds cover the inferior epigastric vessels. The supramesic fossae are between the median and medial umbilical folds, the medial inguinal fossae (inguinal triangles) are between the medial and lateral umbilical folds, and the lateral inguinal fossae and deep inguinal rings are lateral to the lateral umbilical folds.





Authors: Agur, Anne M.R.; Dalley, Arthur F.

Title: *Grant's Atlas of Anatomy, 12th Edition*

Copyright ©2009 Lippincott Williams & Wilkins

> Table of Contents > Chapter 2 - Abdomen > 2.18 Abdominal contents and peritoneum

---

## 2.18 Abdominal contents and peritoneum

*Part of* "Chapter 2 - Abdomen "

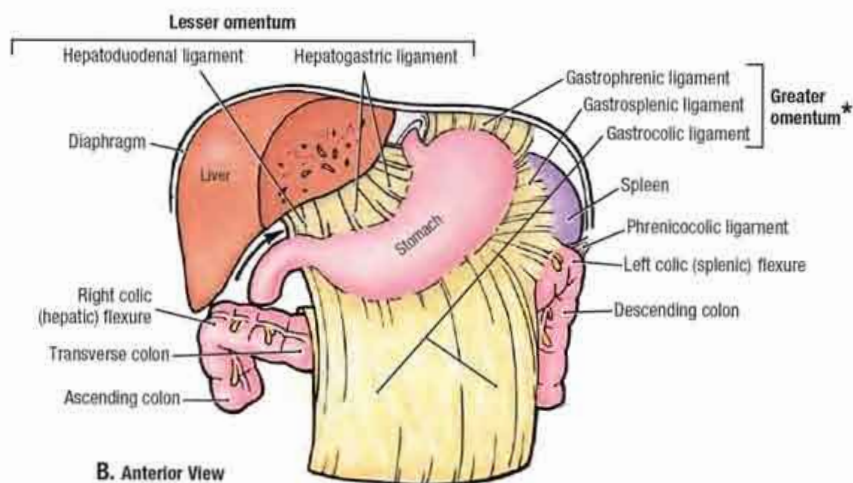
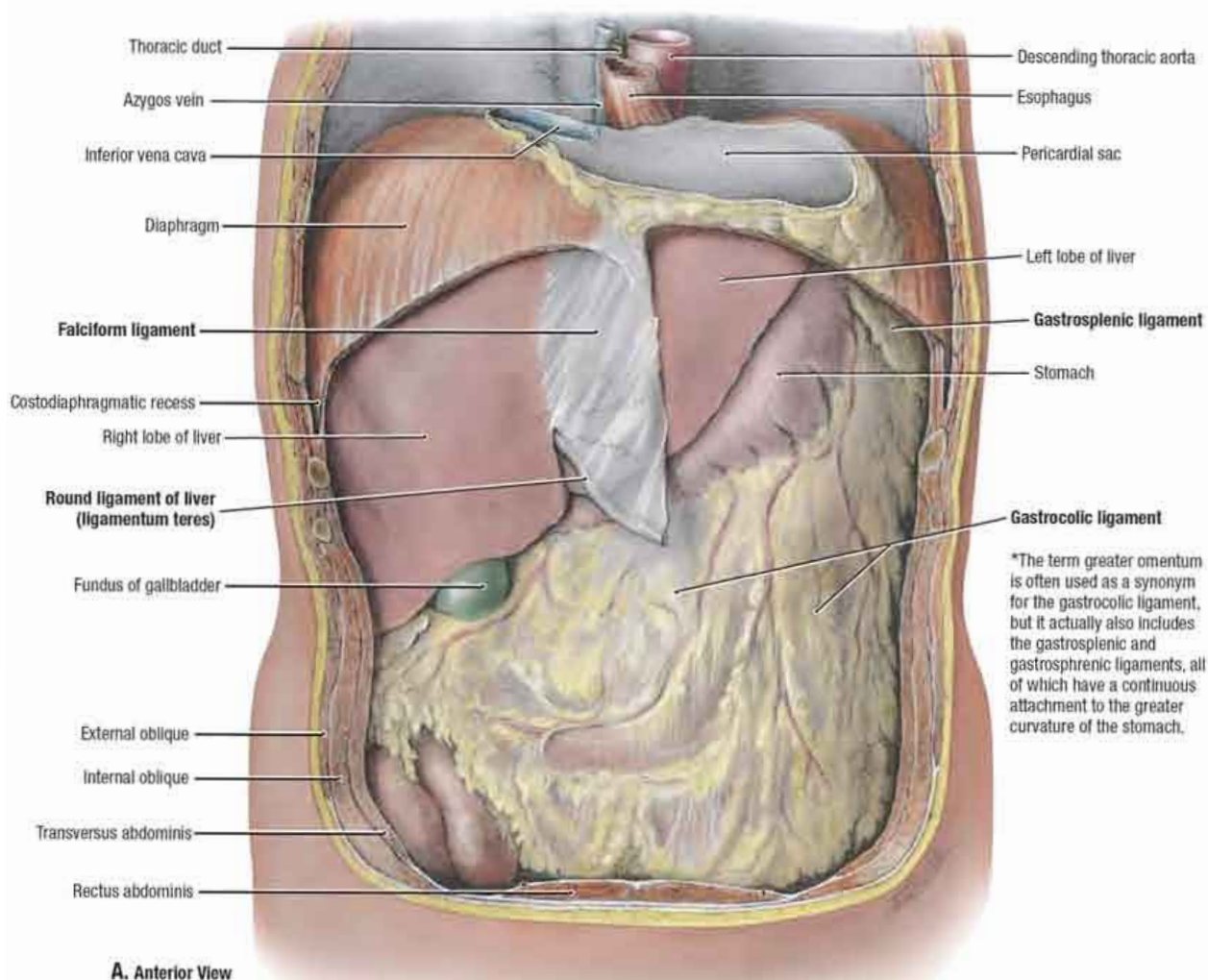
A. Dissection. B. Components of greater and lesser omentum.

*Arrow* , site of omental (epiploic) foramen.

---

P.120





## 2.19 Peritoneal formations and bare areas

### *Part of "Chapter 2 - Abdomen "*

Various terms are used to describe the parts of the peritoneum that connect organs with other organs or to the abdominal wall, and to describe the compartments and recesses that are formed as a consequence. The *arrow* passes through the omental (epiploic) foramen.

#### Peritoneal ligament

Double layer of peritoneum that connects an organ with another organ or to the abdominal wall.  
Mesentery

Double layer of peritoneum that occurs as a result of the invagination of the peritoneum by an organ and constitutes a continuity of the visceral and parietal peritoneum.

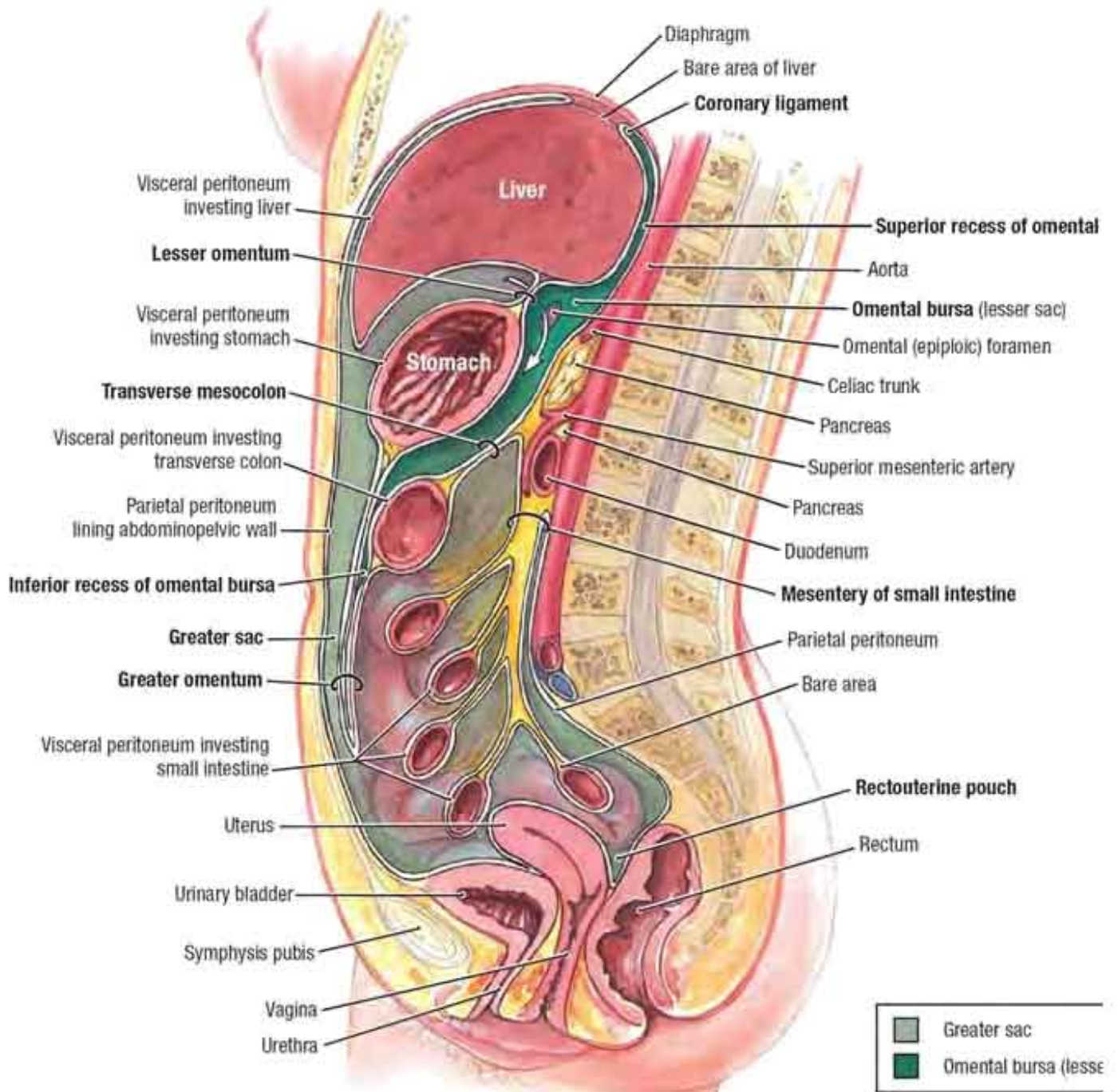
#### Omentum

Double-layered extension of peritoneum passing from the stomach and proximal part of the duodenum to adjacent organs. The greater omentum extends from the greater curvature of stomach and the proximal duodenum; the lesser omentum from the lesser curvature.

#### Bare area

Every organ must have an area, the bare area, that is not covered with visceral peritoneum, allow the entrance and exit of neurovascular structures. Bare areas are formed in relation to the attachments of mesenteries, omenta, and ligaments.

Term	Definition
------	------------



**Median Section**



Authors: Agur, Anne M.R.; Dalley, Arthur F.

Title: *Grant's Atlas of Anatomy, 12th Edition*

Copyright ©2009 Lippincott Williams & Wilkins

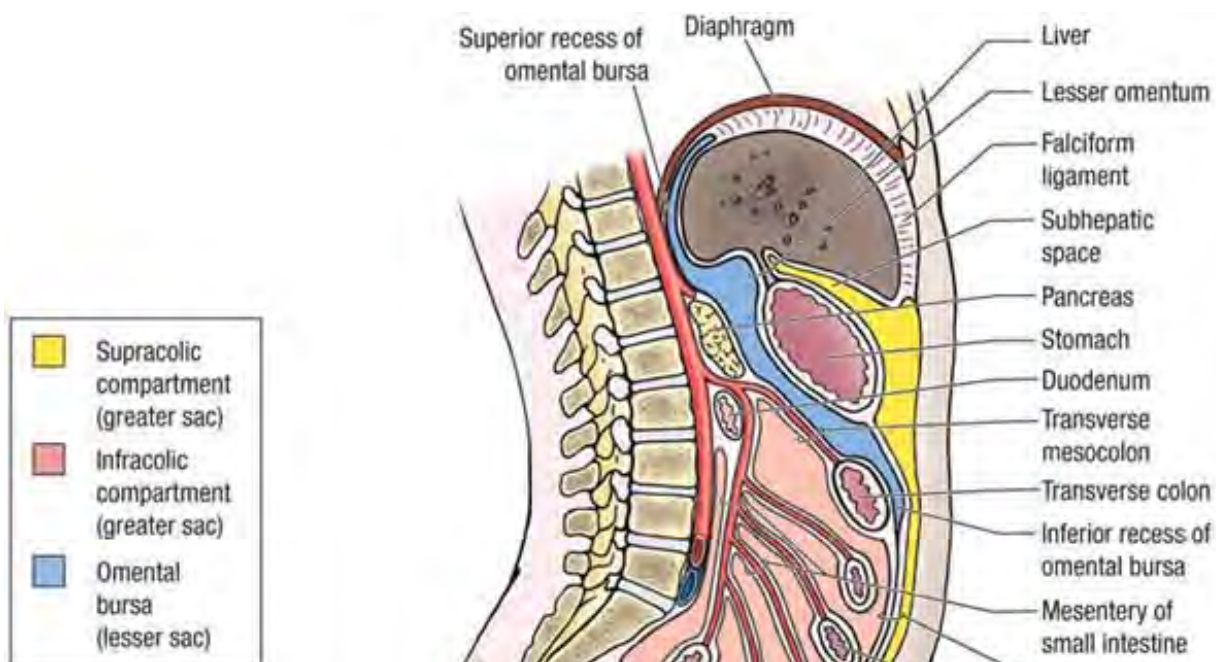
> Table of Contents > Chapter 2 - Abdomen > 2.20 Subdivisions of peritoneal cavity

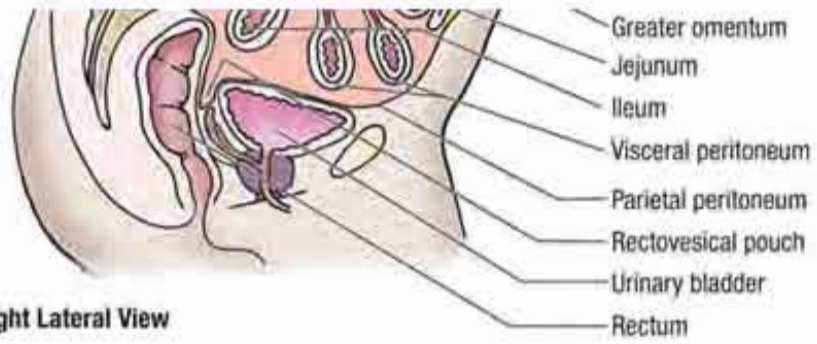
## 2.20 Subdivisions of peritoneal cavity

*Part of "Chapter 2 - Abdomen"*

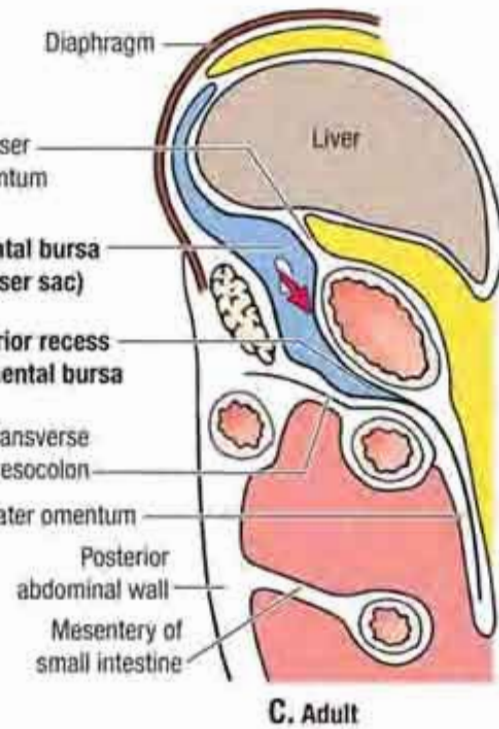
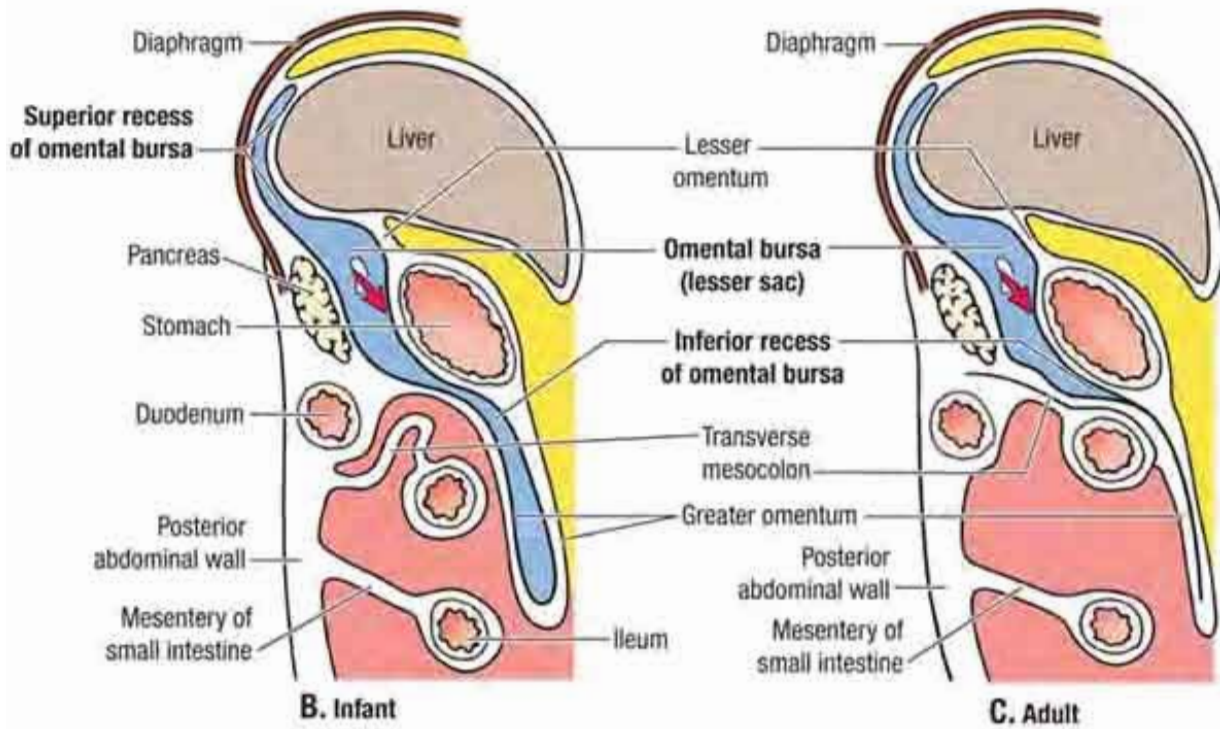
A. Sagittal section. B. In an infant, the omental bursa (lesser sac) is an isolated part of the peritoneal cavity, lying dorsal to the stomach and extending superiorly to the liver and diaphragm (superior recess of the omental bursa) and inferiorly between the layers of the greater omentum (inferior recess of the omental bursa). C. In an adult, after fusion of the layers of the greater omentum, the inferior recess of the omental bursa now extends inferiorly only as far as the transverse colon. The *red arrows* pass from the greater sac through the omental (epiploic) foramen into the omental bursa.

P.122





**A. Right Lateral View**



**Schematic Sagittal Sections, Lateral View**

Authors: Agur, Anne M.R.; Dalley, Arthur F.

Title: *Grant's Atlas of Anatomy, 12th Edition*

Copyright ©2009 Lippincott Williams & Wilkins

> Table of Contents > Chapter 2 - Abdomen > 2.21 Posterior wall of peritoneal cavity

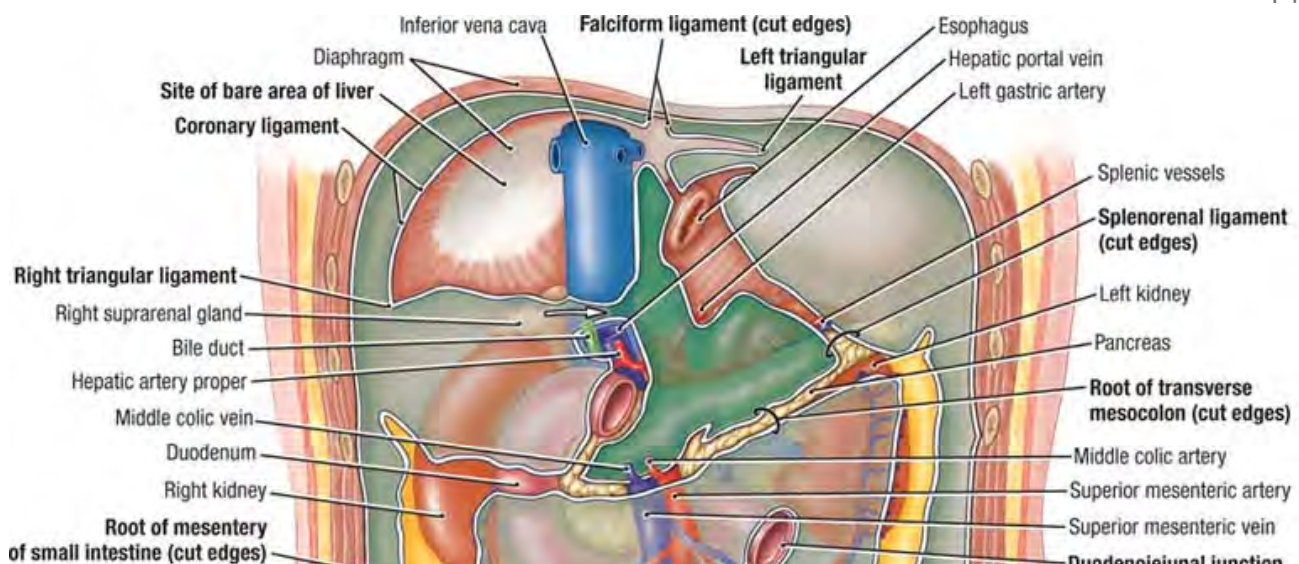
## 2.21 Posterior wall of peritoneal cavity

Part of "Chapter 2 - Abdomen "

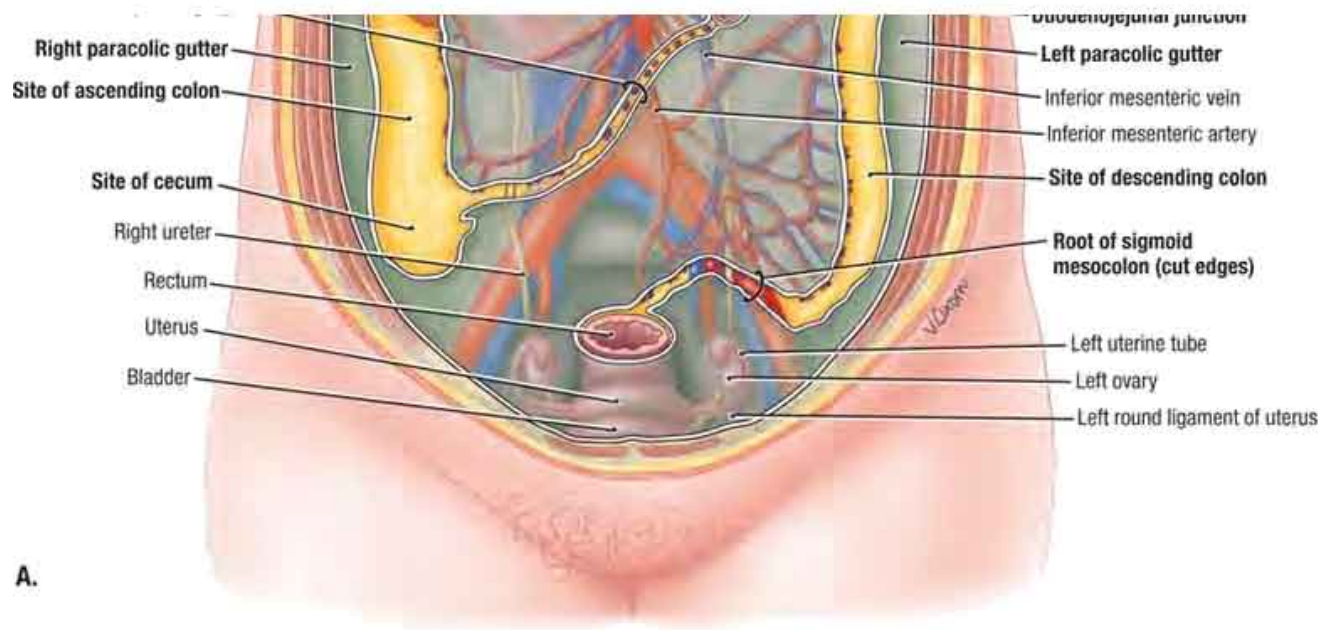
A. Roots of the peritoneal reflections. The peritoneal reflections from the posterior abdominal wall (mesenteries and reflections surrounding bare areas of liver and secondarily retroperitoneal organs) have been cut at their roots, and the intraperitoneal and secondarily retroperitoneal viscera have been removed. The *white arrow* passes through the omental (epiploic) foramen. B. Supracolic and infracolic compartments of the greater sac.

The infracolic spaces and paracolic gutters are of clinical importance because they determine the paths (*black arrows*) for the flow of ascetic fluid with changes in position, and the spread of intraperitoneal reflections.

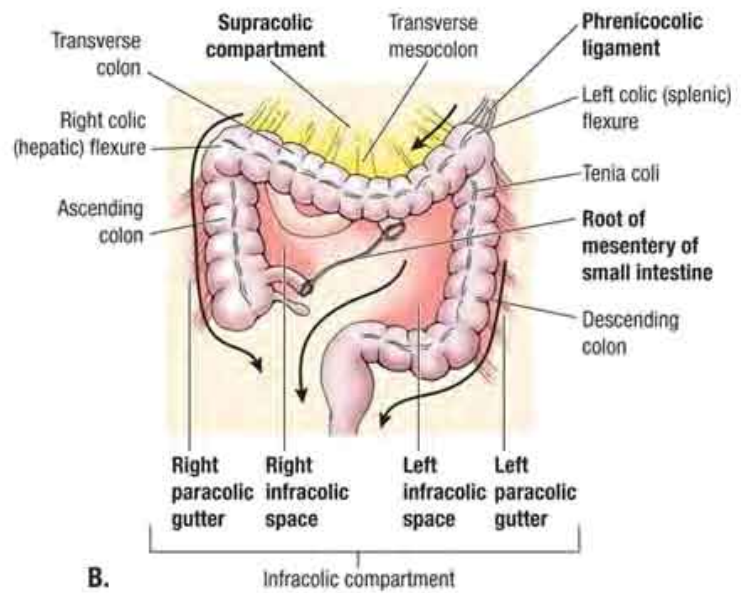
P.123







**Anterior Views**



Authors: Agur, Anne M.R.; Dalley, Arthur F.

Title: *Grant's Atlas of Anatomy, 12th Edition*

Copyright ©2009 Lippincott Williams & Wilkins

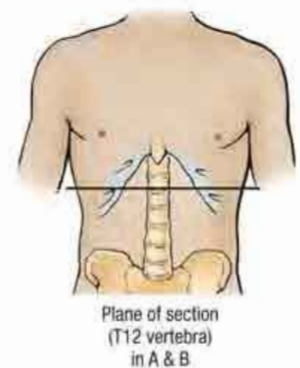
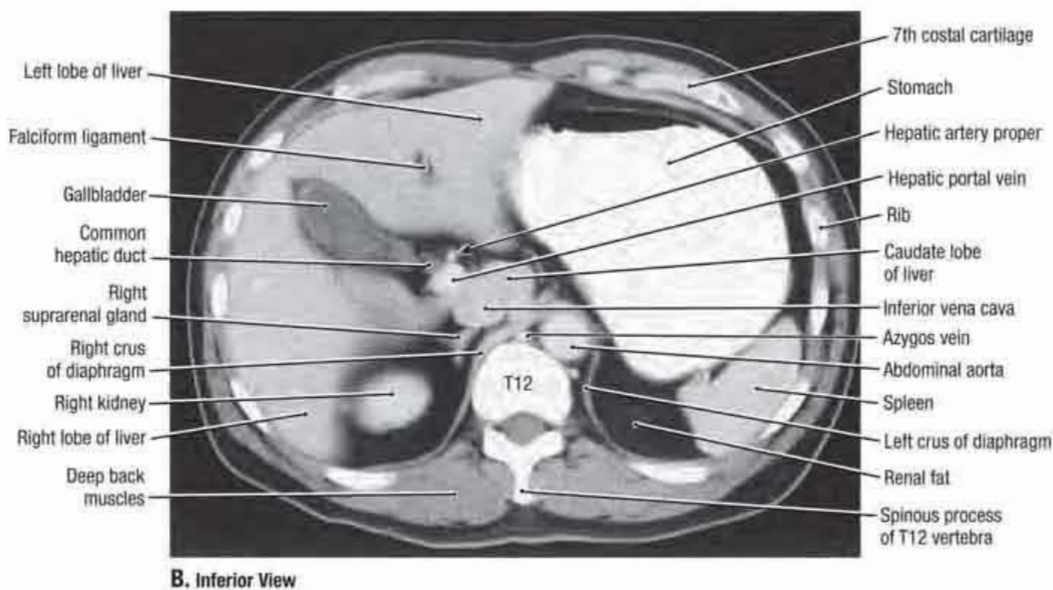
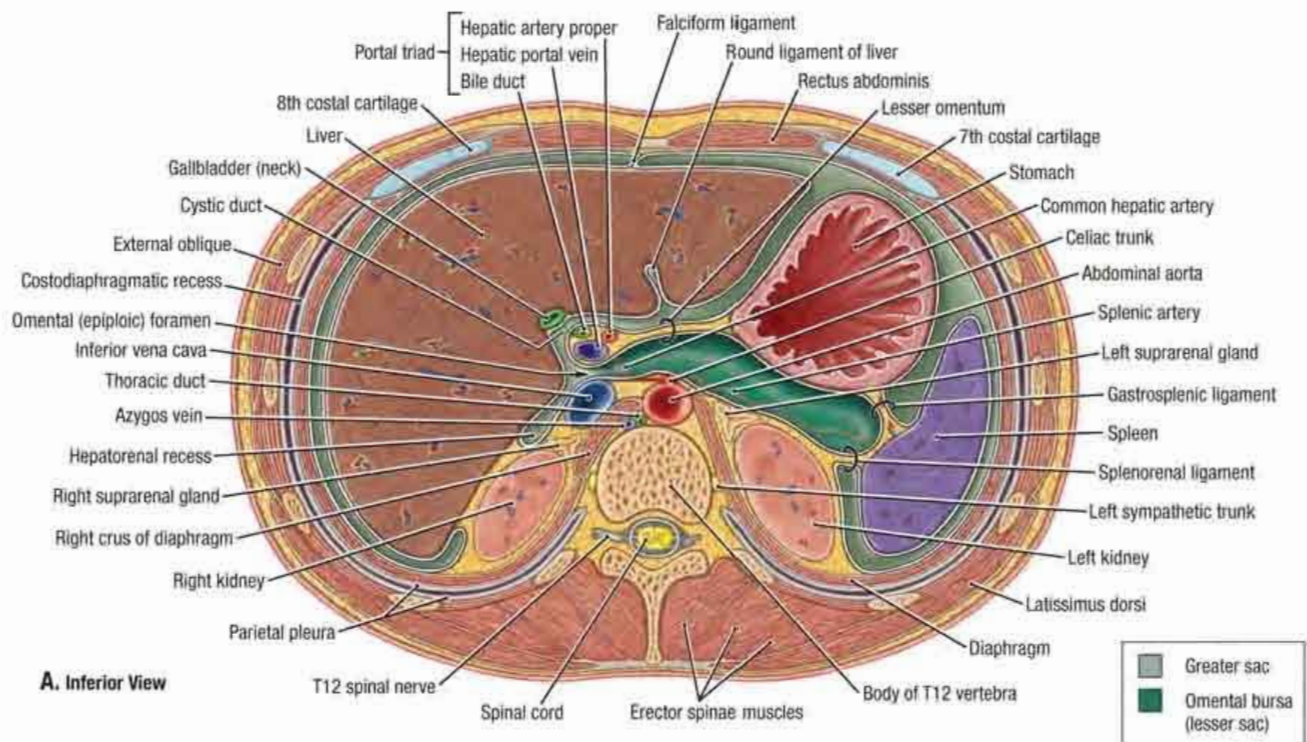
> Table of Contents > Chapter 2 - Abdomen > 2.22 Transverse sections through greater sac and omental bursa.

---

## 2.22 Transverse sections through greater sac and omental bursa.

*Part of* "Chapter 2 - Abdomen "

- When bacterial contamination occurs or when the gut is traumatically penetrated or ruptured as the result of infection and inflammation, gas, fecal matter, and bacteria enter the peritoneal cavity. The result is infection and inflammation of the peritoneum, called peritonitis.
- Under certain pathological conditions such as peritonitis, the peritoneal cavity may be distended with abnormal fluid (ascites). Widespread metastases (spread) of cancer cells to the abdominal viscera cause exudation (escape) of fluid that is often blood stained. Thus the peritoneal cavity may be distended with several liters of abnormal fluid. Surgical puncture of the peritoneal cavity for the aspiration of drainage of fluid is called paracentesis.



Authors: Agur, Anne M.R.; Dalley, Arthur F.

Title: *Grant's Atlas of Anatomy, 12th Edition*

Copyright ©2009 Lippincott Williams & Wilkins

> Table of Contents > Chapter 2 - Abdomen > 2.23 Stomach and omenta

---

## 2.23 Stomach and omenta

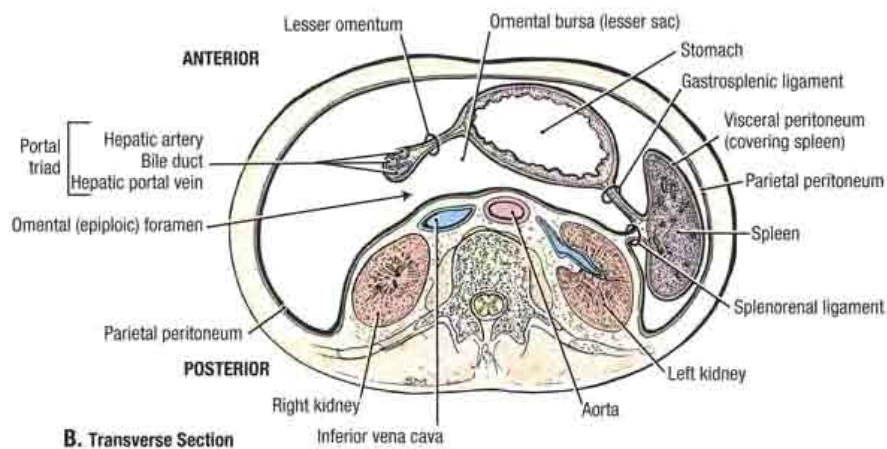
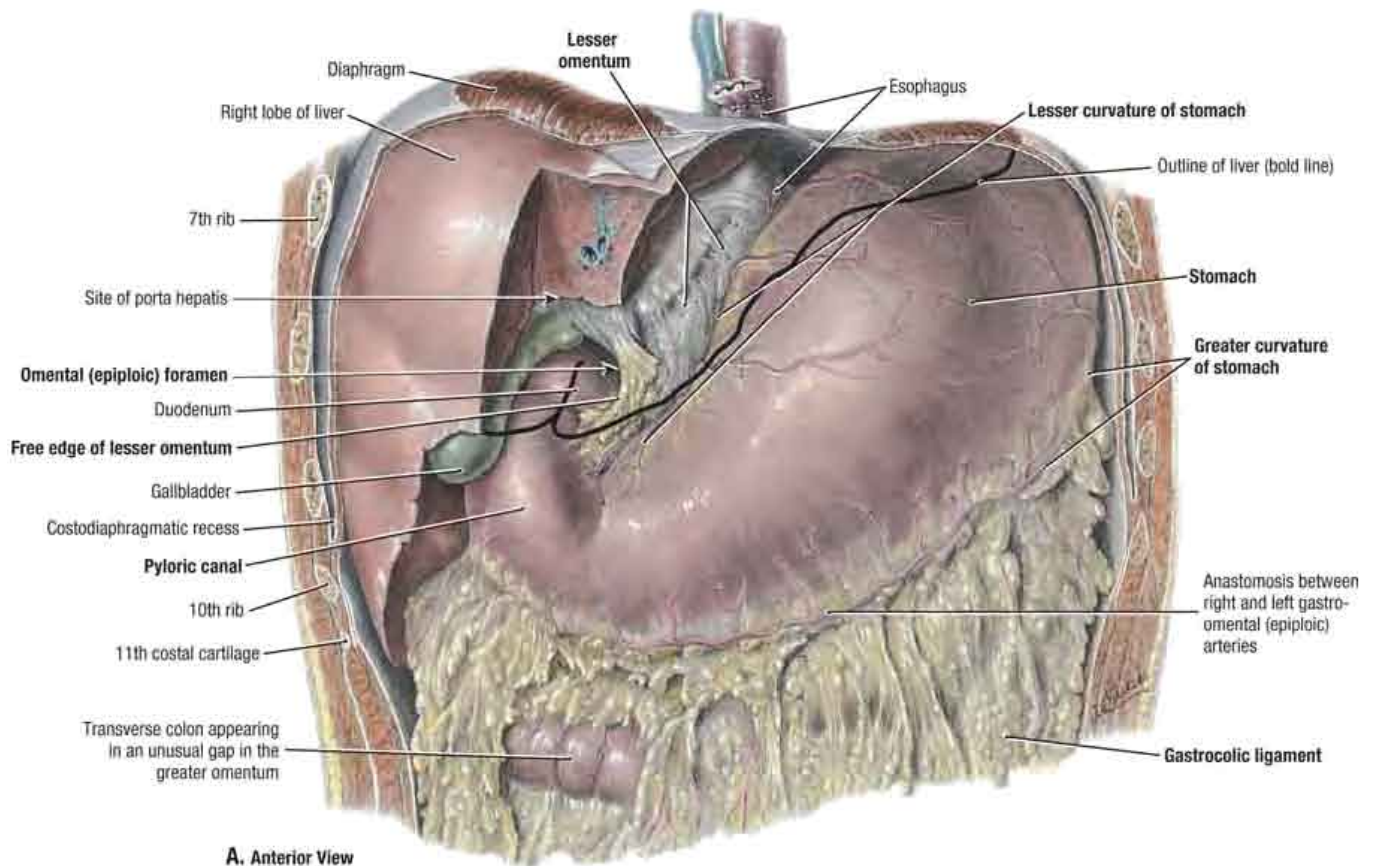
*Part of* "Chapter 2 - Abdomen "

A. Lesser and greater omenta. The stomach is inflated with air, and the left part of the liver is cut away. The gallbladder, followed superiorly, leads to the free margin of the lesser omentum and serves as a guide to the omental epiploic foramen, which lies posterior to that free margin. B. Omental bursa (lesser sac), schematic transverse section.

---

P.125





Authors: Agur, Anne M.R.; Dalley, Arthur F.

Title: *Grant's Atlas of Anatomy, 12th Edition*

Copyright ©2009 Lippincott Williams & Wilkins

> Table of Contents > Chapter 2 - Abdomen > 2.24 Posterior relationships of omental bursa (lesser sac)

---

## 2.24 Posterior relationships of omental bursa (lesser sac)

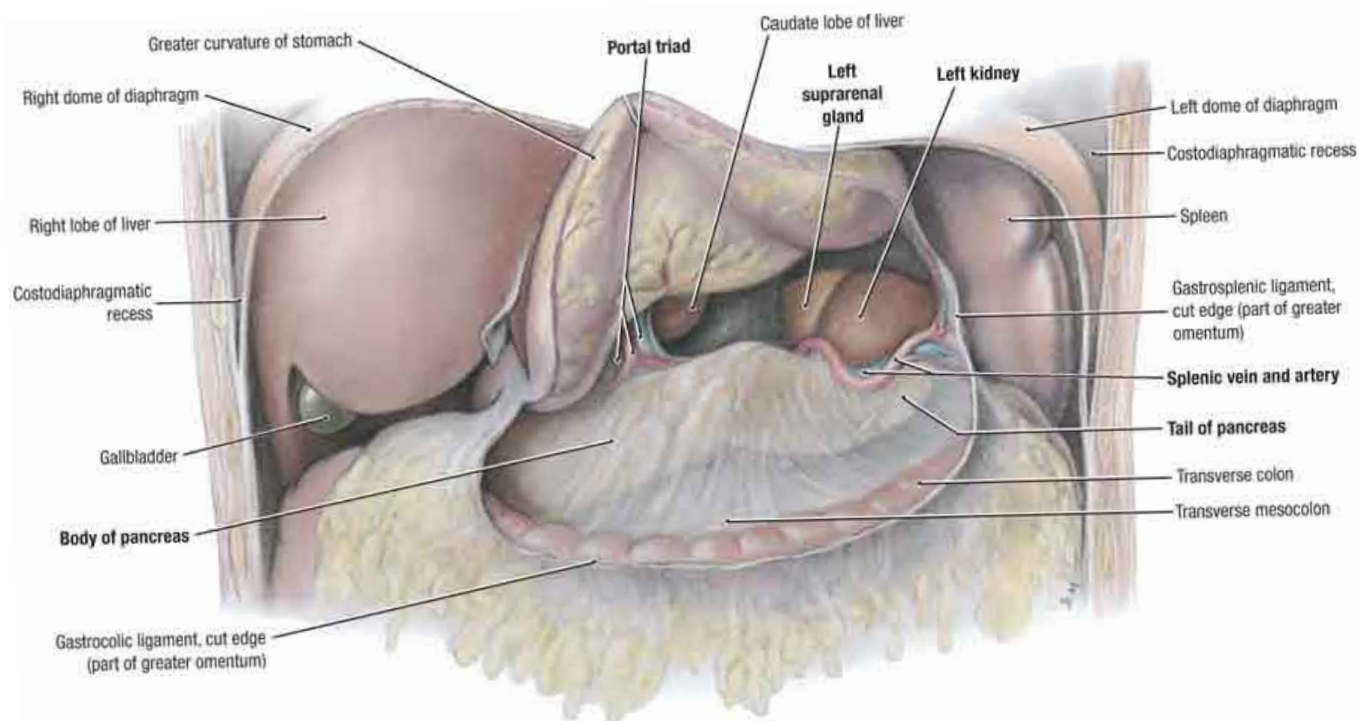
*Part of* "Chapter 2 - Abdomen "

A. Opened omental bursa. The greater omentum has been cut along the greater curvature of the stomach; the stomach is reflected superiorly. Peritoneum of the stomach bed is partially removed. B. Stomach bed. The stomach is excised. Peritoneum covering the stomach bed and inferior part of the kidney and pancreas is largely removed. Adhesions binding the spleen to the diaphragm are pathological, but not unusual.

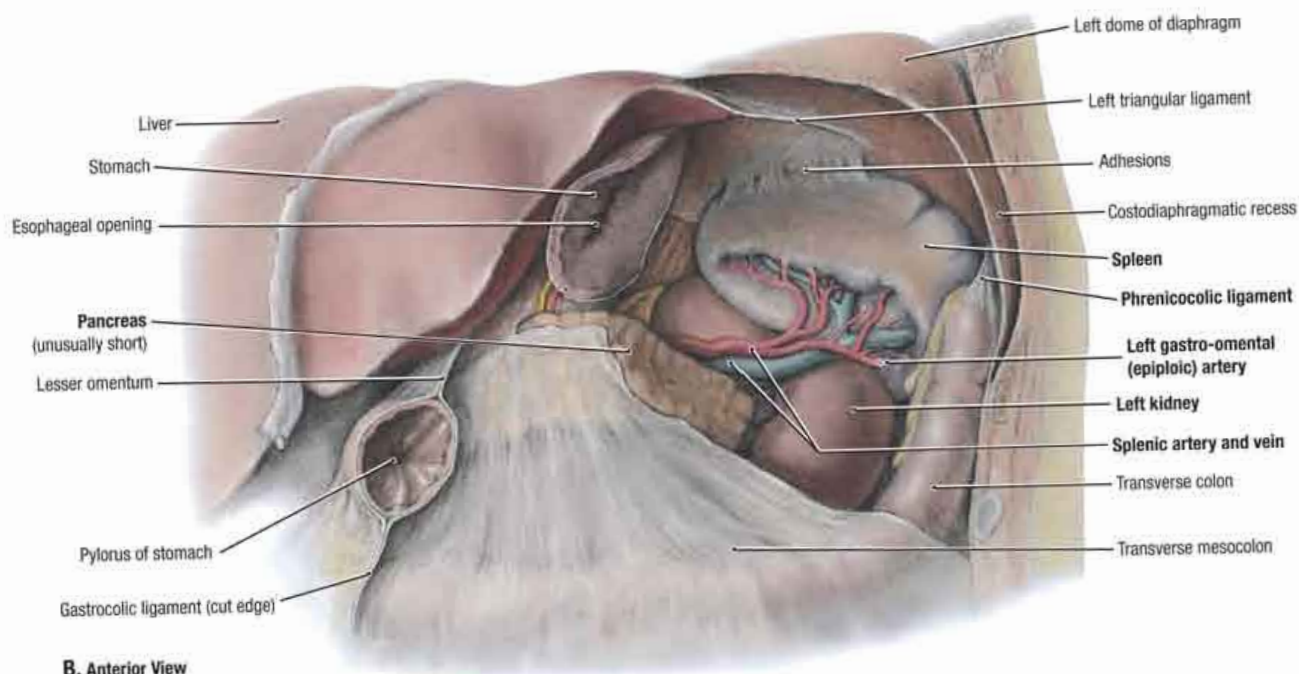
---

P.126





**A. Anterior View**



**B. Anterior View**

Authors: Agur, Anne M.R.; Dalley, Arthur F.

Title: *Grant's Atlas of Anatomy, 12th Edition*

Copyright ©2009 Lippincott Williams & Wilkins

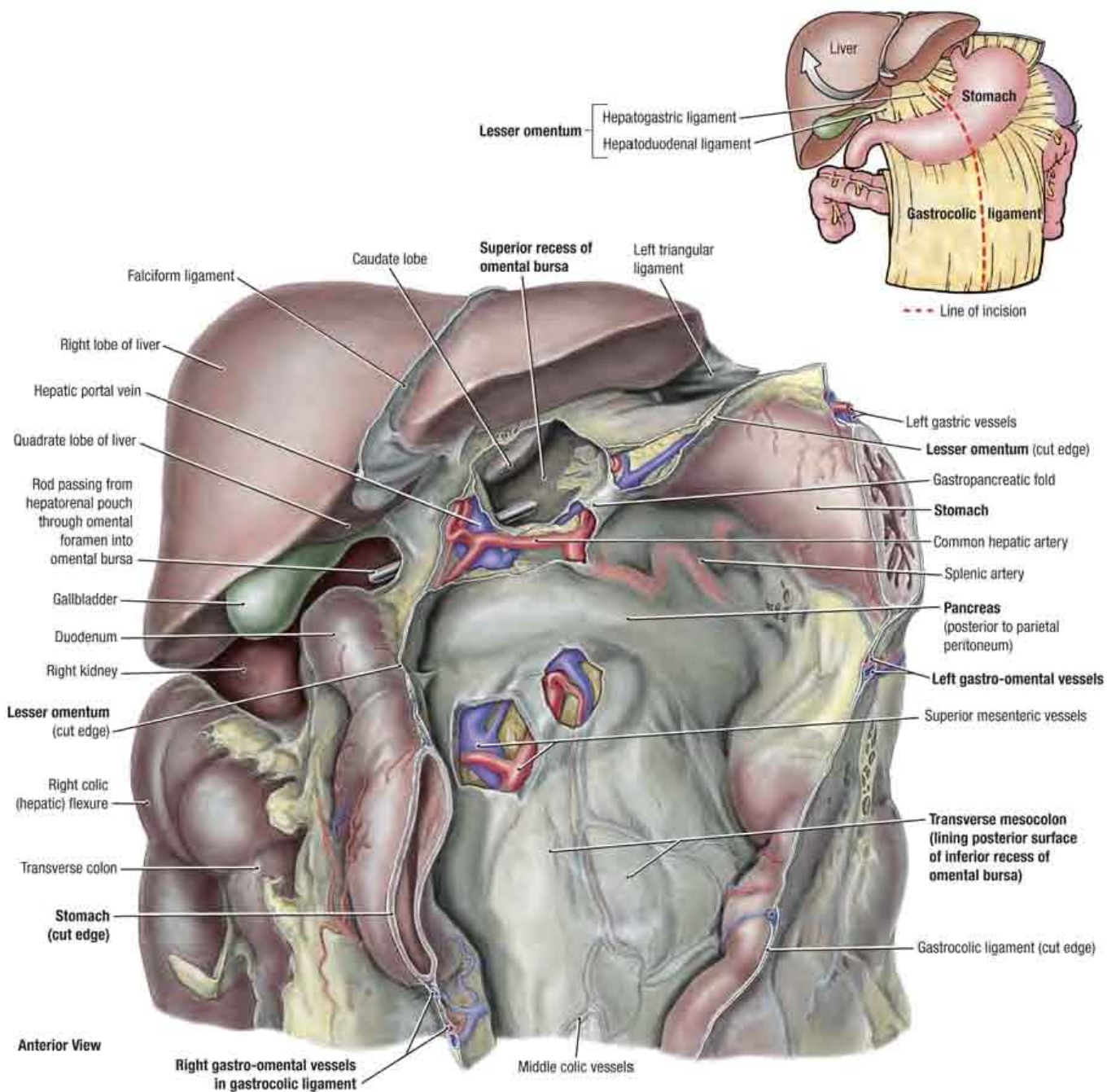
> Table of Contents > Chapter 2 - Abdomen > 2.25 Omental bursa (lesser sac), opened

---

## 2.25 Omental bursa (lesser sac), opened

*Part of* "Chapter 2 - Abdomen "

The anterior wall of the omental bursa, consisting of the stomach, lesser omentum, anterior layer of the greater omentum, and vessels along the curvatures of the stomach, has been sectioned sagittally. The two halves have been retracted to the left and right: the body of the stomach on the left side, and the pyloric part of the stomach and first part of the duodenum on the right. The right kidney forms the posterior wall of the hepatorenal pouch (part of greater sac), and the pancreas lies horizontally on the posterior wall of the main compartment of the omental bursa (lesser sac). The gastrocolic ligament forms the anterior wall and the lower part of the posterior wall of the inferior recess of the omental bursa. The transverse mesocolon forms the upper part of the posterior wall of the inferior recess of the omental bursa.



Authors: Agur, Anne M.R.; Dalley, Arthur F.

Title: *Grant's Atlas of Anatomy, 12th Edition*

Copyright ©2009 Lippincott Williams & Wilkins

> Table of Contents > Chapter 2 - Abdomen > 2.26 Posterior wall of omental bursa

---

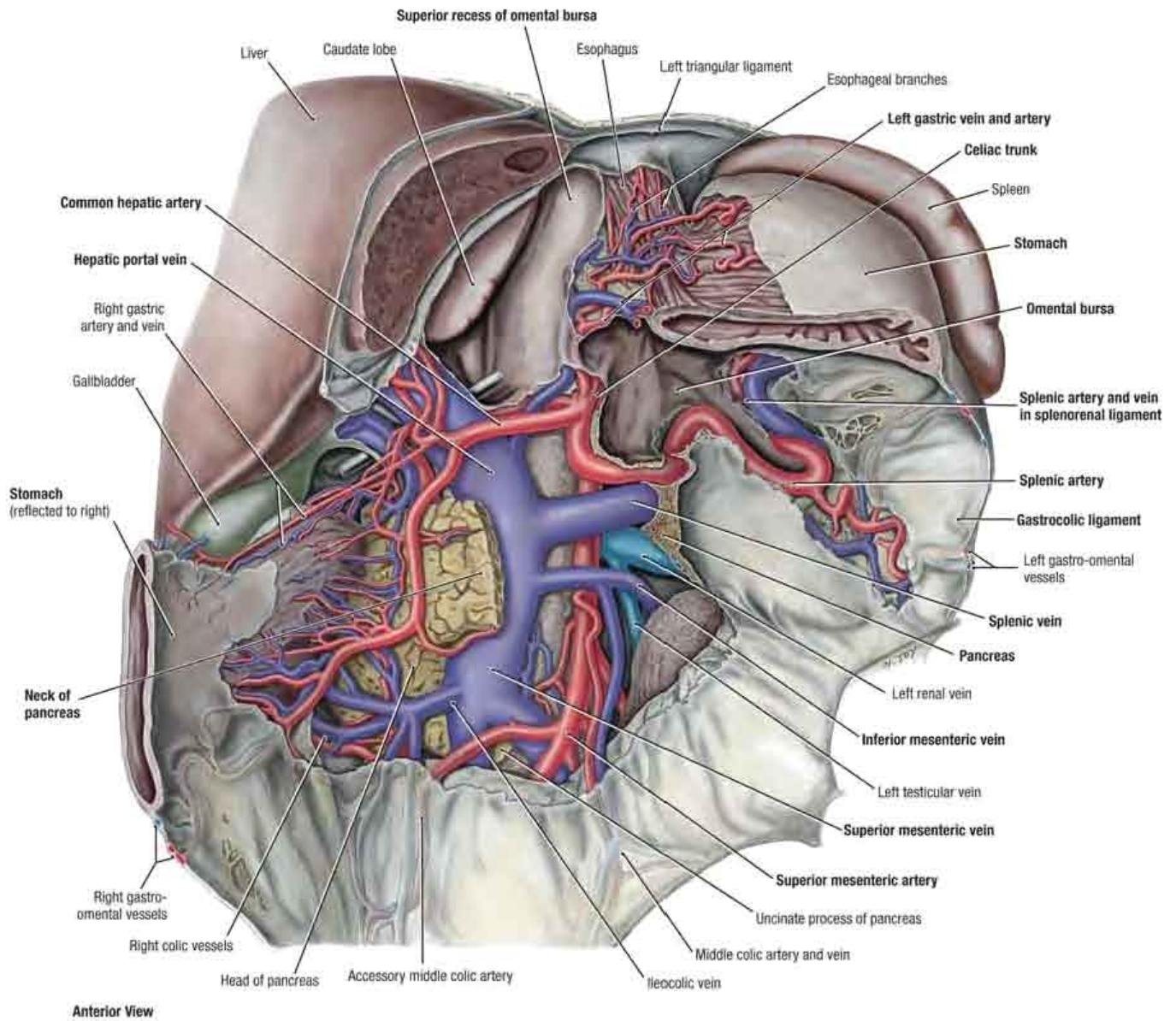
## 2.26 Posterior wall of omental bursa

*Part of* "Chapter 2 - Abdomen "

The parietal peritoneum of the posterior wall of the omental bursa has been mostly removed, and a section of the pancreas has been excised. The rod passes through the omental foramen.

- The celiac trunk gives rise to the left gastric artery, the splenic artery that runs tortuously to the left, and the common hepatic artery that runs to the right, passing anterior to the hepatic portal vein.
- The hepatic portal vein is formed posterior to the neck of the pancreas by the union of the superior mesenteric and splenic veins, with the inferior mesenteric vein joining at or near the angle of union.
- The left testicular vein usually drains into the left renal vein. Both are systemic veins.







Authors: Agur, Anne M.R.; Dalley, Arthur F.

Title: *Grant's Atlas of Anatomy, 12th Edition*

Copyright ©2009 Lippincott Williams & Wilkins

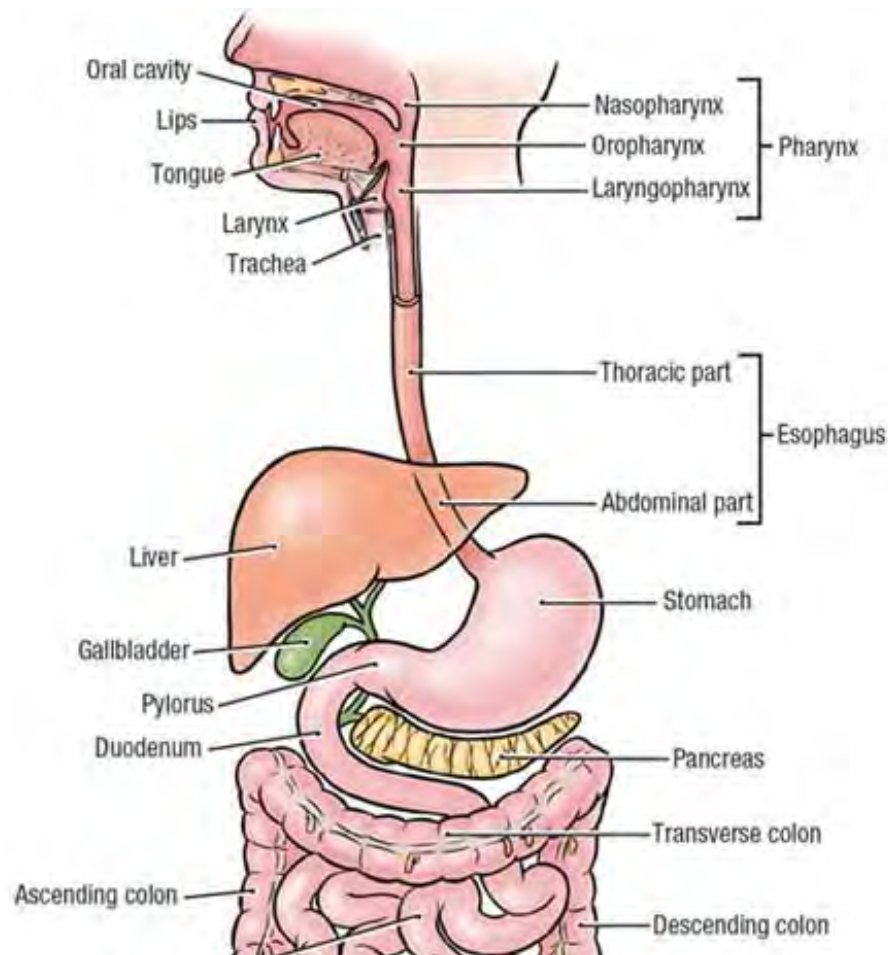
> Table of Contents > Chapter 2 - Abdomen > 2.27 Digestive system

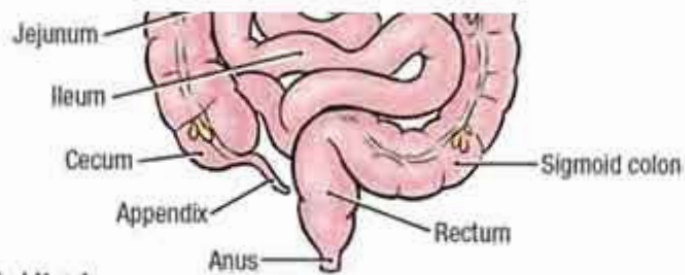
## 2.27 Digestive system

Part of "Chapter 2 - Abdomen"

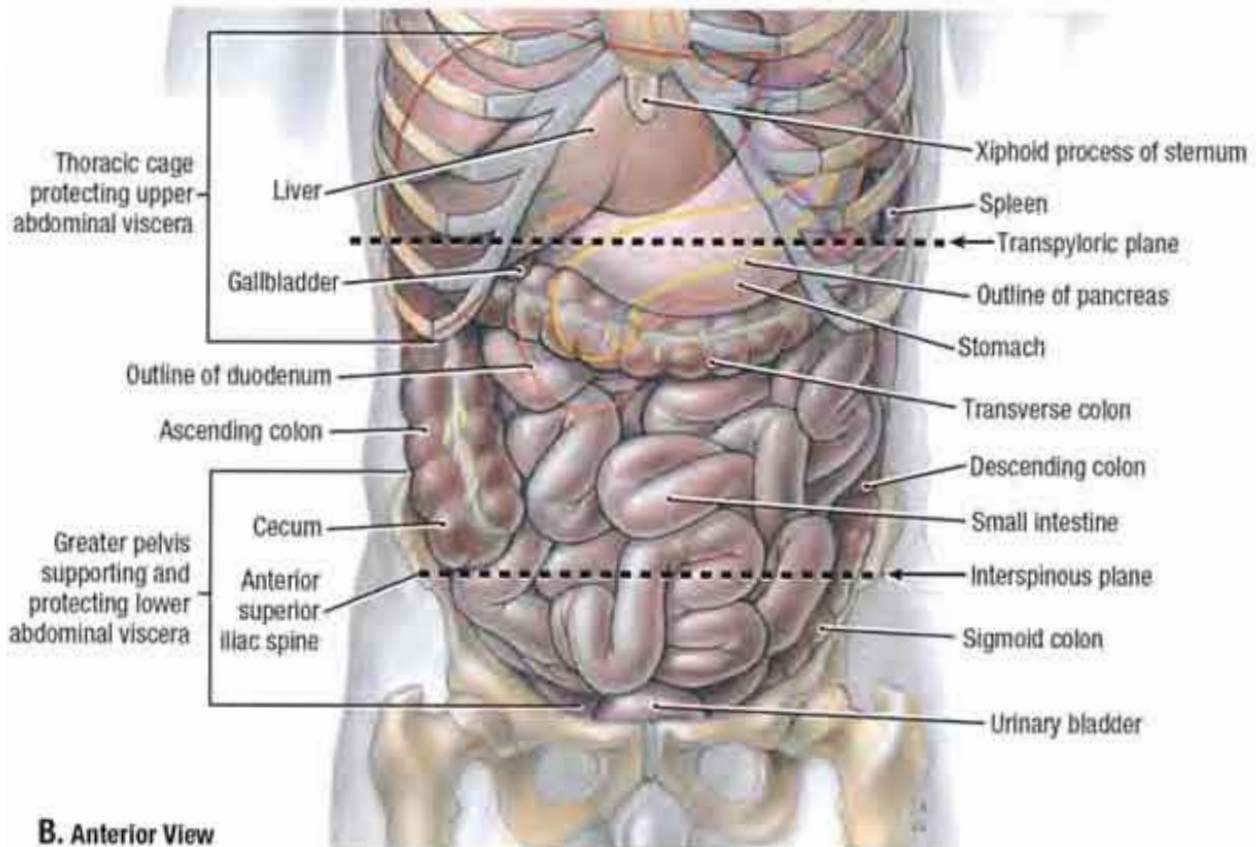
A. Schematic illustration. B. Abdominal portion. The digestive system extends from the lips to the anus. Associated organs include the liver, gallbladder, and pancreas.

P.129





**A. Anterior View;  
Medial View of Bisected Head**



**B. Anterior View**

Authors: Agur, Anne M.R.; Dalley, Arthur F.

Title: *Grant's Atlas of Anatomy, 12th Edition*

Copyright ©2009 Lippincott Williams & Wilkins

> Table of Contents > Chapter 2 - Abdomen > 2.28 Stomach

---

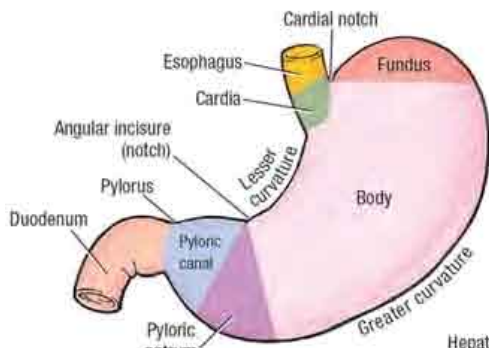
## 2.28 Stomach

*Part of* "Chapter 2 - Abdomen "

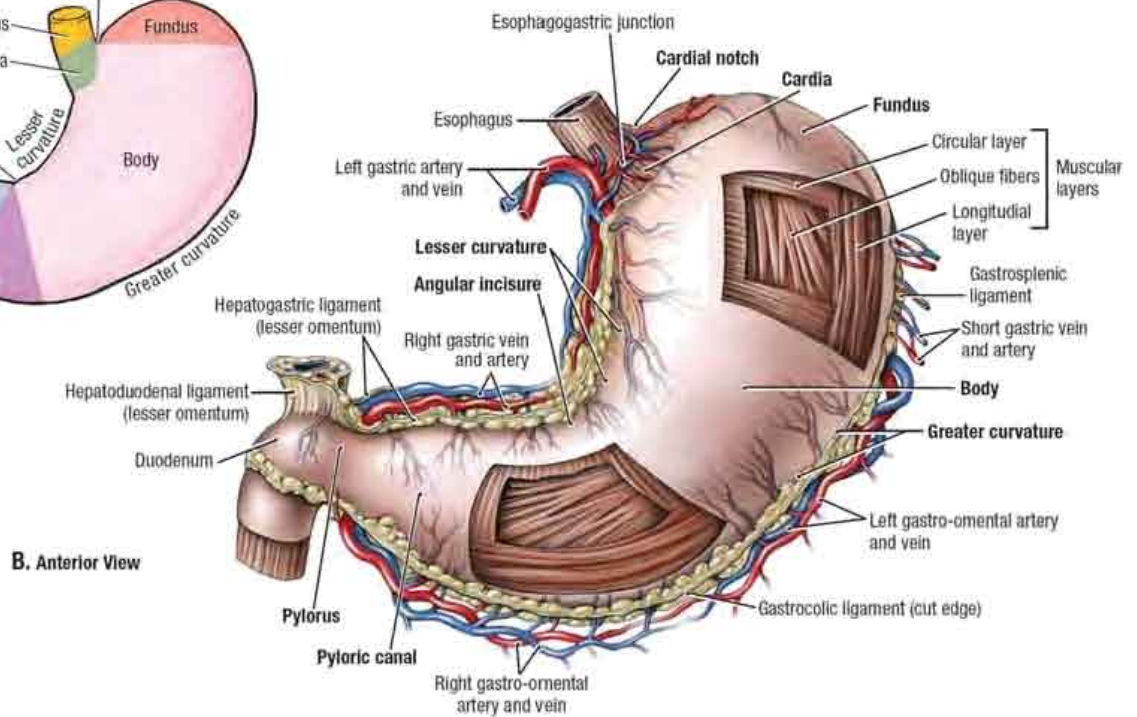
A. Parts. B. External surface. C. Internal surface (mucous membrane), anterior wall removed. Insets: Left side of page "pylorus, viewed from the duodenum. Right side of page "details of the esophagogastric junction.

---

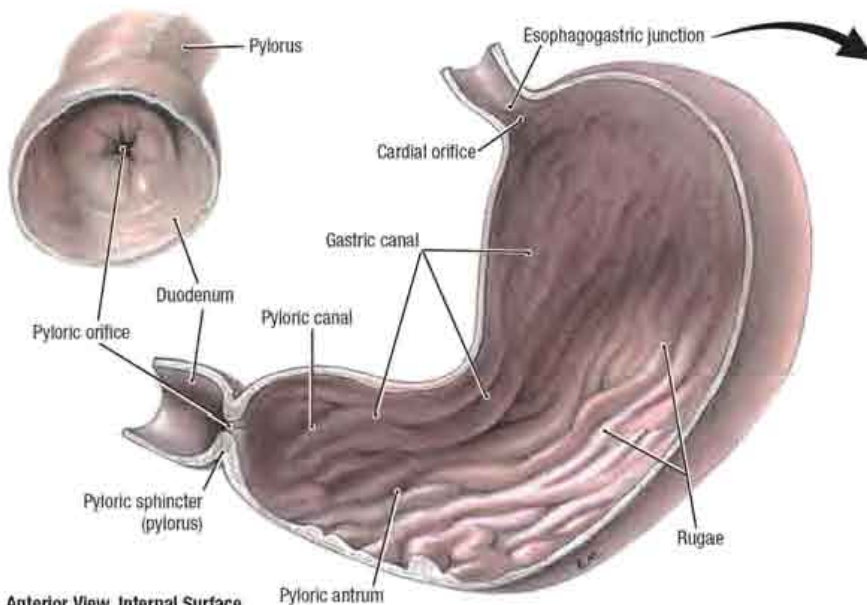
P.130



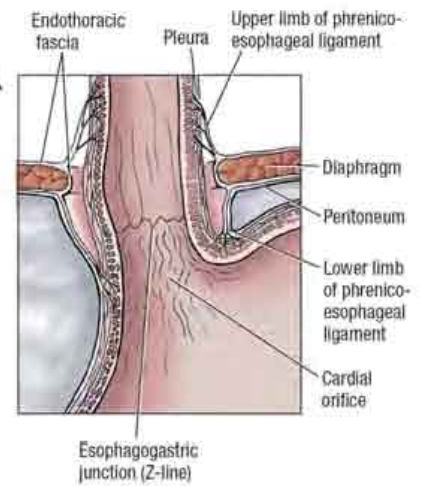
**A. Anterior View**



**B. Anterior View**



**C. Anterior View, Internal Surface**



Authors: Agur, Anne M.R.; Dalley, Arthur F.

Title: *Grant's Atlas of Anatomy, 12th Edition*

Copyright ©2009 Lippincott Williams & Wilkins

> Table of Contents > Chapter 2 - Abdomen > 2.29 Celiac artery

---

## 2.29 Celiac artery

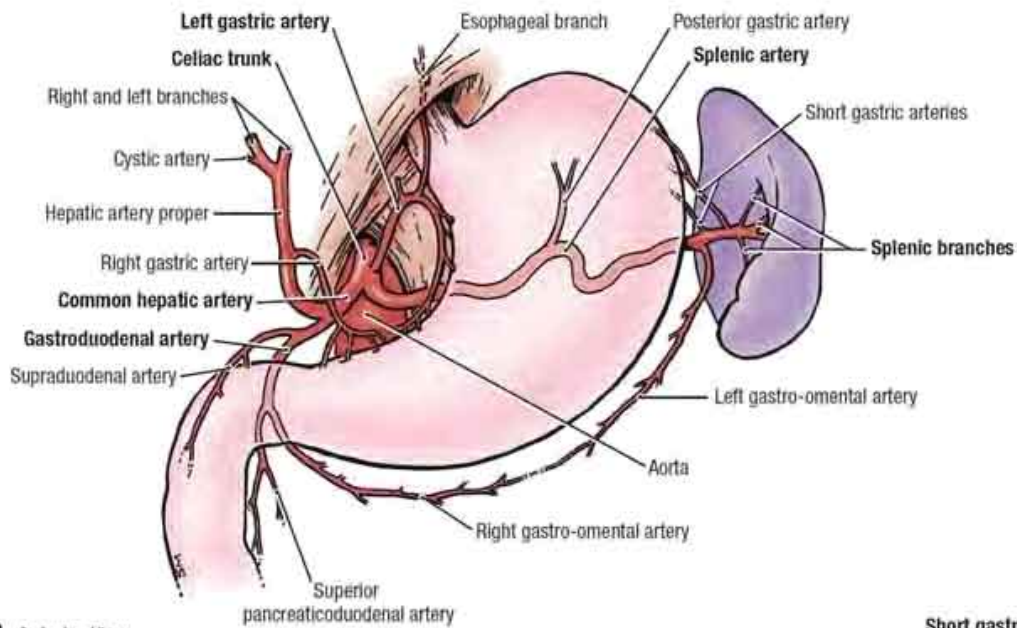
*Part of* "Chapter 2 - Abdomen "

A. Branches of celiac trunk. The celiac trunk is a branch of the abdominal aorta, arising immediately inferior to the aortic hiatus of the diaphragm (T12 vertebral level). The vessel is usually 1 to 2 cm long and divides into the left gastric, common hepatic, and splenic arteries. The celiac trunk supplies the liver, gall bladder, inferior esophagus, stomach, pancreas, spleen, and duodenum. B. Arteries of stomach and spleen. The serous and muscular coats are removed from two areas of the stomach, revealing anastomotic networks in the submucous coat.

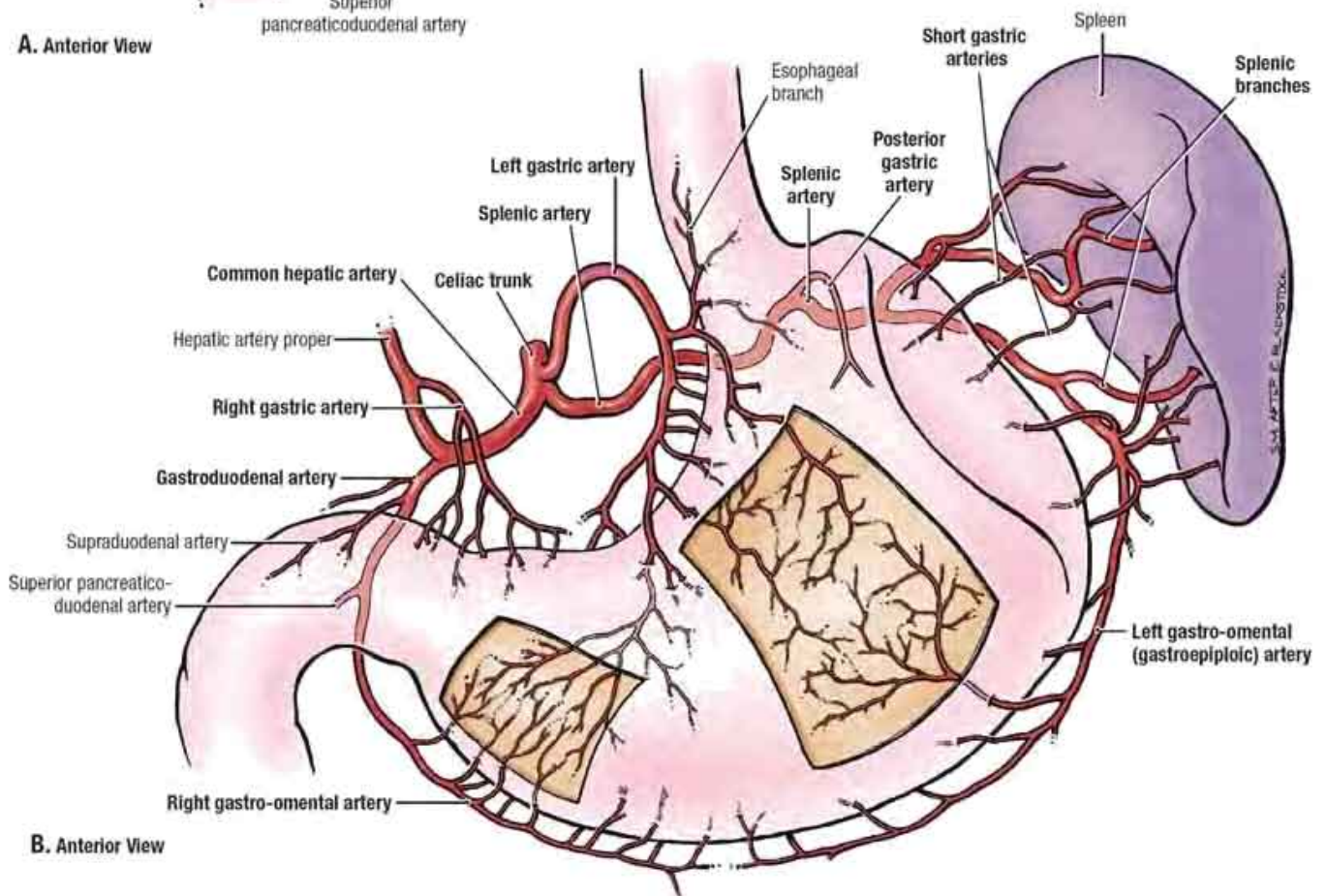
---

P.131





**A. Anterior View**



**B. Anterior View**

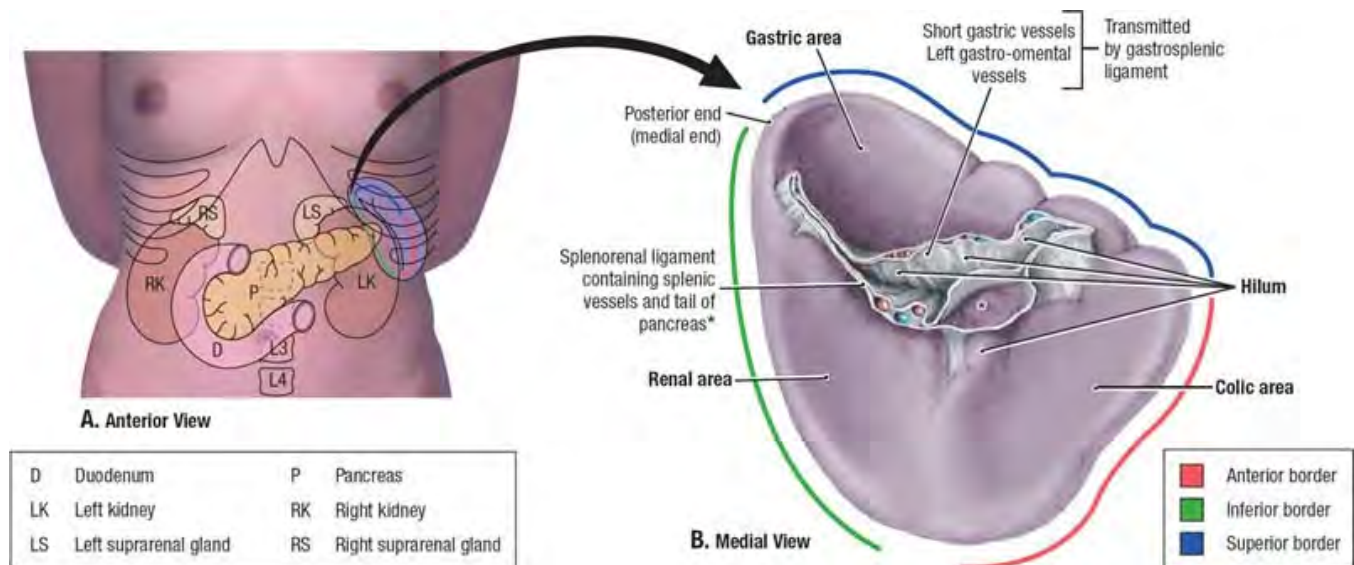
Authors: Agur, Anne M.R.; Dalley, Arthur F.  
Title: *Grant's Atlas of Anatomy, 12th Edition*  
Copyright ©2009 Lippincott Williams & Wilkins

> Table of Contents > Chapter 2 - Abdomen > 2.30 Spleen

## 2.30 Spleen

Part of "Chapter 2 - Abdomen "

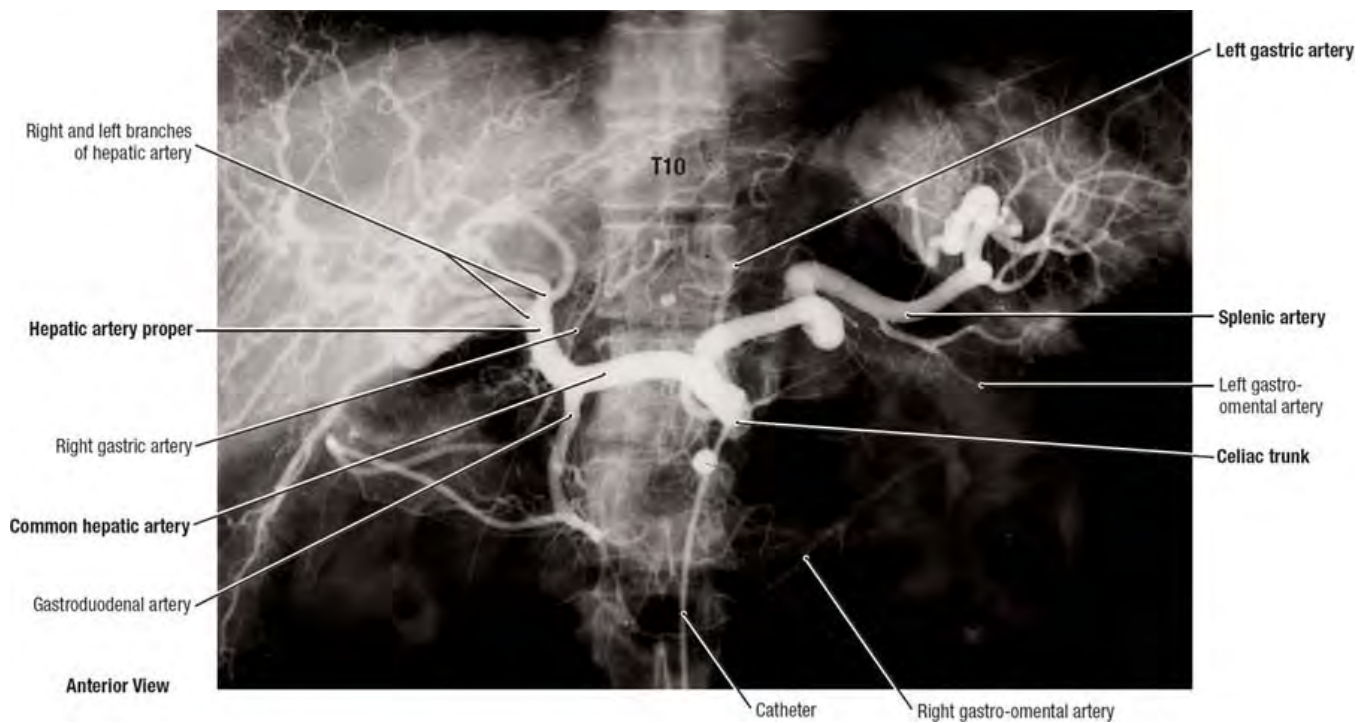
A. The surface anatomy of the spleen. The spleen lies superficially in the left upper abdominal quadrant between the 9th and 11th ribs. B. Note the impressions (colic, renal and gastric areas) made by structures in contact with its visceral surface. The superior border is notched.



## 2.31 Celiac arteriogram

Part of "Chapter 2 - Abdomen "

P.132



Authors: Agur, Anne M.R.; Dalley, Arthur F.

Title: *Grant's Atlas of Anatomy, 12th Edition*

Copyright ©2009 Lippincott Williams & Wilkins

> Table of Contents > Chapter 2 - Abdomen > 2.32 Radiographs of esophagus, stomach, duodenum (barium swallow)

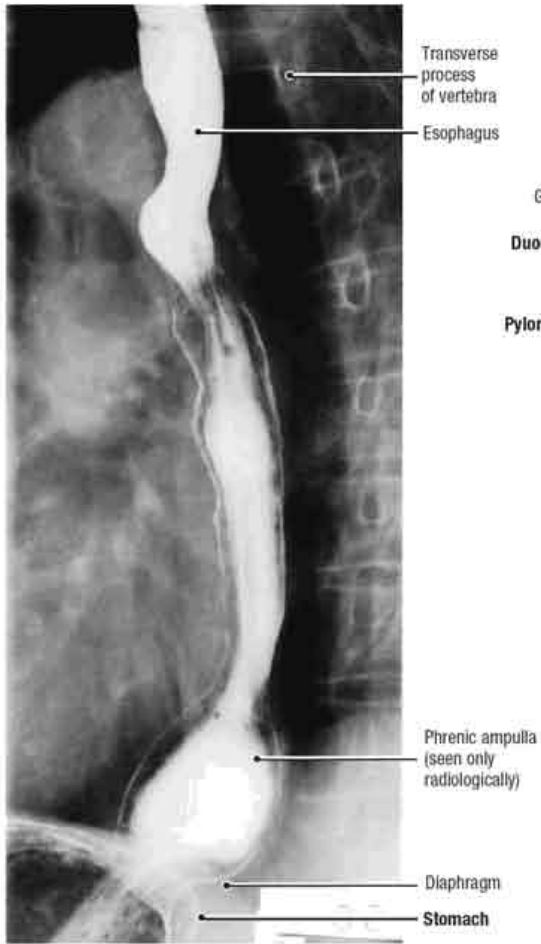
---

## 2.32 Radiographs of esophagus, stomach, duodenum (barium swallow)

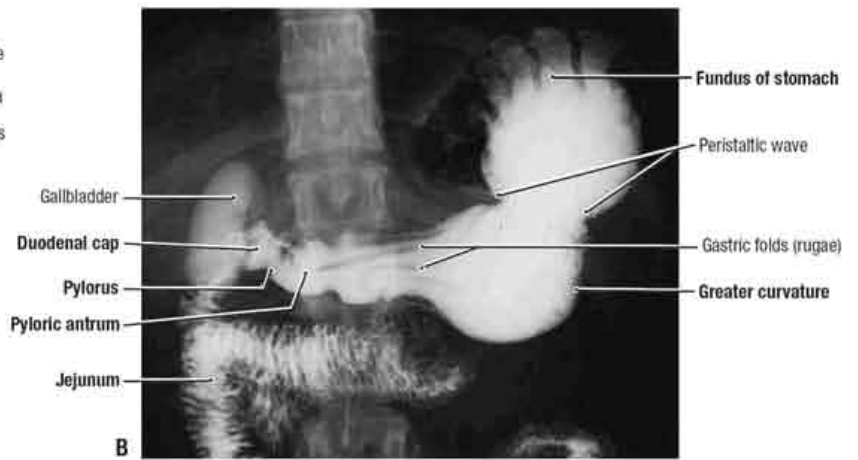
*Part of "Chapter 2 - Abdomen "*

A. Esophagus. The esophageal (phrenic) ampulla is the distensible portion of the esophagus seen only radiologically. B. Stomach, small intestine, and gallbladder. Note additional contrast medium in gallbladder. C. Stomach and duodenum. D. Pyloric antrum and duodenal cap.

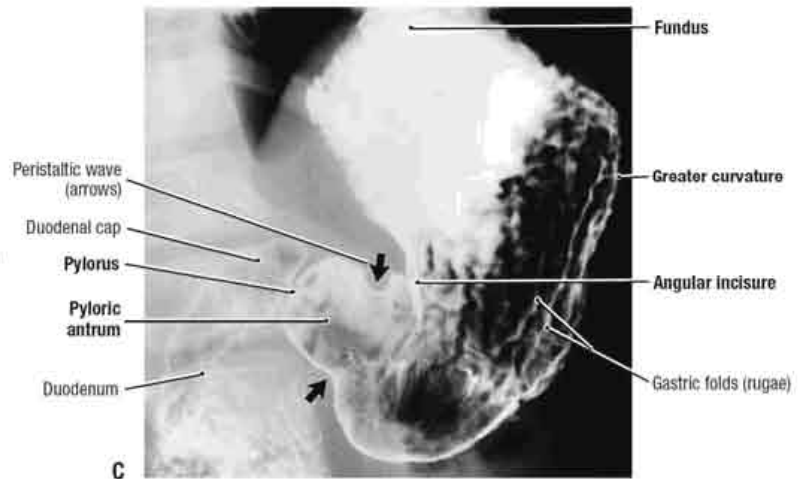
A hiatal—or hiatus—hernia is a protrusion of a part of the stomach into the mediastinum through the esophageal hiatus of the diaphragm. The hernias occur most often in people after middle age, possibly because of weakening of the muscular part of the diaphragm and widening of the esophageal hiatus.



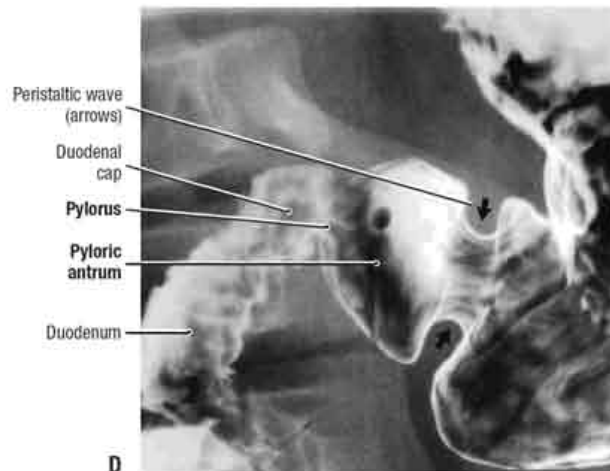
A. Lateral View



B



C



D

Anterior Views (B-D)



Authors: Agur, Anne M.R.; Dalley, Arthur F.

Title: *Grant's Atlas of Anatomy, 12th Edition*

Copyright ©2009 Lippincott Williams & Wilkins

> Table of Contents > Chapter 2 - Abdomen > 2.33 Parts and relationships of pancreas and duodenum

---

## 2.33 Parts and relationships of pancreas and duodenum

*Part of* "Chapter 2 - Abdomen "

A. Pancreas and duodenum in situ.

Superior (1 st part)

Peritoneum Gallbladder Quadrate lobe of liver

Bile duct Gastroduodenal artery Hepatic portal vein Inferior vena cava

Neck of gallbladder

Neck of pancreas

Anterolateral to L1 vertebra

Descending (2 nd part)

Transverse colon Transverse mesocolon Coils of small intestine

Hilum of right kidney Renal vessels Ureter Psoas major

Head of pancreas Pancreatic duct Bile duct

Right of L2–L3 vertebrae

Inferior (horizontal or 3 rd part)

Superior mesenteric artery Superior mesenteric vein Coils of small intestine

Right psoas major Inferior vena cava Aorta Right ureter

Head and uncinete process of pancreas Superior mesenteric artery and vein

Anterior to L3 vertebra

Ascending (4 th part)

Beginning of root of mesentery Coils of jejunum

Left psoas major Left margin of aorta

Superior mesenteric artery and vein

Body of pancreas

Left of L3 vertebra

Part of							Vertebral
Duodenum	Anterior	Posterior	Medial	Superior	Inferior		Level

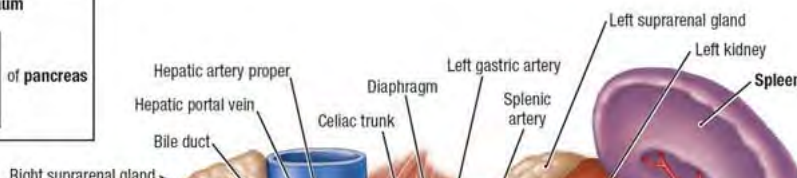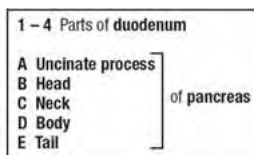
Table 2.3 Parts And Relationships Of Duodenum

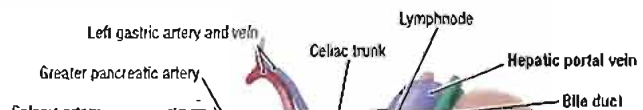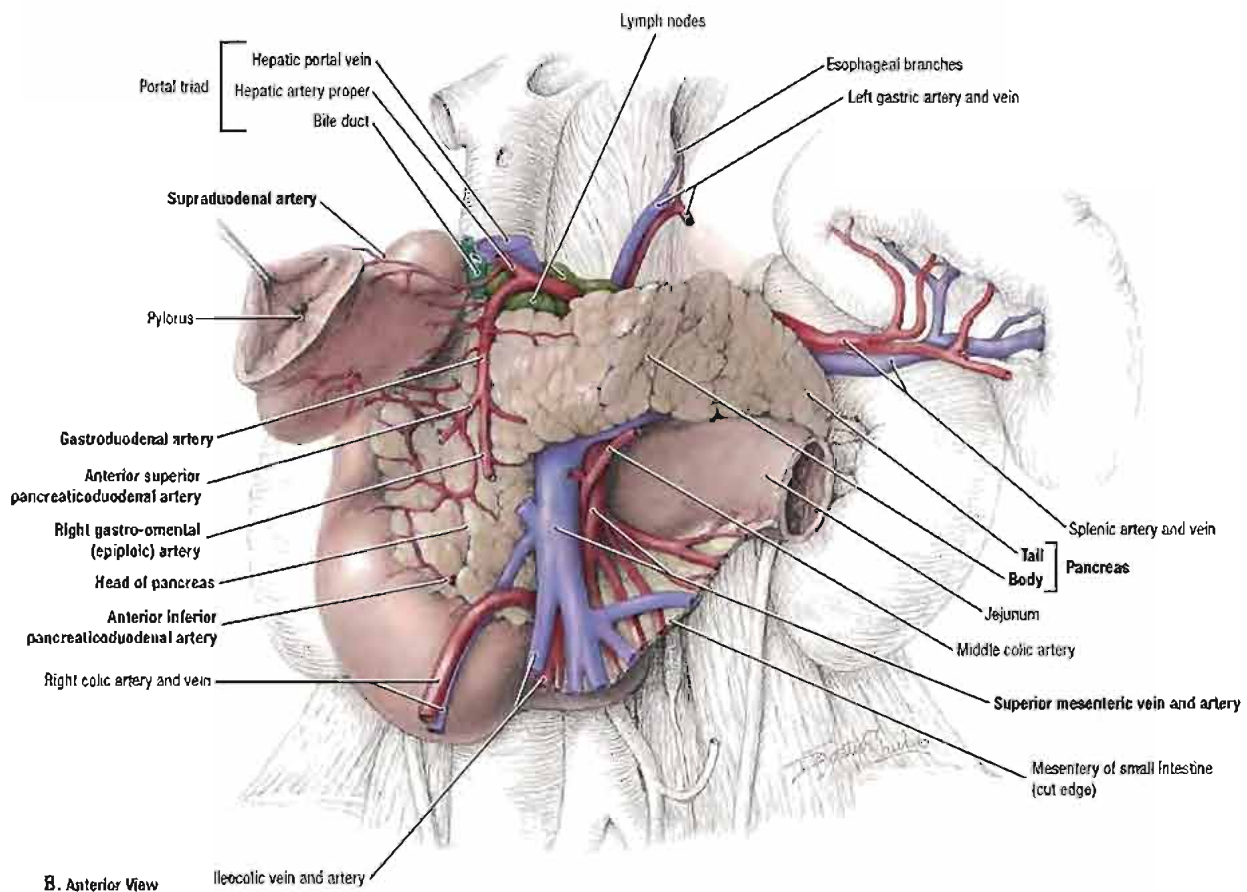
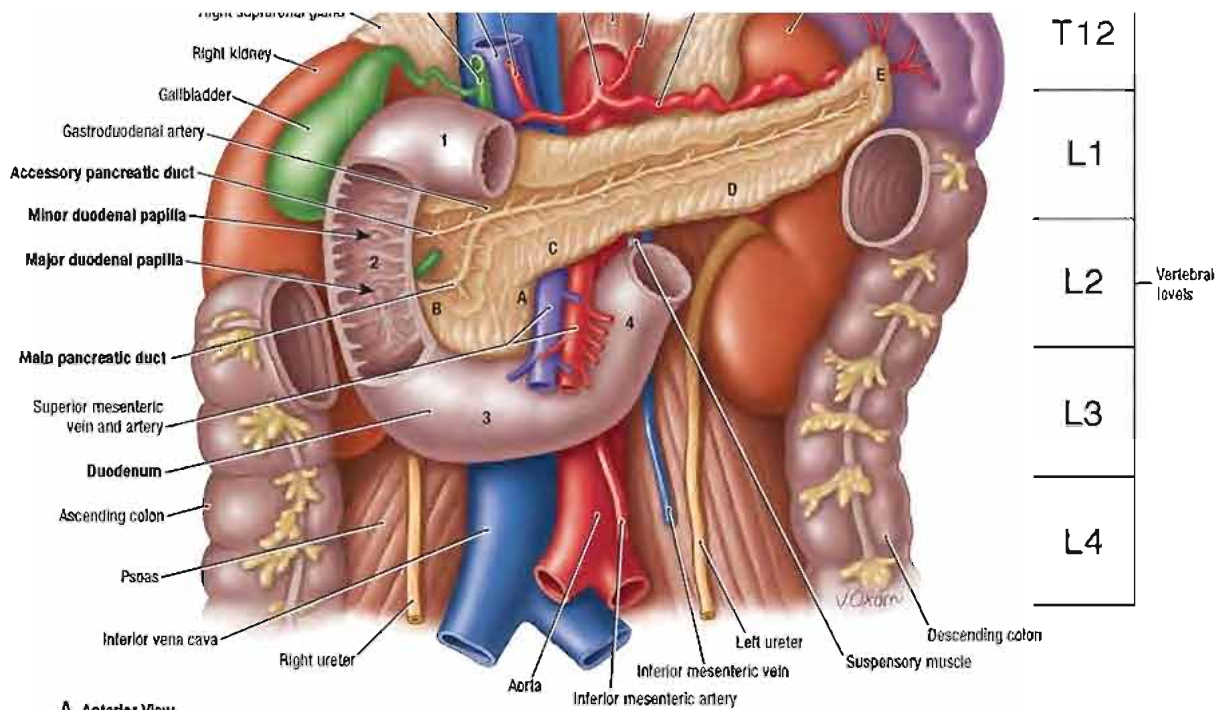
P.134

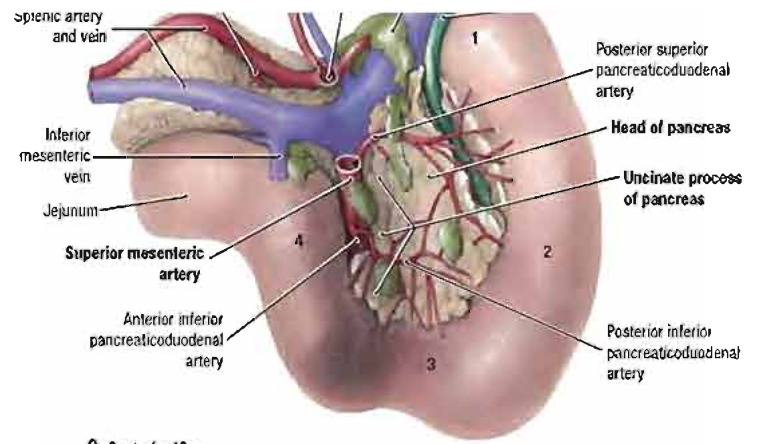
B. Anterior relationships. The gastroduodenal artery descends anterior to the neck of the pancreas. C. Posterior relationships. The splenic artery and vein course on the posterior aspect of the pancreatic tail, which usually extends to the spleen. The pancreas “œ loops” around the right side of the superior mesenteric vessels so that its neck is anterior, its head is to the right, and its uncinete process is posterior to the vessels. The splenic and superior mesenteric veins unite posterior to the neck to form the hepatic portal vein. The bile duct descends in a fissure (opened up) in the posterior part of the head of the pancreas.

Most inflammatory erosions of the duodenal wall, duodenal (peptic) ulcers, are in the posterior wall of the superior (1st) part of the duodenum within 3 cm of the pylorus.

P.135







C. Posterior View

Authors: Agur, Anne M.R.; Dalley, Arthur F.

Title: *Grant's Atlas of Anatomy, 12th Edition*

Copyright ©2009 Lippincott Williams & Wilkins

> Table of Contents > Chapter 2 - Abdomen > 2.34 Blood supply to the pancreas, duodenum, and spleen

---

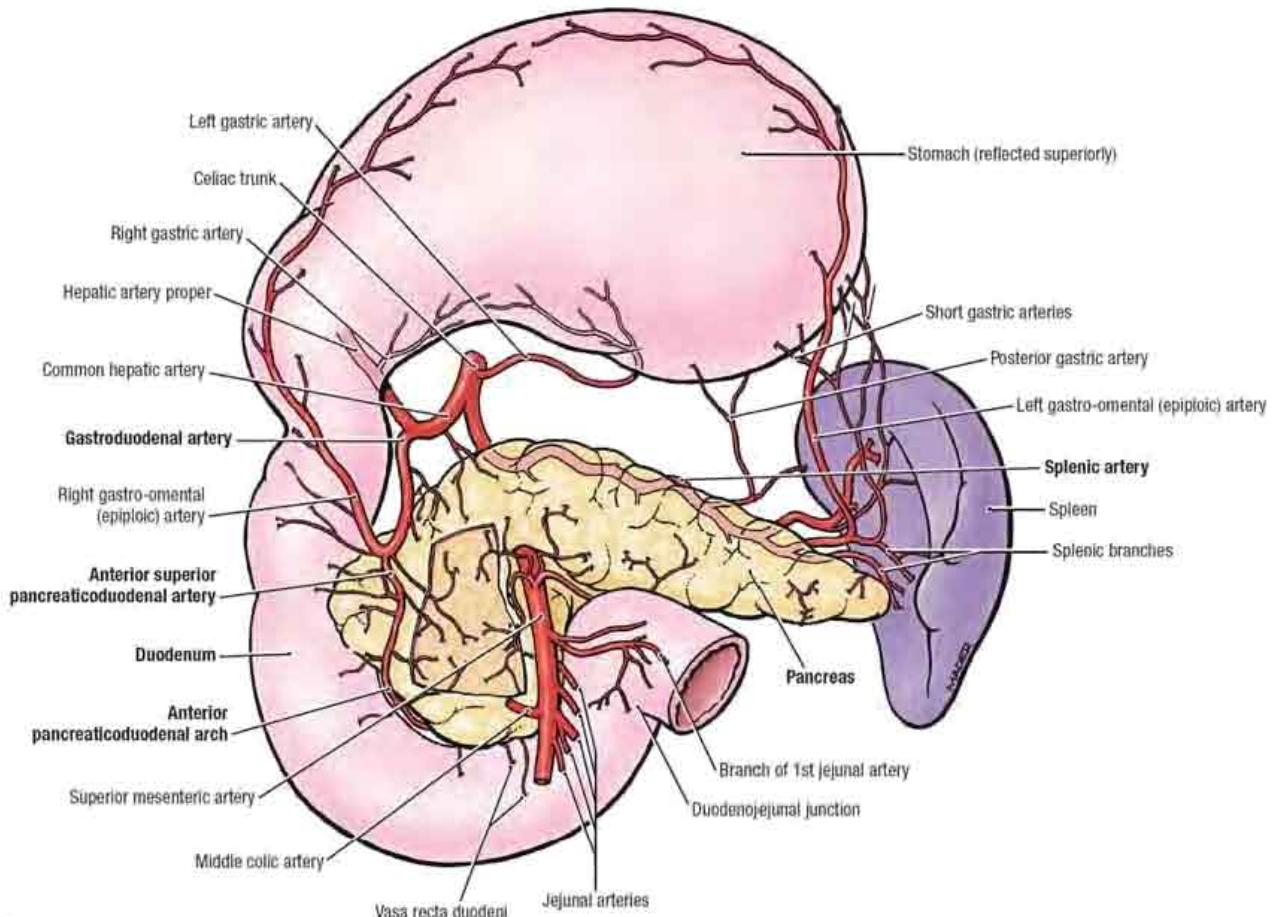
## 2.34 Blood supply to the pancreas, duodenum, and spleen

*Part of* "Chapter 2 - Abdomen "

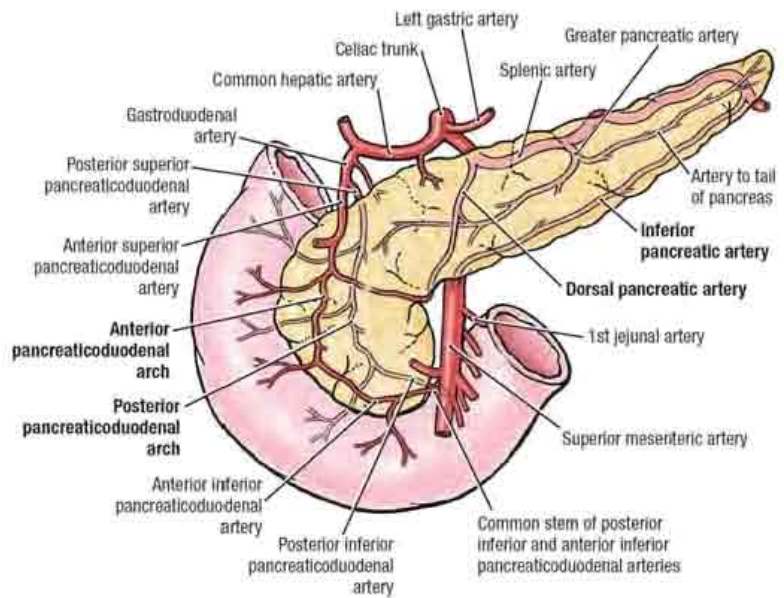
A. Celiac trunk and superior mesenteric artery. B. Pancreatic and pancreaticoduodenal arteries.

- The anterior superior pancreaticoduodenal artery from the gastroduodenal artery and the anterior inferior pancreaticoduodenal artery of the superior mesenteric artery form the anterior pancreaticoduodenal arch anterior to the head of the pancreas. The posterior superior and posterior inferior branches of the same two arteries form the posterior pancreaticoduodenal arch posterior to the pancreas. The anterior and posterior inferior arteries often arise from a common stem.
- Arteries supplying the pancreas are derived from the common hepatic artery, gastroduodenal artery, pancreaticoduodenal arches, splenic artery, and superior mesenteric artery.





**A. Anterior View, with Stomach Reflected Superiorly**



**B. Anterior View**

Authors: Agur, Anne M.R.; Dalley, Arthur F.

Title: *Grant's Atlas of Anatomy, 12th Edition*

Copyright ©2009 Lippincott Williams & Wilkins

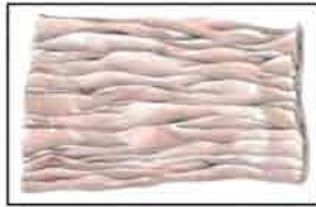
> Table of Contents > Chapter 2 - Abdomen > 2.35 Intestines in situ, interior of small intestine

---


## 2.35 Intestines in situ, interior of small intestine

*Part of* "Chapter 2 - Abdomen "

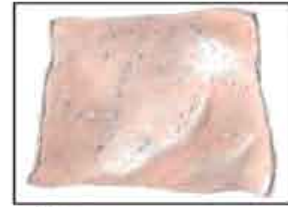A. Proximal jejunum. The circular folds are tall, closely packed, and commonly branched. B. Proximal ileum. The circular folds are low and becoming sparse. The caliber of the gut is reduced, and the wall is thinner. C. Distal ileum. Circular folds are absent, and solitary lymph nodules stud the wall. D. Intestines in situ, greater omentum reflected. The ileum is reflected to expose the appendix. The appendix usually lies posterior to the cecum (retrocecal) or, as in this case, projects over the pelvic brim. The features of the large intestines are the taeniae coli; haustra; and omental appendices.



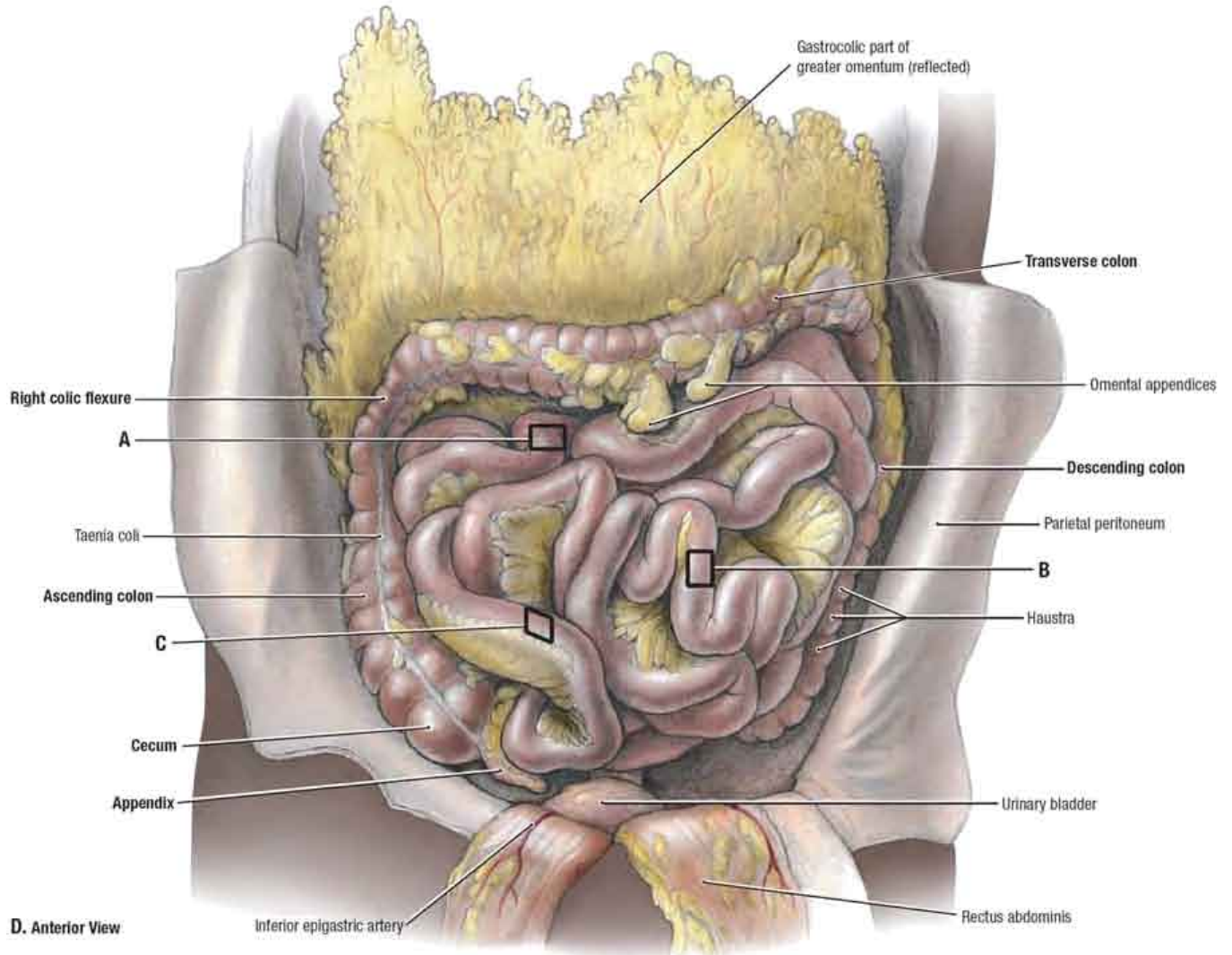
**A. Proximal Jejunum**



**B. Proximal Ileum**



**C. Distal Ileum**



Authors: Agur, Anne M.R.; Dalley, Arthur F.

Title: *Grant's Atlas of Anatomy, 12th Edition*

Copyright ©2009 Lippincott Williams & Wilkins

> Table of Contents > Chapter 2 - Abdomen > 2.36 Sigmoid mesocolon and mesentery of small intestine, interior of transverse colon

---

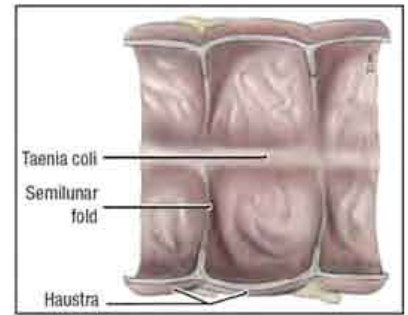
## 2.36 Sigmoid mesocolon and mesentery of small intestine, interior of transverse colon

*Part of* "Chapter 2 - Abdomen "

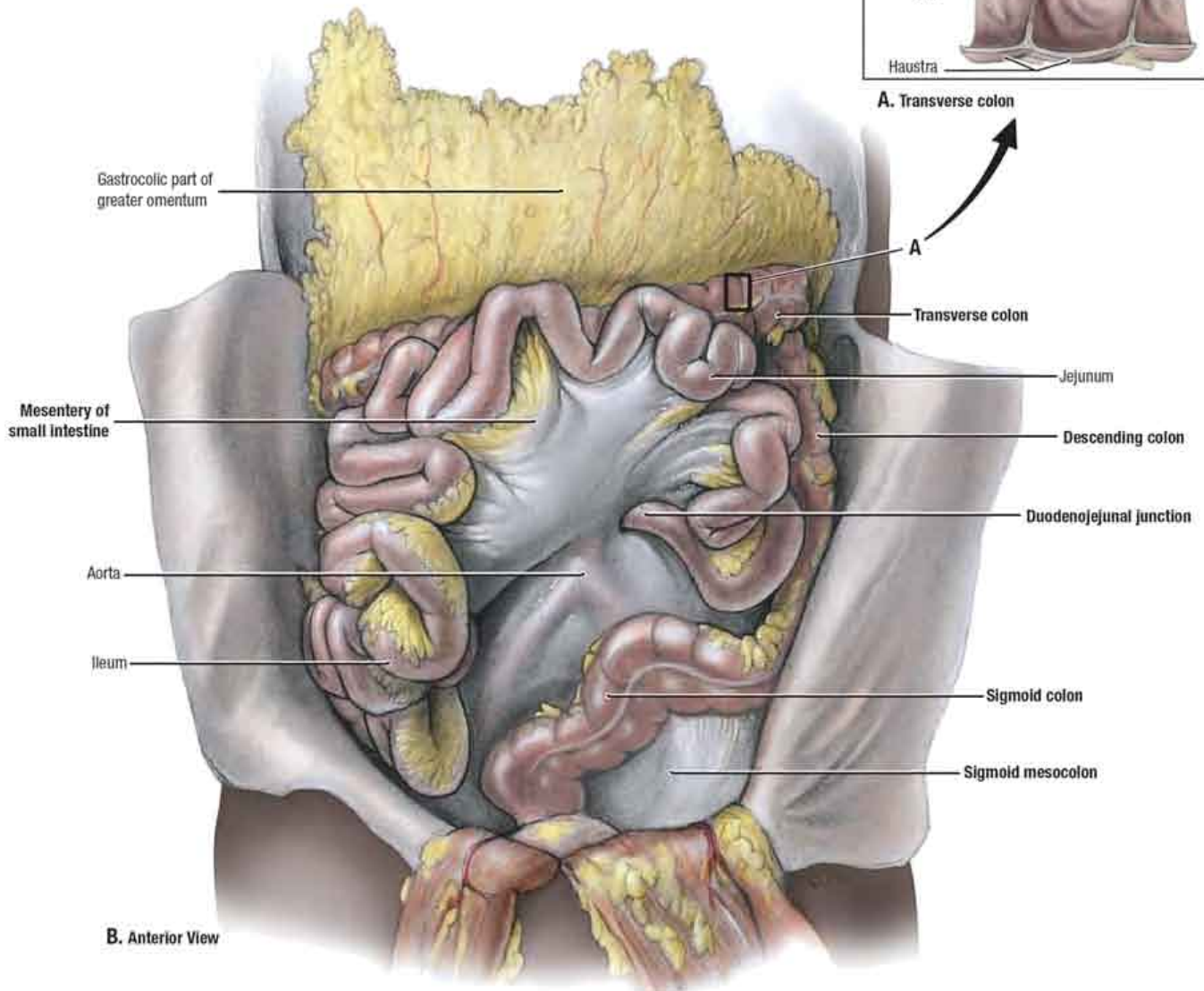
A. Transverse colon. The semilunar folds and taeniae coli form prominent features on the smooth-surfaced wall. B. Sigmoid mesocolon and mesentery of the small intestine.

- The duodenojejunal junction is situated to the left of the median plane.
- The mesentery of the small intestine fans out extensively from its short root to accommodate the length of jejunum and ileum (approximately 6m).
- The descending colon is the narrowest part of the large intestine and is retroperitoneal. The sigmoid colon has a mesentery, the sigmoid mesocolon; the sigmoid colon is continuous with the rectum at the point at which the sigmoid mesocolon ends.





**A. Transverse colon**





Authors: Agur, Anne M.R.; Dalley, Arthur F.

Title: *Grant's Atlas of Anatomy, 12th Edition*

Copyright ©2009 Lippincott Williams & Wilkins

> Table of Contents > Chapter 2 - Abdomen > 2.37 Barium enema and colonoscopy of colon

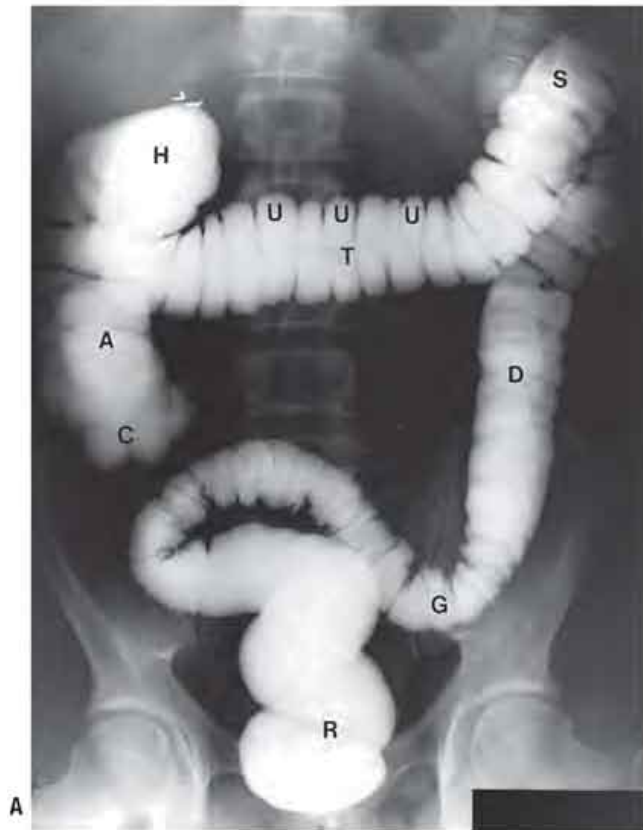
---

## 2.37 Barium enema and colonoscopy of colon

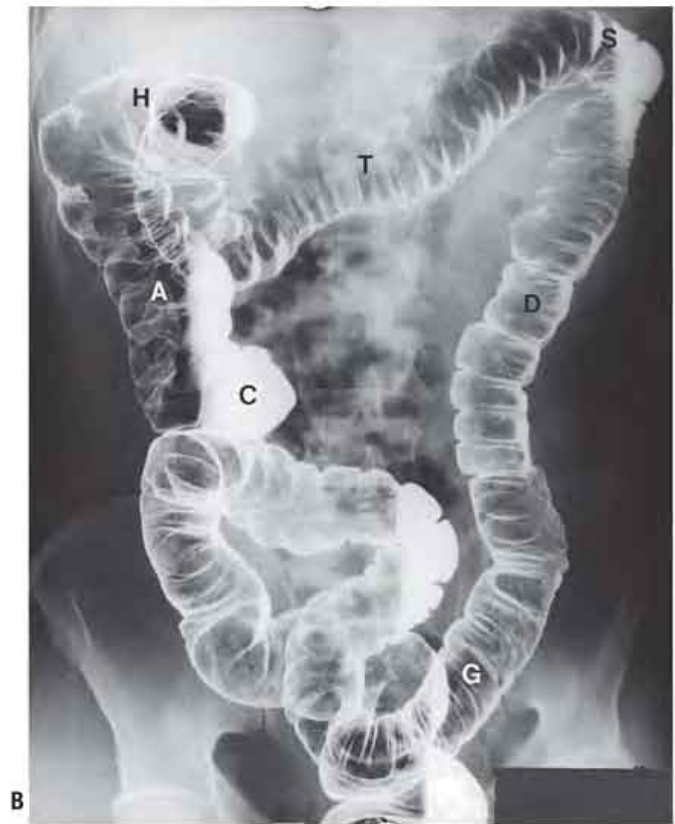
*Part of* "Chapter 2 - Abdomen "

A. Single-contrast study. A barium enema has filled the colon. B. Double-contrast study. Barium can be seen coating the walls of the colon, which is distended with air, providing a vivid view of the mucosal relief and haustra. C. The interior of the colon can be observed with an elongated endoscope, usually a fiberoptic flexible colonoscope. The endoscope is a tube that inserts into the colon through the anus and rectum. D. Diverticulosis of the colon can be photographed through a colonoscope.

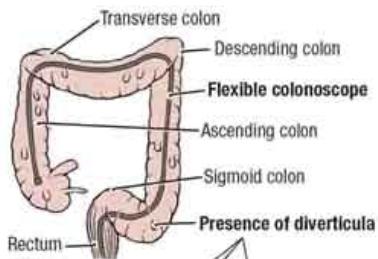
E. Diverticulosis is a disorder in which multiple false diverticula (external evaginations or out-pocketings of the mucosa of the colon) develop along the intestine. It primarily affects middle-aged and elderly people. Diverticulosis is commonly (60%) found in the sigmoid colon. Diverticula are subject to infection and rupture, leading to diverticulitis, and they can distort and erode the nutrient arteries, leading to hemorrhage.



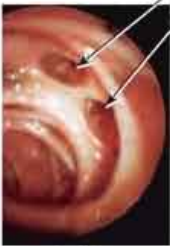**Posteroanterior Radiographs**



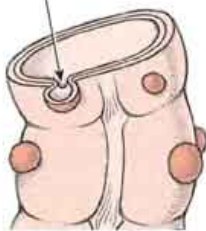
**B**



**C. Anterior View**



**D. Colonoscopic View**



**E. Diverticulosis**

A	Ascending colon	G	Sigmoid colon	S	Splenic flexure
C	Cecum	H	Hepatic flexure	T	Transverse colon
D	Descending colon	R	Rectum	U	Haustra

Authors: Agur, Anne M.R.; Dalley, Arthur F.

Title: *Grant's Atlas of Anatomy, 12th Edition*

Copyright ©2009 Lippincott Williams & Wilkins

> Table of Contents > Chapter 2 - Abdomen > 2.38 Ileocecal region and appendix

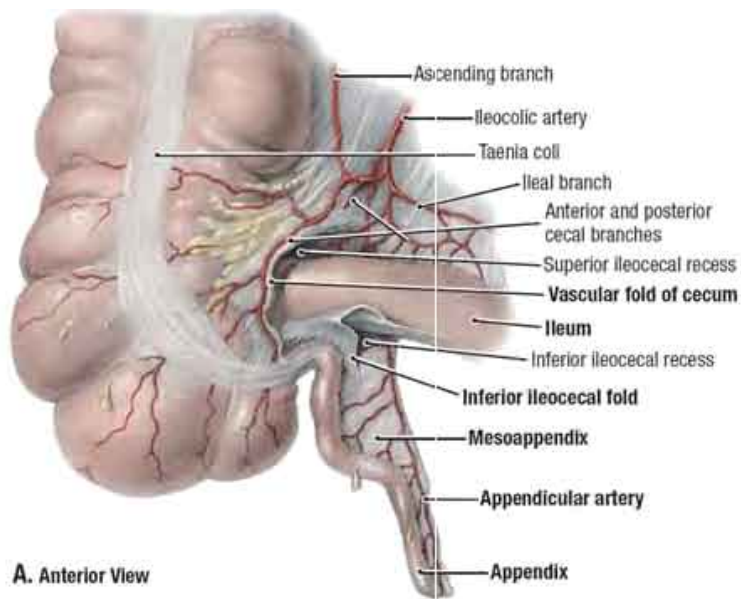
---

## 2.38 Ileocecal region and appendix

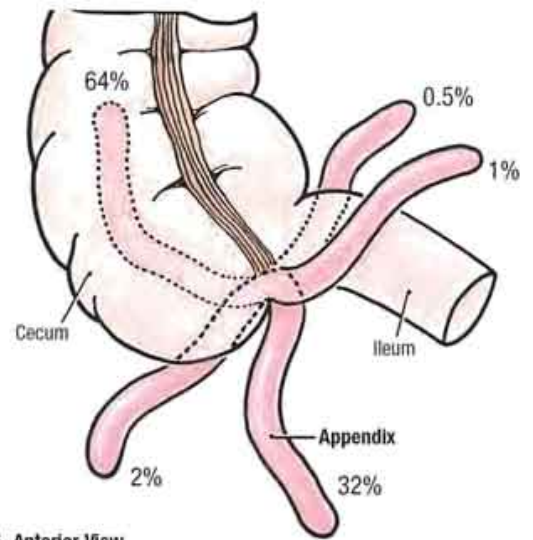
*Part of "Chapter 2 - Abdomen "*

A. Blood supply. The appendicular artery is located in the free edge of the mesoappendix. The inferior ileocecal fold is bloodless, whereas the superior ileocecal fold is called the vascular fold of the cecum. B. The approximate incidence of various locations of the appendix. C. Interior of a dried cecum and ileal diverticulum (of Meckel). This cecum was filled with air until dry, opened, and varnished.

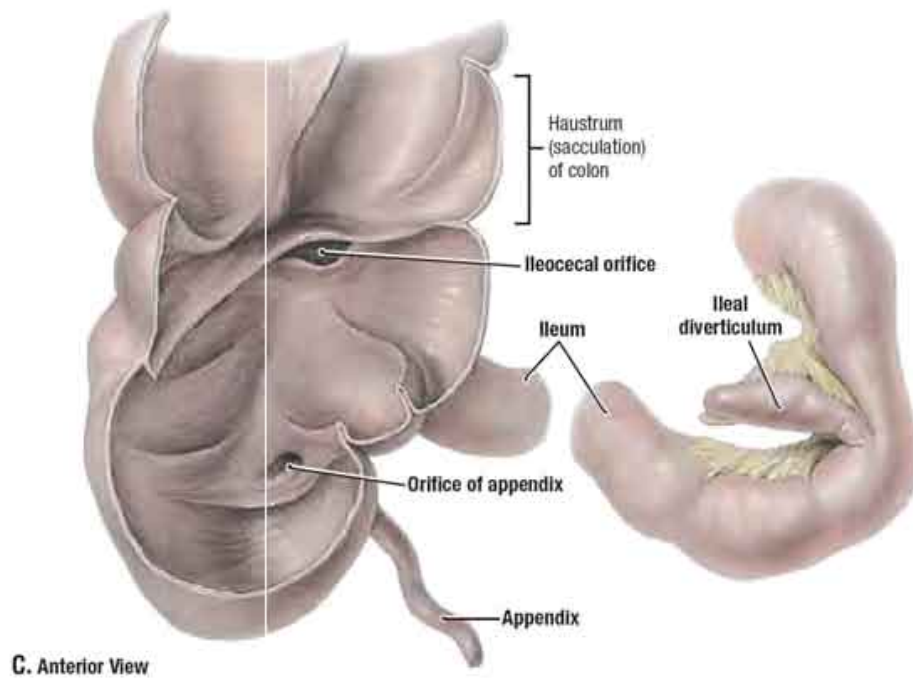
Ileal diverticulum is a congenital anomaly that occurs in 1 to 2% of persons. It is a pouchlike remnant (3–6 cm long) of the proximal part of the yolk stalk, typically within 50 cm of the ileocecal junction. It sometimes becomes inflamed and produces pain that may mimic that produced by appendicitis.



A. Anterior View



B. Anterior View



C. Anterior View

Authors: Agur, Anne M.R.; Dalley, Arthur F.

Title: *Grant's Atlas of Anatomy, 12th Edition*

Copyright ©2009 Lippincott Williams & Wilkins

> Table of Contents > Chapter 2 - Abdomen > 2.39 Superior mesenteric artery and arterial arcades

---

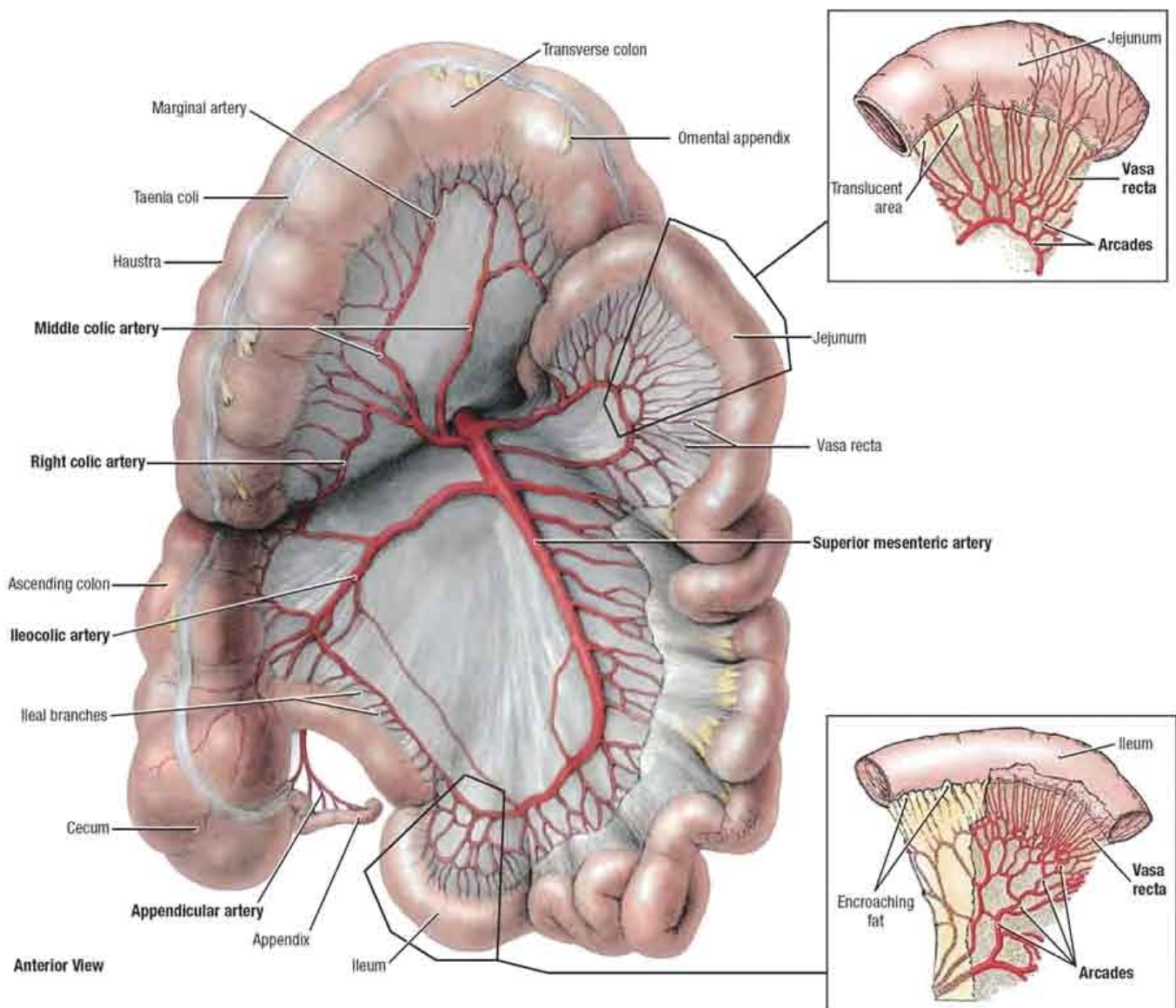
## 2.39 Superior mesenteric artery and arterial arcades

*Part of* "Chapter 2 - Abdomen "

The peritoneum is partially stripped off.

- The superior mesenteric artery ends by anastomosing with one of its own branches, the ileal branch of the ileocolic artery.
  - On the inset drawings of jejunum and ileum compare the diameter, thickness of wall, number of arterial arcades, long or short vasa recta, presence of translucent (fat free) areas at the mesenteric border, and fat encroaching on the wall of the gut between the jejunum and ileum.
- Acute inflammation of the appendix is a common cause of an acute abdomen (severe abdominal pain arising suddenly). The pain of appendicitis usually commences as a vague pain in the periumbilical region because afferent pain fibers enter the spinal cord at the T10 level. Later, severe pain in the right lower quadrant results from irritation of the parietal peritoneum lining the posterior abdominal wall.





Authors: Agur, Anne M.R.; Dalley, Arthur F.

Title: *Grant's Atlas of Anatomy, 12th Edition*

Copyright ©2009 Lippincott Williams & Wilkins

> Table of Contents > Chapter 2 - Abdomen > 2.40 Superior mesenteric arteriograms

---

## 2.40 Superior mesenteric arteriograms

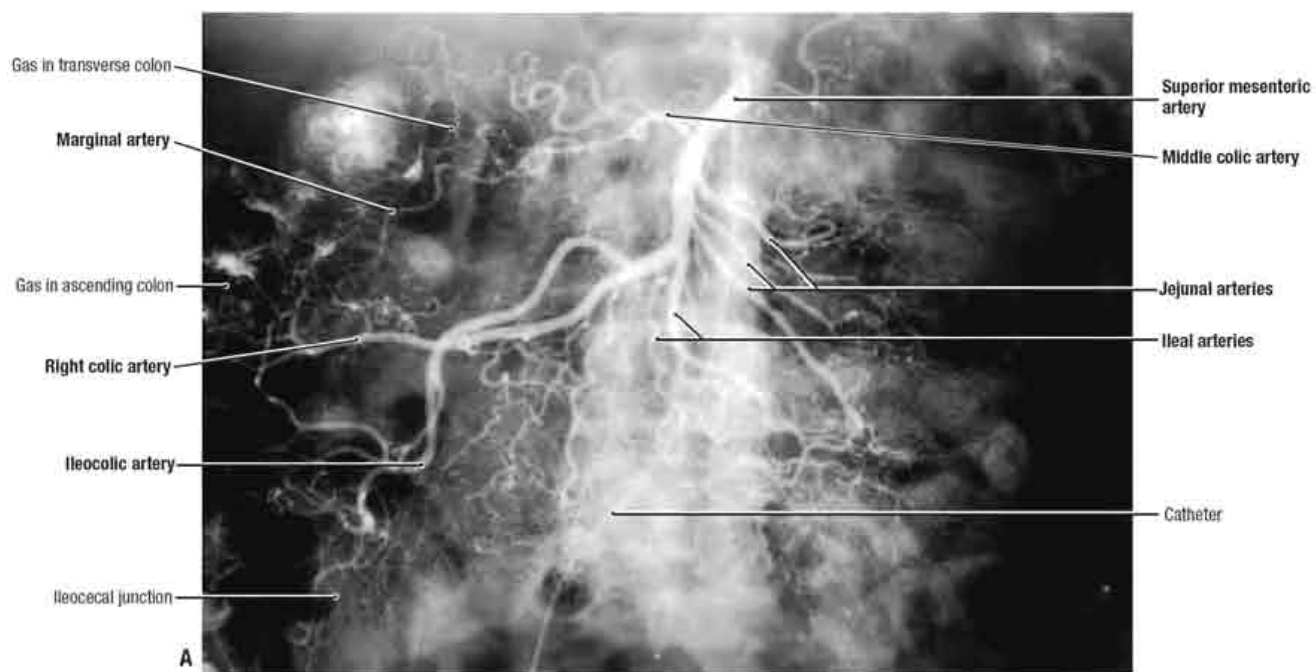
*Part of "Chapter 2 - Abdomen "*

A. Branches of superior mesenteric artery. Consult Figure 2.39 to identify the branches.

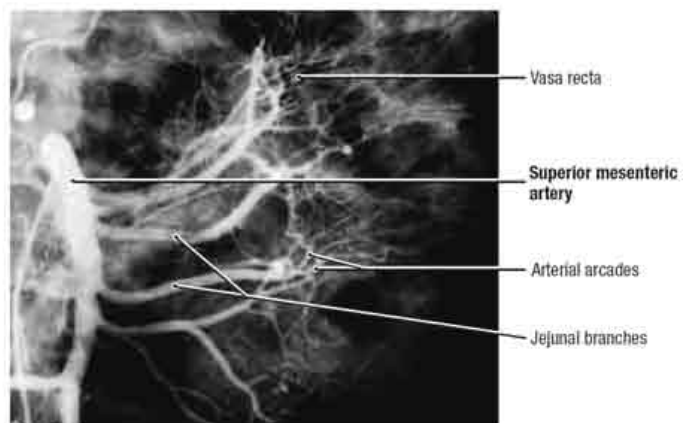
B. Enlargement to show the jejunal branches, arterial arcades, and vasa recta.

- The branches of the superior mesenteric artery include, from its left side, 12 or more jejunal and ileal branches that anastomose to form arcades from which vasa recta pass to the small intestine and, from its right side, the middle colic, ileocolic, and commonly (but not here) an independent right colic artery that anastomose to form a marginal artery that parallels the mesenteric border at the colon and from which vasa recta pass to the large intestine.

Occlusion of the vasa recta by emboli results in ischemia of the part of the intestine concerned. If the ischemia is severe, necrosis of the involved segment results and ileus (obstruction of the intestine) of the paralytic type occurs. Ileus is accompanied by a severe colicky pain, along with abdominal distension, vomiting, and often fever and dehydration. If the condition is diagnosed early (e.g., using a superior mesenteric arteriogram), the obstructed part of the vessel may be cleared surgically



Anteroposterior Arteriograms



B

Authors: Agur, Anne M.R.; Dalley, Arthur F.

Title: *Grant's Atlas of Anatomy, 12th Edition*

Copyright ©2009 Lippincott Williams & Wilkins

> Table of Contents > Chapter 2 - Abdomen > 2.41 Inferior mesenteric artery

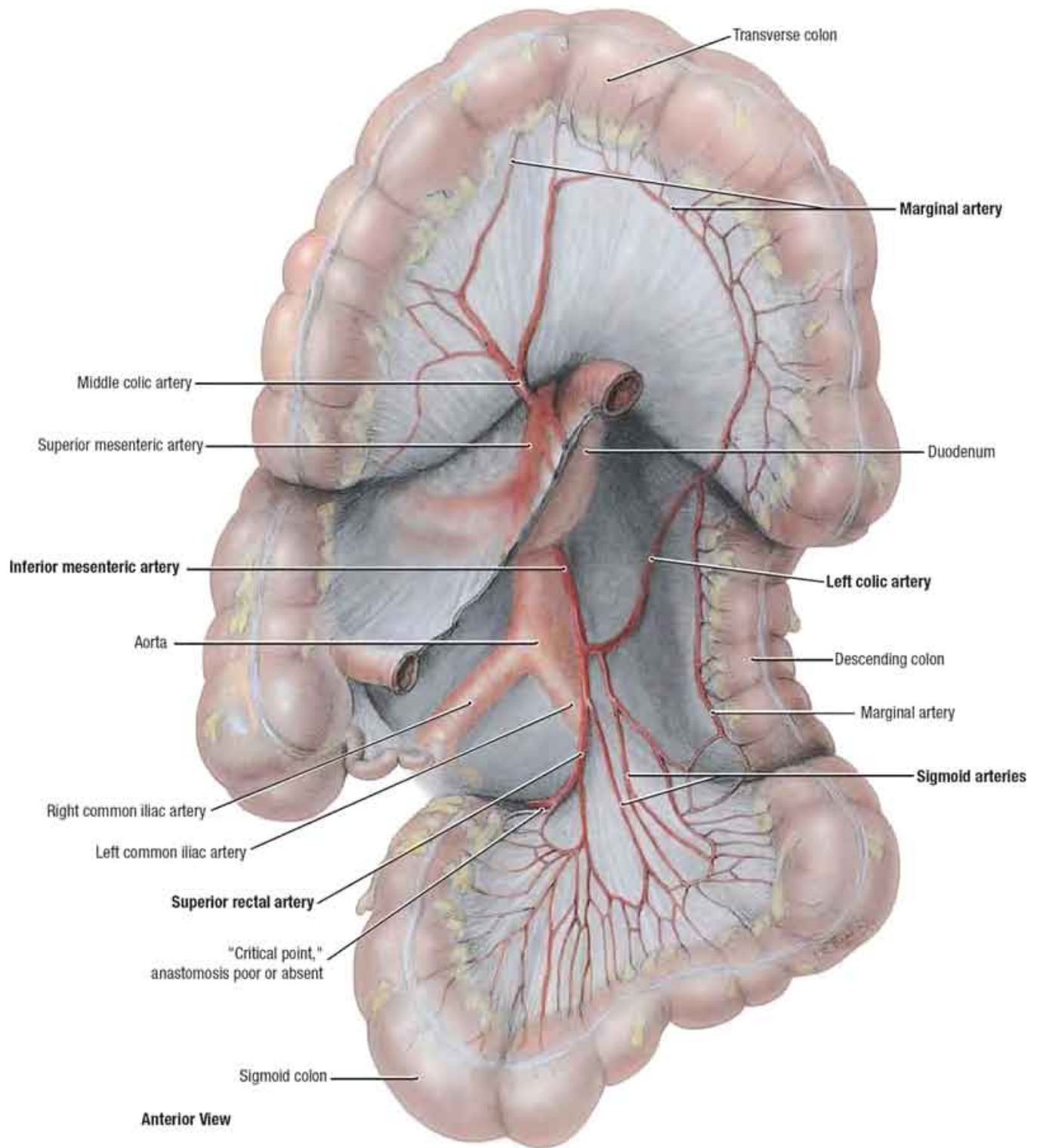
---

## 2.41 Inferior mesenteric artery

*Part of* "Chapter 2 - Abdomen "

The mesentery of the small intestine has been cut at its root.

- The inferior mesenteric artery arises posterior to the ascending part of the duodenum, about 4 cm superior to the bifurcation of the aorta; on crossing the left common iliac artery, it becomes the superior rectal artery.
  - The branches of the inferior mesenteric artery include the left colic artery and several sigmoid arteries; the inferior two sigmoid arteries branch from the superior rectal artery.
- The point at which the last artery to the colon branches from the superior rectal artery is known as the "critical point" ; this branch has poor or no anastomotic connections with the superior rectal artery.





Authors: Agur, Anne M.R.; Dalley, Arthur F.

Title: *Grant's Atlas of Anatomy, 12th Edition*

Copyright ©2009 Lippincott Williams & Wilkins

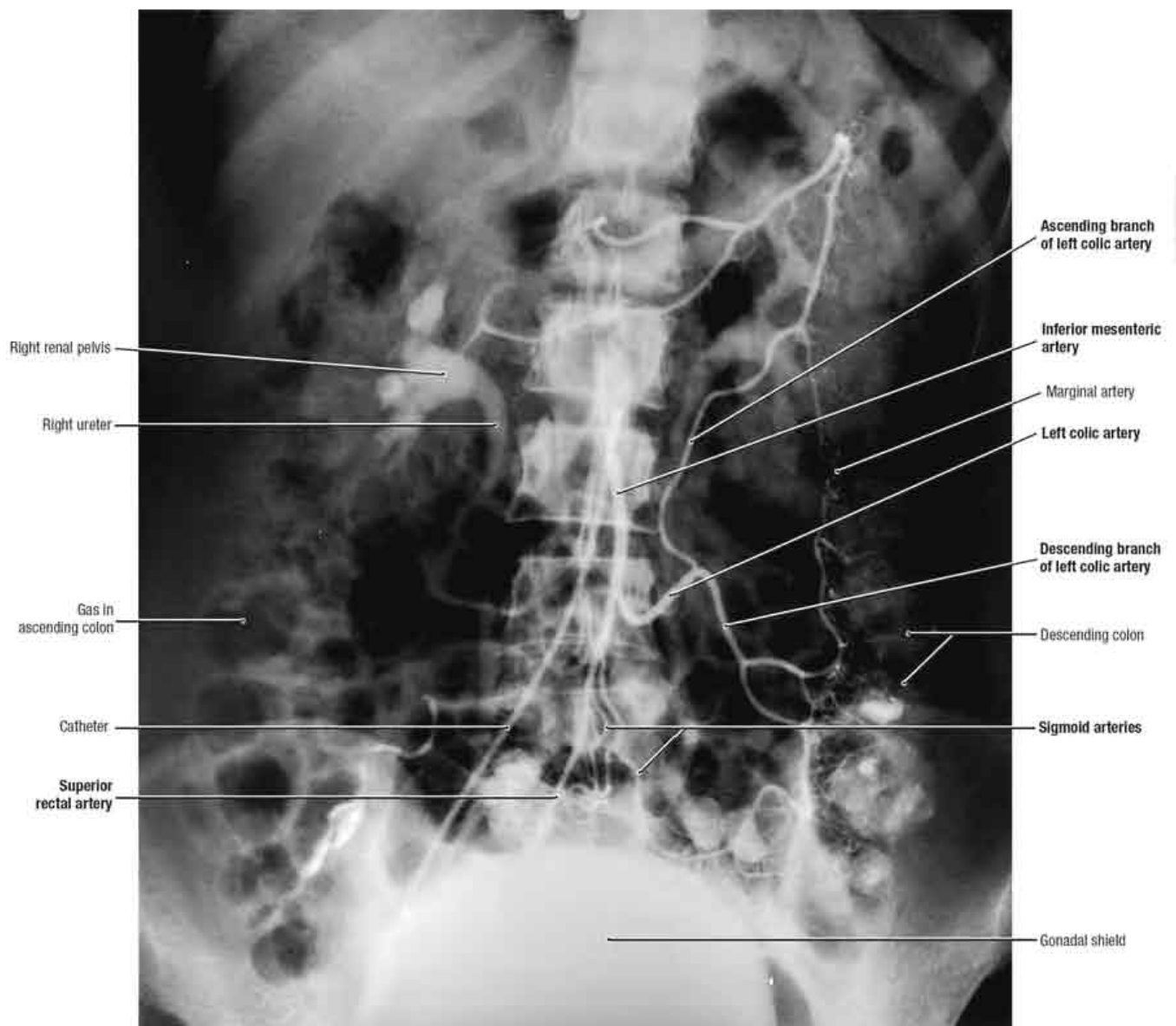
> Table of Contents > Chapter 2 - Abdomen > 2.42 Inferior mesenteric arteriogram

---

## 2.42 Inferior mesenteric arteriogram

*Part of* "Chapter 2 - Abdomen "

- The left colic artery courses to the left toward the descending colon and splits into ascending and descending branches.
- The sigmoid arteries, two to four in number, supply the sigmoid colon.
- The superior rectal artery, which is the continuation of the inferior mesenteric artery, supplies the rectum; the superior rectal anastomoses is formed by branches of the middle and inferior rectal arteries (from the internal iliac artery).



Posteroanterior Arteriogram

Authors: Agur, Anne M.R.; Dalley, Arthur F.

Title: *Grant's Atlas of Anatomy, 12th Edition*

Copyright ©2009 Lippincott Williams & Wilkins

> Table of Contents > Chapter 2 - Abdomen > 2.43 Peritoneum of posterior abdominal cavity

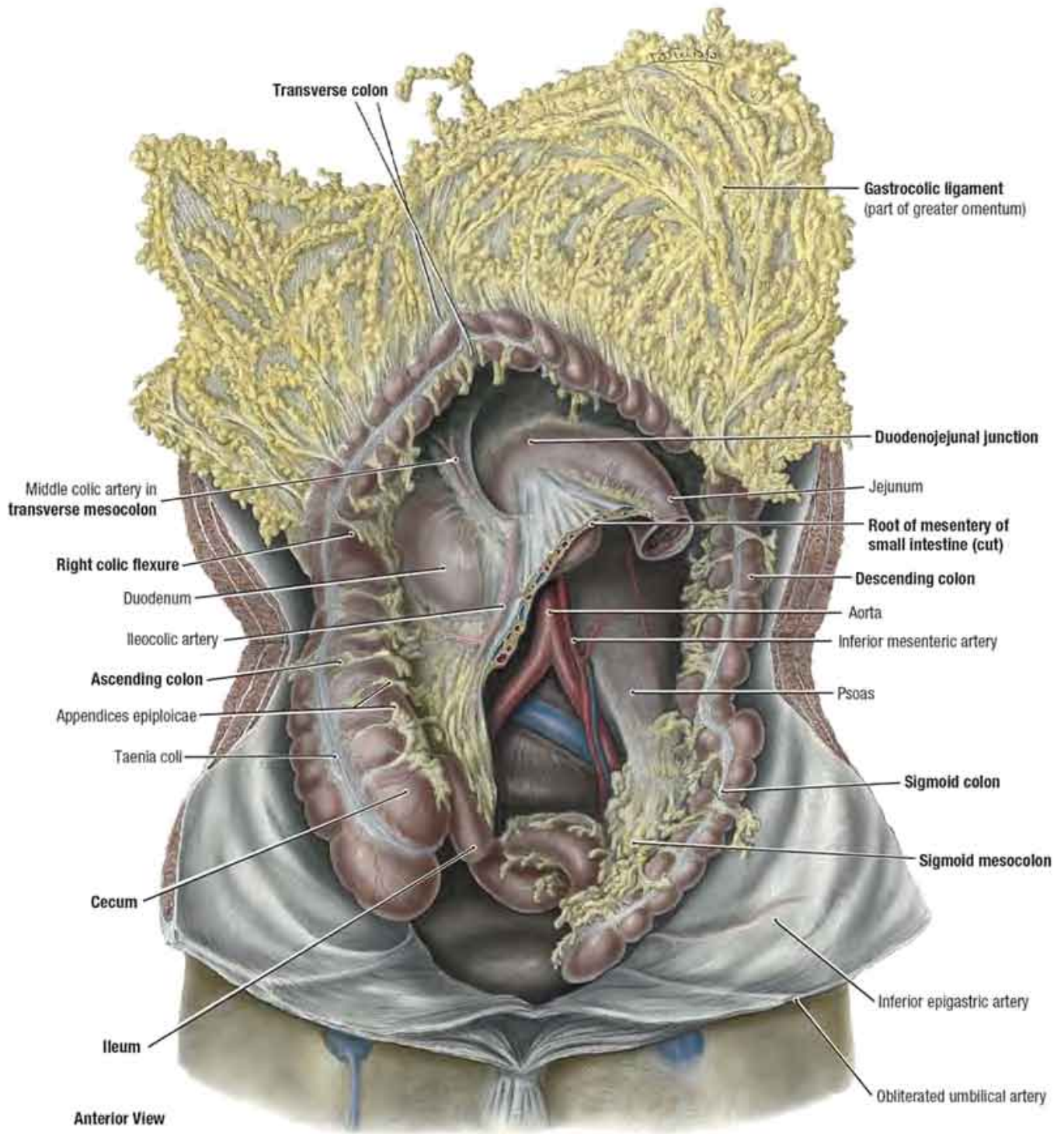
---

## 2.43 Peritoneum of posterior abdominal cavity

*Part of* "Chapter 2 - Abdomen "

The gastrocolic ligament is retracted superiorly, along with the transverse colon and transverse mesocolon. The appendix had been surgically removed. This dissection is continued in Figure 2.44 .

- The root of the mesentery of the small intestine, approximately 15 to 20 cm in length, extends between the duodenojejunal junction and ileocecal junction.
  - The large intestine forms 3/4 sides of a square around the jejunum and ileum. On the right are the cecum and ascending colon, superior is the transverse colon, on the left is the descending and sigmoid colon, inferiorly is the sigmoid colon.
- Chronic inflammation of the colon (ulcerative colitis, Crohn disease) is characterized by severe inflammation and ulceration of the colon and rectum. In some patients, a colectomy is performed, during which the terminal ileum and colon as well as the rectum and anal canal are removed. An ileostomy is then constructed to establish an artificial cutaneous opening between the ileum and the skin of the anterolateral abdominal wall.



Authors: Agur, Anne M.R.; Dalley, Arthur F.

Title: *Grant's Atlas of Anatomy, 12th Edition*

Copyright ©2009 Lippincott Williams & Wilkins

> Table of Contents > Chapter 2 - Abdomen > 2.44 Posterior abdominal cavity with peritoneum removed

---

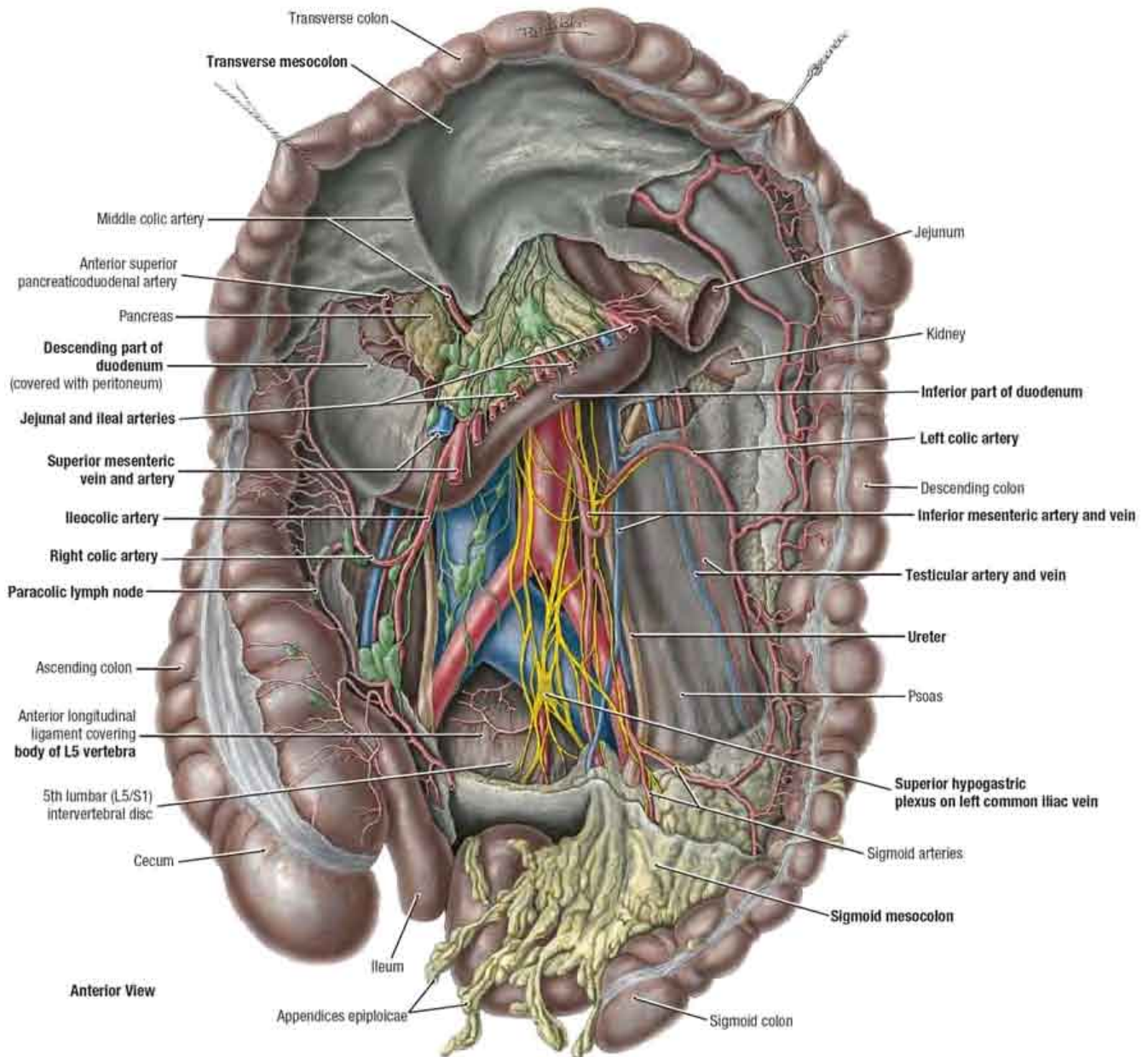
## 2.44 Posterior abdominal cavity with peritoneum removed

*Part of* "Chapter 2 - Abdomen "

The jejunal and ileal branches (cut) pass from the left side of the superior mesenteric artery. The right colic artery here is a branch of the ileocolic artery. This is the same specimen as in Figure 2.43 .

- The duodenum is large in diameter before crossing the superior mesenteric vessels and narrow afterward.
- On the right side, there are lymph nodes on the colon, paracolic nodes beside the colon, and nodes along the ileocolic artery, which drain into nodes anterior to the pancreas.
- The intestines and intestinal vessels lie on a resectable plane anterior to that of the testicular vessels; these in turn lie anterior to the plane of the kidney, its vessels, and the ureter.
- The superior hypogastric plexus lies within the bifurcation of the aorta and anterior to the left common iliac vein, the body of the 5th lumbar vertebra, and the 5th intervertebral disc.





Authors: Agur, Anne M.R.; Dalley, Arthur F.

Title: *Grant's Atlas of Anatomy, 12th Edition*

Copyright ©2009 Lippincott Williams & Wilkins

> Table of Contents > Chapter 2 - Abdomen > 2.45 Diaphragmatic (anterior and superior)  
surface of liver

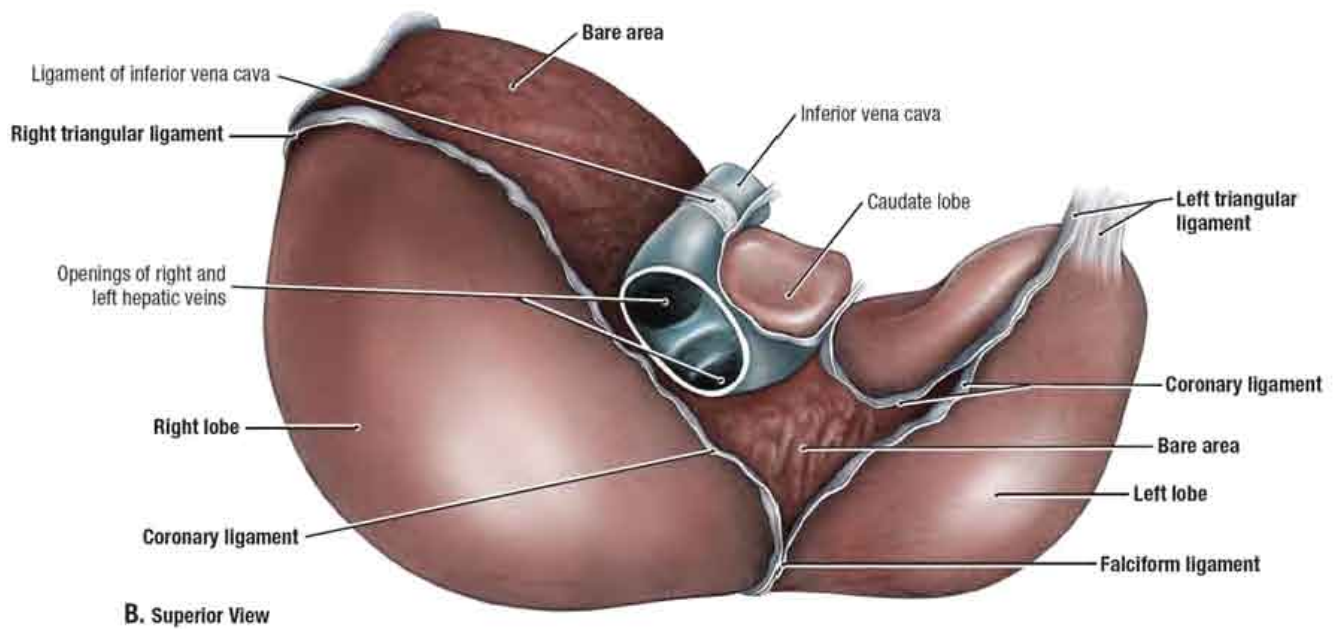
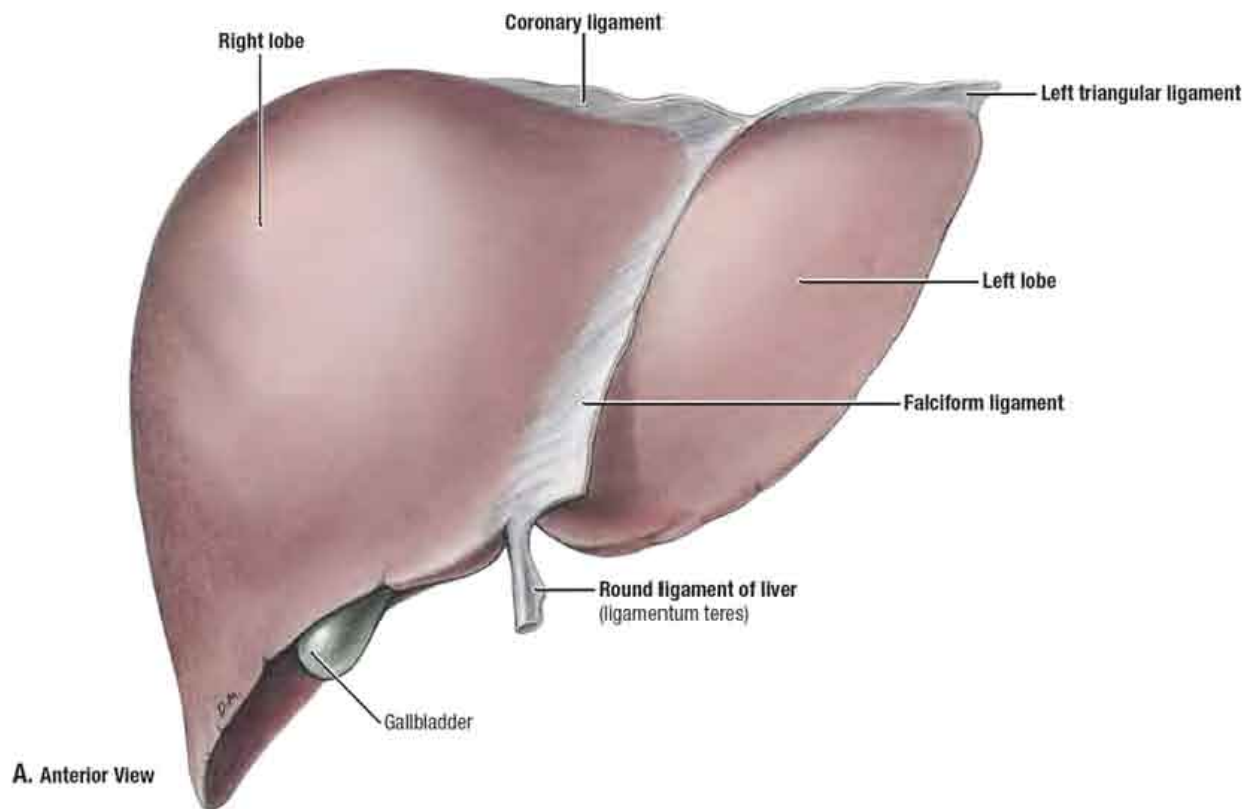
---

## 2.45 Diaphragmatic (anterior and superior) surface of liver

*Part of* "Chapter 2 - Abdomen "

A. The falciform ligament has been severed close to its attachment to the diaphragm and anterior abdominal wall and demarcates the right and left lobes of the liver. The round ligament of the liver (ligamentum teres) lies within the free edge of the falciform ligament.

B. The two layers of peritoneum that form the falciform ligament separate over the superior aspect (surrounding the bare area) of the liver to form the superior layer of the coronary ligament and the right and left triangular ligaments.



Authors: Agur, Anne M.R.; Dalley, Arthur F.

Title: *Grant's Atlas of Anatomy, 12th Edition*

Copyright ©2009 Lippincott Williams & Wilkins

> Table of Contents > Chapter 2 - Abdomen > 2.46 Visceral (posteroinferior) surface of liver

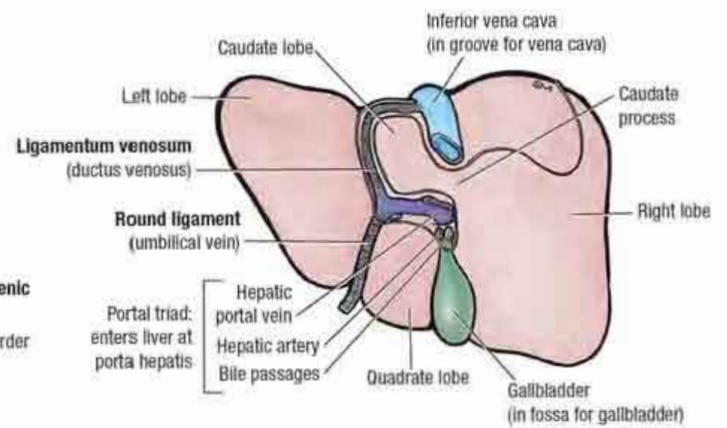
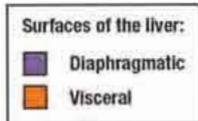
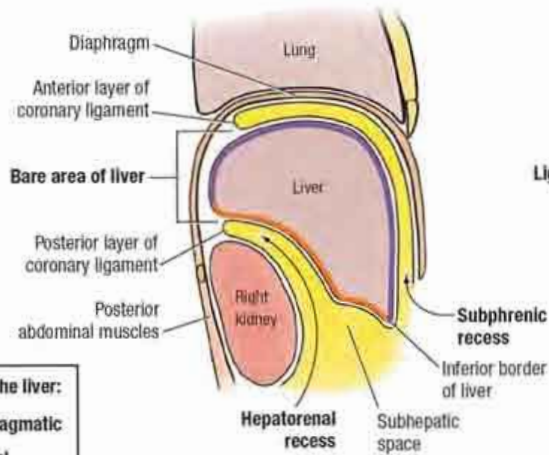
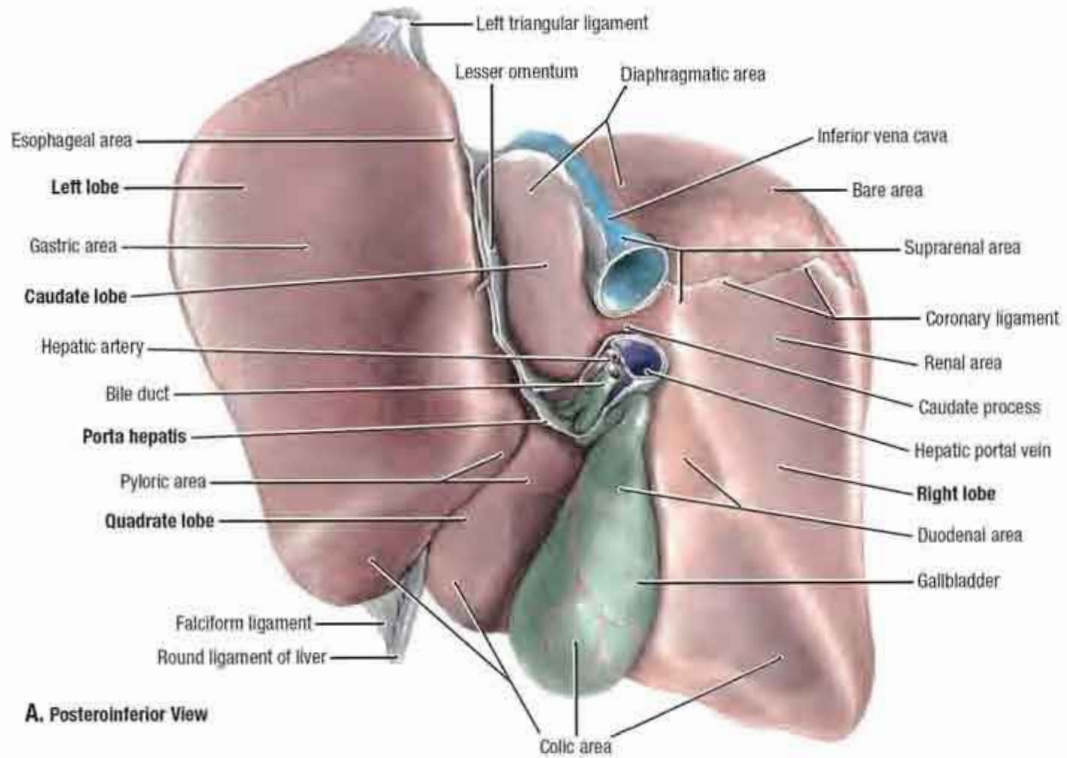
---

## 2.46 Visceral (posteroinferior) surface of liver

*Part of "Chapter 2 - Abdomen "*

A. Isolated specimen demonstrating lobes, and impressions of adjacent viscera. B. Hepatic surfaces and peritoneal recesses. C. Round ligament of liver and ligamentum venosum. The round ligament of liver includes the obliterated remains of the umbilical vein that carried well-oxygenated blood from the placenta to the fetus. The ligamentum venosum is the fibrous remnant of the fetal ductus venosus that shunted blood from the umbilical vein to the inferior vena cava, short circuiting the liver.

Hepatic tissue may be obtained for diagnostic purposes by liver biopsy. The needle puncture is commonly made through the right 10th intercostal space in the midaxillary line. Before the physician takes the bi-opsy, the person is asked to hold his or her breath in full expiration to reduce the costodiaphragmatic recess and to lessen the possibility of damaging the lung and contaminating the pleural cavity.





Authors: Agur, Anne M.R.; Dalley, Arthur F.

Title: *Grant's Atlas of Anatomy, 12th Edition*

Copyright ©2009 Lippincott Williams & Wilkins

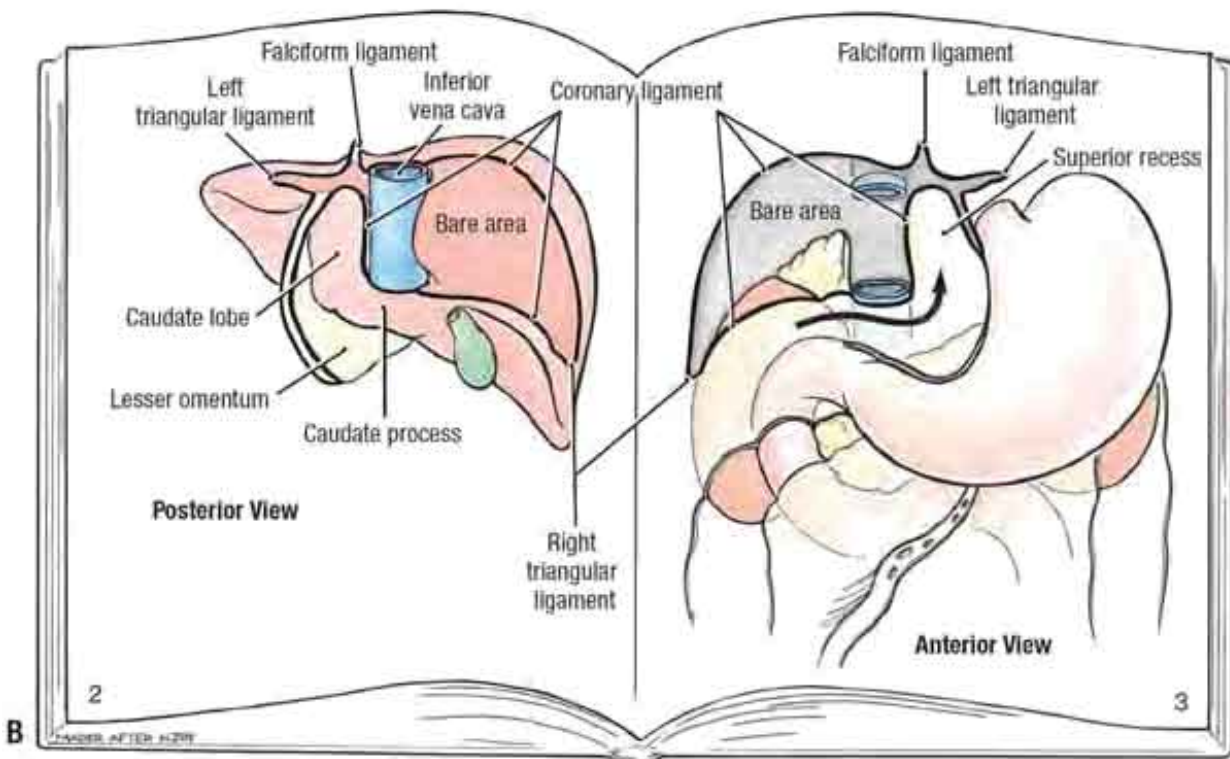
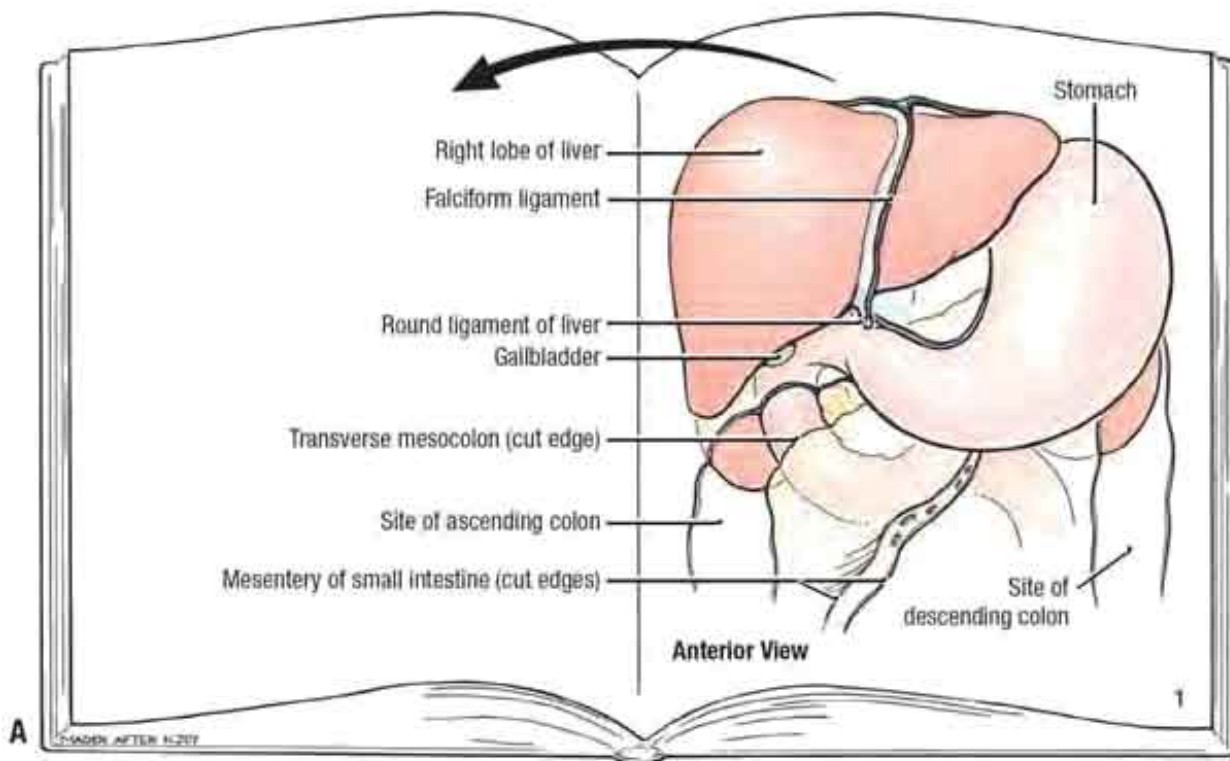
> Table of Contents > Chapter 2 - Abdomen > 2.47 Liver and its posterior relations, schematic illustration

---

## 2.47 Liver and its posterior relations, schematic illustration

*Part of "Chapter 2 - Abdomen"*

A. Liver in situ. The jejunum, ileum, and the ascending, transverse, and descending colon have been removed. B. The liver is drawn schematically on a page in a book, so that as the page is turned (*arrow in A*), the liver is reflected to the right to reveal its posterior surface, and on the facing page, the posterior relations that compose the bed of the liver are viewed. The *arrow in B* traverses the site of the omental (epiploic) foramen. The bare area is triangular, hence the coronary ligament that surrounds it is three-sided; its left side, or base, is between the inferior vena cava and caudate lobe, and its apex is at the right triangular ligament, where the superior and inferior layers of the coronary ligament meet.





Authors: Agur, Anne M.R.; Dalley, Arthur F.

Title: *Grant's Atlas of Anatomy, 12th Edition*

Copyright ©2009 Lippincott Williams & Wilkins

> Table of Contents > Chapter 2 - Abdomen > 2.48 Hepatic veins

---

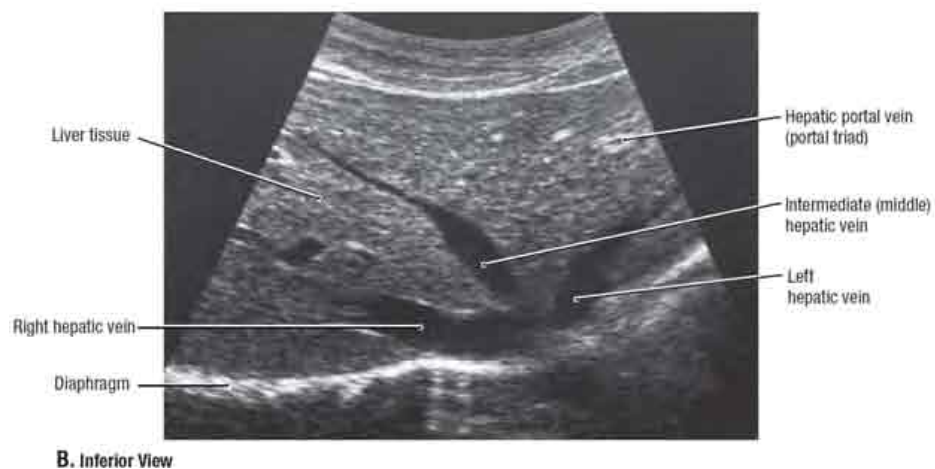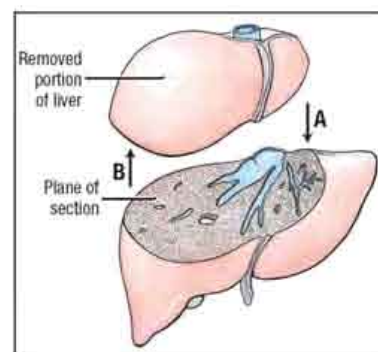
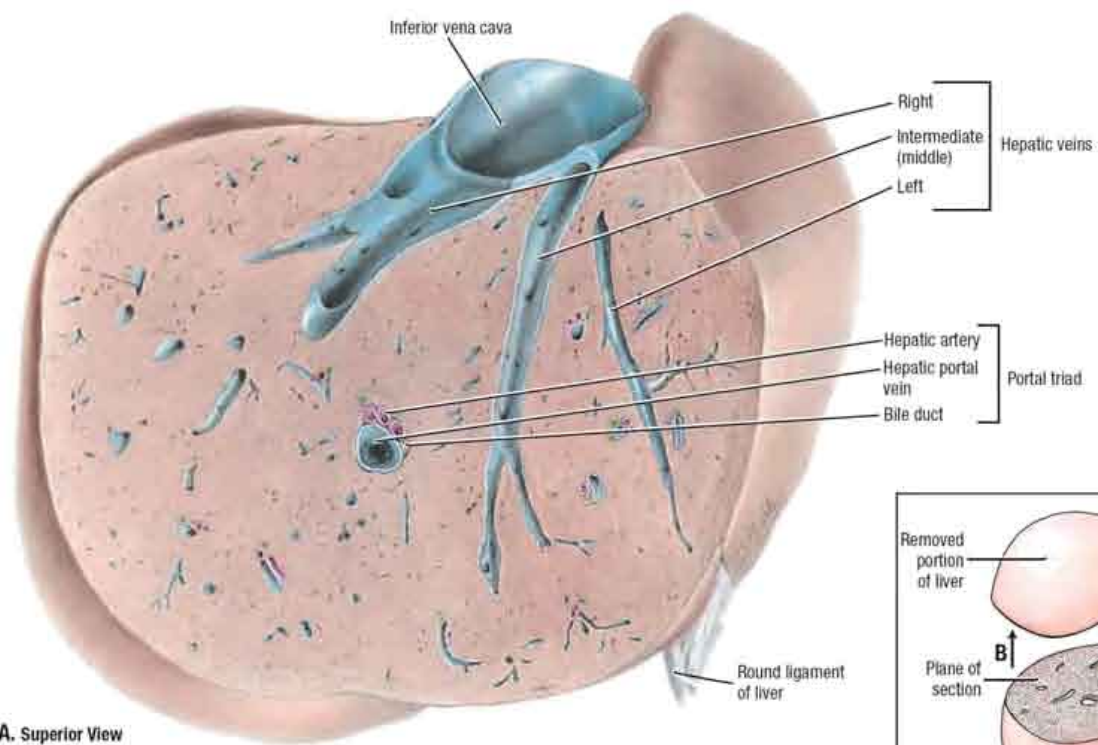
## 2.48 Hepatic veins

*Part of "Chapter 2 - Abdomen "*

A. Approximately horizontal section of liver with the posterior aspect at top of page. Note the multiple perivascular fibrous capsules sectioned throughout the cut surface, each containing a portal triad (the hepatic portal vein, hepatic artery, bile ductules) plus lymph vessels. Interdigitating with these are branches of the three main hepatic veins (right, intermediate, and left), which, unaccompanied and lacking capsules, converge on the inferior vena cava. B. Ultrasound scan. The transducer was placed under the costal margin, and directed posteriorly producing an inverted image corresponding to A.

---

P.150





Authors: Agur, Anne M.R.; Dalley, Arthur F.

Title: *Grant's Atlas of Anatomy, 12th Edition*

Copyright ©2009 Lippincott Williams & Wilkins

> Table of Contents > Chapter 2 - Abdomen > 2.49 Hepatic segmentation

---

## 2.49 Hepatic segmentation

*Part of* "Chapter 2 - Abdomen "

P.151

Each segment is supplied by a secondary or tertiary branch of the hepatic artery, bile duct, portal vein. The hepatic veins interdigitate between the structures of the portal triad and an intersegmental in that they drain adjacent segments.

Since the right and left hepatic arteries and ducts and branches of the right and left portal veins do not communicate, it is possible to perform hepatic lobectomies (removal of the right or left part of the liver) and segmentectomies.

Each segment can be identified numerically or by name (Table 2.4 ).

Functional/surgical term\*\*

Right (part of) liver [Right portal lobe\* ]

Left (part of) liver [Left portal lobe<sup>+</sup> ]

Posterior (part of) liver

Right lateral division

Right medial division

Left medial division

Left lateral division

[Right caudate lobe\* ]

[Left caudate lobe<sup>+</sup> ]

Posterior lateral segment

Segment VII

[Posterior superior area]  
 Posterior medial segment  
 Segment VIII  
 [Anterior superior area]  
 [Medial superior area]  
 Left medial segment  
 Segment IV  
 Lateral segment  
 Segment II  
 [Lateral superior area]  
 Posterior segment  
 Segment I  
 Right anterior lateral  
 segment  
 Segment VI  
 [Posterior inferior area]  
 Anterior medial segment  
 Segment V  
 [Anterior inferior area]  
 [Medial inferior area = quadrate lobe]  
 Left anterior lateral segment  
 Segment III  
 [Lateral inferior area]

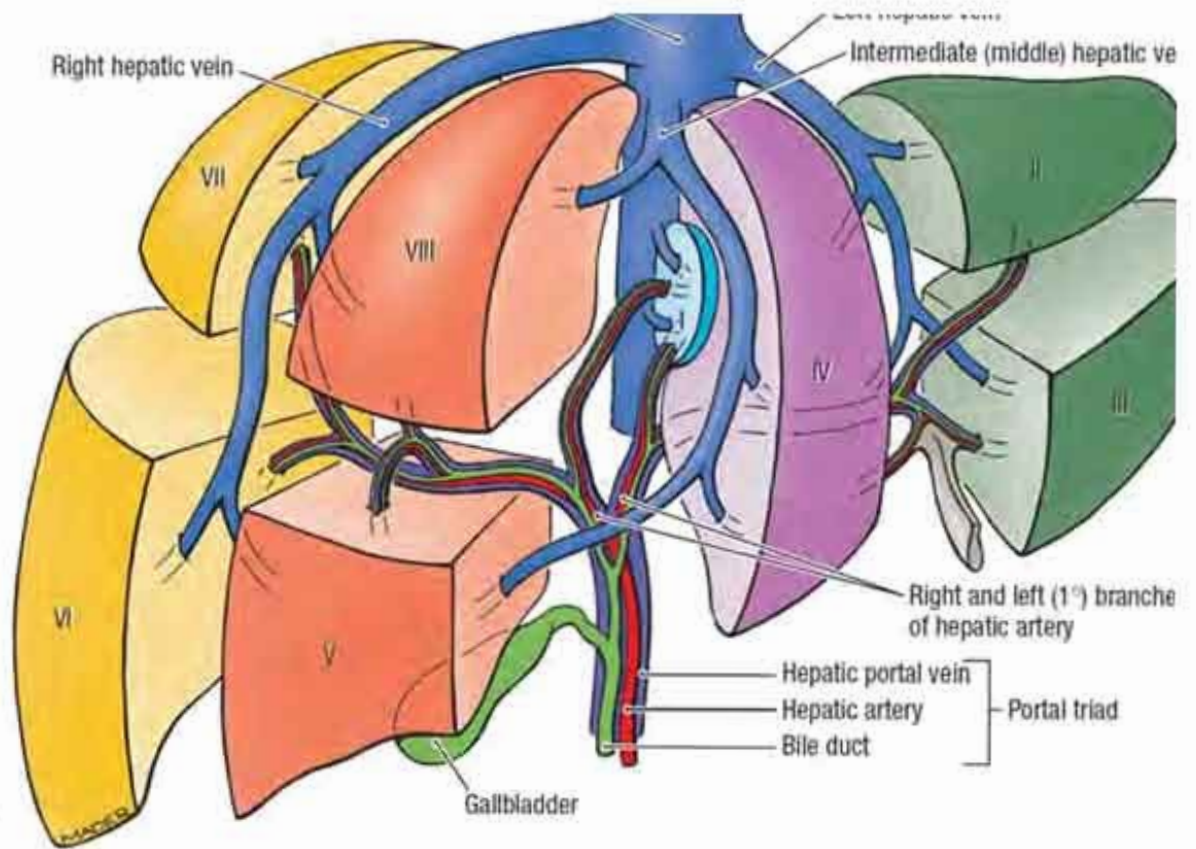
\*\*The labels in the table and figure above reflect the new Terminologia Anatomica:  
 International Anatomical Terminology Previous terminology is in brackets.

Under the schema of the previous terminology, the caudate lobe was divided into right and  
 halves, and \*the right half of the caudate lobe was considered a subdivision of the right por-  
 tal lobe; + the left half of the caudate lobe was considered a subdivision of the left portal lobe

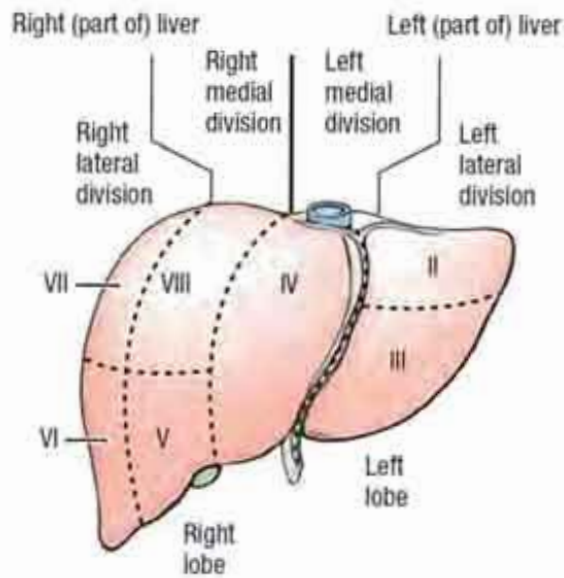
Anatomical Term	Right Lobe	Left Lobe	Caudate Lobe
-----------------	------------	-----------	--------------

Table 2.4 Schema of Terminology for Subdivisions of The Liver

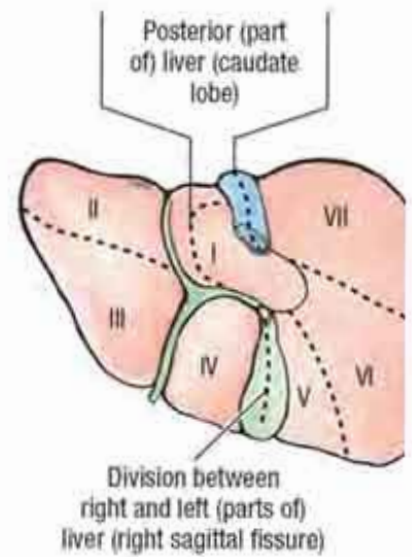




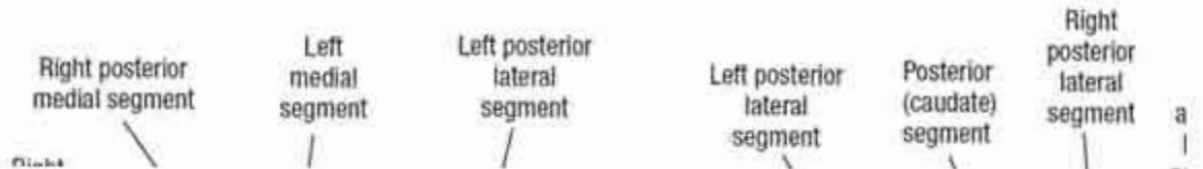
A. Anterior View

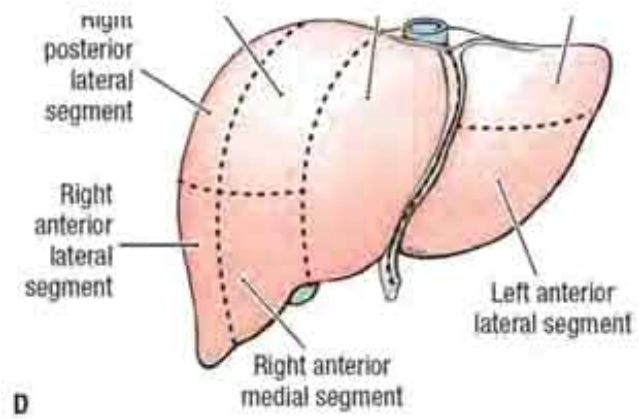


B



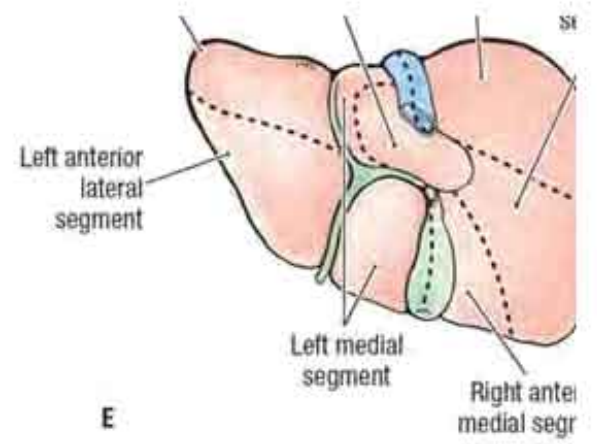
C





D

**Anterior Views (B, D)**



E

**Posteroinferior Views (C, E)**

Authors: Agur, Anne M.R.; Dalley, Arthur F.

Title: *Grant's Atlas of Anatomy, 12th Edition*

Copyright ©2009 Lippincott Williams & Wilkins

> Table of Contents > Chapter 2 - Abdomen > 2.50 Flow of blood and bile in the liver

---

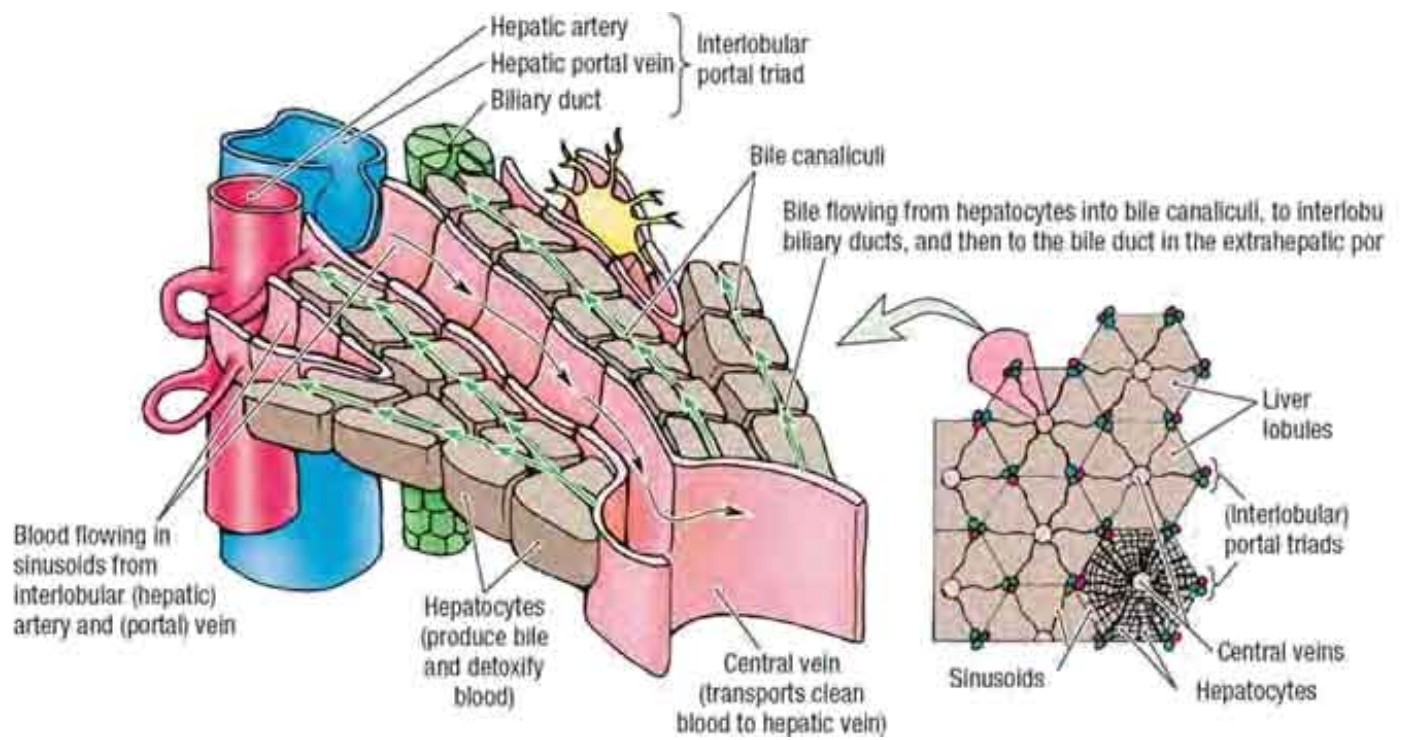
## 2.50 Flow of blood and bile in the liver

*Part of "Chapter 2 - Abdomen "*

This small part of a liver lobule shows the components of the interlobular portal triad and the positioning of the sinusoids and bile canaliculi. Right: The cut surface of the liver shows the hexagonal pattern of the lobules.

- With the exception of lipids, every substance absorbed by the alimentary tract is received first by the liver, via the hepatic portal vein. In addition to its many metabolic activities, the liver stores glycogen and secretes bile.
- There is progressive destruction of hepatocytes in cirrhosis of the liver replacement of them by fibrous tissue. This tissue surrounds the intrahepatic blood vessels and biliary ducts, making the liver firm and impeding circulation of blood through it.





Authors: Agur, Anne M.R.; Dalley, Arthur F.

Title: *Grant's Atlas of Anatomy, 12th Edition*

Copyright ©2009 Lippincott Williams & Wilkins

> Table of Contents > Chapter 2 - Abdomen > 2.51 Exposure of the portal triad

---

## 2.51 Exposure of the portal triad

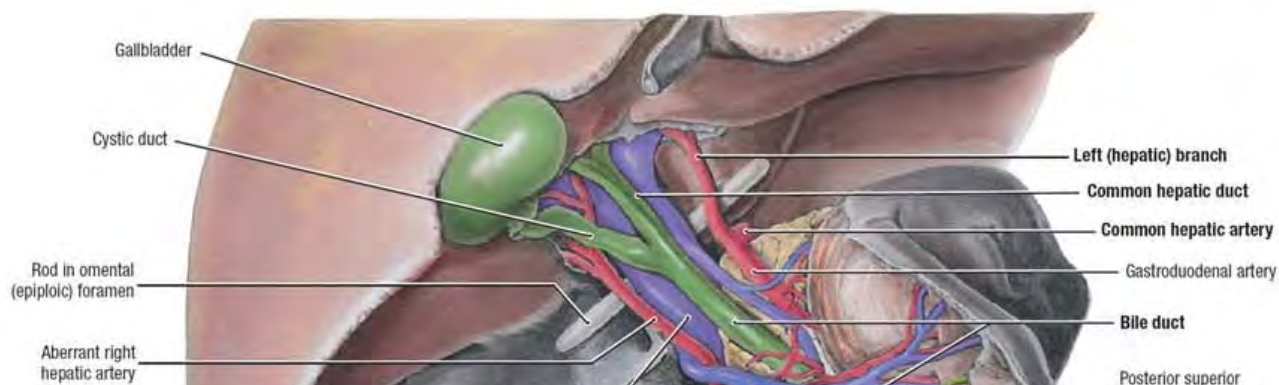
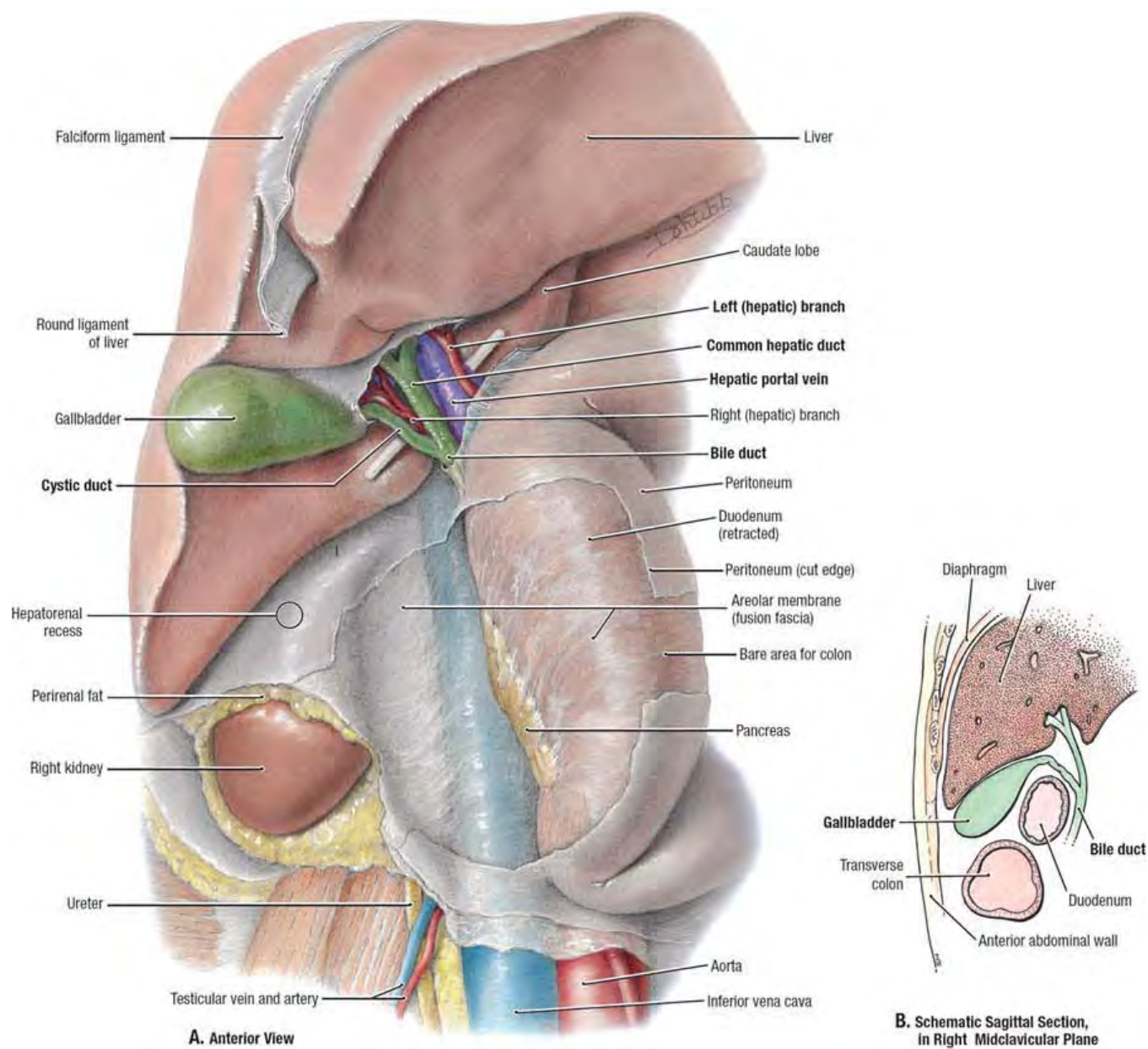
*Part of* "Chapter 2 - Abdomen "

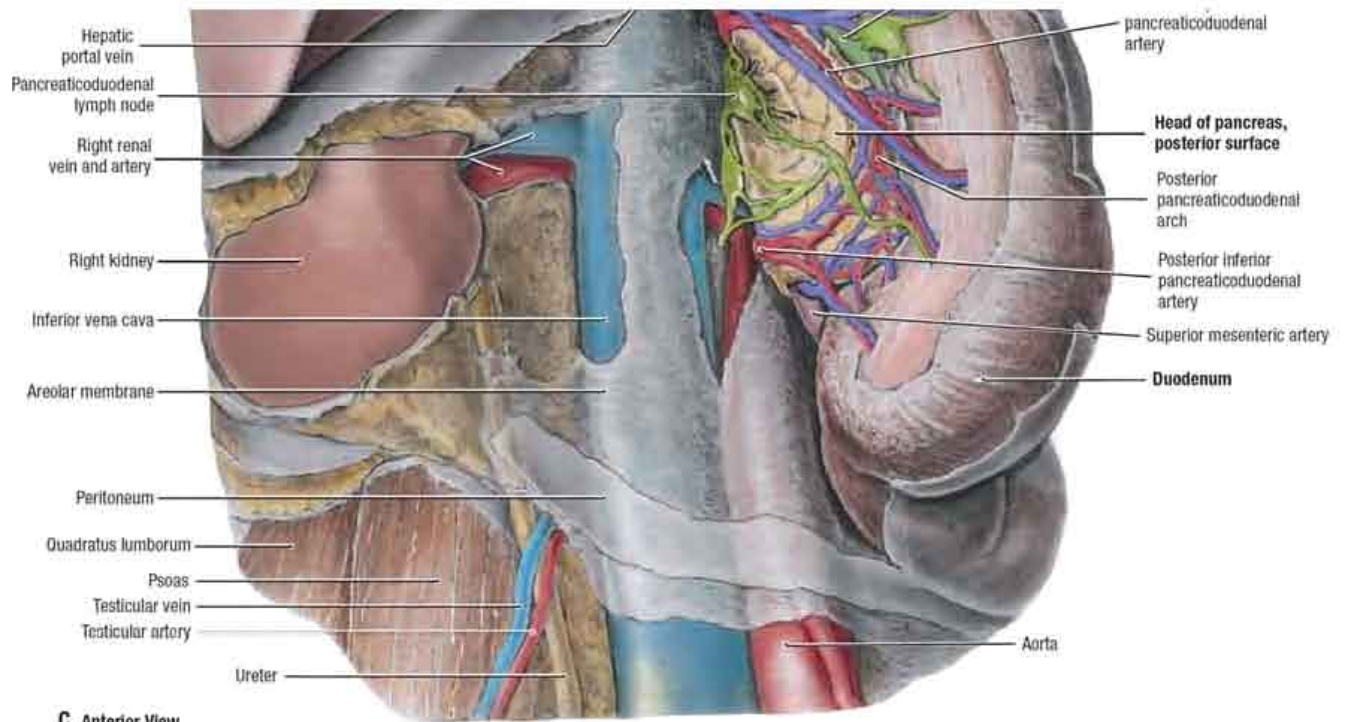
A. The portal triad typically consists of the hepatic portal vein (posteriorly), the hepatic artery proper (ascending from the left), and the bile passages (descending to the right). Here, the hepatic artery proper is replaced by a left hepatic branch, arising directly from the common hepatic artery, and a right hepatic branch, arising from the superior mesenteric artery (a common variation). A rod traverses the omental (epiploic) foramen. The lesser omentum and transverse colon are removed, and the peritoneum is cut along the right border of the duodenum; this part of the duodenum is retracted anteriorly. The space opened up reveals two smooth areolar membranes (fusion fascia) normally applied to each other that are vestiges of the embryonic peritoneum originally covering these surfaces B. Typical relations of gallbladder, cystic duct, and bile duct to the duodenum.

P.153

C. Continuing the dissection in A , the secondarily retroperitoneal viscera (duodenum and head of the pancreas) are retracted anteriorly and to the left. The areolar membrane (fusion fascia) covering the posterior aspect of the pancreas and duodenum is largely removed, and that covering the anterior aspect of the great vessels is partly removed.

A common method for reducing portal hypertension is to divert blood from the portal venous system to the systemic venous system by creating a communication between the portal vein and the IVC. This portacaval anastomosis or portosystemic shunt may be created where these vessels lie close to each other posterior to the liver.





**C. Anterior View**



Authors: Agur, Anne M.R.; Dalley, Arthur F.

Title: *Grant's Atlas of Anatomy, 12th Edition*

Copyright ©2009 Lippincott Williams & Wilkins

> Table of Contents > Chapter 2 - Abdomen > 2.52 Gallbladder and structures of porta hepatis

---

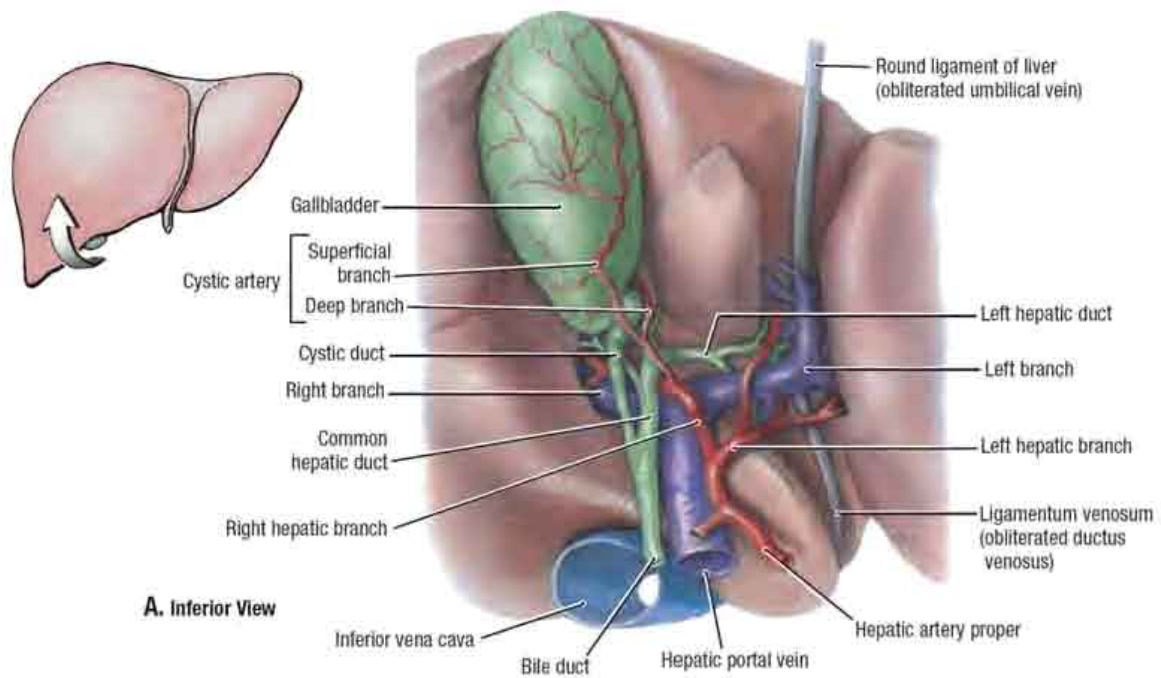
## 2.52 Gallbladder and structures of porta hepatis

*Part of* "Chapter 2 - Abdomen "

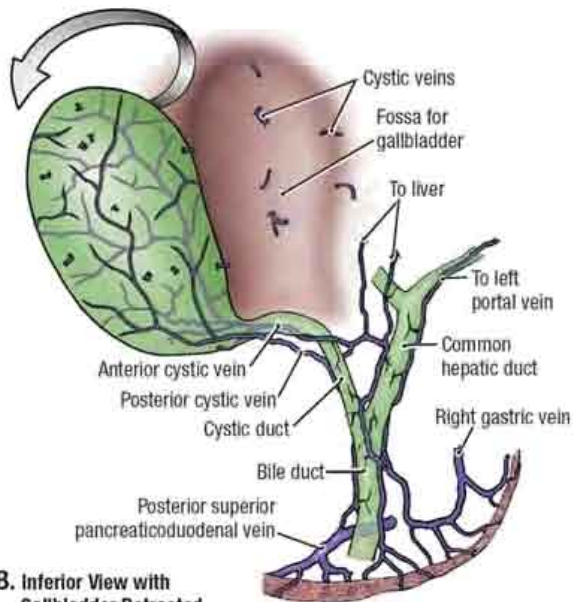
A. Gallbladder, cystic artery and extrahepatic bile ducts. The inferior border of the liver is elevated to demonstrate its visceral surface (as in orientation figure). B. Venous drainage of the gall bladder and extrahepatic ducts. Most veins are tributaries of the hepatic portal vein, but some drain directly to the liver. C. Portal triad within the hepatoduodenal ligament (free edge of lesser omentum).

Gallstones are concretions, pebble(s), in the gallbladder or extrahepatic biliary ducts. The cystohepatic triangle (Calot), between the common hepatic duct, cystic duct, and liver is an important endoscopic landmark for locating the cystic artery.

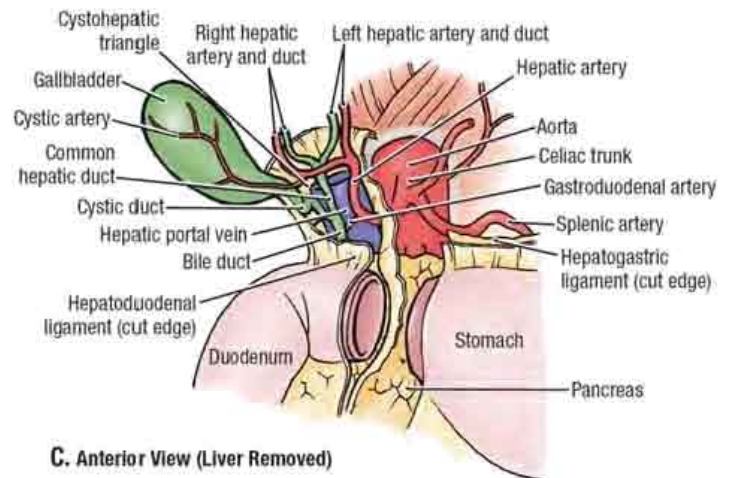




**A. Inferior View**



**B. Inferior View with Gallbladder Retracted**



**C. Anterior View (Liver Removed)**

Authors: Agur, Anne M.R.; Dalley, Arthur F.

Title: *Grant's Atlas of Anatomy, 12th Edition*

Copyright ©2009 Lippincott Williams & Wilkins

> Table of Contents > Chapter 2 - Abdomen > 2.53 Vessels in porta hepatis

---

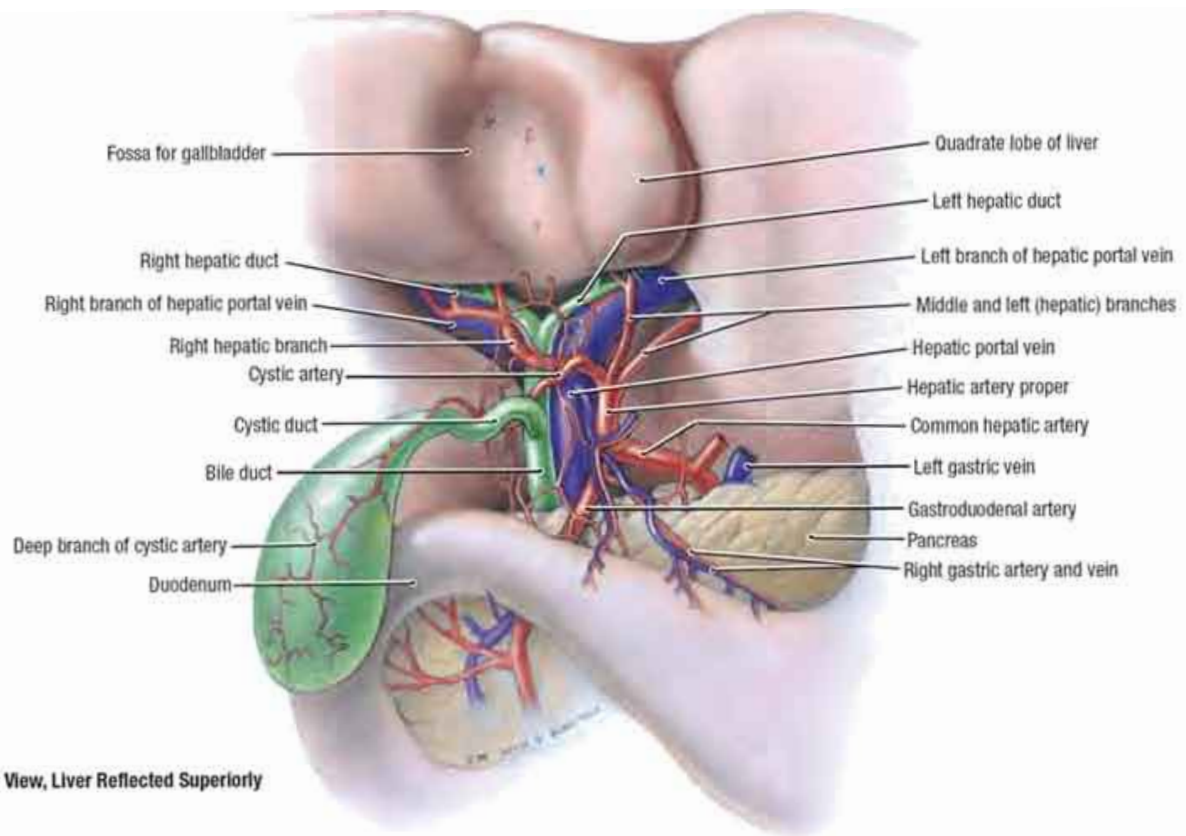
## 2.53 Vessels in porta hepatis

*Part of* "Chapter 2 - Abdomen "

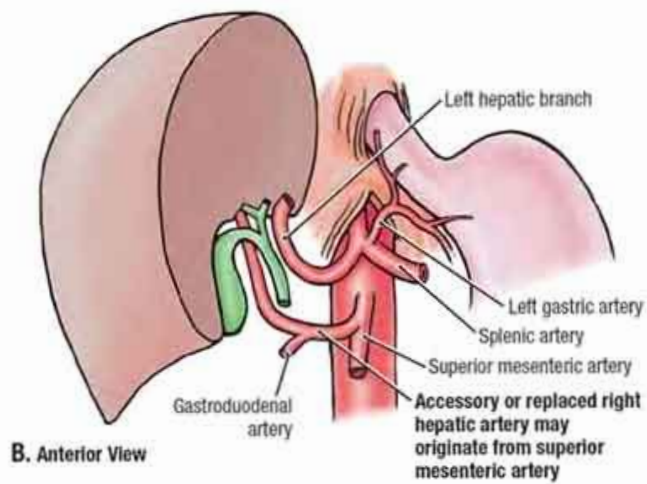
A. Hepatic and cystic vessels. The liver is reflected superiorly. The gallbladder, freed from its bed, or fossa, has remained nearly in its anatomical position, pulled slightly to the right. The deep branch of the cystic artery on the deep, or attached, surface of the gallbladder anastomoses with branches of the superficial branch of the cystic artery and sends twigs into the bed of the gallbladder. Veins (not all shown) accompany most arteries. B. Aberrant (accessory or replaced) right hepatic artery. C. Aberrant left hepatic artery.

---

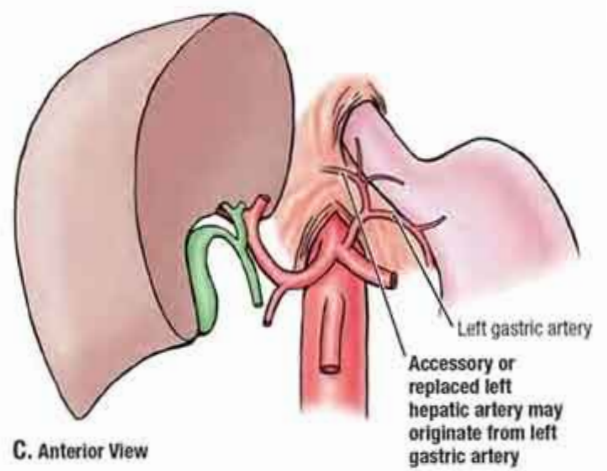
P.156



**A. Anterior View, Liver Reflected Superiorly**



**B. Anterior View**



**C. Anterior View**

Authors: Agur, Anne M.R.; Dalley, Arthur F.

Title: *Grant's Atlas of Anatomy, 12th Edition*

Copyright ©2009 Lippincott Williams & Wilkins

> Table of Contents > Chapter 2 - Abdomen > 2.54 Bile and pancreatic ducts

---

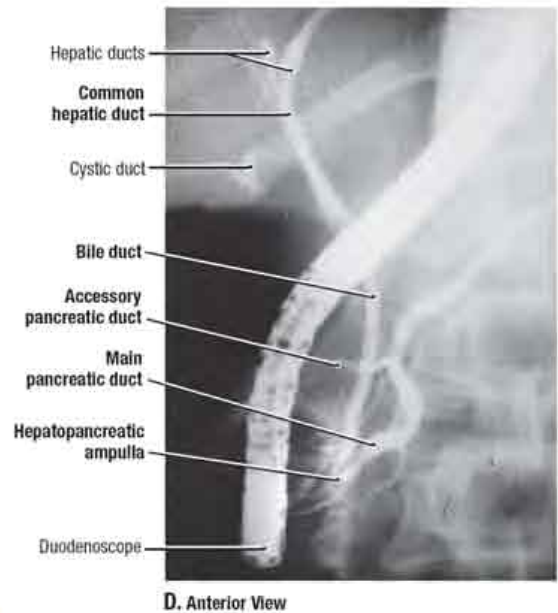
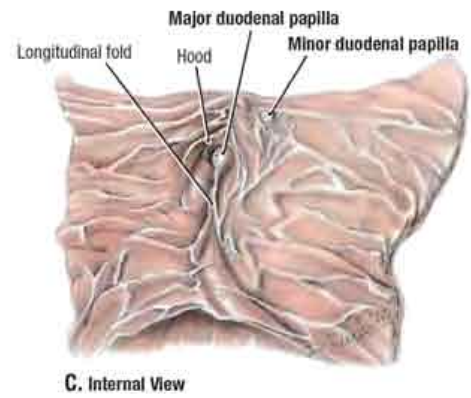
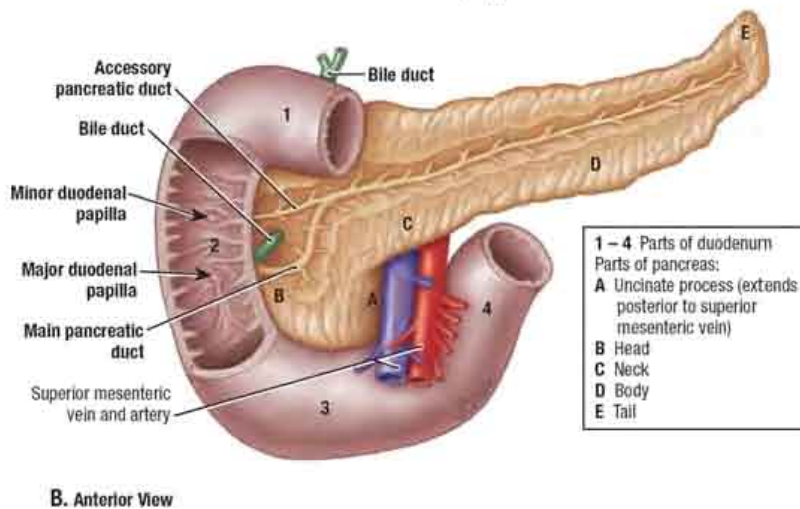
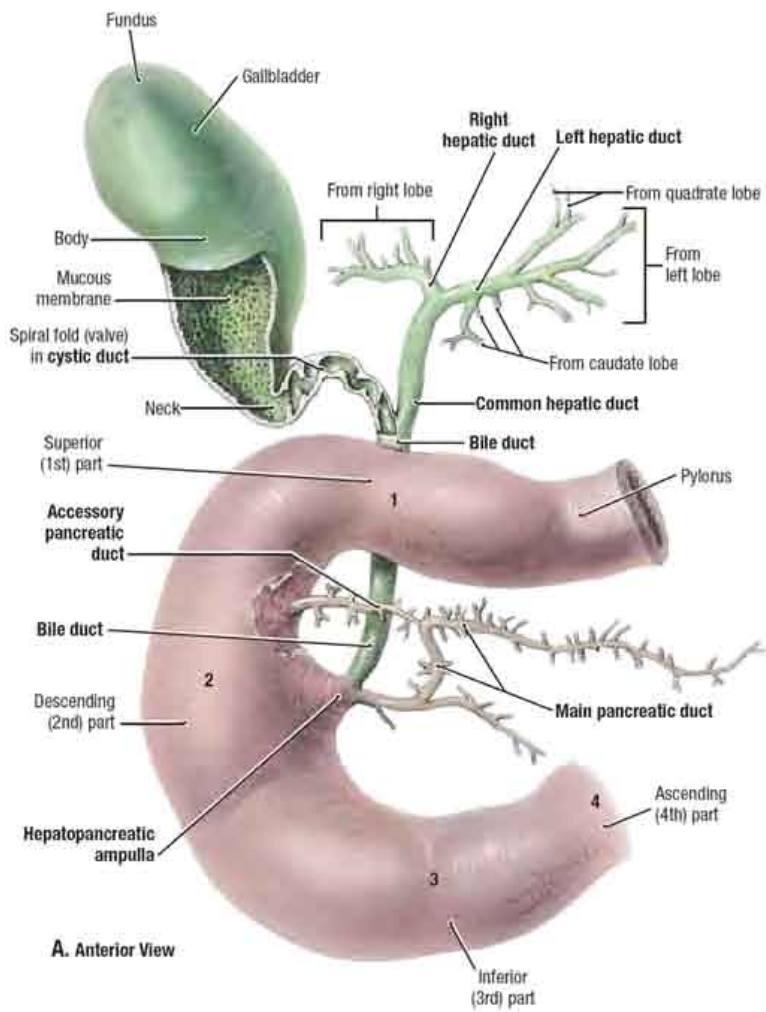
## 2.54 Bile and pancreatic ducts

*Part of "Chapter 2 - Abdomen "*

A. Extrahepatic bile passages and pancreatic ducts. B. Descending (2nd) part of the duodenum (interior). C. Endoscopic retrograde cholangiography and pancreatography (ERCP) demonstrating the bile and pancreatic ducts. The right and left hepatic ducts collect bile from the liver; the common hepatic duct unites with the cystic duct superior to the duodenum to form the bile duct which descends posterior to the superior (1st) part of the duodenum.

The bile duct joins the main pancreatic duct, forming the hepatopancreatic ampulla, which opens on the major duodenal papilla. This opening is the narrowest part of the biliary passages and is the common site for impaction of a gallstone. Gallstones may produce biliary colic (pain in the epigastric region).

The accessory pancreatic duct opens on the minor duodenal papilla.





Authors: Agur, Anne M.R.; Dalley, Arthur F.

Title: *Grant's Atlas of Anatomy, 12th Edition*

Copyright ©2009 Lippincott Williams & Wilkins

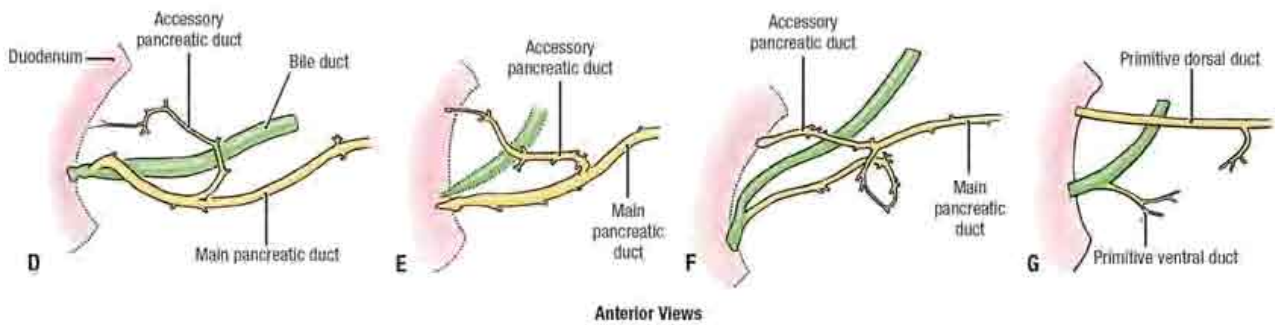
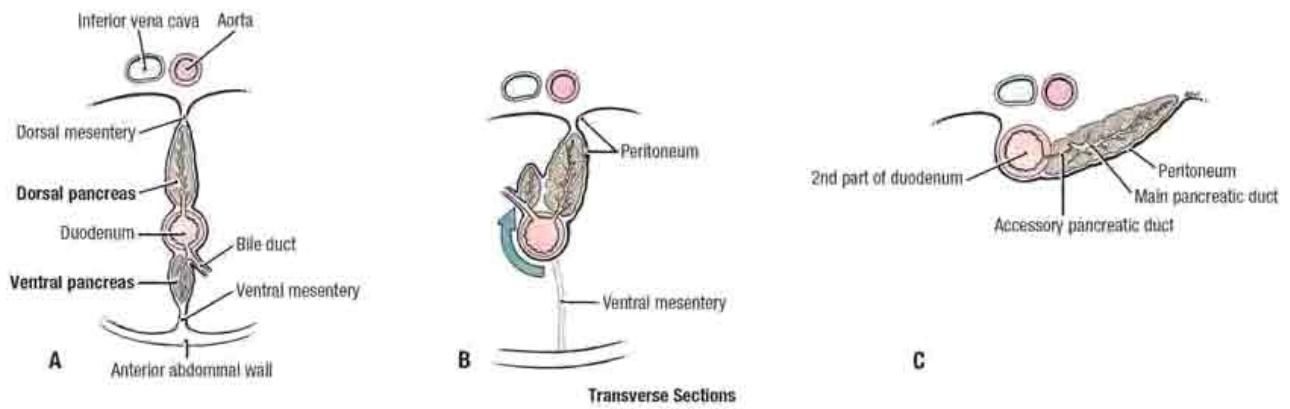
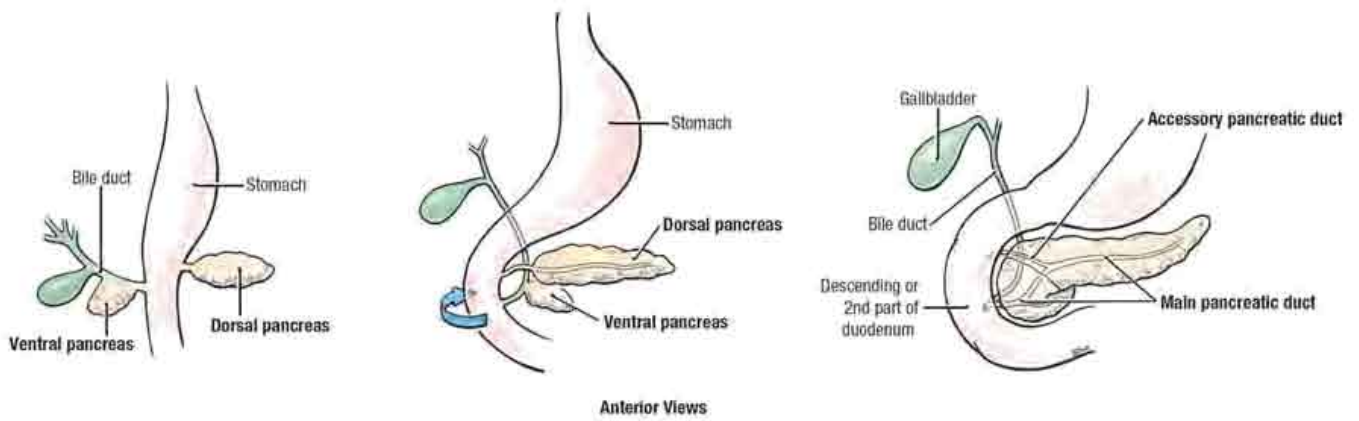
> Table of Contents > Chapter 2 - Abdomen > 2.55 Development and variability of the pancreatic ducts

---

## 2.55 Development and variability of the pancreatic ducts

*Part of "Chapter 2 - Abdomen "*

“C. Anterior views (top) and transverse sections (bottom) of the stages in the development of the pancreas. A. The small, primitive ventral bud arises in common with the bile duct, and a larger, primitive dorsal bud arises independently from the duodenum. B. The 2nd, or descending, part of the duodenum rotates on its long axis, which brings the ventral bud and bile duct posterior to the dorsal bud. C. A connecting segment unites the dorsal duct to the ventral duct, whereupon the duodenal end of the dorsal duct atrophies, and the direction of flow within it is reversed. “G. Common variations of the pancreatic duct. D. An accessory duct that has lost its connection with the duodenum. E. An accessory duct that is large enough to relieve an obstructed main duct. F. An accessory duct that could probably substitute for the main duct. G. A persisting primitive dorsal duct unconnected to the primitive ventral duct.



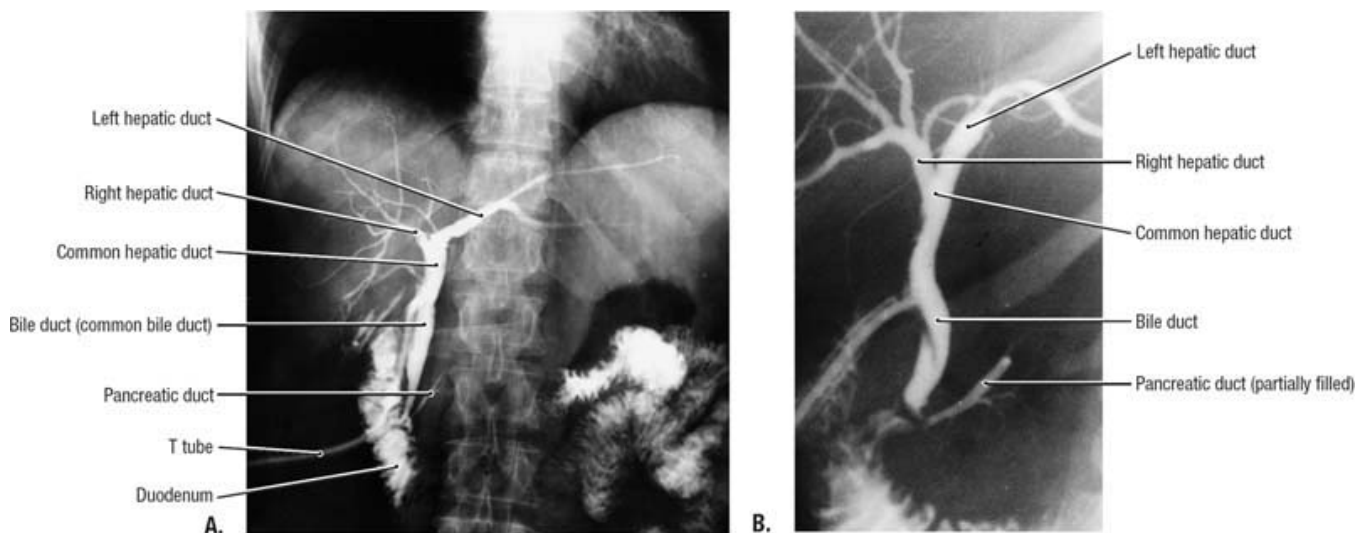
Authors: Agur, Anne M.R.; Dalley, Arthur F.  
Title: *Grant's Atlas of Anatomy, 12th Edition*  
Copyright ©2009 Lippincott Williams & Wilkins

> Table of Contents > Chapter 2 - Abdomen > 2.56 Radiographs of biliary passages

## 2.56 Radiographs of biliary passages

*Part of* "Chapter 2 - Abdomen "

After a cholecystectomy (removal of the gallbladder), contrast medium was injected with a T tube inserted into the bile passages. The biliary passages are visualized in the superior abdomen in A and are more localized in B.



Authors: Agur, Anne M.R.; Dalley, Arthur F.

Title: *Grant's Atlas of Anatomy, 12th Edition*

Copyright ©2009 Lippincott Williams & Wilkins

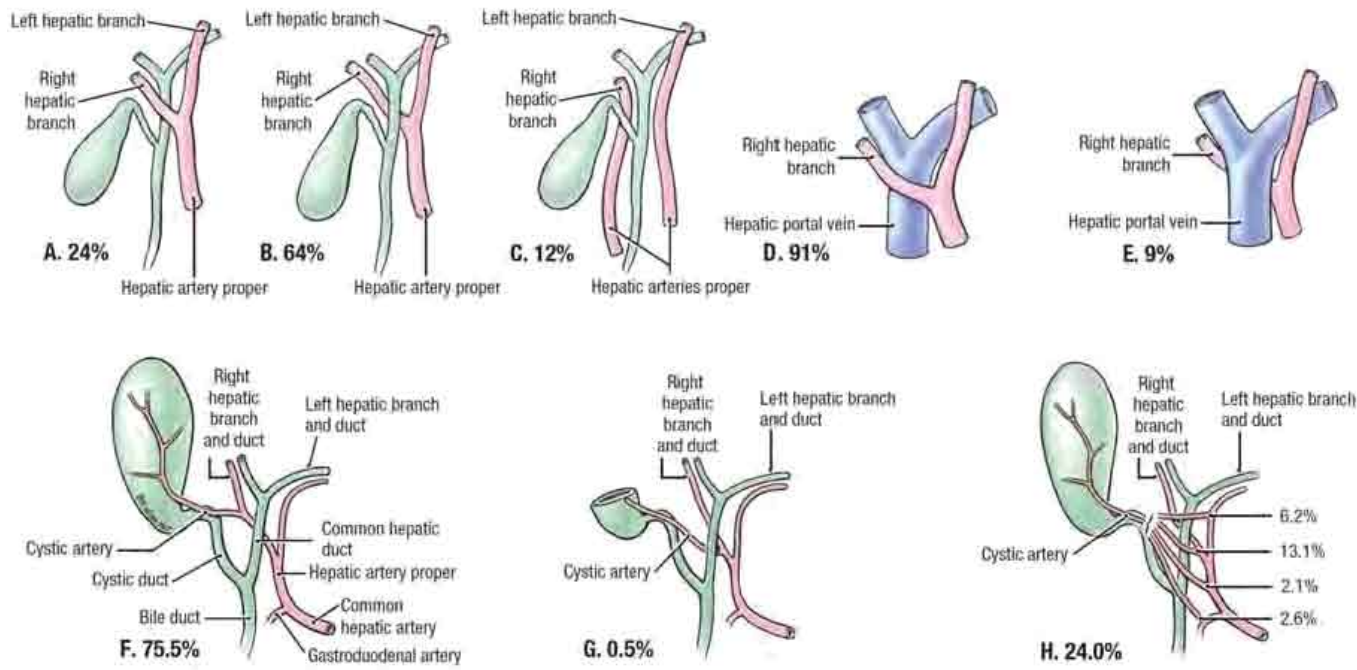
> Table of Contents > Chapter 2 - Abdomen > 2.57 Variations in hepatic and cystic arteries

---

## 2.57 Variations in hepatic and cystic arteries

*Part of* "Chapter 2 - Abdomen "

In a study of 165 cadavers, five patterns were observed. A. Right hepatic artery crossing anterior to bile passages, 24%. B. Right hepatic artery crossing posterior to bile passages, 64%. C. Aberrant artery arising from the superior mesenteric artery, 12%. The artery crossed anterior (D) to the portal vein in 91%, and posterior (E) in 9%. The cystic artery usually arises from the right hepatic artery in the angle between the common hepatic duct and cystic duct, without crossing the common hepatic duct (F and G) . However, when it arises on the left of the bile passages, it almost always crosses anterior to the passages (H) .



Anterior Views



**Authors:** Agur, Anne M.R.; Dalley, Arthur F.

**Title:** *Grant's Atlas of Anatomy, 12th Edition*

Copyright ©2009 Lippincott Williams & Wilkins

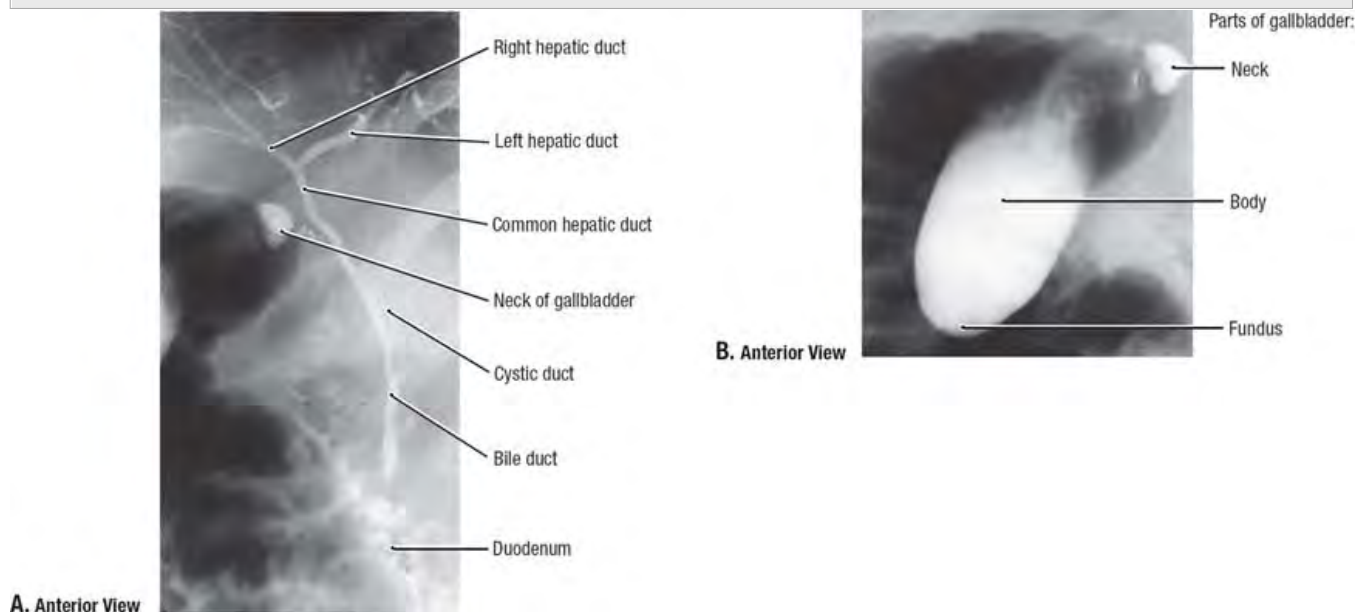
> Table of Contents > Chapter 2 - Abdomen > 2.58 Endoscopic retrograde cholangiography of gallbladder and biliary passages

## 2.58 Endoscopic retrograde cholangiography of gallbladder and biliary passages

*Part of "Chapter 2 - Abdomen"*

A. Cystic duct. B. Parts of gallbladder.

Endoscopic retrograde cholangiography (ERCP) is done by first passing a fiberoptic endoscope through the mouth, esophagus, and stomach. Then the duodenum is entered and a cannula is inserted into the major duodenal papilla and advanced under fluoroscopic control into the duct of choice (bile duct or pancreatic duct) for injection of radiographic contrast medium.





Authors: Agur, Anne M.R.; Dalley, Arthur F.

Title: *Grant's Atlas of Anatomy, 12th Edition*

Copyright ©2009 Lippincott Williams & Wilkins

> Table of Contents > Chapter 2 - Abdomen > 2.59 Variations of cystic and hepatic ducts and gallbladder

---

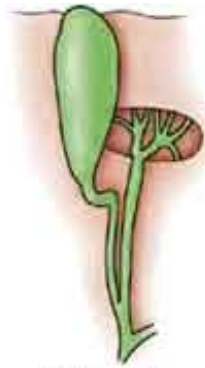## 2.59 Variations of cystic and hepatic ducts and gallbladder

*Part of "Chapter 2 - Abdomen "*

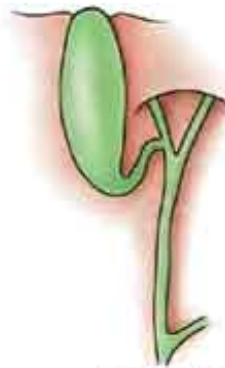
The cystic duct usually lies on the right side of the common hepatic duct, joining it just above the superior (1st) part of the duodenum, but this varies as in A – C . Of 95 gallbladders and bile passages studied, 7 had accessory ducts. Of these, 4 joined the common hepatic duct near the cystic duct (D) , 2 joined the cystic duct (E) , and 1 was an anastomosing duct connecting the cystic with the common hepatic duct. F. Folded gallbladder. G. Double gallbladder.

---

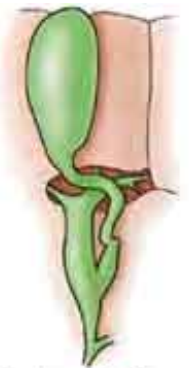
P.160



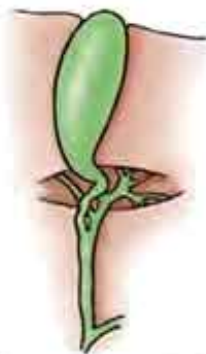**A. Low Union**



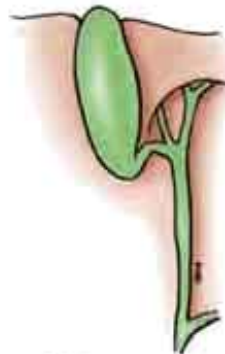**B. High Union**



**C. Swerving Course**



**D. Accessory Hepatic Duct**



**E. Accessory Hepatic Duct**



**F. Folded Gallbladder**



**G. Double Gallbladder**

Inferior Views

Authors: Agur, Anne M.R.; Dalley, Arthur F.

Title: *Grant's Atlas of Anatomy, 12th Edition*

Copyright ©2009 Lippincott Williams & Wilkins

> Table of Contents > Chapter 2 - Abdomen > 2.60 Portal venous system

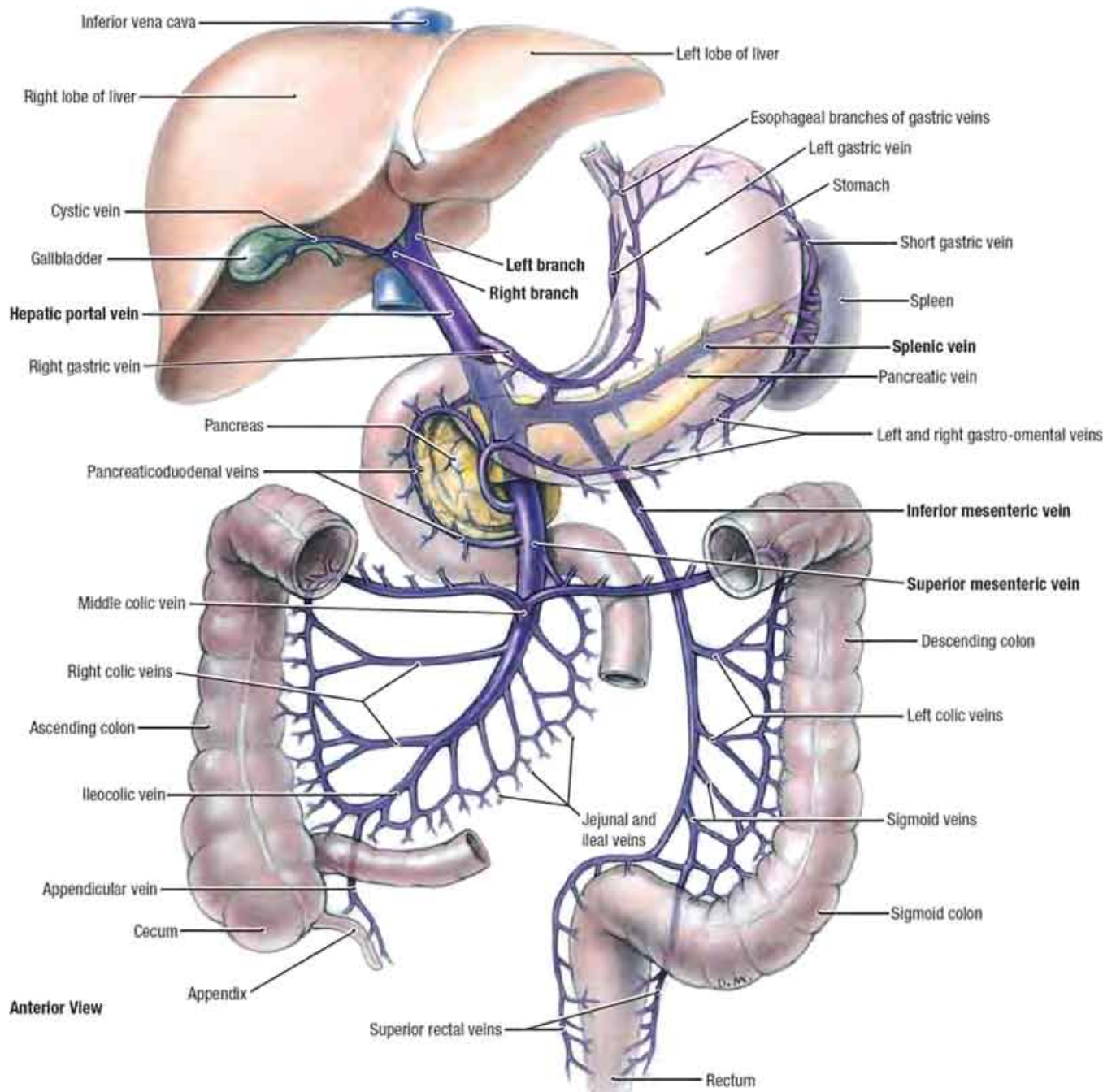
---

## 2.60 Portal venous system

*Part of* "Chapter 2 - Abdomen "

- The hepatic portal vein drains venous blood from the gastrointestinal tract, spleen, pancreas, and gallbladder to the sinusoids of the liver; from here, the blood is conveyed to the systemic venous system by the hepatic veins that drain directly to the inferior vena cava.
- The hepatic portal vein forms posterior to the neck of the pancreas by the union of the superior mesenteric and splenic veins, with the inferior mesenteric vein joining at or near the angle of union.
- The splenic vein drains blood from the inferior mesenteric, left gastro-omental (epiploic), short gastric, and pancreatic veins.
- The right gastro-omental, pancreaticoduodenal, jejunal, ileal, right, and middle colic veins drain into the superior mesenteric vein.
- The inferior mesenteric vein commences in the rectal plexus as the superior rectal vein and, after crossing the common iliac vessels, becomes the inferior mesenteric vein; branches include the sigmoid and left colic veins.
- The hepatic portal vein divides into right and left branches at the porta hepatis. The left branch carries mainly, but not exclusively, blood from the inferior mesenteric, gastric, and splenic veins, and the right branch carries blood mainly from the superior mesenteric vein.





Authors: Agur, Anne M.R.; Dalley, Arthur F.

Title: *Grant's Atlas of Anatomy, 12th Edition*

Copyright ©2009 Lippincott Williams & Wilkins

> Table of Contents > Chapter 2 - Abdomen > 2.61 Portacaval system

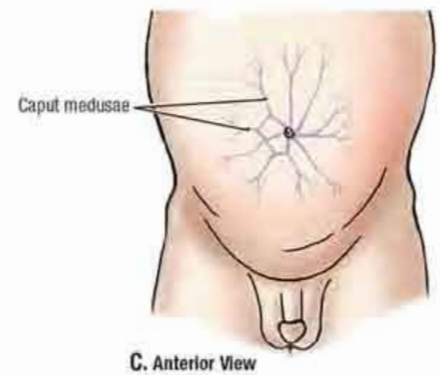
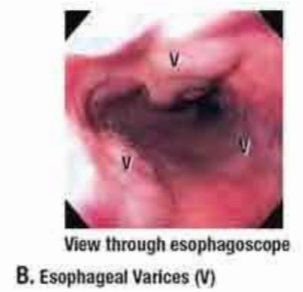
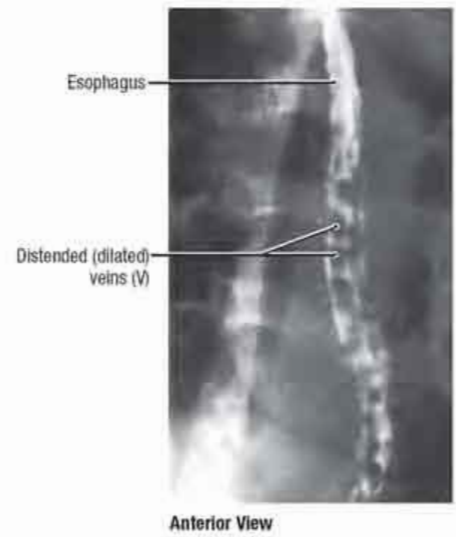
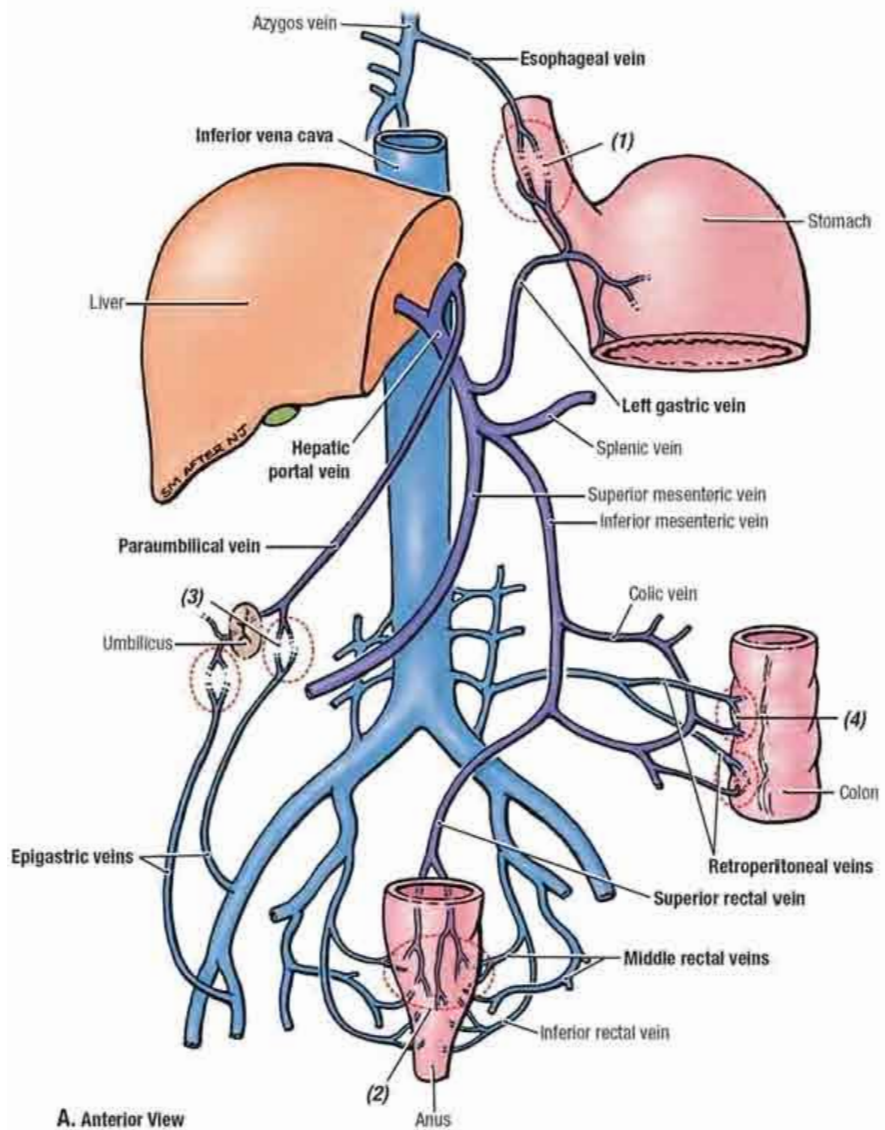
---

## 2.61 Portacaval system

*Part of "Chapter 2 - Abdomen "*

A. Portacaval system. In this diagram, portal tributaries are dark blue, and systemic tributaries and communicating veins are light blue.

In portal hypertension (as in hepatic cirrhosis), the portal blood cannot pass freely through the liver, and the portocaval anastomoses become engorged, dilated, or even varicose; as a consequence, these veins may rupture. The sites of the portocaval anastomosis shown are between (1) esophageal veins draining into the azygos vein (systemic) and left gastric vein (portal), which when dilated are esophageal varices, also shown in B ; (2) the inferior and middle rectal veins, draining into the inferior vena cava (systemic) and the superior rectal vein continuing as the inferior mesenteric vein (portal) (hemorrhoids result if the vessels are dilated); (3) paraumbilical veins (portal) and small epigastric veins of the anterior abdominal wall (systemic), which when varicose form "caput medusae" (so named because of the resemblance of the radiating veins to the serpents on the head of Medusa, a character in Greek mythology); and (4) twigs of colic veins (portal) anastomosing with systemic retroperitoneal veins. B. Esophageal varices. C. Caput medusae.



Authors: Agur, Anne M.R.; Dalley, Arthur F.

Title: *Grant's Atlas of Anatomy, 12th Edition*

Copyright ©2009 Lippincott Williams & Wilkins

> Table of Contents > Chapter 2 - Abdomen > 2.62 Posterior abdominal viscera and their anterior relations

---

## 2.62 Posterior abdominal viscera and their anterior relations

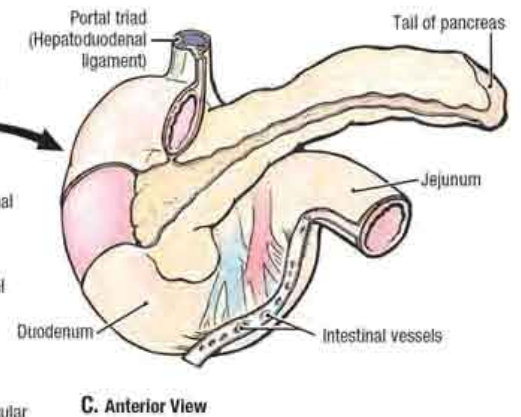
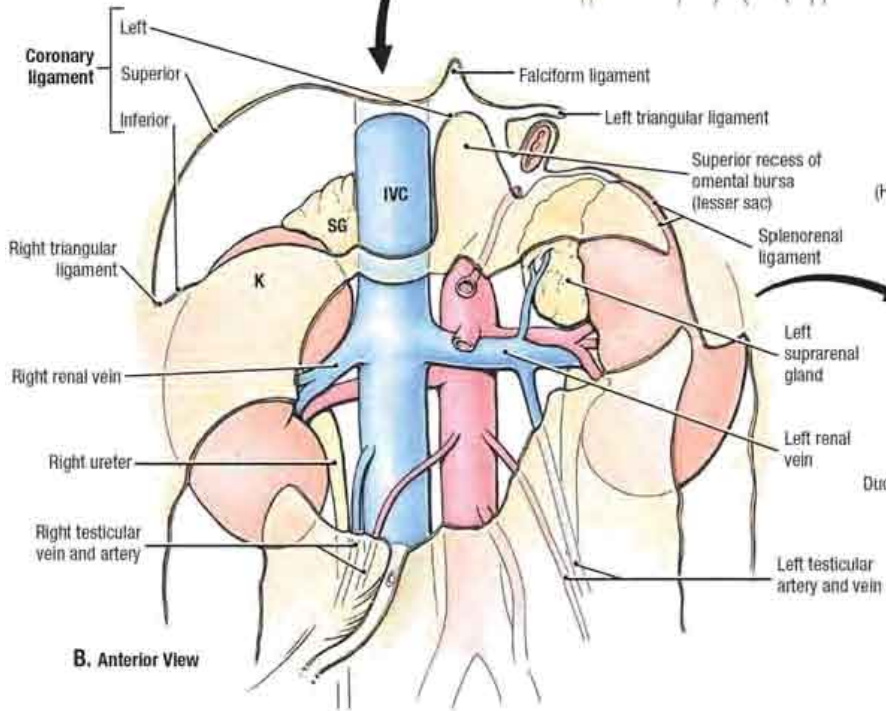
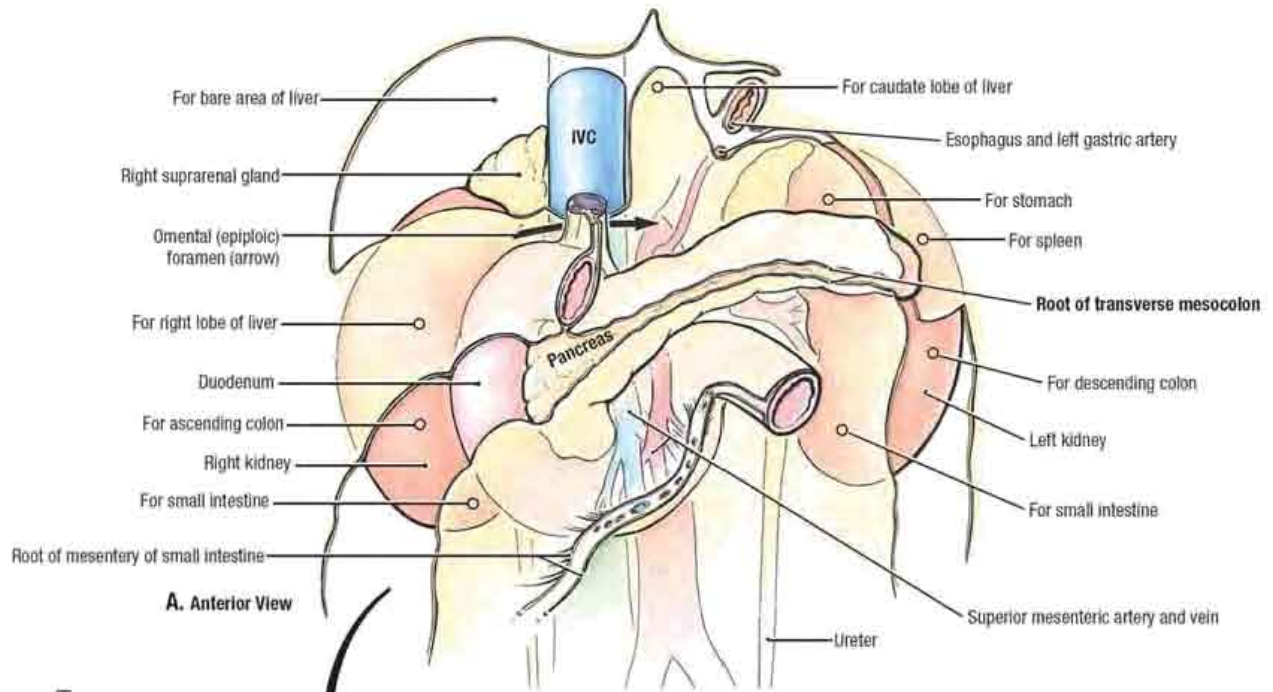
*Part of* "Chapter 2 - Abdomen "

The peritoneal coverings are yellow. A. Duodenum and pancreas in situ. Note the line of attachment of the root of the transverse mesocolon is to the body and tail of the pancreas. The viscera contacting specific regions are indicated by the term *œfor.*• The omental (epiploic) foramen is traversed by an arrow. B. After removal of duodenum and pancreas. The three parts of the coronary ligament are attached to the diaphragm, except where the inferior vena cava (IVC), suprarenal gland (SG), and kidney (K) intervene. C. Pancreas and duodenum removed from A.

---

P.163







Authors: Agur, Anne M.R.; Dalley, Arthur F.

Title: *Grant's Atlas of Anatomy, 12th Edition*

Copyright ©2009 Lippincott Williams & Wilkins

> Table of Contents > Chapter 2 - Abdomen > 2.63 Viscera and vessels of posterior abdominal wall

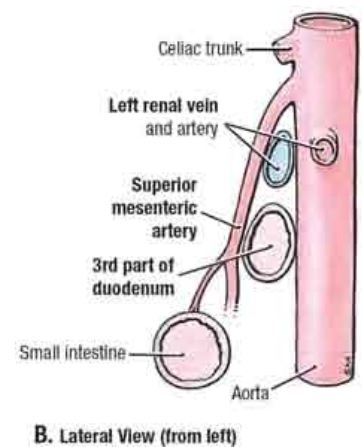
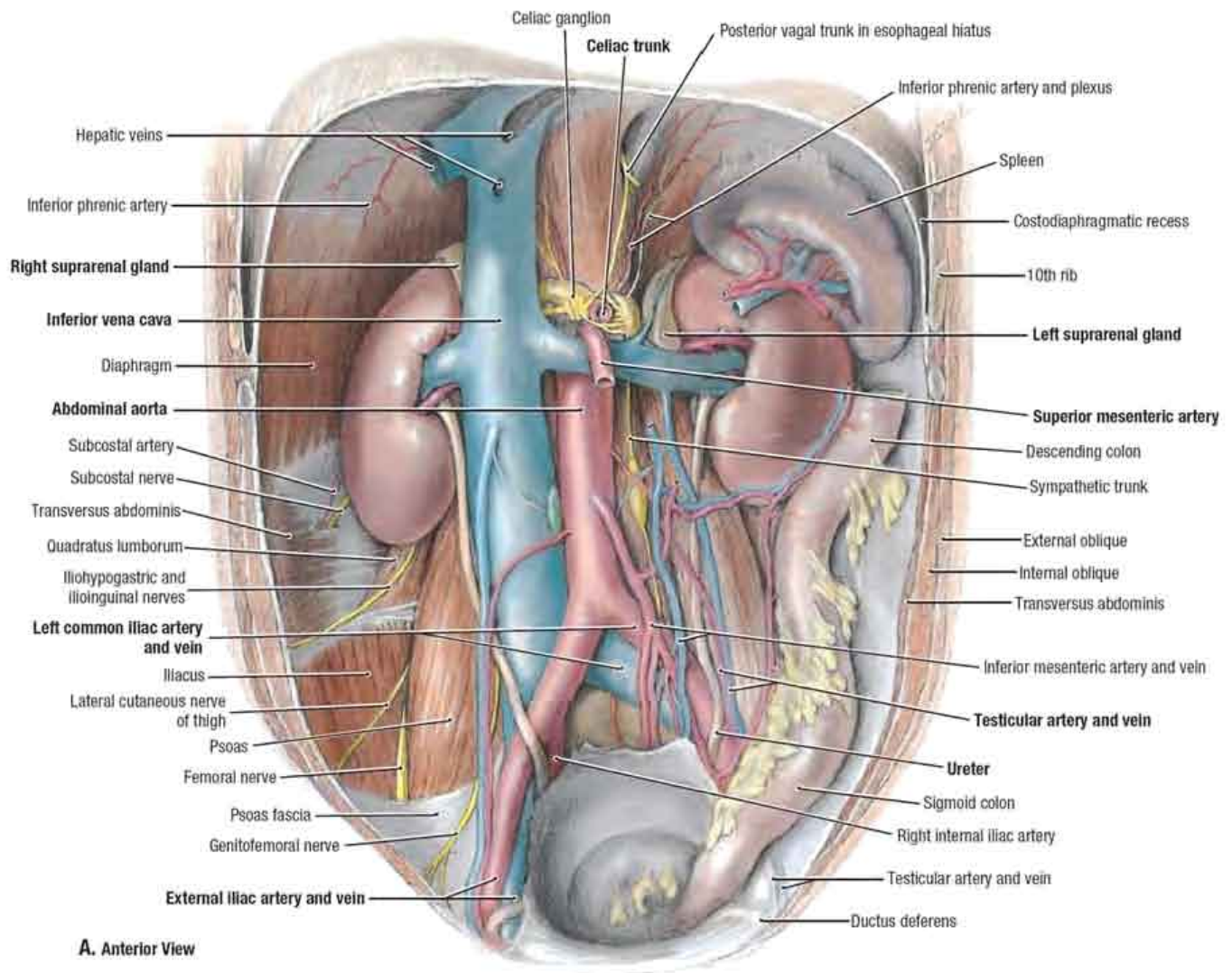
---

## 2.63 Viscera and vessels of posterior abdominal wall

*Part of* "Chapter 2 - Abdomen "

A. Great vessels, kidneys, and suprarenal glands. B. Relationships of left renal vein and inferior (3rd) part of duodenum to aorta and superior mesenteric artery.

- The abdominal aorta is shorter and smaller in caliber than the inferior vena cava.
- The inferior mesenteric artery arises about 4 cm superior to the aortic bifurcation and crosses the left common iliac vessels to become the superior rectal artery.
- The left renal vein drains the left testis, left suprarenal gland, and left kidney; the renal arteries are posterior to the renal veins.
- The ureter crosses the external iliac artery just beyond the common iliac bifurcation.
- The testicular vessels cross anterior to the ureter and join the ductus deferens at the deep inguinal ring.
- In B , the left renal vein and duodenum (and uncinate process of pancreas – not shown) pass between the aorta posteriorly and the superior mesenteric artery, anteriorly; they may be compressed like nuts in a nutcracker.



Authors: Agur, Anne M.R.; Dalley, Arthur F.

Title: *Grant's Atlas of Anatomy, 12th Edition*

Copyright ©2009 Lippincott Williams & Wilkins

> Table of Contents > Chapter 2 - Abdomen > 2.64 Exposure of the left kidney and suprarenal gland

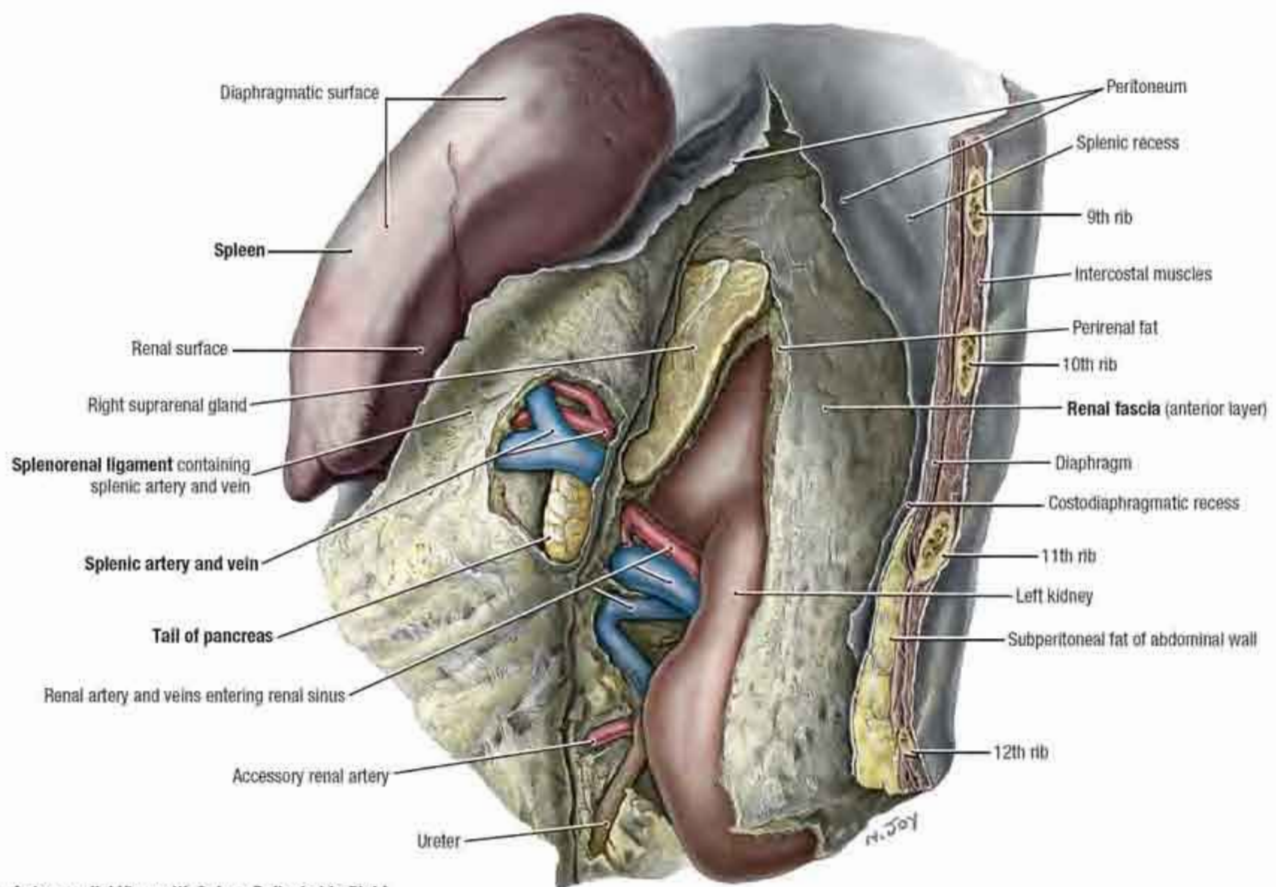
---

## 2.64 Exposure of the left kidney and suprarenal gland

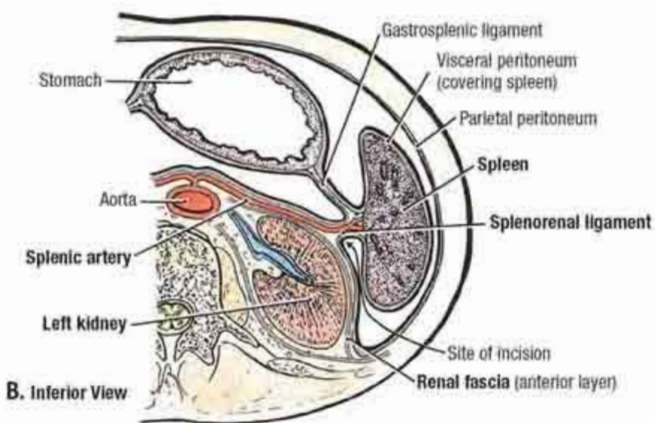
*Part of* "Chapter 2 - Abdomen "

A. Dissection. B. Schematic section with spleen and splenorenal ligament intact. C. Procedure used in A to expose the kidney. The spleen and splenorenal ligament are reflected anteriorly, with the splenic vessels and tail of the pancreas. Part of the renal fascia of the kidney is removed.

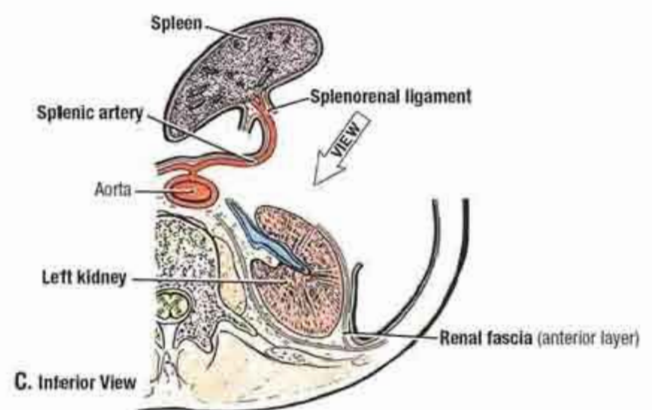
Note the proximity of the splenic vein and left renal vein, enabling a splenorenal shunt to be established surgically to relieve portal hypertension.



**A. Anteromedial View with Spleen Reflected to Right**



**B. Inferior View**



**C. Inferior View**

Authors: Agur, Anne M.R.; Dalley, Arthur F.

Title: *Grant's Atlas of Anatomy, 12th Edition*

Copyright ©2009 Lippincott Williams & Wilkins

> Table of Contents > Chapter 2 - Abdomen > 2.65 Kidneys and suprarenal glands

---

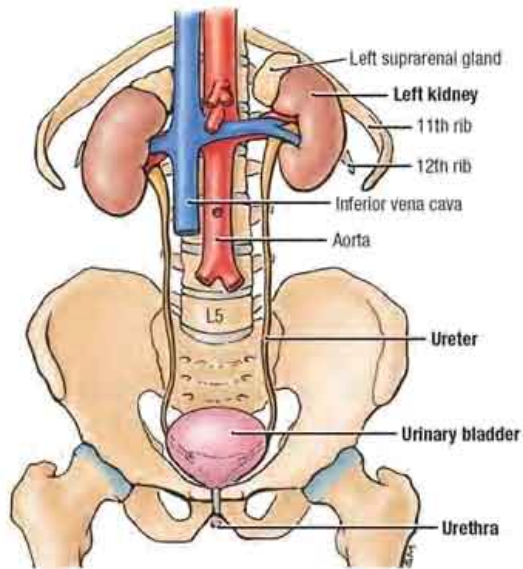
## 2.65 Kidneys and suprarenal glands

*Part of* "Chapter 2 - Abdomen "

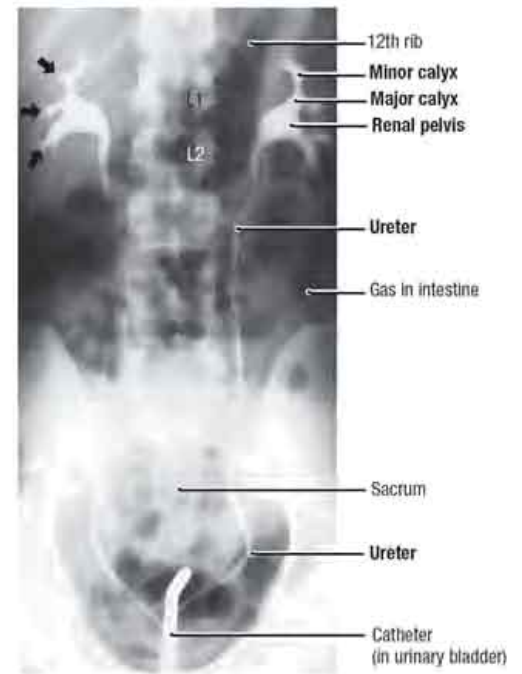
A. Overview of urinary system. B. Pyelogram. Radiopaque material occupies the cavities that normally conduct urine. Note the papillae (indicated with arrows) bulging into the minor calices, which empty into a major calyx that opens, in turn, into the renal pelvis drained by the ureter. C. Arterial supply of the suprarenal glands, kidneys and ureters.

Renal transplantation is now an established operation for the treatment of selected cases of chronic renal failure. The kidney can be removed from the donor without damaging the suprarenal gland because of the weak septum of renal fascia that separates the kidney from this gland. The site for transplanting a kidney is in the iliac fossa of the greater pelvis. The renal artery and vein are joined to the external iliac artery and vein, respectively, and the ureter is sutured into the urinary bladder.

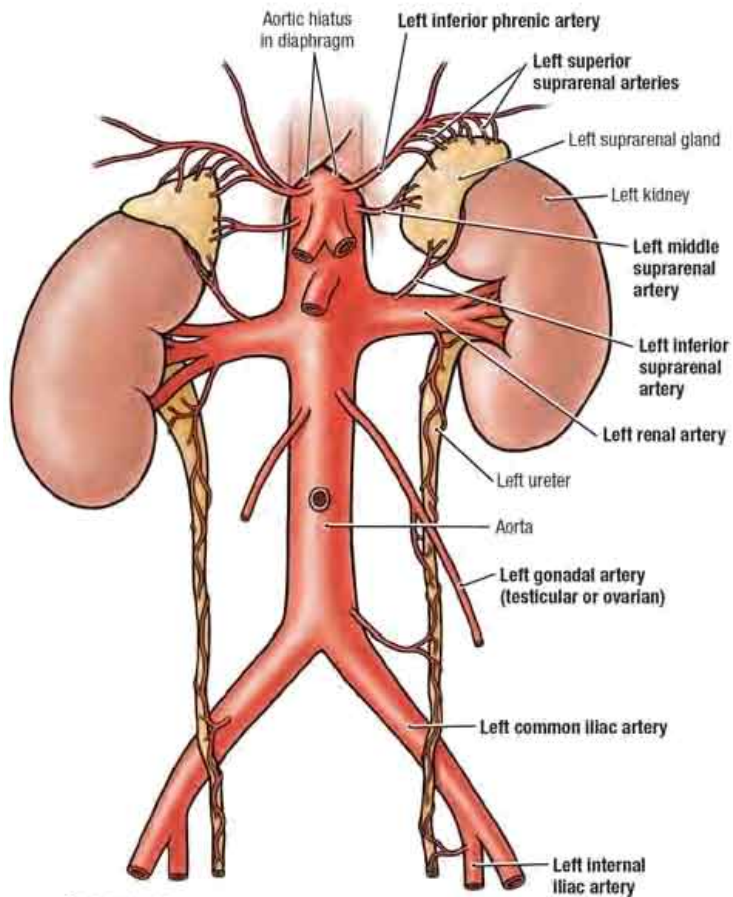




A. Anterior View



B. Anteroposterior Pyelogram



C. Anterior View

Authors: Agur, Anne M.R.; Dalley, Arthur F.

Title: *Grant's Atlas of Anatomy, 12th Edition*

Copyright ©2009 Lippincott Williams & Wilkins

> Table of Contents > Chapter 2 - Abdomen > 2.66 Structure of kidney

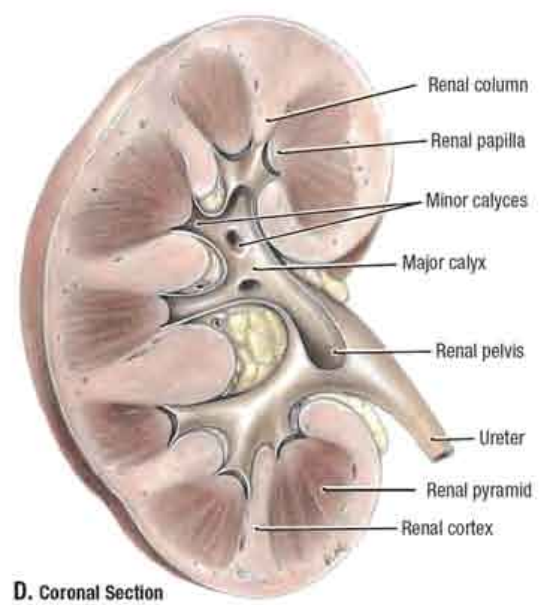
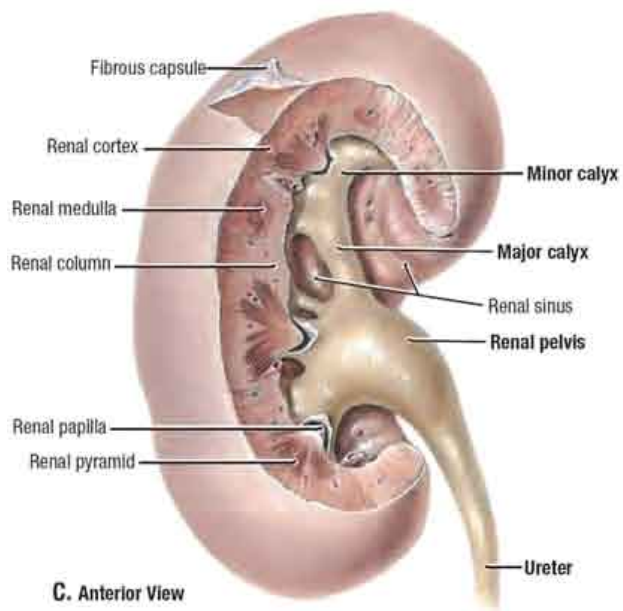
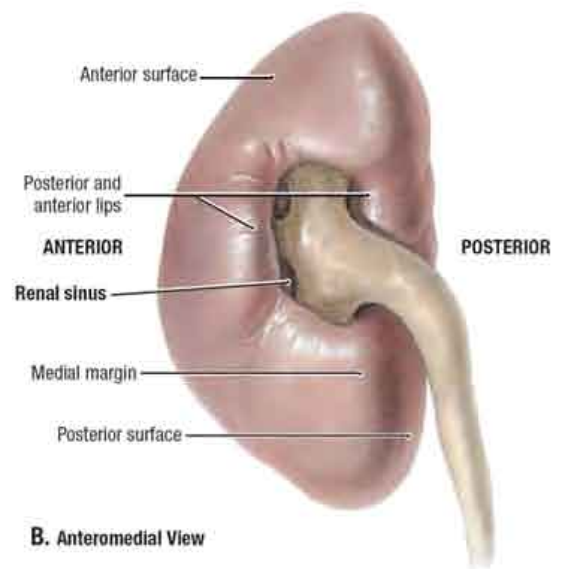
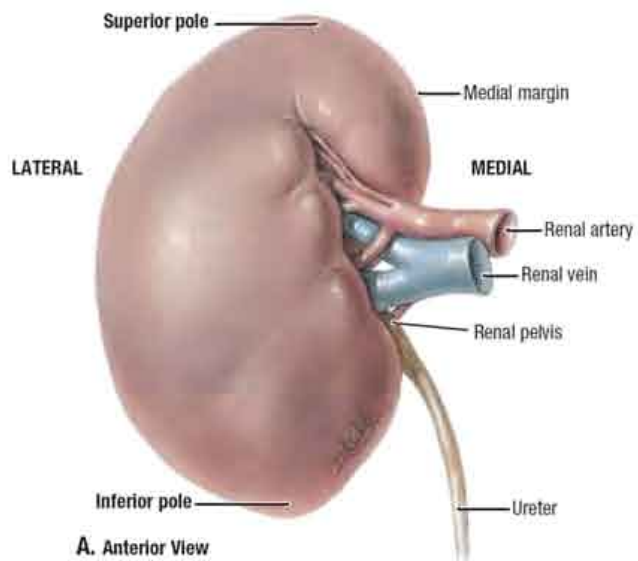
---

## 2.66 Structure of kidney

*Part of "Chapter 2 - Abdomen "*

A. External features. The superior pole of the kidney is closer to the median plane than the inferior pole. Approximately 25% of kidneys may have a 2nd, 3rd, and even 4th accessory renal artery branching from the aorta. These multiple vessels enter through the renal sinus or at the superior or inferior pole. B. Renal sinus. The renal sinus is a vertical "pocket" opening on the medial side of the kidney. Tucked into the pocket are the renal pelvis and renal vessels in a matrix of perirenal fat. C. Renal calices. The anterior wall of the renal sinus has been cut away to expose the renal pelvis and the calices. D. Internal features.

Cysts in the kidney, multiple or solitary, are common and usually benign findings during ultrasound examinations and dissection of cadavers. Adult polycystic disease of the kidneys, however, is an important cause of renal failure.



Authors: Agur, Anne M.R.; Dalley, Arthur F.

Title: *Grant's Atlas of Anatomy, 12th Edition*

Copyright ©2009 Lippincott Williams & Wilkins

> Table of Contents > Chapter 2 - Abdomen > 2.67 Segments of the kidneys

---

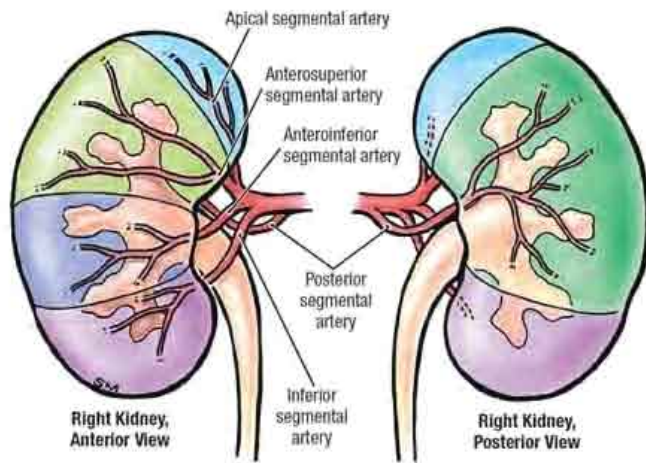
## 2.67 Segments of the kidneys

*Part of "Chapter 2 - Abdomen "*

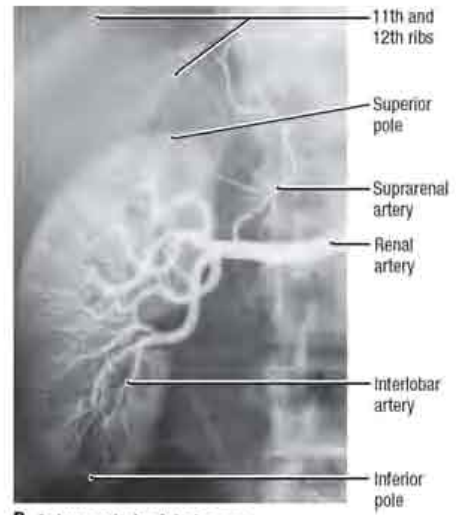

A. Segmental arteries. Segmental arteries do not anastomose significantly with other segmental arteries; they are end arteries.

The area supplied by each segmented artery is an independent, surgically respectable unit or renal segment.

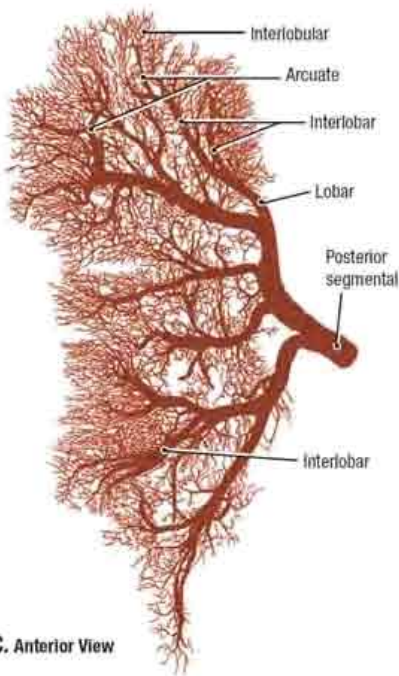
B. Renal arteriogram. C. Corrosion cast of posterior segmental artery of kidney. D. The nephron is the functional unit of the kidney consisting of a renal corpuscle, proximal tubule, nephron loop and distal tubule. Papillary ducts open onto renal papillae, emptying into minor calices.



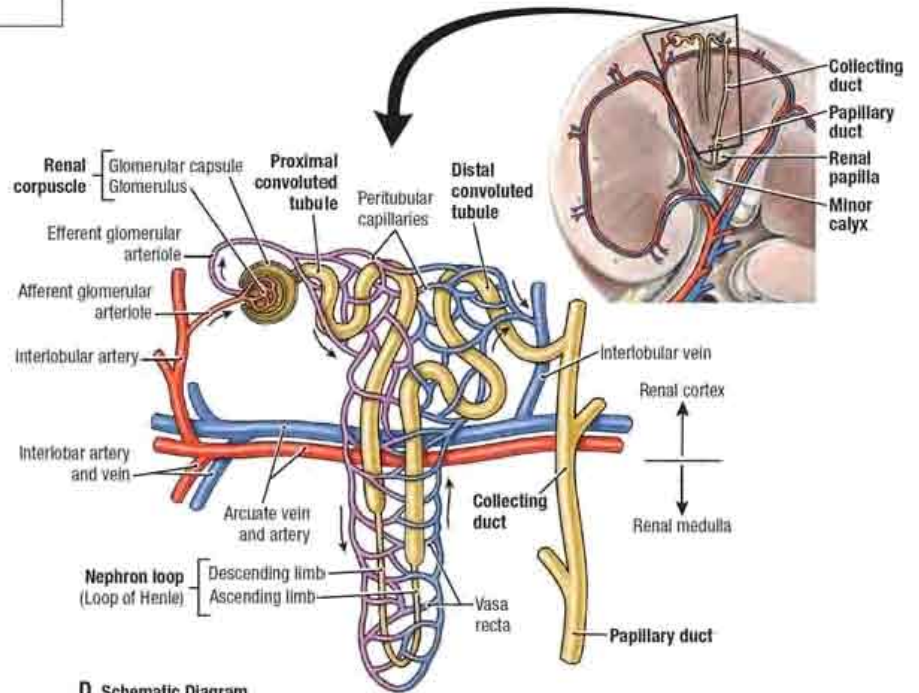
A



B. Anteroposterior Arteriogram



C. Anterior View



D. Schematic Diagram



Authors: Agur, Anne M.R.; Dalley, Arthur F.

Title: *Grant's Atlas of Anatomy, 12th Edition*

Copyright ©2009 Lippincott Williams & Wilkins

> Table of Contents > Chapter 2 - Abdomen > 2.68 Anomalies of kidney and ureter

---

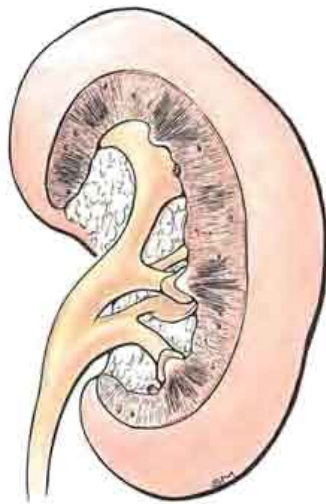
## 2.68 Anomalies of kidney and ureter

*Part of "Chapter 2 - Abdomen "*

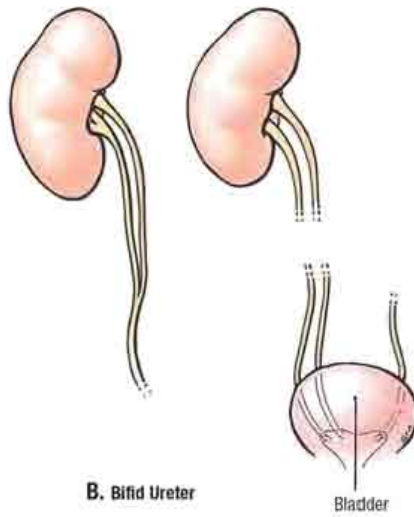
A. Bifid pelves. The pelves are almost replaced by two long major calices, which extend outside the sinus. B. Duplicated, or bifid, ureters. These can be unilateral or bilateral, and complete or incomplete. C. Retrocaval ureter. The ureter courses posterior and then anterior to the inferior vena cava. D. Horseshoe kidney. The right and left kidneys are fused in the midline. E. Ectopic pelvic kidney. Pelvic kidneys have no fatty capsule and can be unilateral or bilateral. During childbirth, they may cause obstruction and suffer injury.

---

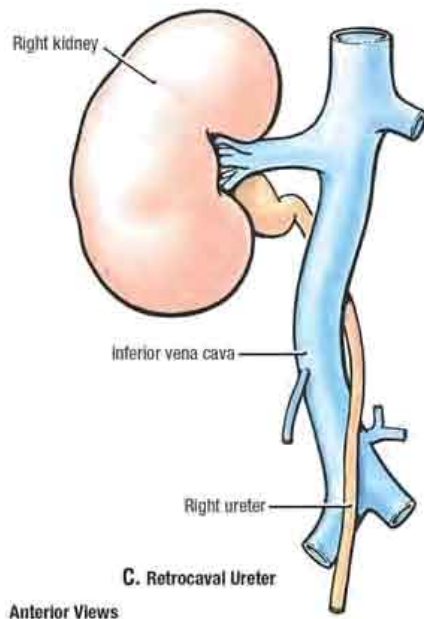
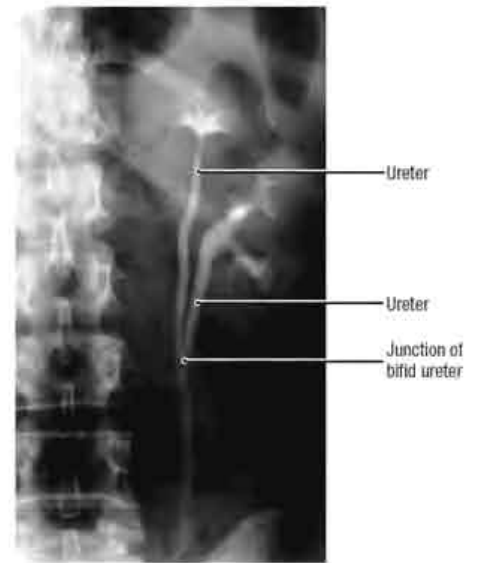
P.169



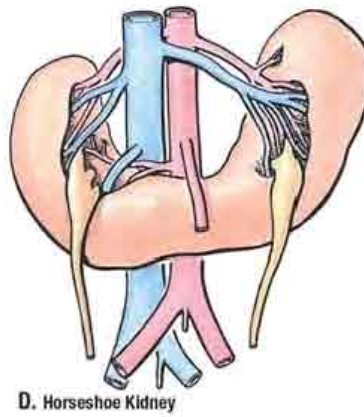
**A. Bifid Pelvis**



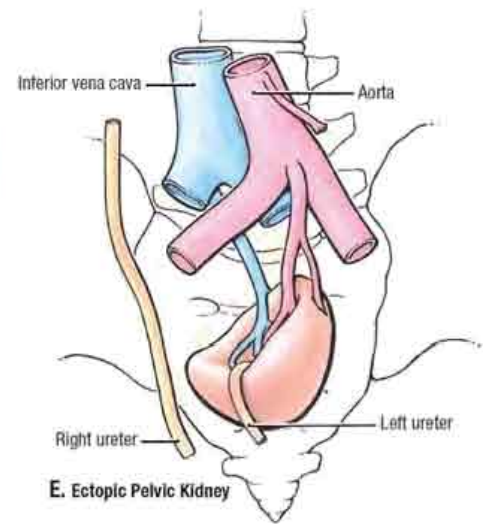
**B. Bifid Ureter**



**C. Retrocaval Ureter**  
Anterior Views



**D. Horseshoe Kidney**



**E. Ectopic Pelvic Kidney**

Authors: Agur, Anne M.R.; Dalley, Arthur F.

Title: *Grant's Atlas of Anatomy, 12th Edition*

Copyright ©2009 Lippincott Williams & Wilkins

> Table of Contents > Chapter 2 - Abdomen > 2.69 Exposure of kidney

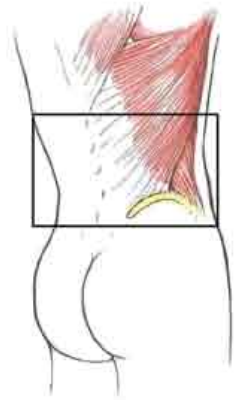
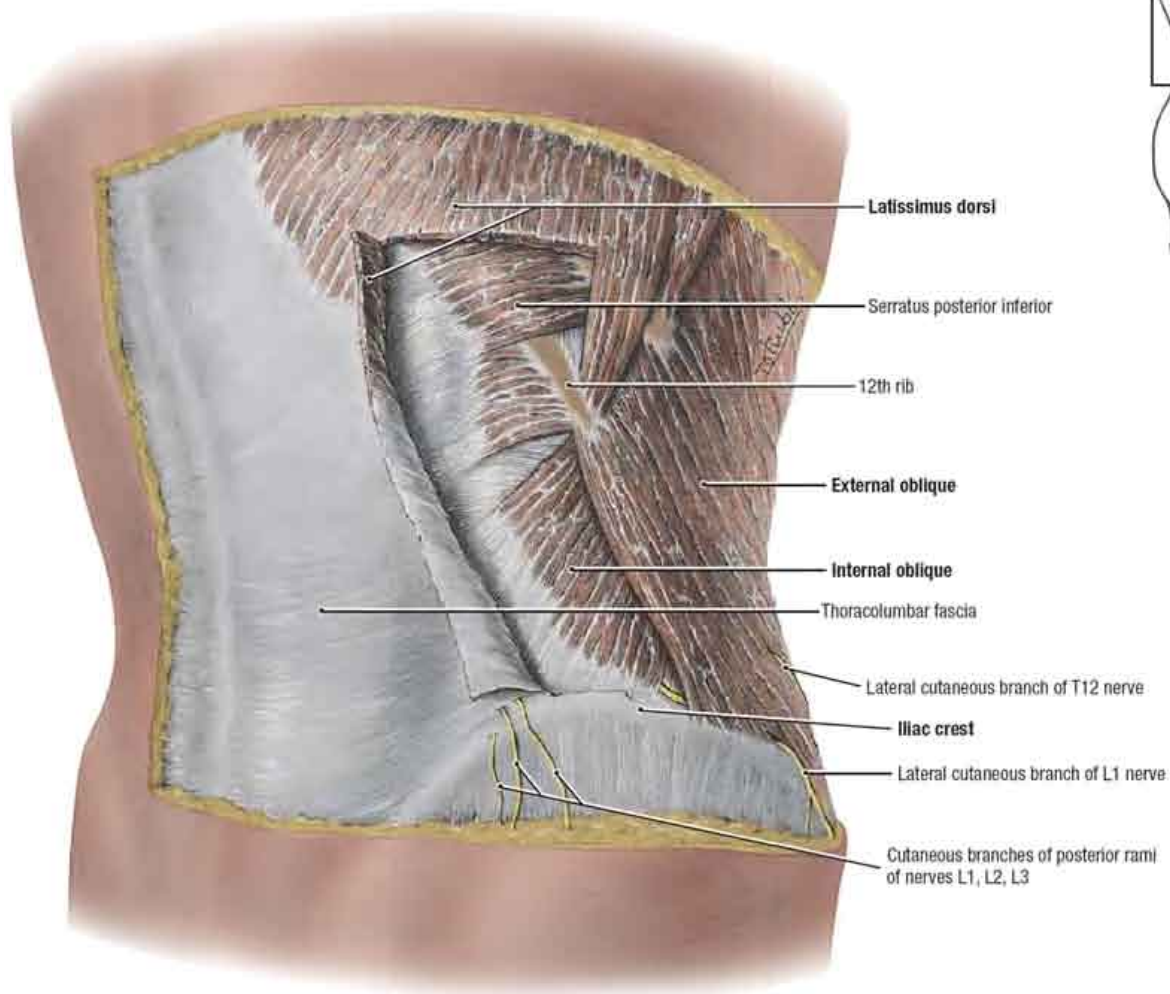
---

## 2.69 Exposure of kidney

*Part of* "Chapter 2 - Abdomen "

The latissimus dorsi is partially reflected.

- The external oblique muscle has an oblique, free posterior border that extends from the tip of the 12th rib to the midpoint of the iliac crest.
- The internal oblique muscle extends posteriorly beyond the border of the external oblique muscle.



Posterolateral View

Authors: Agur, Anne M.R.; Dalley, Arthur F.

Title: *Grant's Atlas of Anatomy, 12th Edition*

Copyright ©2009 Lippincott Williams & Wilkins

> Table of Contents > Chapter 2 - Abdomen > 2.70 Exposure of kidney II

---

## 2.70 Exposure of kidney II

*Part of* "Chapter 2 - Abdomen"

The external oblique muscle is incised and reflected laterally, and the internal oblique muscle is incised and reflected medially; the transversus abdominis muscle and its posterior aponeurosis are exposed where pierced by the subcostal (T12) and iliohypogastric (L1) nerves. These nerves give off motor twigs and lateral cutaneous branches and continue anteriorly between the internal oblique and transversus abdominis muscles.



Authors: Agur, Anne M.R.; Dalley, Arthur F.

Title: *Grant's Atlas of Anatomy, 12th Edition*

Copyright ©2009 Lippincott Williams & Wilkins

> Table of Contents > Chapter 2 - Abdomen > 2.71 Exposure of kidney and renal fascia

---

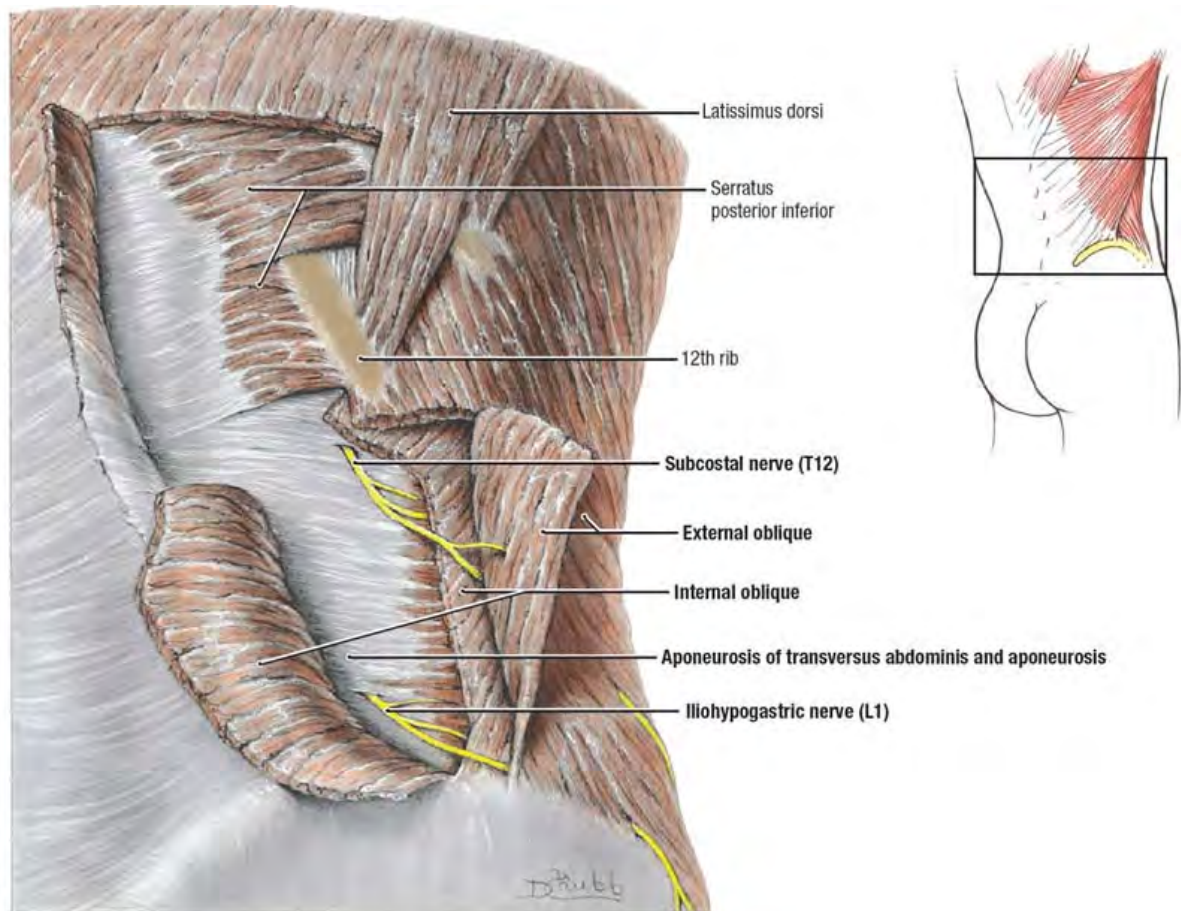
## 2.71 Exposure of kidney and renal fascia

*Part of "Chapter 2 - Abdomen "*

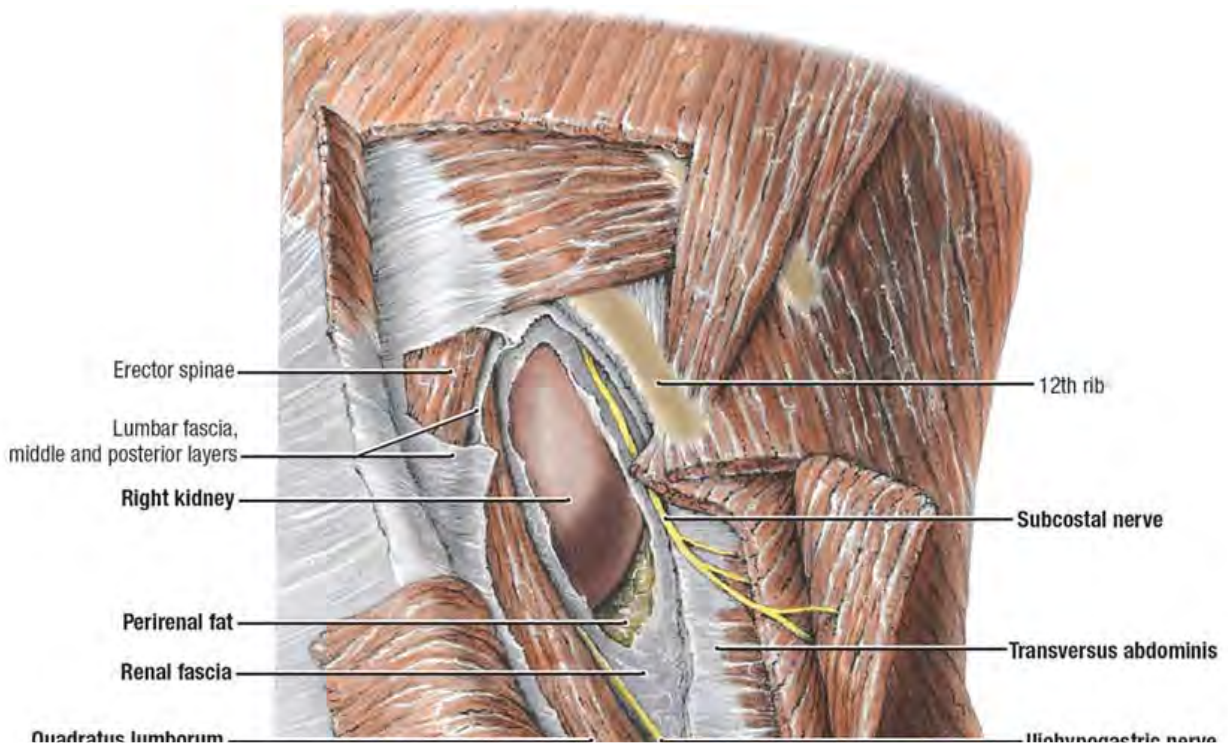
A. Dissection. The posterior aponeurosis of the transversus abdominis muscle is divided between the subcostal and iliohypogastric nerves and lateral to the oblique lateral border of the quadratus lumborum muscle; the retroperitoneal fat surrounding the kidney is exposed. B. Renal fascia and retroperitoneal fat, schematic transverse section. The renal fascia is within this fat; the portion of fat internal to the renal fascia is termed perinephric fat (perirenal fat capsule), and the fat immediately external is paranephric fat (pararenal fat body).

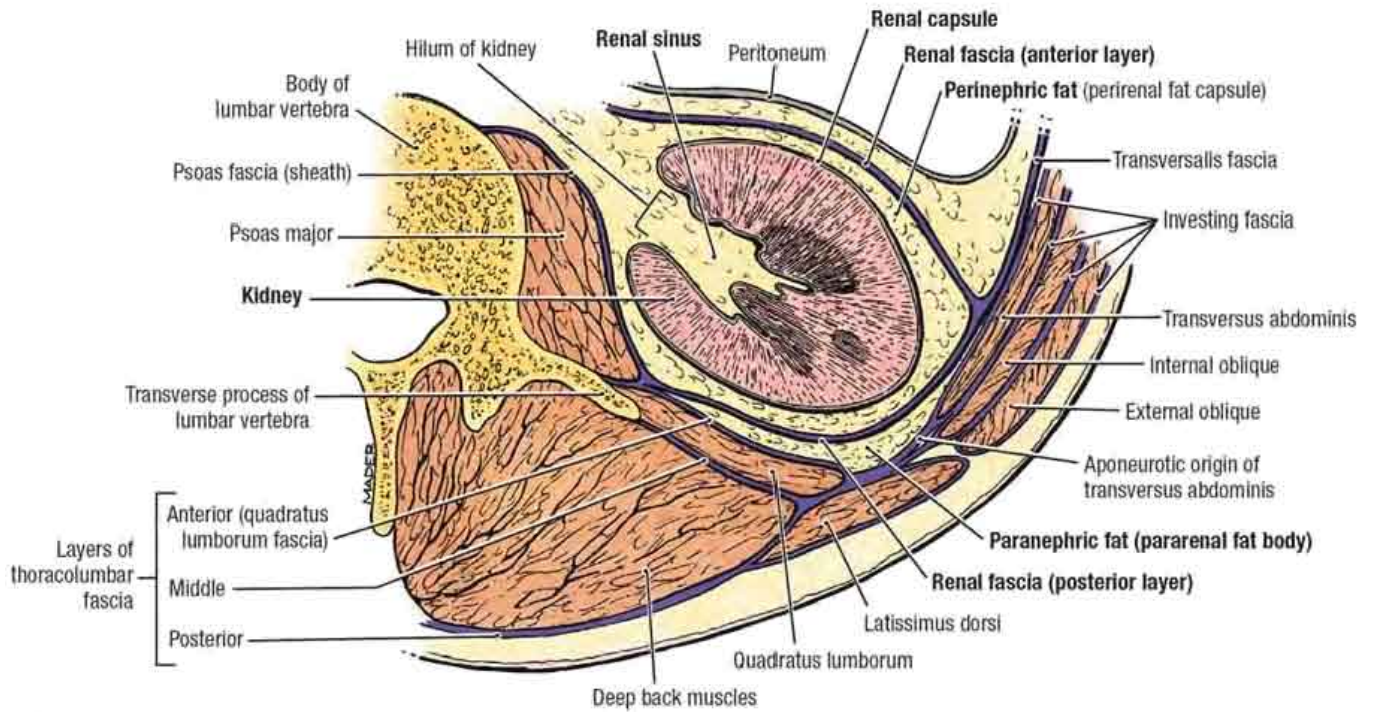
---

P.171



P.172





**B. Transverse Section**

**Authors:** Agur, Anne M.R.; Dalley, Arthur F.

**Title:** *Grant's Atlas of Anatomy, 12th Edition*

Copyright ©2009 Lippincott Williams & Wilkins

> Table of Contents > Chapter 2 - Abdomen > 2.72 Lumbar plexus and vertebral attachment of diaphragm

---

## 2.72 Lumbar plexus and vertebral attachment of diaphragm

*Part of* "Chapter 2 - Abdomen "

Psoas major, <sup>a b</sup>

Transverse processes of lumbar vertebrae; sides of bodies of T12–L5 vertebrae and intervening intervertebral discs

By a strong tendon to lesser trochanter of femur

Anterior rami of lumbar nerves (L1, L2, L3)

Acting inferiorly with iliacus, it flexes thigh at hip; acting superiorly, it flexes vertebral column laterally; it is used to balance the trunk; during sitting it acts inferiorly with iliacus to flex trunk

Iliacus <sup>a</sup>

Superior two thirds of iliac fossa, ala of sacrum; and anterior sacroiliac ligaments

Lesser trochanter of femur and shaft inferior to it, and to psoas major tendon

Femoral nerve (L2, L3)

Flexes thigh and stabilizes hip joint; acts with psoas major

Quadratus lumborum

Medial half of inferior border of 12th rib and tips of lumbar transverse processes

Iliolumbar ligament and internal lip of iliac crest

Anterior rami of T12 and L1-L4 nerves

Extends and laterally flexes vertebral column; fixes 12th rib during inspiration

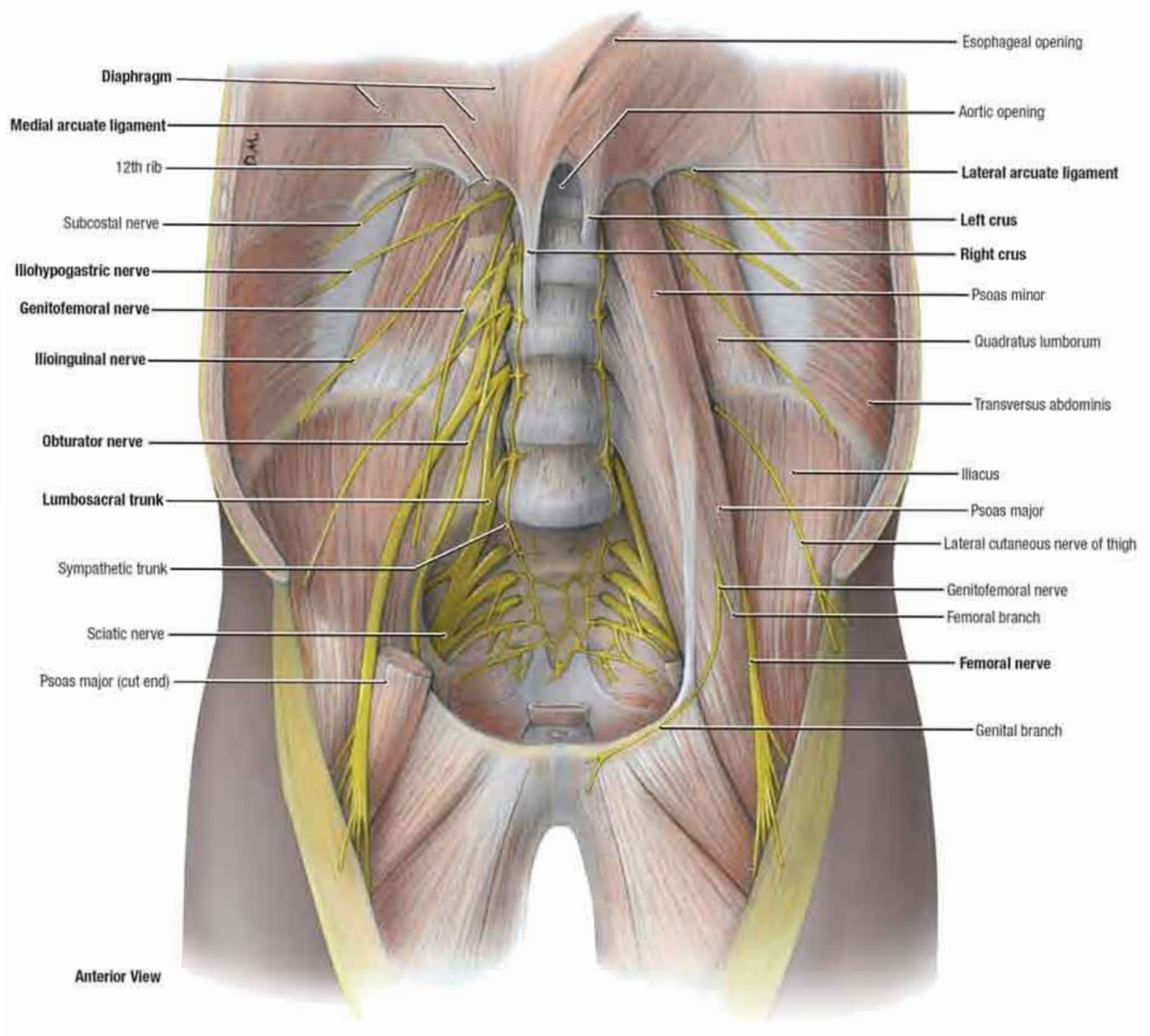
<sup>a</sup>Psoas major and iliacus muscles are often described together as the iliopsoas muscle when flexion of the thigh is discussed.

↳ Psoas minor attaches proximally to the sides of bodies of T12–L1 vertebrae and intervertebral disc and distally to the pectineal line and iliopectineal eminence via the iliopectineal arch; it does not cross the hip joint. It is used to balance the trunk, in conjunction with psoas major. Innervation is from the anterior rami of lumbar nerves (L1, L2).

Muscle	Superior Attachments	Inferior Attachments	Innervation	Actions
--------	----------------------	----------------------	-------------	---------

<h2>Table 2.5 Principal Muscles of Posterior Abdominal Wall</h2>
--





Authors: Agur, Anne M.R.; Dalley, Arthur F.

Title: *Grant's Atlas of Anatomy, 12th Edition*

Copyright ©2009 Lippincott Williams & Wilkins

> Table of Contents > Chapter 2 - Abdomen > 2.73 Nerves of the lumbar plexus

---

## 2.73 Nerves of the lumbar plexus

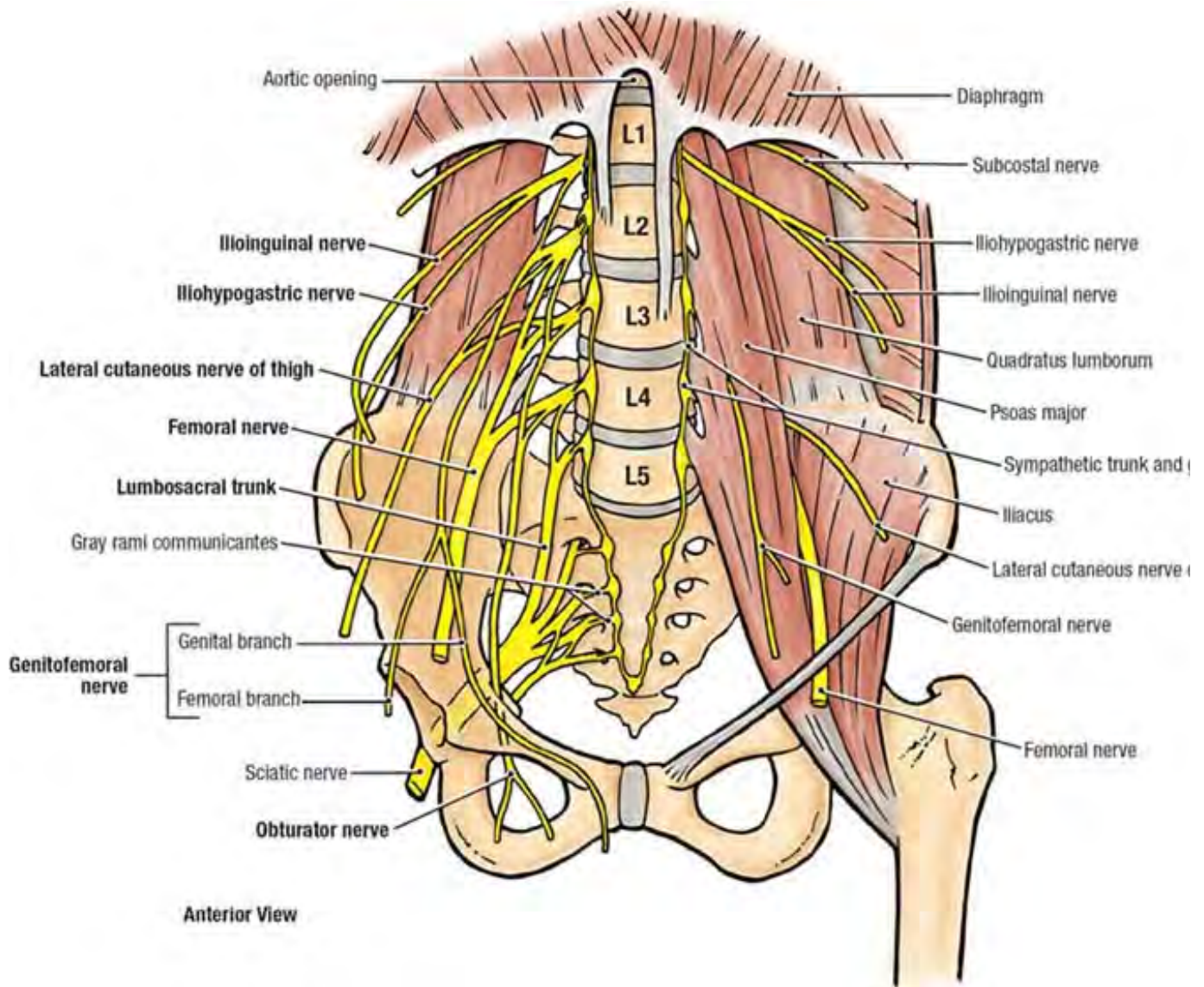
*Part of "Chapter 2 - Abdomen "*

The lumbar plexus of nerves is in the posterior part of the psoas major, anterior to the lumbar transverse processes. This nerve network is composed of the anterior rami of L1-L4 nerves. The rami receive gray rami communicates from the sympathetic trunks. The following nerves are branches of the lumbar plexus:

- Iliioinguinal and iliohypogastric nerves (L1) arise from the anterior ramus of L1 and enter the abdomen posterior to the medial arcuate ligaments and pass inferolaterally, anterior to the quadratus lumborum muscle; they pierce the transversus abdominis muscle near the anterior superior iliac spine and pass through the internal and external oblique muscles to supply the skin of the suprapubic and inguinal regions.
- Lateral cutaneous nerve of thigh (L2, L3) runs inferolaterally on the iliacus muscle and enters the thigh posterior to the inguinal ligament, just medial to the anterior superior iliac spine; it supplies the skin on the anterolateral surface of the thigh.
- Femoral nerve (L2-L4) emerges from the lateral border of the psoas and innervates the iliacus muscle and the extensor muscles of the knee.
- Genitofemoral nerve (L1, L2) pierces the anterior surface of the psoas major muscle and runs inferiorly on it deep to the psoas fascia; it divides lateral to the common and external iliac arteries into femoral and genital branches.
- Obturator nerve (L2-L4) emerges from the medial border of the psoas to supply the adductor muscles of the thigh.

- Lumbosacral trunk (L4, L5) passes over the ala (wing) of the sacrum and descends in the pelvis to take part in the formation of the sacral plexus along with the anterior rami of S1-S4 nerves.

P.174



Authors: Agur, Anne M.R.; Dalley, Arthur F.

Title: *Grant's Atlas of Anatomy, 12th Edition*

Copyright ©2009 Lippincott Williams & Wilkins

> Table of Contents > Chapter 2 - Abdomen > 2.74 Diaphragm

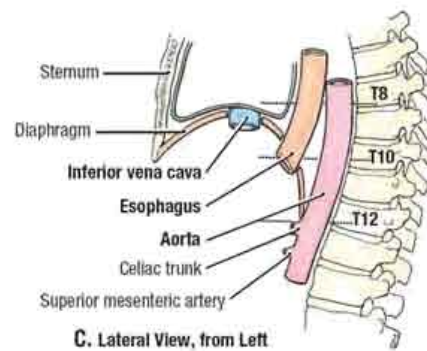
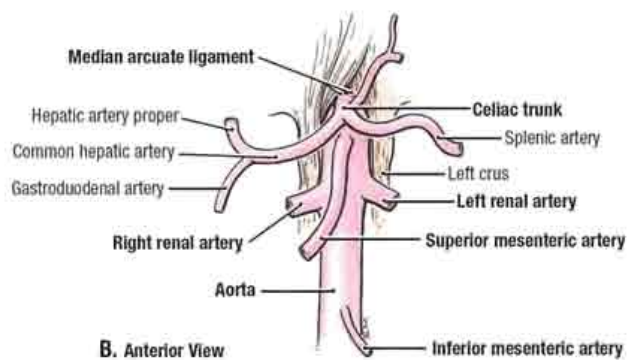
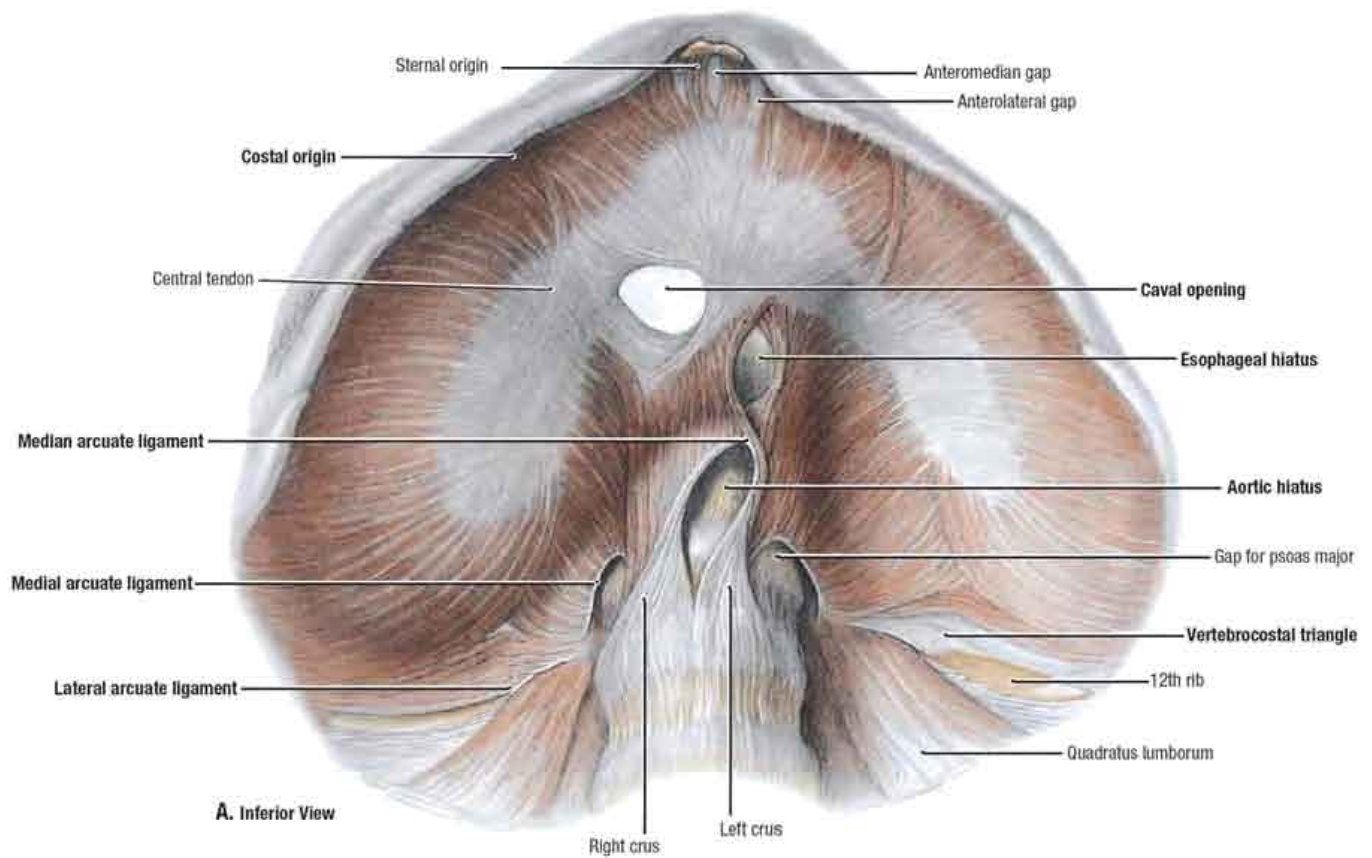
---

## 2.74 Diaphragm

*Part of "Chapter 2 - Abdomen "*

A. Dissection. The clover-shaped central tendon is the aponeurotic insertion of the muscle. The diaphragm in this specimen fails to arise from the left lateral arcuate ligament, leaving a potential opening, the vertebrocostal triangle, through which abdominal contents may be herniated into the thoracic cavity. B. Median arcuate ligament and branches of the aorta. C. Openings of the diaphragm. There are three major openings through which major structures pass from the thorax into the abdomen: the caval opening for the inferior vena cava, most anterior, at the T8 vertebral level to the right of the midline; the esophageal hiatus, intermediate, at T10 level and to the left; and the aortic hiatus, which allows the aorta to pass posterior to the vertebral attachment of the diaphragm in the midline at T12.







Authors: Agur, Anne M.R.; Dalley, Arthur F.

Title: *Grant's Atlas of Anatomy, 12th Edition*

Copyright ©2009 Lippincott Williams & Wilkins

> Table of Contents > Chapter 2 - Abdomen > 2.75 Abdominal aorta and inferior vena cava and their branches

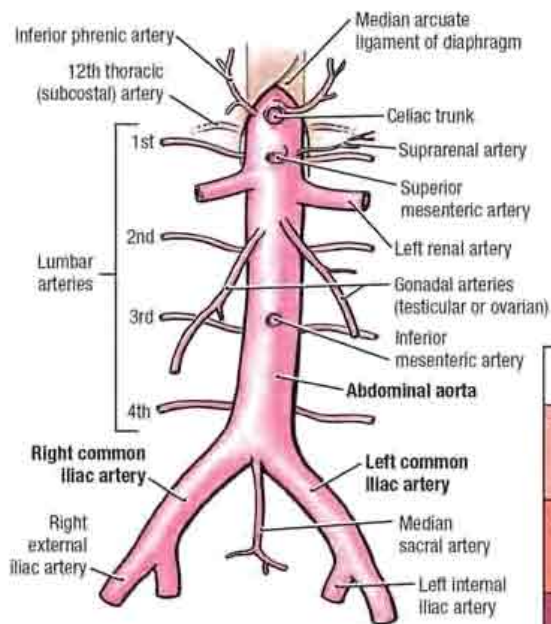
---

## 2.75 Abdominal aorta and inferior vena cava and their branches

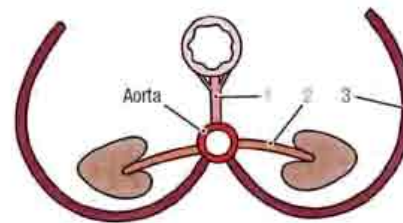
*Part of "Chapter 2 - Abdomen "*

A. Branches of abdominal aorta. B. Tributaries of the inferior vena cava (IVC). The asymmetry in the renal and common iliac veins reflects the placement of the IVC to the right of the midline.

Rupture of an aneurysm (localized enlargement) of the abdominal aorta causes severe pain in the abdomen or back. If unrecognized, a ruptured aneurysm has a mortality of nearly 90% because of heavy blood loss. Surgeons can repair an aneurysm by opening it, inserting a prosthetic graft (such as one made of Dacron), and sewing the wall of the aneurysmal aorta over the graft to protect it. Aneurysms may also be treated by endovascular catheterization procedures.

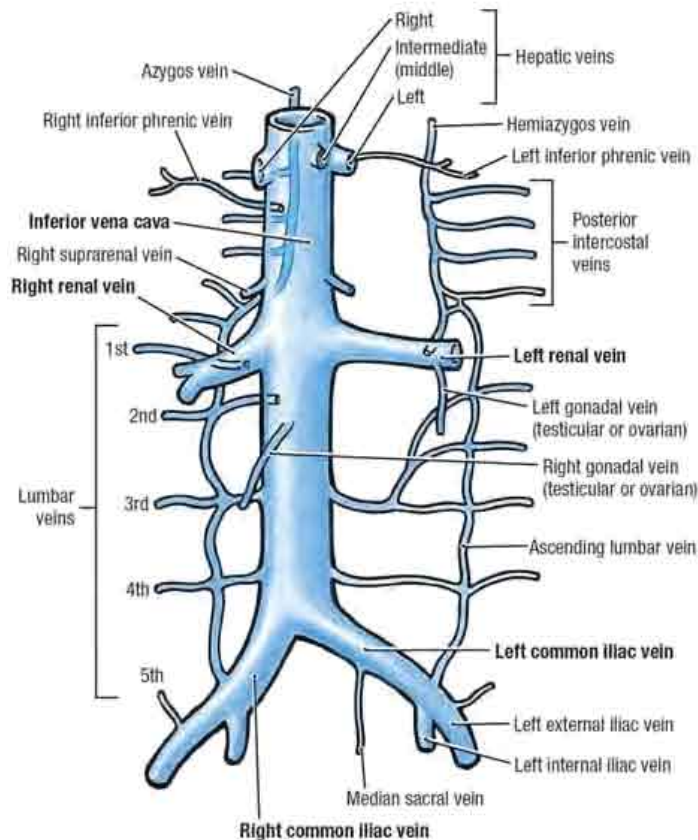


A. Anterior View



Three Vascular Planes

	Vascular plane	Class	Distribution	Abdominal Branches (Arteries)	Vertebral Level
1	Anterior midline	Unpaired visceral	Alimentary tract	Celiac	T12
				Superior mesenteric (SMA)	L1
				Inferior mesenteric (IMA)	L3
2	Lateral	Paired visceral	Urogenital and endocrine organs	Suprarenal	L1
				Renal	L1
				Gonadal (testicular or ovarian)	L2
3	Posterior-lateral (segmental)	Paired parietal	Diaphragm Body Wall	Subcostal	T12
				Inferior phrenic	T12
				Lumbar	L1-L4



B. Anterior View

Authors: Agur, Anne M.R.; Dalley, Arthur F.

Title: *Grant's Atlas of Anatomy, 12th Edition*

Copyright ©2009 Lippincott Williams & Wilkins

> Table of Contents > Chapter 2 - Abdomen > 2.76 Abdominopelvic nerve plexuses and ganglia

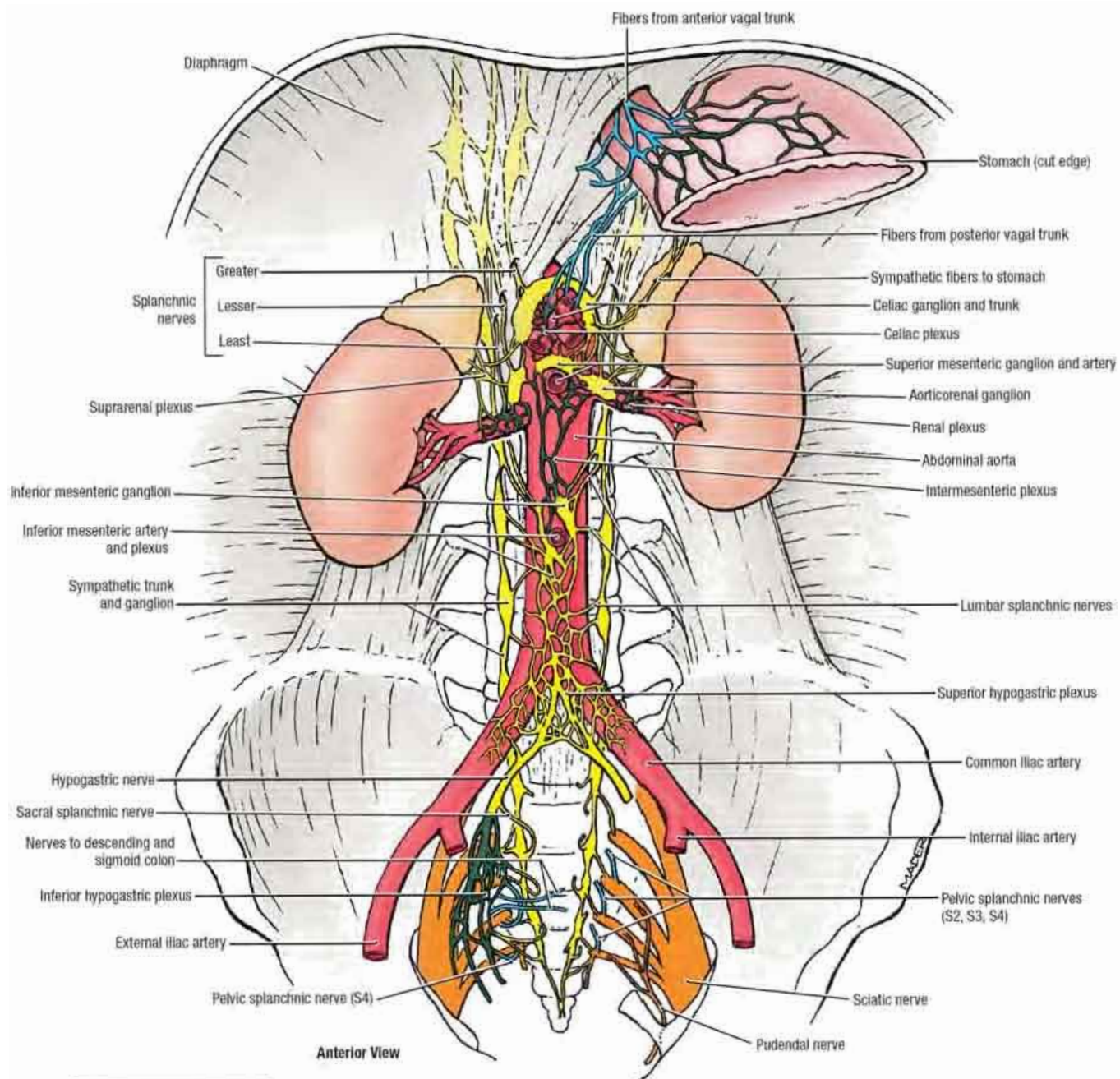
---

## 2.76 Abdominopelvic nerve plexuses and ganglia

*Part of* "Chapter 2 - Abdomen "

---

P.177



<span style="color: yellow;">■</span>	Sympathetic
<span style="color: blue;">■</span>	Parasympathetic
<span style="color: green;">■</span>	Plexuses (sympathetic and parasympathetic)
<span style="color: orange;">■</span>	Sacral plexus (somatic)

Authors: Agur, Anne M.R.; Dalley, Arthur F.

Title: *Grant's Atlas of Anatomy, 12th Edition*

Copyright ©2009 Lippincott Williams & Wilkins

> Table of Contents > Chapter 2 - Abdomen > 2.77 Overview of autonomic nervous system

---

## 2.77 Overview of autonomic nervous system

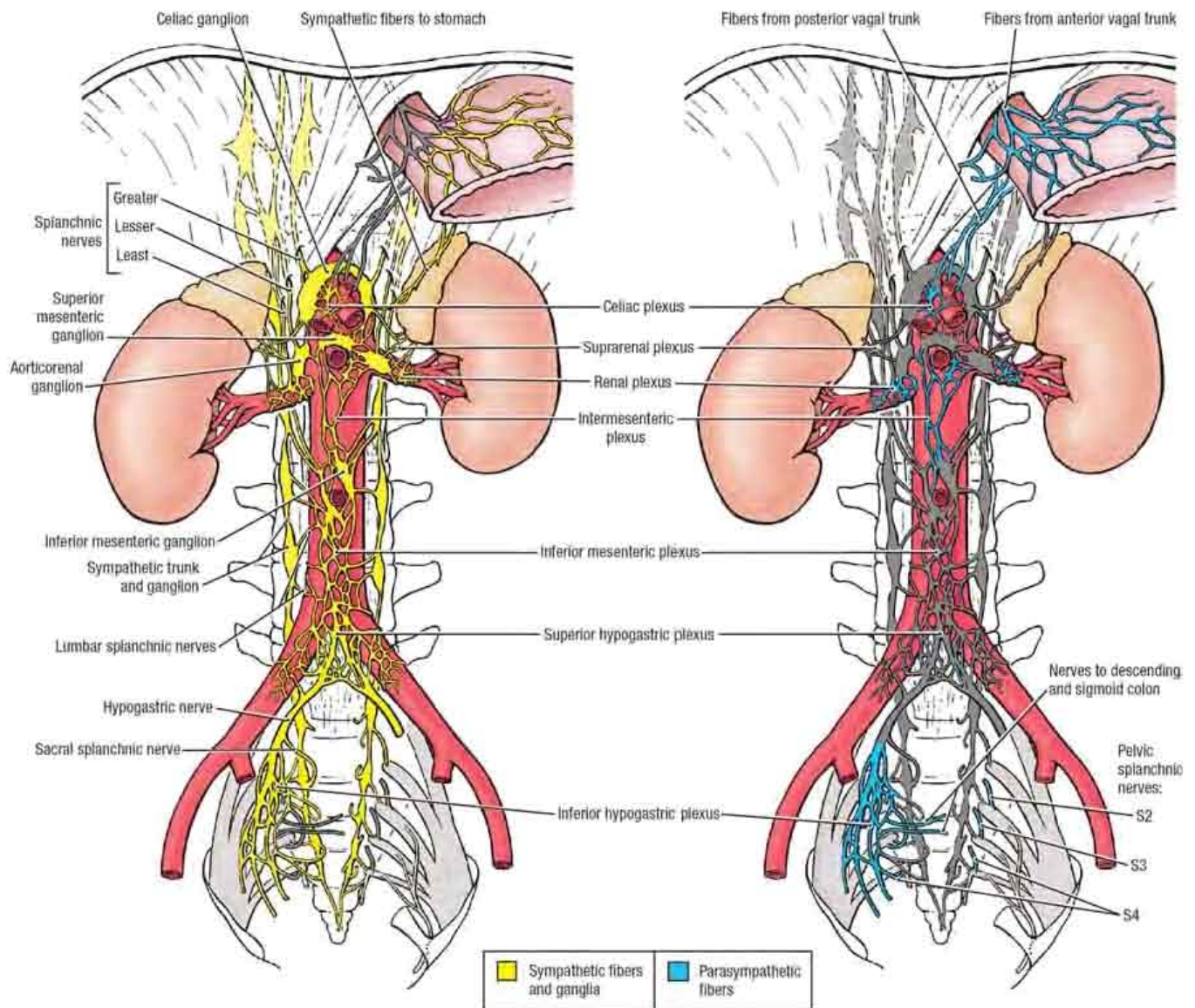
*Part of* "Chapter 2 - Abdomen "

A. Sympathetic. B. Parasympathetic.

---

P.178





**A. Sympathetic Innervation**

**Anterior Views**

**B. Parasympathetic Innervation**

Authors: Agur, Anne M.R.; Dalley, Arthur F.

Title: *Grant's Atlas of Anatomy, 12th Edition*

Copyright ©2009 Lippincott Williams & Wilkins

> Table of Contents > Chapter 2 - Abdomen > 2.78 Origin and distribution of presynaptic and postsynaptic sympathetic and parasympathetic fibers, and the ganglia involved in supplying abdominal viscera

---

## 2.78 Origin and distribution of presynaptic and postsynaptic sympathetic and parasympathetic fibers, and the ganglia involved in supplying abdominal viscera

*Part of* "Chapter 2 - Abdomen "

A. Overview. B. Fibers supplying the intrinsic plexuses of abdominal viscera.

---

P.179

A. Cardiopulmonary (Cervical and upper thoracic)

Postsynaptic

Sympathetic

Cervical and upper thoracic sympathetic trunk

Thoracic cavity (viscera superior to level of diaphragm)

B. Abdominopelvic

1. Lower thoracic

a. Greater

b. Lesser

c. Least

2. Lumbar

3. Sacral

## Presynaptic

Lower thoracic and abdominopelvic sympathetic trunk:

1. Thoracic sympathetic trunk:
  - a. T5–T9 or T10 level
  - b. T10–T11 level
  - c. T12 level
2. Abdominal sympathetic trunk
3. Pelvic (sacral) sympathetic trunk

Abdominopelvic cavity (prevertebral ganglia serving viscera and suprarenal glands inferior to level of diaphragm)

- 1. Abdominal prevertebral ganglia:
  - a. Celiac ganglia
  - b. Aorticorenal ganglia
  - c. & 2. Other abdominal prevertebral ganglia (superior and inferior mesenteric, and of inter-mesenteric/hypogastric plexuses
- 3. Pelvic prevertebral ganglia

## C. Pelvic

### Presynaptic

### Parasympathetic


Anterior rami of S2–S4 spinal nerves

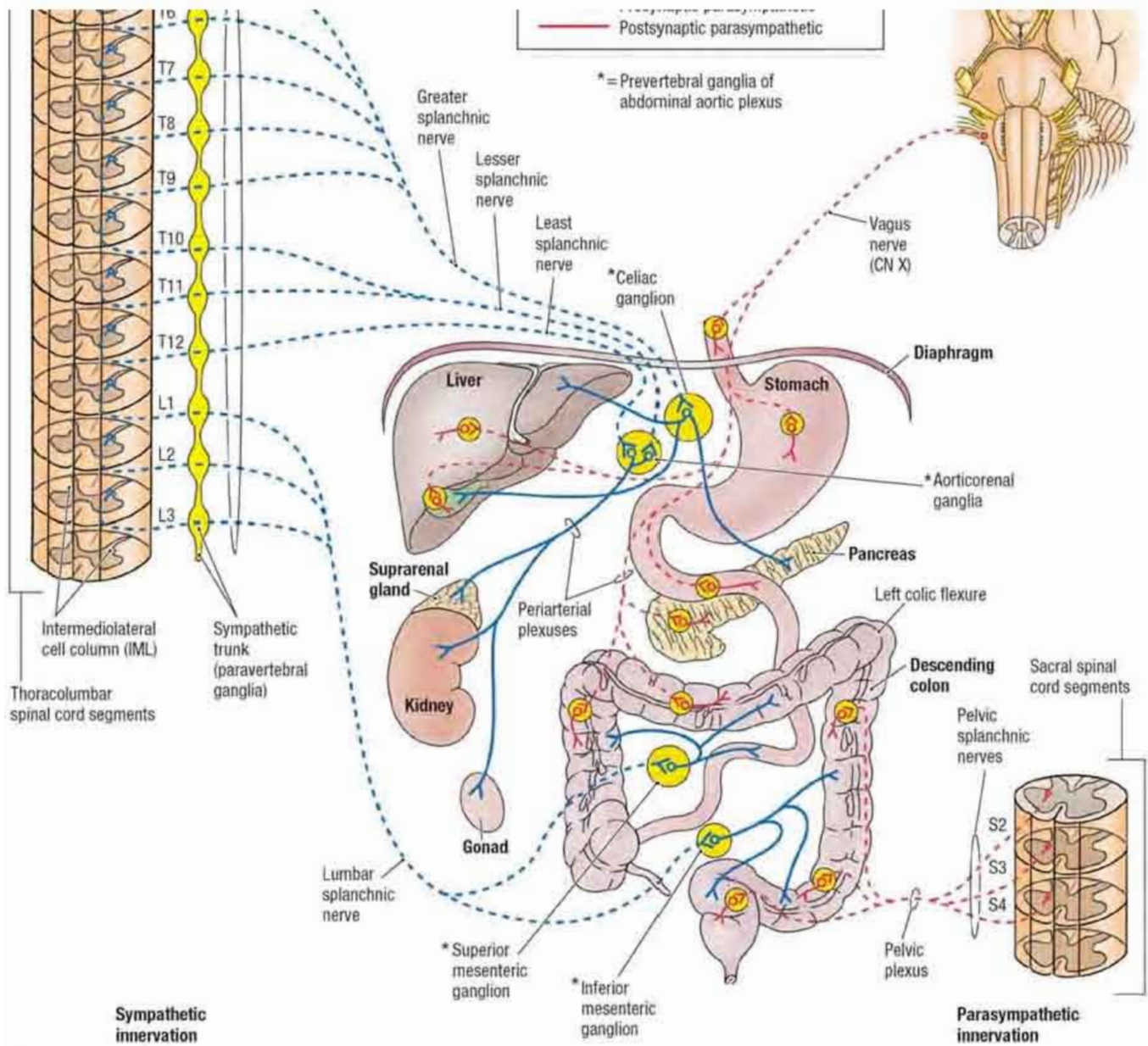
Intrinsic ganglia of descending and sigmoid colon, rectum, and pelvic viscera

• Splanchnic nerves also convey visceral afferent fibers, which are not part of the autonomic nervous system.

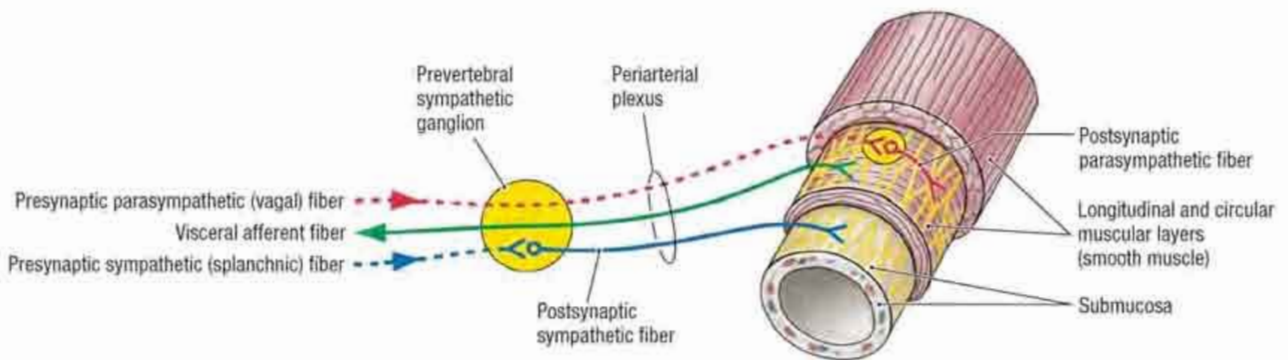
Splanchnic Nerves	Autonomic Fiber Type <sup>a</sup>	System	Origin	Destination
-------------------	-----------------------------------	--------	--------	-------------

Table 2.6 Autonomic Innervation of the Abdominal Viscera (Splanchnic Nerves)





A



B



Authors: Agur, Anne M.R.; Dalley, Arthur F.

Title: *Grant's Atlas of Anatomy, 12th Edition*

Copyright ©2009 Lippincott Williams & Wilkins

> Table of Contents > Chapter 2 - Abdomen > 2.79 Abdominal nerve plexuses and ganglia

---

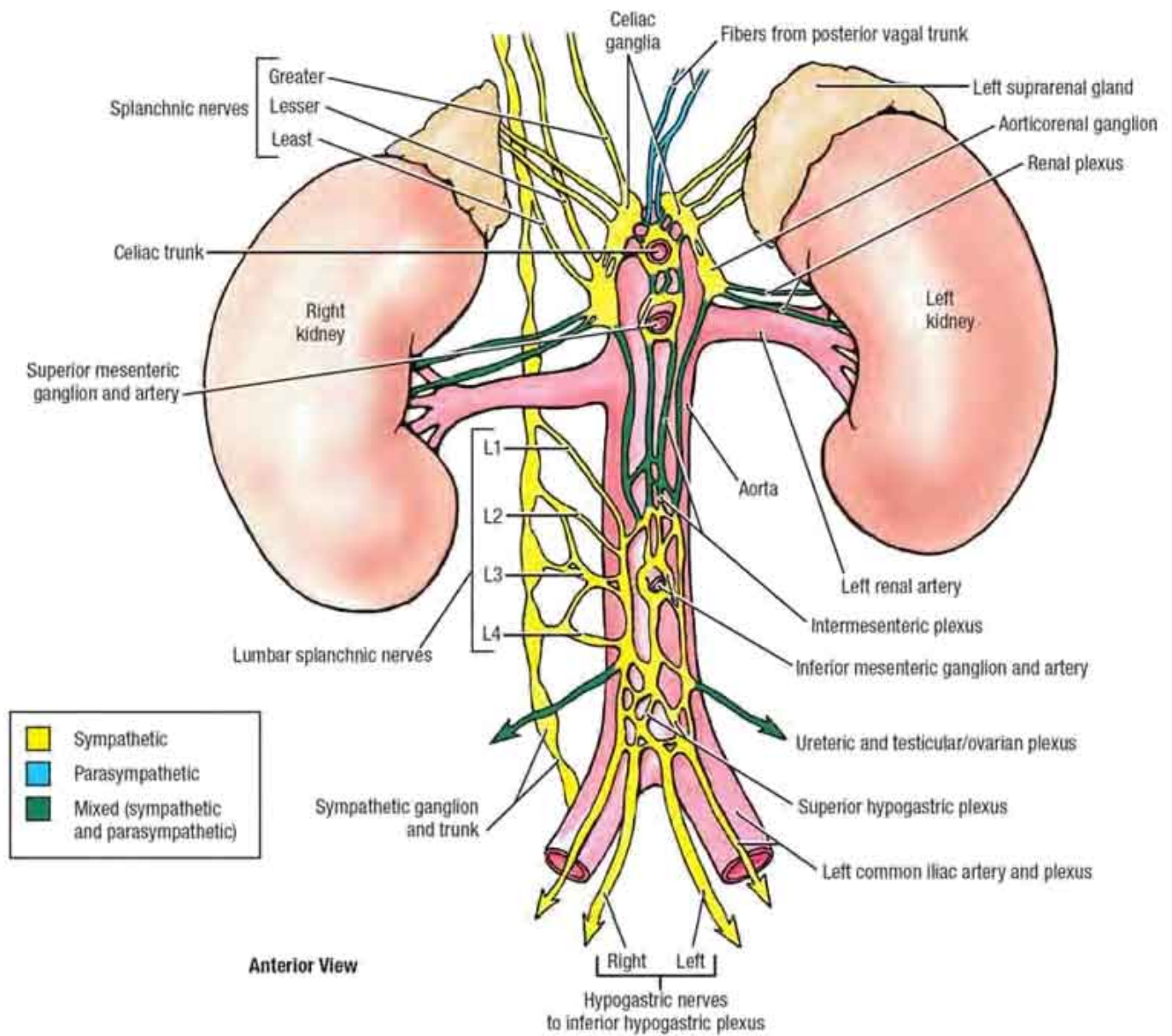
## 2.79 Abdominal nerve plexuses and ganglia

*Part of* "Chapter 2 - Abdomen "

---

P.180





Authors: Agur, Anne M.R.; Dalley, Arthur F.

Title: *Grant's Atlas of Anatomy, 12th Edition*

Copyright ©2009 Lippincott Williams & Wilkins

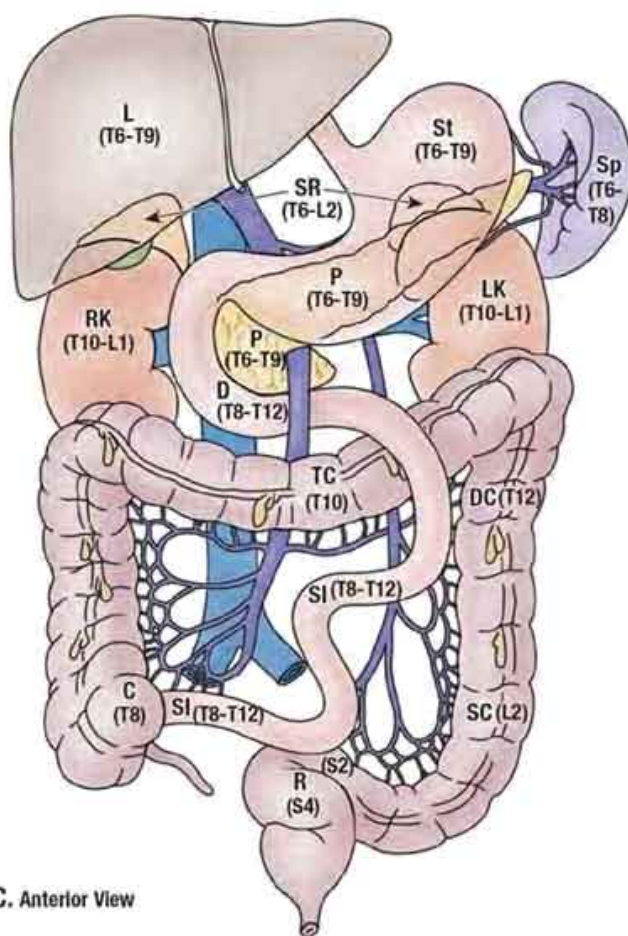
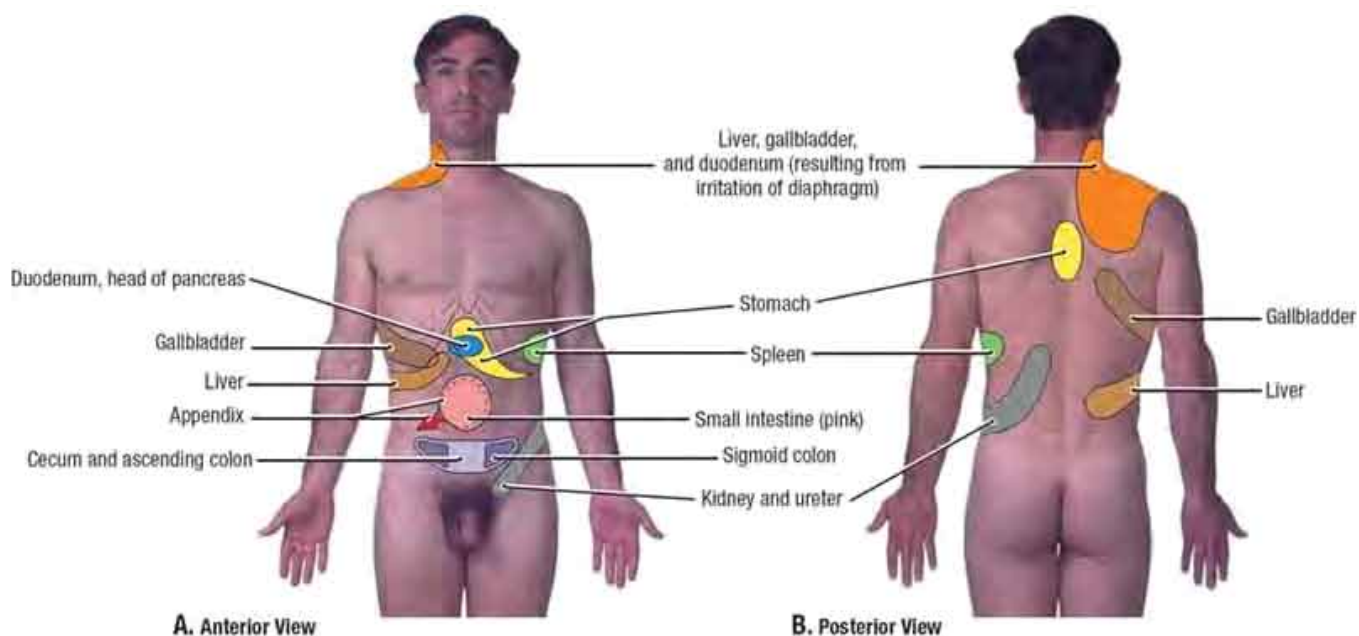
> Table of Contents > Chapter 2 - Abdomen > 2.80 Surface projections of visceral pain

---

## 2.80 Surface projections of visceral pain

*Part of "Chapter 2 - Abdomen "*

A. and B. Pain arising from a viscus (organ) varies from dull to severe but is poorly localized. It radiates to the part of the body supplied by somatic sensory fibers associated with the same spinal ganglion and segment of the spinal cord that receive visceral sensory (autonomic) fibers from the viscus concerned. The pain is interpreted by the brain as though the irritation occurred in the area of skin supplied by the posterior roots of the affected segments. This is called visceral referred pain. C. Approximate spinal cord segments and spinal sensory ganglia involved in sympathetic and visceral afferent (pain) innervation of abdominal viscera.



C	Cecum	RK	Right kidney
D	Duodenum	SC	Sigmoid colon
DC	Descending colon	SI	Small intestine
L	Liver	Sp	Spleen
LK	Left kidney	SR	Suprarenal glands
P	Pancreas	St	Stomach
R	Rectum	TC	Transverse colon

Authors: Agur, Anne M.R.; Dalley, Arthur F.

Title: *Grant's Atlas of Anatomy, 12th Edition*

Copyright ©2009 Lippincott Williams & Wilkins

> Table of Contents > Chapter 2 - Abdomen > 2.81 Vagus nerves in abdomen

---

## 2.81 Vagus nerves in abdomen

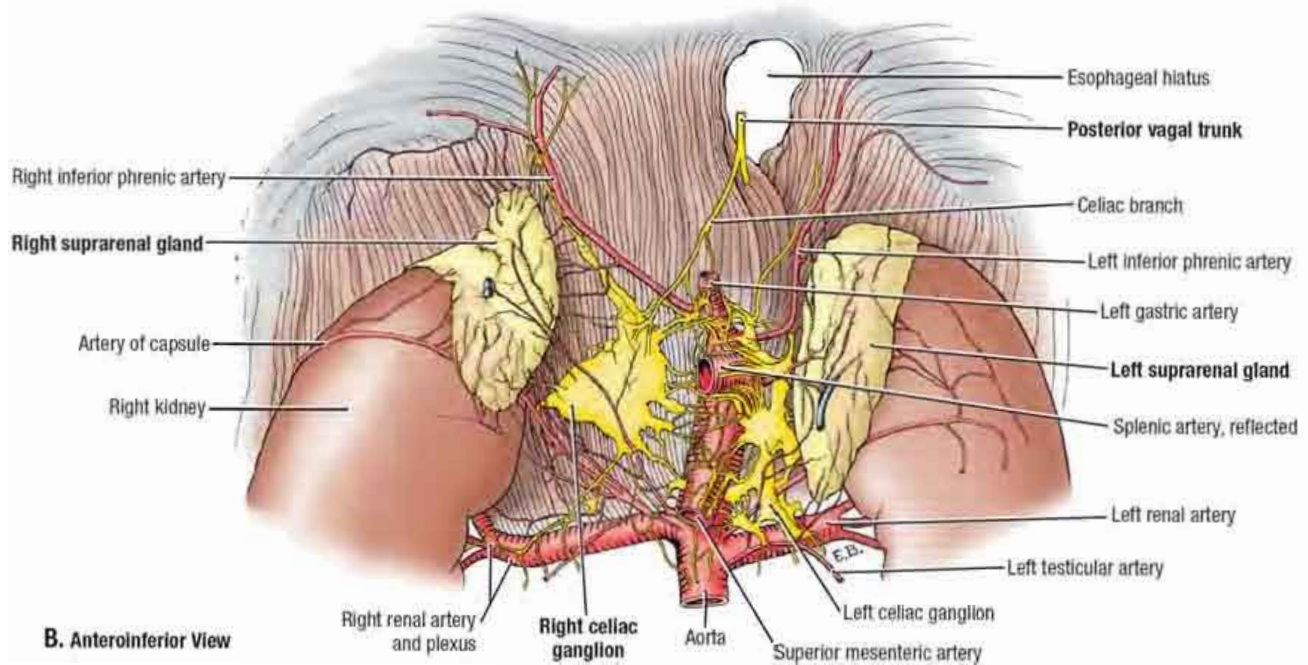
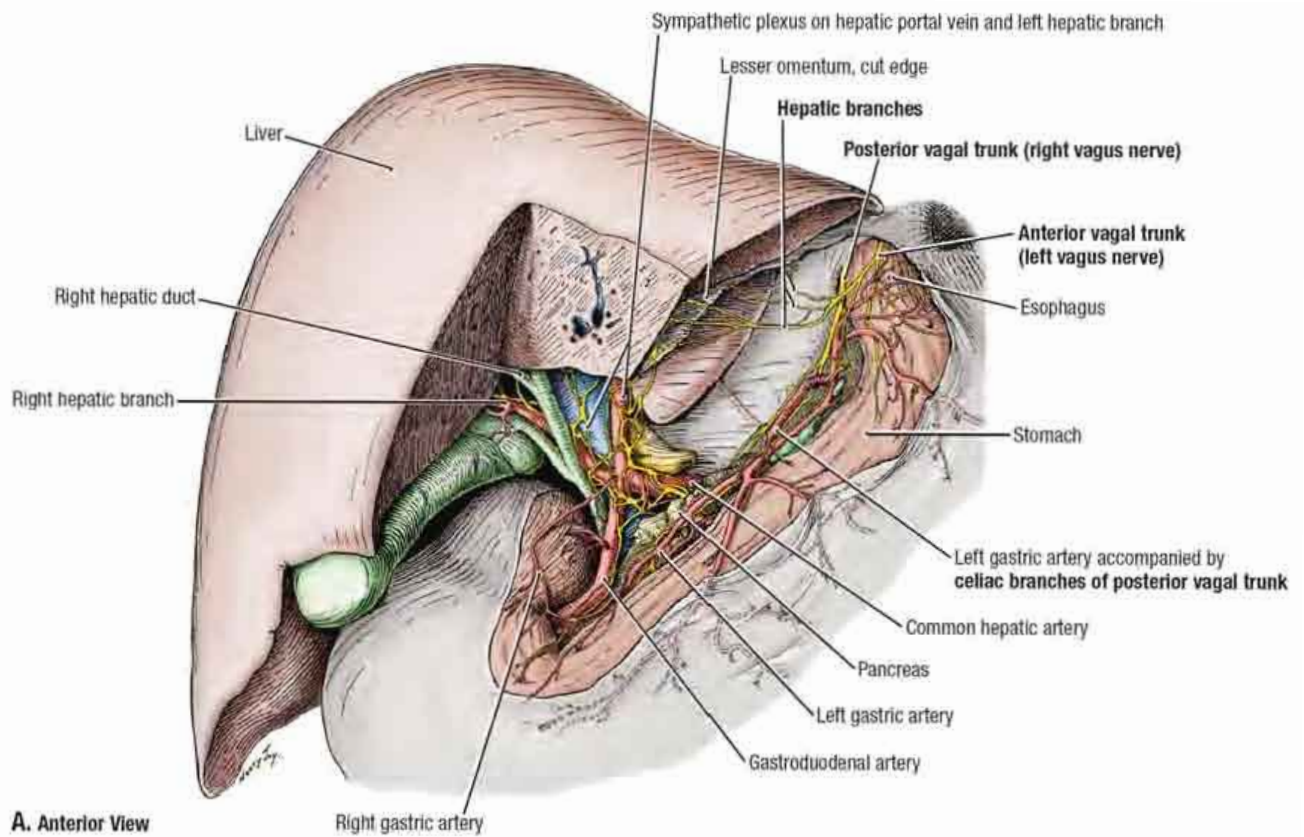
*Part of* "Chapter 2 - Abdomen "

A. Anterior and posterior vagal trunks. B. Celiac plexus and ganglia and suprarenal glands.

---

P.182







Authors: Agur, Anne M.R.; Dalley, Arthur F.

Title: *Grant's Atlas of Anatomy, 12th Edition*

Copyright ©2009 Lippincott Williams & Wilkins

> Table of Contents > Chapter 2 - Abdomen > 2.82 Lymphatic drainage of suprarenal glands, kidneys, and ureters

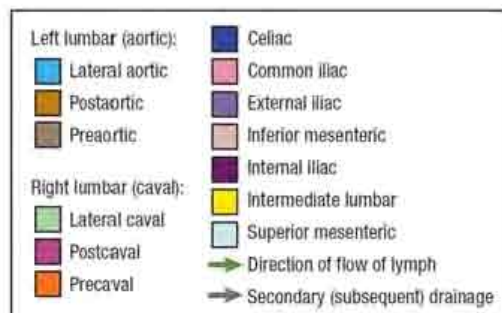

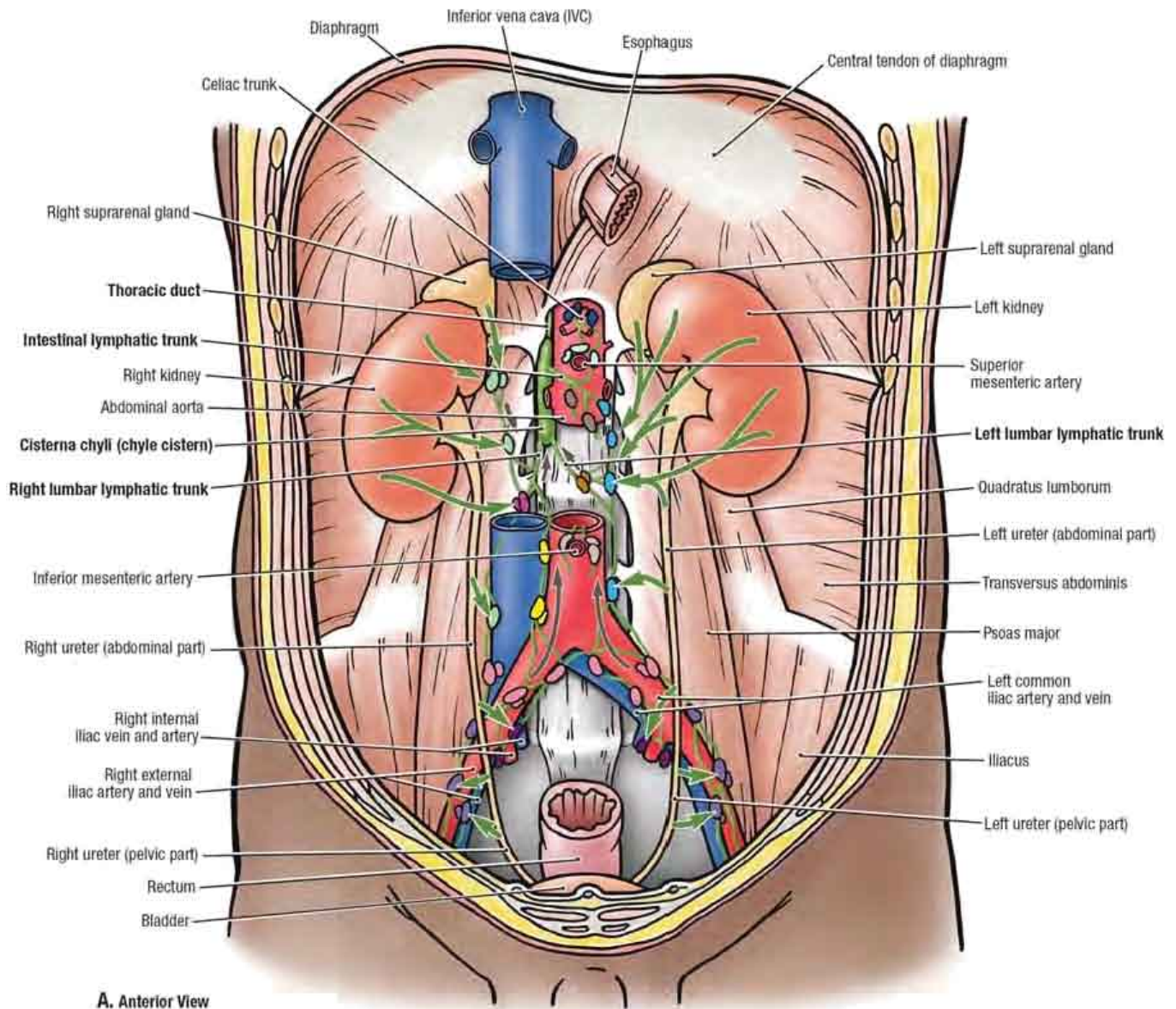
---

## 2.82 Lymphatic drainage of suprarenal glands, kidneys, and ureters

*Part of* "Chapter 2 - Abdomen "

---

P.183



Authors: Agur, Anne M.R.; Dalley, Arthur F.

Title: *Grant's Atlas of Anatomy, 12th Edition*

Copyright ©2009 Lippincott Williams & Wilkins

> Table of Contents > Chapter 2 - Abdomen > 2.83 Lumbar lymph nodes, sympathetic trunk, nerves, and ganglia

---

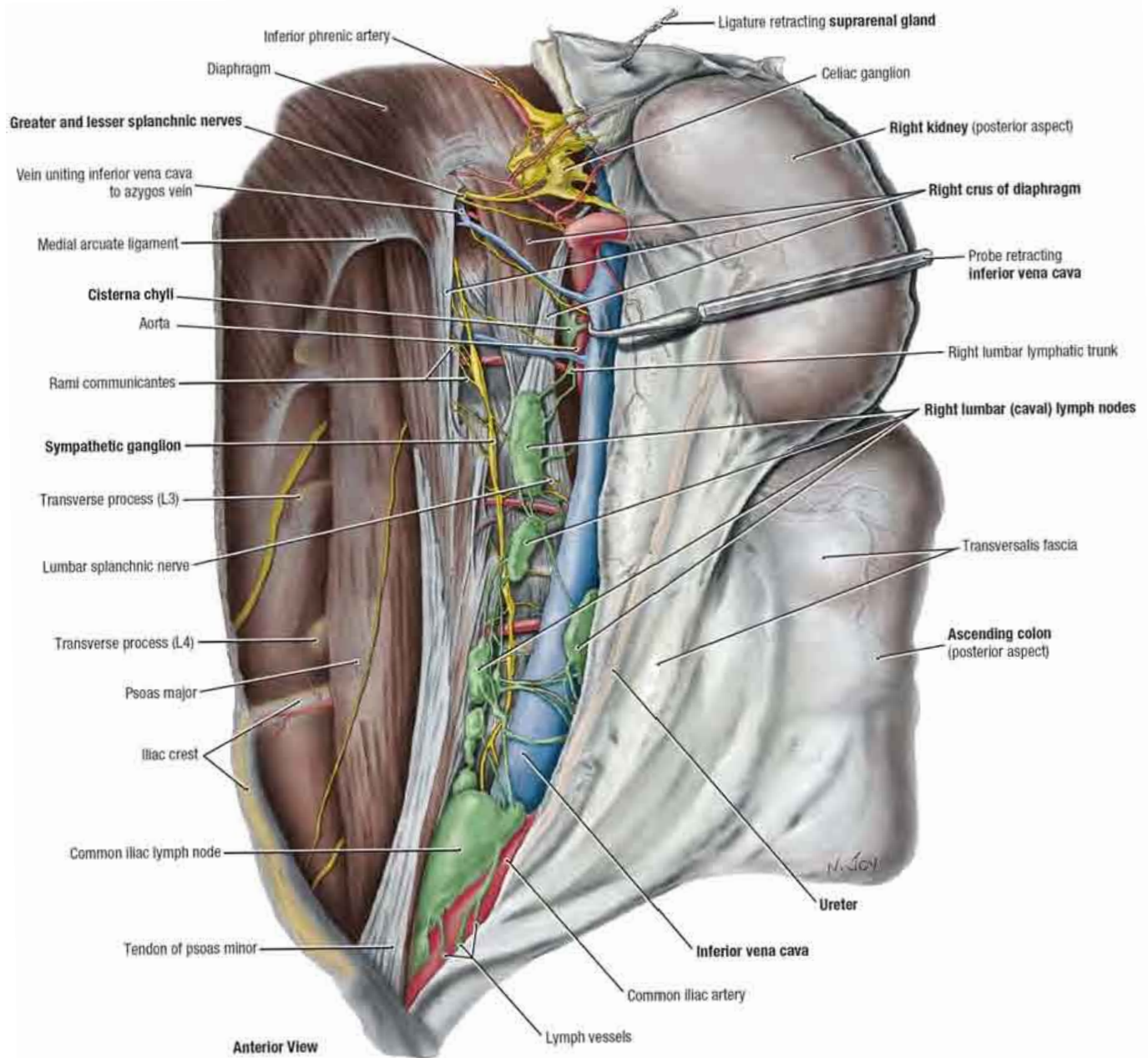
## 2.83 Lumbar lymph nodes, sympathetic trunk, nerves, and ganglia

*Part of* "Chapter 2 - Abdomen "

The right suprarenal gland, kidney, ureter, and colon are reflected to the left; the inferior vena cava is pulled medially, and the third and fourth lumbar veins are removed. In this specimen, the greater and lesser splanchnic nerves, the sympathetic trunk, and a communicating vein pass through an unusually wide cleft in the right crus. The splanchnic nerves convey preganglionic fibers arising from the cell bodies in the (thoracolumbar) sympathetic trunk. The greater splanchnic nerve is from thoracic ganglia 5 to 9, and the lesser from thoracic ganglia 10 to 11.

---

P.184



Authors: Agur, Anne M.R.; Dalley, Arthur F.

Title: *Grant's Atlas of Anatomy, 12th Edition*

Copyright ©2009 Lippincott Williams & Wilkins

> Table of Contents > Chapter 2 - Abdomen > 2.84 Lymphatic drainage

---

## 2.84 Lymphatic drainage

*Part of "Chapter 2 - Abdomen"*

A. Stomach and small intestine. B. Spleen and pancreas. C. Drainage from lumbar and intestinal lymphatic trunks. The *arrows* indicate the direction of lymph flow; each group of lymph nodes is color coded. Lymph from the abdominal nodes drains into the cisterna chyli, origin of the inferior end of the thoracic duct. The thoracic duct receives all lymph that forms inferior to the diaphragm and left upper quadrant (thorax and left upper limb) and empties into the junction of the left subclavian and left internal jugular veins.

---

P.185

D. Large intestine. E. Liver and gallbladder. F. Liver.



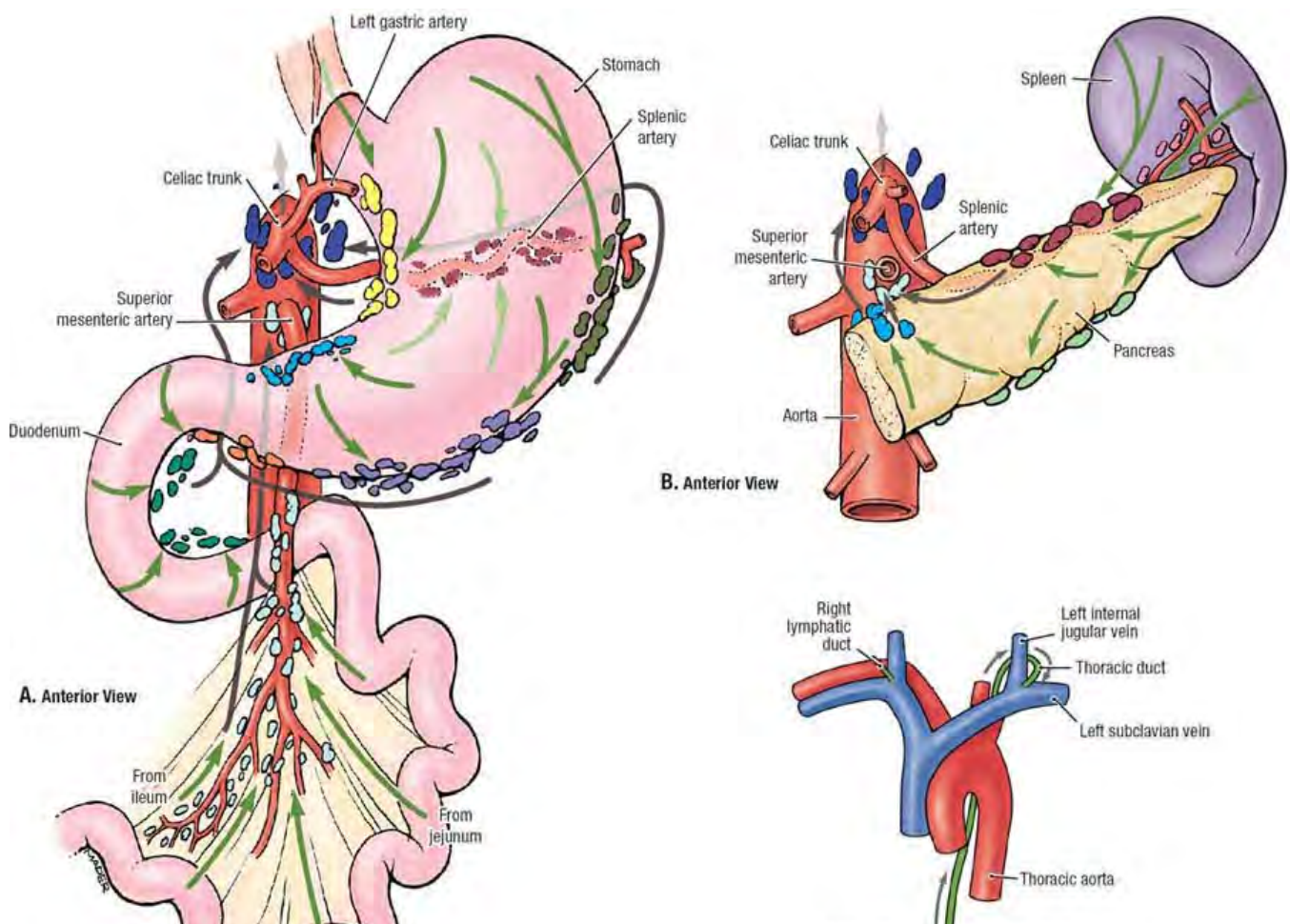
Authors: Agur, Anne M.R.; Dalley, Arthur F.  
Title: *Grant's Atlas of Anatomy, 12th Edition*  
Copyright ©2009 Lippincott Williams & Wilkins

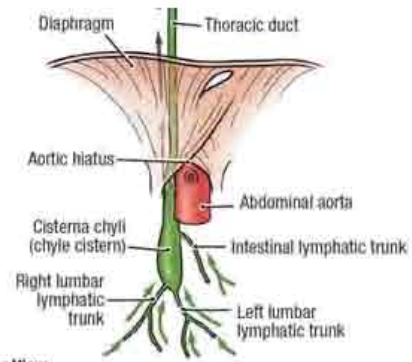
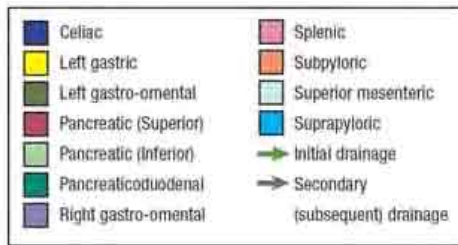
> Table of Contents > Chapter 2 - Abdomen > 2.85 Transverse or horizontal (axial) MRIs of the abdomen

## 2.85 Transverse or horizontal (axial) MRIs of the abdomen

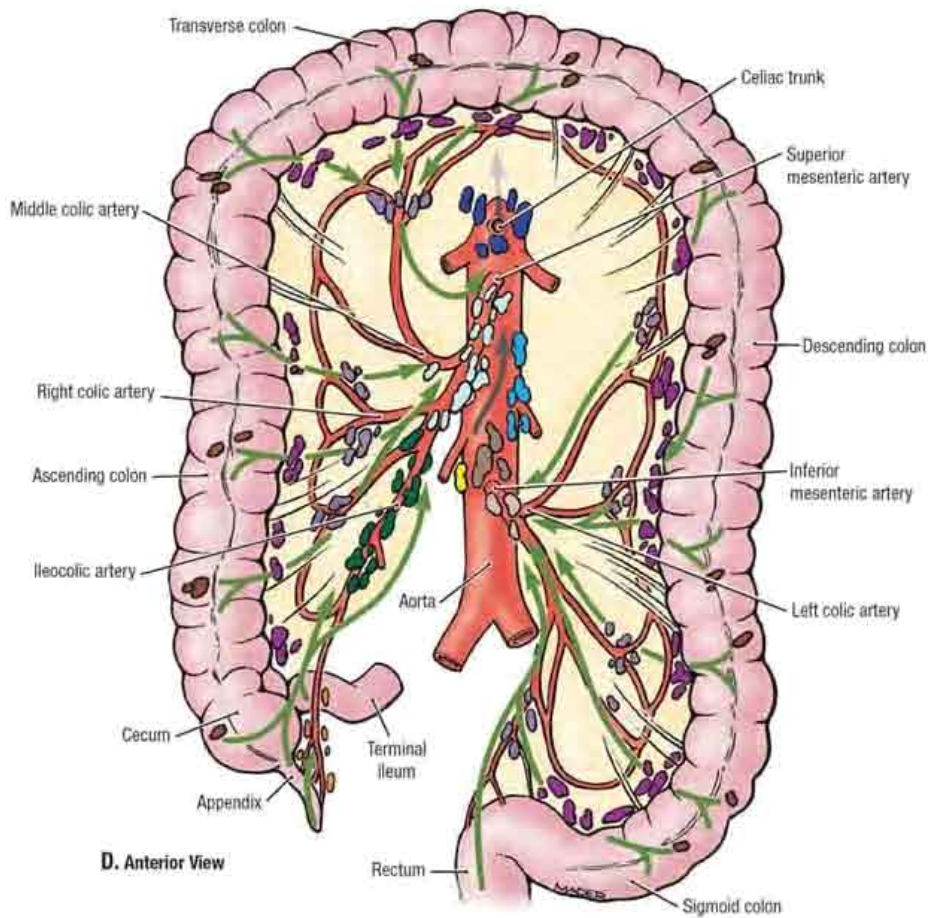
Part of "Chapter 2 - Abdomen "

P.186

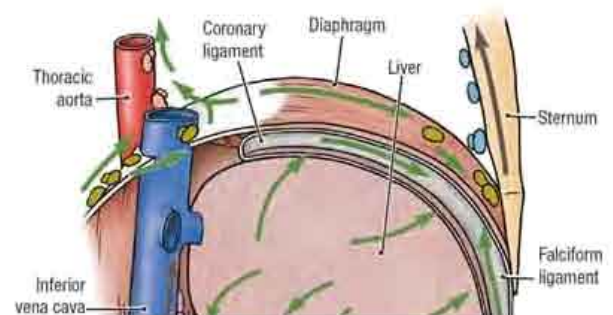
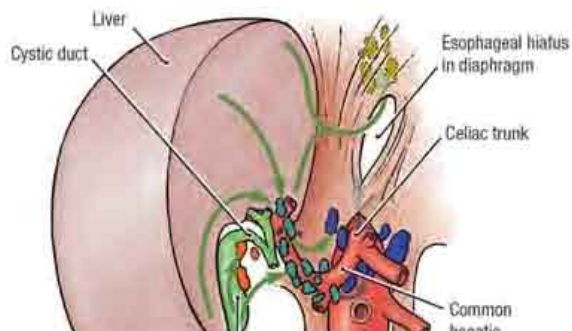
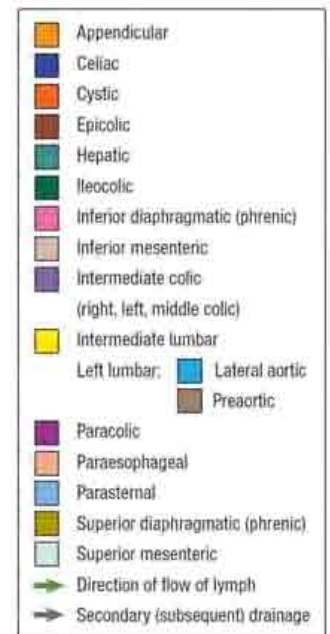


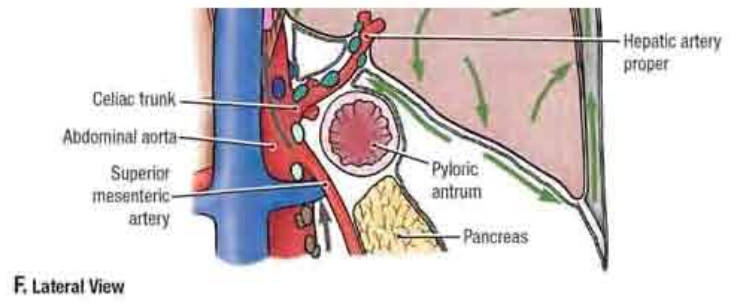
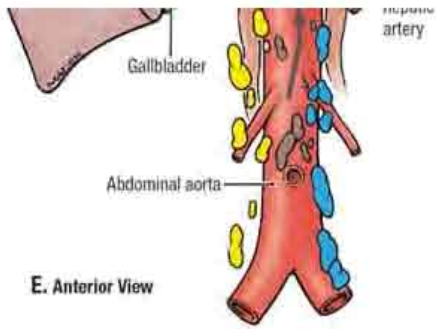


C. Anterior View



D. Anterior View







Authors: Agur, Anne M.R.; Dalley, Arthur F.  
 Title: *Grant's Atlas of Anatomy, 12th Edition*  
 Copyright ©2009 Lippincott Williams & Wilkins

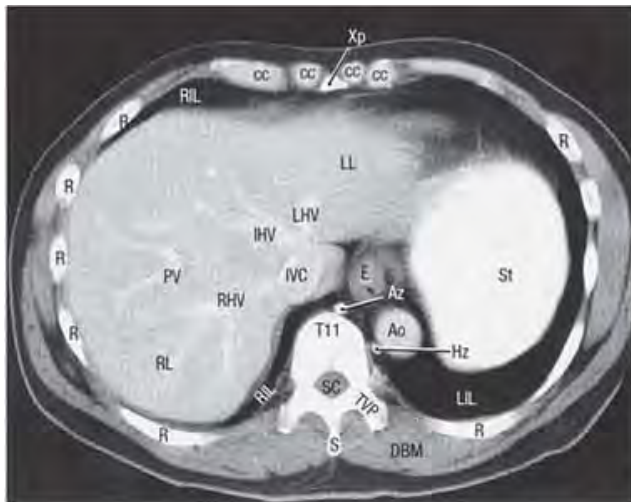
> Table of Contents > Chapter 2 - Abdomen > 2.86 Coronal MRIs of the abdomen

## 2.86 Coronal MRIs of the abdomen

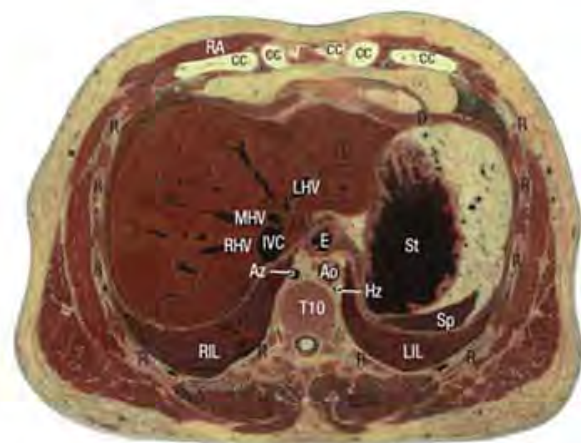
Part of "Chapter 2 - Abdomen "

P.187

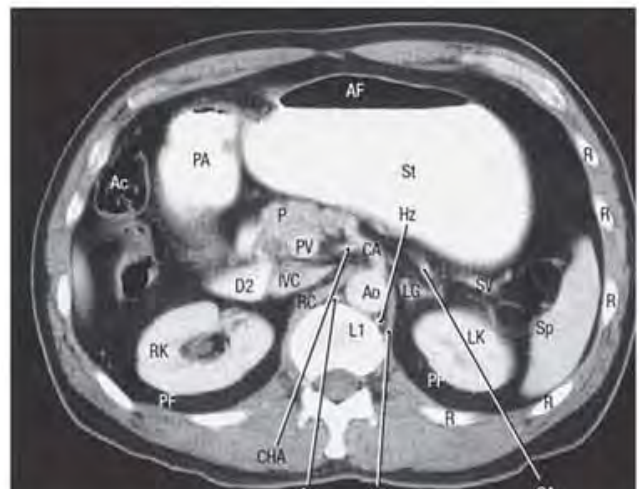
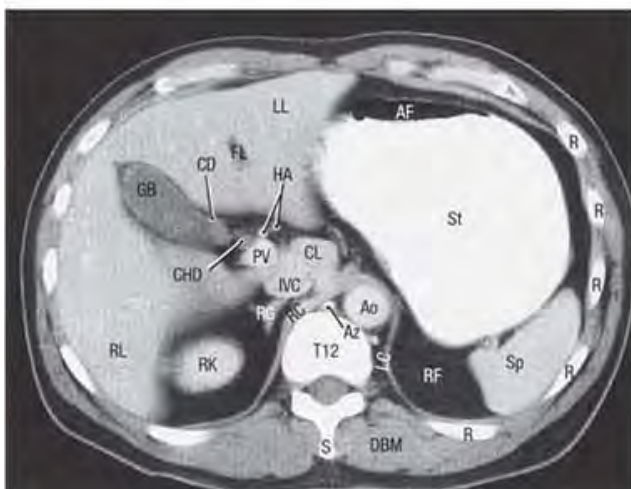
P.188



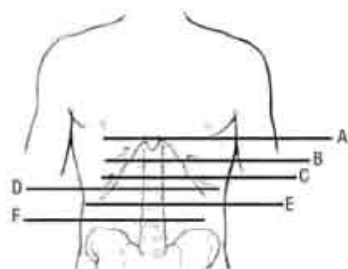
A



B



C

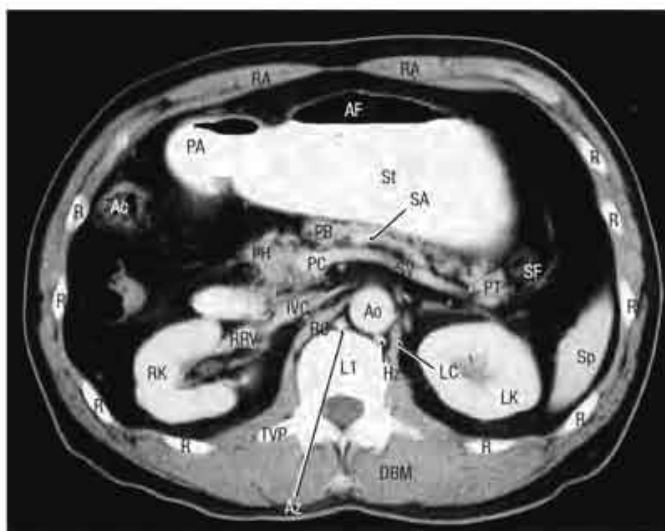


Ac Ascending colon  
AF Air-fluid level of stomach  
Ao Aorta  
Az Azygos vein  
CA Celiac artery  
cc Costal cartilage  
CD Cystic duct  
CHA Common hepatic artery  
CHD Common hepatic duct  
CL Caudate lobe of liver  
D Diaphragm

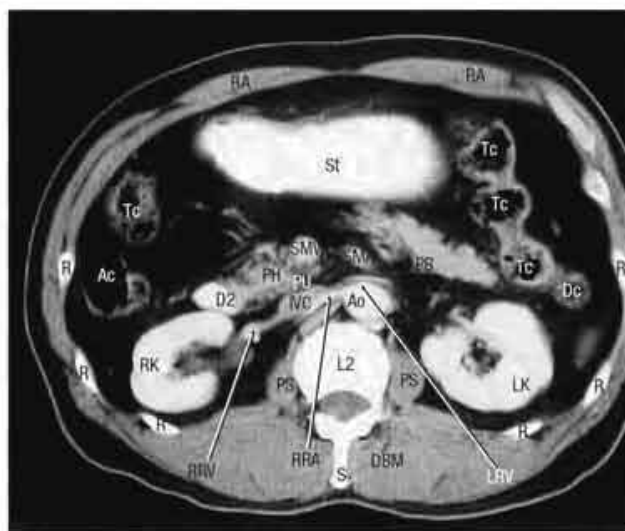
D

DBM Deep back muscles  
Dc Descending colon  
D2 Descending part of duodenum  
D3 Inferior part of duodenum  
E Esophagus  
FL Falciform ligament  
GB Gallbladder  
HA Hepatic artery  
Hz Hemiazygos vein  
IMV Inferior mesenteric vein  
IVC Inferior vena cava

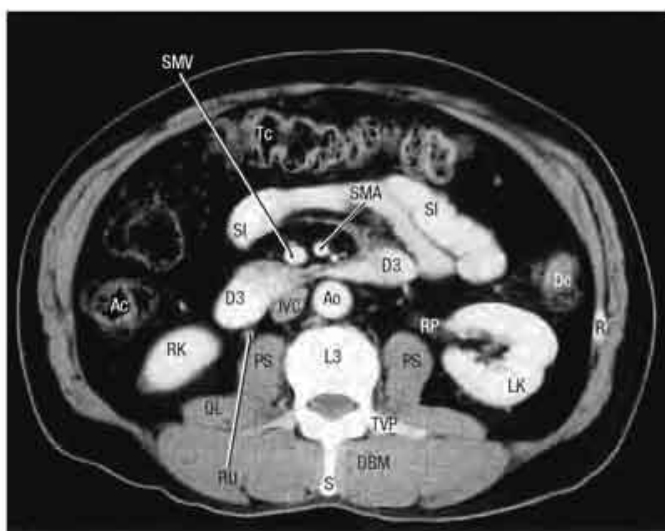LC Left crus of diaphragm  
LG Left suprarenal gland  
LHV Left hepatic vein  
LIL Left inferior lobe of lung  
LK Left kidney  
LL Left lobe of liver  
LRV Left renal vein  
LU Left ureter  
IHV Intermediate hepatic vein  
P Pancreas  
PA Pyloric antrum of stomach



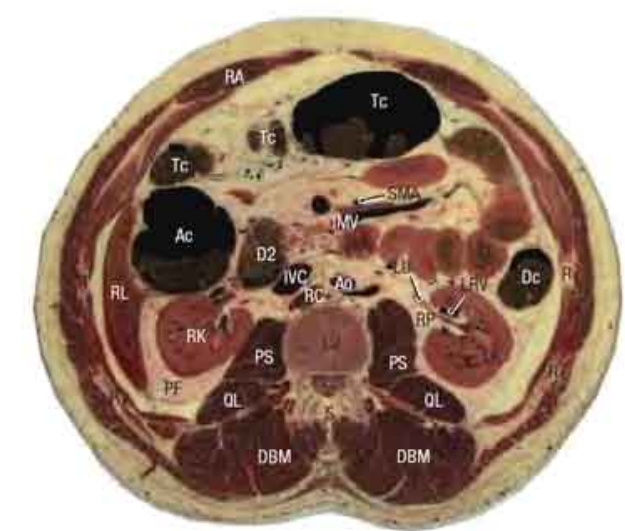
E



F



G



H



PB	Body of pancreas	R	Rib	RP	Renal pelvis	SMA	Superior mesenteric artery
PC	Portal confluence	RA	Rectus abdominis	RRA	Right renal artery	SMV	Superior mesenteric vein
PF	Perinephric fat	RC	Right crus of diaphragm	RRV	Right renal vein	Sp	Spleen
PH	Head of pancreas	RF	Retropitoneal fat	RU	Right ureter	St	Stomach
PS	Psoas muscle	RG	Right suprarenal gland	S	Spinous process	SV	Splenic vein
PT	Tail of pancreas	RHV	Right hepatic vein	SA	Splenic artery	Tc	Transverse colon
PU	Uncinate process of pancreas	RIL	Right inferior lobe of lung	SC	Spinal cord	TVP	Transverse process
PV	Hepatic portal vein	RK	Right kidney	SF	Splenic flexure	Xp	Xiphoid process
QL	Quadratus lumborum	RL	Right lobe of liver	SI	Small intestine		

Authors: Agur, Anne M.R.; Dalley, Arthur F.

Title: *Grant's Atlas of Anatomy, 12th Edition*

Copyright ©2009 Lippincott Williams & Wilkins

> Table of Contents > Chapter 2 - Abdomen > 2.87 Sagittal MRIs of the abdomen

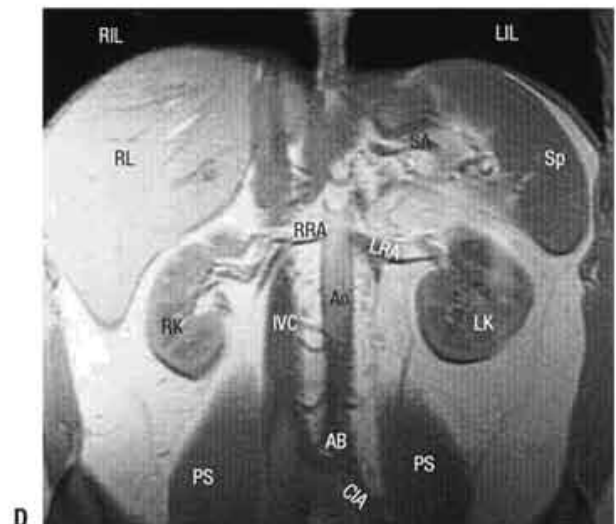
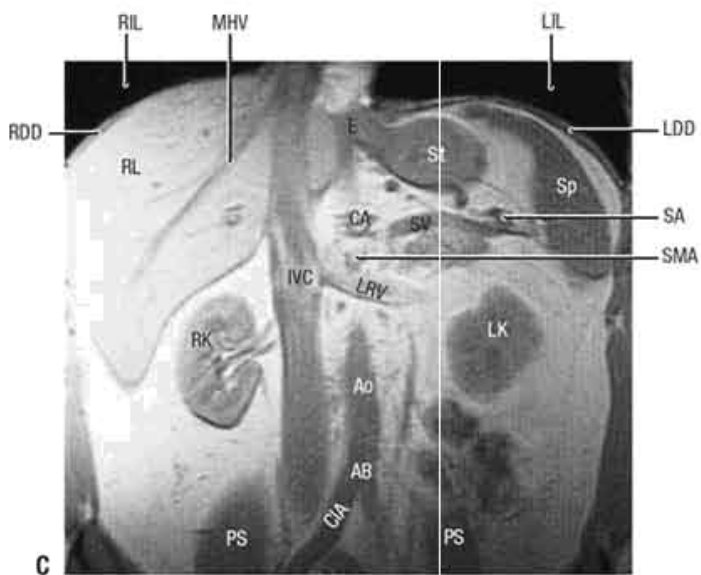
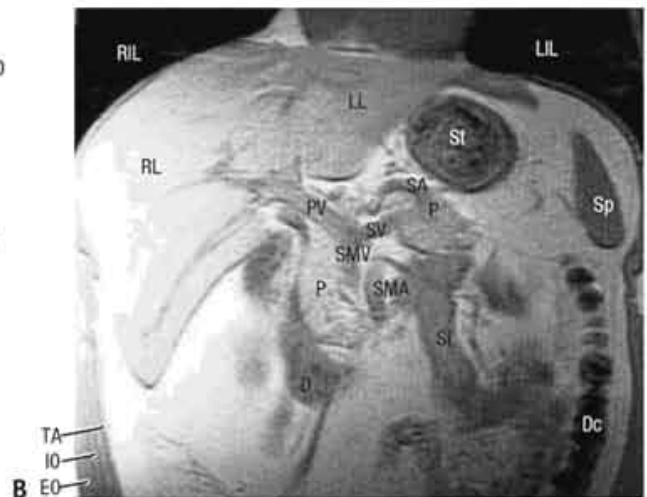
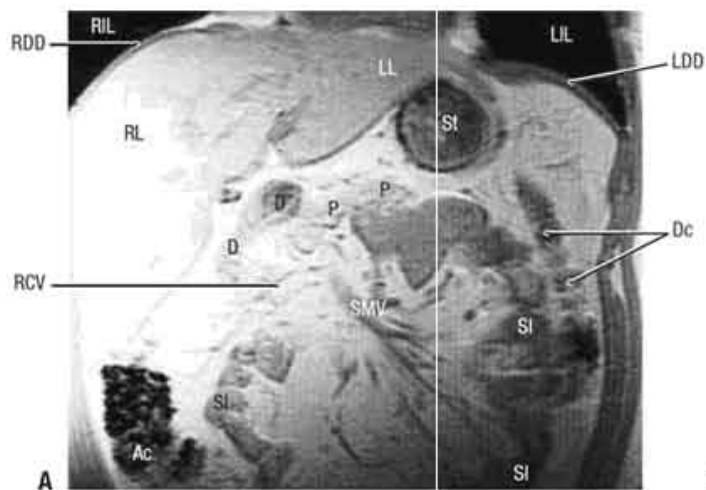
---

## 2.87 Sagittal MRIs of the abdomen

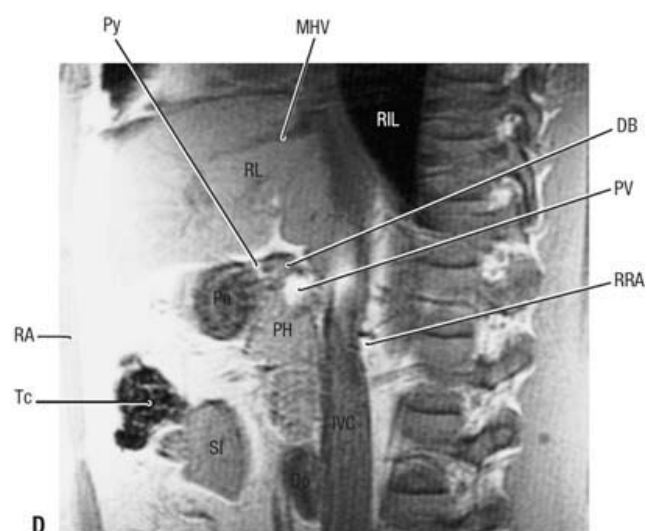
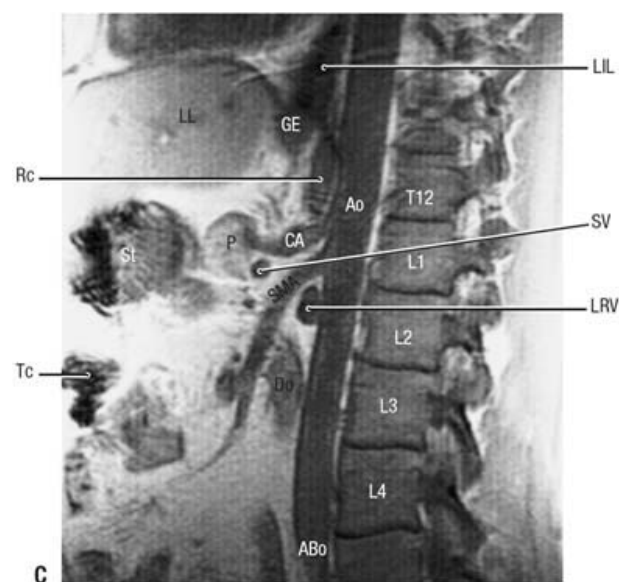
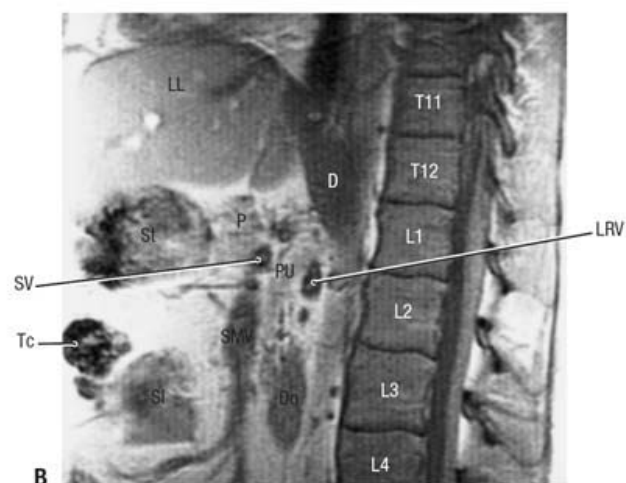
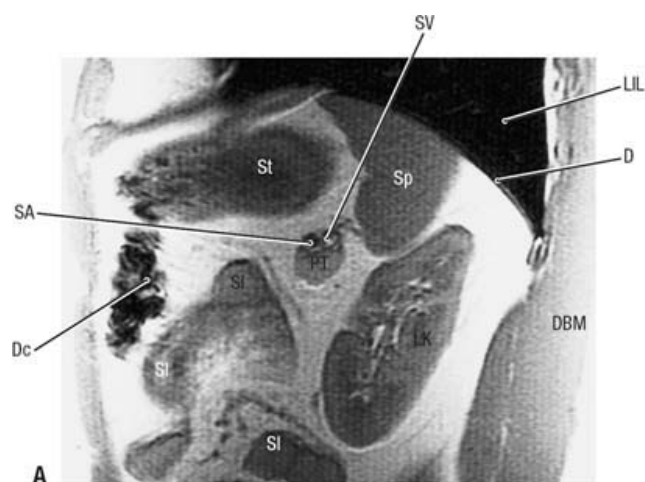
*Part of* "Chapter 2 - Abdomen "

---

P.189



AB	Aortic bifurcation	LIL	Left lung (inferior lobe)	RK	Right kidney
Ac	Ascending colon	LK	Left kidney	RL	Right lobe of liver
Ao	Aorta	LL	Left lobe of liver	RRA	Right renal artery
CA	Celiac artery	LRA	Left renal artery	SA	Splenic artery
CIA	Common iliac artery	LRV	Left renal vein	SI	Small intestine
D	Duodenum	MHV	Middle hepatic vein	SMA	Superior mesenteric artery
Dc	Descending colon	P	Pancreas	SMV	Superior mesenteric vein
E	Esophagus	PV	Portal vein	Sp	Spleen
EO	External oblique	PS	Psoas	St	Stomach
IO	Internal oblique	RCV	Right colic vein	SV	Splenic vein
IVC	Inferior vena cava	RDD	Right dome of diaphragm	TA	Transversus abdominis
LDD	Left dome of diaphragm	RIL	Right lung (inferior lobe)		



Ao	Aorta	LL	Left lobe of liver	RC	Right crus
ABo	Bifurcation of aorta	LRV	Left renal vein	RIL	Inferior lobe of right lung
CA	Celiac artery	MHV	Middle hepatic vein	RL	Right lobe of right liver
D	Diaphragm	P	Pancreas	RRA	Right renal artery
DB	Bulb of duodenum	Pa	Pyloric antrum	SA	Splenic artery
Dc	Descending colon	PC	Portal confluence	SI	Small intestine
Do	Duodenum	PH	Head of pancreas	SMA	Superior mesenteric artery
DBM	Deep back muscles	PT	Tail of pancreas	SMV	Superior mesenteric vein
GE	Gastroesophageal junction	PV	Portal vein	Sp	Spleen
IVC	Inferior vena cava	PU	Uncinate process of pancreas	St	Stomach
LIL	Inferior lobe of left lung	Py	Pylorus of stomach	SV	Splenic vein
LK	Left kidney	RA	Rectus abdominus	Tc	Transverse colon

Authors: Agur, Anne M.R.; Dalley, Arthur F.

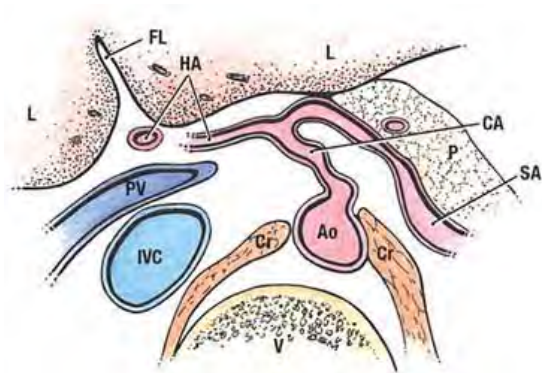
Title: *Grant's Atlas of Anatomy, 12th Edition*

Copyright ©2009 Lippincott Williams & Wilkins

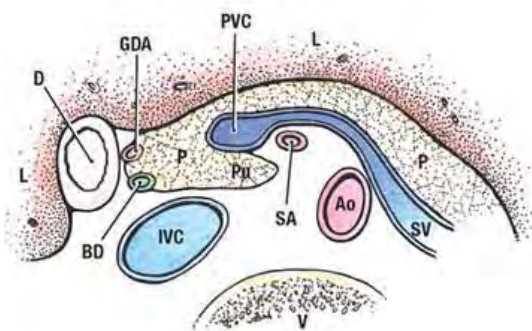
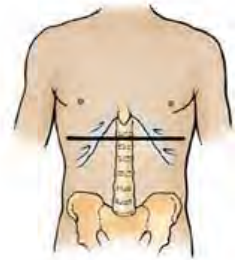
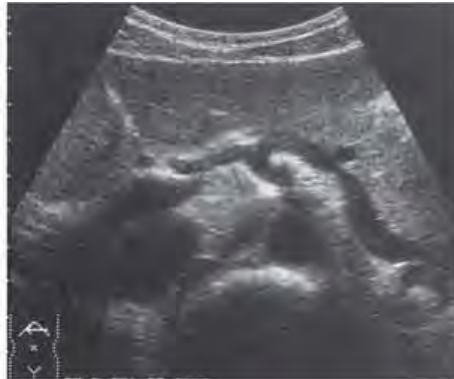> Table of Contents > Chapter 2 - Abdomen > 2.88 Ultrasound scans and MR angiogram of the abdomen

## 2.88 Ultrasound scans and MR angiogram of the abdomen


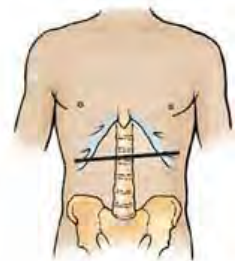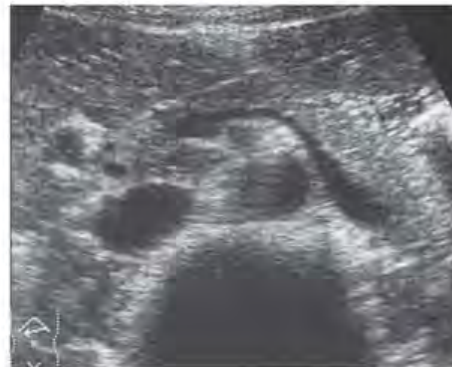
Part of "Chapter 2 - Abdomen "



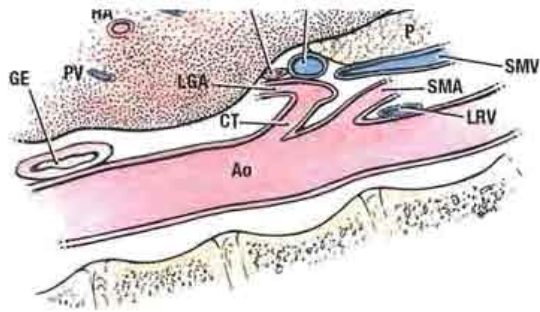
A. Transverse Section, Inferior View



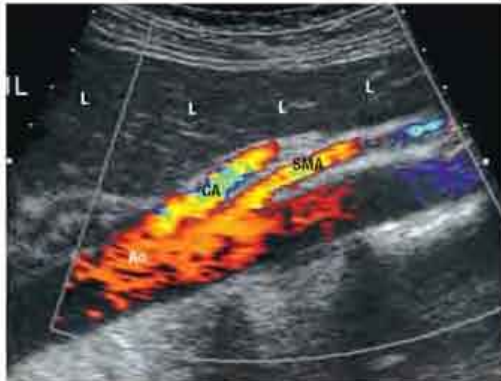
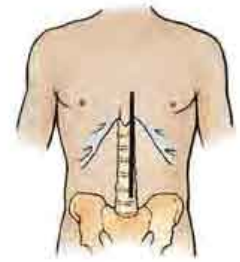
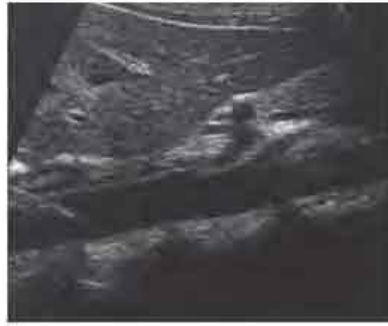B. Transverse Section, Inferior View



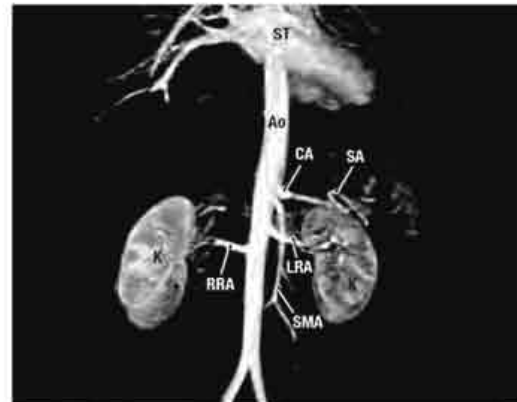




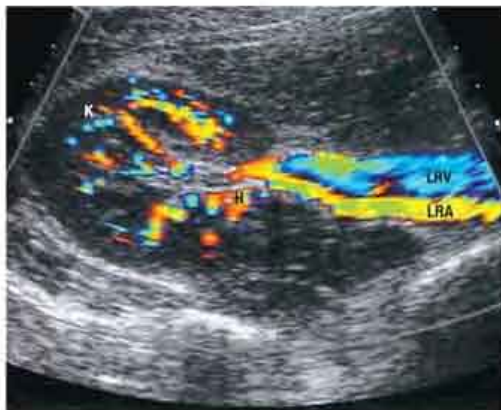C. Median Section, Right Lateral View



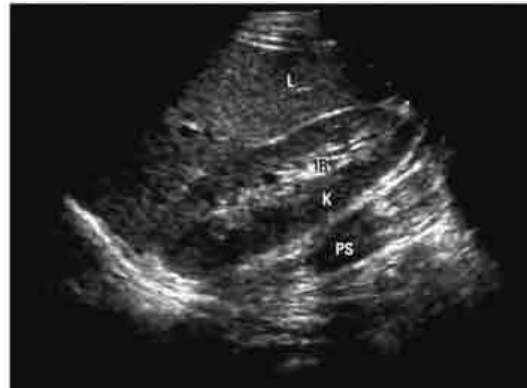
D. Median Section, Right Lateral View



E. Anterior View



F. Transverse Section



G. Sagittal Section, Right Lateral View

A major advantage of ultrasonography is its ability to produce real-time images, demonstrating motion of structures and flow within blood vessels. In Doppler ultrasonography (D and F) the shifts in frequency between emitted ultrasonic waves and their echoes are

used to measure the velocities of moving objects. This technique is based on the principle of the Doppler effect. Blood flow through vessels is displayed in color, superimposed on the two-dimensional cross-sectional image. (slow flow: blue; fast flow: orange)

Ao	Aorta	IR	Intrahepatic fat	PV	Portal vein
BD	Bile duct	IVC	Inferior vena cava	PVC	Portal venous confluence
CA	Celiac artery	K	Cortex of kidney	RRA	Right renal artery
Cr	Crus of diaphragm	L	Liver	SA	Splenic artery
D	Duodenum	LGA	Left gastric artery	SMA	Superior mesenteric artery
FL	Falciform ligament	LRA	Left renal artery	SMV	Superior mesenteric vein
GDA	Gastroduodenal artery	LRV	Left renal vein	ST	Stomach
GE	Gastroesophageal junction	P	Pancreas	SV	Splenic vein
H	Hilum of kidney	PS	Psoas	V	Vertebra
HA	Hepatic artery	Pu	Uncinate process of pancreas		

A. Transverse ultrasound scan through celiac trunk. B. Transverse ultrasound scan through pancreas. C and D. Sagittal ultrasound scans through the aorta, celiac trunk, and superior mesenteric artery. (D. With Doppler.) E. MR angiogram of abdominal aorta and branches. F. Transverse ultrasound scan at hilum of left kidney with the left renal artery and vein (with Doppler). G. Sagittal ultrasound scan of the right kidney.

Authors: Agur, Anne M.R.; Dalley, Arthur F.

Title: *Grant's Atlas of Anatomy, 12th Edition*

Copyright ©2009 Lippincott Williams & Wilkins

> Table of Contents > Chapter 3 - Pelvis and Perineum > Chapter 3 - Pelvis and Perineum

---

# Chapter 3

## Pelvis and Perineum

---

P.194

- 3.1 Surface anatomy of the male pelvic girdle
- 3.2 Surface anatomy of the female pelvic girdle
- 3.3 Bones and divisions of pelvis
- 3.4 Pelvis, anatomical position
- 3.5 Male pelvic girdle
- 3.6 Female pelvic girdle
- 3.7 Pelvis and pelvic ligaments
- 3.8 Obturator internus and piriformis
- 3.9 Muscles of the pelvic diaphragm
- 3.10 Floor and walls of male pelvis, pelvic diaphragm
- 3.11 Floor and walls of female pelvis
- 3.12 Sacral and coccygeal nerve plexuses
- 3.13 Right half of hemisected female pelvis
- 3.14 Right half of hemisected male pelvis
- 3.15 Anal sphincters and anal canal

- 3.16 Rectum, anal canal, and neurovascular structures of the posterior pelvis
- 3.17 Vasculature of rectum
- 3.18 Innervation of rectum and anal canal
- 3.19 Rectum in situ
- 3.20 Male pelvic organs and external genitalia
- 3.21 Urinary bladder, prostate, and ductus deferens
- 3.22 Posterior approach to anterior pelvic and perineal structures and spaces
- 3.23 Seminal glands and prostate
- 3.24 Interior of male urinary bladder and prostatic urethra
- 3.25 Male pelvis, transverse sections
- 3.26 Transrectal ultrasound scans of male pelvis
- 3.27 Arteries and veins of male pelvis
- 3.28 Pelvic vessels in situ; lateral pelvic wall
- 3.29 Portal–systemic anastomoses
- 3.30 Lymphatic drainage of male pelvis and perineum
- 3.31 Innervation of male pelvis and perineum
- 3.32 Female pelvic organs in situ
- 3.33 Female genital organs
- 3.34 Uterus and its adnexa
- 3.35 Uterus and broad ligament
- 3.36 Pregnant uterus
- 3.37 Ureter and relationship to uterine artery
- 3.38 Arterial supply of female pelvis and perineum

- 3.39 Arteries and veins of female pelvis
- 3.40 Lymphatic drainage of female pelvis and perineum
- 3.41 Innervation of female pelvic viscera
- 3.42 Innervation of pelvic viscera during pregnancy; nerve blocks
- 3.43 Serial dissection of autonomic nerves of female pelvis
- 3.44 Transverse section through female pelvis
- 3.45 Pelvic fascia and supporting mechanism of cervix and upper vagina
- 3.46 Surface anatomy of male perineum
- 3.47 Surface anatomy of the female perineum
- 3.48 Male and female perineal compartments
- 3.49 Perineal fascia and perineal compartments
- 3.50 Supporting and compressor/sphincteric muscles of pelvis
- 3.51 Dissection of male perineumâ€™ I
- 3.52 Dissection of the male perineumâ€™ II
- 3.53 Dissection of the male perineumâ€™ III
- 3.54 Glans, prepuce, and neurovascular bundle of penis
- 3.55 Layers and nerves of penis
- 3.56 Male urogenital system, erectile bodies
- 3.57 Cross sections of penis
- 3.58 Urethra
- 3.59 Female perineumâ€™ I
- 3.60 Innervation of the female perineum
- 3.61 Female perineumâ€™ II
- 3.62 Female perineumâ€™ III



- 3.63 Female perineumâ€”IV
- 3.64 Female perineumâ€”V
- 3.65 Female perineumâ€”V
- 3.66 Transverse (axial) MRIs and sectional specimen of the male pelvis and perineum, inferior views
- 3.67 Pelvic angiography
- 3.68 Coronal MRIs of the male pelvis and perineum, anterior views
- 3.69 Median MRIs of the male and female pelvis and perineum
- 3.70 Transverse (axial) MRIs and sectional specimens of the female pelvis and perineum, inferior views
- 3.71 Coronal MRIs of the female pelvis and perineum, anterior views
- 3.72 Ultrasound scans of female pelvis
- 3.73 Radiograph of uterus and uterine tubes (hysterosalpingogram)

Authors: Agur, Anne M.R.; Dalley, Arthur F.

Title: *Grant's Atlas of Anatomy, 12th Edition*

Copyright ©2009 Lippincott Williams & Wilkins

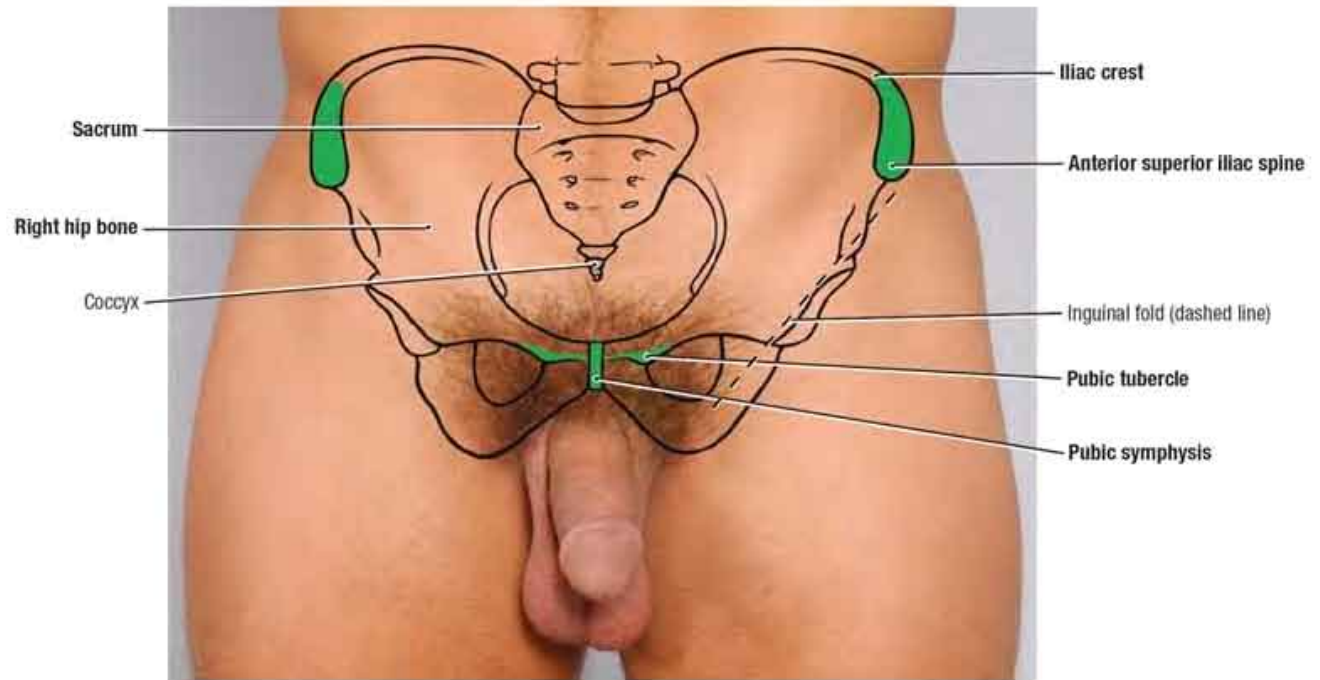
> Table of Contents > Chapter 3 - Pelvis and Perineum > 3.1 Surface anatomy of the male pelvic girdle

---

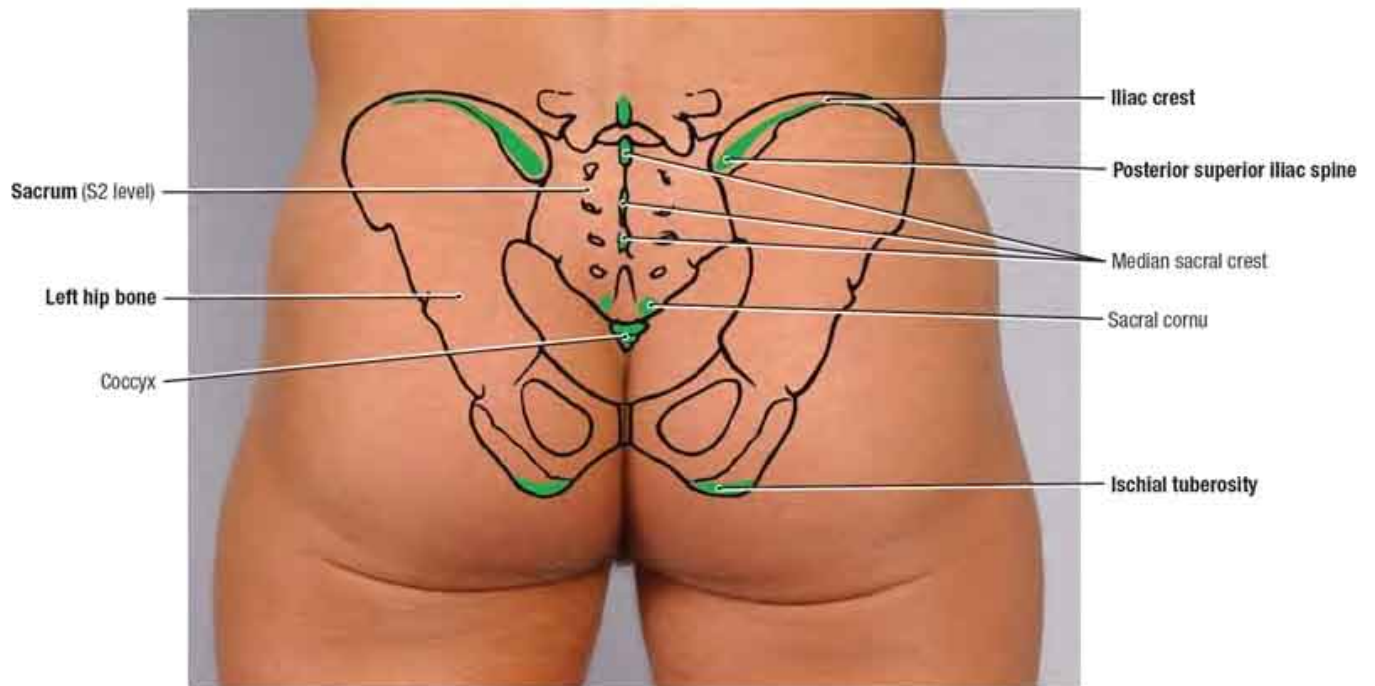
## 3.1 Surface anatomy of the male pelvic girdle

*Part of "Chapter 3 - Pelvis and Perineum "*

The pelvic girdle (bony pelvis) is a basin-shaped ring of three bones (right and left hip bones and sacrum) that connects the vertebral column to the femora. Palpable features *(green)* should be symmetrical across the midline. A. The anterior third of the iliac crests are subcutaneous and usually easily palpable. The remainder of the crests may also be palpable, depending on the thickness of the overlying subcutaneous tissue (fat). The inguinal ligament spans between the palpable anterior superior iliac spine (ASIS) and pubic tubercle, located superior to the lateral and medial ends of the inguinal fold. B. The posterior superior iliac spine is usually palpable and often lies deep to a visible dimple, indicating the S-2 vertebral level. The ischial tuberosities may be palpated when the thigh is flexed at the hip joint.



**A. Anterior View**



**B. Posterior View**

Authors: Agur, Anne M.R.; Dalley, Arthur F.

Title: *Grant's Atlas of Anatomy, 12th Edition*

Copyright ©2009 Lippincott Williams & Wilkins

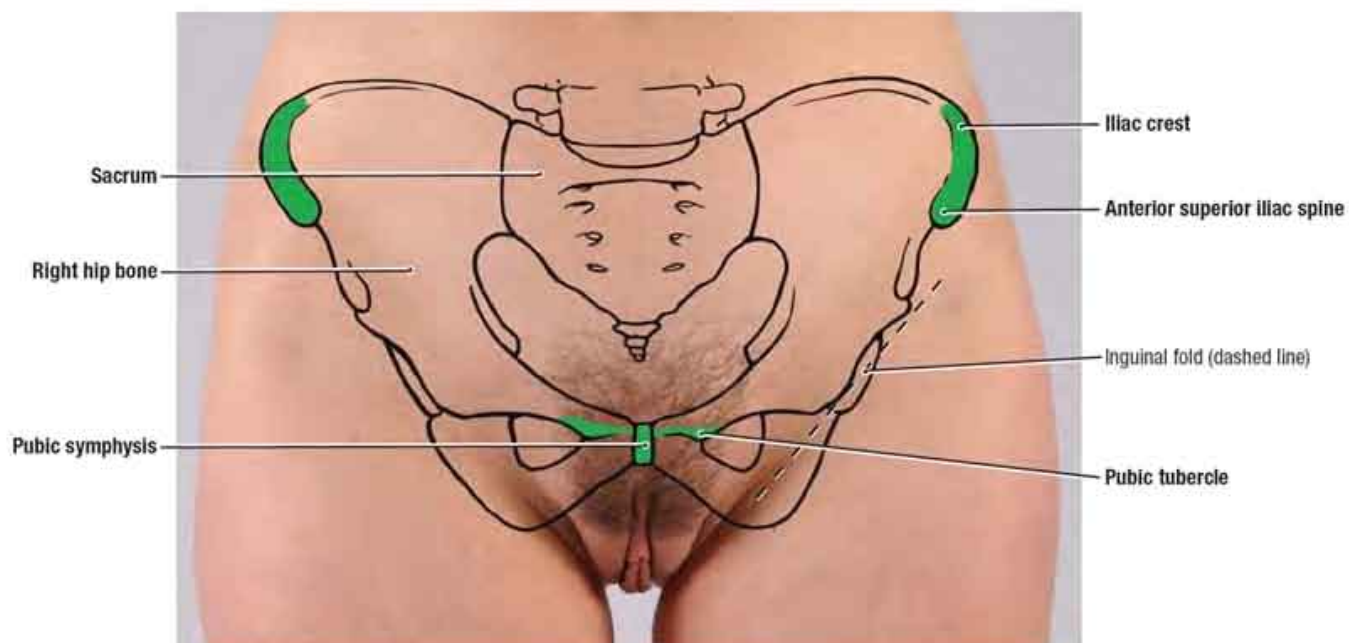
> Table of Contents > Chapter 3 - Pelvis and Perineum > 3.2 Surface anatomy of the female pelvic girdle

---

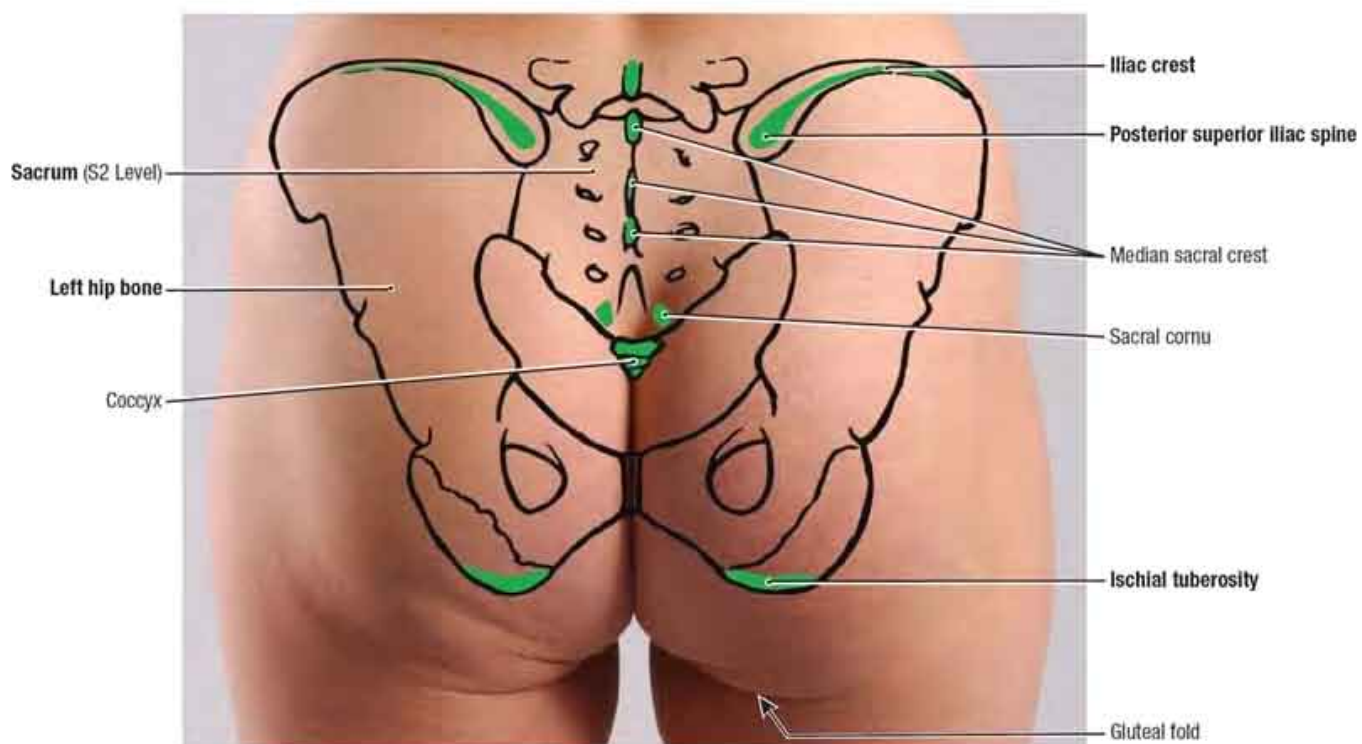
## 3.2 Surface anatomy of the female pelvic girdle

*Part of* "Chapter 3 - Pelvis and Perineum "

The female pelvic girdle is relatively wider and shallower than that of the male, related to its additional roles of bearing the weight of the gravid uterus in late pregnancy, and allowing passage of the fetus through the pelvic outlet during childbirth (parturition). (*Green*: palpable features) A. The hip bones are joined anteriorly at the pubic symphysis. The presence of a thick overlying pubic fat-pad forming the mons pubis may interfere with palpation of the pubic tubercles and symphysis. B. Posteriorly the hip bones are joined to the sacrum at the sacroiliac joints.



**A. Anterior View**



**B. Posterior View**



Authors: Agur, Anne M.R.; Dalley, Arthur F.

Title: *Grant's Atlas of Anatomy, 12th Edition*

Copyright ©2009 Lippincott Williams & Wilkins

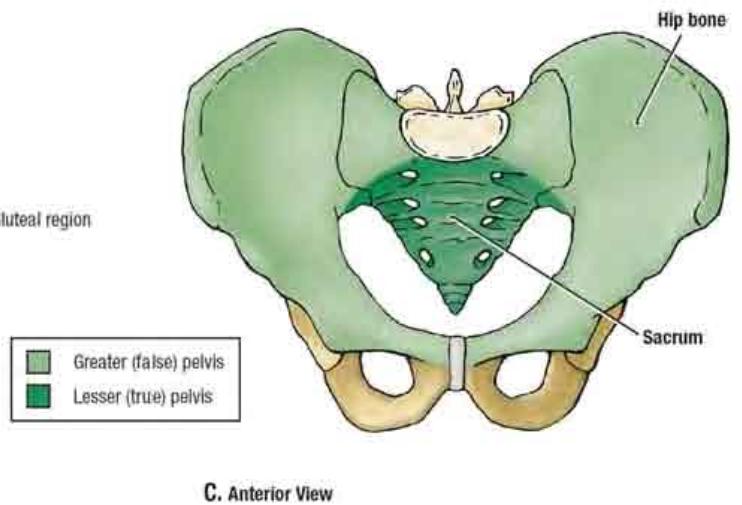
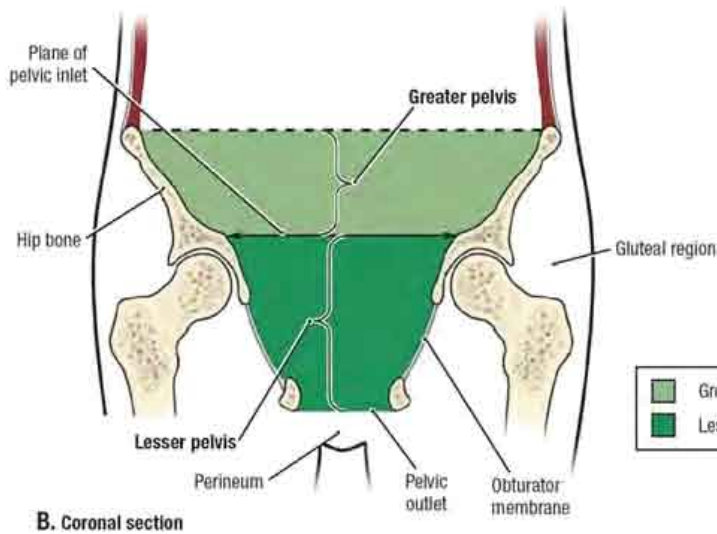
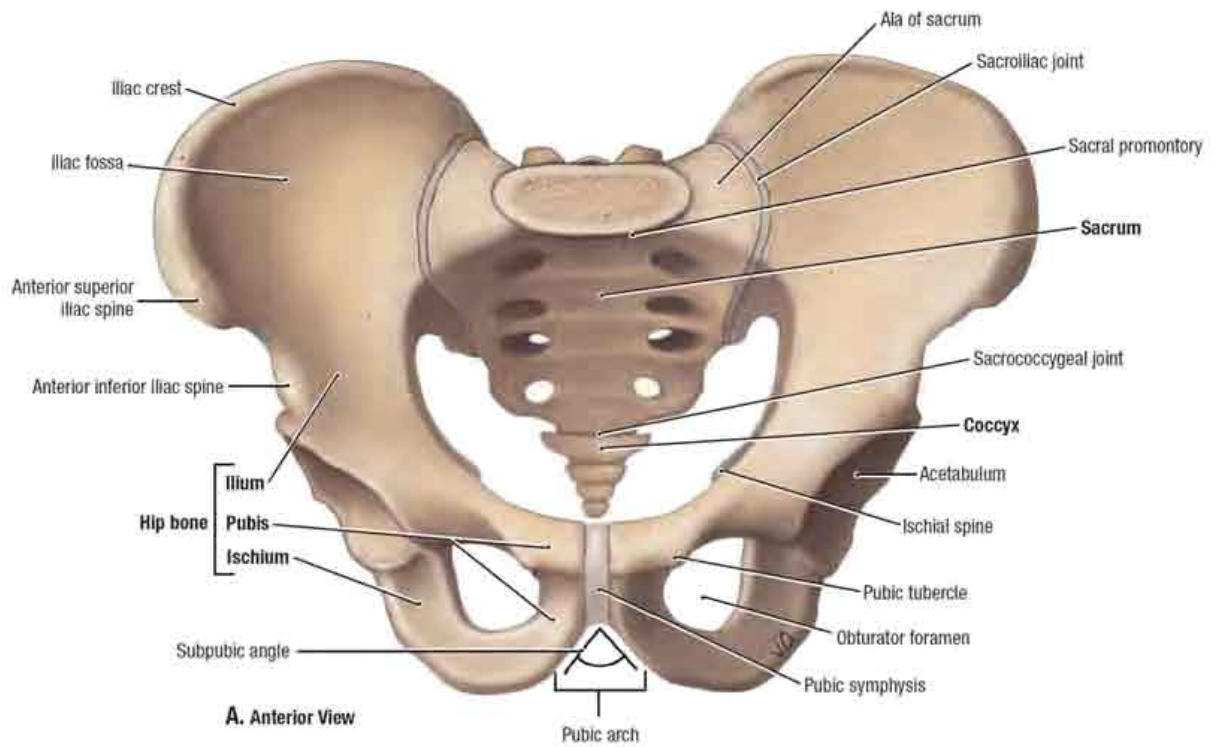
> Table of Contents > Chapter 3 - Pelvis and Perineum > 3.3 Bones and divisions of pelvis

---

## 3.3 Bones and divisions of pelvis

*Part of* "Chapter 3 - Pelvis and Perineum "

A. Bones of pelvis. The three bones composing the pelvis are the pubis, ischium, and ilium. B and C . Lesser and greater pelvis, schematic illustrations. The plane of the pelvic inlet (*double-headed arrow* in B ) separates the greater pelvis (part of the abdominal cavity) from the lesser pelvis (pelvic cavity).



Authors: Agur, Anne M.R.; Dalley, Arthur F.

Title: *Grant's Atlas of Anatomy, 12th Edition*

Copyright ©2009 Lippincott Williams & Wilkins

> Table of Contents > Chapter 3 - Pelvis and Perineum > 3.4 Pelvis, anatomical position

---

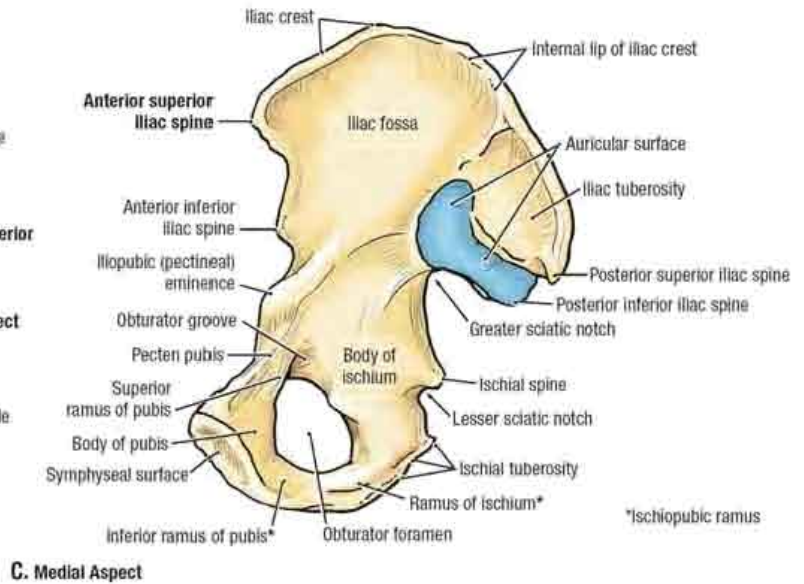
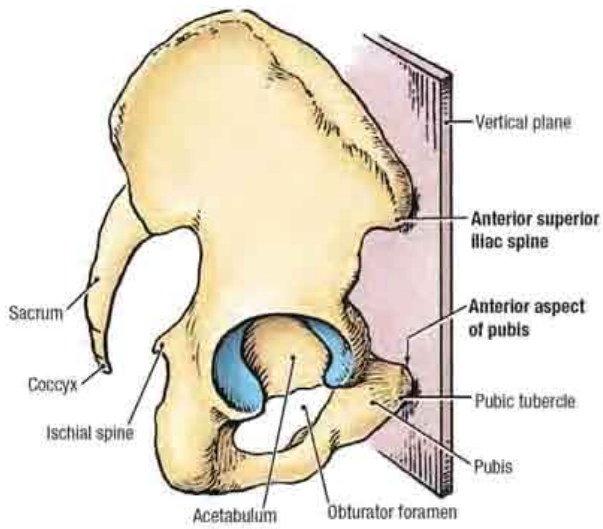
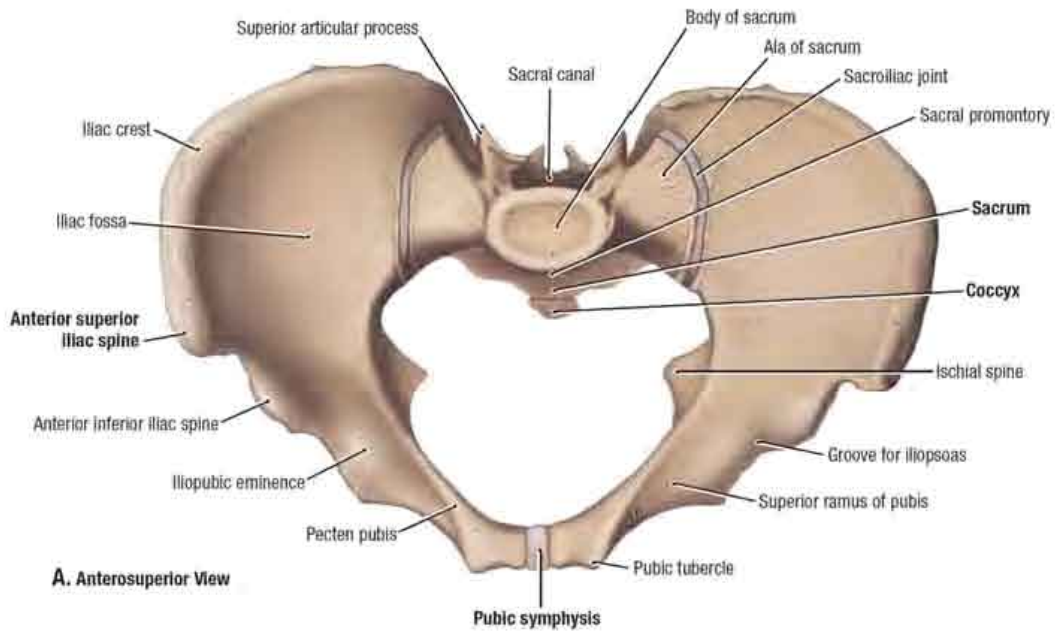
## 3.4 Pelvis, anatomical position

*Part of* "Chapter 3 - Pelvis and Perineum "

A. Pelvic girdle. B. Placement of hip bone in anatomical position. In the anatomical position: (1) the anterior superior iliac spine and the anterior aspect of the pubis lie in the same vertical plane; (2) the sacrum is located superiorly, the coccyx posteriorly and the pubic symphysis anteroinferiorly. C. Features of hip bone.

---

P.198



\*Ischiopubic ramus

**Authors:** Agur, Anne M.R.; Dalley, Arthur F.

**Title:** *Grant's Atlas of Anatomy, 12th Edition*

Copyright ©2009 Lippincott Williams & Wilkins

> Table of Contents > Chapter 3 - Pelvis and Perineum > 3.5 Male pelvic girdle

---

## 3.5 Male pelvic girdle

*Part of* "Chapter 3 - Pelvis and Perineum "

General structure

Thick and heavy

Thin and light

Greater pelvis (pelvis major)

Deep

Shallow

Lesser pelvis (pelvis minor)

Narrow and deep, tapering

Wide and shallow, cylindrical

Pelvic inlet (superior pelvic aperture)

Heart shaped, narrow

Oval or rounded, wide

Pelvic outlet (inferior pelvic aperture)

Comparatively small

Comparatively large

Pubic arch and subpubic angle

Narrow

Wide

Obturator foramen

Round

Oval

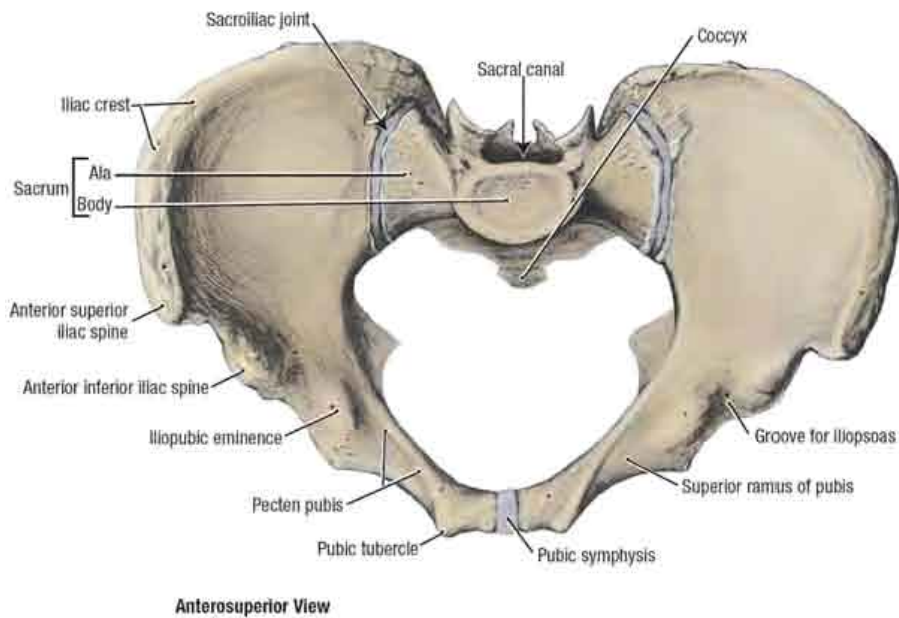
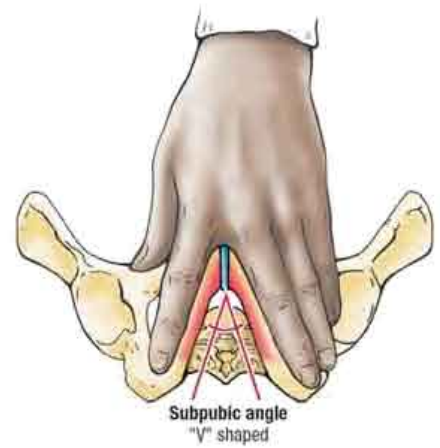
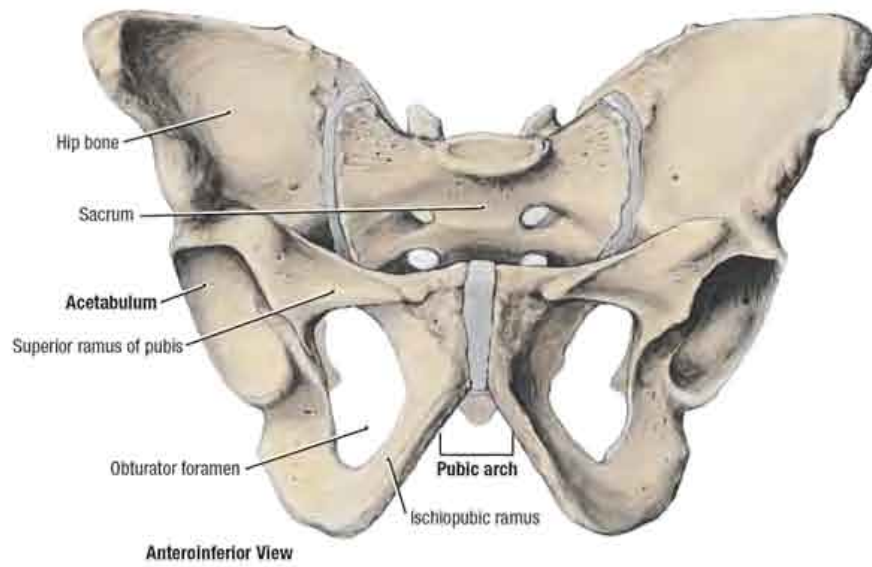
Acetabulum



Large  
Small

Bony pelvis    Male    Female

Table 3.1 Differences between Male and Female Pelves
--



Authors: Agur, Anne M.R.; Dalley, Arthur F.

Title: *Grant's Atlas of Anatomy, 12th Edition*

Copyright ©2009 Lippincott Williams & Wilkins

> Table of Contents > Chapter 3 - Pelvis and Perineum > 3.6 Female pelvic girdle

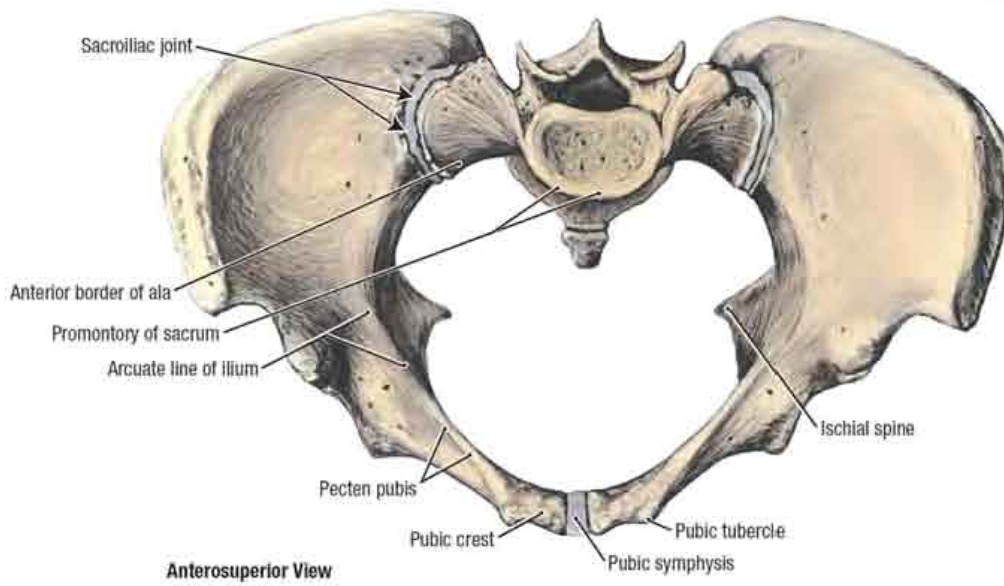
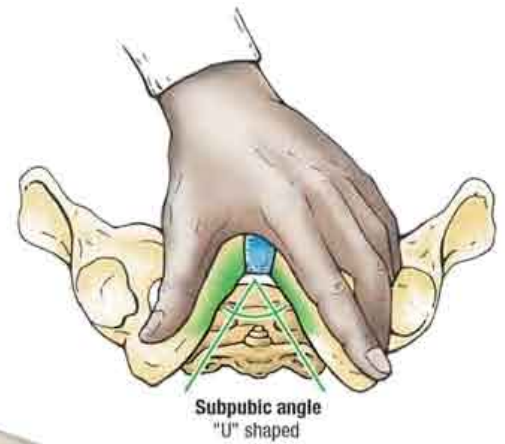
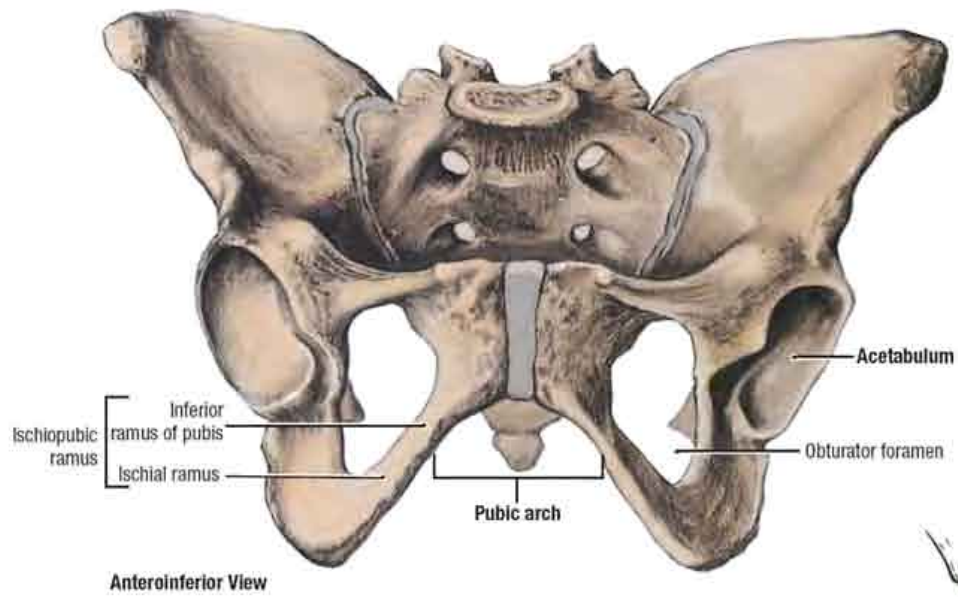
---

## 3.6 Female pelvic girdle

*Part of* "Chapter 3 - Pelvis and Perineum "

---

P.200



Authors: Agur, Anne M.R.; Dalley, Arthur F.

Title: *Grant's Atlas of Anatomy, 12th Edition*

Copyright ©2009 Lippincott Williams & Wilkins

> Table of Contents > Chapter 3 - Pelvis and Perineum > 3.7 Pelvis and pelvic ligaments

---

## 3.7 Pelvis and pelvic ligaments

*Part of* "Chapter 3 - Pelvis and Perineum "

A. Ligaments of pelvis, anterior aspect of pelvis.

---

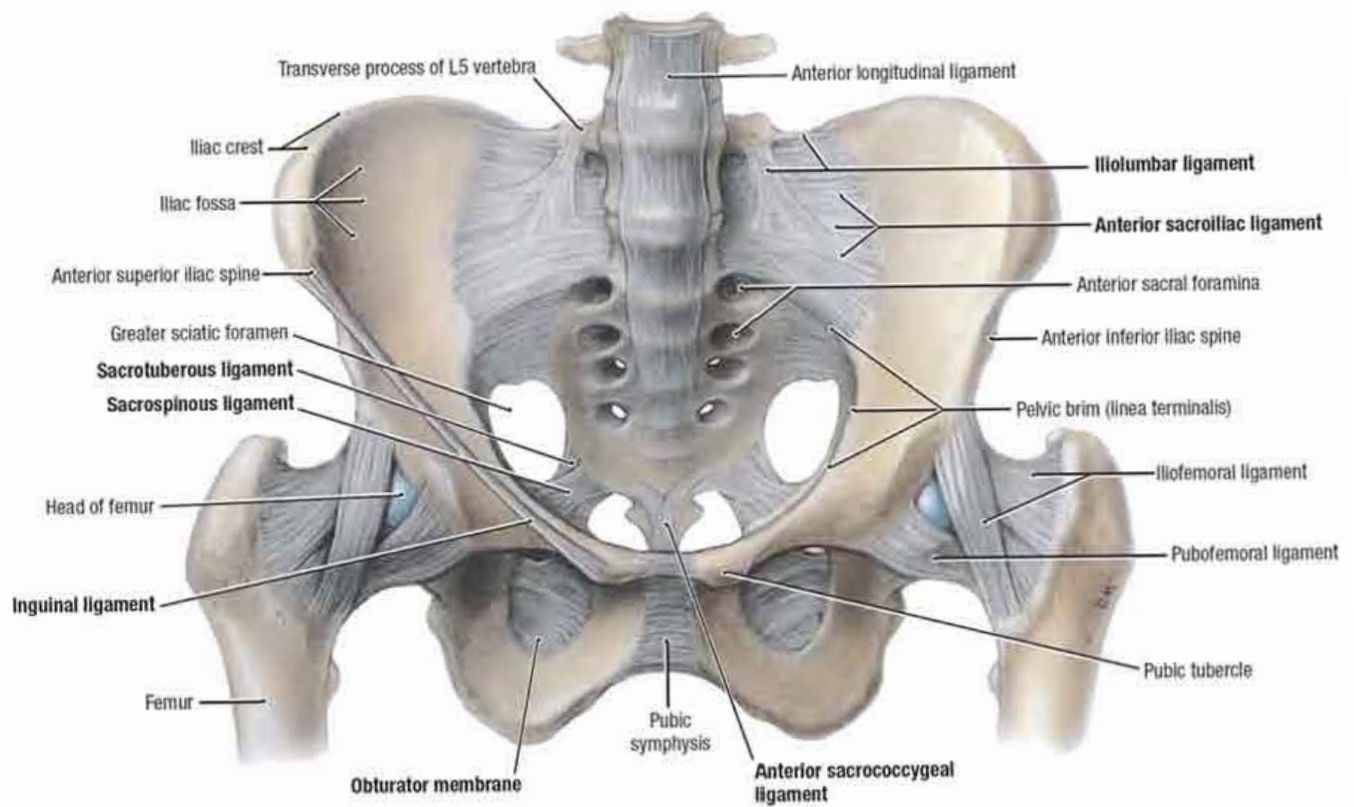
P.201

B. Ligaments of pelvis, posterior aspect of pelvis.

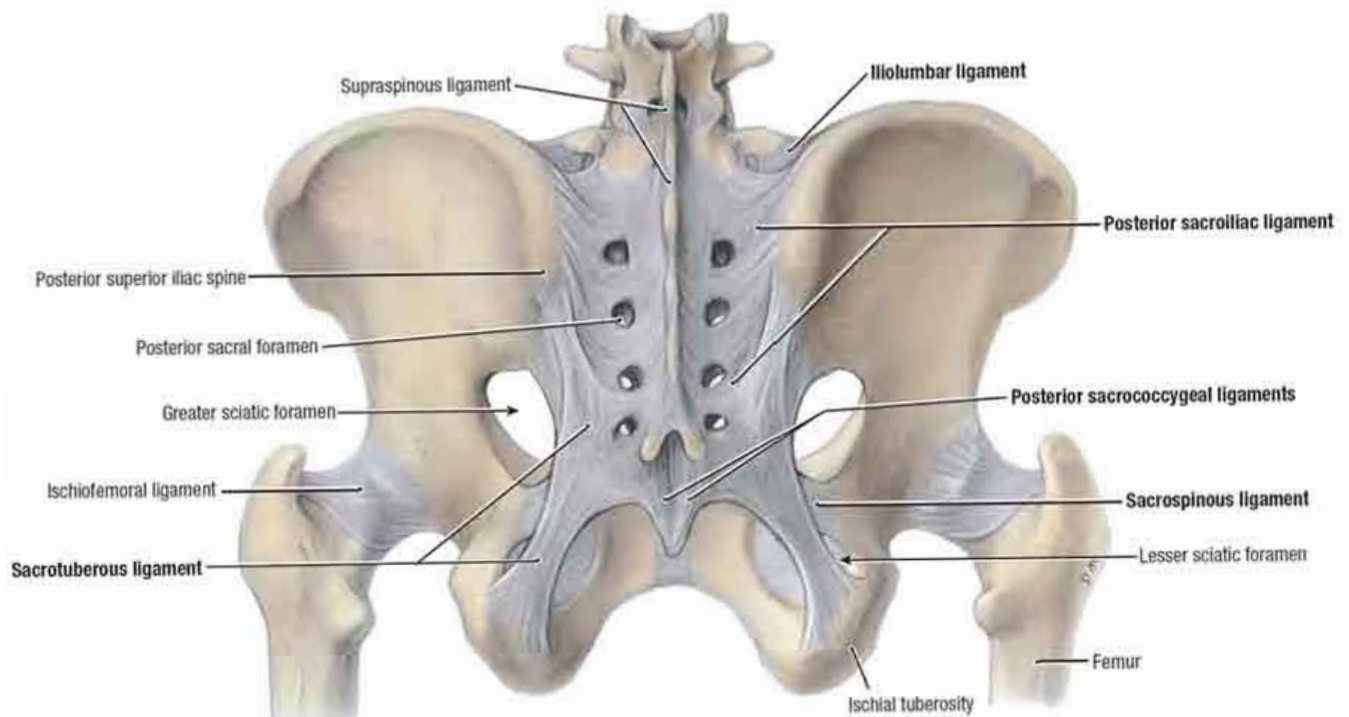
---

P.202





**A. Anterior View**



**B. Posterior View**

Authors: Agur, Anne M.R.; Dalley, Arthur F.

Title: *Grant's Atlas of Anatomy, 12th Edition*

Copyright ©2009 Lippincott Williams & Wilkins

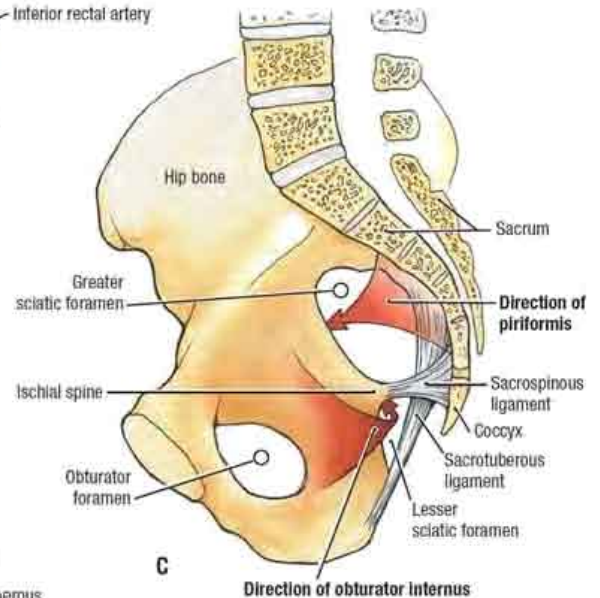
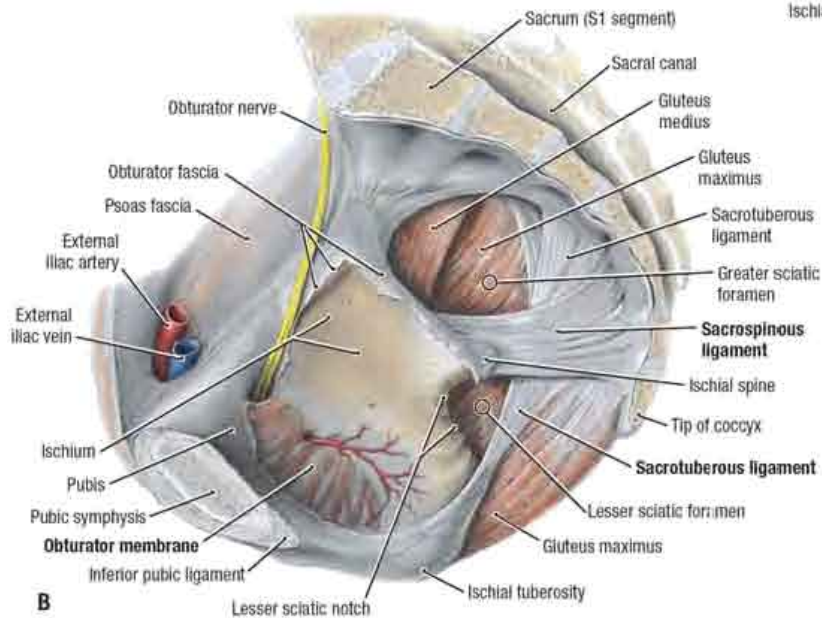
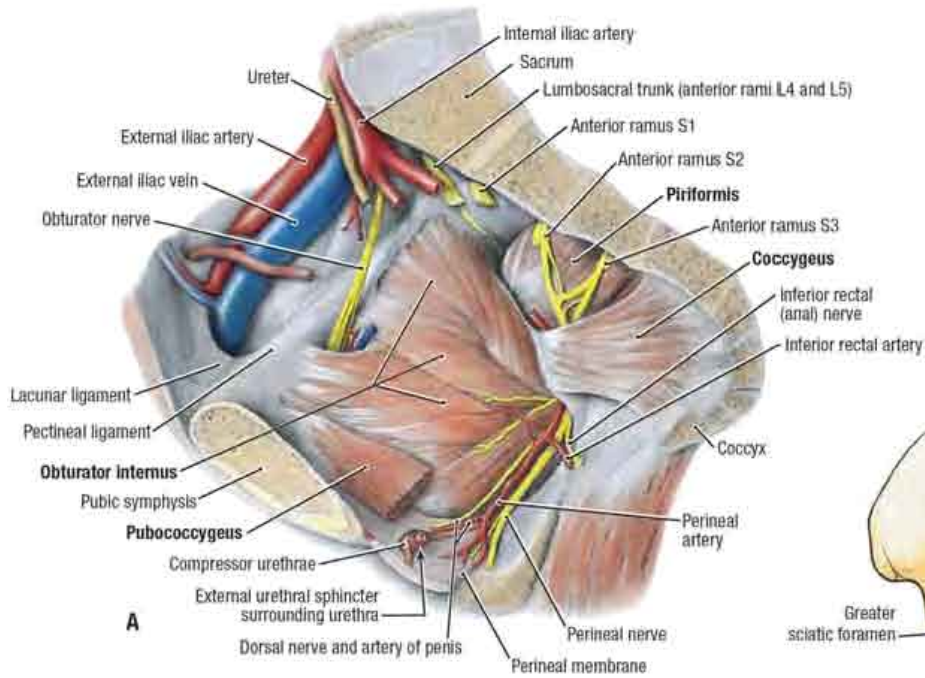
> Table of Contents > Chapter 3 - Pelvis and Perineum > 3.8 Obturator internus and piriformis

---

## 3.8 Obturator internus and piriformis

*Part of* "Chapter 3 - Pelvis and Perineum "

- On the lateral pelvic wall the obturator foramen is closed by the obturator membrane; the obturator internus muscle attaches mainly to the obturator membrane and exits the lesser pelvis through the lesser sciatic foramen; obturator fascia lies on the medial surface of the muscle.
- Piriformis lies on the posterolateral pelvic wall and leaves the lesser pelvis through the greater sciatic foramen.



Medial Views

Authors: Agur, Anne M.R.; Dalley, Arthur F.

Title: *Grant's Atlas of Anatomy, 12th Edition*

Copyright ©2009 Lippincott Williams & Wilkins

> Table of Contents > Chapter 3 - Pelvis and Perineum > 3.9 Muscles of the pelvic diaphragm

---

## 3.9 Muscles of the pelvic diaphragm

*Part of* "Chapter 3 - Pelvis and Perineum "

A. The pelvic floor is formed by the funnel- or bowl-shaped pelvic diaphragm. The funnel shape can be seen in a medial view of a median section. B. The bowl shape from a superior view.

Lateral wall

Obturator internus

Pelvic surfaces of ilium and ischium, obturator membrane

Greater trochanter of femur

Nerve to obturator internus (L5, S1, S2)

Rotates thigh laterally; assists in holding head of femur in acetabulum

Posterolateral wall

Piriformis

Pelvic surface of S2–S4 segments, superior margin of greater sciatic notch, sacrotuberous ligament

Anterior rami of S1 and S2

Rotates thigh laterally; abducts thigh; assists in holding head of femur in acetabulum

Floor

Levator ani (pubococcygeus, puborectalis, and iliococcygeus)

Body of pubis, tendinous arch of obturator fascia, ischial spine

Perineal body, coccyx, anococcygeal ligament, walls of prostate or vagina, rectum, and anal canal

Nerve to levator ani (branches of S4), inferior anal (rectal) nerve, and coccygeal plexus

Forms most of pelvic diaphragm that helps support pelvic viscera and resists increases in

intraabdominal pressure

Coccygeus (ischiococcygeus)

Ischial spine

Inferior end of sacrum and coccyx

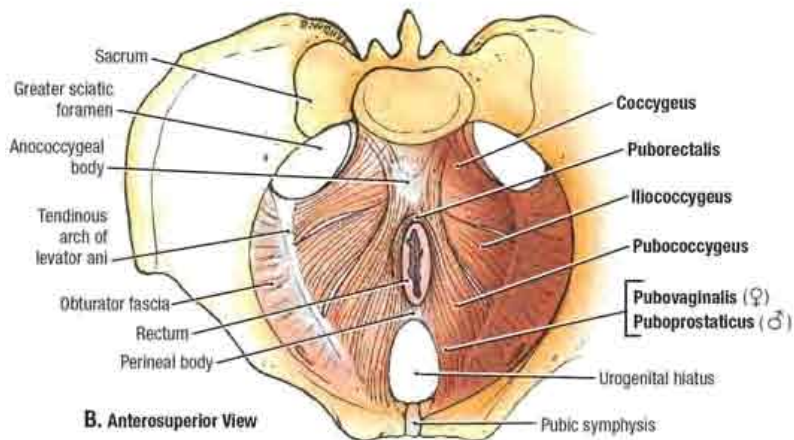
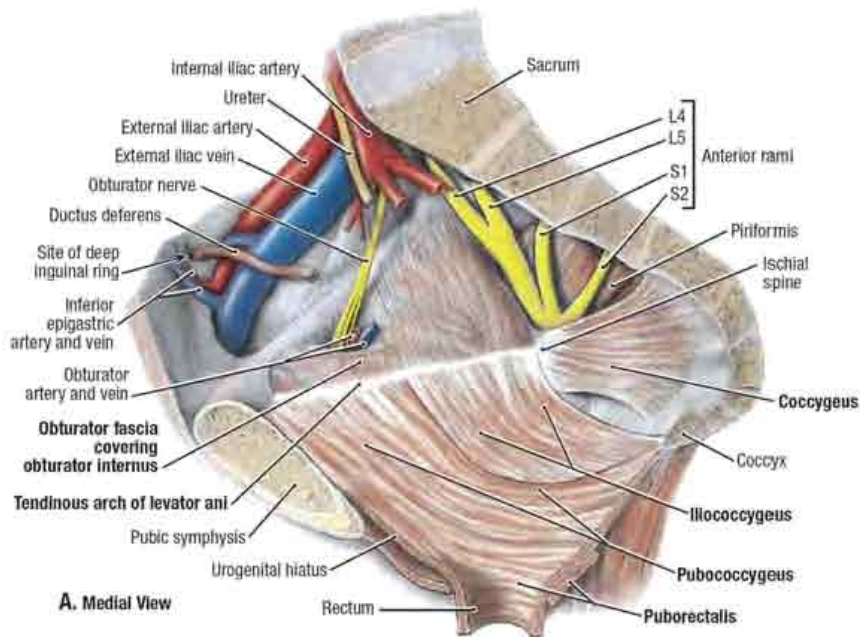
Branches of S4 and S5 spinal nerves

Forms small part of pelvic diaphragm that supports pelvic viscera; flexes coccyx

Boundary	Muscle	Proximal attachment	Distal attachment	Innervation	Main Action
----------	--------	---------------------	-------------------	-------------	-------------

Table 3.2 Muscles of Pelvic Walls and Floor





#### Muscles of floor of pelvis\*:

Pelvic diaphragm (PD) = Levator ani (LA) + Coccygeus (C)  
(PD = LA + C)

Levator ani (LA) = Pubococcygeus (PC) + Iliococcygeus (IC)  
(LA = PC + IC)

Pubococcygeus (PC ♀) = Puborectalis (PR) + Pubovaginalis (PV)  
(PC = PR + PV ♀)

Pubococcygeus (PC ♂) = Puborectalis (PR) + Puboprostaticus (PP)  
(PC = PR + PP ♂) (Levator prostatae [LP])

\*Formulas: Dr. Larry M. Ross,  
The University of Texas Medical School at Houston

Authors: Agur, Anne M.R.; Dalley, Arthur F.

Title: *Grant's Atlas of Anatomy, 12th Edition*

Copyright ©2009 Lippincott Williams & Wilkins

> Table of Contents > Chapter 3 - Pelvis and Perineum > 3.10 Floor and walls of male pelvis, pelvic diaphragm

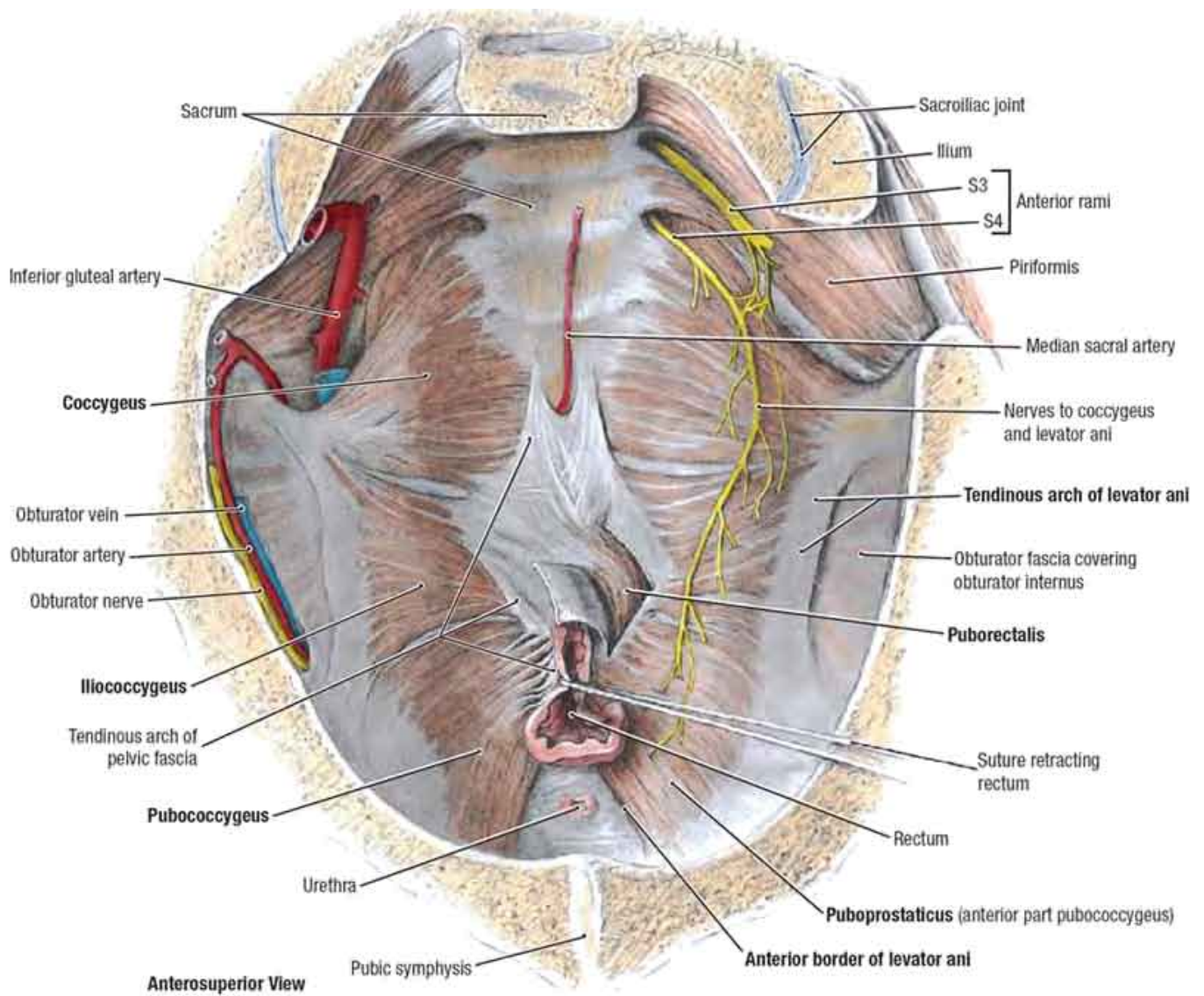
---

## 3.10 Floor and walls of male pelvis, pelvic diaphragm

*Part of "Chapter 3 - Pelvis and Perineum "*

The pelvic viscera are removed, and the bony pelvis has been cut to show the levator ani and coccygeus muscles.

- The pubococcygeus muscle arises mainly from the pubic bone, the iliococcygeus muscle from the tendinous arch, and the coccygeus muscle from the ischial spine.
- In the male, the anterior part of the pubococcygeus muscle that lies adjacent to the prostate is the puboprostaticus.
- Although not part of the pelvic diaphragm, the piriformis assists in closure of the pelvic outlet, largely occluding the greater sciatic foramen.



Authors: Agur, Anne M.R.; Dalley, Arthur F.

Title: *Grant's Atlas of Anatomy, 12th Edition*

Copyright ©2009 Lippincott Williams & Wilkins

> Table of Contents > Chapter 3 - Pelvis and Perineum > 3.11 Floor and walls of female pelvis

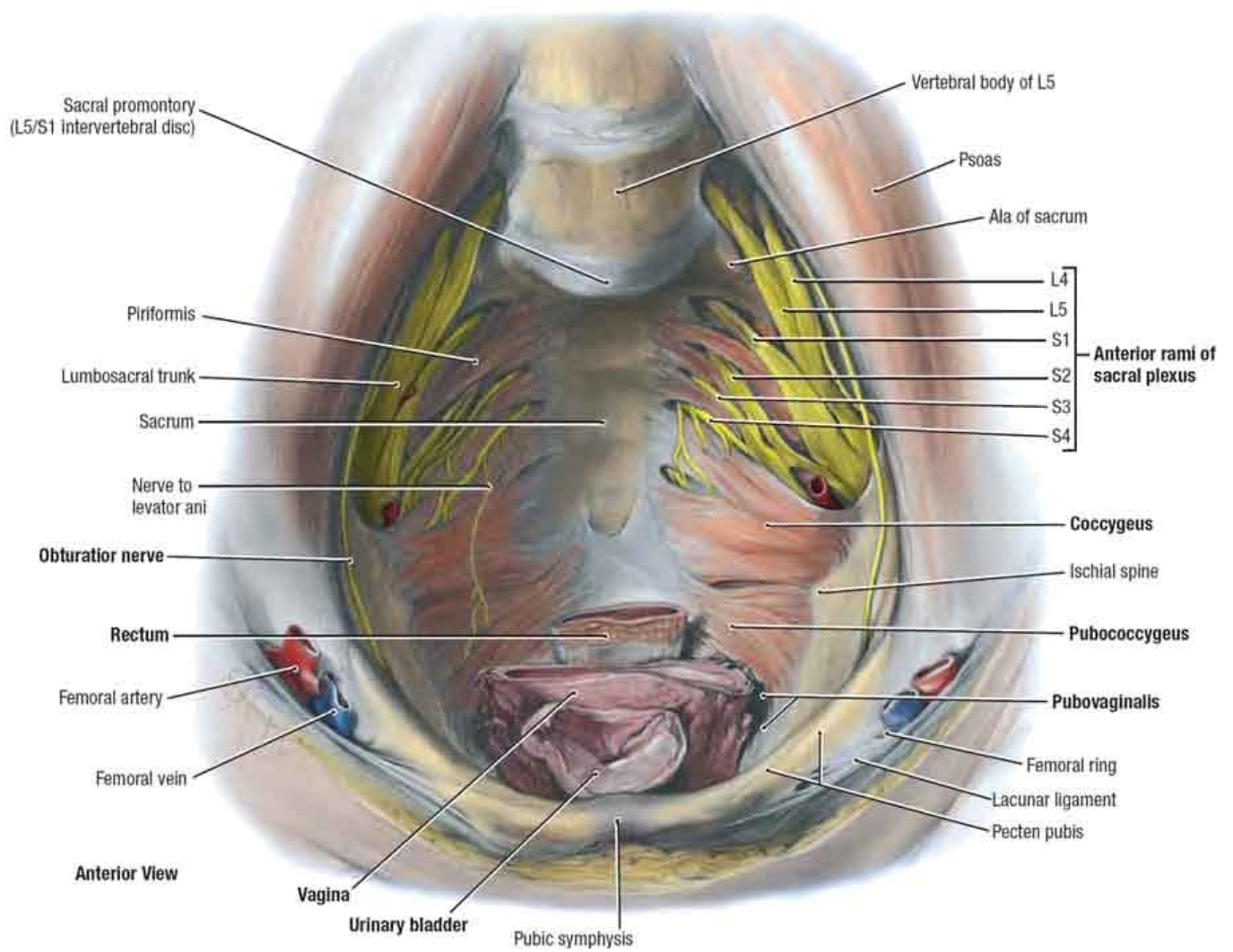
---

## 3.11 Floor and walls of female pelvis

*Part of* "Chapter 3 - Pelvis and Perineum "

The pelvic viscera are removed to reveal the levator ani and coccygeus muscles.

- Note the relative positions of the bladder, vagina, and rectum as they penetrate the pelvic floor.
- Branches of S3 and S4 nerves supply the levator ani and coccygeus muscles; the pudendal nerve, through its perineal branch, also supplies the levator ani muscle (see Table 3.2 ).
- The obturator nerve runs along the lateral wall of the pelvis and enters the thigh by passing through the obturator canal.
- The anterior rami of L4–S4 are part of the sacral plexus, almost all of which exits the pelvis via the greater sciatic foramen with the piriformis.





Authors: Agur, Anne M.R.; Dalley, Arthur F.

Title: *Grant's Atlas of Anatomy, 12th Edition*

Copyright ©2009 Lippincott Williams & Wilkins

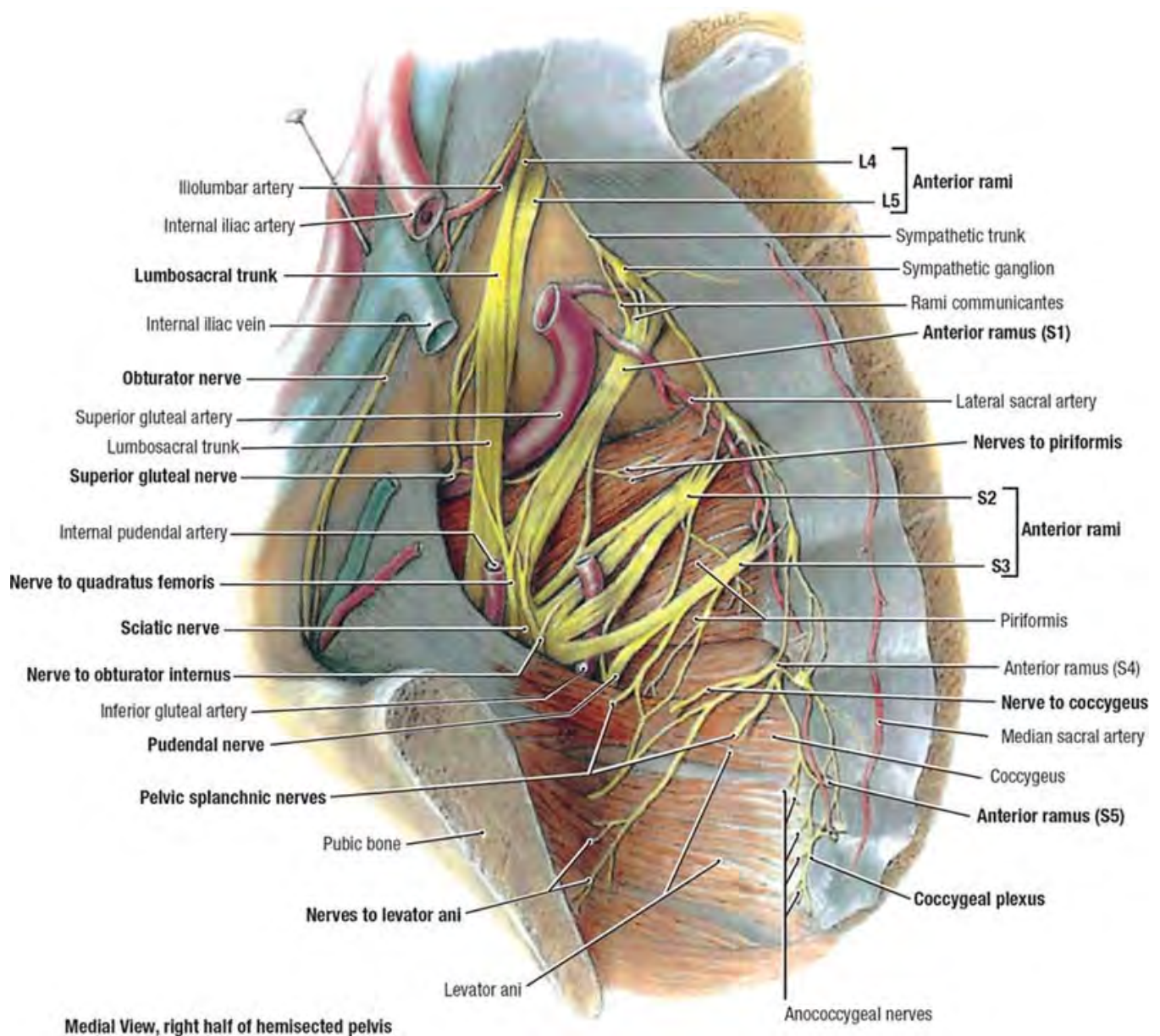
> Table of Contents > Chapter 3 - Pelvis and Perineum > 3.12 Sacral and coccygeal nerve plexuses

---

## 3.12 Sacral and coccygeal nerve plexuses

*Part of "Chapter 3 - Pelvis and Perineum "*

- The sympathetic trunk or its ganglia send rami communicantes to each sacral and coccygeal nerve.
- The anterior ramus from L4 joins that of L5 to form the lumbosacral trunk.
- The anterior rami of S1 and S2 supply the piriformis muscle; S3 and S4 supply the coccygeus and levator ani muscles.
- The sciatic nerve arises from anterior rami of L4, L5, S1, S2, and S3; the pudendal nerve from S2, S3, and S4; and the coccygeal plexus from S4, S5, and coccygeal segments.



Sciatic

L4, L5, S1, S2, S3

Articular branches to hip joint and muscular branches to flexors of knee in thigh and all muscles in leg and foot

Superior gluteal

L4, L5, S1

Gluteus medius and gluteus minimus muscles

Nerve to quadratus femoris and inferior gemellus

L4, L5, S1

Quadratus femoris and inferior gemellus muscles

Inferior gluteal

L5, S1, S2

Gluteus maximus muscle

Nerve to obturator internus and superior gemellus

L5, S1, S2

Obturator internus and superior gemellus muscles

Nerve to piriformis

S1, S2

Piriformis muscle

Posterior femoral cutaneous

S2, S3

Cutaneous branches to buttock and uppermost medial and posterior surfaces of thigh

Perforating cutaneous

S2, S3

Cutaneous branches to medial part of buttock

Pudendal

S2, S3, S4

Structures in perineum, sensory to genitalia, muscular branches to perineal muscles, external urethral sphincter, and external anal sphincter

Pelvic splanchnic

S2, S3, S4

Pelvic viscera via inferior hypogastric and pelvic plexuses

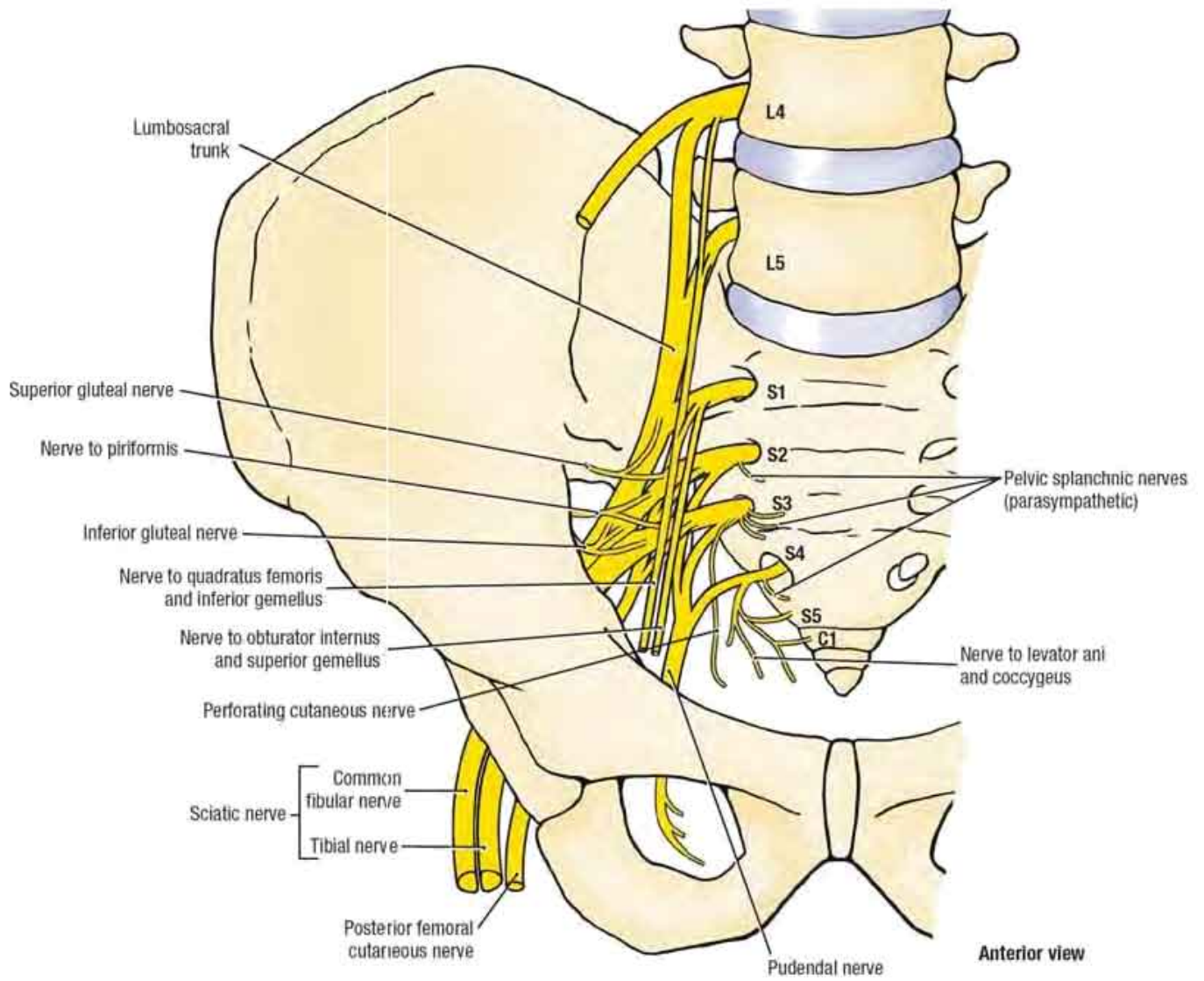
Nerves to levator ani and coccygeus

S3, S4

Levator ani and coccygeus muscles

Nerve    Origin    Distribution

### Table 3.3 Nerves of Sacral and Coccygeal Plexuses



Authors: Agur, Anne M.R.; Dalley, Arthur F.

Title: *Grant's Atlas of Anatomy, 12th Edition*

Copyright ©2009 Lippincott Williams & Wilkins

> Table of Contents > Chapter 3 - Pelvis and Perineum > 3.13 Right half of hemisected female pelvis

---

## 3.13 Right half of hemisected female pelvis

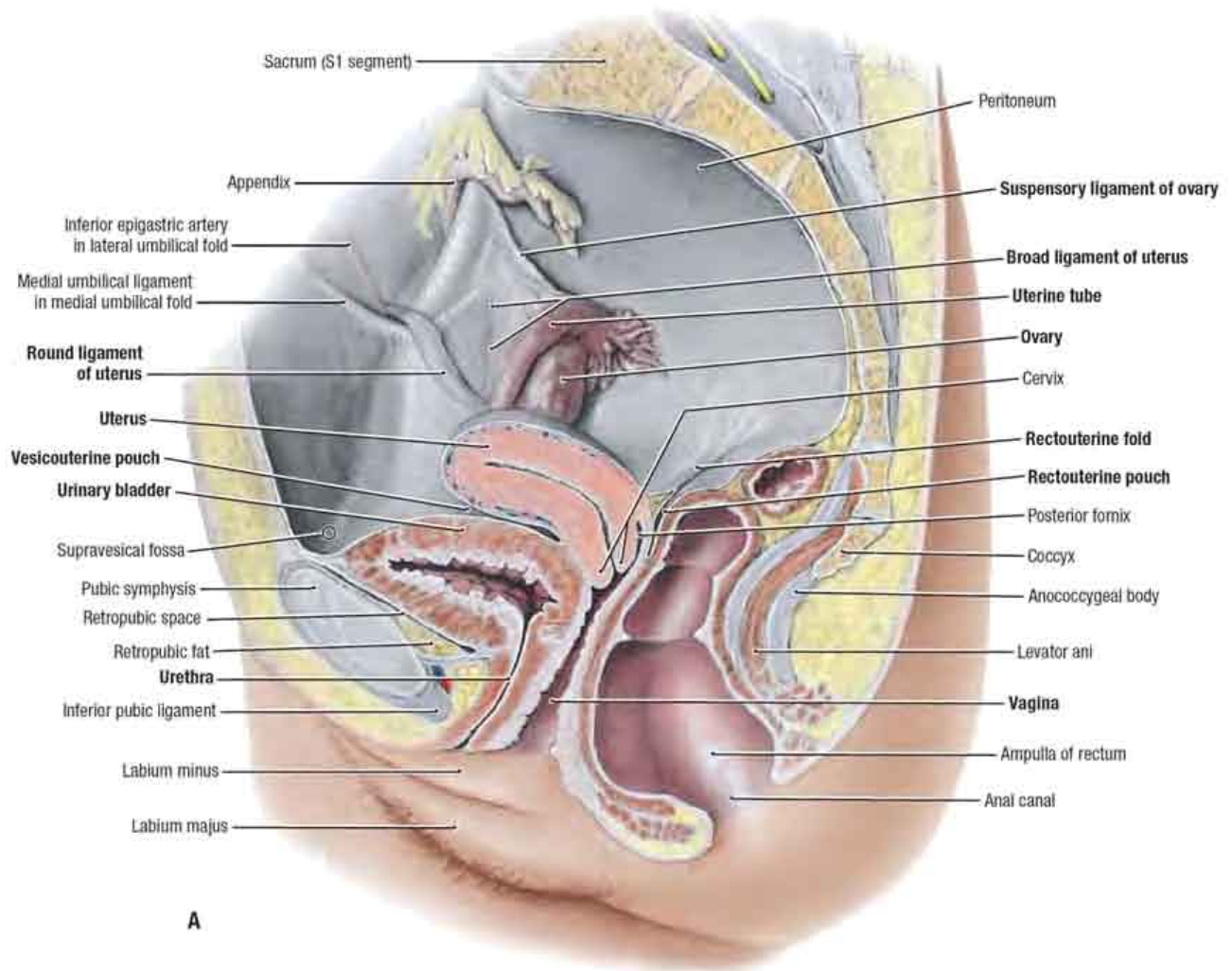
*Part of* "Chapter 3 - Pelvis and Perineum "

A. Organs in situ.

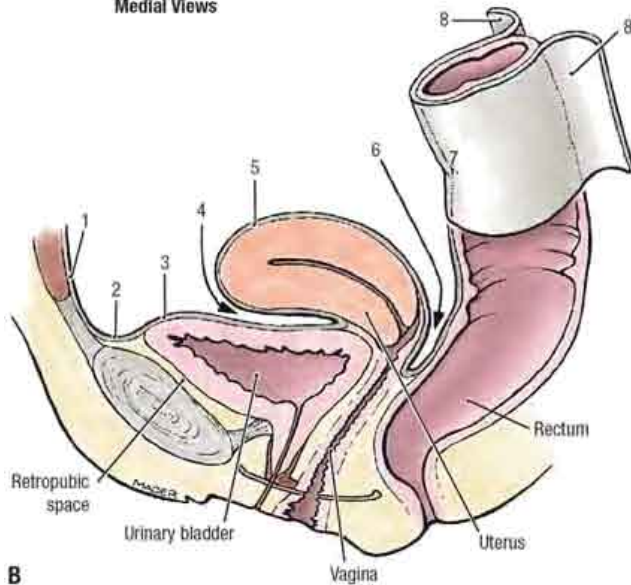
- The urethra, the vagina, and the rectum are parallel to one another; the uterus is nearly at right angles to these structures when the bladder is empty.

B. Peritoneum covering female pelvic organs.





#### Medial Views



#### Female:

Peritoneum passes:

- From the anterior abdominal wall (1)
- Superior to the pubic bone (2)
- On the superior surface of the urinary bladder (3)
- From the bladder to the uterus, forming the vesicouterine pouch (4)
- On the fundus and body of the uterus, posterior fornix, and all of the vagina (5)
- Between the rectum and uterus, forming the rectouterine pouch (6)
- On the anterior and lateral sides of the rectum (7)
- Posteriorly to become the sigmoid mesocolon (8)



Authors: Agur, Anne M.R.; Dalley, Arthur F.

Title: *Grant's Atlas of Anatomy, 12th Edition*

Copyright ©2009 Lippincott Williams & Wilkins

> Table of Contents > Chapter 3 - Pelvis and Perineum > 3.14 Right half of hemisected male pelvis

---

## 3.14 Right half of hemisected male pelvis

*Part of* "Chapter 3 - Pelvis and Perineum "

Organs in situ. A. The urinary bladder is distended and displaced posteriorly, not anteriorly as is usual, forming a broad and deep supravescical fossa when the bladder is full. B. Peritoneum covering male pelvic organs.

---

P.210



Authors: Agur, Anne M.R.; Dalley, Arthur F.

Title: *Grant's Atlas of Anatomy, 12th Edition*

Copyright ©2009 Lippincott Williams & Wilkins

> Table of Contents > Chapter 3 - Pelvis and Perineum > 3.15 Anal sphincters and anal canal

---

## 3.15 Anal sphincters and anal canal

*Part of* "Chapter 3 - Pelvis and Perineum "

A. Levator ani, in right half of hemisected pelvis.

- The subcutaneous fibers of the external anal sphincter are reflected with forceps. The pubococcygeus muscle is cut to reveal the anal canal, to which it is, in part, attached.

B. Puborectalis.

- The innermost part of the pubococcygeus muscle, the puborectalis, forms a U-shaped muscular "sling" around the anorectal junction, which maintains the anorectal (perineal) flexure.

C. External and internal anal sphincters.

- The internal anal sphincter is a thickening of the inner, circular muscular coat of the anal canal.
- The external anal sphincter has three continuous zones: deep, superficial, and subcutaneous; the deep part intermingles with the puborectalis muscle posteriorly.
- The longitudinal muscle layer of the rectum separates the internal and external anal sphincters and terminates in the subcutaneous tissue and skin around the



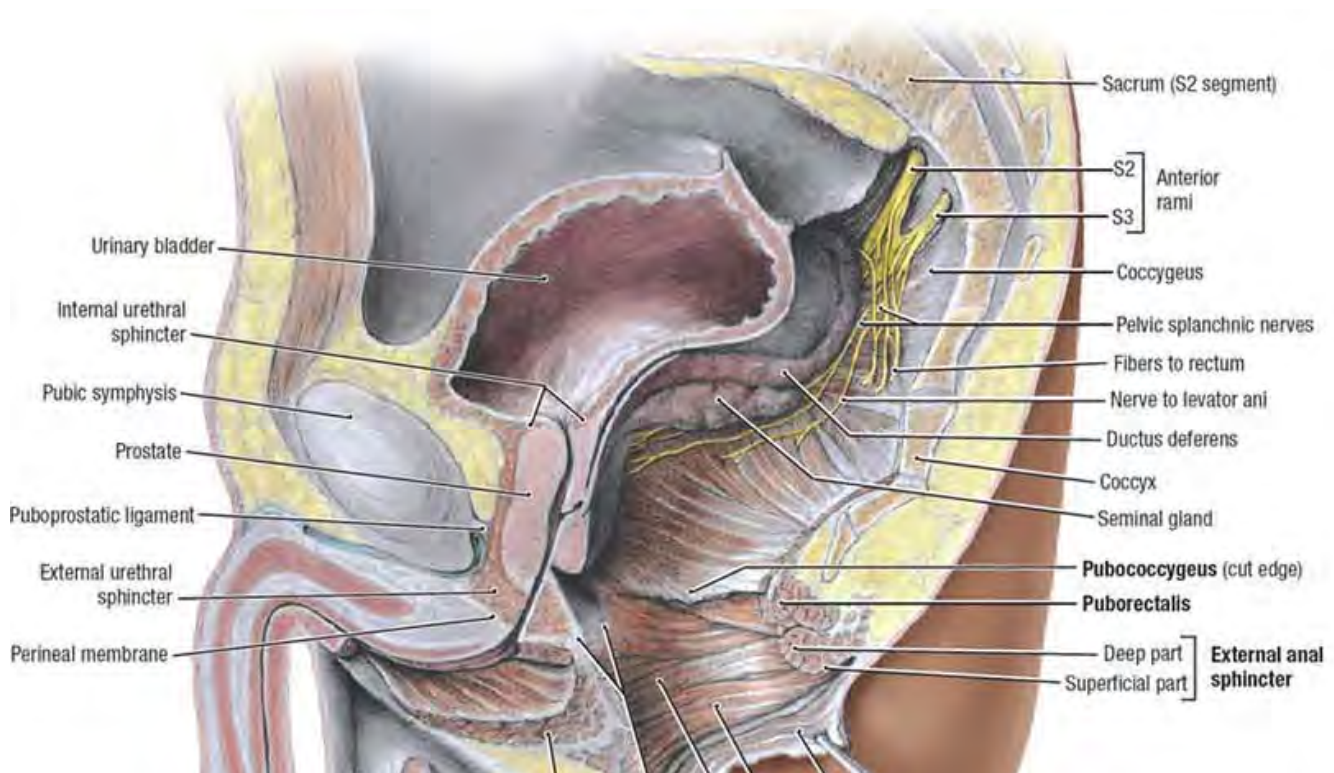
anus.

P.211

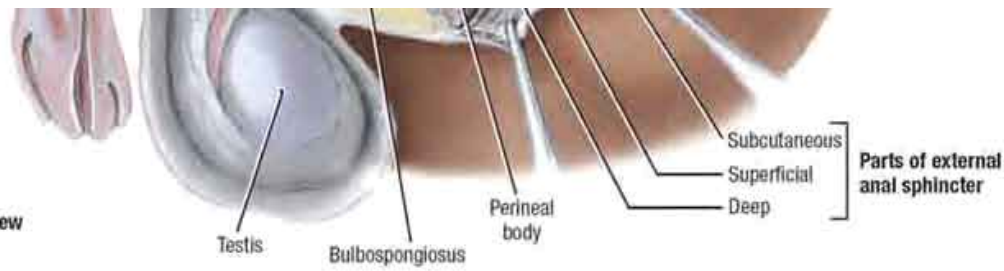
#### D. Features of the anal canal.

- The anal columns are 5 to 10 vertical folds of mucosa separated by anal valves; they contain portions of the rectal venous plexus.
- The pecten is a smooth area of hairless stratified epithelium that lies between the anal valves superiorly and the inferior border of the internal anal sphincter inferiorly.
- The pectinate line is an irregular line at the base of the anal valves where the intestinal mucosa is continuous with the pecten; this indicates the junction of the *superior part of the anal canal (derived from embryonic hindgut)* and the inferior part of the *anal canal (derived from the anal pit [proctodeum])*. Innervation is visceral proximal to the line and somatic distally; lymphatic drainage is to the pararectal nodes proximally and to the superficial inguinal nodes distally.

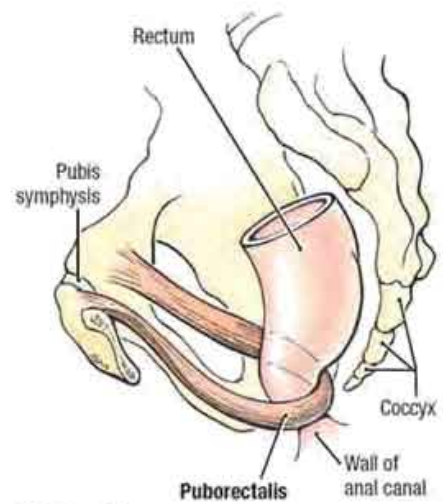
P.212



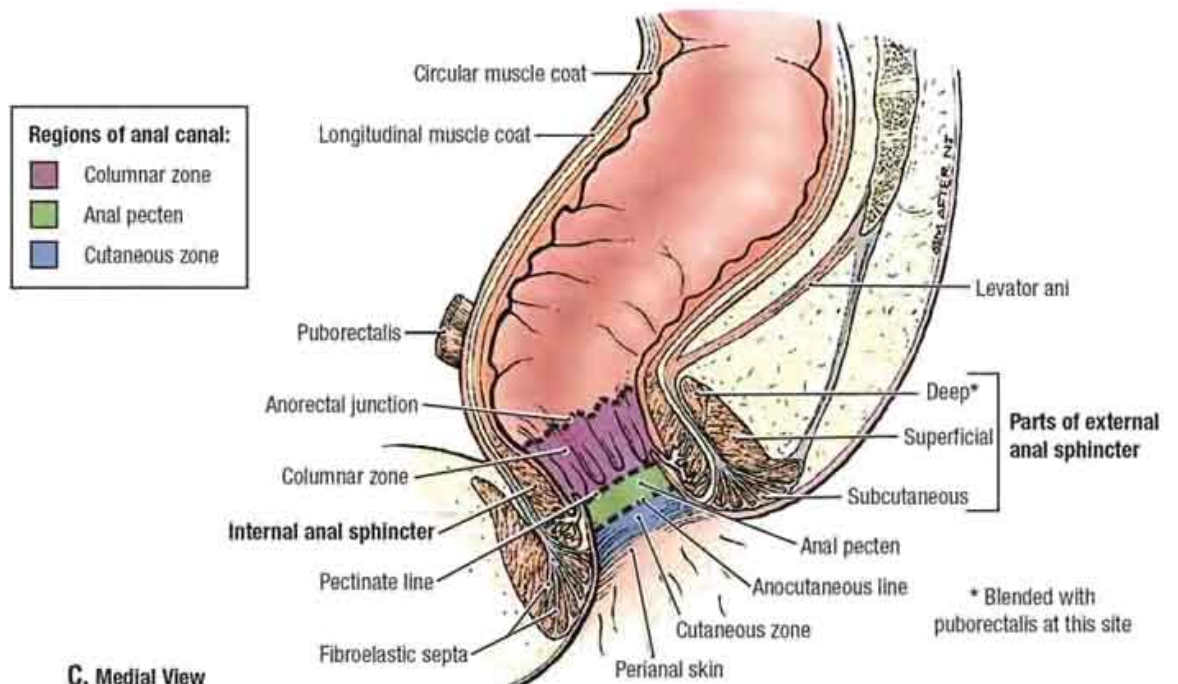
**A. Medial View**

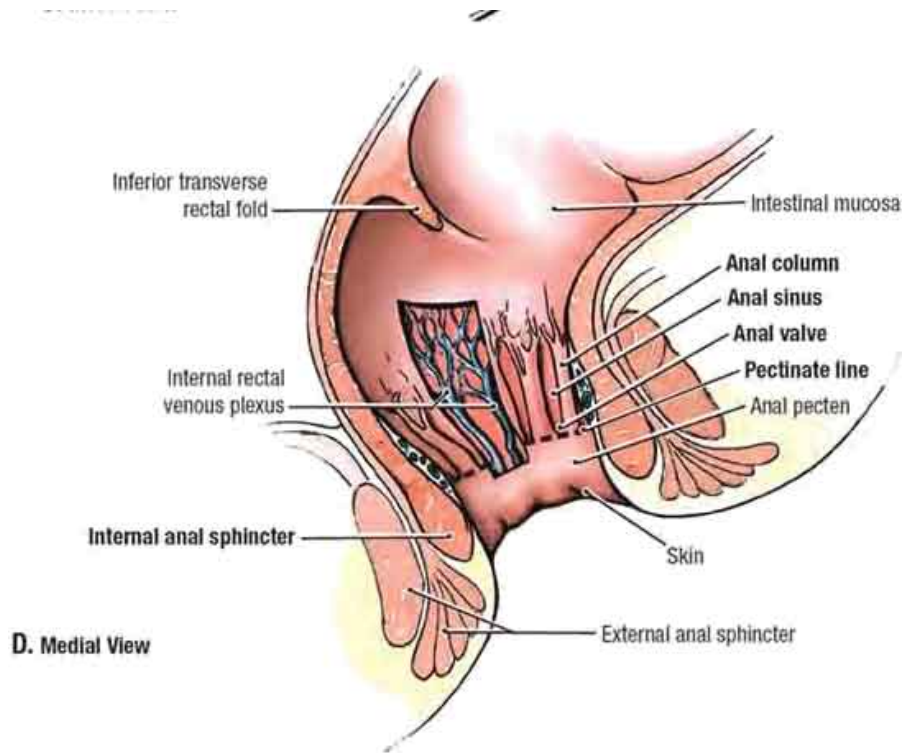


**B. Lateral View**



**C. Medial View**





Authors: Agur, Anne M.R.; Dalley, Arthur F.

Title: *Grant's Atlas of Anatomy, 12th Edition*

Copyright ©2009 Lippincott Williams & Wilkins

> Table of Contents > Chapter 3 - Pelvis and Perineum > 3.16 Rectum, anal canal, and neurovascular structures of the posterior pelvis

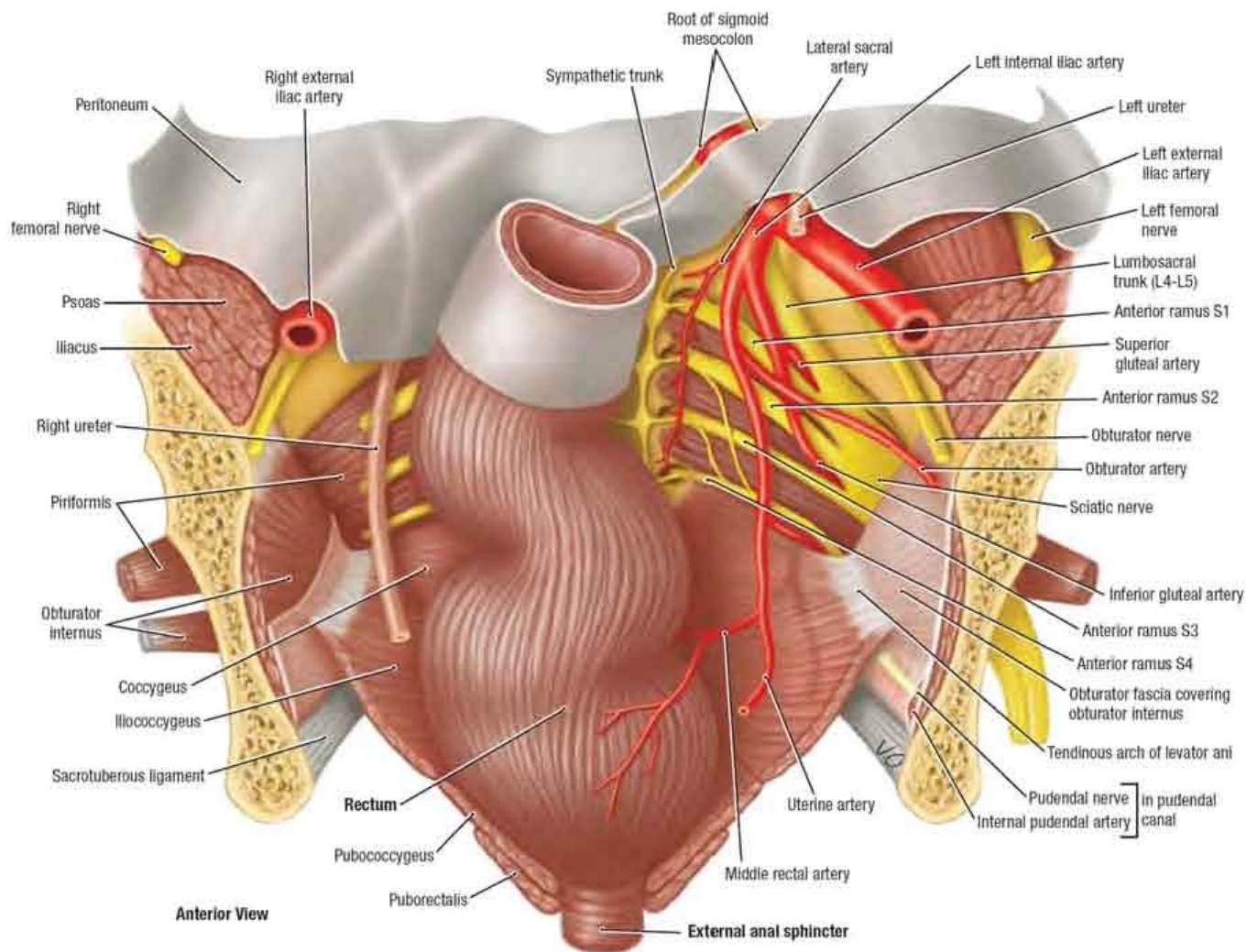
---

## 3.16 Rectum, anal canal, and neurovascular structures of the posterior pelvis

*Part of* "Chapter 3 - Pelvis and Perineum "

The pelvis is coronally bisected anterior to the rectum and anal canal. The superior gluteal artery often passes posteriorly between the anterior rami of L5 and S1, and the inferior gluteal artery between S2 and S3.







Authors: Agur, Anne M.R.; Dalley, Arthur F.

Title: *Grant's Atlas of Anatomy, 12th Edition*

Copyright ©2009 Lippincott Williams & Wilkins

> Table of Contents > Chapter 3 - Pelvis and Perineum > 3.17 Vasculature of rectum

---

## 3.17 Vasculature of rectum

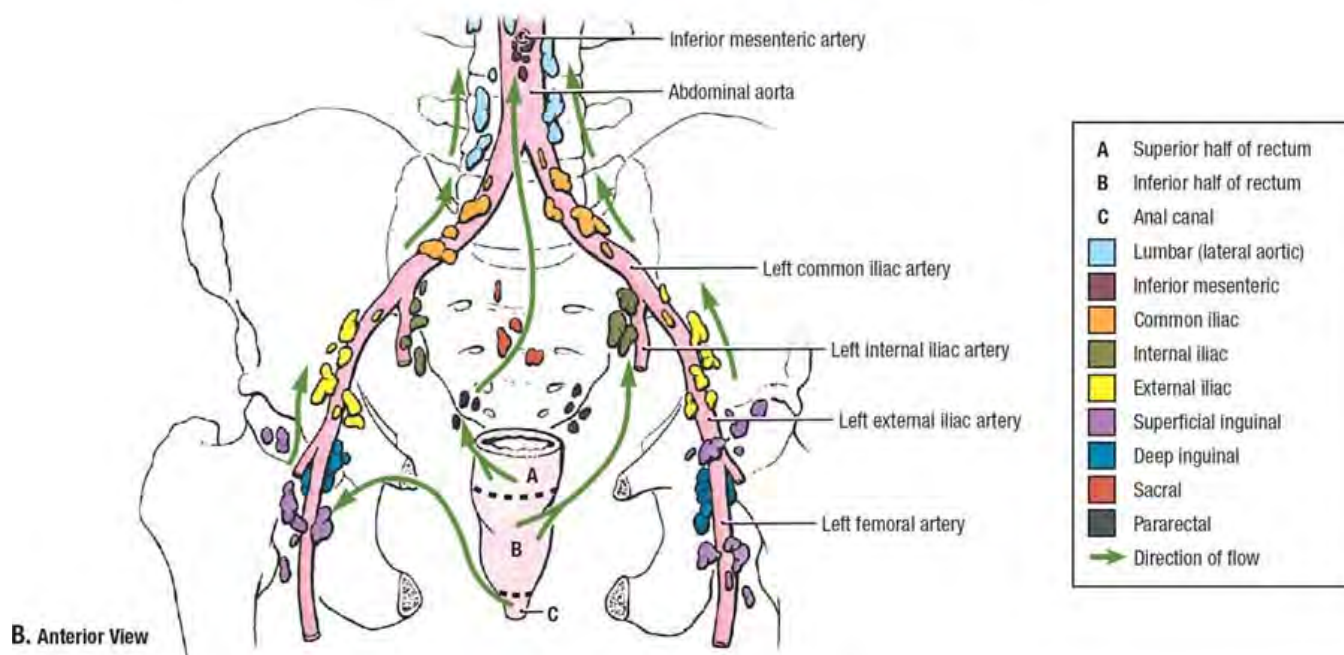
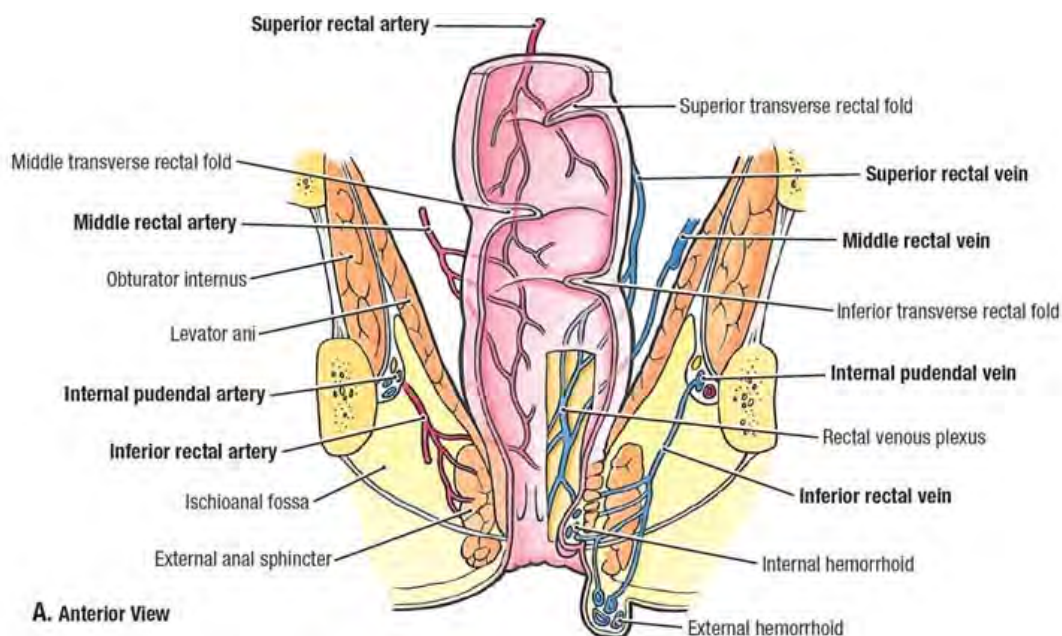
*Part of* "Chapter 3 - Pelvis and Perineum "

### A. Arterial and venous drainage.

- The continuation of the inferior mesenteric artery, the superior rectal artery, supplies the proximal part of rectum.
- Right and left middle rectal arteries, usually arising from the inferior vesical (male) or uterine (female) arteries, supply the middle and inferior parts of the rectum.
- Inferior rectal arteries, arising from the internal pudendal arteries, supply the anorectal junction and the anal canal.

### B. Lymphatic drainage.

- The superior, middle, and inferior rectal veins drain the rectum and anal canal; there are anastomoses between the plexuses formed by all three veins.
- The rectal venous plexus surrounds the distal rectum and anal canal and consists of an internal rectal plexus deep to the epithelium of the anal canal and an external rectal plexus external to the muscular coats of the wall of the anal canal.
- The superior rectal vein drains into the portal system, and the middle and inferior veins drain into the systemic system; thus, this is an important area of portacaval anastomosis.



Authors: Agur, Anne M.R.; Dalley, Arthur F.  
Title: *Grant's Atlas of Anatomy, 12th Edition*  
Copyright ©2009 Lippincott Williams & Wilkins

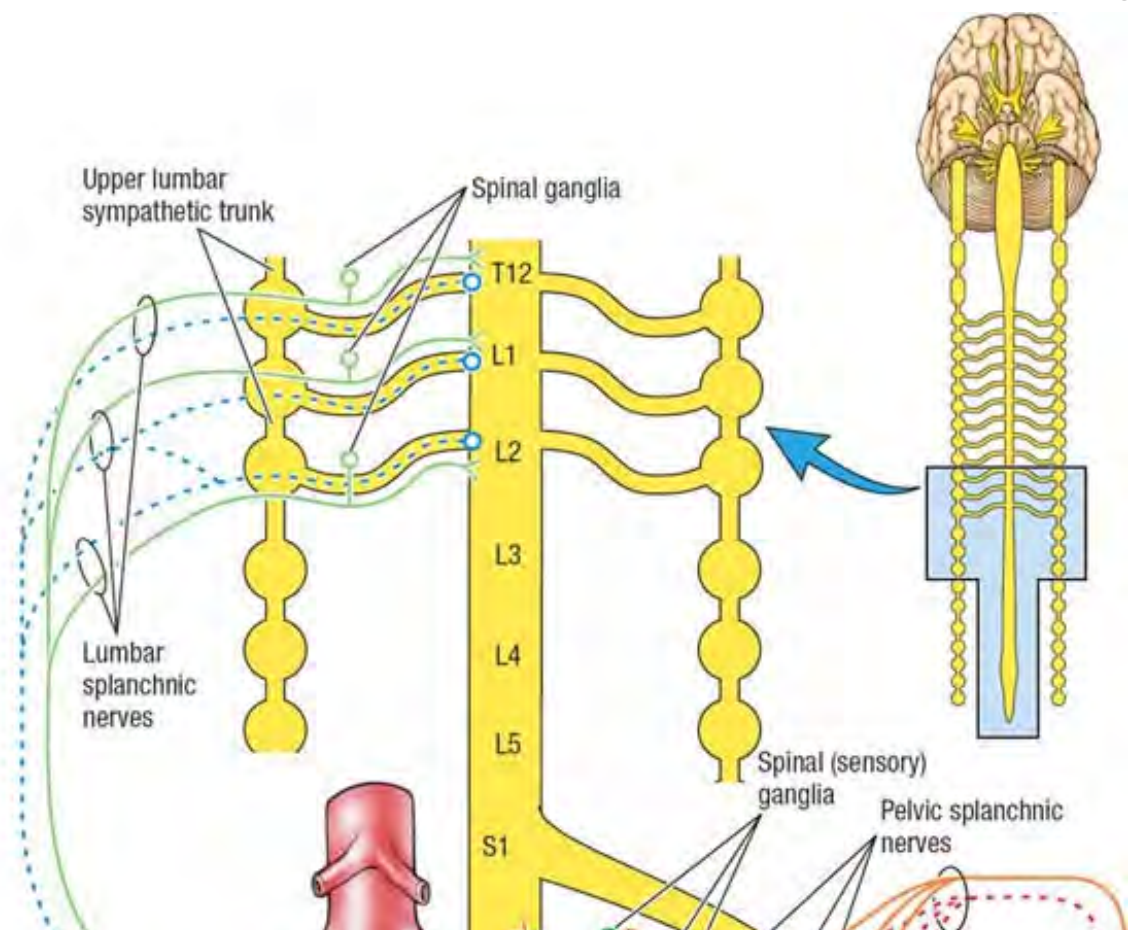
> Table of Contents > Chapter 3 - Pelvis and Perineum > 3.18 Innervation of rectum and anal canal

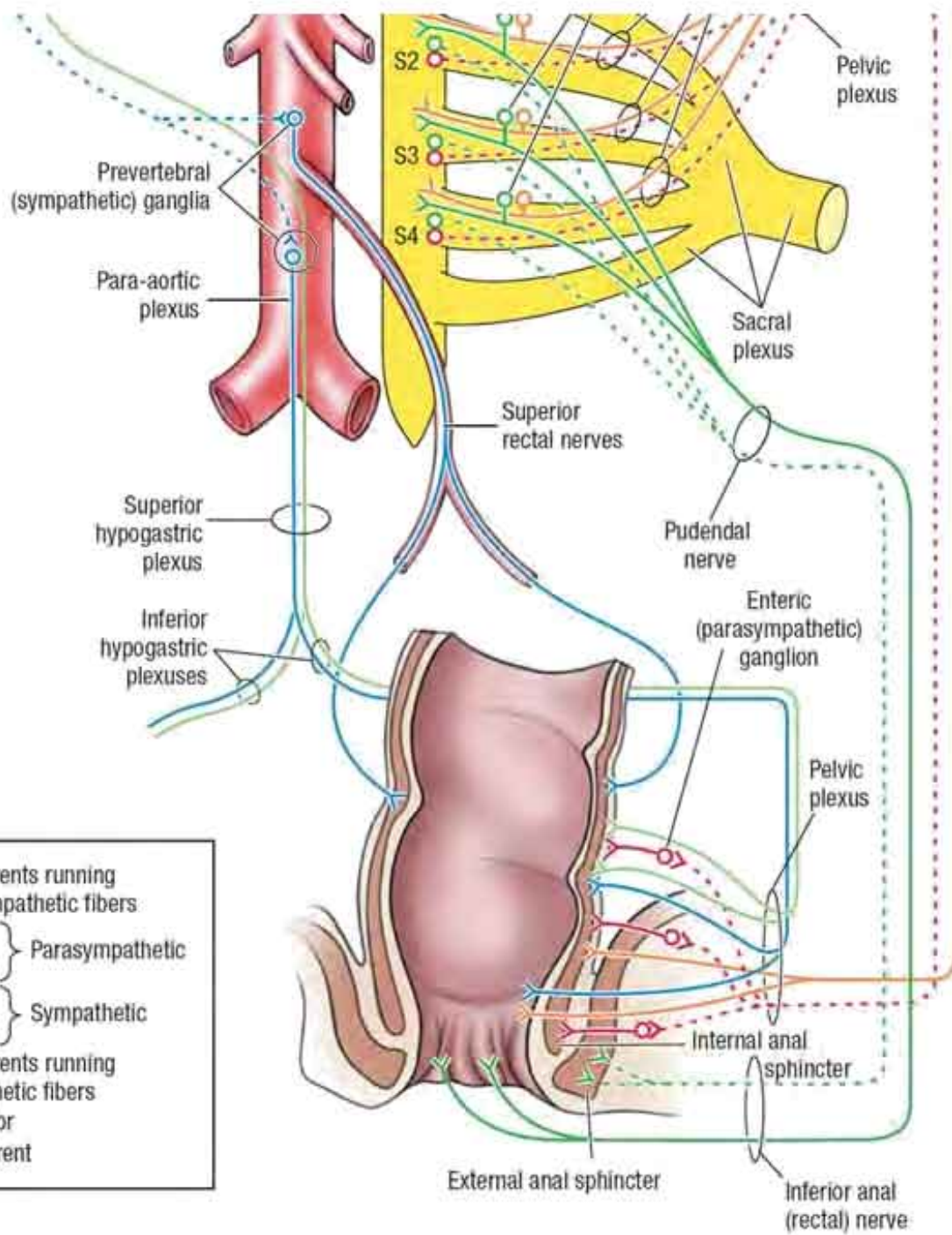
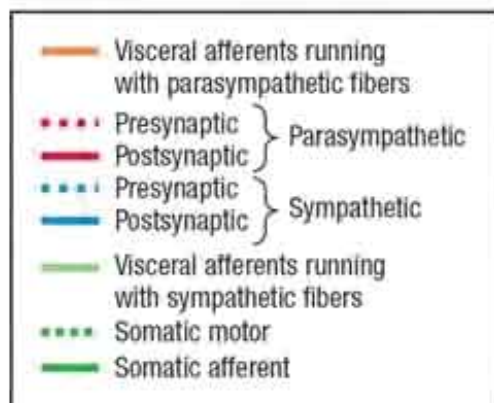
## 3.18 Innervation of rectum and anal canal

*Part of "Chapter 3 - Pelvis and Perineum"*

The lumbar and pelvic spinal nerves and hypogastric plexuses have been retracted laterally for clarity.

P.215







Authors: Agur, Anne M.R.; Dalley, Arthur F.

Title: *Grant's Atlas of Anatomy, 12th Edition*

Copyright ©2009 Lippincott Williams & Wilkins

> Table of Contents > Chapter 3 - Pelvis and Perineum > 3.19 Rectum in situ

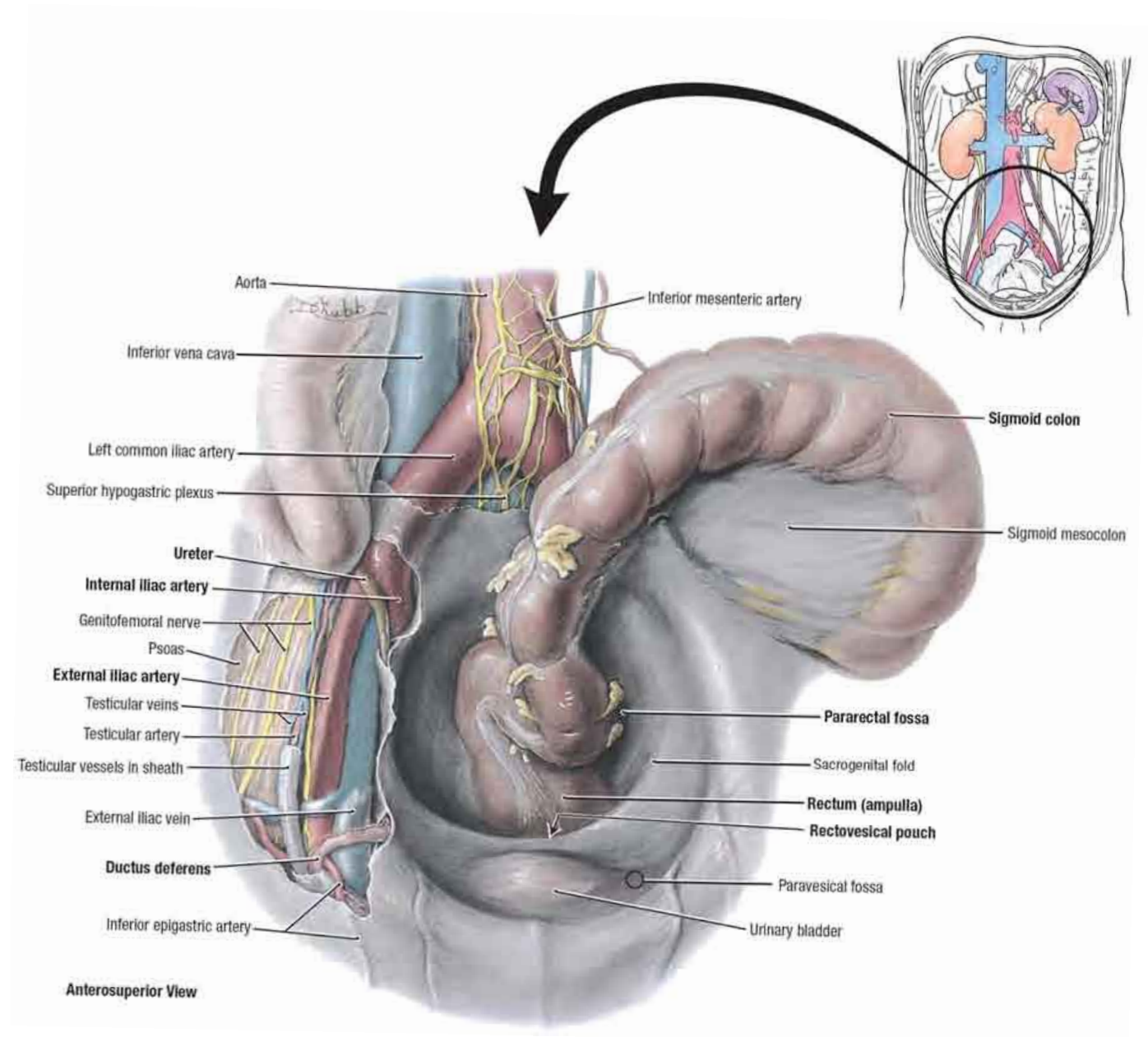
---

## 3.19 Rectum in situ

*Part of "Chapter 3 - Pelvis and Perineum "*

- The sigmoid colon begins at the left pelvic brim and becomes the rectum anterior to the third sacral segment in the midline.
- The superior hypogastric plexus lies inferior to the bifurcation of the aorta and anterior to the left common iliac vein.
- The ureter adheres to the external aspect of the peritoneum, crosses the external iliac vessels, and descends anterior to the internal iliac artery. The ductus deferens and its artery also adhere to the peritoneum, cross the external iliac vessels, and then hook around the inferior epigastric artery to join the other components of the spermatic cord.
- The genitofemoral nerve lies on the psoas.





Authors: Agur, Anne M.R.; Dalley, Arthur F.

Title: *Grant's Atlas of Anatomy, 12th Edition*

Copyright ©2009 Lippincott Williams & Wilkins

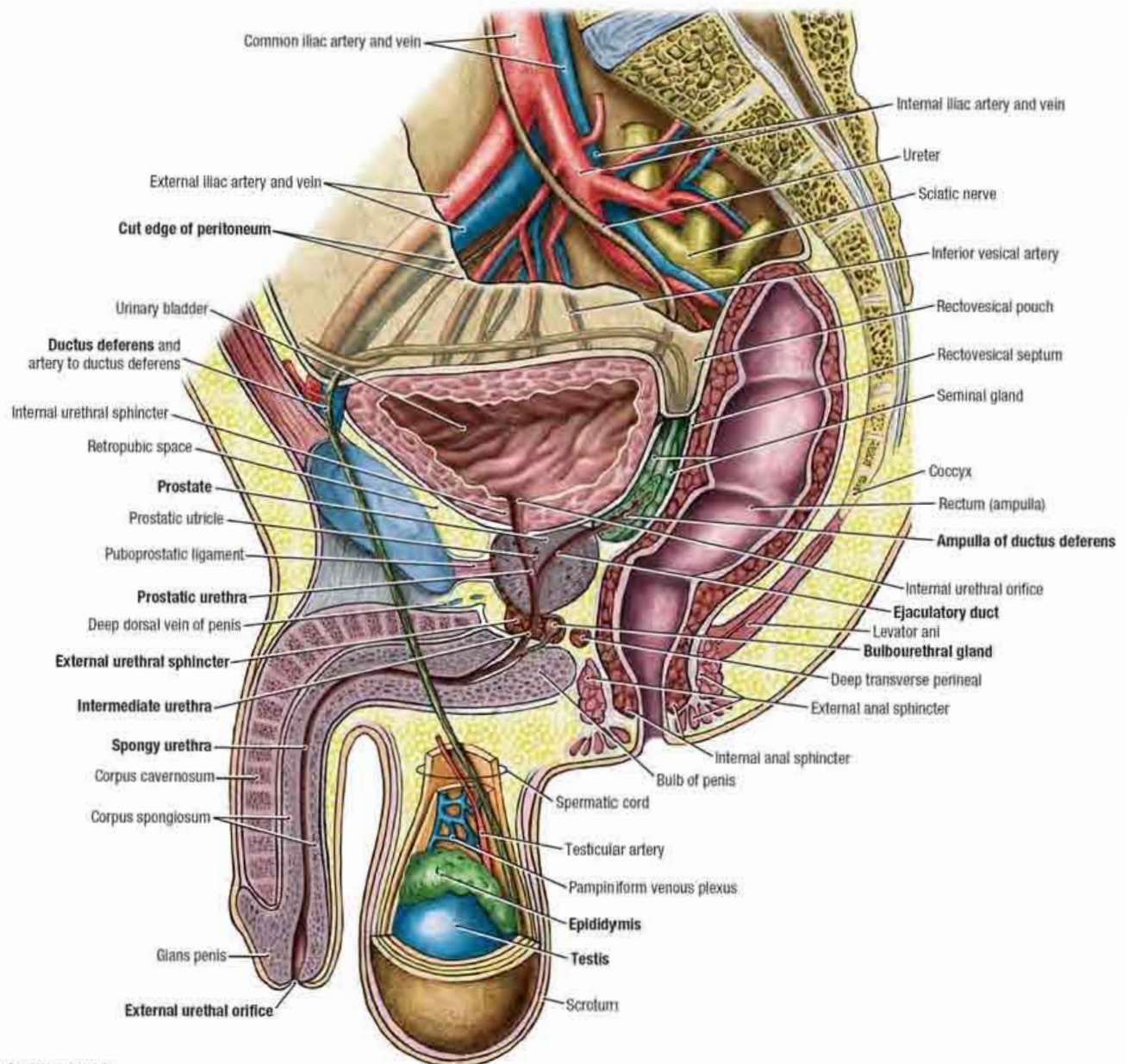
> Table of Contents > Chapter 3 - Pelvis and Perineum > 3.20 Male pelvic organs and external genitalia

---

## 3.20 Male pelvic organs and external genitalia

*Part of* "Chapter 3 - Pelvis and Perineum "

- Most of the pelvic viscera are subperitoneal, embedded in a matrix of fatty endopelvic fascia.
- The genital tract is demonstrated in its entirety; it merges with the urinary tract in the prostatic urethra.



Median Section of Pelvis,  
Stepped Dissection of Testis

Authors: Agur, Anne M.R.; Dalley, Arthur F.

Title: *Grant's Atlas of Anatomy, 12th Edition*

Copyright ©2009 Lippincott Williams & Wilkins

> Table of Contents > Chapter 3 - Pelvis and Perineum > 3.21 Urinary bladder, prostate, and ductus deferens

---

## 3.21 Urinary bladder, prostate, and ductus deferens

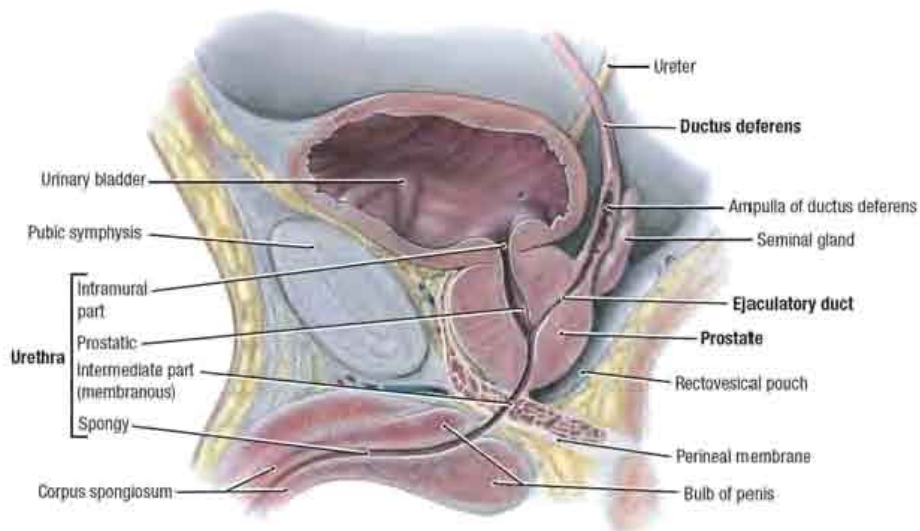
*Part of* "Chapter 3 - Pelvis and Perineum "

A. Dissection. The ejaculatory duct (approximately 2 cm in length) is formed by the union of the ductus deferens and duct of the seminal gland; it passes anteriorly and inferiorly through the substance of the prostate to enter the prostatic urethra on the seminal colliculus. B. Overview of urogenital system, schematic illustration. C. Coronal section through urinary bladder and prostate.

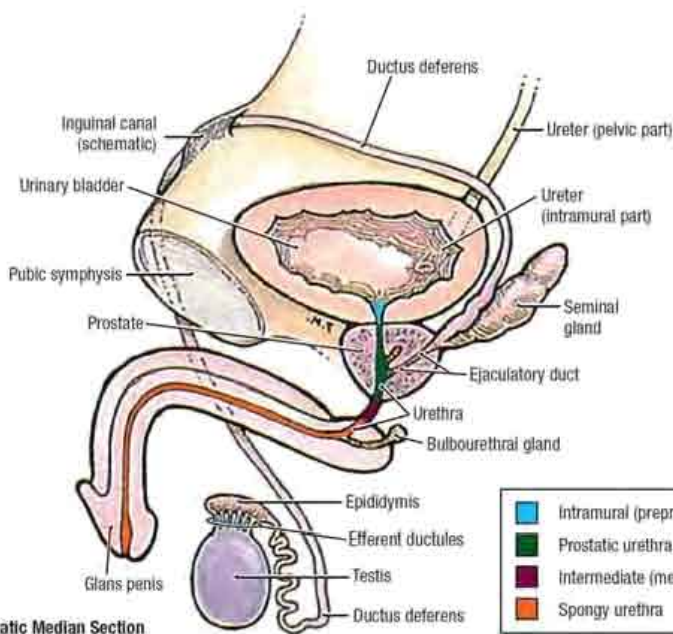
---

P.218

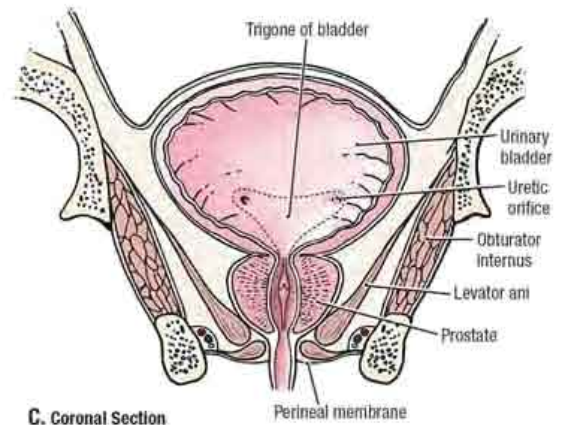




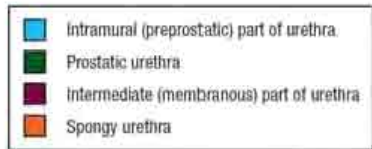
**A. Median Section**



**B. Schematic Median Section**



**C. Coronal Section**





Authors: Agur, Anne M.R.; Dalley, Arthur F.

Title: *Grant's Atlas of Anatomy, 12th Edition*

Copyright ©2009 Lippincott Williams & Wilkins

> Table of Contents > Chapter 3 - Pelvis and Perineum > 3.22 Posterior approach to anterior pelvic and perineal structures and spaces

---

## 3.22 Posterior approach to anterior pelvic and perineal structures and spaces

*Part of "Chapter 3 - Pelvis and Perineum "*

A. Dissection. The rectovesical septum and all pelvic and perineal structures posterior to it have been removed. B. Posterior surface of inferior part of anterior abdominal wall with umbilical folds and ligaments and anterior pelvic viscera. C. Schematic coronal section through the anterior pelvis (plane of urinary bladder and prostate) demonstrating pelvic fascia.

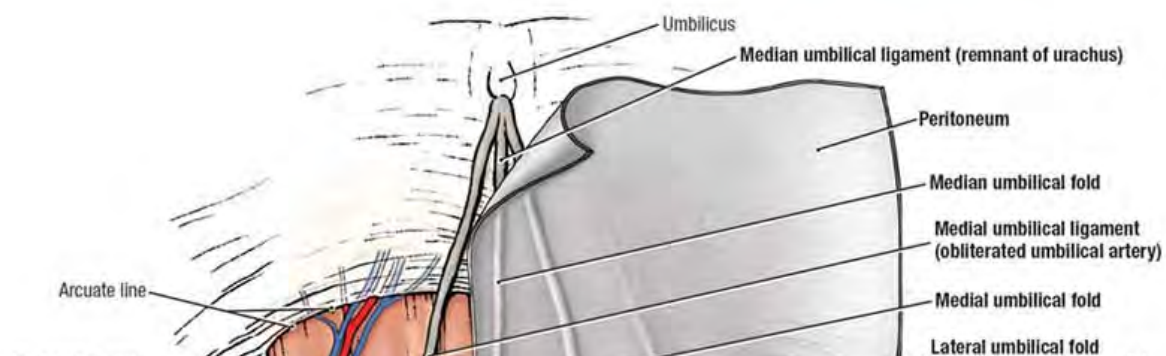
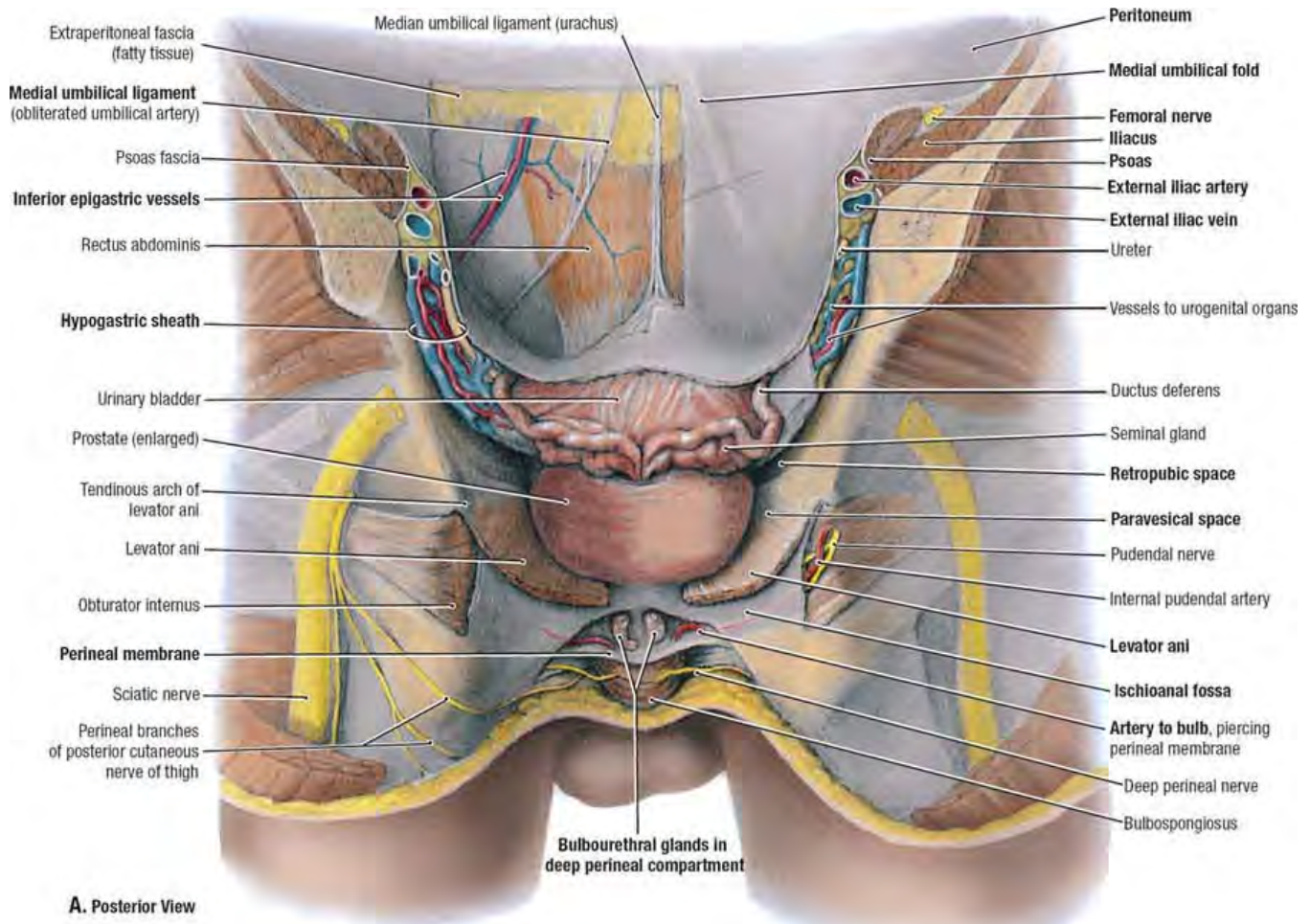
- In A and B , the inferior epigastric artery and accompanying veins enter the rectus sheath, covered posteriorly with peritoneum to form the lateral umbilical fold. The medial umbilical fold is formed by peritoneum overlying the medial umbilical ligament (obliterated umbilical artery), and the median umbilical fold is formed by the median umbilical ligament (urachus).
- In A , the femoral nerve lies between the psoas and iliacus muscles, covered on their internal aspects with psoas (membranous parietal) fascia; the external iliac artery and vein lie within the areolar extraperitoneal fascia.
- The pelvic genitourinary organs are subperitoneal. Near the bladder, the ureter accompanies a "sheath" of internal iliac vessels and derivatives within the fibroareolar hypogastric sheath.
- The levator ani and its fascial coverings separate the retropubic and paravesical spaces of the pelvis from the ischioanal fossae of the perineum. The fat that

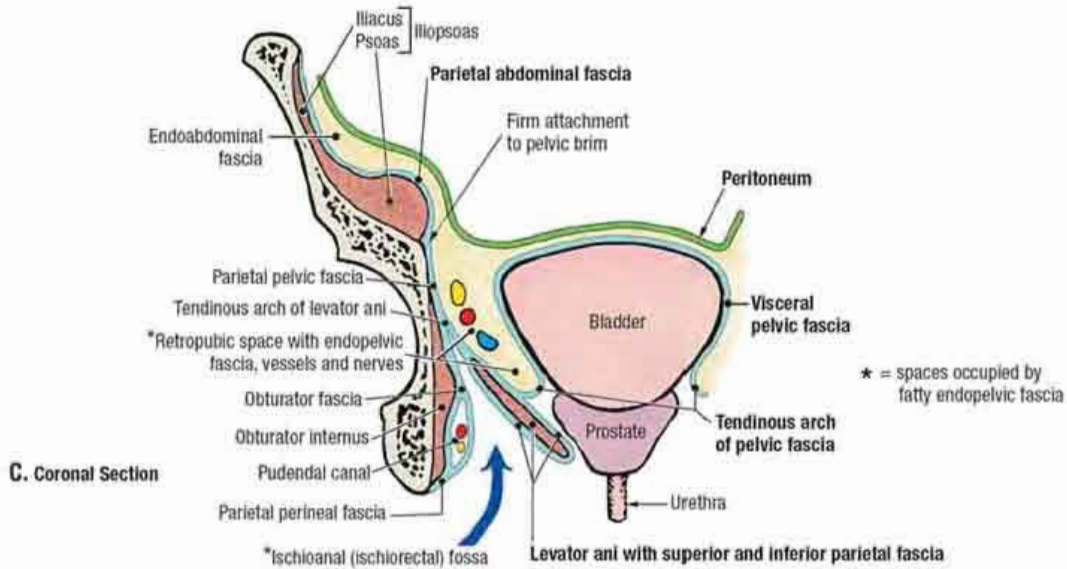
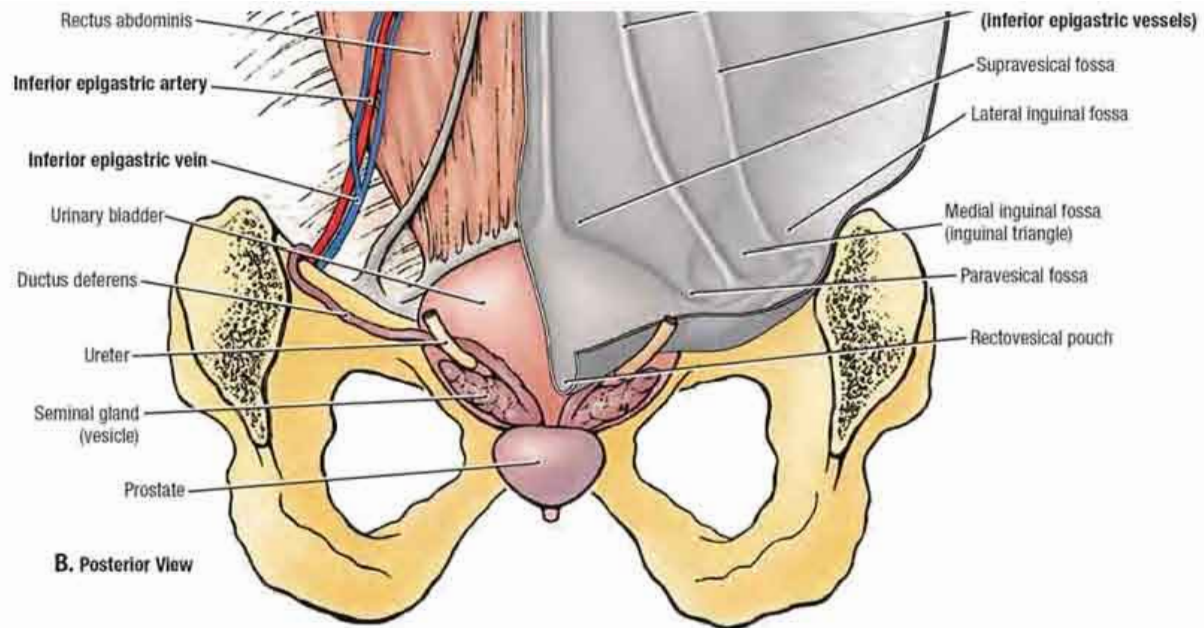
occupies these spaces has been removed.

- The bulbourethral glands and the initial part of the artery to the bulb lie superior to the perineal membrane in the deep perineal compartment.

P.219

P.220





Authors: Agur, Anne M.R.; Dalley, Arthur F.

Title: *Grant's Atlas of Anatomy, 12th Edition*

Copyright ©2009 Lippincott Williams & Wilkins

> Table of Contents > Chapter 3 - Pelvis and Perineum > 3.23 Seminal glands and prostate

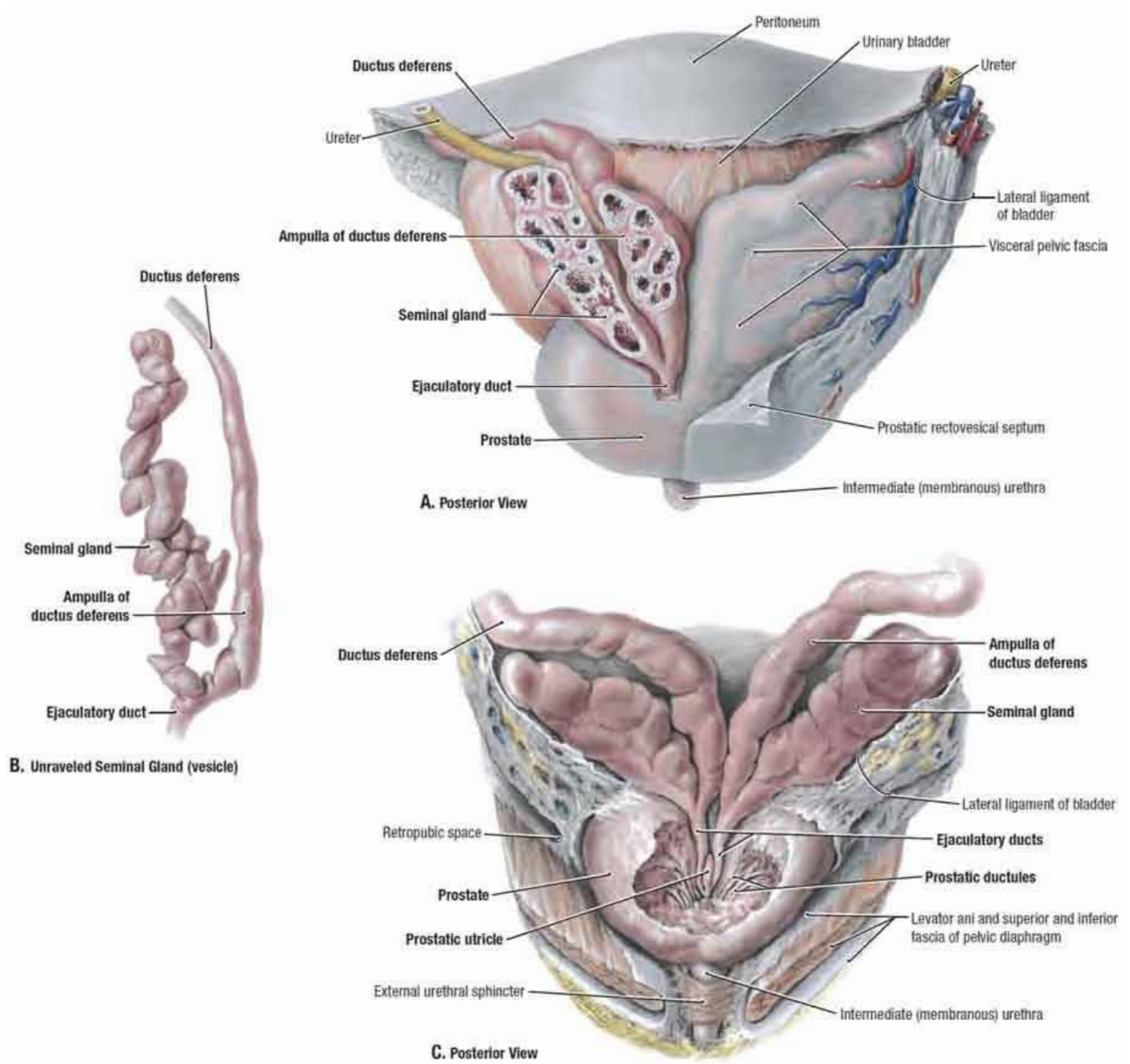
---

## 3.23 Seminal glands and prostate

*Part of* "Chapter 3 - Pelvis and Perineum "

A. Bladder, ductus deferens, seminal glands (vesicles), and prostate. The left seminal gland and ampulla of the ductus deferens are dissected and opened; part of the prostate is cut away to expose the ejaculatory duct. B. Seminal vesicle, unraveled. The vesicle is a tortuous tube with numerous dilatations. The ampulla of the ductus deferens has similar dilatations. C. Prostate, dissected posteriorly. The ejaculatory duct (approximately 2 cm in length) is formed by the union of the ductus deferens and the duct of the seminal gland; it passes anteriorly and inferiorly through the substance of the prostate to enter the prostatic urethra on the seminal colliculus. The prostatic utricle lies between the ends of the two ejaculatory ducts. The prostatic ductules mostly open onto the prostatic sinus.







Authors: Agur, Anne M.R.; Dalley, Arthur F.

Title: *Grant's Atlas of Anatomy, 12th Edition*

Copyright ©2009 Lippincott Williams & Wilkins

> Table of Contents > Chapter 3 - Pelvis and Perineum > 3.24 Interior of male urinary bladder and prostatic urethra

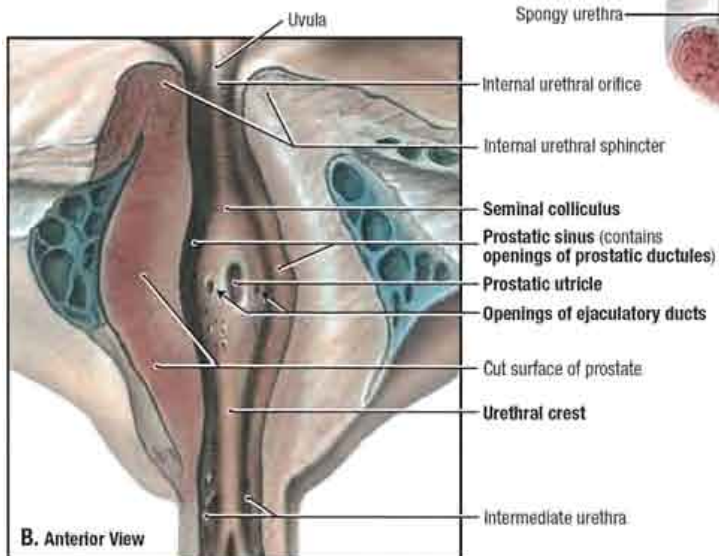
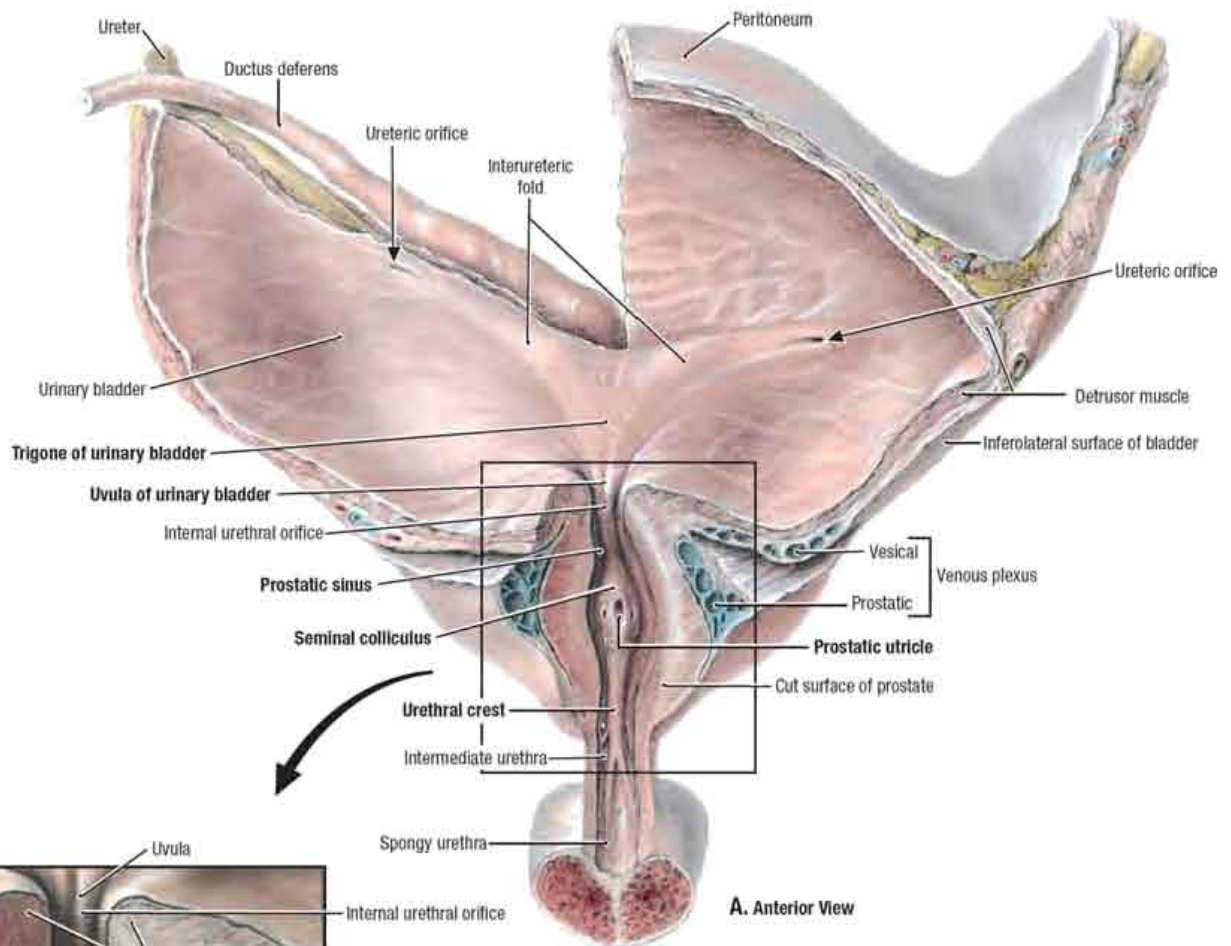
---

## 3.24 Interior of male urinary bladder and prostatic urethra

*Part of* "Chapter 3 - Pelvis and Perineum "

A. Dissection. The anterior walls of the bladder, prostate, and urethra were cut away. B. Features of the prostatic urethra.

- The mucous membrane is smooth over the trigone of the urinary bladder (triangular region demarcated by ureteric and internal urethral orifices) but folded elsewhere, especially when the bladder is empty.
- The opening of the prostatic utricle is in the seminal colliculus on the urethral crest; there is an orifice of an ejaculatory duct on each side of the prostatic utricle. The prostatic fascia encloses a venous plexus.



Authors: Agur, Anne M.R.; Dalley, Arthur F.

Title: *Grant's Atlas of Anatomy, 12th Edition*

Copyright ©2009 Lippincott Williams & Wilkins

> Table of Contents > Chapter 3 - Pelvis and Perineum > 3.25 Male pelvis, transverse sections

---

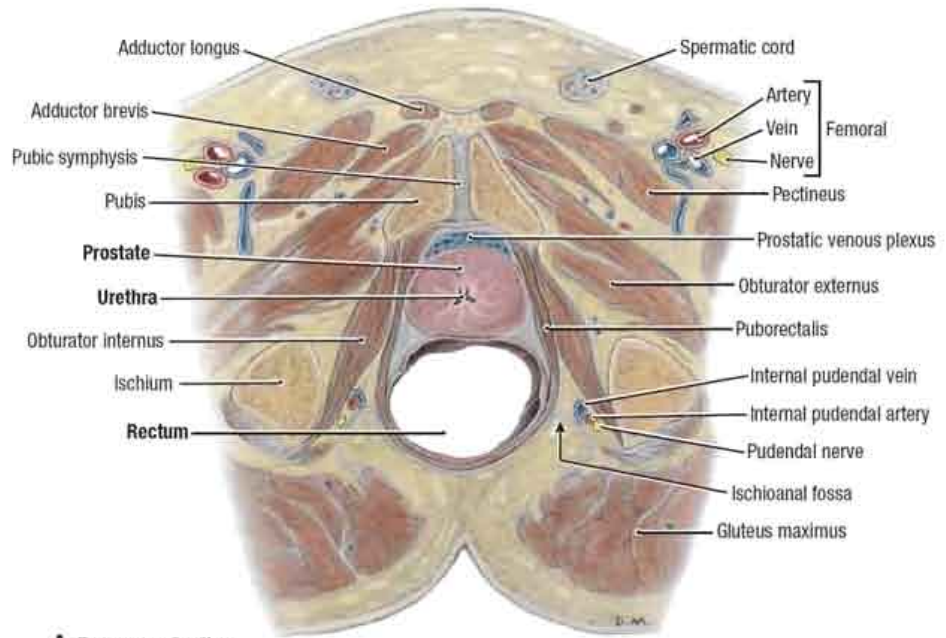
## 3.25 Male pelvis, transverse sections

*Part of* "Chapter 3 - Pelvis and Perineum "

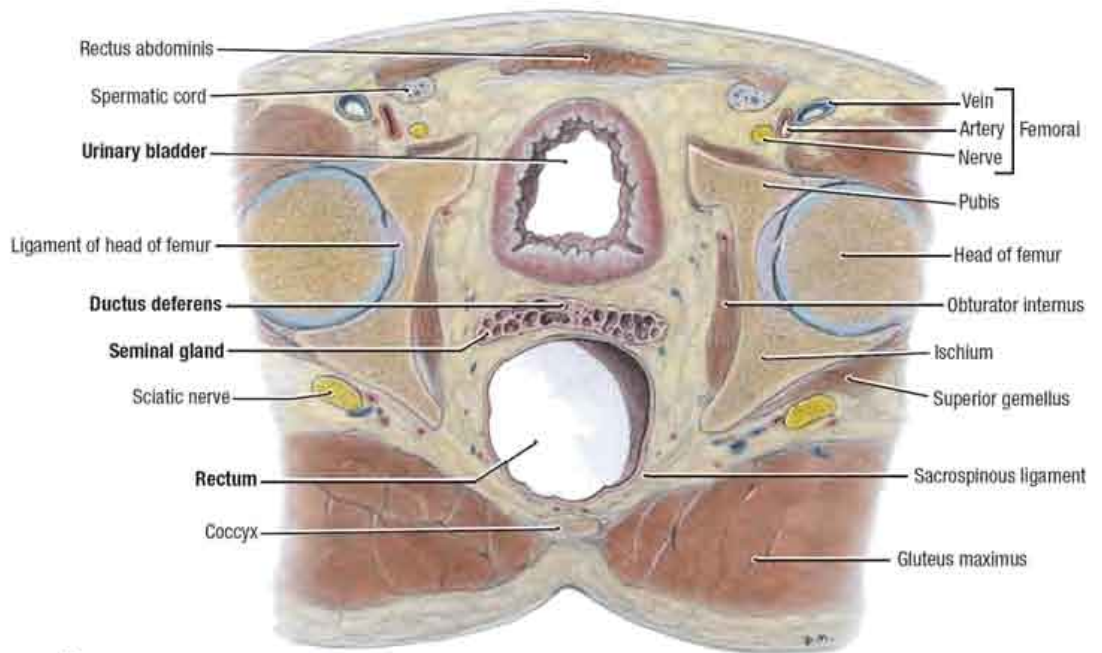
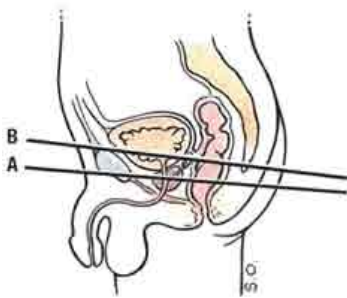
A. Section through prostate and puborectalis. B. Section through urinary bladder and seminal gland.

---

P.223



**A. Transverse Section**



**B. Transverse Section**

Authors: Agur, Anne M.R.; Dalley, Arthur F.

Title: *Grant's Atlas of Anatomy, 12th Edition*

Copyright ©2009 Lippincott Williams & Wilkins

> Table of Contents > Chapter 3 - Pelvis and Perineum > 3.26 Transrectal ultrasound scans of male pelvis

---

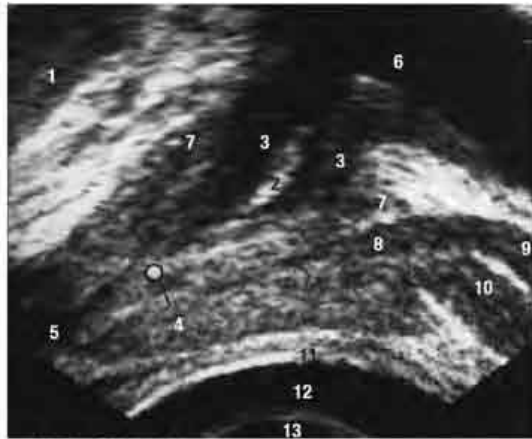
## 3.26 Transrectal ultrasound scans of male pelvis

*Part of "Chapter 3 - Pelvis and Perineum "*

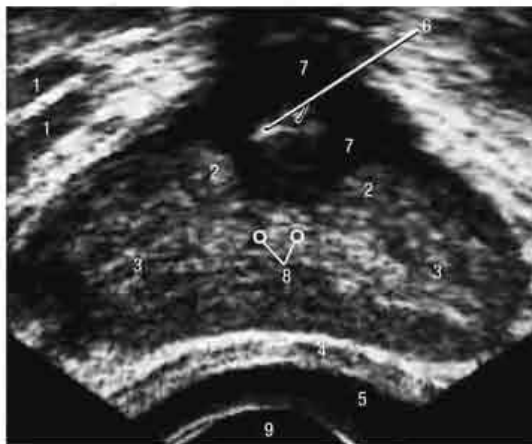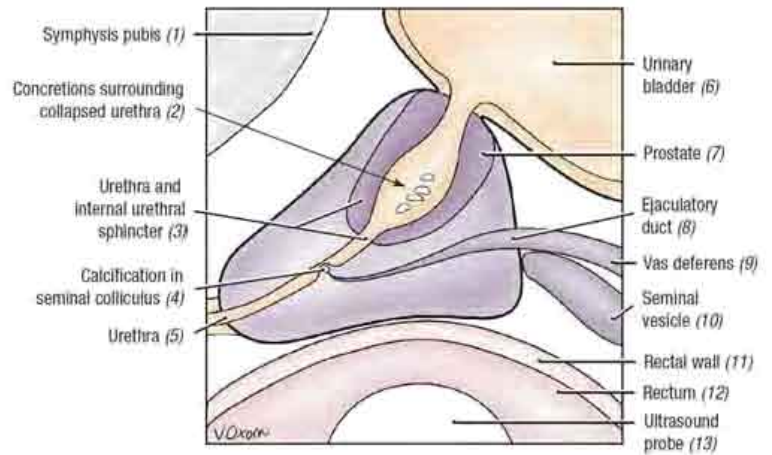
A. In this longitudinal ultrasound scan, the probe was inserted into the rectum to scan the anteriorly located prostate. The ducts of the glands in the peripheral zone open into the prostatic sinuses, whereas the ducts of the glands in the central (internal) zone open into the prostatic sinuses and onto the seminal colliculus. The large peripheral zone (3) is the common site for carcinomas.

B. Normal prostate of young male. C. Benign prostatic hyperplasia. Note the enlarged transition zone (2). The transition zone of the prostate normally starts becoming hyperplastic after age 30. The numbers in parentheses correspond to labels on the ultrasound scan.

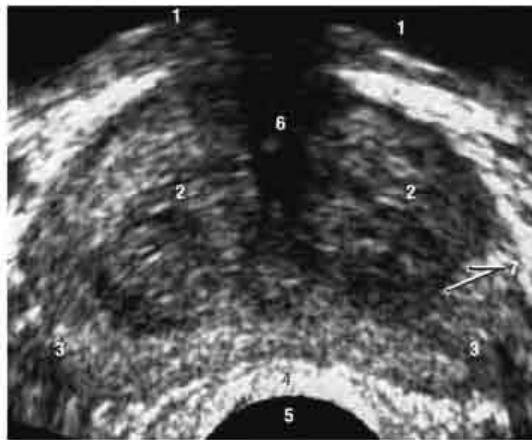
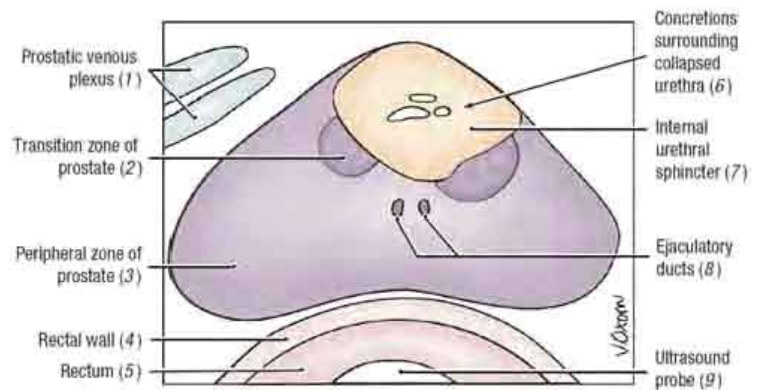




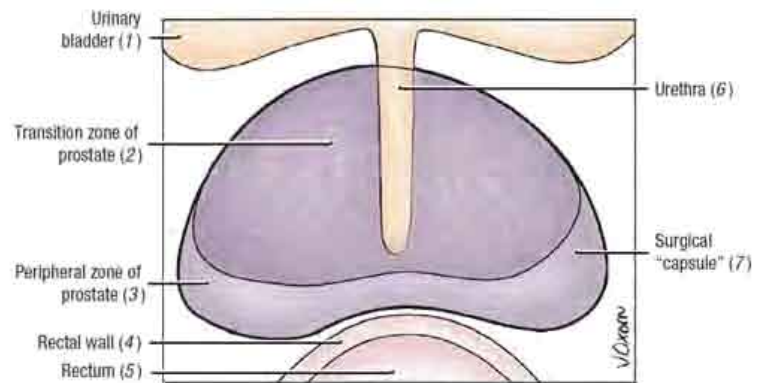
A. Longitudinal (Median) Scan



B. Transverse (Axial) Scan



C. Transverse (Axial) Scan



Authors: Agur, Anne M.R.; Dalley, Arthur F.  
Title: *Grant's Atlas of Anatomy, 12th Edition*  
Copyright ©2009 Lippincott Williams & Wilkins

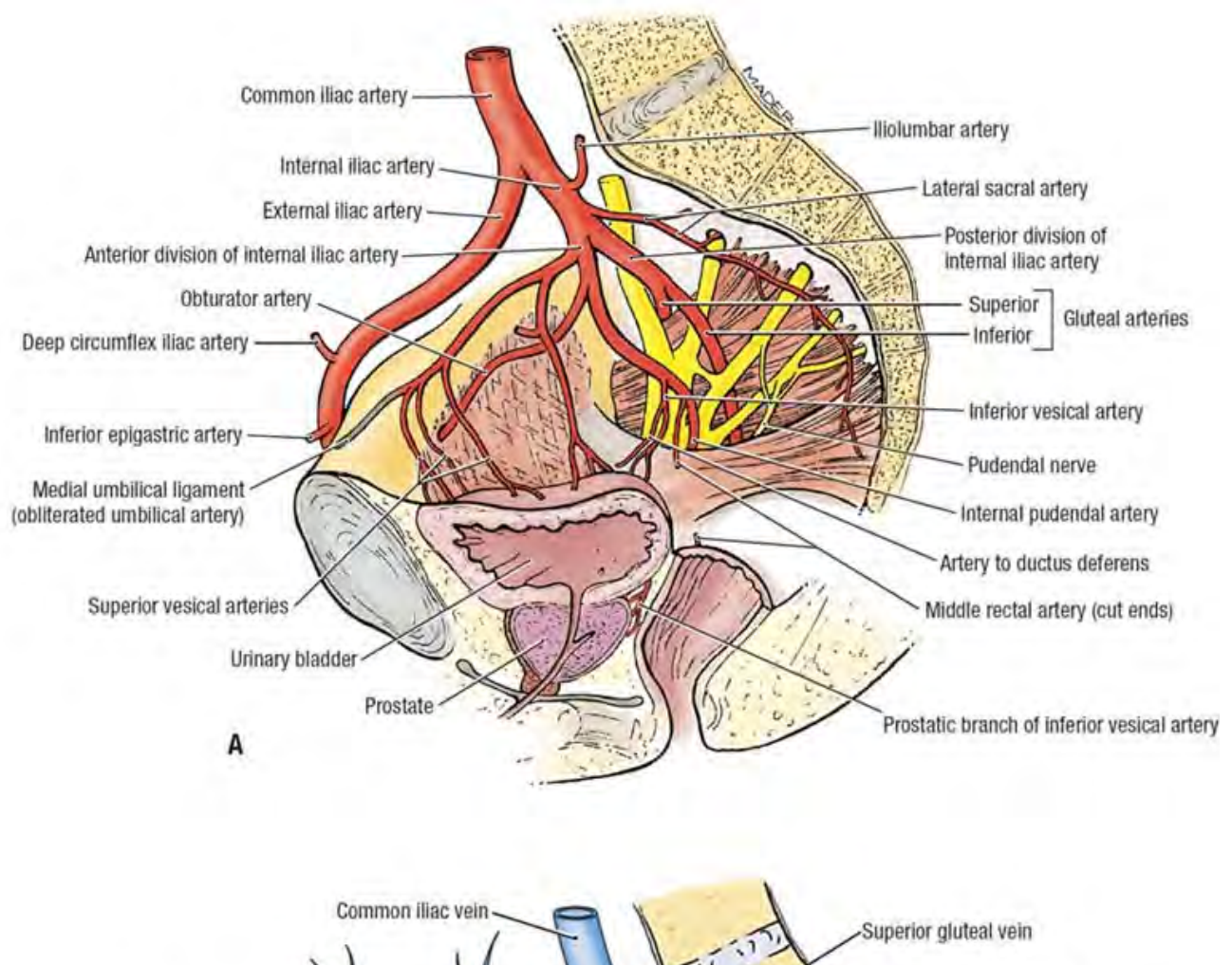
> Table of Contents > Chapter 3 - Pelvis and Perineum > 3.27 Arteries and veins of male pelvis

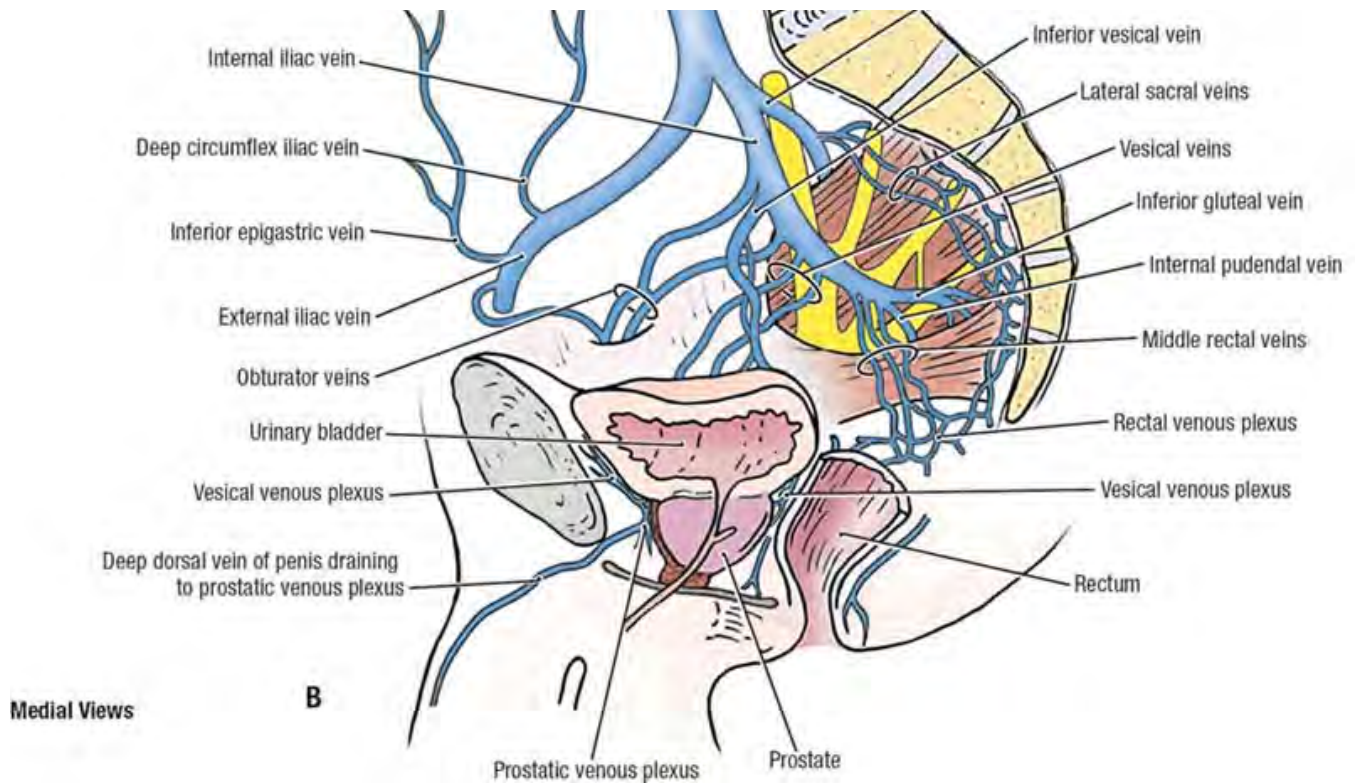
## 3.27 Arteries and veins of male pelvis

Part of "Chapter 3 - Pelvis and Perineum "

A. Arteries. B. Pelvic veins and venous plexuses.

P.225





Internal iliac

Common iliac artery

Passes medially over pelvic brim and descends into pelvic cavity; often forms anterior and posterior divisions

Main blood supply to pelvic organs, gluteal muscles, and perineum

Anterior division of internal iliac

Internal iliac artery

Passes laterally along lateral wall of pelvis, dividing into visceral, obturator, and internal pudendal arteries

Pelvic viscera, perineum, and muscles of superior medial thigh

Umbilical

Anterior division of internal iliac artery

Short pelvic course; gives off superior vesical arteries, then obliterates, becoming medial umbilical ligament

Urinary bladder and, in some males, ductus deferens

Superior vesical

Patent part of umbilical artery

Usually multiple; pass to superior aspect of urinary bladder



Superior aspect of urinary bladder and distal ureter

Artery to ductus deferens

Superior or inferior vesical artery

Runs subperitoneally to ductus deferens

Ductus deferens

Obturator

Anterior division of internal iliac artery

Runs anteroinferiorly on lateral pelvic wall

Pelvic muscles, nutrient artery to ilium, head of femur and medial compartment of thigh

Inferior vesical

Passes subperitoneally giving rise to prostatic artery and occasionally the artery to the ductus deferens

Inferior aspect of urinary bladder, pelvic ureter, seminal glands, and prostate

Middle rectal

Descends in pelvis to rectum

Seminal glands, prostate, and inferior part of rectum

Internal pudendal

Exits pelvis through greater sciatic foramen and enters perineum via lesser sciatic foramen

Main artery to perineum, including muscles and skin of anal and urogenital triangles; erectile bodies

Posterior division of internal iliac artery

Internal iliac artery

Passes posteriorly and gives rise to parietal branches

Pelvic wall and gluteal region

Iliolumbar

Posterior division of internal iliac artery

Ascends anterior to sacroiliac joint and posterior to common iliac vessels and psoas major Iliacus, psoas major, quadratus lumborum muscles, and cauda equina in vertebral canal

Lateral sacral (superior and inferior)

Run on anteromedial aspect of piriformis to send branches into pelvic sacral foramina

Piriformis muscle, structures in sacral canal and erector spinae muscles

Testicular (gonadal) [see Fig. 3.28A ]

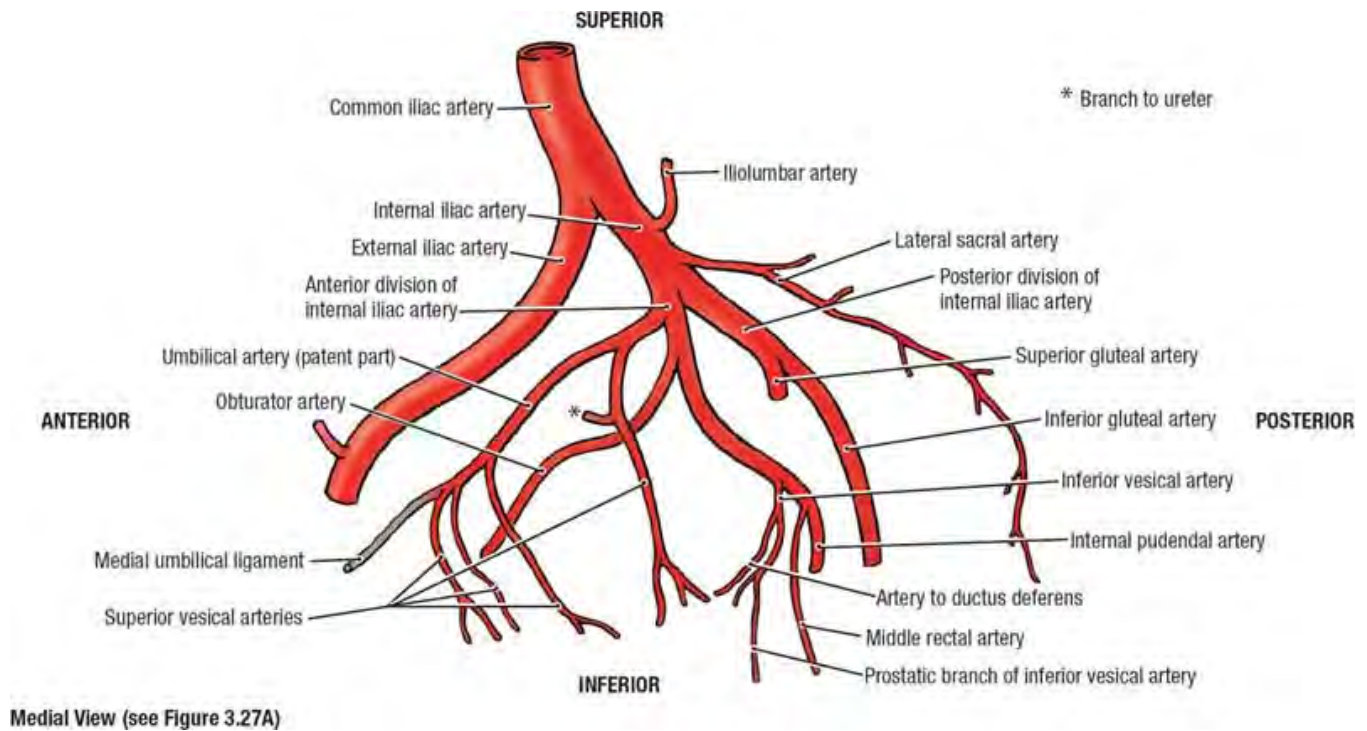
Abdominal aorta

Descends retroperitoneally; traverses inguinal canal and enters scrotum  
 Abdominal ureter, testis and epididymis

Artery    Origin    Course    Distribution

Table 3.4 Arteries of Male Pelvis

P.226





Authors: Agur, Anne M.R.; Dalley, Arthur F.

Title: *Grant's Atlas of Anatomy, 12th Edition*

Copyright ©2009 Lippincott Williams & Wilkins

> Table of Contents > Chapter 3 - Pelvis and Perineum > 3.28 Pelvic vessels in situ; lateral pelvic wall

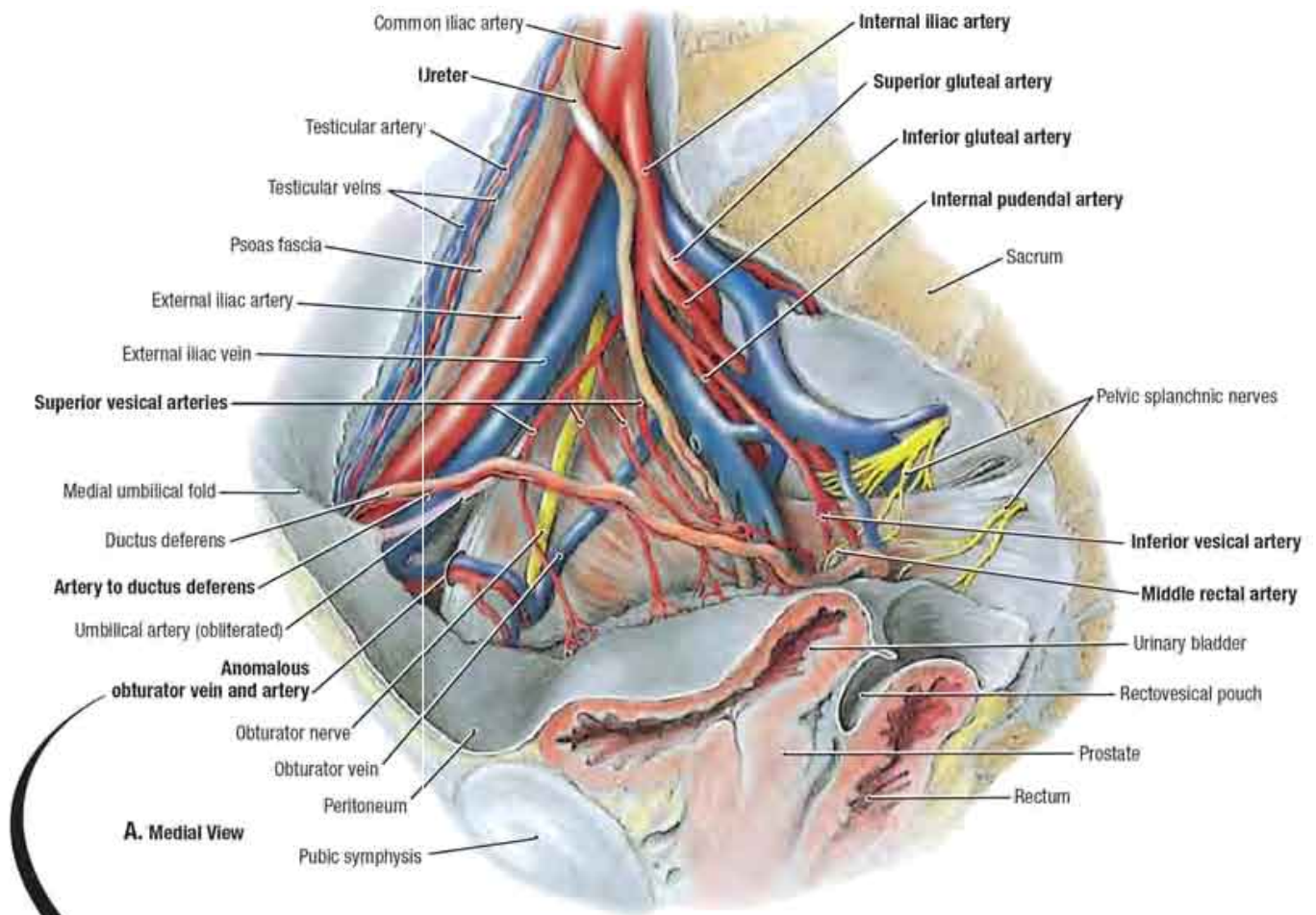
---

## 3.28 Pelvic vessels in situ; lateral pelvic wall

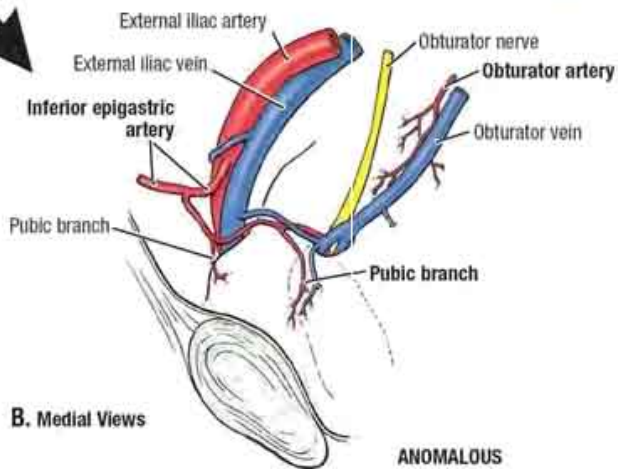
*Part of* "Chapter 3 - Pelvis and Perineum "

A. Dissection. B. Usual and anomalous obturator arteries.

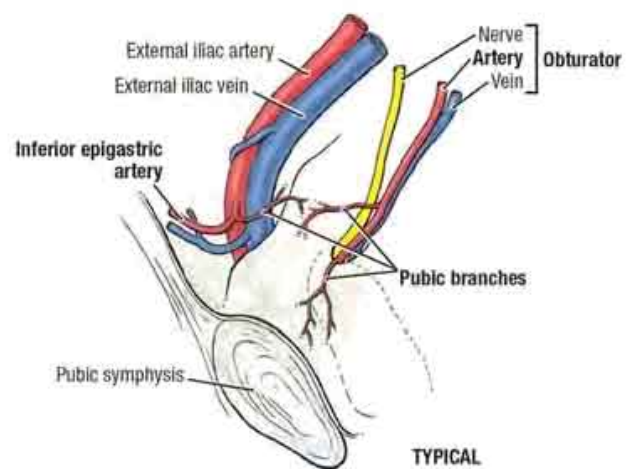
- The ureter crosses the external iliac artery at its origin (common iliac bifurcation), and the ductus deferens crosses the external iliac artery at its termination (deep inguinal ring).
- In this specimen, an anomalous (replaced) obturator artery branches from the inferior epigastric artery (B) .



**A. Medial View**



**B. Medial Views**



Authors: Agur, Anne M.R.; Dalley, Arthur F.

Title: *Grant's Atlas of Anatomy, 12th Edition*

Copyright ©2009 Lippincott Williams & Wilkins

> Table of Contents > Chapter 3 - Pelvis and Perineum > 3.29 Portal-systemic anastomoses

---

## 3.29 Portal-systemic anastomoses

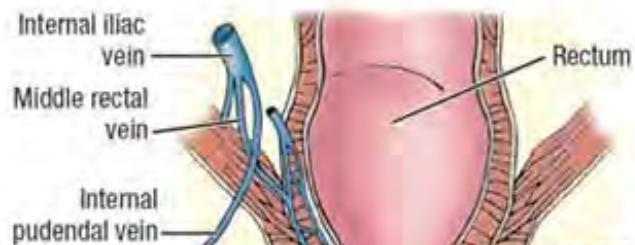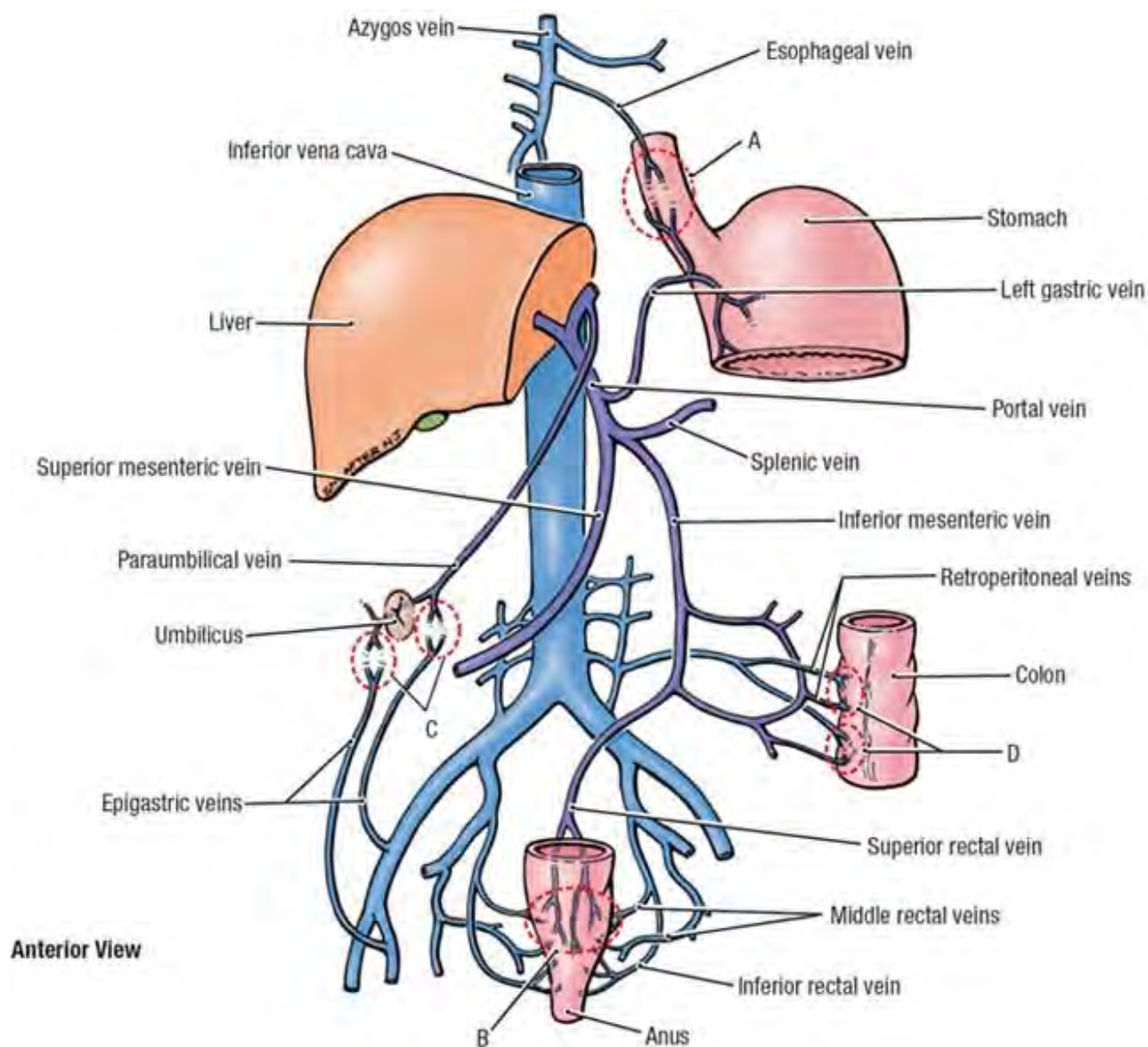
Part of "Chapter 3 - Pelvis and Perineum "

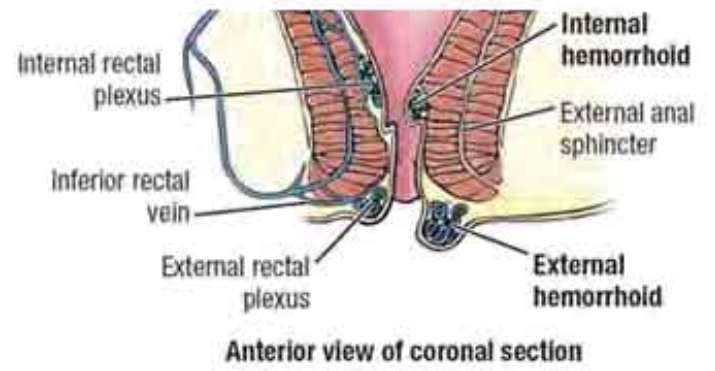
The portal tributaries are *purple*, and systemic tributaries are *blue*. A-D indicate sites of portal systemic anastomoses. *A*, between portal and systemic esophageal veins; *B*, between portal and systemic rectal veins; *C*, paraumbilical veins (portal) anastomosing with small epigastric veins of the anterior abdominal wall (systemic); *D*, twigs of colic veins (portal) anastomosing with retroperitoneal veins (systemic).

Internal hemorrhoids (piles) are prolapses of rectal mucosa containing the normally dilated veins of the *internal rectal venous plexus*. Internal hemorrhoids are thought to result from a breakdown of the muscularis mucosae, a smooth muscle layer deep to the mucosa (see figure at right). Internal hemorrhoids that prolapse through the anal canal are often compressed by the contracted sphincters, impeding blood flow. As a result, they tend to strangulate, ulcerate, and bleed.

External hemorrhoids are thromboses (blood clots) in the veins of the *external rectal venous plexus* and are covered by skin. Predisposing factors for hemorrhoids include pregnancy, chronic constipation, and any disorder that impedes venous return. The superior rectal vein drains into the inferior mesenteric vein, whereas the middle and inferior rectal veins drain through the systemic system into the inferior vena cava. Any abnormal increase in pressure in the valveless portal system or veins of the trunk may cause enlargement of the superior rectal veins, resulting in an increase in blood flow or stasis in the internal rectal venous plexus. In *portal hypertension* that occurs in relation to *hepatic cirrhosis*, the portocaval anastomosis (e.g., esophageal) may become varicose and rupture.

---







Authors: Agur, Anne M.R.; Dalley, Arthur F.

Title: *Grant's Atlas of Anatomy, 12th Edition*

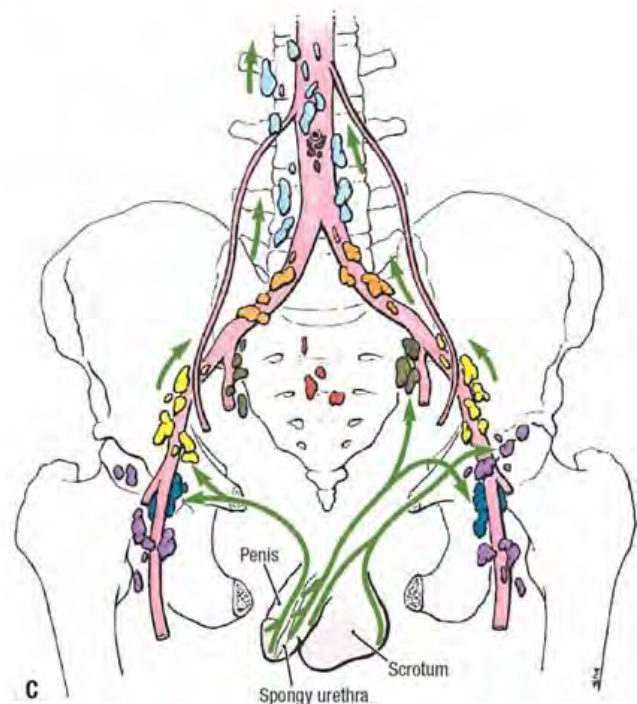
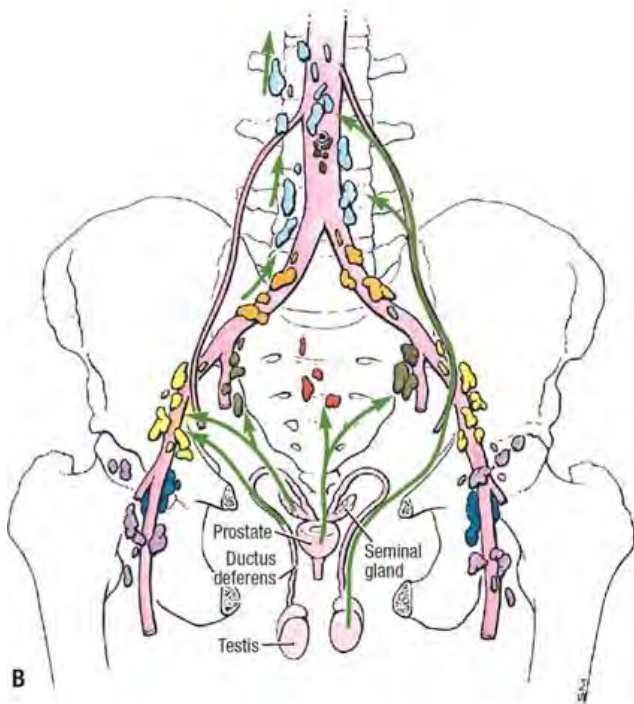
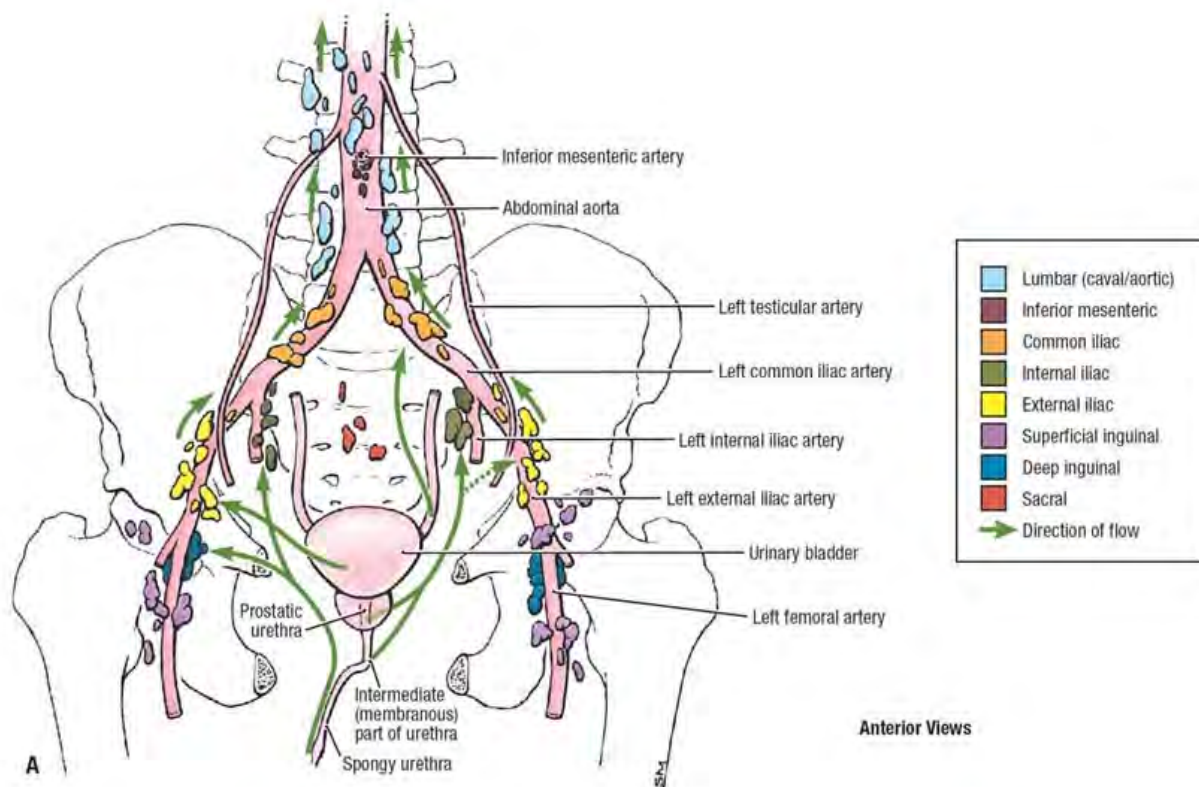
Copyright ©2009 Lippincott Williams & Wilkins

> Table of Contents > Chapter 3 - Pelvis and Perineum > 3.30 Lymphatic drainage of male pelvis and perineum

---

## 3.30 Lymphatic drainage of male pelvis and perineum

*Part of* "Chapter 3 - Pelvis and Perineum "



Lumbar

Gonads and associated structures (including testicular vessels), urethra, testis,

epididymis, common iliac nodes

Inferior mesenteric nodes

Superiormost rectum, sigmoid colon, descending colon, pararectal nodes

Common iliac nodes

External and internal iliac lymph nodes

Internal iliac nodes

Inferior pelvic structures, deep perineal structures, sacral nodes, prostatic urethra, prostate, base of bladder, inferior part of pelvic ureter, inferior part of seminal glands, cavernous bodies, anal canal (above pectinate line), inferior rectum

External iliac nodes

Anterosuperior pelvic structures, deep inguinal nodes, superior aspect of bladder, superior part of pelvic ureter, upper part of seminal gland, pelvic part of ductus deferens, intermediate and spongy urethra

Superficial inguinal nodes

Lower limb, superficial drainage of inferolateral quadrant of trunk, including anterior abdominal wall inferior to umbilicus, gluteal region, superficial perineal structures, skin of perineum including skin and prepuce of penis, scrotum, perianal skin, anal canal inferior to pectinate line

Deep inguinal nodes

Glans of penis, distal spongy urethra, superficial inguinal nodes

Sacral nodes

Posteroinferior pelvic structures, inferior rectum

Pararectal nodes

Superior rectum

Lymph Node Group   Structures Typically Draining to Lymph Node Group

### Table 3.5 Lymphatic Drainage of the Male Pelvis and Perineum

P.230

Urinary tract

Vasoconstriction of renal vessels slows urine formation; internal sphincter of male bladder contracted to prevent retrograde ejaculation and maintain urinary continence

Inhibits contraction of internal sphincter of bladder in males; contracts detrusor muscle of the bladder wall causing urination

#### Genital system

Causes ejaculation and vasoconstriction resulting in remission of erection

Produces engorgement (erection) of erectile tissues of the external genitals

#### Rectum

Maintains tonus of internal anal sphincter; inhibits peristalsis of rectum

Rectal contraction (peristalsis) for defecation; inhibition of contraction of internal anal sphincter

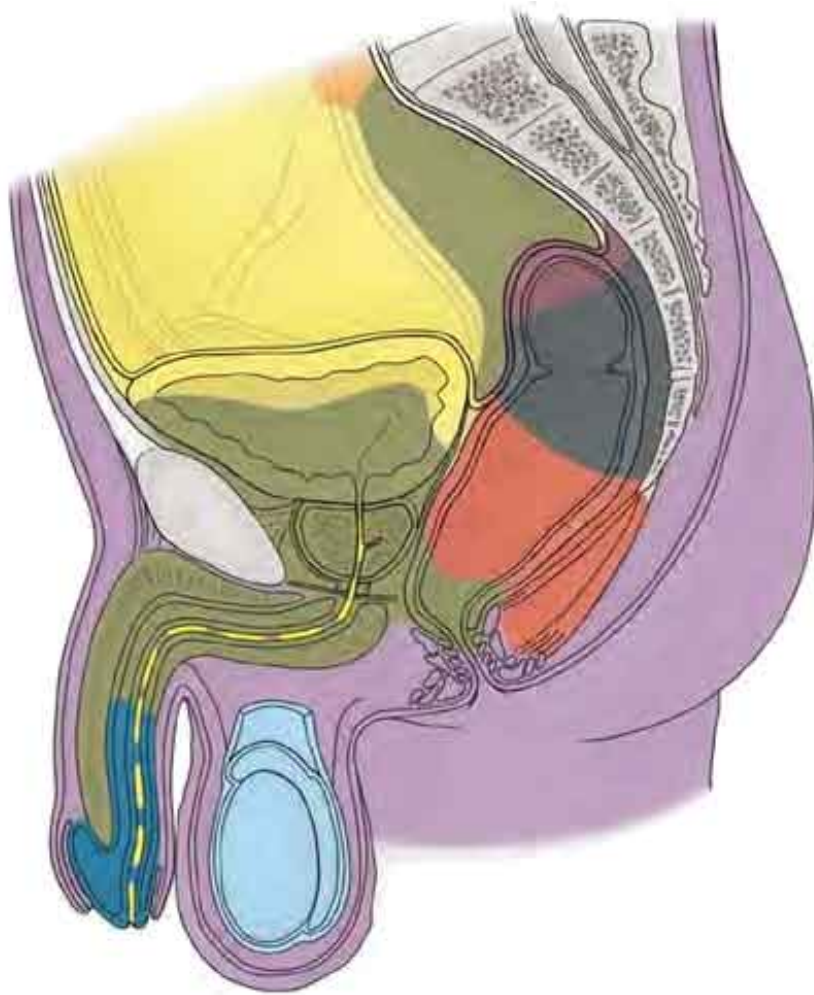
The parasympathetic system is restricted in its distribution to the head, neck, and body cavities (except for erectile tissues of genitalia); otherwise, parasympathetic fibers are never found in the body wall and limbs. Sympathetic fibers, by comparison, are distributed to all vascularized portions of the body.

Organ, Tract, or  
System

Effect of Sympathetic  
Stimulation

Effect of Parasympathetic  
Stimulation

Table 3.6 Effect of Sympathetic and Parasympathetic Stimulation on the Urinary Tract, Genital System, and Rectum



**Lymph nodes:**

-  Lumbar (caval/aortic)
-  Inferior mesenteric
-  Common iliac
-  Internal iliac
-  External iliac
-  Superficial inguinal
-  Deep inguinal
-  Sacral
-  Pararectal



Authors: Agur, Anne M.R.; Dalley, Arthur F.

Title: *Grant's Atlas of Anatomy, 12th Edition*

Copyright ©2009 Lippincott Williams & Wilkins

> Table of Contents > Chapter 3 - Pelvis and Perineum > 3.31 Innervation of male pelvis and perineum

---

## 3.31 Innervation of male pelvis and perineum

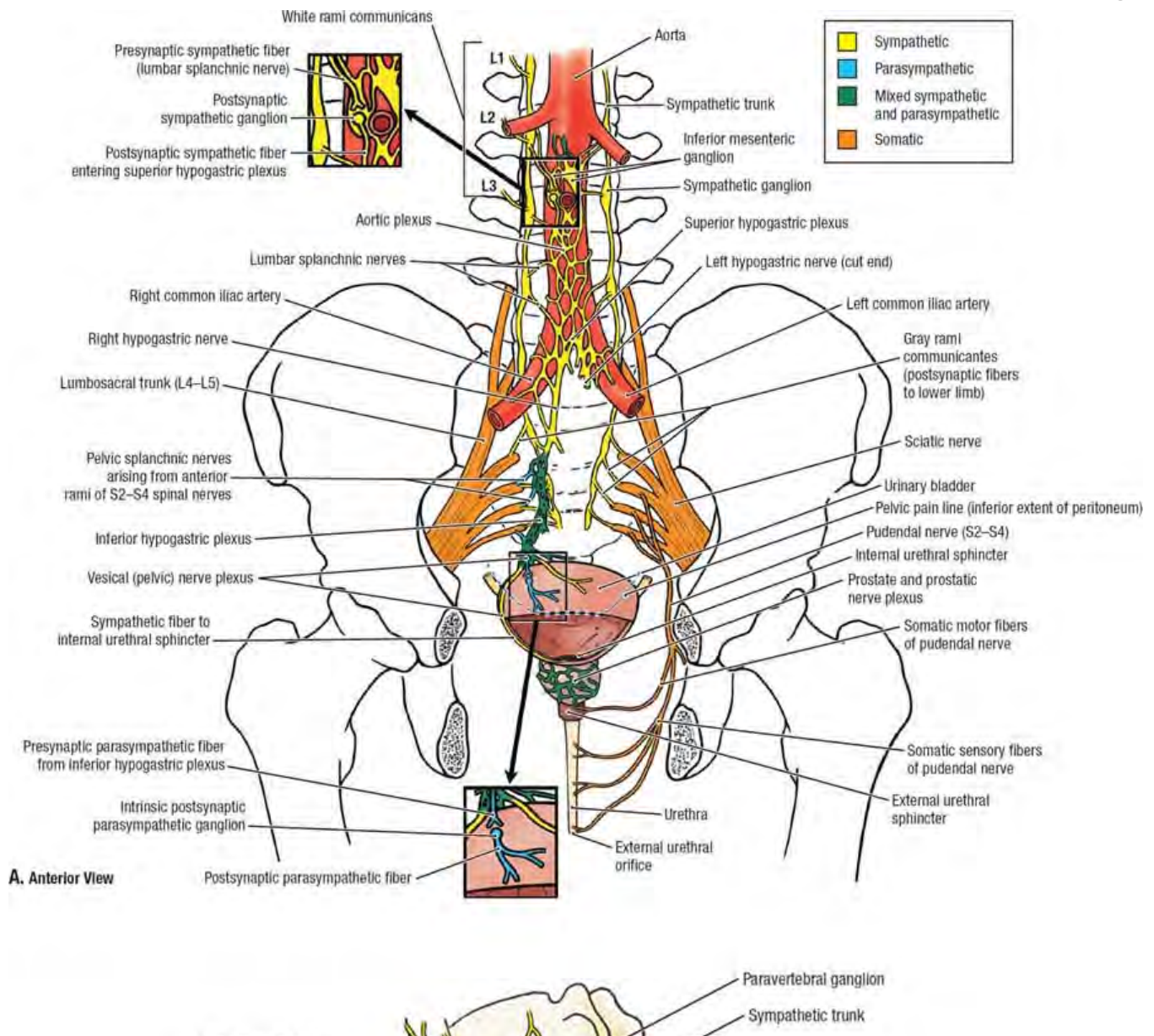
*Part of* "Chapter 3 - Pelvis and Perineum "

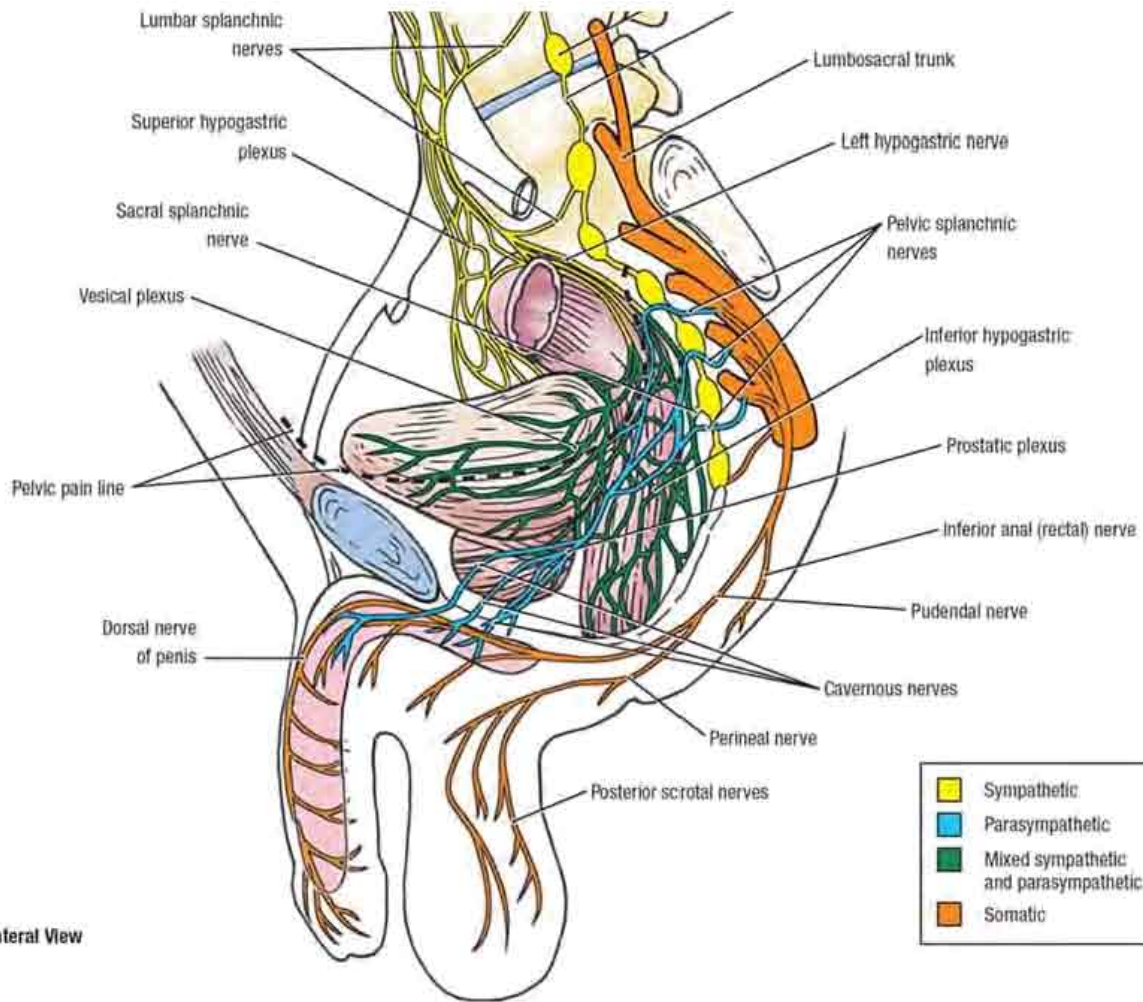
A. Overview. B. Innervation of prostate and external genitalia.

- The primary function of the sacral sympathetic trunks is to provide postsynaptic fibers to the sacral plexus for sympathetic innervation of the lower limb.
- The periarterial plexuses of the ovarian, superior rectal, and internal iliac arteries are minor routes by which sympathetic fibers enter the pelvis. Their primary function is vasomotion of the arteries they accompany.
- The hypogastric plexuses (superior and inferior) are networks of sympathetic and visceral afferent nerve fibers.
- The superior hypogastric plexus carries fibers conveyed to and from the aortic (intermesenteric) plexus by the L3 and L4 splanchnic nerves. The superior hypogastric plexus divides into right and left hypogastric nerves that merge with the parasympathetic pelvic splanchnic nerves to form the inferior hypogastric plexuses.
- The fibers of the inferior hypogastric plexuses continue to the pelvic viscera upon which they form pelvic plexuses, e.g., prostatic nerve plexus.
- The pelvic splanchnic nerves convey presynaptic parasympathetic fibers from the S2–S4 spinal cord segments, which make up the sacral outflow of the parasympathetic system.

- Visceral afferents conveying unconscious reflex sensation follow the course of the parasympathetic fibers retrogradely to the spinal sensory ganglia of S2–S4, as do those transmitting pain sensations from the viscera inferior to the pelvic pain line (structures that do not contact the peritoneum plus the distal sigmoid colon and rectum). Visceral afferent fibers conducting pain from structures superior to the pelvic pain line (structures in contact with the peritoneum, except for the distal sigmoid colon and rectum) follow the sympathetic fibers retrogradely to inferior thoracic and superior lumbar spinal ganglia.

P.232





## 3.32 Female pelvic organs in situ

*Part of "Chapter 3 - Pelvis and Perineum"*

A. Median section. The uterus is bent on itself (anteflexed) at the junction of its body and the cervix; the cervix, opening on the anterior wall of the vagina, has a short, round, anterior lip and a long, thin, posterior lip. B. Hysterectomy (excision of the uterus) is performed through the lower anterior abdominal wall or through the vagina. Because the uterine artery crosses superior to the ureter near the lateral fornix of the vagina, the ureter is in danger of being inadvertently clamped or severed when the uterine artery is tied off during a hysterectomy.

---

P.233

C. True pelvis with peritoneum intact, viewed from above. The uterus is usually asymmetrically placed. The round ligament of the female takes the same subperitoneal course as the ductus deferens of the male.

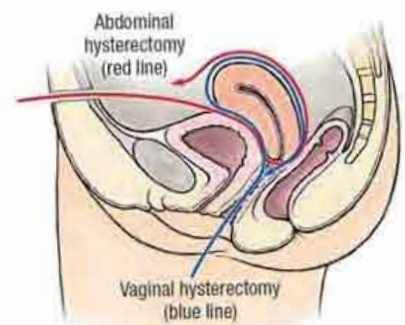
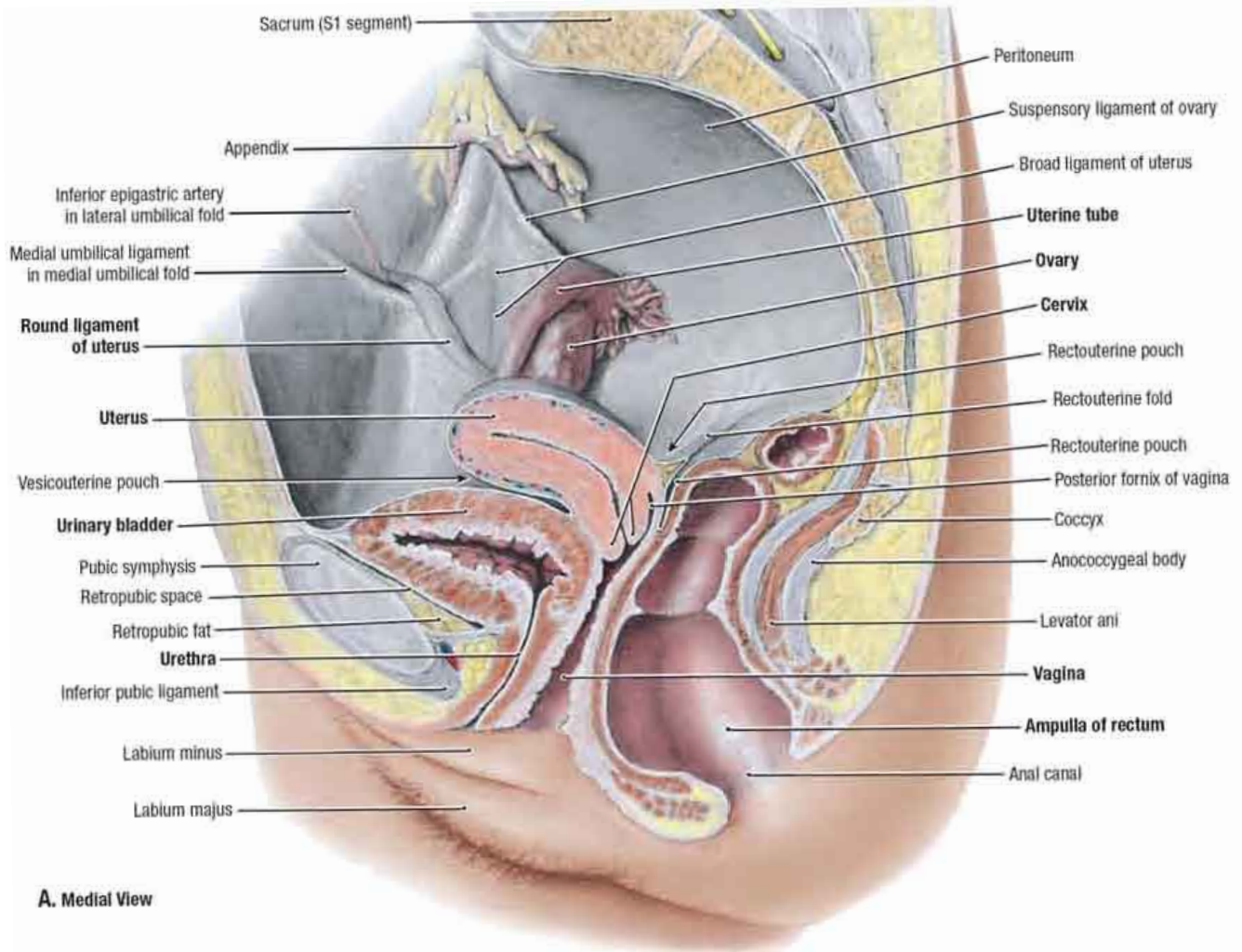
D. Laparoscopy involves inserting a laparoscope into the peritoneal cavity through a small incision below the umbilicus. Insufflation of inert gas creates a pneumoperitoneum to provide space to visualize the pelvic organs. Additional openings (ports) can be made to introduce other instruments for manipulation or to enable therapeutic procedures (e.g., ligation of the uterine tubes).

---

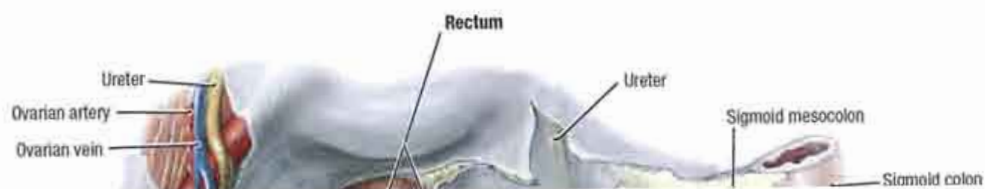P.234



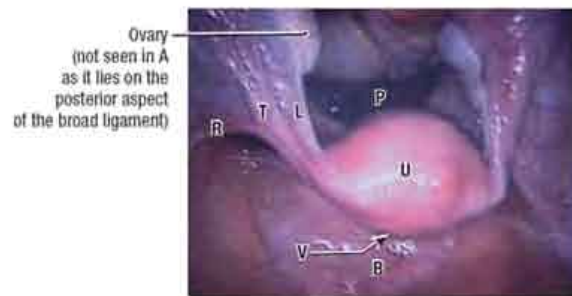
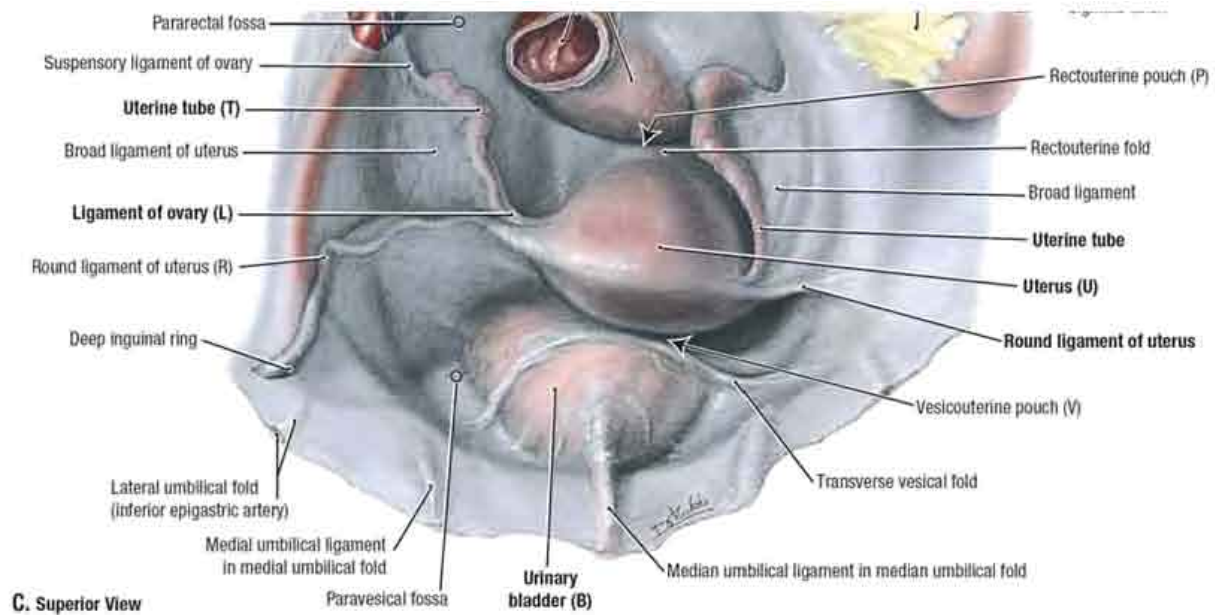




**B. Medial View**







**D. Laparoscopic View of Normal Pelvis**

Authors: Agur, Anne M.R.; Dalley, Arthur F.

Title: *Grant's Atlas of Anatomy, 12th Edition*

Copyright ©2009 Lippincott Williams & Wilkins

> Table of Contents > Chapter 3 - Pelvis and Perineum > 3.33 Female genital organs

---

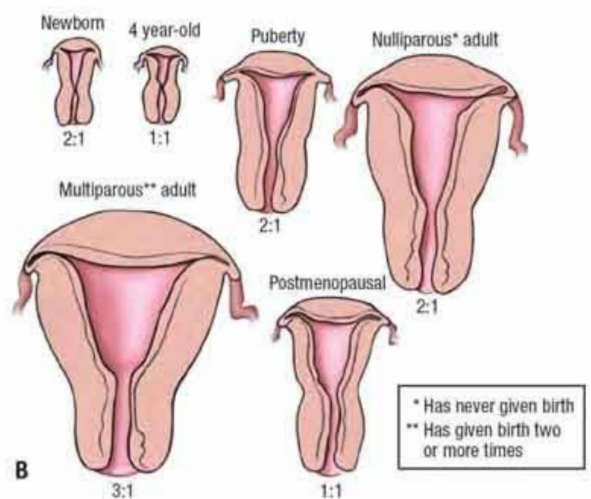
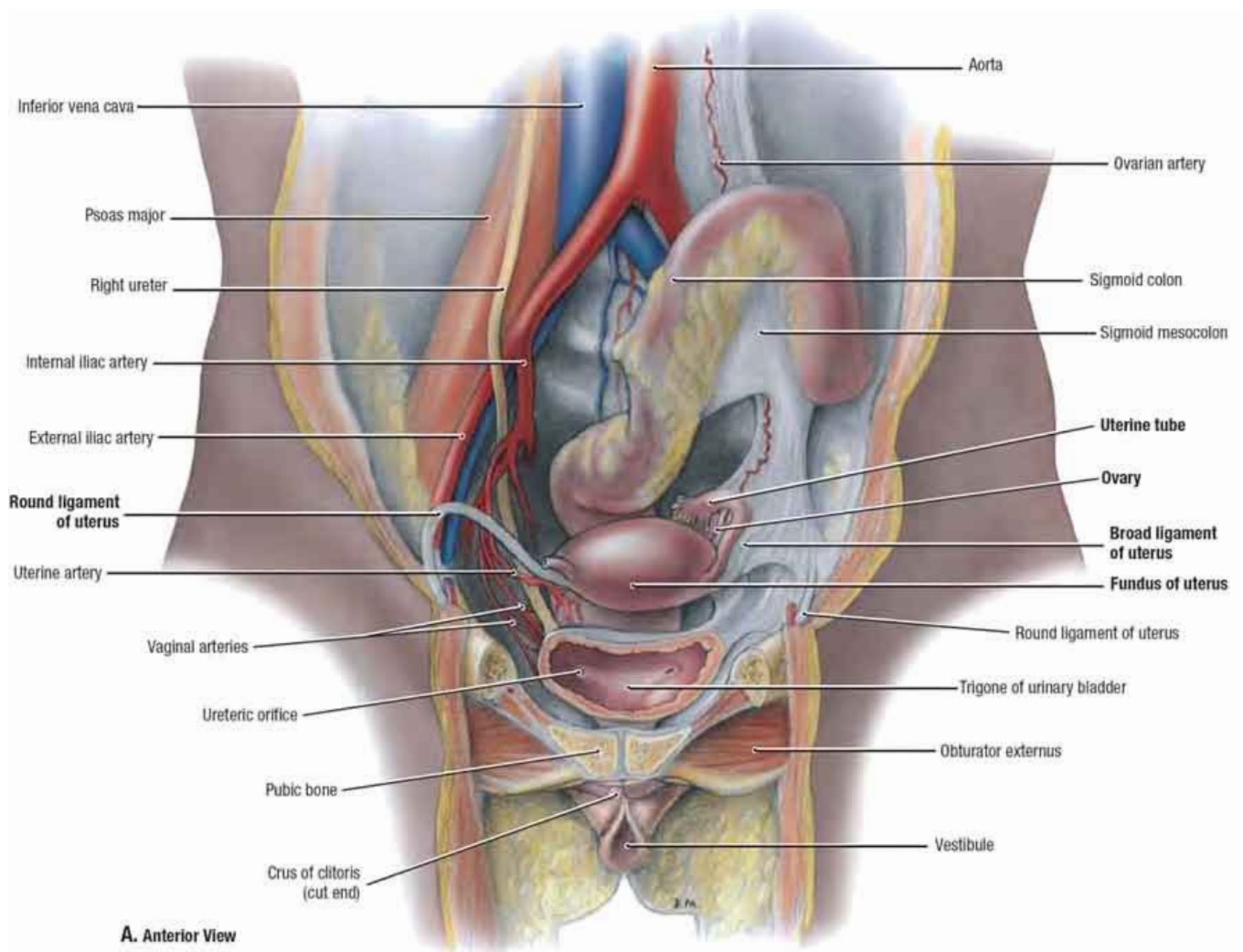
## 3.33 Female genital organs

*Part of "Chapter 3 - Pelvis and Perineum "*

A. Dissection. Part of the pubic bones, the anterior aspect of the bladder, and "on the specimen's right side" the uterine tube, ovary, broad ligament, and peritoneum covering the lateral wall of the pelvis have been removed. B. Lifetime changes in uterine size and proportion (body to cervical ratio, e.g., 2:1). All these stages represent normal anatomy for the particular age and reproductive status of the woman.

---

P.235



Authors: Agur, Anne M.R.; Dalley, Arthur F.

Title: *Grant's Atlas of Anatomy, 12th Edition*

Copyright ©2009 Lippincott Williams & Wilkins

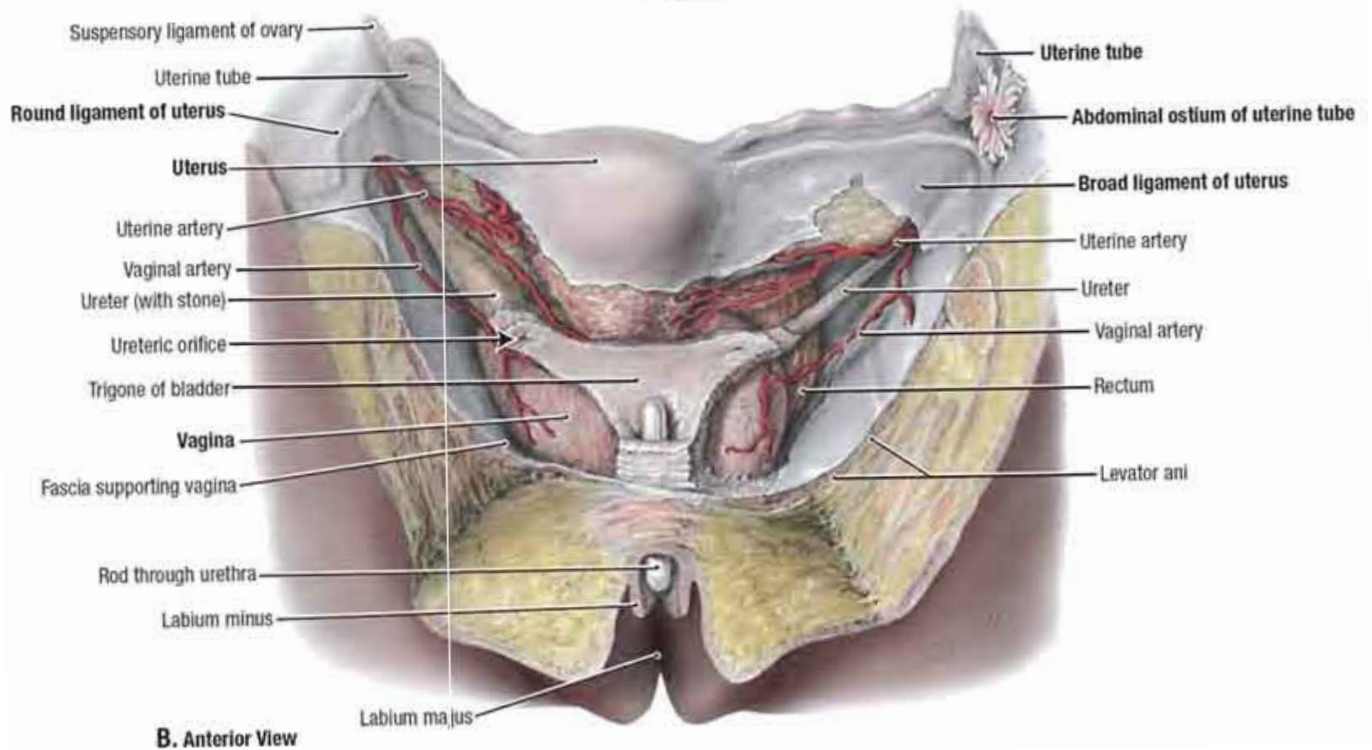
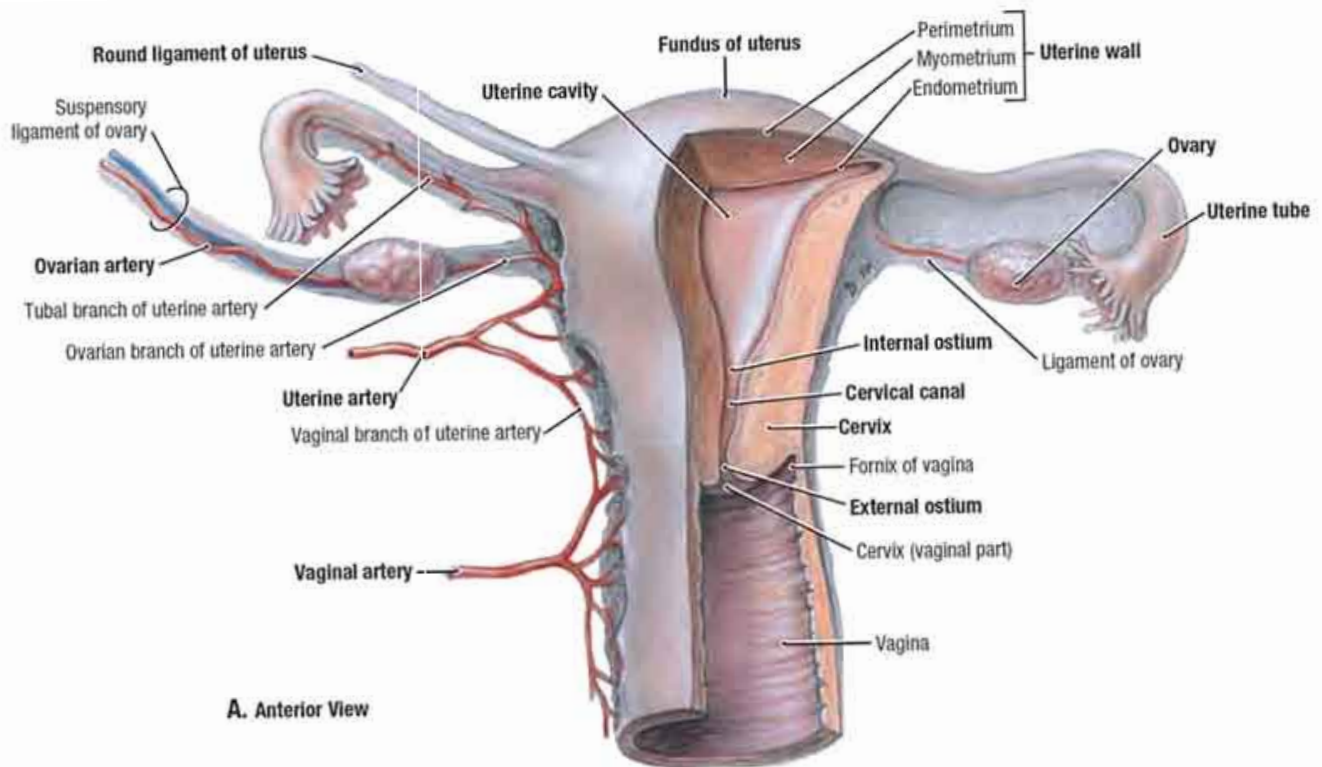
> Table of Contents > Chapter 3 - Pelvis and Perineum > 3.34 Uterus and its adnexa

---

## 3.34 Uterus and its adnexa

*Part of "Chapter 3 - Pelvis and Perineum "*

A. Blood supply. On the specimen's left side, part of the uterine wall with the round ligament and the vaginal wall have been cut away to expose the cervix, uterine cavity, and thick muscular wall of the uterus, the myometrium. On the specimen's right side, the ovarian artery (from the aorta) and uterine artery (from the internal iliac) supply the ovary, uterine tube, and uterus and anastomose in the broad ligament along the lateral aspect of the uterus. The uterine artery sends a uterine branch to supply the uterine body and fundus and a vaginal branch to supply the cervix and vagina. B. Uterus and broad ligament. The pubic bones and bladder, trigone excepted, are removed, as a continued dissection from Figure 3.33 .





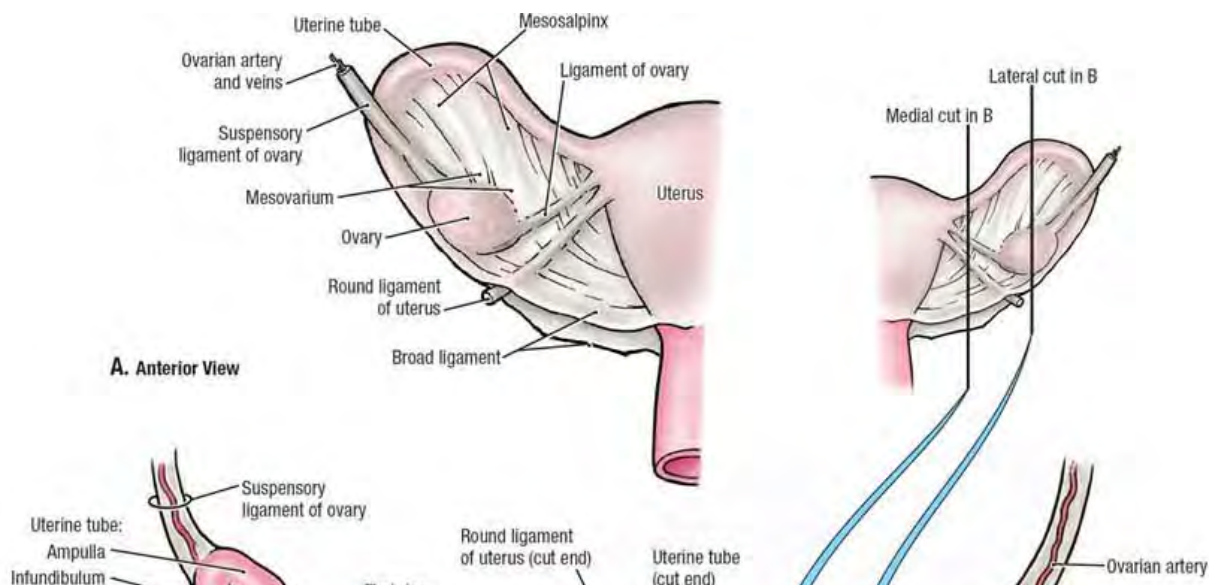
## 3.35 Uterus and broad ligament

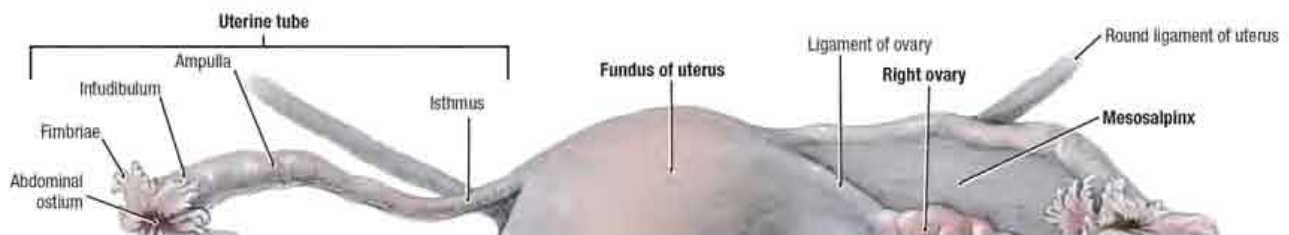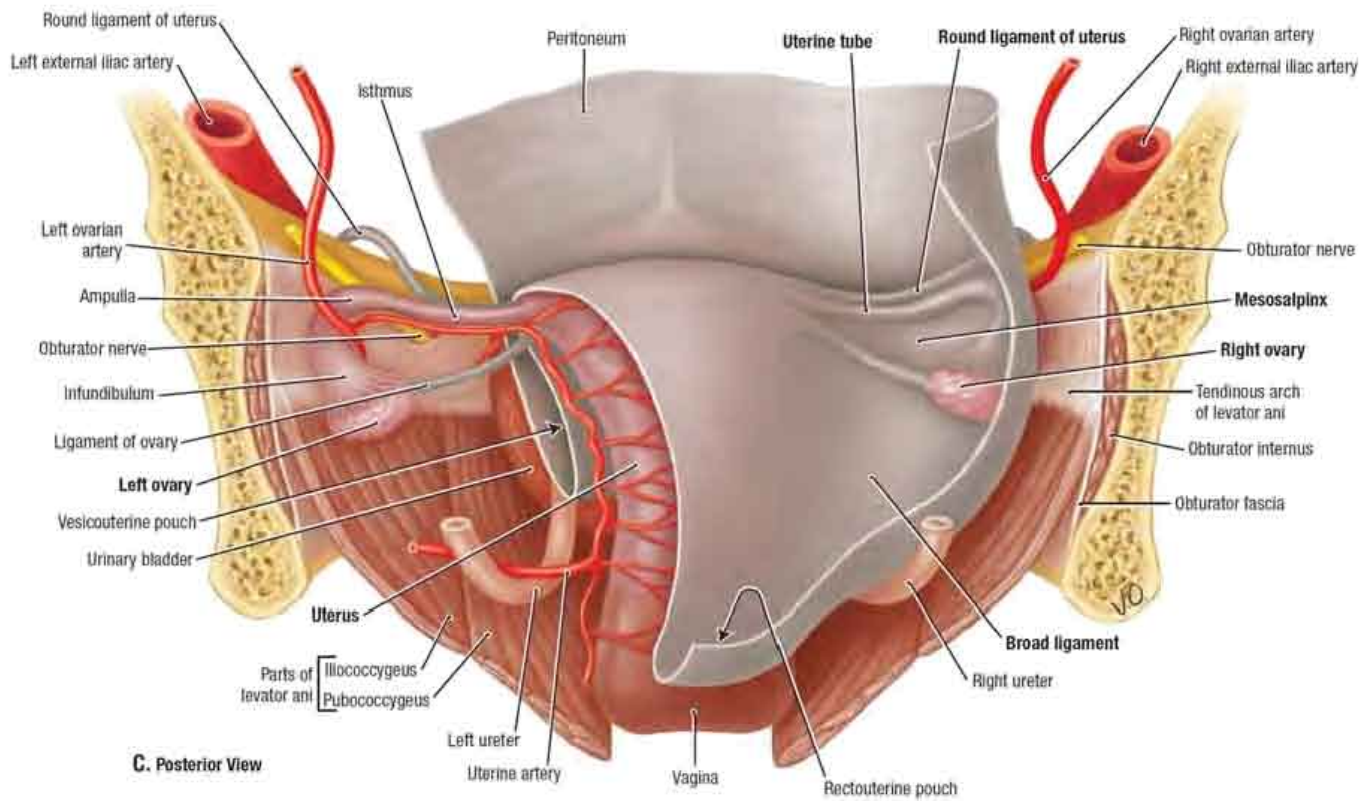
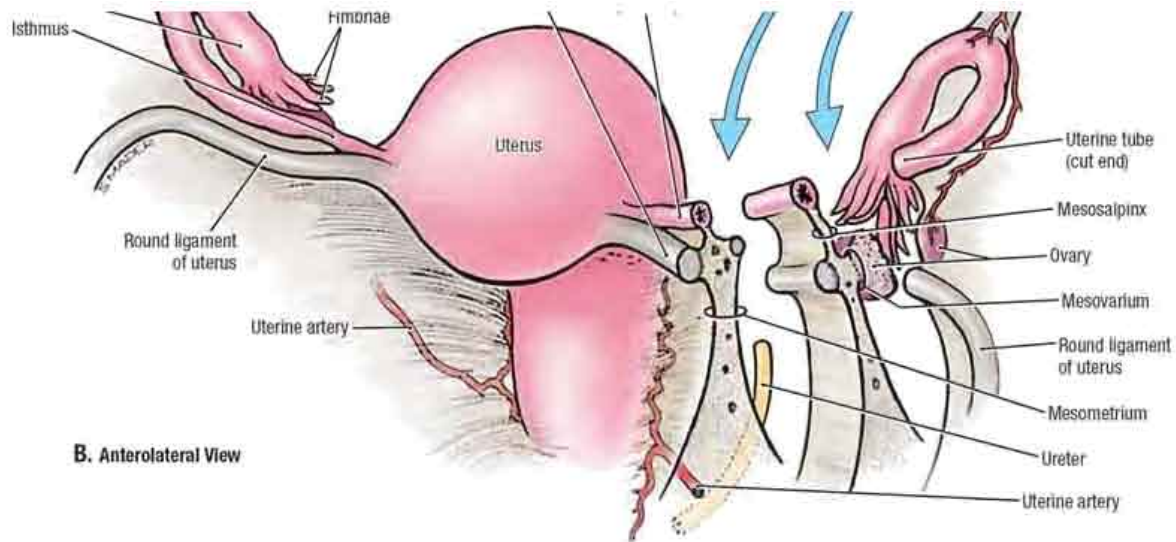
Part of "Chapter 3 - Pelvis and Perineum "

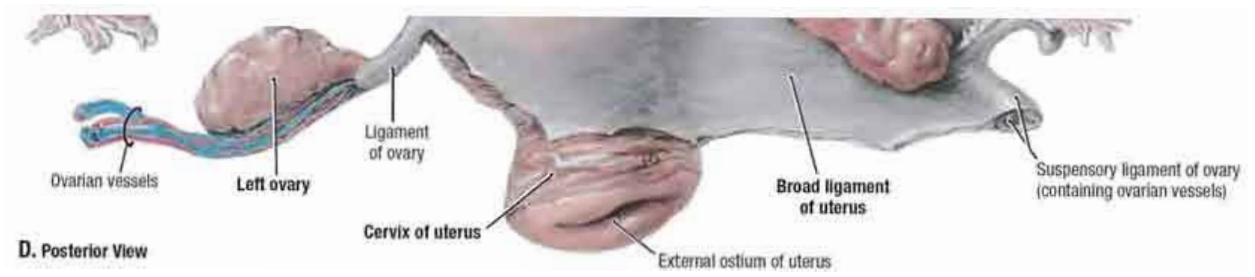A and B. Two paramedian sections show "mesenteries" with the prefix meso-. "Salpinx" is the Greek word for trumpet or tube, "metro" for uterus. The mesentery of the uterus and uterine tube is called the broad ligament. The major part of the broad ligament, the *mesometrium*, is attached to the uterus. The ovary is attached: to the broad ligament by a mesentery of its own, called the *mesovarium*; to the uterus by the ligament of the ovary; and near the pelvic brim, by the suspensory ligament of the ovary containing the ovarian vessels. The part of the broad ligament superior to the level of the mesovarium is called the *mesosalpinx*. C. Uterus in situ. D. Uterus and adnexa, removed from cadaver.

P.237

P.238







## 3.36 Pregnant uterus

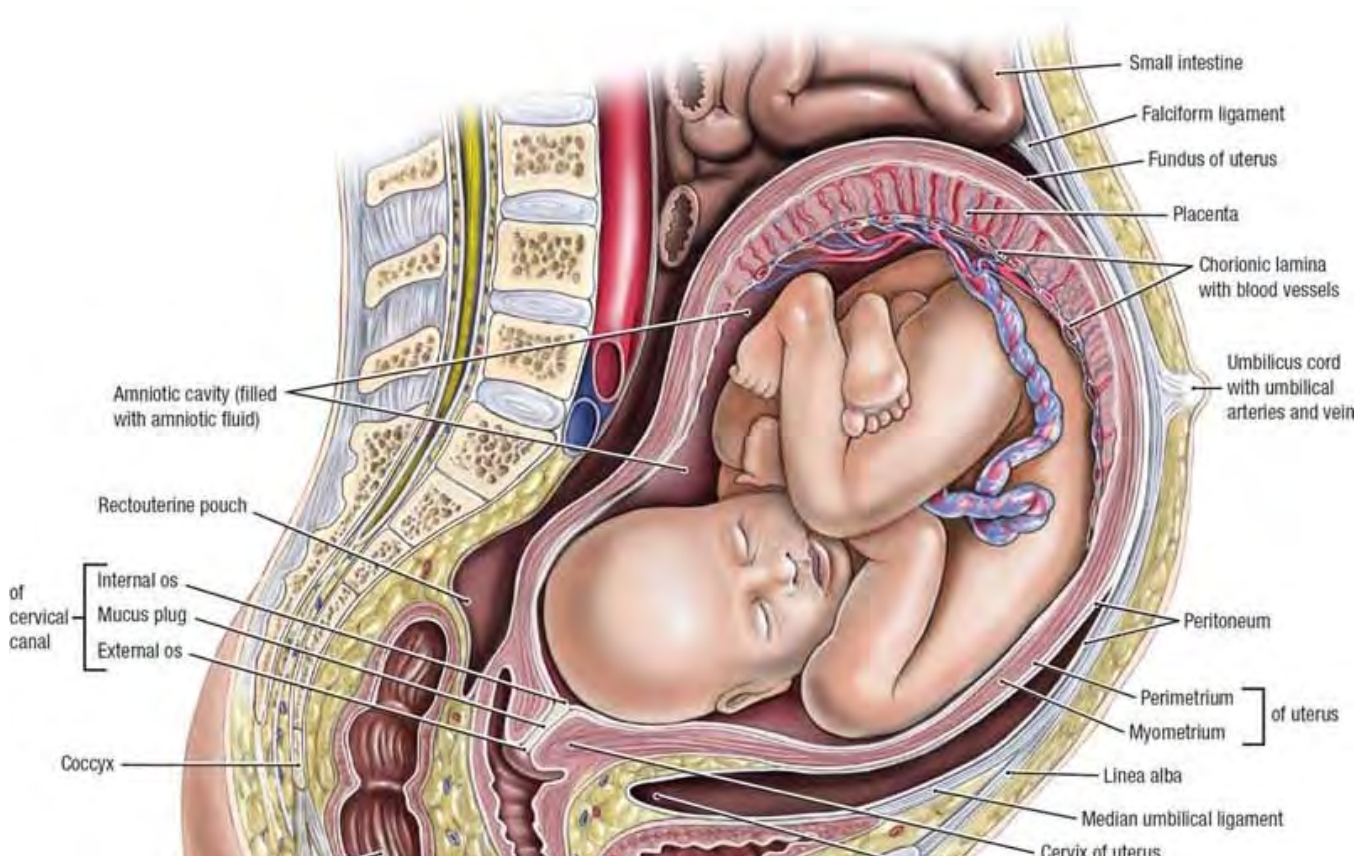
Part of "Chapter 3 - Pelvis and Perineum "

A. Median section; fetus is intact.

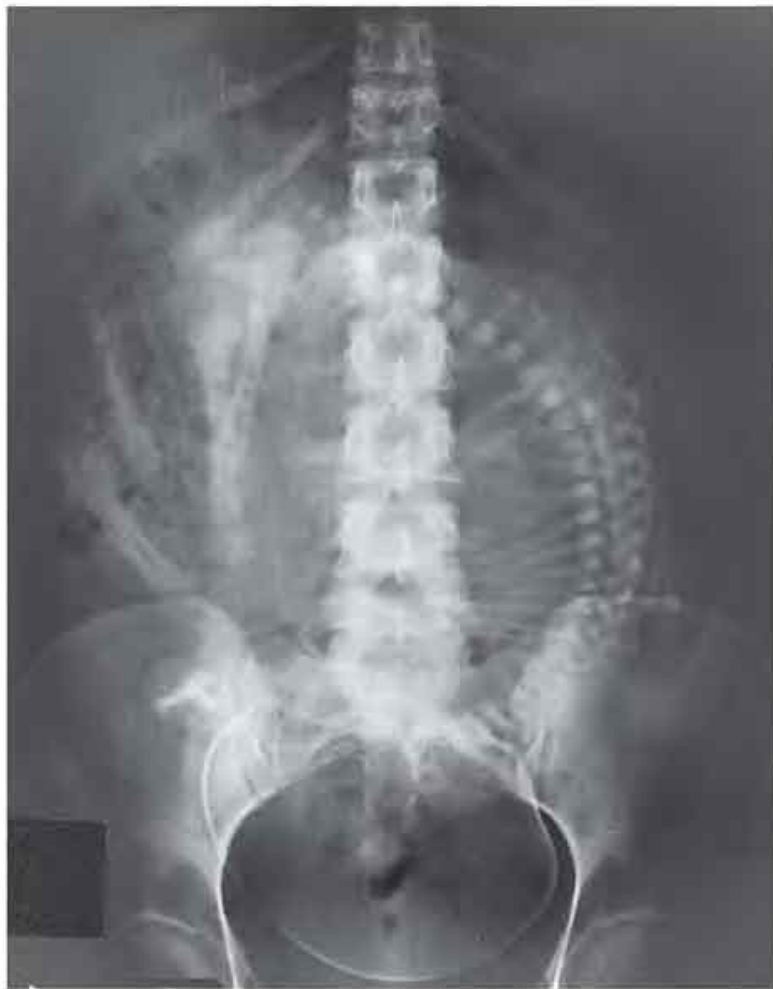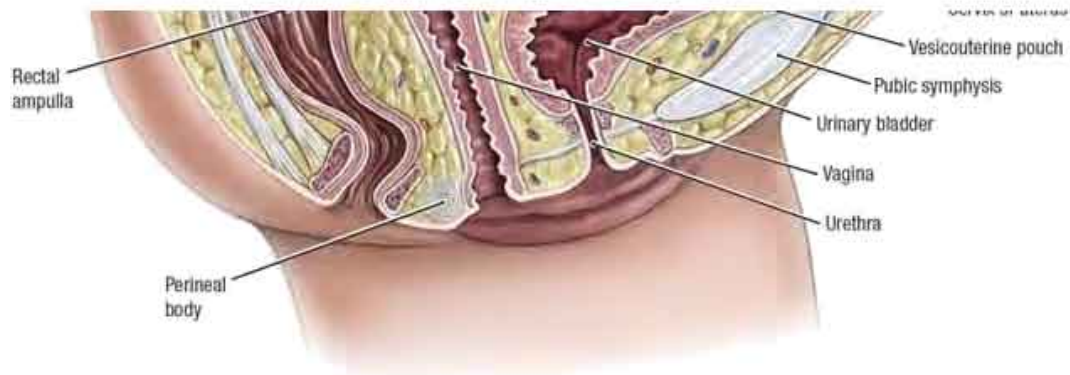
P.239

B. Radiograph of fetus. C. Photograph of an 18-week-old fetus connected to the placenta by the umbilical cord.

P.240



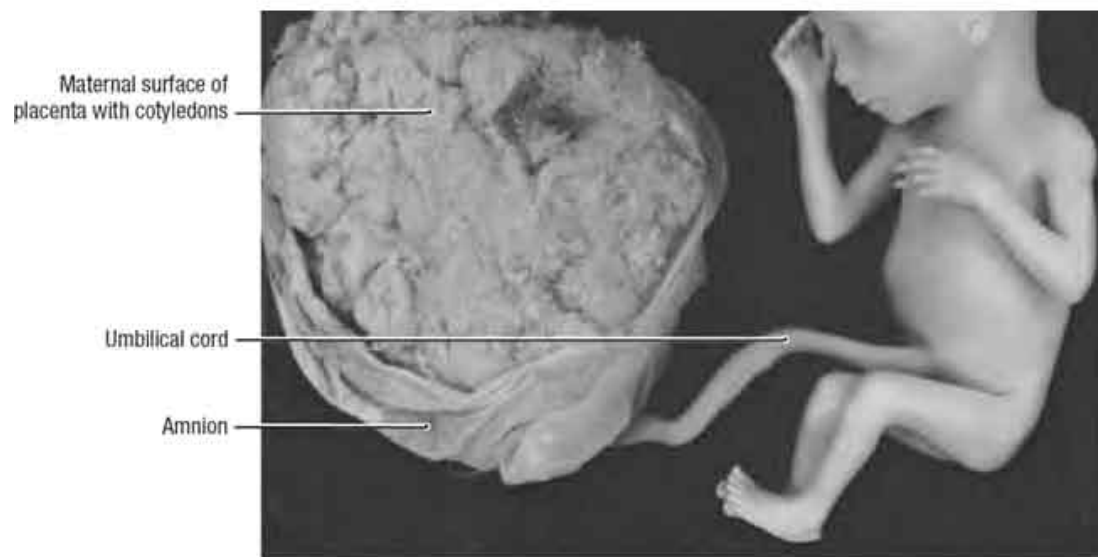




**B. Anteroposterior View**







**C. Maternal Surface of Placenta**

Authors: Agur, Anne M.R.; Dalley, Arthur F.

Title: *Grant's Atlas of Anatomy, 12th Edition*

Copyright ©2009 Lippincott Williams & Wilkins

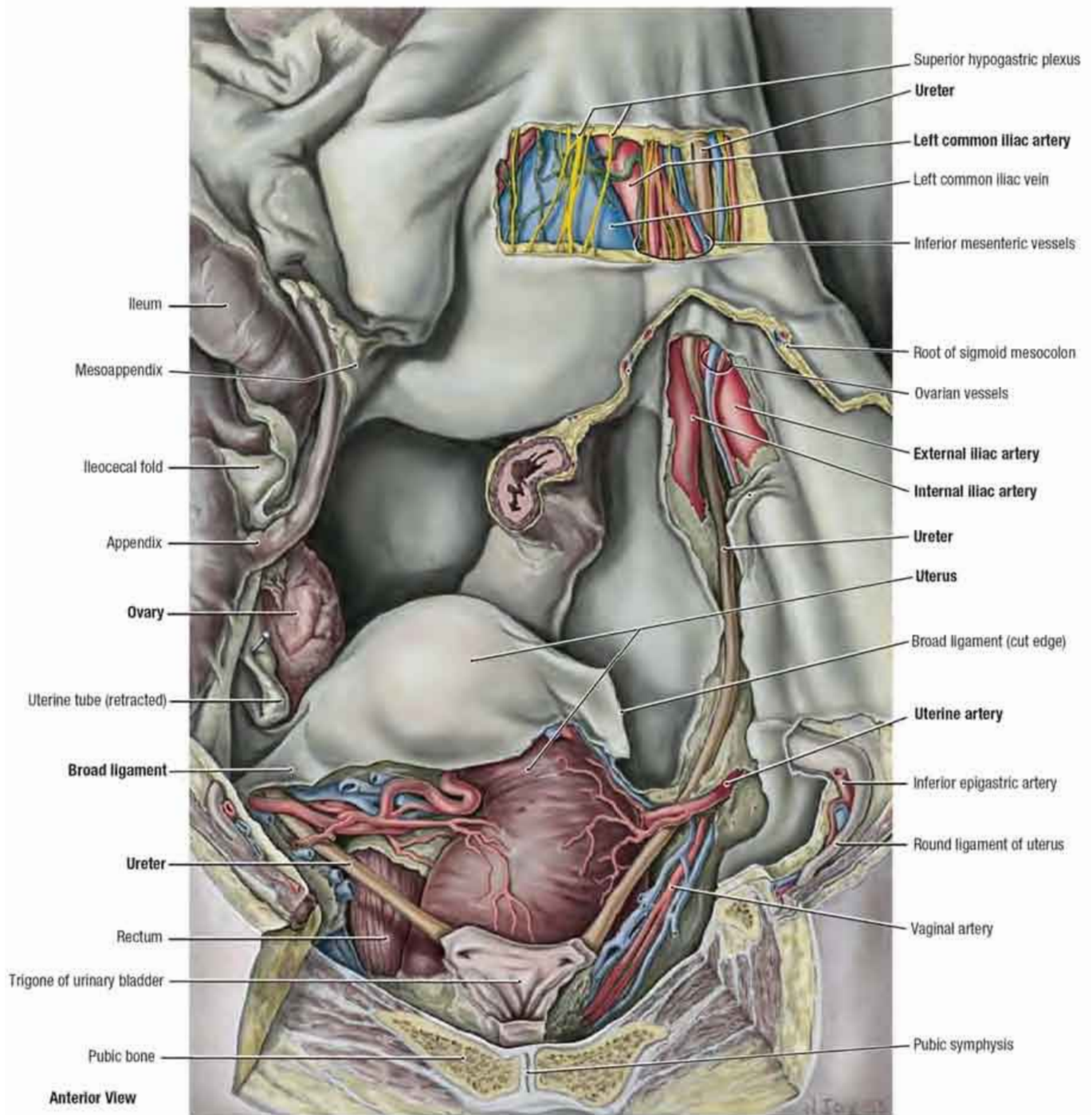
> Table of Contents > Chapter 3 - Pelvis and Perineum > 3.37 Ureter and relationship to uterine artery

---

## 3.37 Ureter and relationship to uterine artery

*Part of* "Chapter 3 - Pelvis and Perineum "

- Most of the pubic symphysis and most of the bladder (except the trigone) have been removed as in Figure 3.34B .
- The left ureter is crossed by the ovarian vessels and nerves; the apex of the inverted V-shaped root of the sigmoid mesocolon is situated anterior to the left ureter.
- The left ureter crosses the external iliac artery at the bifurcation of the common iliac artery and then descends anterior to the internal iliac artery; its course is subperitoneal from where it enters the pelvis to where it passes deep to the broad ligament and is crossed by the uterine artery.



Authors: Agur, Anne M.R.; Dalley, Arthur F.

Title: *Grant's Atlas of Anatomy, 12th Edition*

Copyright ©2009 Lippincott Williams & Wilkins

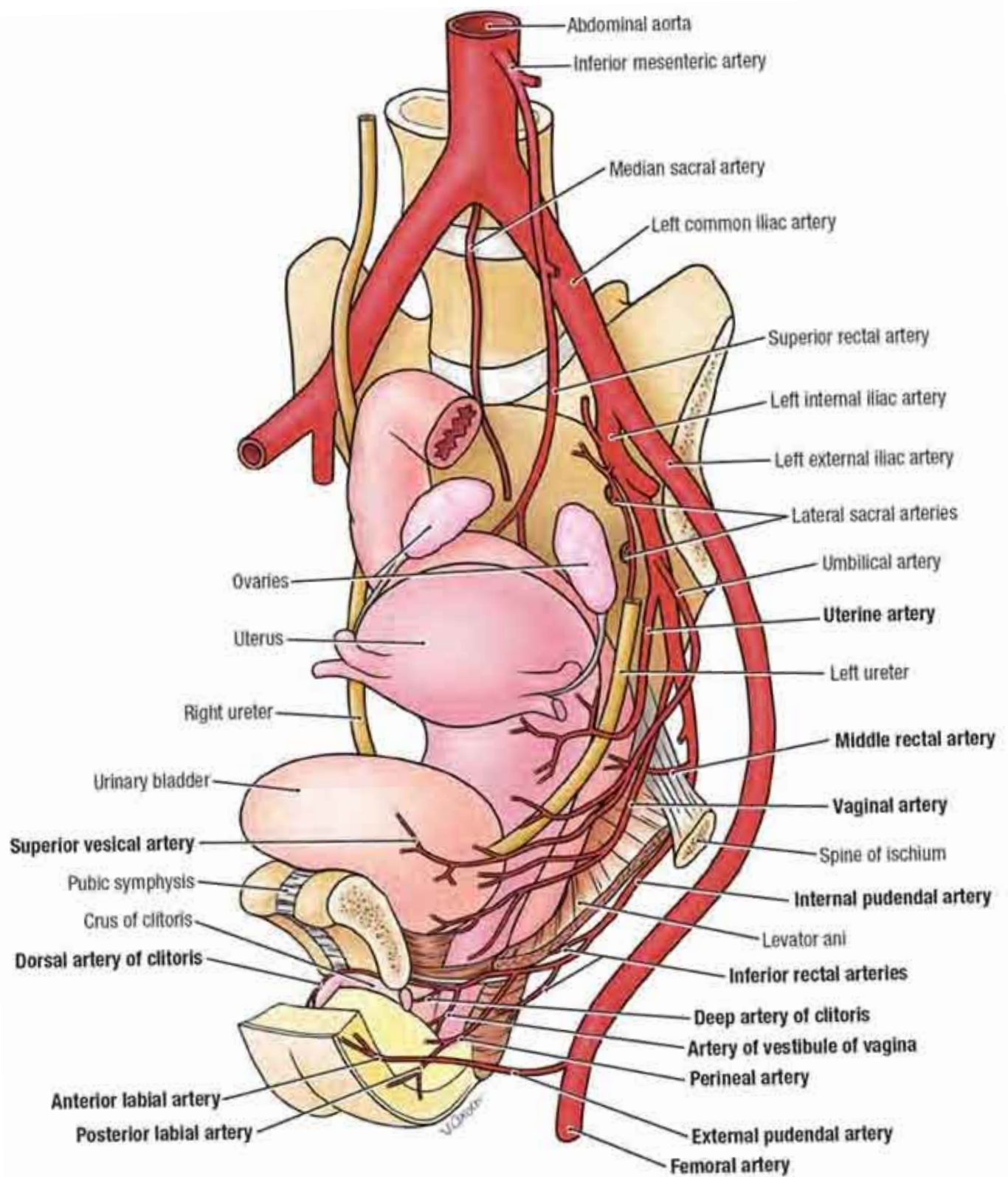
> Table of Contents > Chapter 3 - Pelvis and Perineum > 3.38 Arterial supply of female pelvis and perineum

---

## 3.38 Arterial supply of female pelvis and perineum

*Part of "Chapter 3 - Pelvis and Perineum "*

- The blood supply of the uterus is mainly from the *uterine arteries*, with potential collateral supply from the ovarian arteries.
- The arteries supplying the superior part of the vagina derive from the *uterine arteries*; the arteries supplying the middle and inferior parts of the vagina derive from the *vaginal* and *internal pudendal arteries*.
- The superior vesical arteries supply the anterosuperior parts of the bladder; the vaginal arteries supply the posteroinferior parts of the bladder.



**Anterolateral View**



Authors: Agur, Anne M.R.; Dalley, Arthur F.  
Title: *Grant's Atlas of Anatomy, 12th Edition*  
Copyright ©2009 Lippincott Williams & Wilkins

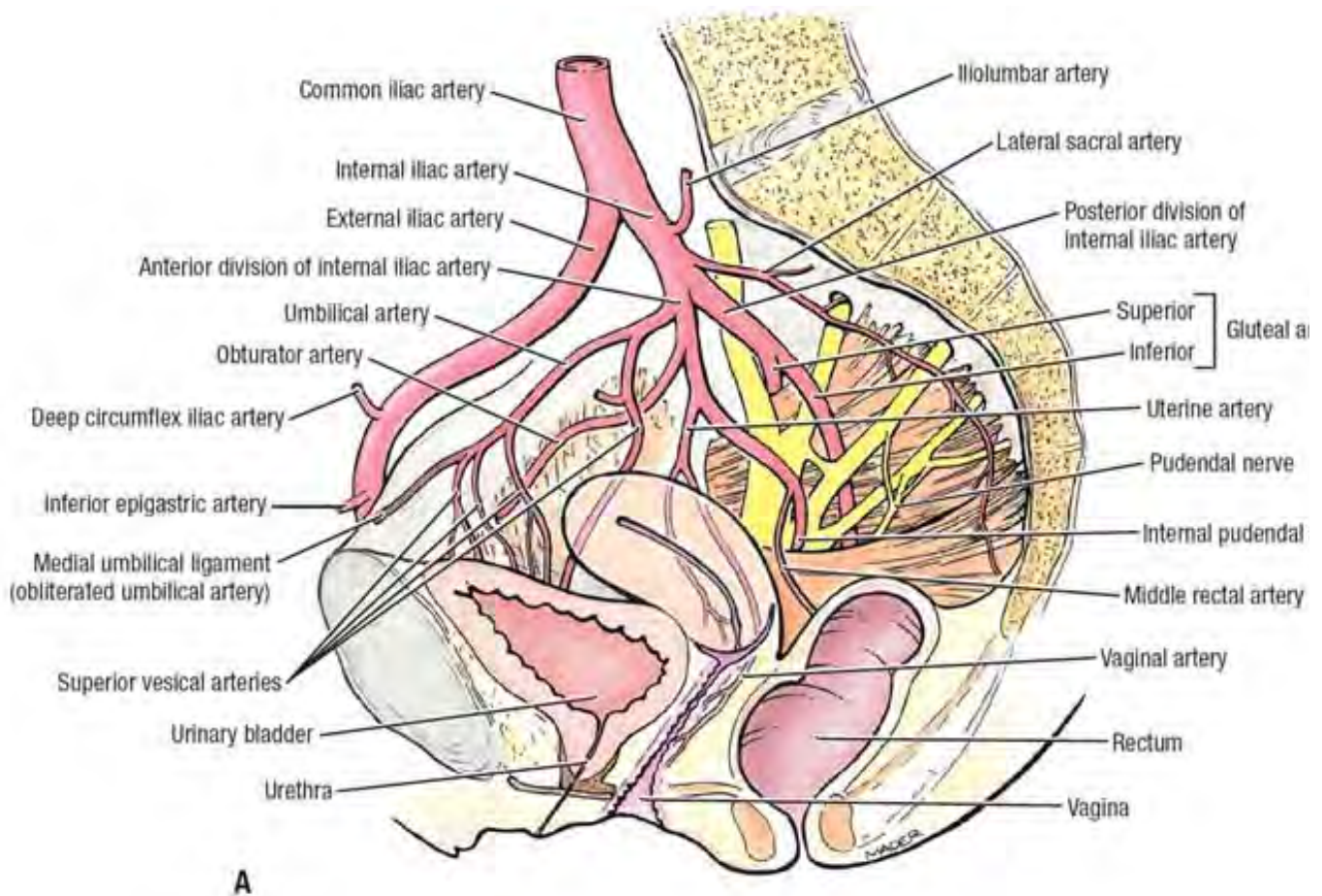
> Table of Contents > Chapter 3 - Pelvis and Perineum > 3.39 Arteries and veins of female pelvis

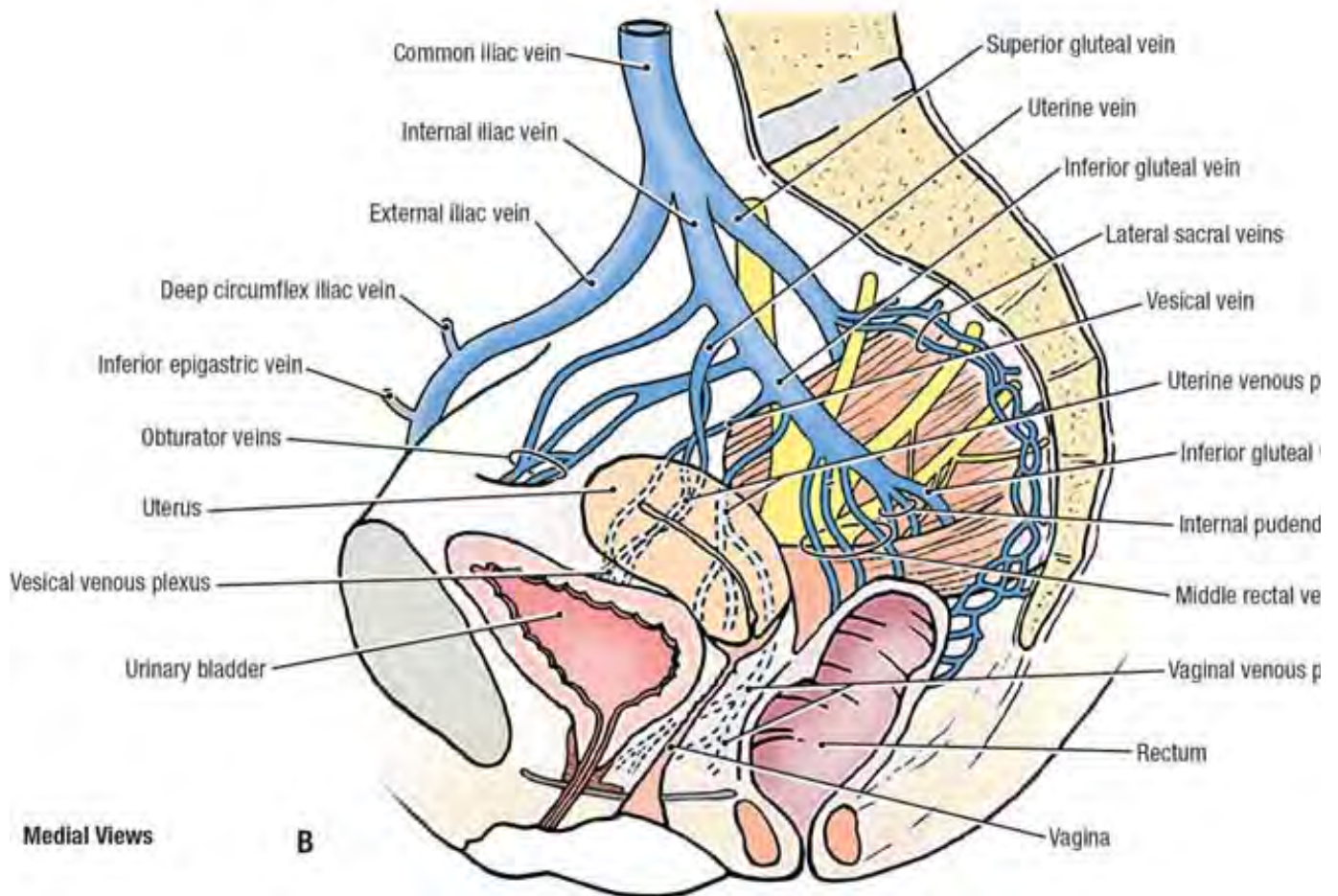
## 3.39 Arteries and veins of female pelvis

Part of "Chapter 3 - Pelvis and Perineum "

A. Arteries. B. Pelvic veins and venous plexuses.

P.243





Internal iliac

Common iliac artery

Passes over pelvic brim and descends into pelvic cavity

Main blood supply to pelvic organs, gluteal muscles, and perineum

Anterior division of internal iliac artery

Internal iliac artery

Passes anteriorly along lateral wall of pelvis, dividing into visceral, obturator, and internal pudendal arteries

Pelvic viscera and muscles of superior medial thigh, and perineum

Umbilical

Anterior division of internal iliac artery

Short pelvic course, gives off superior vesical arteries

Superior aspect of urinary bladder

Superior vesical artery

Patent proximal part of umbilical artery

Usually multiple, pass to superior aspect of urinary bladder

Superior aspect of urinary bladder

Obturator

Anterior division of internal iliac artery

Runs anteroinferiorly on lateral pelvic wall

Pelvic muscles, nutrient artery to ilium, head of femur, and muscles of medial compartment thigh

Uterine

Runs anteromedially in base of broad ligament/superior cardinal ligament; gives rise to vaginal branch, then crosses ureter superiorly to reach lateral aspect of uterine cervix

Uterus, ligaments of uterus, medial parts of uterine tube and ovary, and superior vagina

Vaginal

Divides into vaginal and inferior vesical branches

Vaginal branch: lower vagina, vestibular bulb, and adjacent rectum; inferior vesical branch: fundus of urinary bladder

Middle rectal

Descends in pelvis to inferior part of rectum

Inferior part of rectum

Internal pudendal

Exits pelvis via greater sciatic foramen and enters perineum (ischioanal fossa) via lesser sciatic foramen

Main artery to perineum including muscles of anal canal and perineum, skin and urogenital triangle, and erectile bodies

Posterior division of internal iliac artery

Internal iliac artery

Passes posteriorly and gives rise to parietal branches

Pelvic wall and gluteal region

Iliolumbar

Posterior division of internal iliac artery

Ascends anterior to sacroiliac joint and posterior to common iliac vessels and psoas major Iliacus, psoas major, quadratus lumborum muscles, and cauda equina in vertebral canal

Lateral sacral (superior and inferior)

Run on anteromedial aspect of piriformis

Piriformis muscle, structures in sacral canal and erector spinae muscles

Ovarian

Abdominal aorta

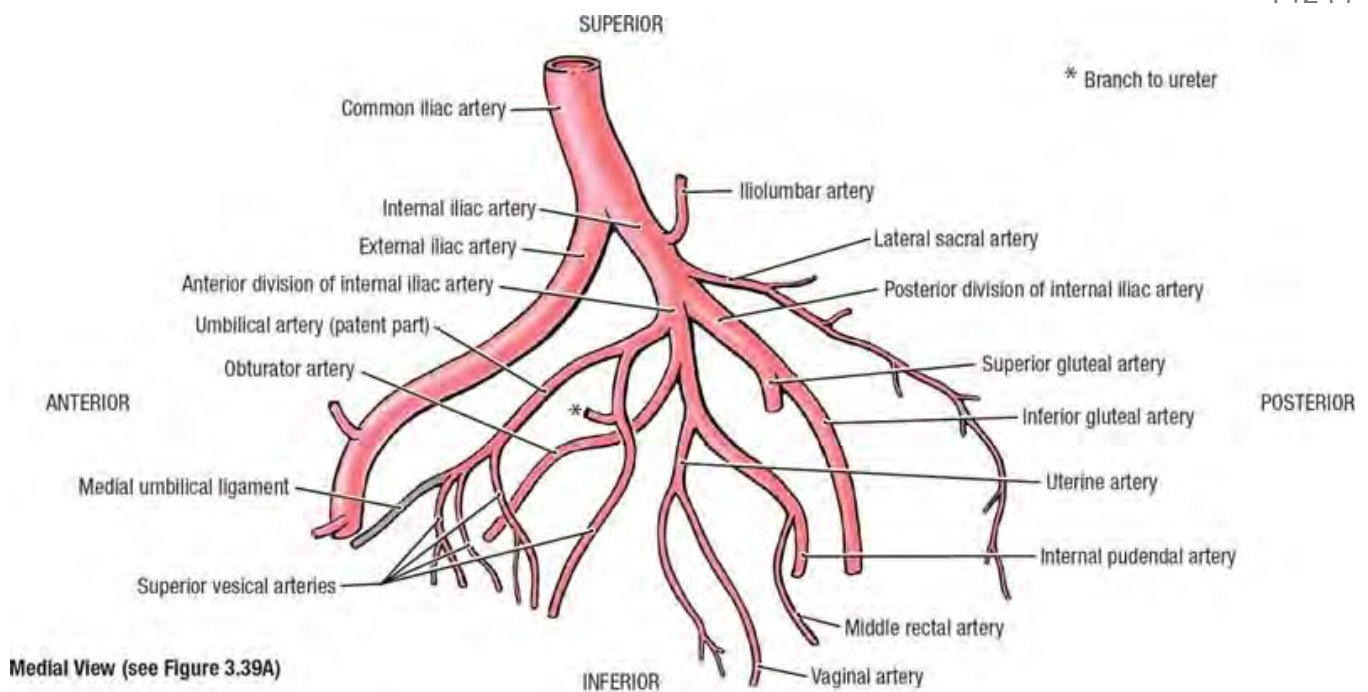
Crosses pelvic brim and descends in suspensory ligament to ovary

Abdominal and/or pelvic ureter, ovary, and ampullary end of uterine tube

Artery    Origin    Course    Distribution

Table 3.7 Arteries of Female Pelvis

P.244



**Authors:** Agur, Anne M.R.; Dalley, Arthur F.

**Title:** *Grant's Atlas of Anatomy, 12th Edition*

Copyright ©2009 Lippincott Williams & Wilkins

> Table of Contents > Chapter 3 - Pelvis and Perineum > 3.40 Lymphatic drainage of female pelvis and perineum

---

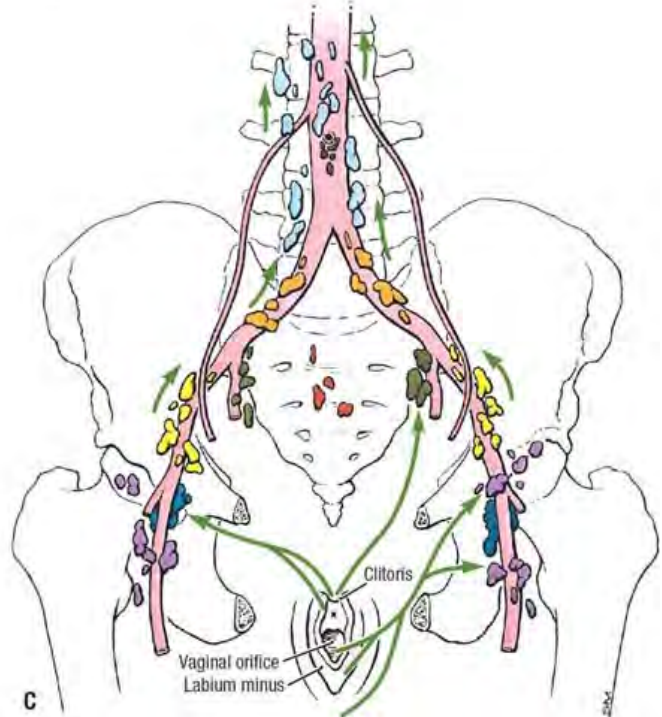
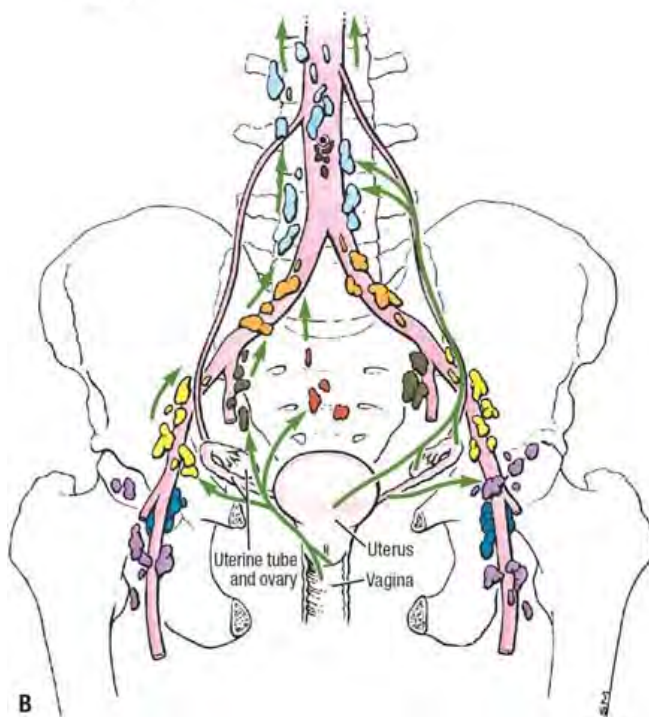
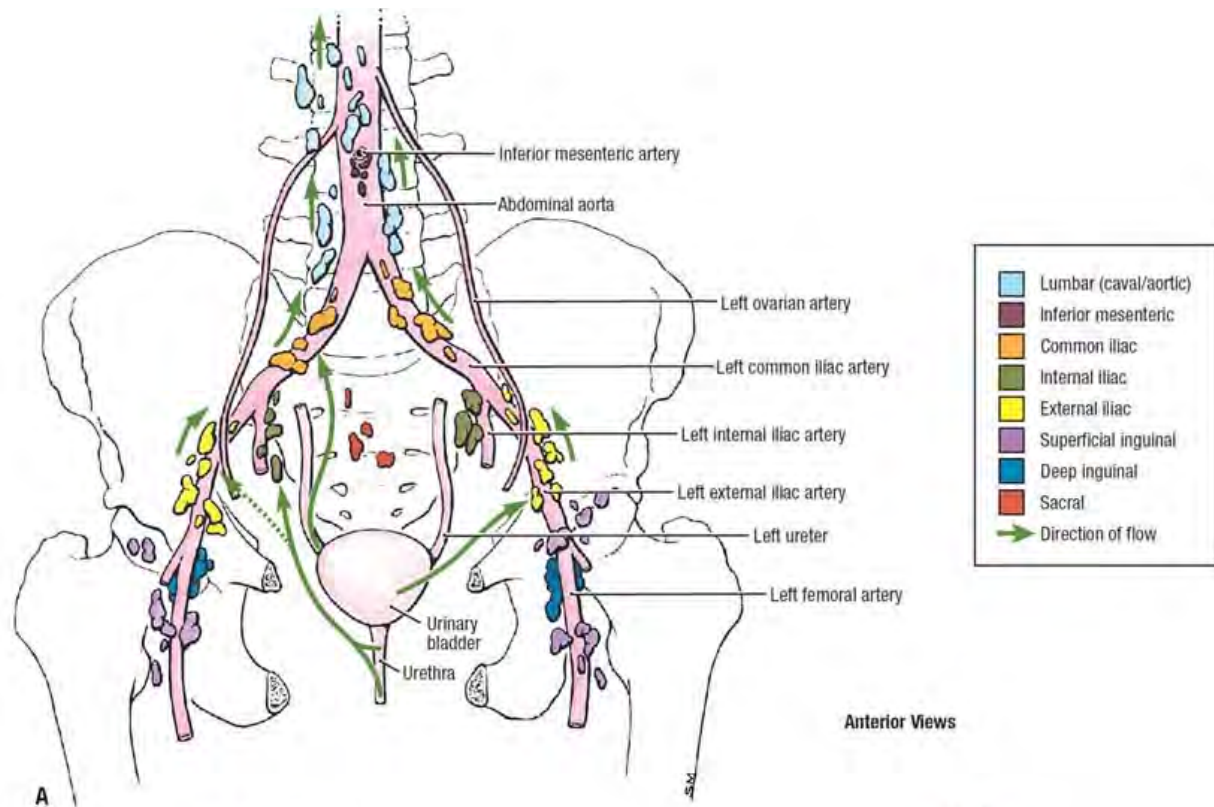
## 3.40 Lymphatic drainage of female pelvis and perineum

*Part of* "Chapter 3 - Pelvis and Perineum "

---

P.245





## Lumbar

Gonads and associated structures (along ovarian vessels), ovary, uterine tube (except isthmus and intrauterine parts), fundus of uterus, common iliac nodes

Inferior mesenteric

Superiormost rectum, sigmoid colon, descending colon, pararectal nodes

Common iliac

External and internal iliac lymph nodes

Internal iliac

Inferior pelvic structures, deep perineal structures, sacral nodes, base of bladder, inferior pelvic ureter, anal canal (above pectinate line), inferior rectum, middle and upper vagina, cervix, body of uterus, sacral nodes

External iliac

Anterosuperior pelvic structures, deep inguinal nodes, superior bladder, superior pelvic ureter, upper vagina, cervix, lower body of uterus

Superficial inguinal

Lower limb, superficial drainage of inferolateral quadrant of trunk, including anterior abdominal wall inferior to umbilicus, gluteal region, superolateral uterus (near attachment of round ligament), skin of perineum including vulva, ostium of vagina (inferior to hymen), prepuce of clitoris, perianal skin, anal canal inferior to pectinate line

Deep inguinal

Glans of clitoris, superficial inguinal nodes

Sacral

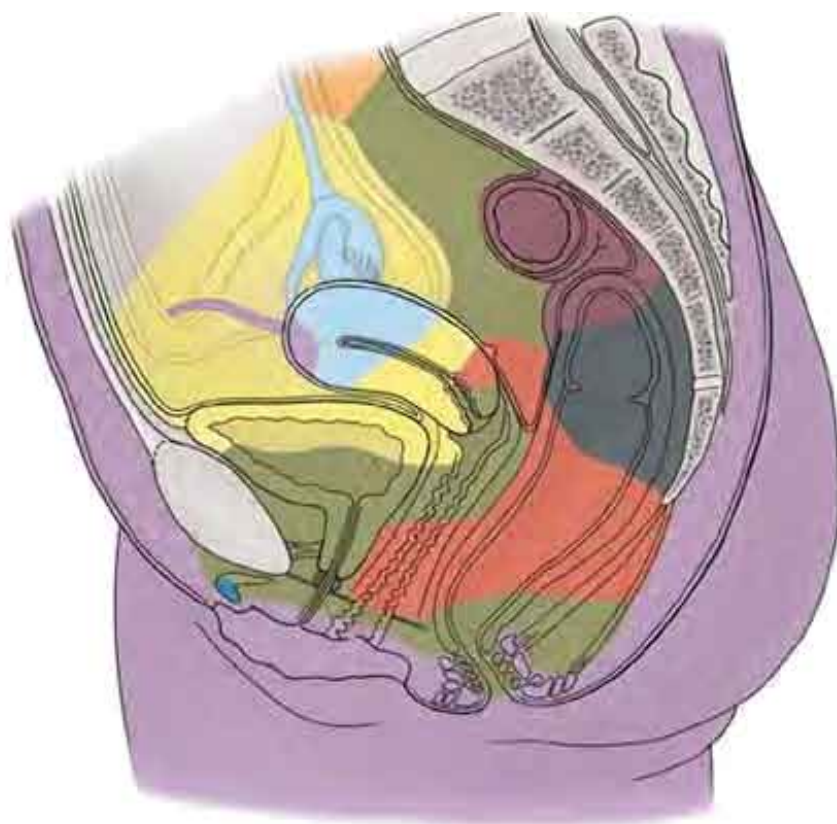
Posteroinferior pelvic structures, inferior rectum, inferior vagina

Pararectal

Superior rectum

Lymph Node Group    Structures Typically Draining to Lymph Node Group

Table 3.8 Lymphatic Drainage of the Structures of the Female Pelvis and Perineum



**Lymph nodes:**

-  Lumbar (caval/aortic)
-  Inferior mesenteric
-  Common iliac
-  Internal iliac
-  External iliac
-  Superficial inguinal
-  Deep inguinal
-  Sacral
-  Pararectal

Authors: Agur, Anne M.R.; Dalley, Arthur F.

Title: *Grant's Atlas of Anatomy, 12th Edition*

Copyright ©2009 Lippincott Williams & Wilkins

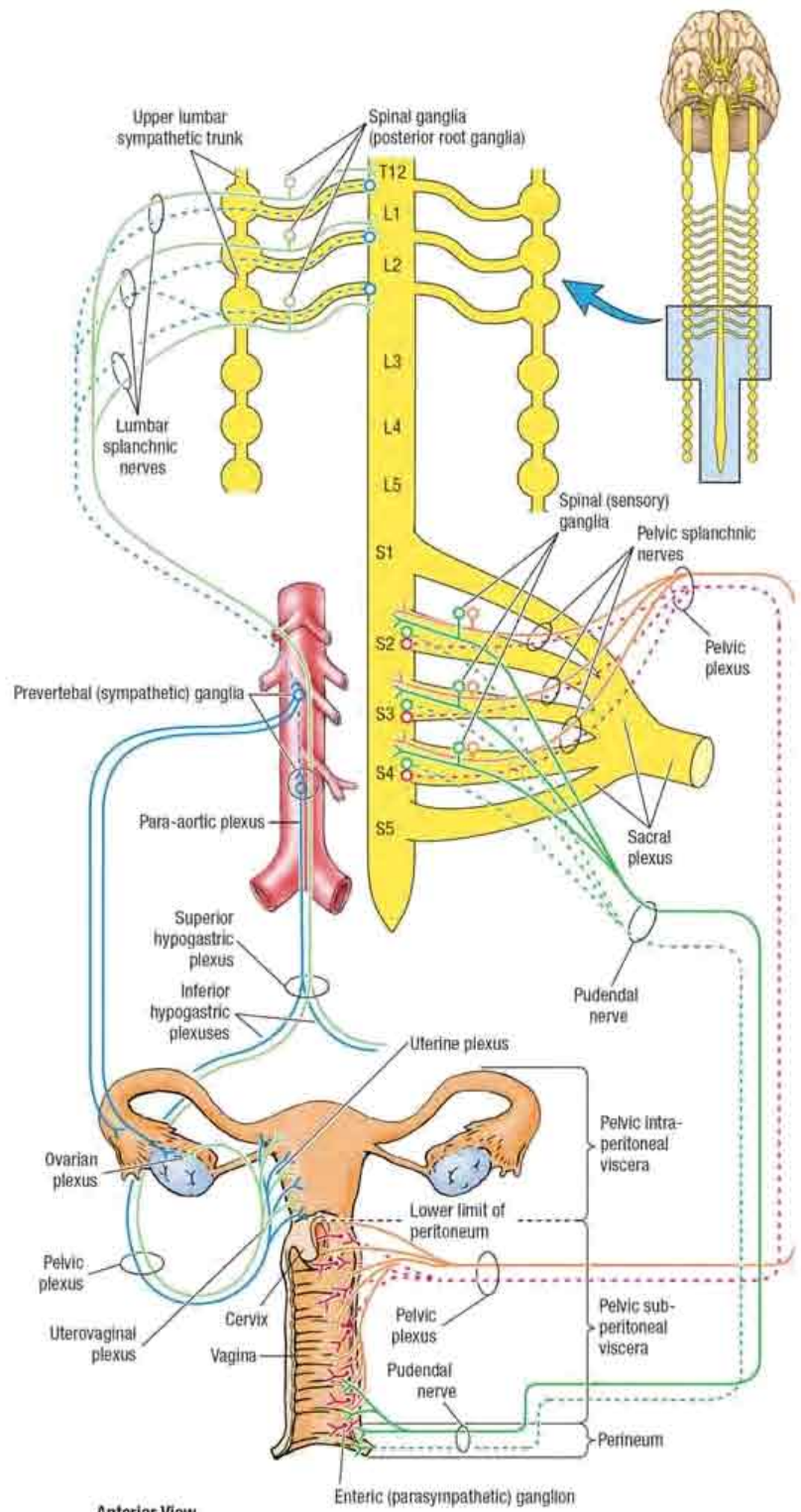
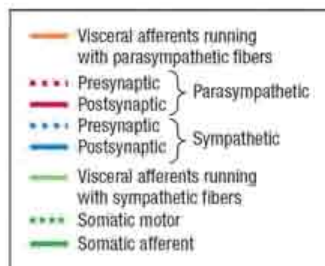
> Table of Contents > Chapter 3 - Pelvis and Perineum > 3.41 Innervation of female pelvic viscera

---

## 3.41 Innervation of female pelvic viscera

*Part of* "Chapter 3 - Pelvis and Perineum "

- Pelvic splanchnic nerves (S2–S4) supply parasympathetic motor fibers to the uterus and vagina (and vasodilator fibers to the erectile tissue of the clitoris and bulb of the vestibule; not shown).
- Presynaptic sympathetic fibers pass through the lumbar splanchnic nerves to synapse in prevertebral ganglia; the postsynaptic fibers travel through the superior and inferior hypogastric plexuses to reach the pelvic viscera.
- Visceral afferent fibers conducting pain from intraperitoneal viscera travel with the sympathetic fibers to the T12–L2 spinal ganglia. Visceral afferent fibers conducting pain from subperitoneal viscera travel with parasympathetic fibers to the S2–S4 spinal ganglia.
- Somatic sensation from the opening of the vagina also passes to the S2–S4 spinal ganglia via the pudendal nerve.
- Muscular contractions of the uterus are hormonally induced.



Anterior View



Authors: Agur, Anne M.R.; Dalley, Arthur F.

Title: *Grant's Atlas of Anatomy, 12th Edition*

Copyright ©2009 Lippincott Williams & Wilkins

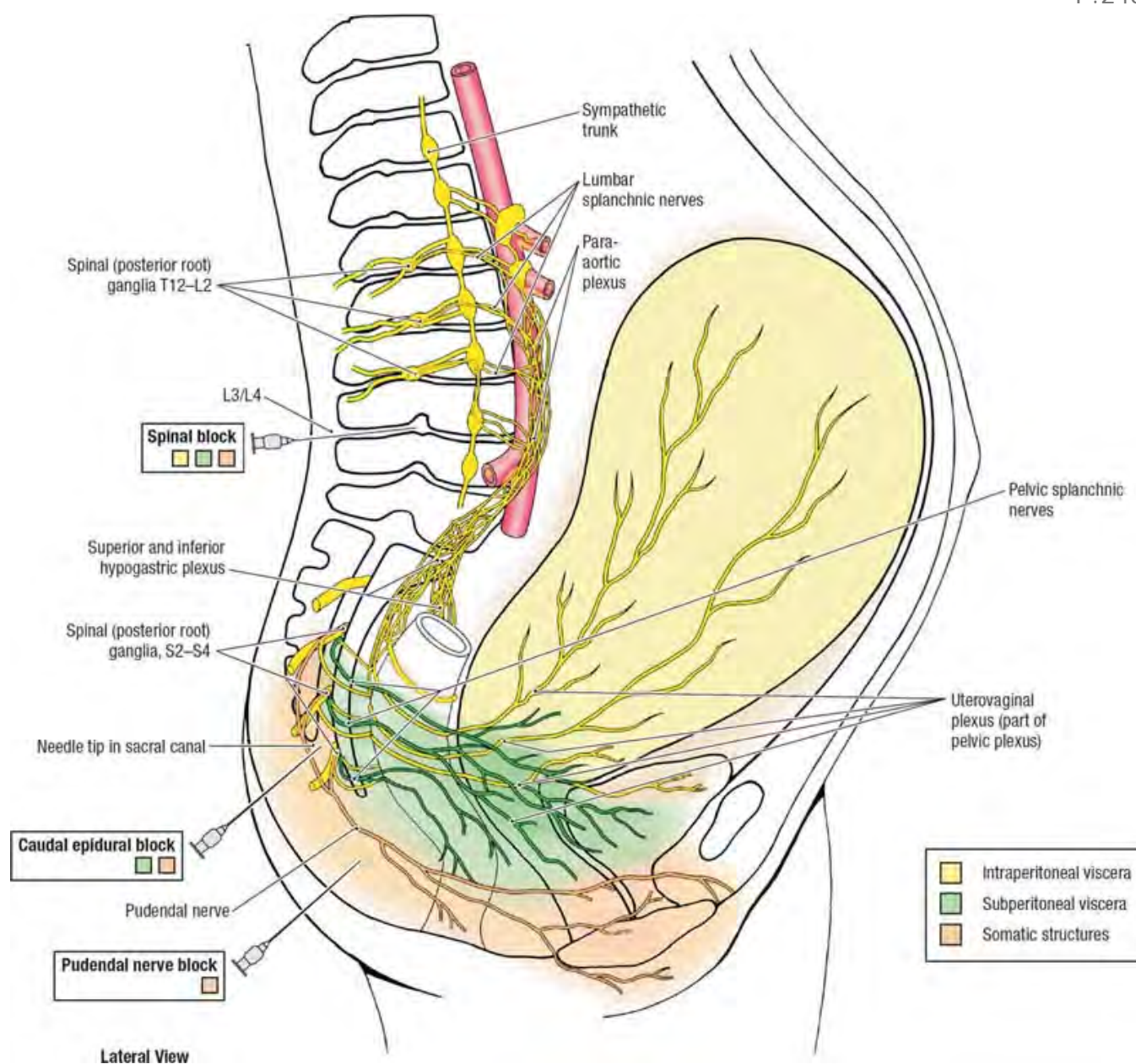
> Table of Contents > Chapter 3 - Pelvis and Perineum > 3.42 Innervation of pelvic viscera during pregnancy; nerve blocks

---

## 3.42 Innervation of pelvic viscera during pregnancy; nerve blocks

*Part of "Chapter 3 - Pelvis and Perineum "*

- A spinal block, in which the anesthetic agent is introduced with a needle into the spinal subarachnoid space at the L3–L4 vertebral level produces complete anesthesia inferior to approximately the waist level. The perineum, pelvic floor, and birth canal are anesthetized, and motor and sensory functions of the entire lower limbs, as well as sensation of uterine contractions, are temporarily eliminated.
- With the caudal epidural block, the anesthetic agent is administered using an in-dwelling catheter in the sacral canal. The entire birth canal, pelvic floor, and most of the perineum are anesthetized, but the lower limbs are not usually affected. The mother is aware of her uterine contractions.
- A pudendal nerve block is a peripheral nerve block that provides local anesthesia over the S2–S4 dermatomes (most of the perineum) and the inferior quarter of the vagina. It does not block pain from the superior birth canal (uterine cervix and superior vagina, so the mother is able to feel uterine contractions).



Authors: Agur, Anne M.R.; Dalley, Arthur F.

Title: *Grant's Atlas of Anatomy, 12th Edition*

Copyright ©2009 Lippincott Williams & Wilkins

> Table of Contents > Chapter 3 - Pelvis and Perineum > 3.43 Serial dissection of autonomic nerves of female pelvis

---

## 3.43 Serial dissection of autonomic nerves of female pelvis

*Part of* "Chapter 3 - Pelvis and Perineum "

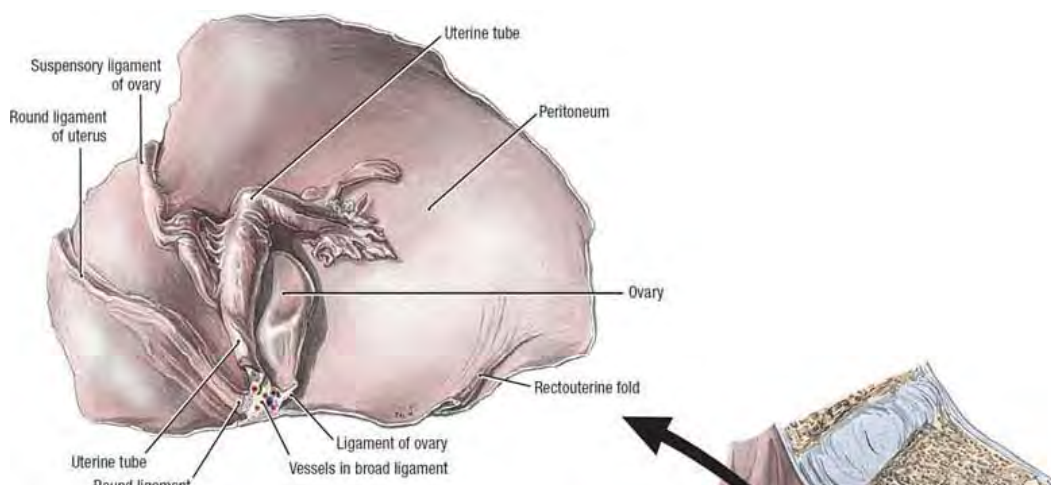
A. Broad ligament and peritoneum of the lateral wall of the pelvic cavity have been removed to expose the endopelvic fascia.

P.249

B. The rectum and endopelvic fascia have been reflected anteriorly to expose the hypogastric nerves, sympathetic trunk, and pelvic splanchnic nerves (parasympathetic).

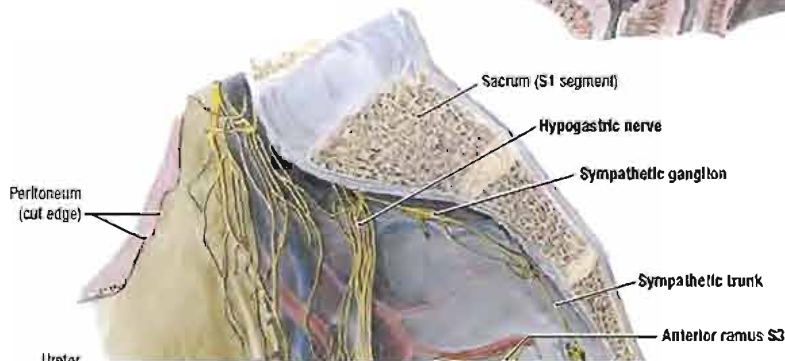
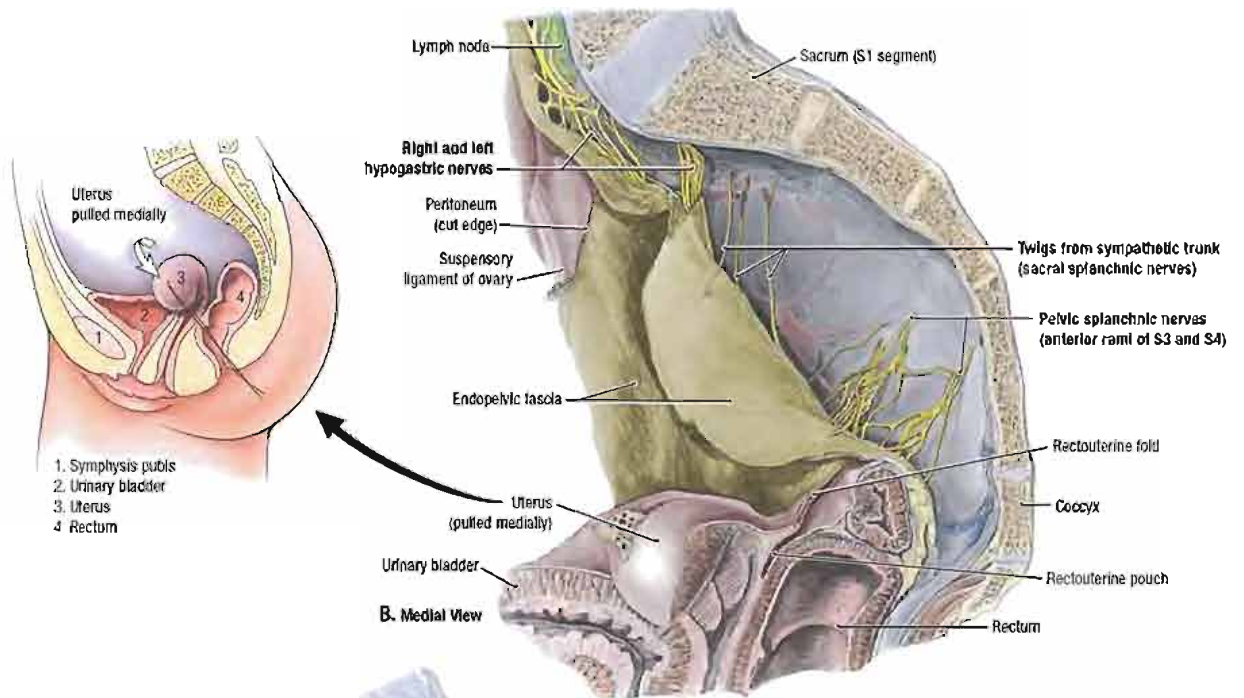
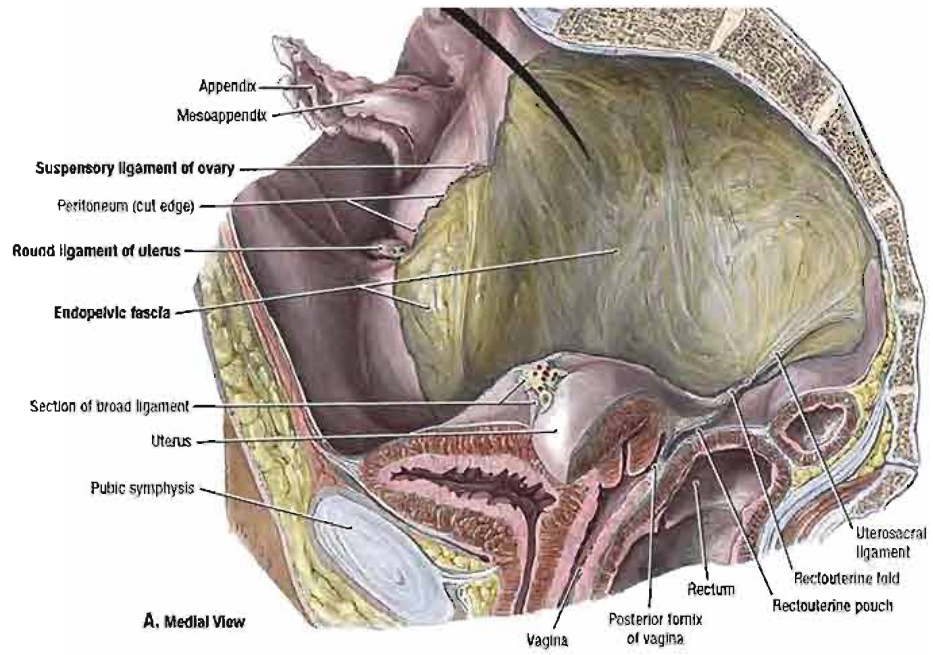
C. The subperitoneal fatty-areolar tissue has been removed and the inferior hypogastric plexus exposed. The inferior hypogastric plexus continues as the uterovaginal plexus and supplies the uterus, uterine tubes, vagina, urethra, greater vestibular glands, erectile tissue of the clitoris, and bulb of the vestibule.

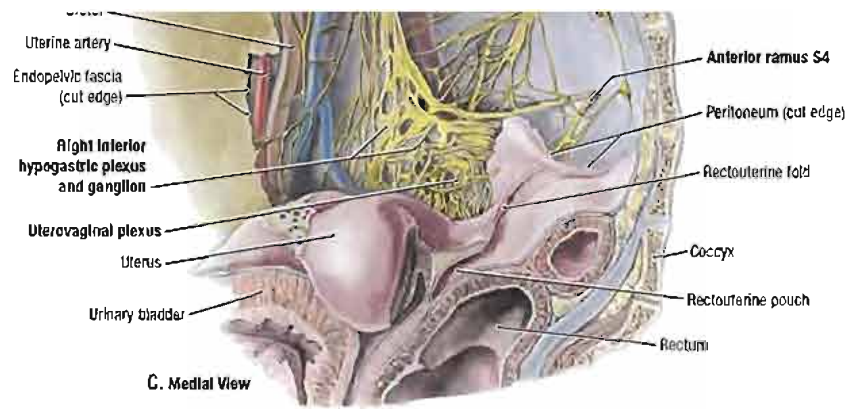
P.250





Removed from A







Authors: Agur, Anne M.R.; Dalley, Arthur F.

Title: *Grant's Atlas of Anatomy, 12th Edition*

Copyright ©2009 Lippincott Williams & Wilkins

> Table of Contents > Chapter 3 - Pelvis and Perineum > 3.44 Transverse section through female pelvis

---

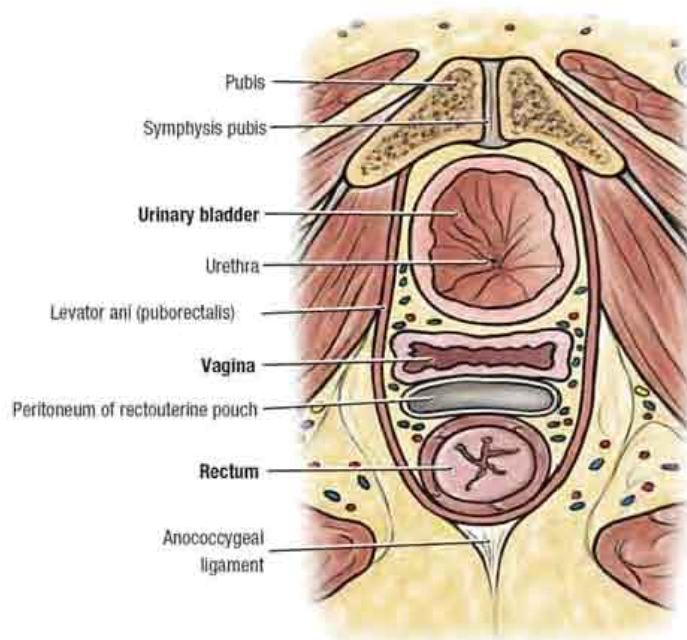
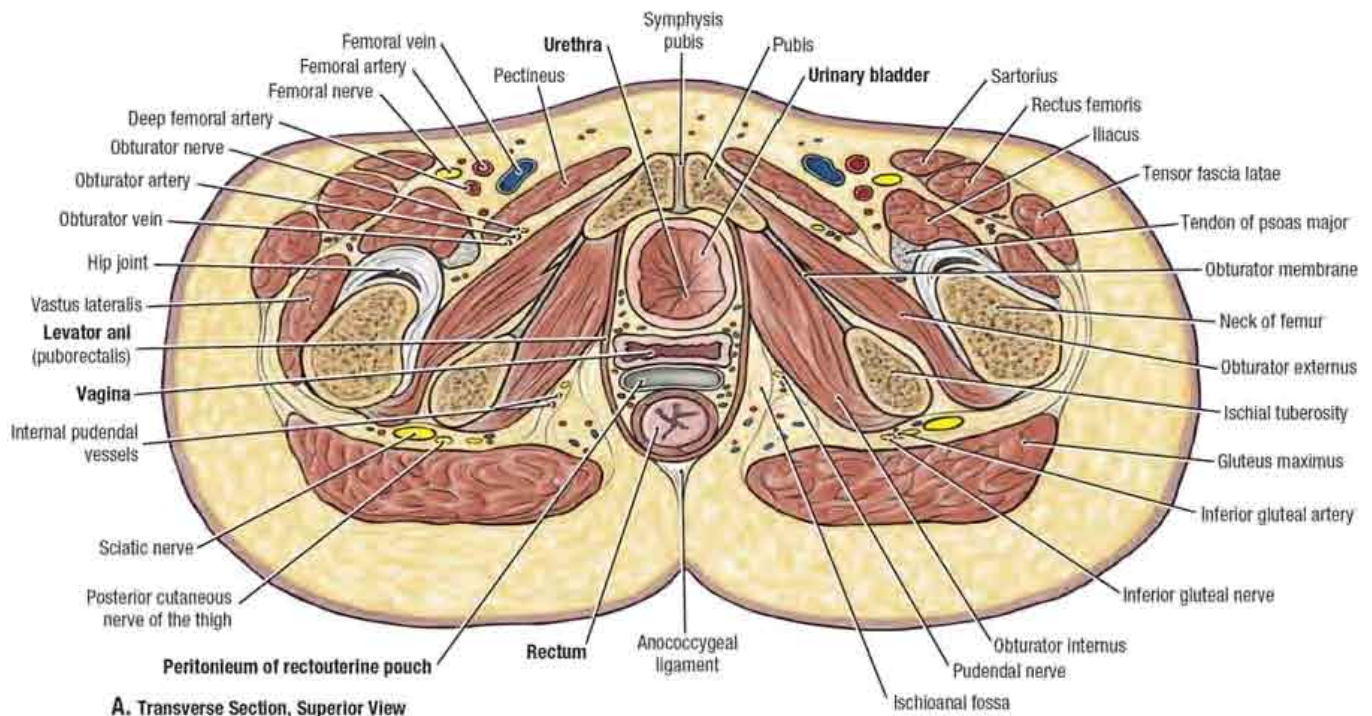
## 3.44 Transverse section through female pelvis

*Part of* "Chapter 3 - Pelvis and Perineum "

A. Transverse section through the ischial tuberosities. B. Enlargement of central part of section including the bladder, vagina, rectum, and rectouterine pouch.

---

P.251



Authors: Agur, Anne M.R.; Dalley, Arthur F.

Title: *Grant's Atlas of Anatomy, 12th Edition*

Copyright ©2009 Lippincott Williams & Wilkins

> Table of Contents > Chapter 3 - Pelvis and Perineum > 3.45 Pelvic fascia and supporting mechanism of cervix and upper vagina

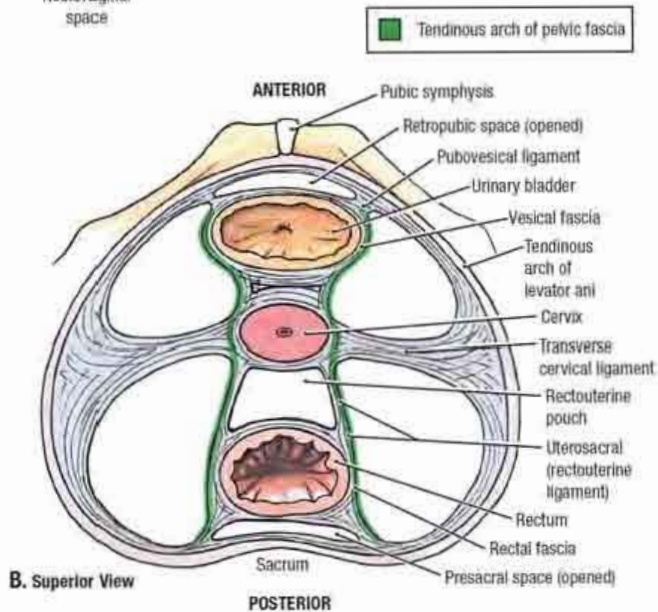
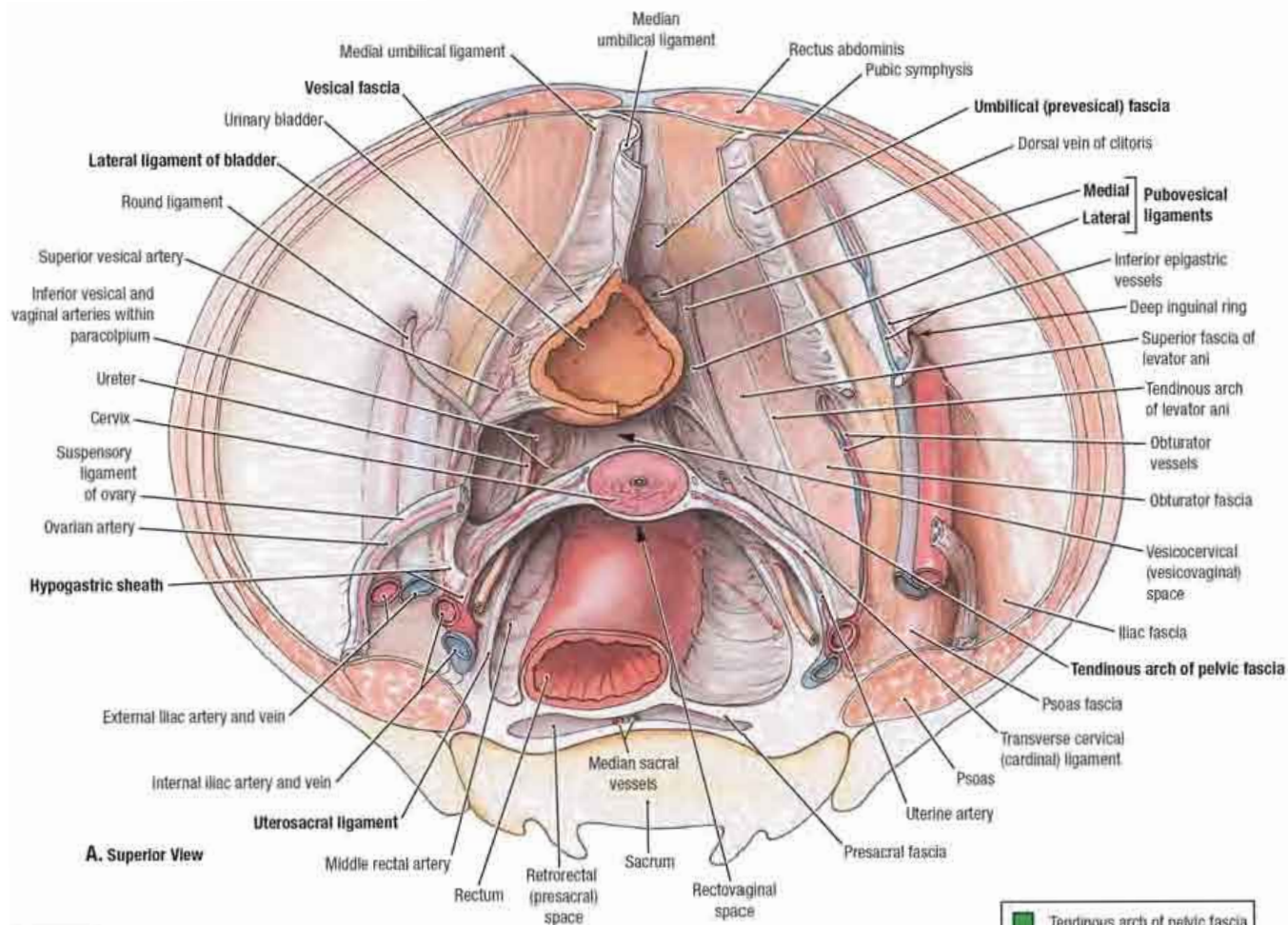
---

## 3.45 Pelvic fascia and supporting mechanism of cervix and upper vagina

*Part of* "Chapter 3 - Pelvis and Perineum "

A. Greater and lesser pelvis demonstrating pelvic viscera and endopelvic fascia. B. Schematic illustration of fascial ligaments and areolar spaces at level of tendinous arch of pelvic fascia.

- Note the parietal pelvic fascia covering the obturator internus and levator ani muscles and the visceral pelvic fascia surrounding the pelvic organs. These membranous fasciae are continuous where the organs penetrate the pelvic floor, forming a tendinous arch of pelvic fascia bilaterally.
- The endopelvic fascia lies between, and is continuous with, both visceral and parietal layers of pelvic fascia. The loose, areolar portions of the endopelvic fascia have been removed; the fibrous, condensed portions remain. Note the condensation of this fascia into the hypogastric sheath, containing the vessels to the pelvic viscera, the ureters, and (in the male) the ductus deferens.
- Observe the ligamentous extensions of the hypogastric sheath: the lateral ligament of the urinary bladder, the transverse cervical ligament at the base of the broad ligament, and a less prominent lamina posteriorly containing the middle rectal vessels.





Authors: Agur, Anne M.R.; Dalley, Arthur F.

Title: *Grant's Atlas of Anatomy, 12th Edition*

Copyright ©2009 Lippincott Williams & Wilkins

> Table of Contents > Chapter 3 - Pelvis and Perineum > 3.46 Surface anatomy of male perineum

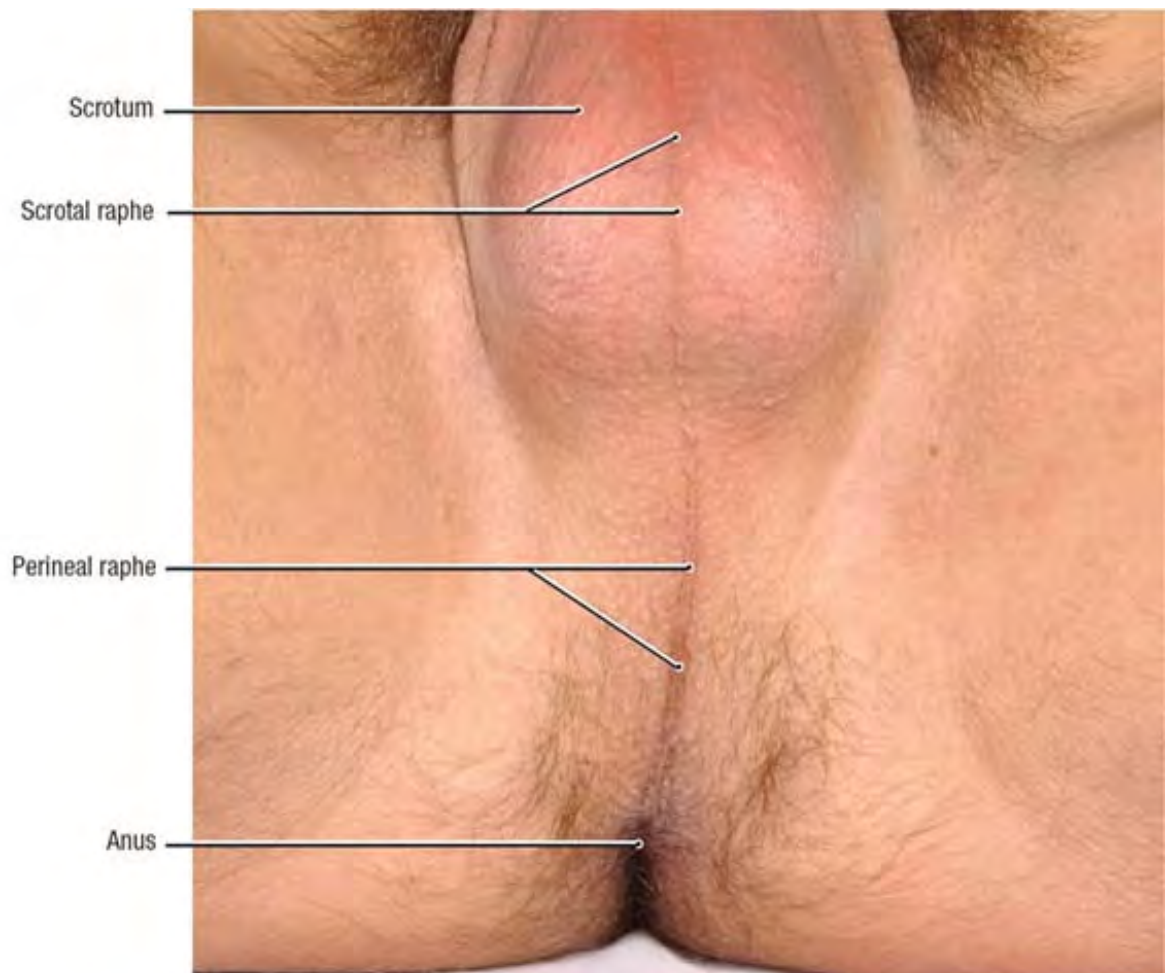
---

## 3.46 Surface anatomy of male perineum

Part of "Chapter 3 - Pelvis and Perineum "

A. Scrotum and anal region. B. Penis, scrotum, and anal region.

P.253





**A. Inferior View**

Pubic hairs covering pubic region

Root of penis

Body of penis

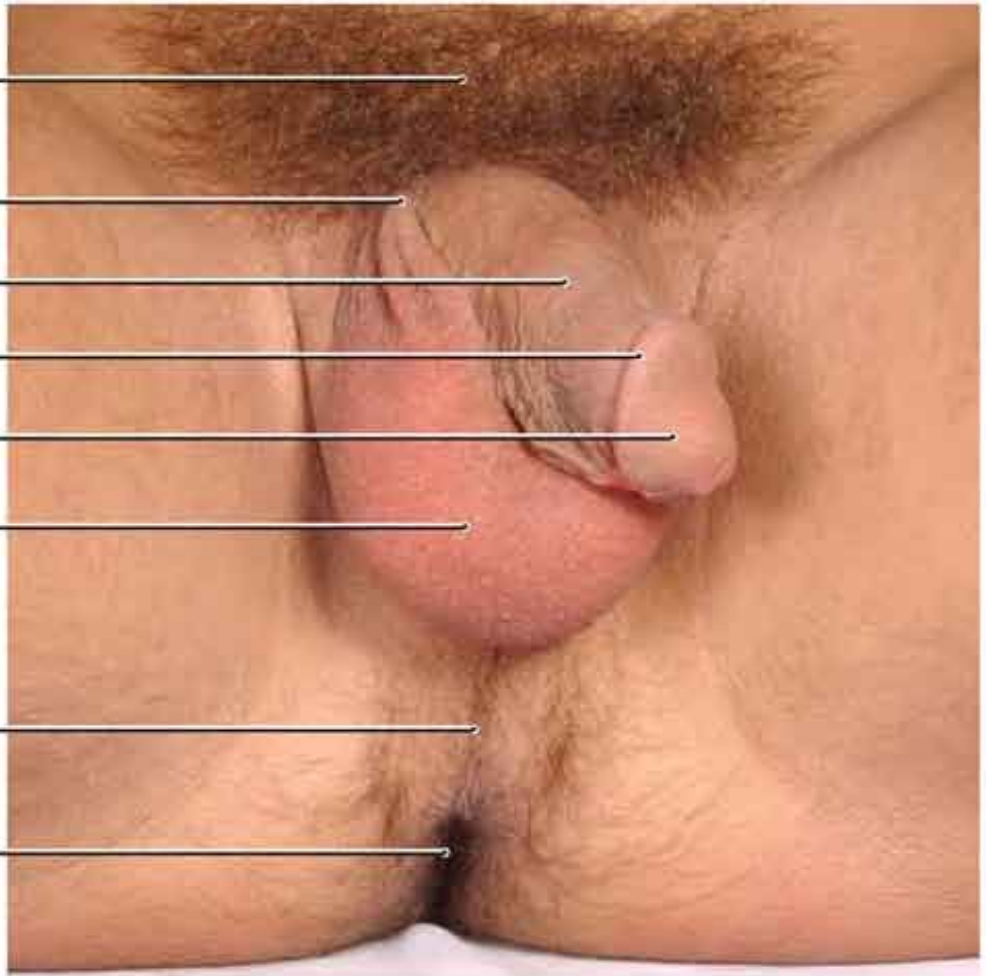Corona of penis

Glans penis

Scrotum

Perineal raphe

Anus



**B. Inferior View**

Authors: Agur, Anne M.R.; Dalley, Arthur F.

Title: *Grant's Atlas of Anatomy, 12th Edition*

Copyright ©2009 Lippincott Williams & Wilkins

> Table of Contents > Chapter 3 - Pelvis and Perineum > 3.47 Surface anatomy of the female perineum

---

## 3.47 Surface anatomy of the female perineum

*Part of* "Chapter 3 - Pelvis and Perineum "

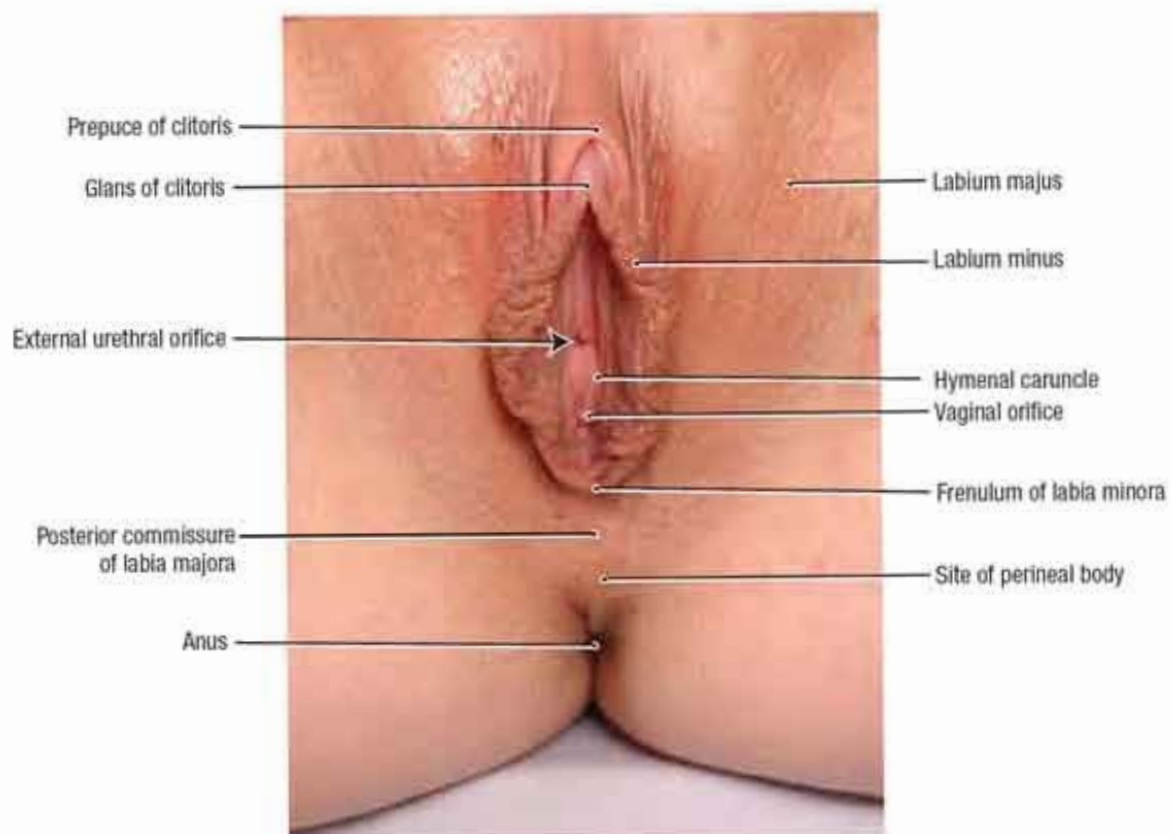
A. External genitalia (pudendum; vulva), standing position. B. Vestibule of vagina and the external urethral and vaginal orifices opening into it (recumbent position).

---

P.254



**A. Anterior View**



**B. Antero-inferior View (Lithotomy Position)**

Authors: Agur, Anne M.R.; Dalley, Arthur F.

Title: *Grant's Atlas of Anatomy, 12th Edition*

Copyright ©2009 Lippincott Williams & Wilkins

> Table of Contents > Chapter 3 - Pelvis and Perineum > 3.48 Male and female perineal compartments

---

## 3.48 Male and female perineal compartments

*Part of "Chapter 3 - Pelvis and Perineum "*

Figure 3.48 F. Sequential demonstration of structures of the perineal compartments, from deep to superficial. Figure 3.48 C. Deep perineal compartment (superior to perineal membrane). A. Pelvic diaphragm. B. Muscles of deep perineal compartment. C. Deep perineal vessels and nerves, covered by perineal membrane on right side.

---

P.255

Figure 3.48 F. Superficial perineal compartment (inferior to perineal membrane). D. Erectile bodies. E. Muscles of superficial perineal compartment. F. Superficial muscles imposed on surface anatomy of perineum.

---

P.256

External anal sphincter

Skin and fascia surrounding anus; coccyx via anococcygeal ligament

Passes around lateral aspects of anal canal; insertion into perineal body

Inferior anal (rectal) nerve, a branch of pudendal nerve (S2–S4)

Constricts anal canal during peristalsis, resisting defecation; supports and fixes perineal body and pelvic floor

Bulbospongiosus

*Male:* median raphe on ventral surface of bulb of penis; perineal body

*Male:* surrounds lateral aspects of bulb of penis and most proximal part of body of penis, inserting into perineal membrane, dorsal aspect of corpora spongiosum and cavernosa, and fascia of bulb of penis

Muscular (deep) branch of perineal nerve, a branch of the pudendal nerve (S2–S4)

*Male:* supports and fixes perineal body/pelvic floor; compresses bulb of penis to expel last drops of urine/semen; assists erection by compressing outflow via deep perineal vein and by pushing blood from bulb into body of penis

*Female:* perineal body

*Female:* passes on each side of lower vagina, enclosing bulb and greater vestibular gland; inserts onto pubic arch and fascia of corpora cavernosa of clitoris

*Female:* supports and fixes perineal body/pelvic floor; â€œsphincterâ€• of vagina; assists in erection of clitoris (and perhaps bulb of vestibule); compresses greater vestibular gland

Ischiocavernosus

Internal surface of ischiopubic ramus and ischial tuberosity

Embraces crus of penis or clitoris, inserting onto the inferior and medial aspects of the crus and to the perineal membrane medial to the crus

Maintains erection of penis or clitoris by compressing outflow veins and pushing blood from the root of penis or clitoris into the body of penis or clitoris

Superficial transverse

Internal surface of ischiopubic ramus and ischial tuberosity

Passes along inferior aspect of posterior border of perineal membrane to perineal body

Supports and fixes perineal body (pelvic floor) to support abdominopelvic viscera and resist increased intraabdominal pressure

Deep transverse perineal (male only)

Passes along superior aspect of posterior border of perineal membrane to perineal body, and external anal sphincter

Muscular (deep) branch of perineal nerve

Smooth muscle (female only)

Ischiopubic rami

Passes to lateral wall of urethra and vagina

Autonomic nerves

Quantity of smooth muscle increases with age; function uncertain

External urethral sphincter

Surrounds urethra superior to perineal membrane; in males, also ascends anterior aspect of prostate

Dorsal nerve of penis or clitoris, the terminal branch of the pudendal nerve (S2–S4)



Compresses urethra to maintain urinary continence

Compressor urethrae (females only)

Internal surface of ischiopubic ramus

Continuous with external urethral sphincter

Compresses urethra; with pelvic diaphragm; assists in elongation of urethra

Urethrovaginal sphincter (females only)

Anterior side of urethra

Continuous with compressor urethrae; extends posteriorly on lateral wall of urethra and vagina to interdigitate with fibers from opposite side of perineal body

Compresses urethra and vagina

Oelrich TM. The urethral sphincter muscle in the male. *Am J Anat* 1980;158:229â€“246.

Oelrich TM. The striated urogenital sphincter muscle in the female. *Anat Rec* 1983;205:223â€“232.

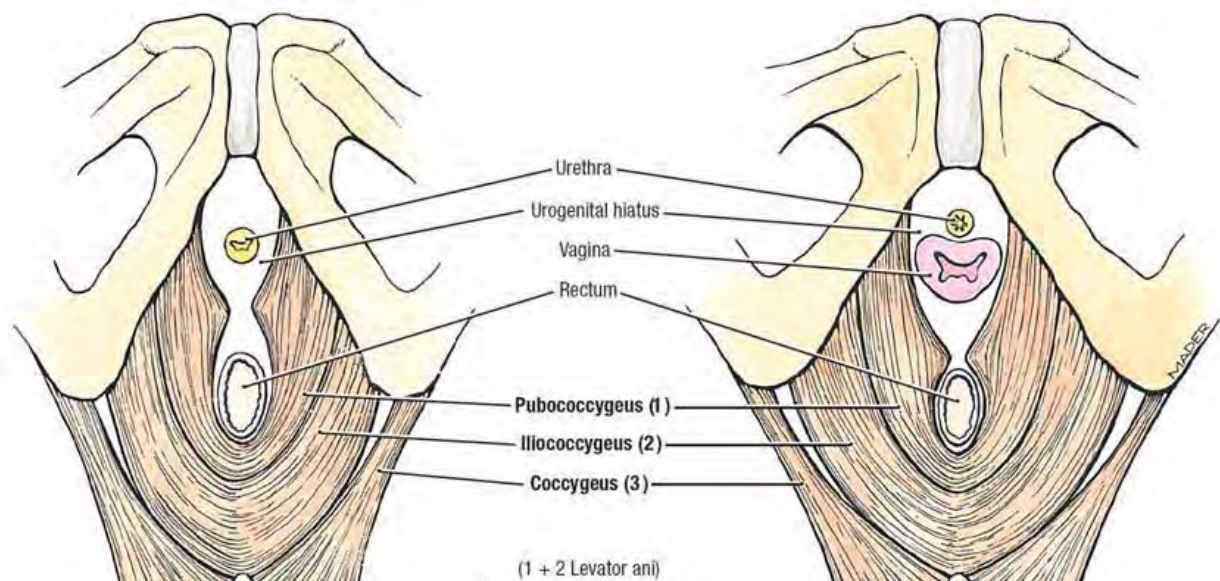
Mirilas P, Skandalakis JE. Urogenital diaphragm: an erroneous concept casting its shadow over the sphincter urethrae and deep perineal space. *J Am Coll Surg* 2004;198:279â€“290.

DeLancey JO. Correlative study of paraurethral anatomy. *Obstet Gynecol* 1986;68:91â€“97.

Muscle	Origin	Course and Insertion	Innervation	Main Action
--------	--------	----------------------	-------------	-------------

Table 3.9 Muscles of Perineum

P.257



A. Interior View



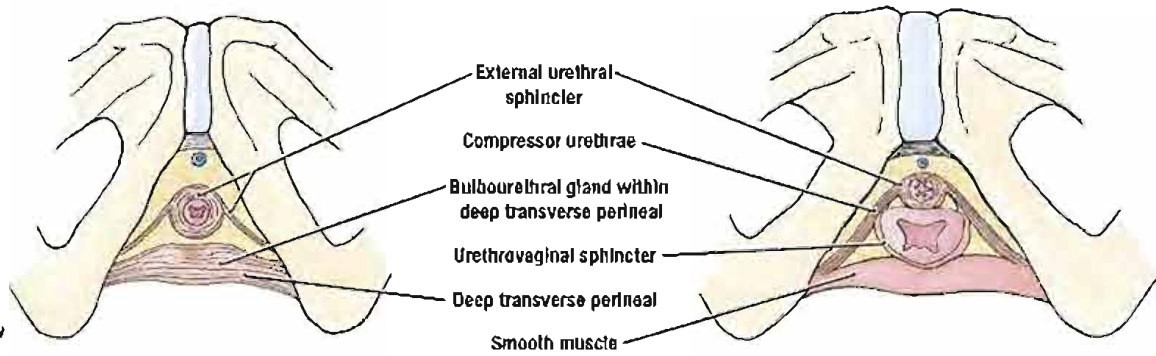
(1 + 2 + 3 Pelvic diaphragm)



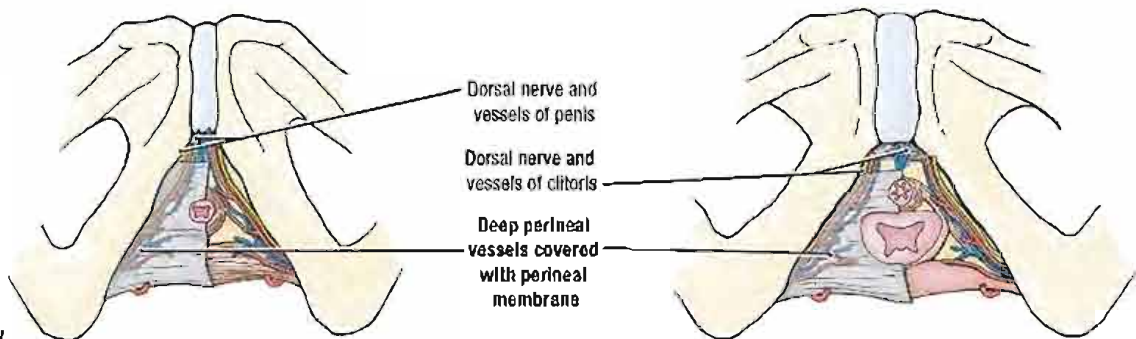
Male

Female

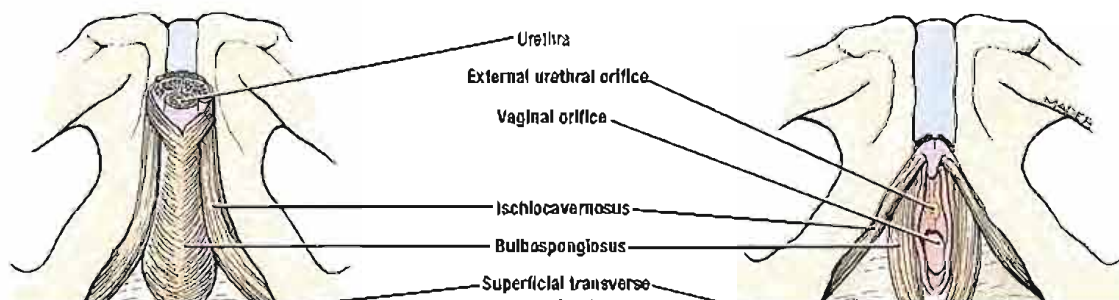
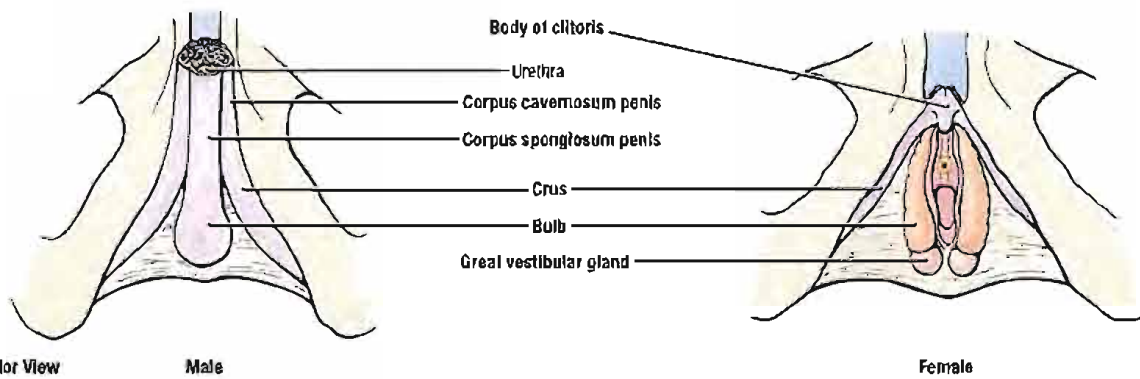
B. Interior View

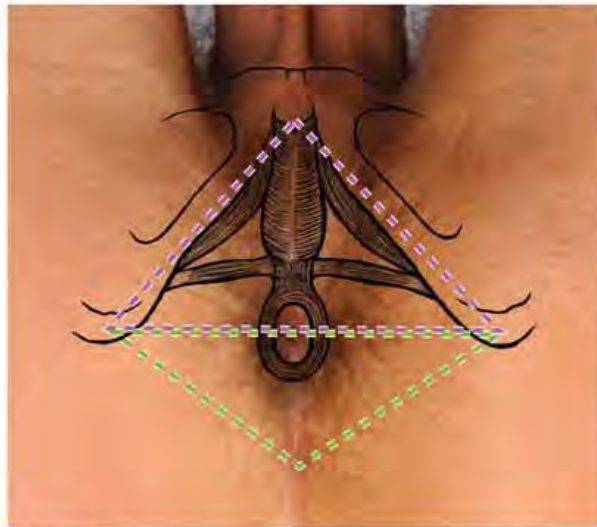
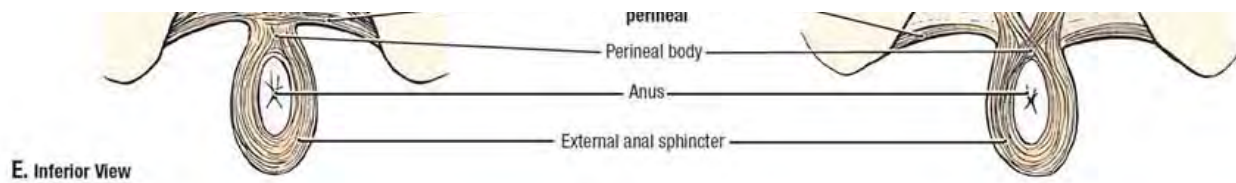


C. Interior View

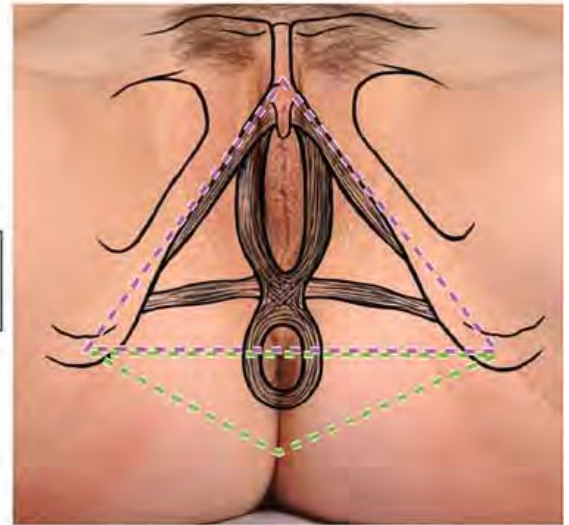


D. Interior View



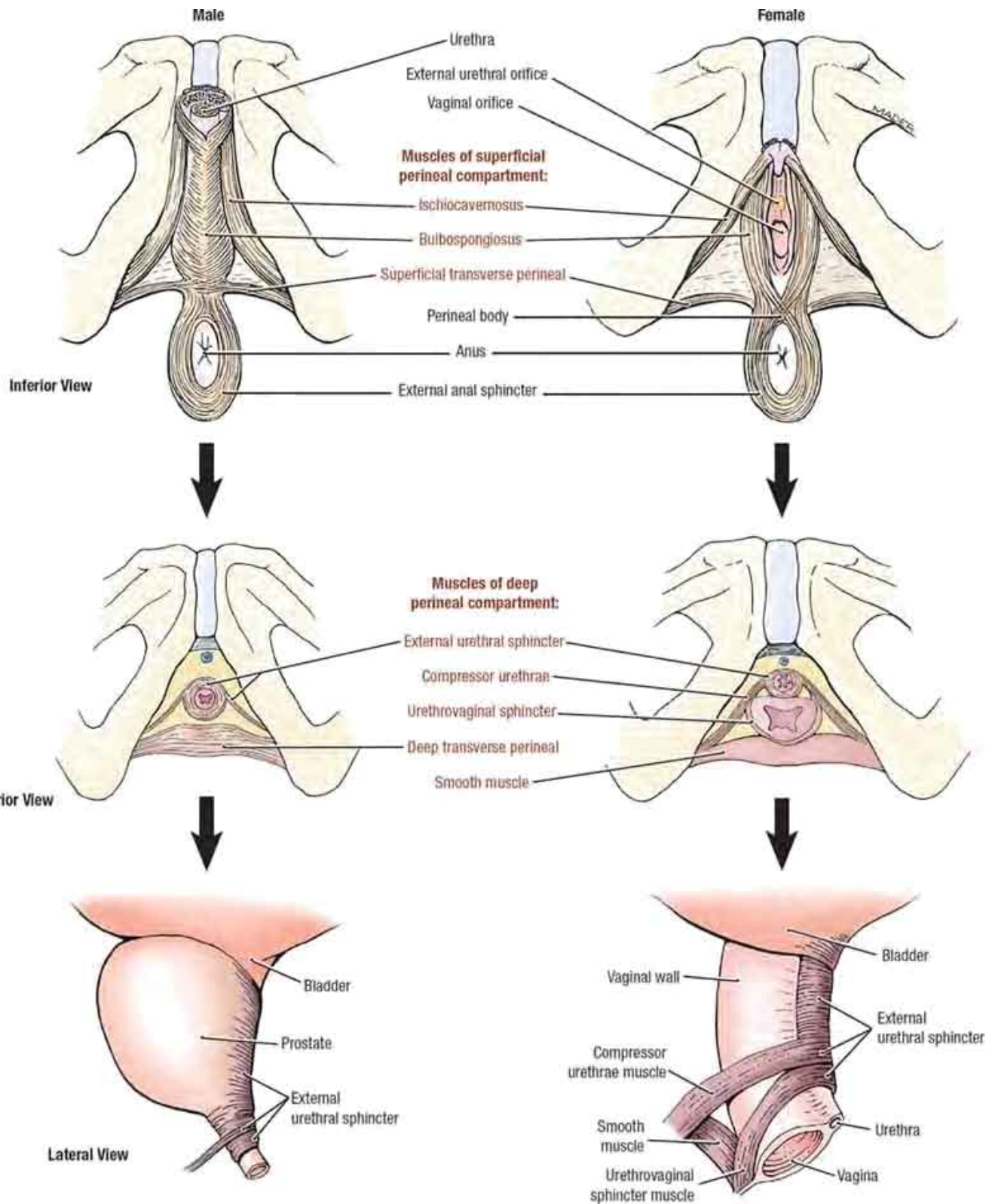


**F. Inferior View**



A potential subcutaneous perineal space (pouch) lies between the membranous layer of the subcutaneous tissue of the perineum and the perineal fascia (investing fascia of the superficial perineal muscles). The superficial perineal compartment (pouch) is an enclosed compartment bounded inferiorly by the perineal fascia and superiorly by the perineal membrane. The deep compartment is bounded inferiorly by the perineal membrane and continues superiorly to the (inferior investing fascia of the) pelvic diaphragm. (Oelich, 1980, 1983; DeLancy 1986; Mirilus, 2004).





Authors: Agur, Anne M.R.; Dalley, Arthur F.  
Title: *Grant's Atlas of Anatomy, 12th Edition*  
Copyright ©2009 Lippincott Williams & Wilkins

> Table of Contents > Chapter 3 - Pelvis and Perineum > 3.49 Perineal fascia and perineal compartments

## 3.49 Perineal fascia and perineal compartments

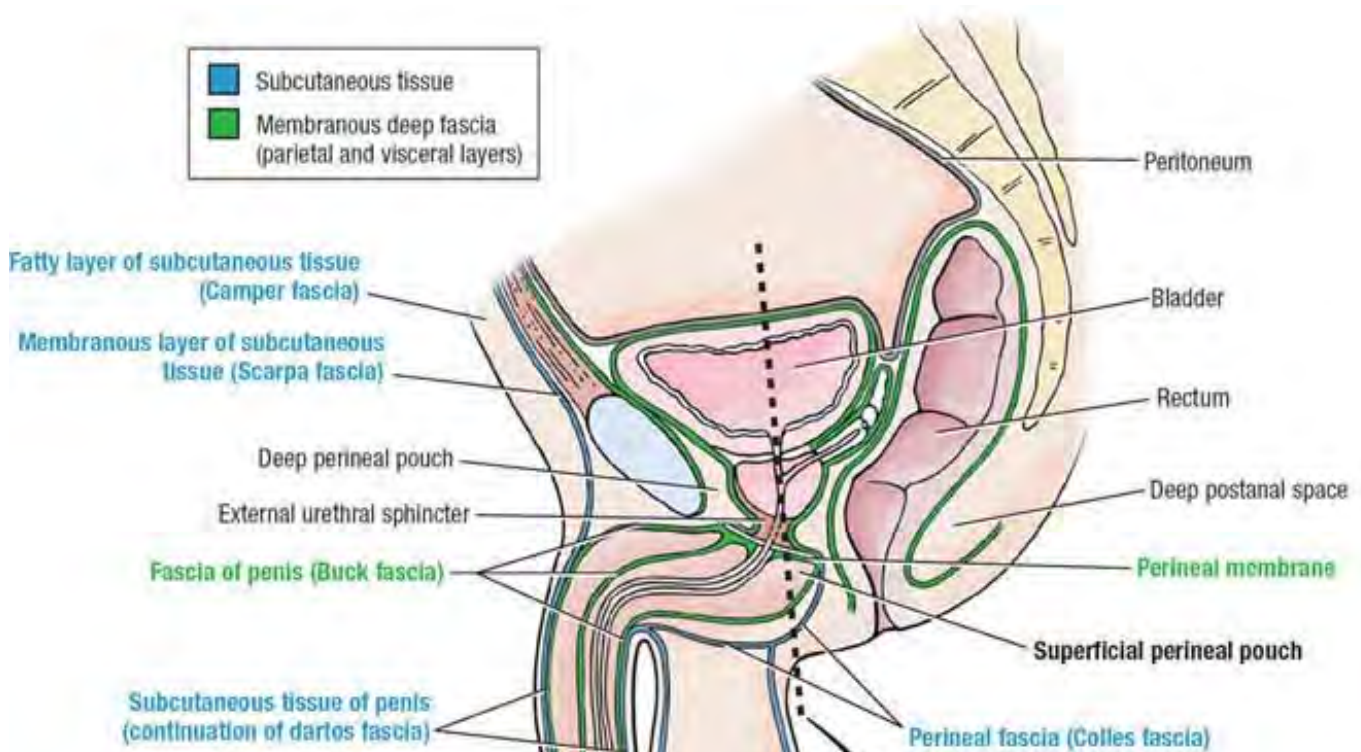
Part of "Chapter 3 - Pelvis and Perineum "

A. Fascia of male perineum, median section. B. Compartments of male perineum, coronal section.

P.259

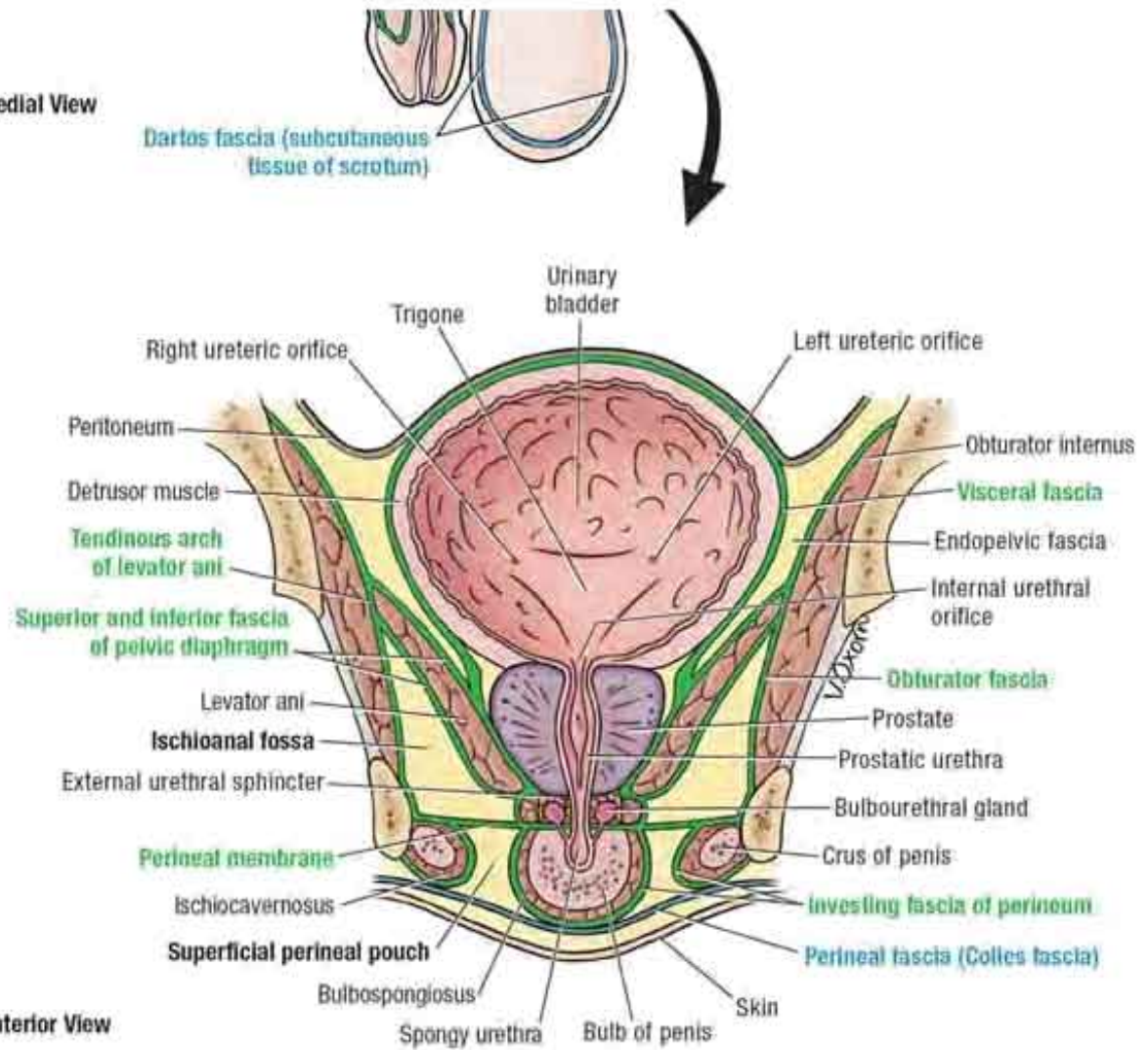
C. Fascia of female perineum, median section. D. Compartments of female perineum, coronal section.

P.260

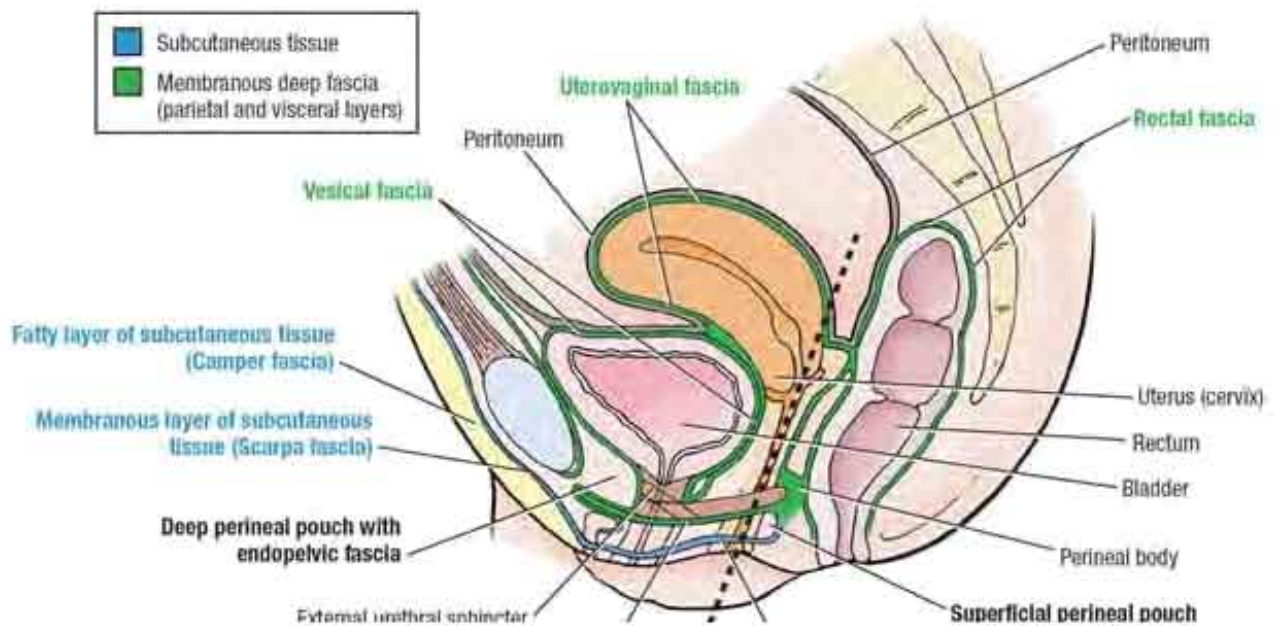




### A. Medial View



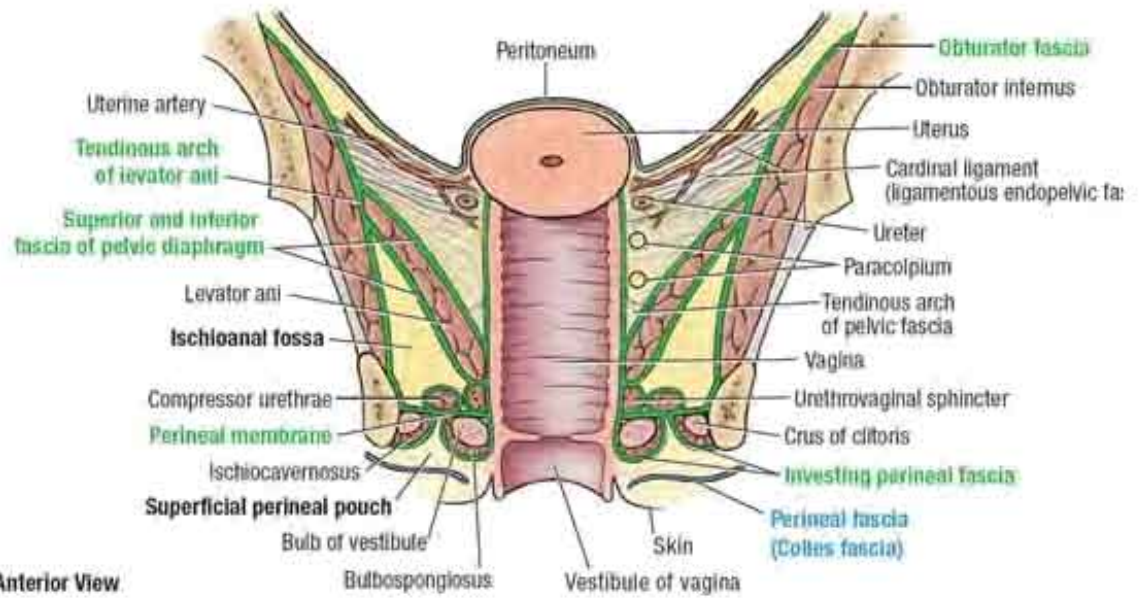
### B. Anterior View



C. Medial View

Perineal membrane

Perineal fascia (Colles fascia)



D. Anterior View

Authors: Agur, Anne M.R.; Dalley, Arthur F.

Title: *Grant's Atlas of Anatomy, 12th Edition*

Copyright ©2009 Lippincott Williams & Wilkins

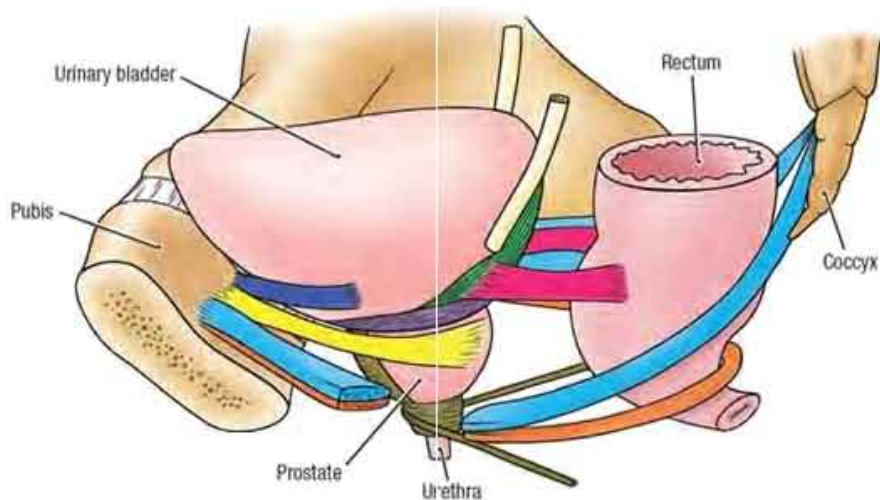
> Table of Contents > Chapter 3 - Pelvis and Perineum > 3.50 Supporting and  
compressor/sphincteric muscles of pelvis

---

## 3.50 Supporting and compressor/sphincteric muscles of pelvis

*Part of* "Chapter 3 - Pelvis and Perineum "

A. Male. B. Female.



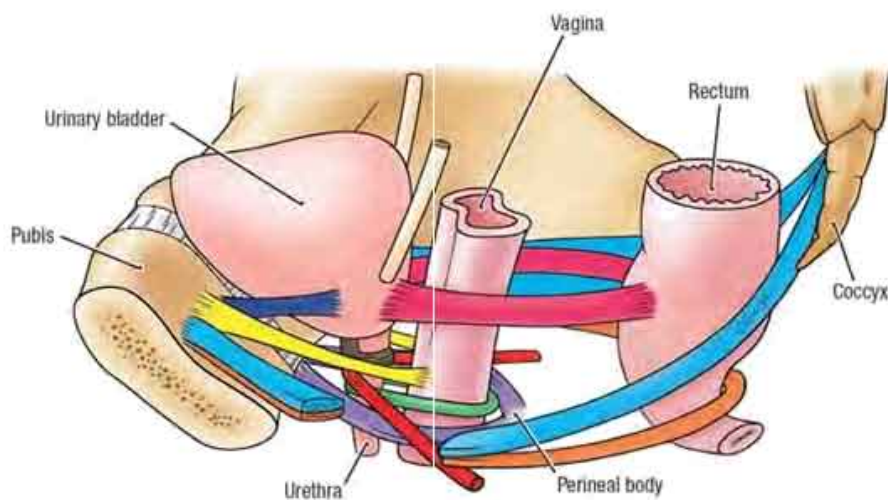
**A. Left Lateral View, Male**

**MALE:**

- Puboprostaticus
- Pubococcygeus
- Puborectalis
- Muscle of uvula
- Rectovesicalis

**Muscles compressing urethra:**

- Internal urethral sphincter
- Pubovesicalis
- External urethral sphincter



**B. Left Lateral View, Female**

**FEMALE:**

- Pubovesicalis
- Pubococcygeus
- Puborectalis
- Rectovesicalis

**Muscles compressing urethra:**

- Compressor urethrae
- External urethral sphincter

**Muscles compressing vagina:**

- Pubovaginalis
- Urethrovaginal sphincter (part of external urethral sphincter)
- Bulbospongiosus

Authors: Agur, Anne M.R.; Dalley, Arthur F.

Title: *Grant's Atlas of Anatomy, 12th Edition*

Copyright ©2009 Lippincott Williams & Wilkins

> Table of Contents > Chapter 3 - Pelvis and Perineum > 3.51 Dissection of male perineum

---

## 3.51 Dissection of male perineum

Part of "Chapter 3 - Pelvis and Perineum "

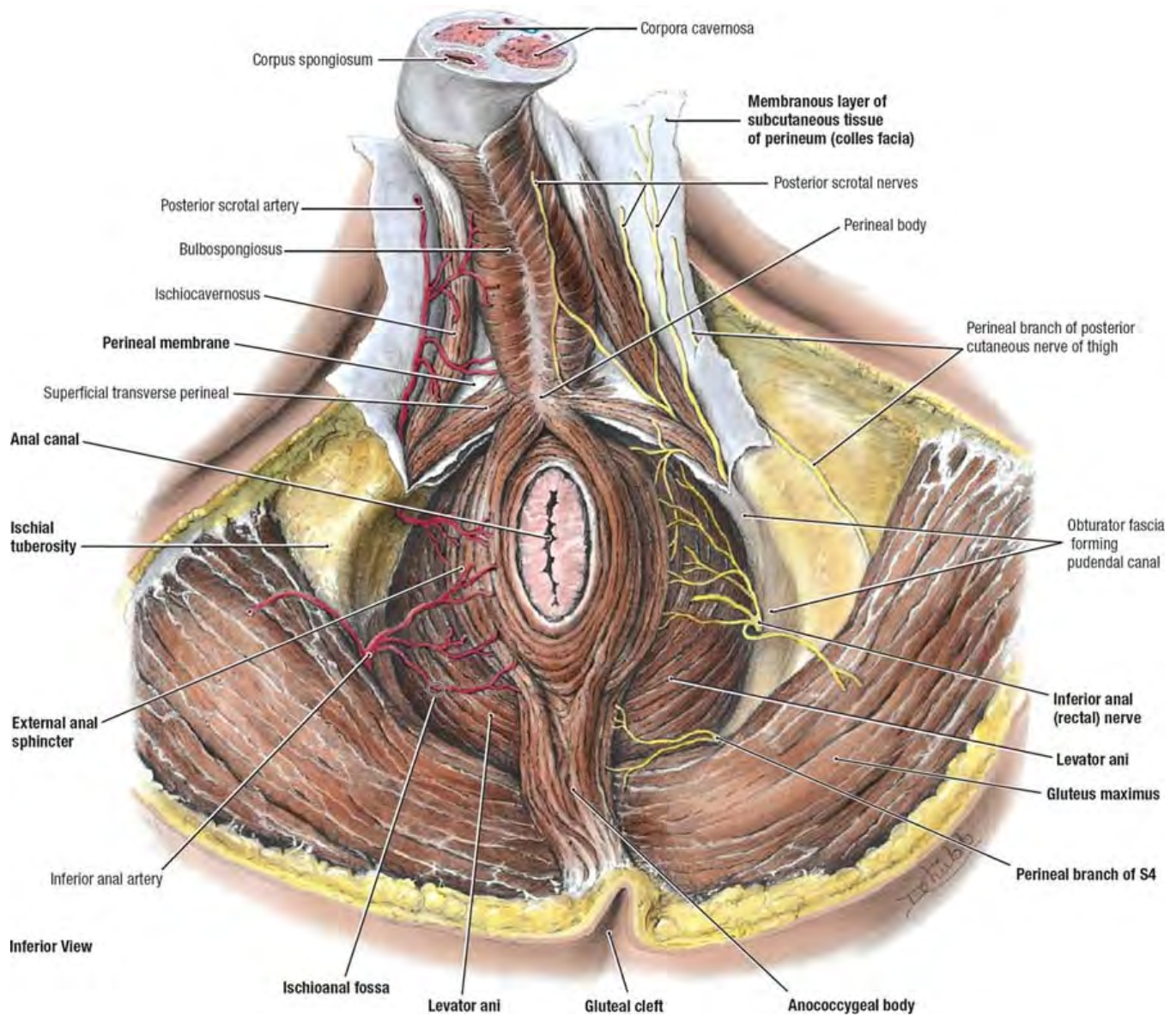
Superficial dissection.

- The membranous layer of subcutaneous tissue of the perineum was incised and reflected, opening the subcutaneous perineal compartment (pouch) in which the cutaneous nerves course.
- The perineal membrane is exposed between the three paired muscles of the superficial compartment; although not evident here, the muscles are individually ensheathed with investing fascia.
- The anal canal is surrounded by the external anal sphincter. The superficial fibers of the sphincter anchor the anal canal anteriorly to the perineal body and posteriorly, via the anococcygeal body (ligament), to the coccyx and skin of the gluteal cleft.
- Ischioanal (ischiorectal) fossae, from which fat bodies have been removed, lie on each side of the external anal sphincter. The fossae are also bound medially and superiorly by the levator ani; laterally by the ischial tuberosities and obturator internus fascia; and posteriorly by the gluteus maximus overlying the sacrotuberous ligaments. An anterior recess of each ischioanal fossa extends superior to the perineal membrane.
- In the lateral wall of the fossa, the inferior anal (rectal) nerve emerges from the pudendal canal and, with the perineal branch of S4, supplies the voluntary external anal sphincter and perianal skin; most cutaneous twigs have been



removed.

P.262



Authors: Agur, Anne M.R.; Dalley, Arthur F.

Title: *Grant's Atlas of Anatomy, 12th Edition*

Copyright ©2009 Lippincott Williams & Wilkins

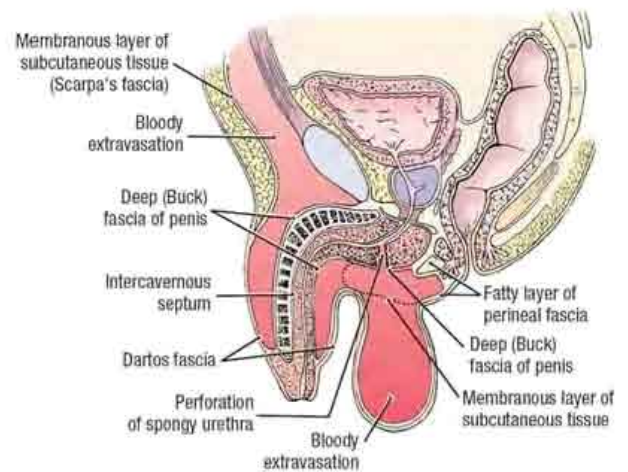
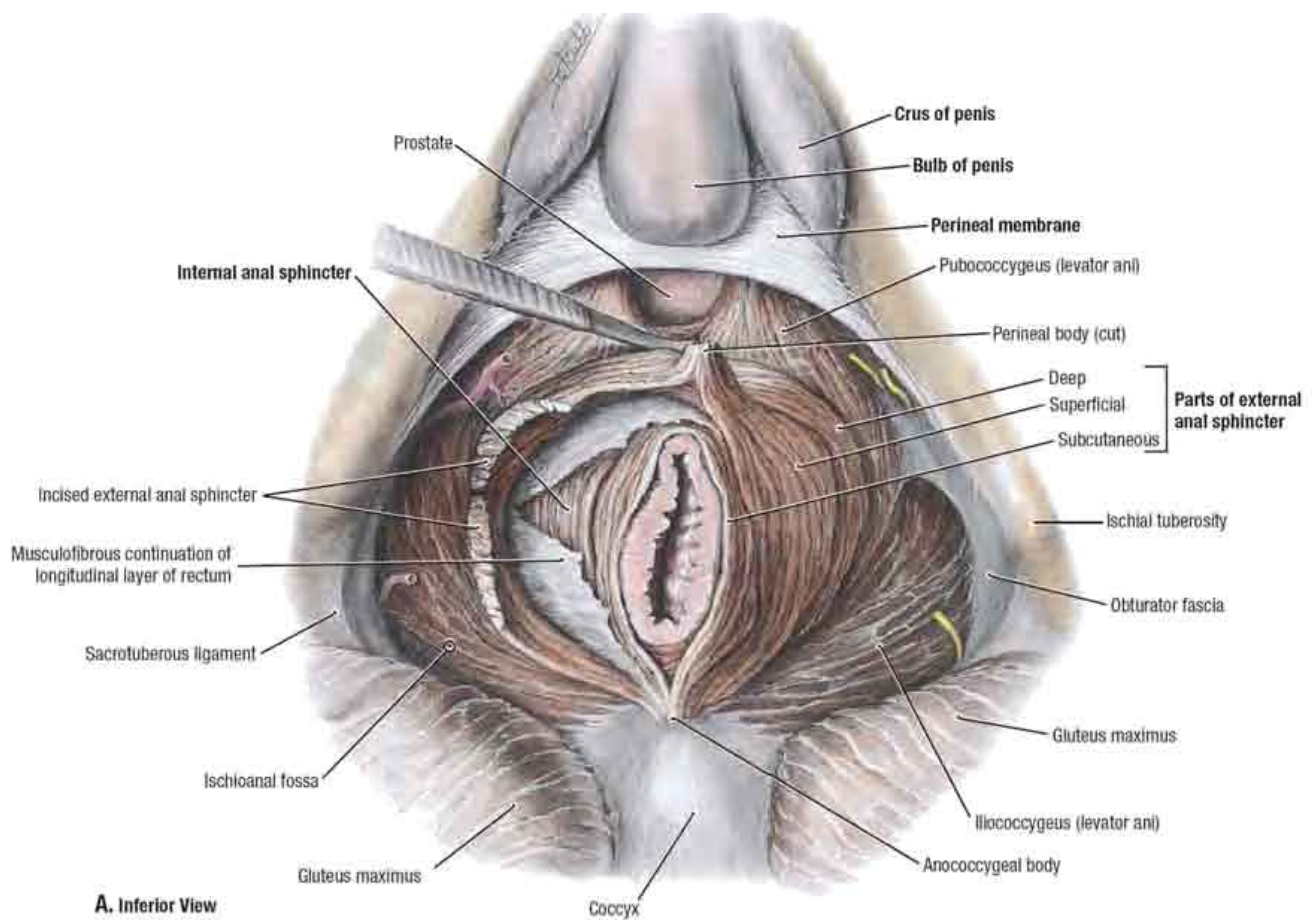
> Table of Contents > Chapter 3 - Pelvis and Perineum > 3.52 Dissection of the male perineum " II

---

## 3.52 Dissection of the male perineum " II

*Part of* "Chapter 3 - Pelvis and Perineum "

A. The superficial perineal muscles have been removed, revealing the roots of the erectile bodies (crura and bulb) of the penis, attached to the ischiopubic rami and perineal membrane. On the left side the superficial and deep parts of the external anal sphincter were incised and reflected; the underlying musculofibrous continuation of the outer longitudinal layer of the muscular layer of the rectum is cut to reveal thickening of the inner circular layer that comprises the internal anal sphincter. B. Rupture of the spongy urethra in the bulb of the penis results in urine passing (extravasating) into the subcutaneous perineal compartment. The attachments of the membranous layer of subcutaneous tissue determine the direction and restrictions of flow of the extravasated urine. Urine and blood may pass deep to the continuations of the membranous layer in the scrotum, penis, and inferior abdominal wall. The urine cannot pass laterally and inferiorly into the thighs because the membranous layer fuses with the fascia lata (deep fascia of the thigh), nor posteriorly into the anal triangle due to continuity with the perineal membrane and perineal body.



Authors: Agur, Anne M.R.; Dalley, Arthur F.

Title: *Grant's Atlas of Anatomy, 12th Edition*

Copyright ©2009 Lippincott Williams & Wilkins

> Table of Contents > Chapter 3 - Pelvis and Perineum > 3.53 Dissection of the male perineum " III

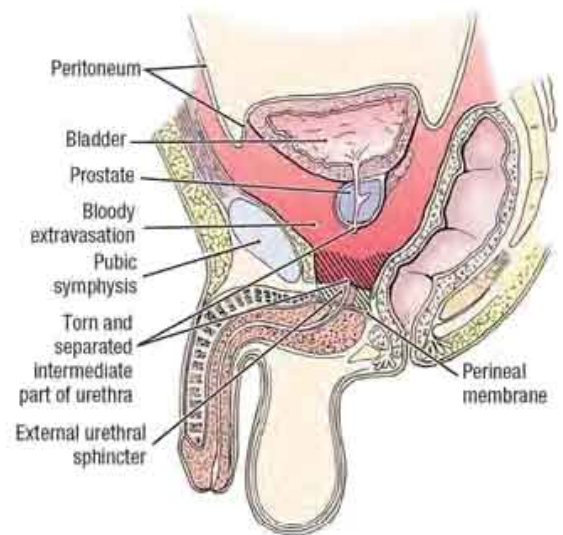
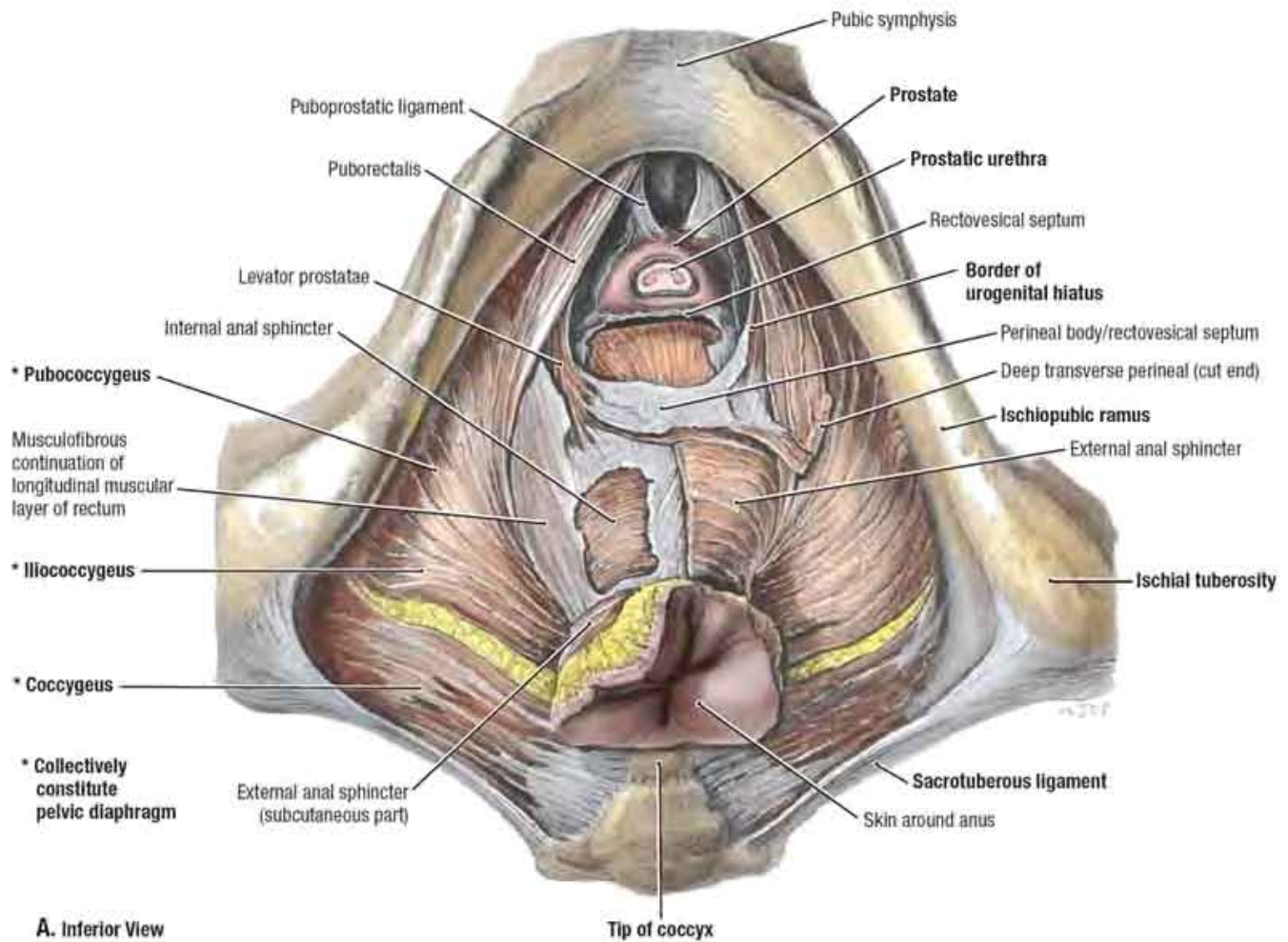
---

## 3.53 Dissection of the male perineum " III

*Part of* "Chapter 3 - Pelvis and Perineum "

A. The perineal membrane and structures superficial to it have been removed. The prostatic urethra, base of the prostate, and rectum are visible through the urogenital hiatus of the pelvic diaphragm. The osseofibrous boundaries are demonstrated. B. Rupture of the intermediate part of the urethra results in extravasation of urine and blood into the deep perineal compartment. The fluid may pass superiorly through the urogenital hiatus and distribute extraperitoneally around the prostate and bladder.









Authors: Agur, Anne M.R.; Dalley, Arthur F.

Title: *Grant's Atlas of Anatomy, 12th Edition*

Copyright ©2009 Lippincott Williams & Wilkins

> Table of Contents > Chapter 3 - Pelvis and Perineum > 3.54 Glans, prepuce, and neurovascular bundle of penis

---

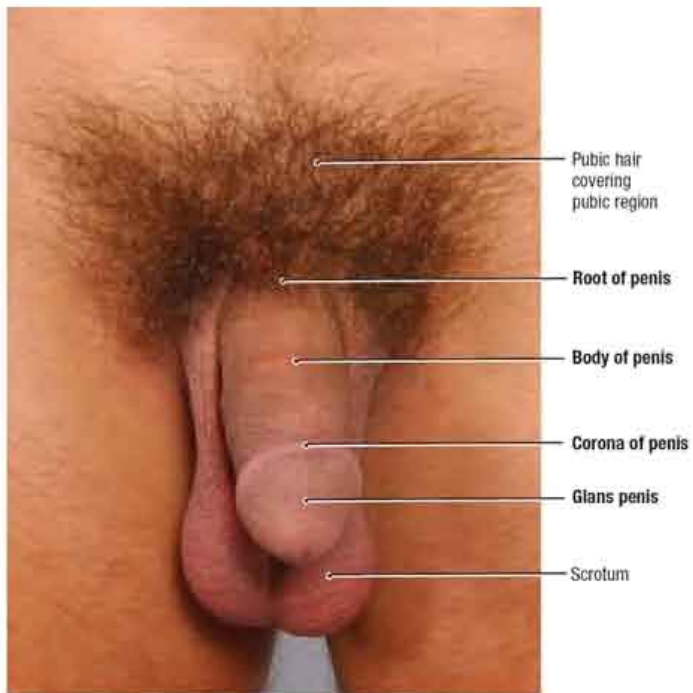## 3.54 Glans, prepuce, and neurovascular bundle of penis

*Part of* "Chapter 3 - Pelvis and Perineum "

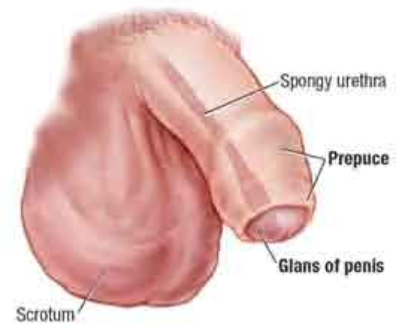
A. Surface anatomy, penis circumcised. B. Uncircumcised penis. C. Vessels and nerves of penis and contents of spermatic cord.

In C:

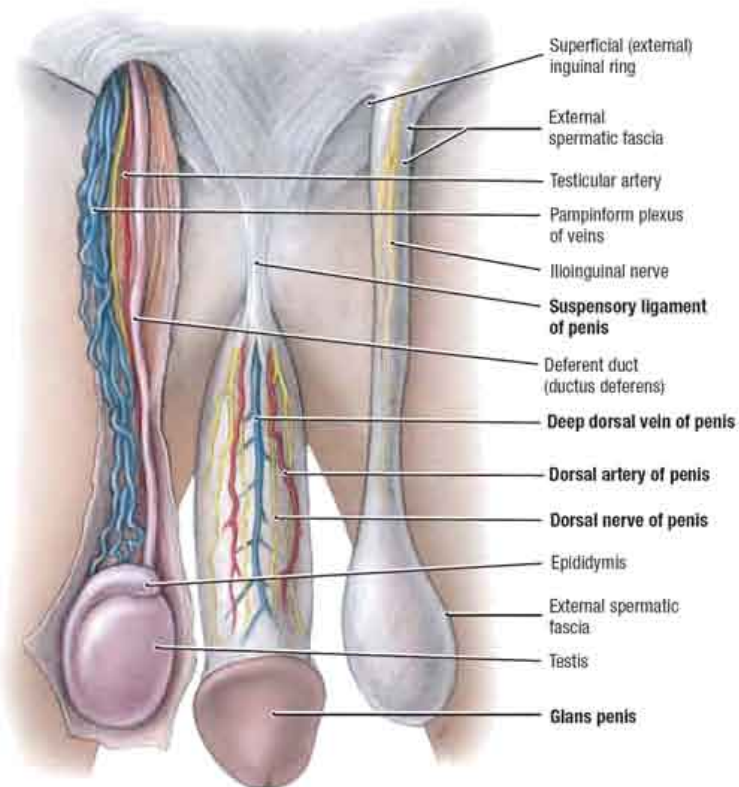
- The superficial and deep fasciae covering the penis are removed to expose the midline deep dorsal vein and the bilateral dorsal arteries and nerves of the penis. The triangular suspensory ligament of the penis attaches to the region of the pubic symphysis and blends with the deep fascia of the penis.
- On the specimen's left, the spermatic cord passes through the external inguinal ring and picks up a covering of external spermatic fascia from the margins of the superficial inguinal ring.
- On the specimen's right, the coverings of the spermatic cord and testis are incised and reflected, and the contents of the cord are separated.



**A. Anterior View**



**B. Right Anterolateral View**



**C. Anterior View**

Authors: Agur, Anne M.R.; Dalley, Arthur F.

Title: *Grant's Atlas of Anatomy, 12th Edition*

Copyright ©2009 Lippincott Williams & Wilkins

> Table of Contents > Chapter 3 - Pelvis and Perineum > 3.55 Layers and nerves of penis

---

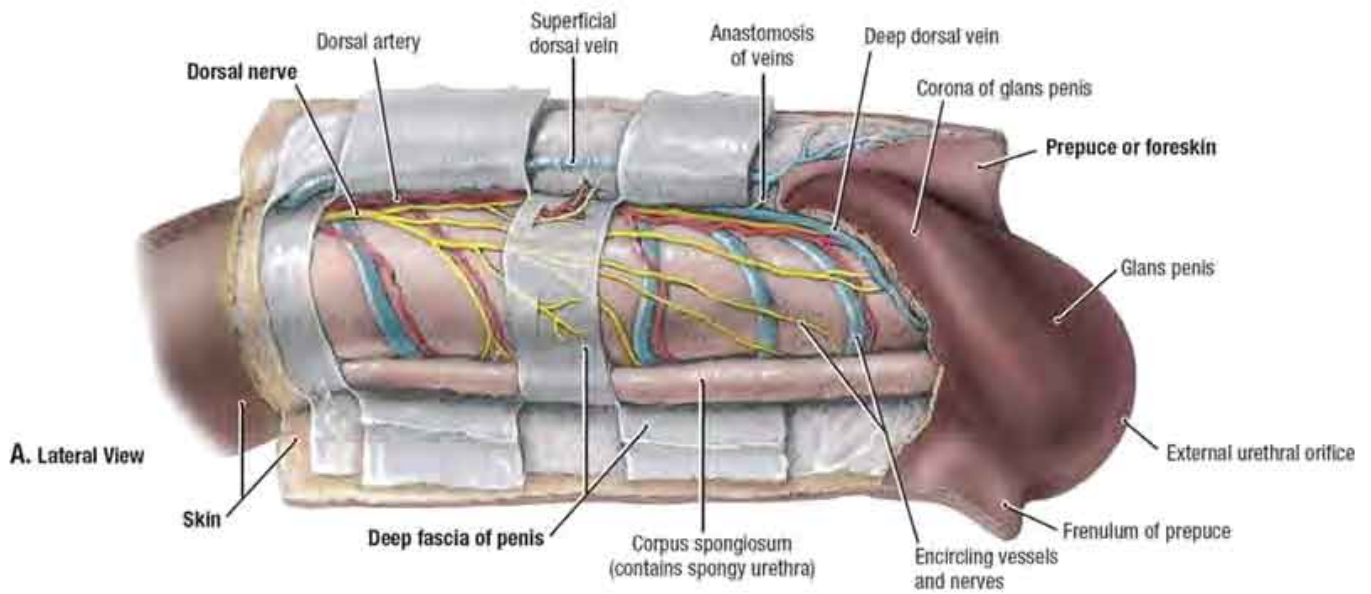
## 3.55 Layers and nerves of penis

*Part of* "Chapter 3 - Pelvis and Perineum "

A. Dissection. The skin, subcutaneous tissue, and deep fascia of the penis and prepuce are reflected separately. B. Distribution of pudendal nerve, right hemipelvis. Five regions transversed by the nerve are demonstrated.

---

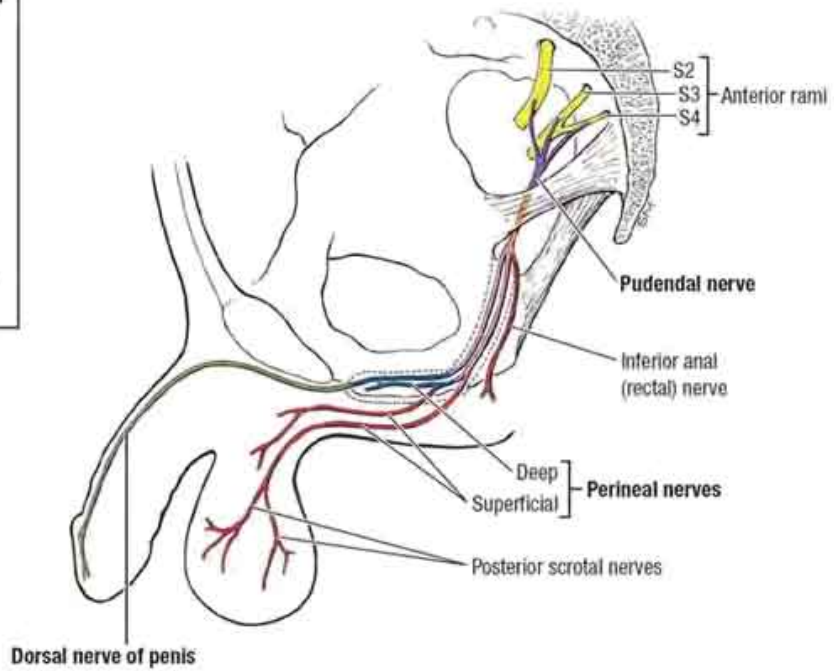
P.266



**Regions traversed by pudendal nerve and its branches:**

- Pelvis
- Gluteal region
- Pudendal canal
- Deep perineal pouch
- Dorsum of penis
- Superficial perineum (superficial compartment, ischioanal fossae)

**B. Medial View**





Authors: Agur, Anne M.R.; Dalley, Arthur F.

Title: *Grant's Atlas of Anatomy, 12th Edition*

Copyright ©2009 Lippincott Williams & Wilkins

> Table of Contents > Chapter 3 - Pelvis and Perineum > 3.56 Male urogenital system, erectile bodies

---

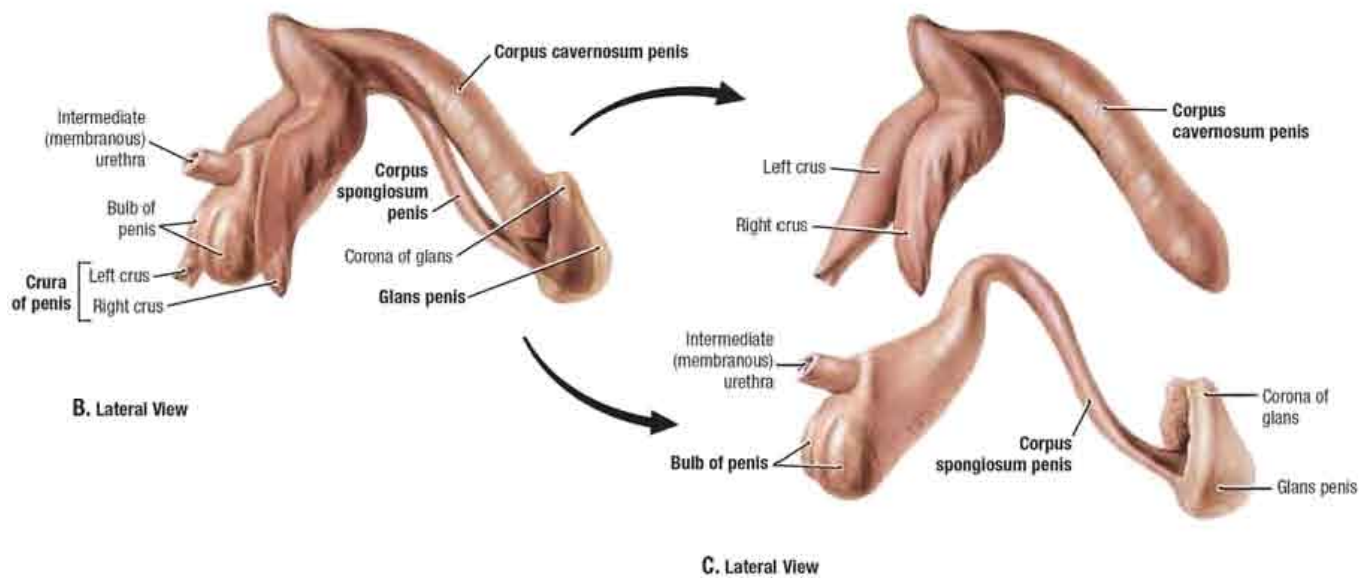
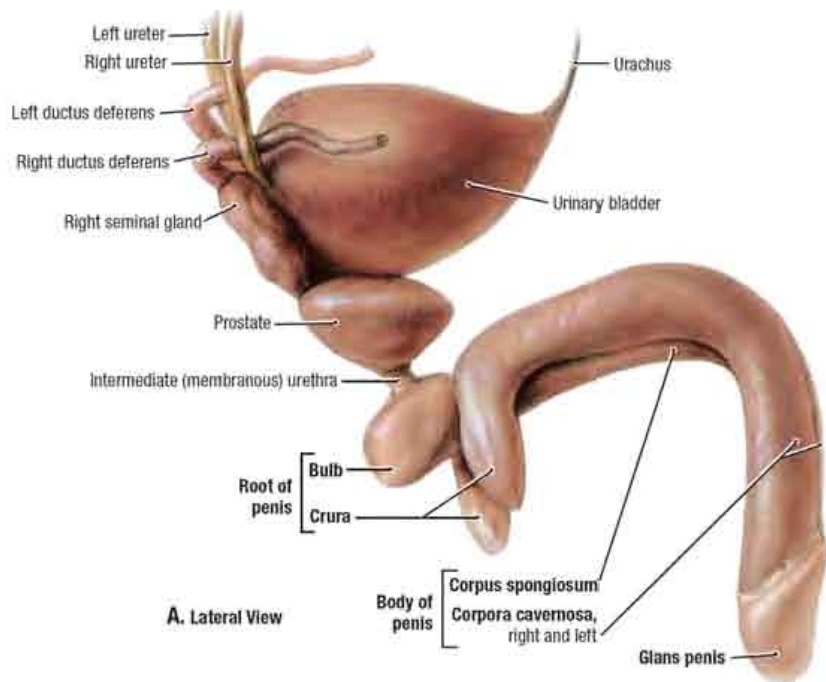
## 3.56 Male urogenital system, erectile bodies

*Part of* "Chapter 3 - Pelvis and Perineum "

A. Pelvic components of genital and urinary tracts and erectile bodies of perineum. B. Dissection of male erectile bodies (corpora cavernosa and corpus spongiosum). C. Corpus spongiosum and corpora cavernosa, separated. The corpora cavernosa is bent where the penis is suspended by the suspensory ligament of the penis from the pubic symphysis. The corpus spongiosum extends posteriorly as the bulb of the penis and terminates anteriorly as the glans.

---

P.267



Authors: Agur, Anne M.R.; Dalley, Arthur F.

Title: *Grant's Atlas of Anatomy, 12th Edition*

Copyright ©2009 Lippincott Williams & Wilkins

> Table of Contents > Chapter 3 - Pelvis and Perineum > 3.57 Cross sections of penis

---

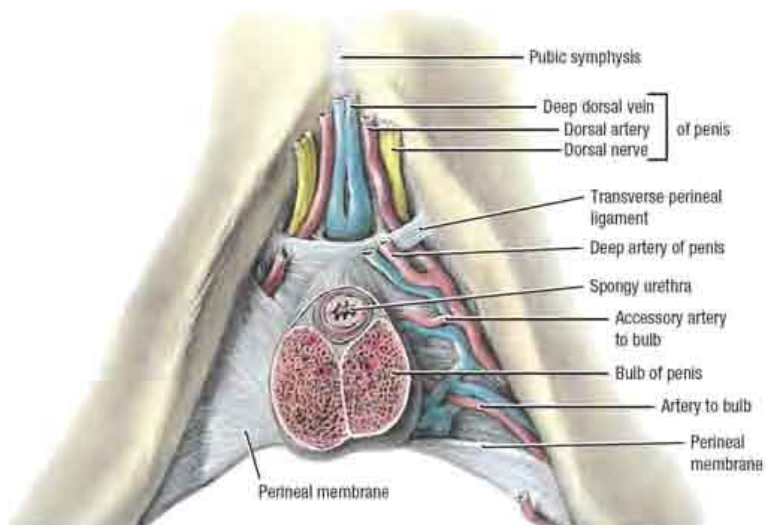
## 3.57 Cross sections of penis

*Part of* "Chapter 3 - Pelvis and Perineum "

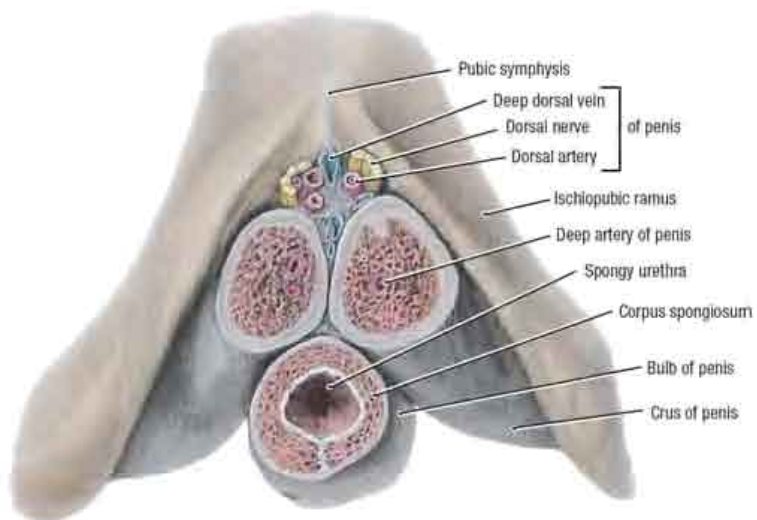
A. Transverse section through bulb of penis with crura removed. The bulb is cut posterior to the entry of the intermediate urethra. On the left side, the perineal membrane is partially removed, opening the deep perineal compartment. B. The crura and bulb of penis have been sectioned obliquely. The spongy urethra is dilated within the bulb of the penis. C. Transverse section through body of penis. D. Transverse section through the proximal part of the glans penis. E. Transverse section through the distal part of the glans penis.

---

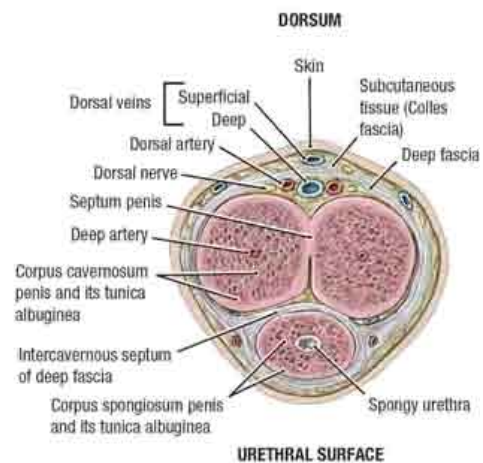
P.268



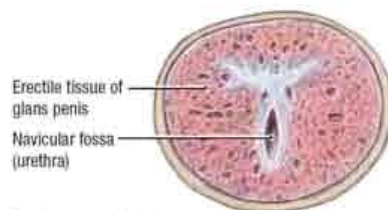
**A. Anterior/Inferior View**



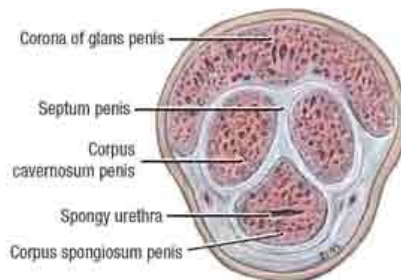
**B. Anterior View**



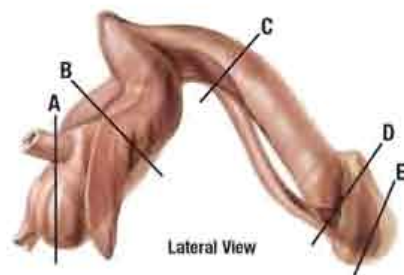
**C. Transverse Section**



**D. Transverse Section**



**E. Transverse Section**



**Lateral View**

Authors: Agur, Anne M.R.; Dalley, Arthur F.

Title: *Grant's Atlas of Anatomy, 12th Edition*

Copyright ©2009 Lippincott Williams & Wilkins

> Table of Contents > Chapter 3 - Pelvis and Perineum > 3.58 Urethra

---

## 3.58 Urethra

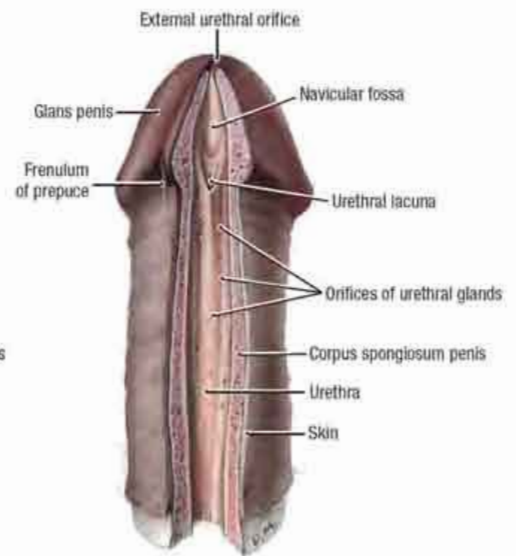
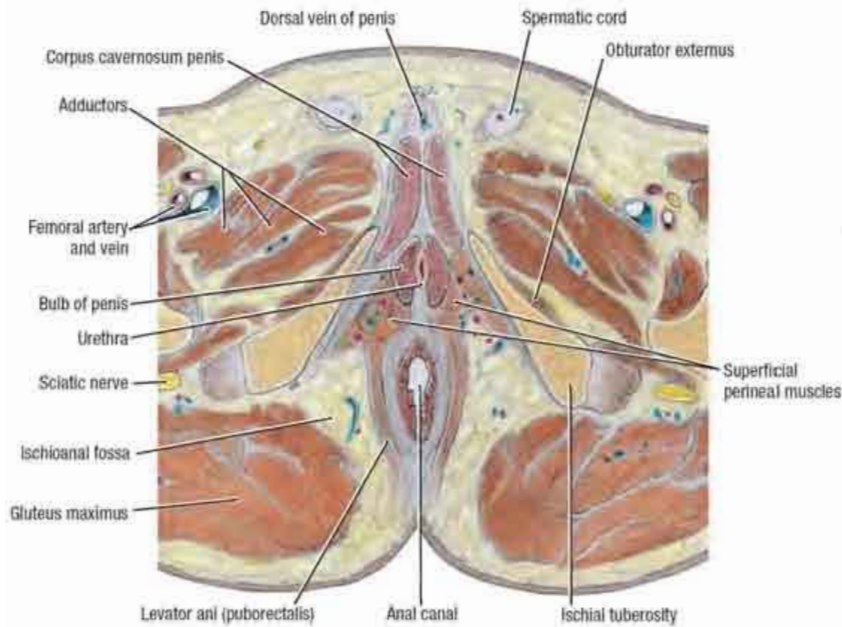
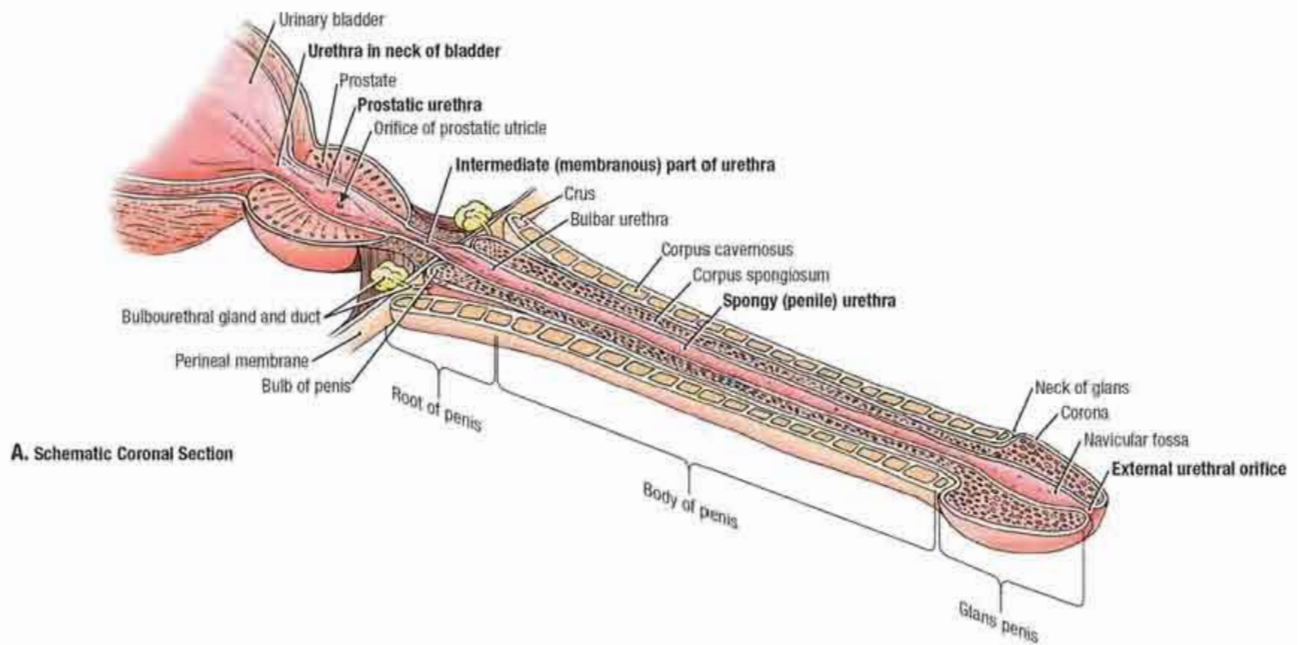
*Part of* "Chapter 3 - Pelvis and Perineum "

A. Urethra and related structures. B. Transverse section of body passing through the bulb of the penis. C. Spongy urethra, interior. A longitudinal incision was made on the urethral surface of the penis and carried through the floor of the urethra, allowing a view of the dorsal surface of the interior of the urethra.

---

P.269





Authors: Agur, Anne M.R.; Dalley, Arthur F.

Title: *Grant's Atlas of Anatomy, 12th Edition*

Copyright ©2009 Lippincott Williams & Wilkins

> Table of Contents > Chapter 3 - Pelvis and Perineum > 3.59 Female perineum

---

## 3.59 Female perineum

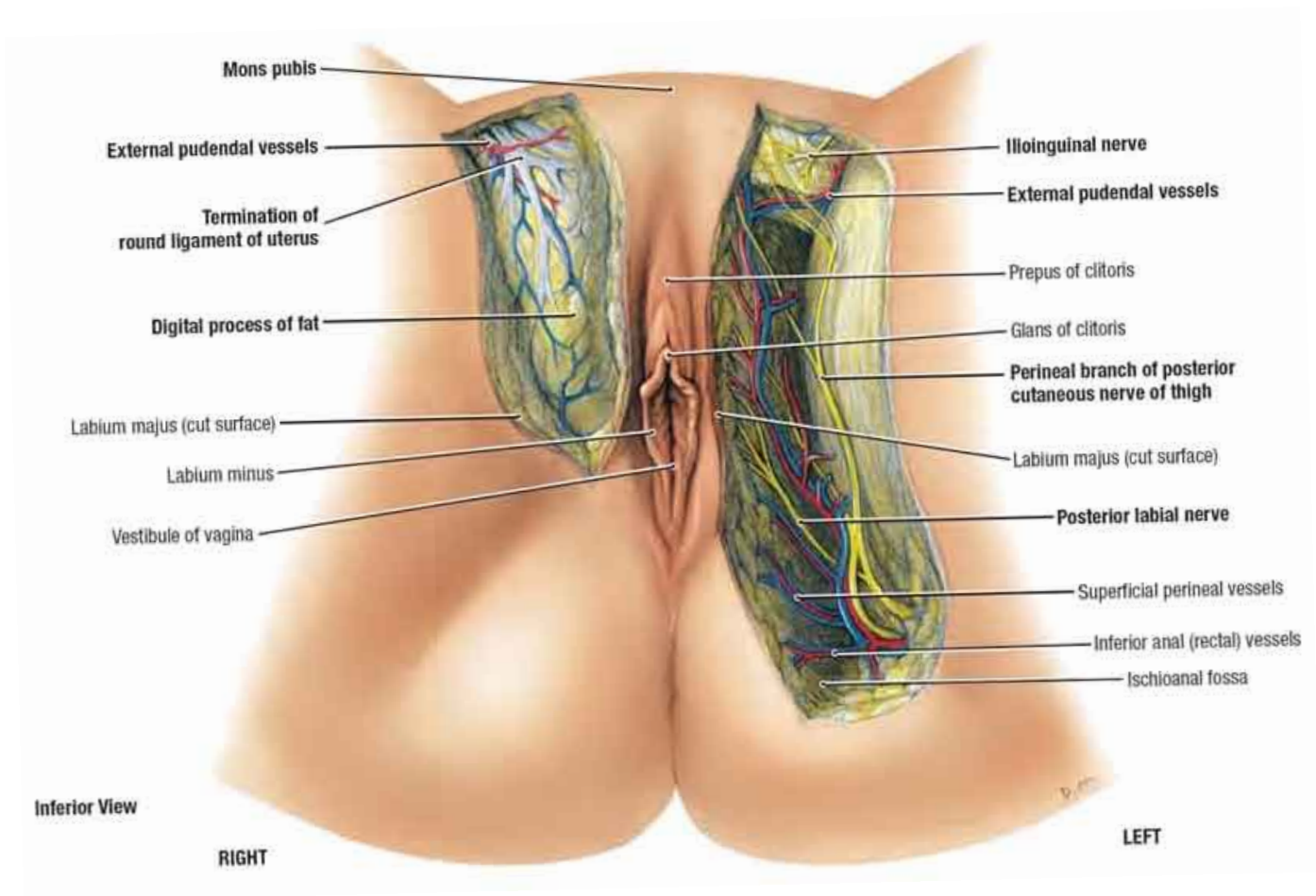
Part of "Chapter 3 - Pelvis and Perineum "

Superficial dissection. On the right side of the specimen:

- A long digital process of fat lies deep to the subcutaneous fatty tissue and descends into the labium majus.
- The round ligament of the uterus ends as a branching band of fascia that spreads out superficial to the fatty digital process.

On the left side of the specimen:

- Most of the fatty digital process is removed.
- The mons pubis is the rounded fatty prominence anterior to the pubic symphysis and bodies of the pubic bones.
- The posterior labial vessels and nerves (S2, S3) are joined by the perineal branch of the posterior cutaneous nerve of thigh (S1, S2, S3) and run anteriorly to the mons pubis. At the mons pubis the vessels anastomose with the external pudendal vessels, and the nerves overlap in supply with the ilioinguinal nerve (L1).



Authors: Agur, Anne M.R.; Dalley, Arthur F.

Title: *Grant's Atlas of Anatomy, 12th Edition*

Copyright ©2009 Lippincott Williams & Wilkins

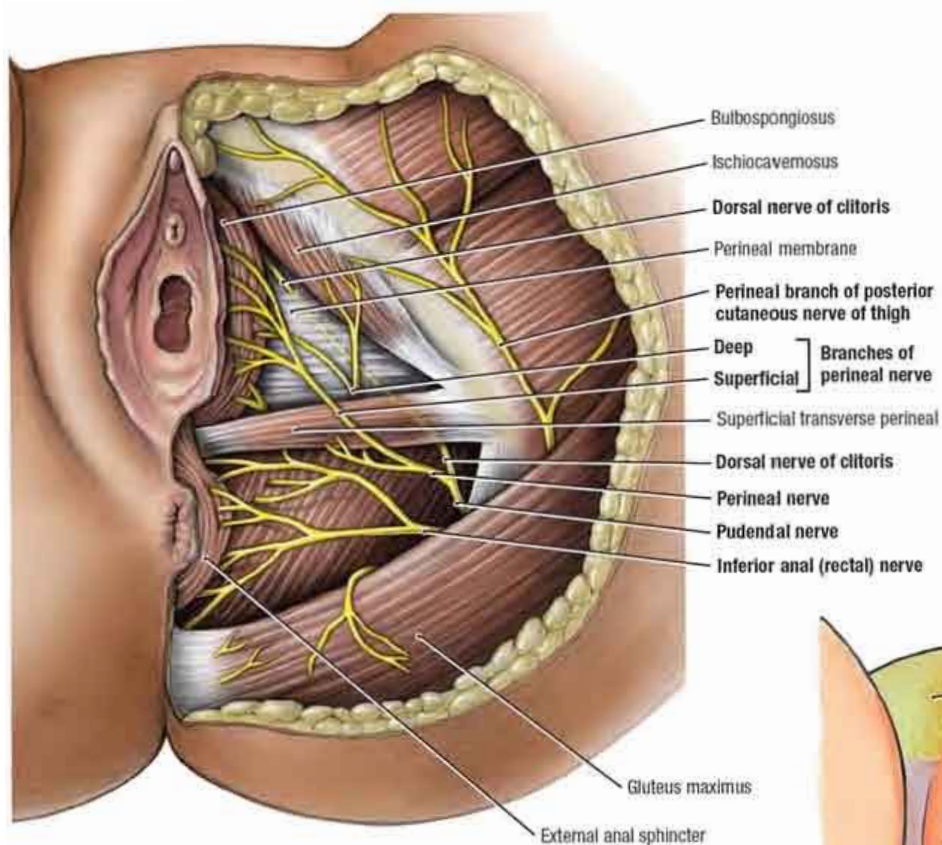
> Table of Contents > Chapter 3 - Pelvis and Perineum > 3.60 Innervation of the female perineum

---

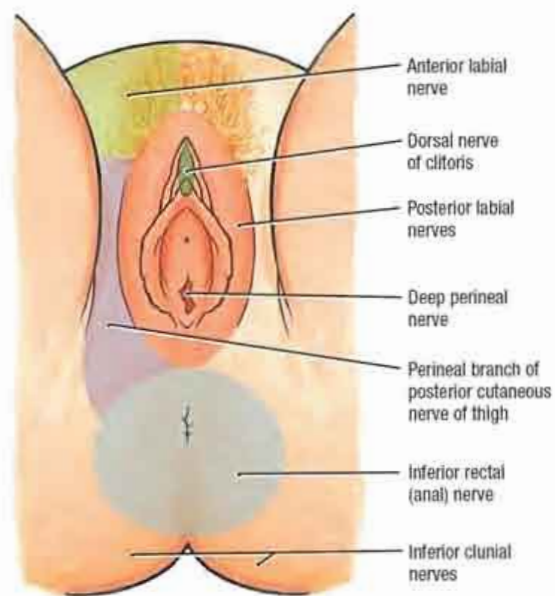
## 3.60 Innervation of the female perineum

*Part of "Chapter 3 - Pelvis and Perineum "*

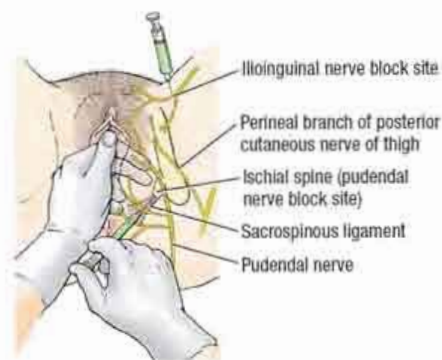
A and B. The anterior aspect of the perineum is supplied by anterior labial nerves, derived from the ilioinguinal nerve and genital branch of the genitofemoral nerve. The pudendal nerve is the main nerve of the perineum. Posterior labial nerves, derived from the superficial perineal nerve, supply most of the vulva. The deep perineal nerve supplies the orifice of the vagina and superficial perineal muscles; and the dorsal nerve of the clitoris supplies deep perineal muscles and sensations to the clitoris. The inferior anal (rectal) nerve, also from the pudendal nerve, innervates the external anal sphincter and the perianal skin. The lateral perineum is supplied by the perineal branch of the posterior cutaneous nerve of the thigh. C. To relieve the pain experienced during childbirth, pudendal nerve block anesthesia may be performed by injecting a local anesthetic agent into the tissue surrounding the pudendal nerve, near the ischial spine. A pudendal nerve block does not abolish sensations from the anterior and lateral parts of the perineum. Therefore, a block of the ilioinguinal and/or perineal branch of the posterior cutaneous nerve of the thigh may also need to be performed.



**A. Inferior View**



**B. Inferior View**



**C. Inferior View**



Authors: Agur, Anne M.R.; Dalley, Arthur F.

Title: *Grant's Atlas of Anatomy, 12th Edition*

Copyright ©2009 Lippincott Williams & Wilkins

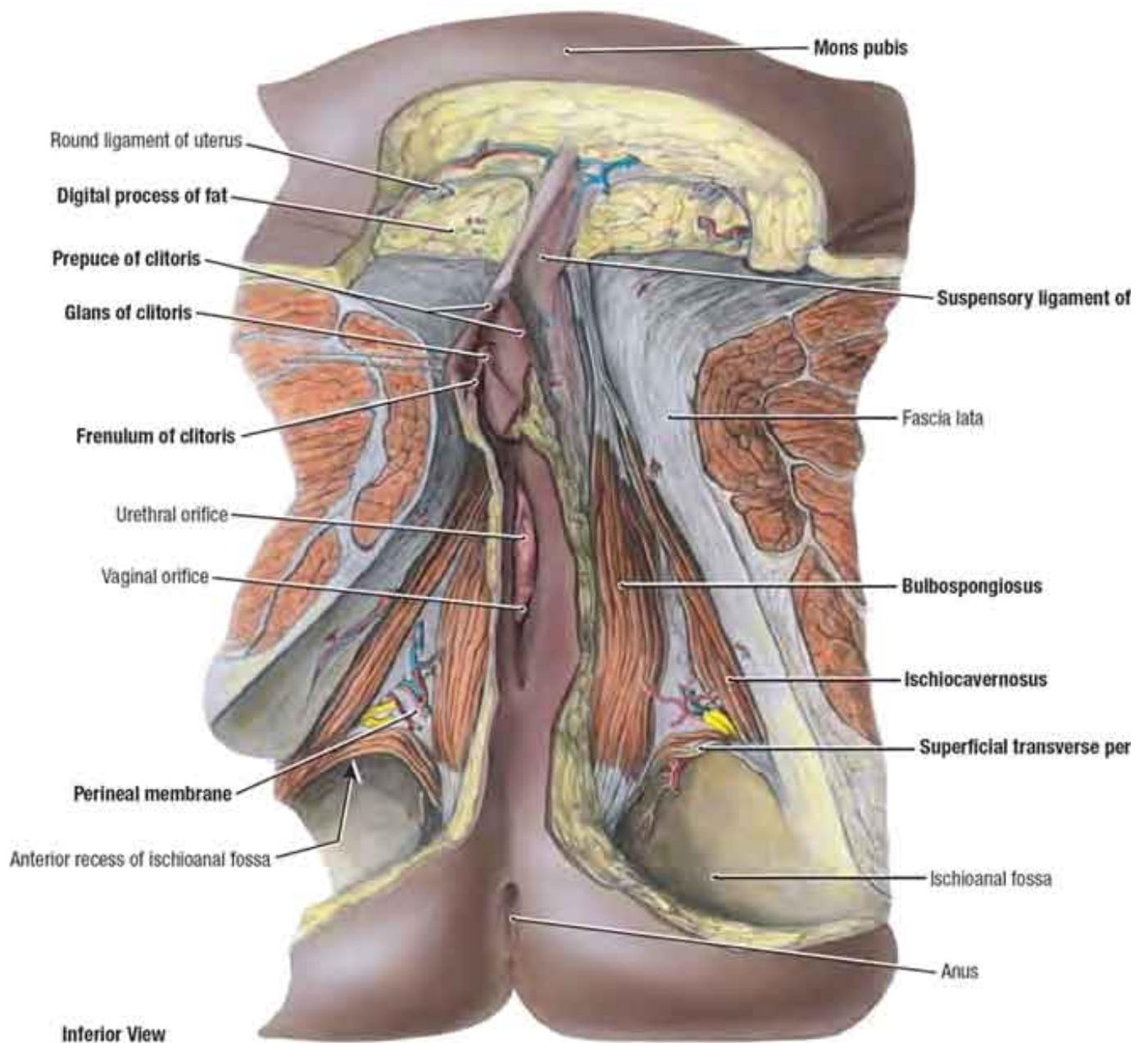
> Table of Contents > Chapter 3 - Pelvis and Perineum > 3.61 Female perineum II

---

## 3.61 Female perineum II

*Part of* "Chapter 3 - Pelvis and Perineum "

- Note the thickness of the subcutaneous fatty tissue of the mons pubis and the encapsulated digital process of fat deep to this. The suspensory ligament of the clitoris descends from the linea alba.
- Anteriorly, each labium minus forms two laminae or folds: the lateral laminae of the labia pass on each side of the glans clitoridis and unite, forming a hood that partially or completely covers the glans, the prepuce (foreskin) of the clitoris. The medial laminae of the labia merge posterior to the glans, forming the frenulum of the clitoris.
- There are three muscles on each side: bulbospongiosus, ischiocavernosus, and superficial transverse perineal; the perineal membrane is visible between them.
- The bulbospongiosus muscle overlies the bulb of the vestibule and the great vestibular gland. In the male, the muscles of the two sides are united by a median raphe; in the female, the orifice of the vagina separates the right from the left.



Authors: Agur, Anne M.R.; Dalley, Arthur F.

Title: *Grant's Atlas of Anatomy, 12th Edition*

Copyright ©2009 Lippincott Williams & Wilkins

> Table of Contents > Chapter 3 - Pelvis and Perineum > 3.62 Female perineum " III

---

## 3.62 Female perineum " III

*Part of* "Chapter 3 - Pelvis and Perineum "

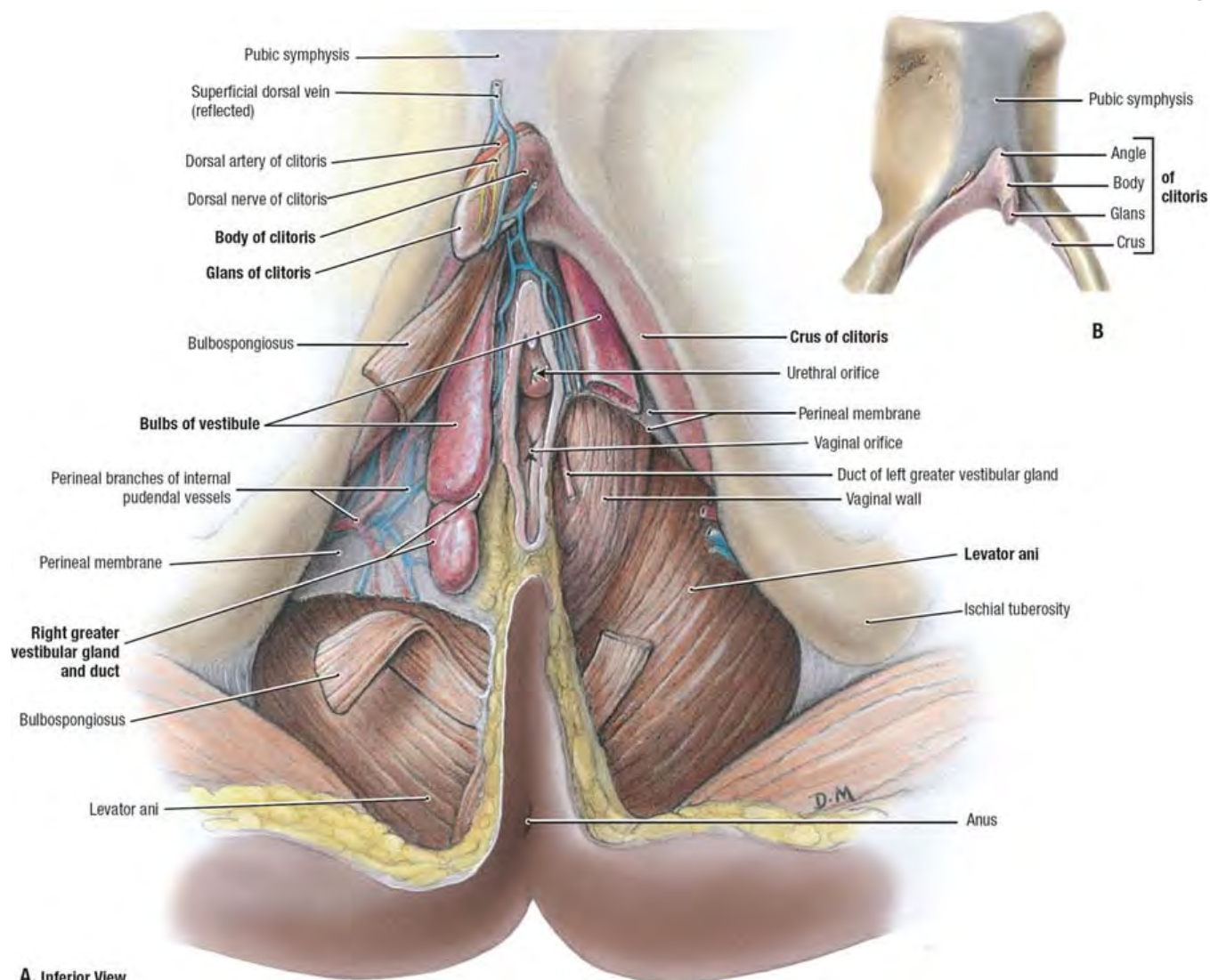
A. Deeper dissection. B. Clitoris.

In A:

- The bulbospongiosus muscle is reflected on the right side and mostly removed on the left side; the posterior portion of the bulb of the vestibule and the greater vestibular gland have been removed on the left side.
- The glans and body of the clitoris is displaced to the right so that the distribution of the dorsal vessels and nerve of the clitoris can be seen.
- Homologues of the bulb of the penis, the bulbs of the vestibule exist as two masses of elongated erectile tissue that lie along the sides of the vaginal orifice; veins connect the bulbs of the vestibule to the glans of the clitoris.
- On the specimen's right side, the greater vestibular gland is situated at the posterior end of the bulb; both structures are covered by bulbospongiosus muscle.
- On the specimen's left side, the bulb, gland, and perineal membrane are cut away, thereby revealing the external aspect of the vaginal wall.

In B:

- The body of the clitoris, composed of two crura (corpora cavernosa), is capped by the glans.



Authors: Agur, Anne M.R.; Dalley, Arthur F.

Title: *Grant's Atlas of Anatomy, 12th Edition*

Copyright ©2009 Lippincott Williams & Wilkins

> Table of Contents > Chapter 3 - Pelvis and Perineum > 3.63 Female perineum IV

---

## 3.63 Female perineum IV

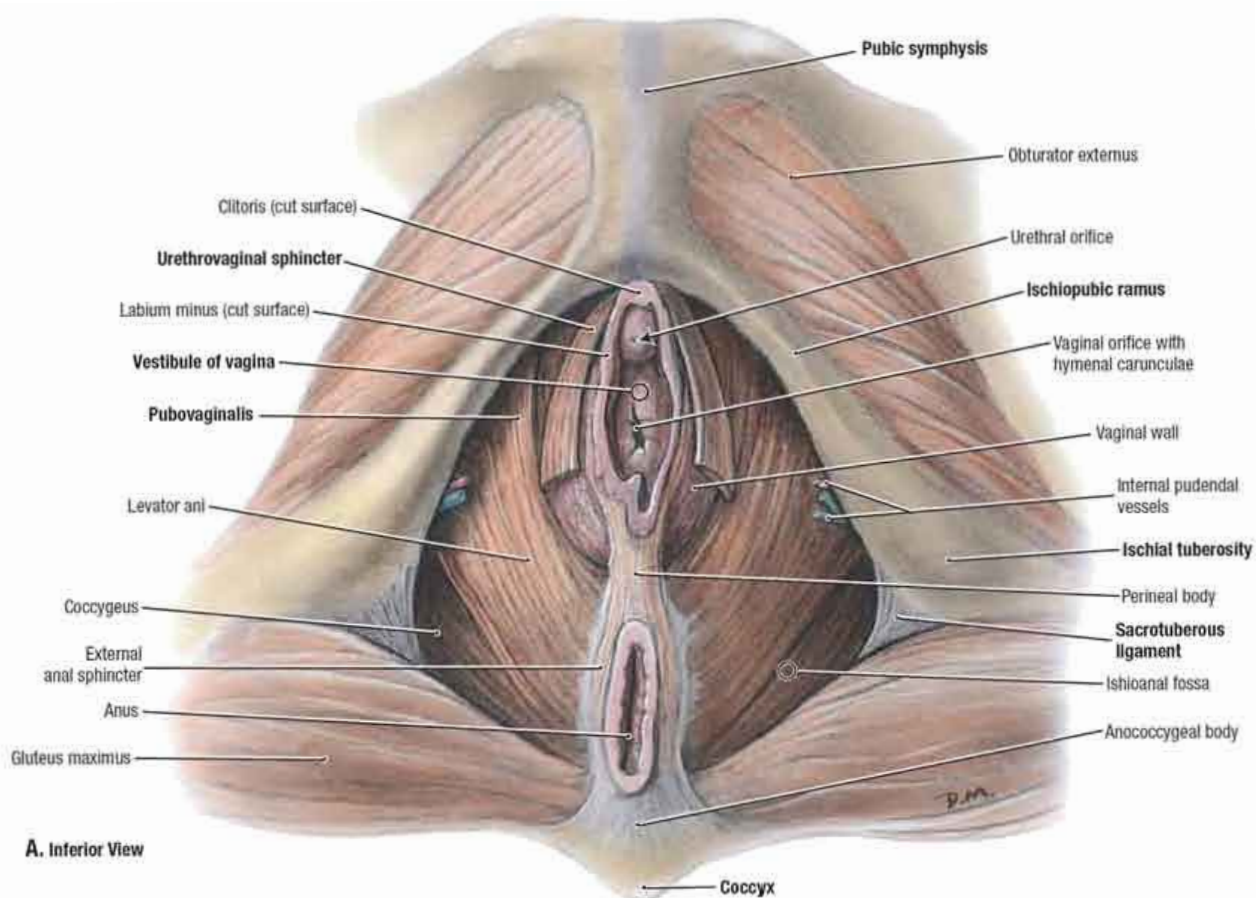
*Part of* "Chapter 3 - Pelvis and Perineum "

A. Deep perineal compartment. The perineal membrane and smooth muscle corresponding in position to the deep transverse perineal muscle in the male have been removed.

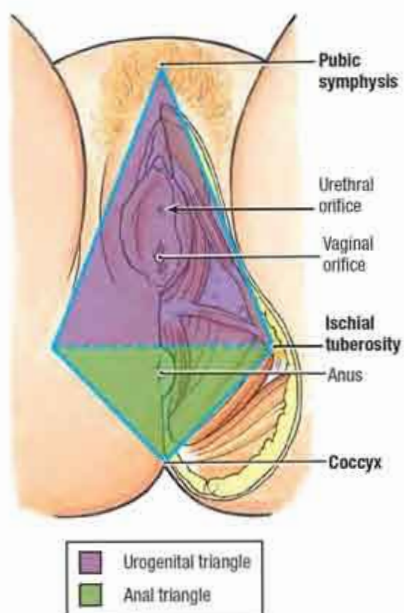
- The most anterior and medial part of the levator ani muscle, the pubovaginalis, passes posterior to the vaginal orifice.
- The urethrovaginal sphincter, part of the external urethral sphincter of the female, rests on the urethra and straddles the vagina.
- The labia minora (cut short here) bound the vestibule of the vagina.

A and B. The osseoligamentous boundaries of the diamond-shaped perineum are the pubic symphysis, ischiopubic rami, ischial tuberosities, sacrotuberous ligaments, and coccyx. For descriptive purposes, a transverse line connecting the ischial tuberosities subdivides the diamond into urogenital and anal triangles.





**A. Inferior View**



**B. Inferior View**

Authors: Agur, Anne M.R.; Dalley, Arthur F.

Title: *Grant's Atlas of Anatomy, 12th Edition*

Copyright ©2009 Lippincott Williams & Wilkins

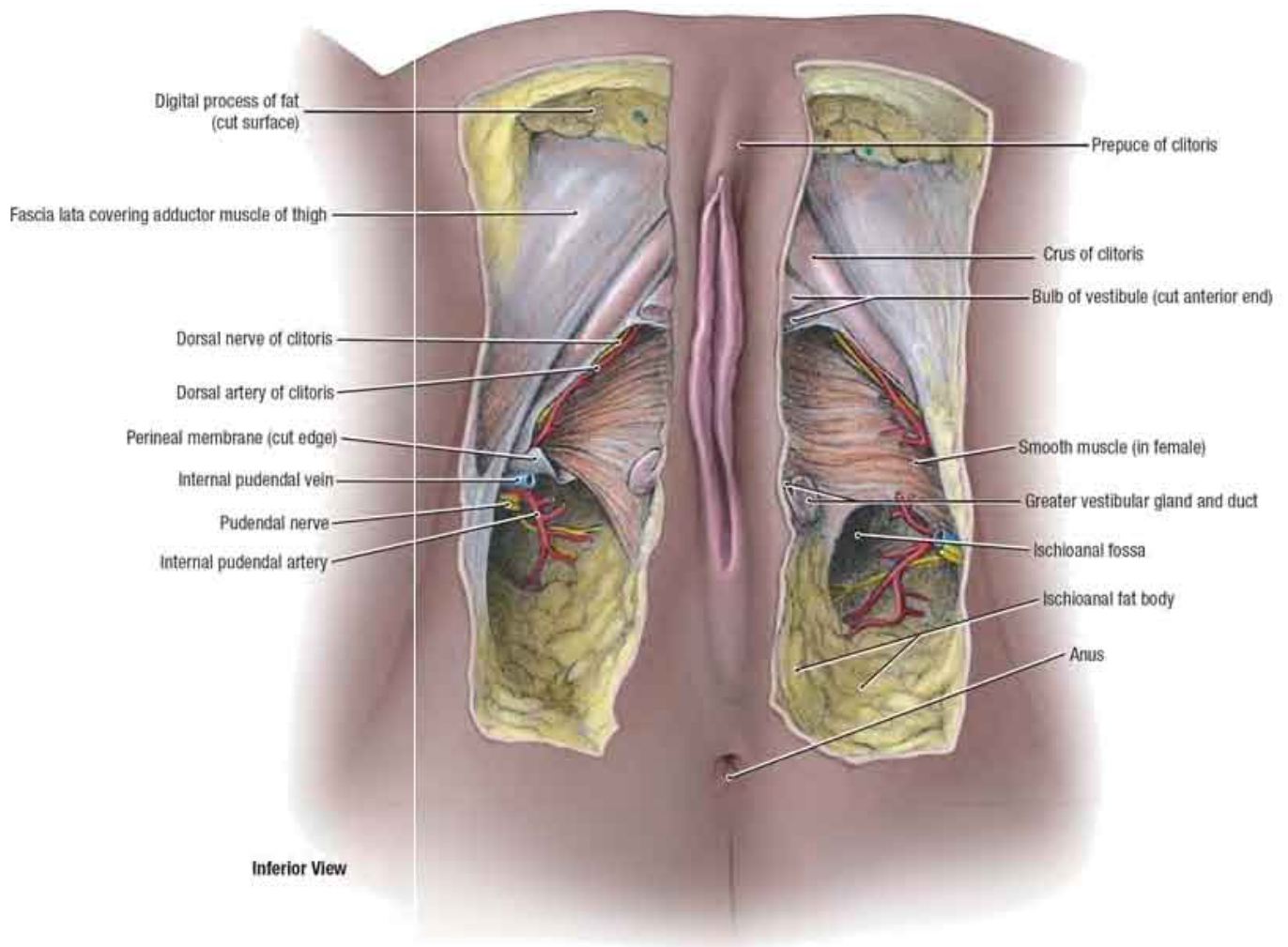
> Table of Contents > Chapter 3 - Pelvis and Perineum > 3.64 Female perineum V

---

## 3.64 Female perineum V

*Part of* "Chapter 3 - Pelvis and Perineum "

This is a different dissection than the previous series, with the vulva undissected centrally but the perineum dissected deeply on each side. Although most of the perineal membrane and bulbs of the vestibule have been removed, the greater vestibular glands (structures of the superficial perineal compartment) have been left in place. The development and extent of the smooth muscle layer corresponding in position to the voluntary deep transverse perineal muscles of the male is highly variable, being relatively extensive in this case, blending centrally with voluntary fibers of the external urethral sphincter and the perineal body.



Authors: Agur, Anne M.R.; Dalley, Arthur F.

Title: *Grant's Atlas of Anatomy, 12th Edition*

Copyright ©2009 Lippincott Williams & Wilkins

> Table of Contents > Chapter 3 - Pelvis and Perineum > 3.65 Female perineum V

---

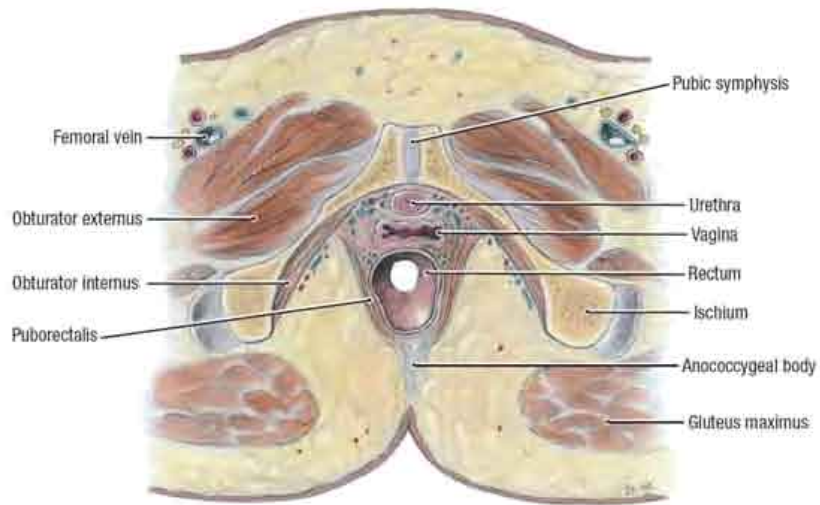
## 3.65 Female perineum V

*Part of* "Chapter 3 - Pelvis and Perineum "

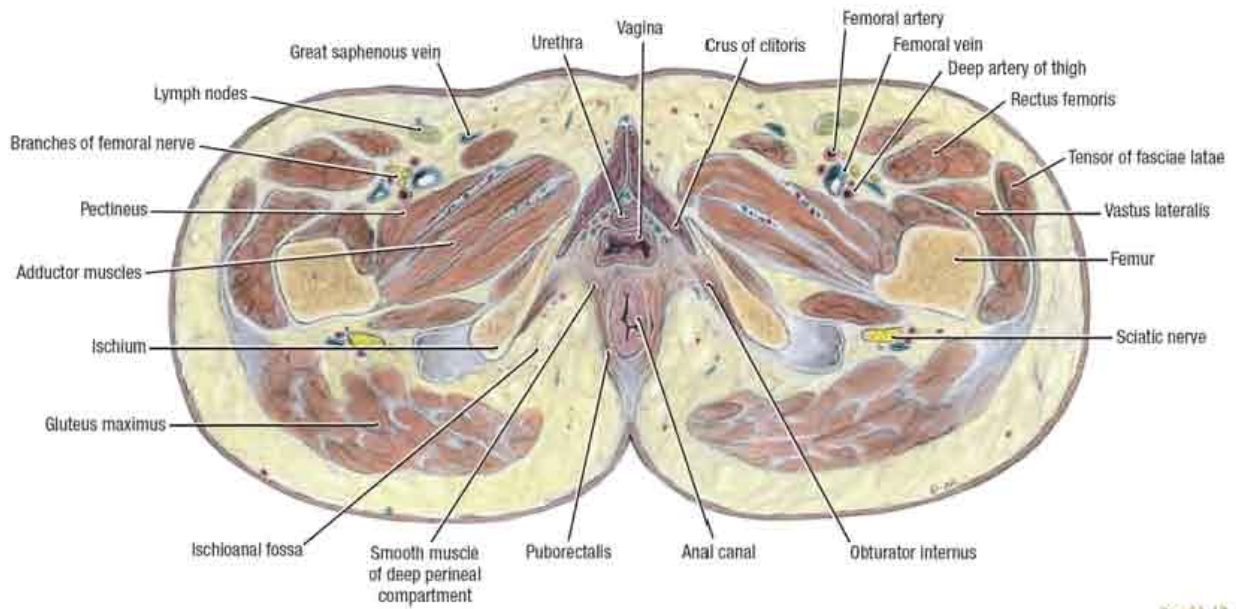
A. Section through vagina and urethra at base of urinary bladder. B. Section through vagina, urethra, and crura of clitoris.

---

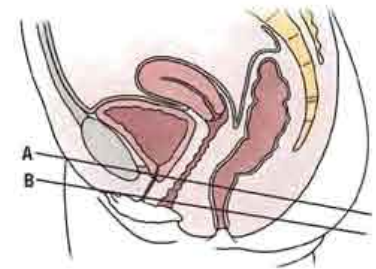
P.276



**A. Transverse Section**



**B. Transverse Section**





Authors: Agur, Anne M.R.; Dalley, Arthur F.  
 Title: *Grant's Atlas of Anatomy, 12th Edition*  
 Copyright ©2009 Lippincott Williams & Wilkins

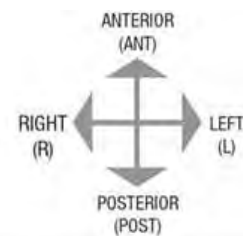
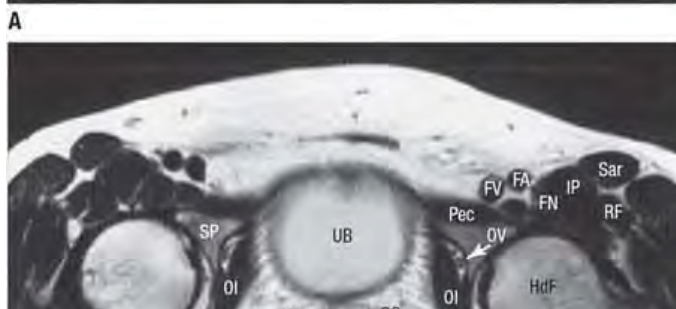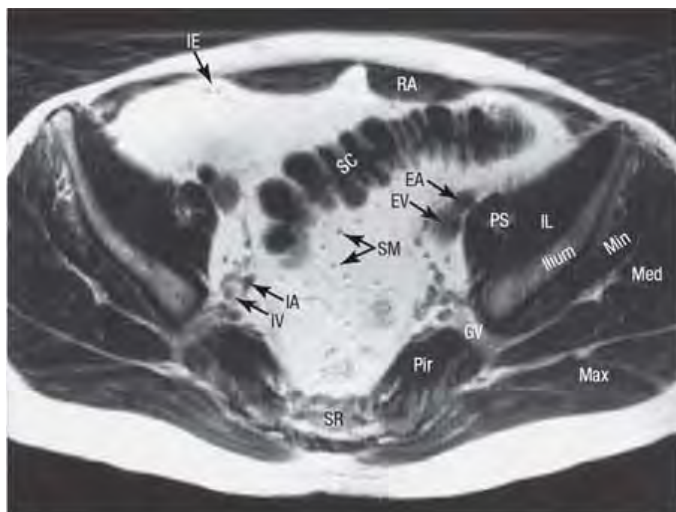> Table of Contents > Chapter 3 - Pelvis and Perineum > 3.66 Transverse (axial) MRIs and sectional specimen of the male pelvis and perineum, inferior views

## 3.66 Transverse (axial) MRIs and sectional specimen of the male pelvis and perineum, inferior views

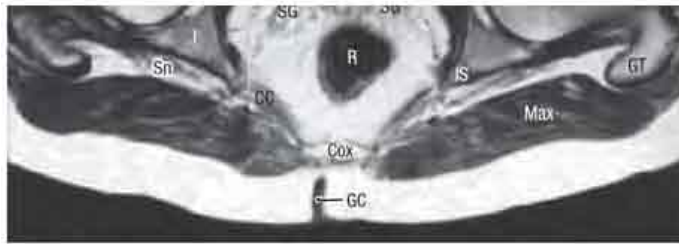
Part of "Chapter 3 - Pelvis and Perineum "

€" D. MRIs. E. Anatomical section.

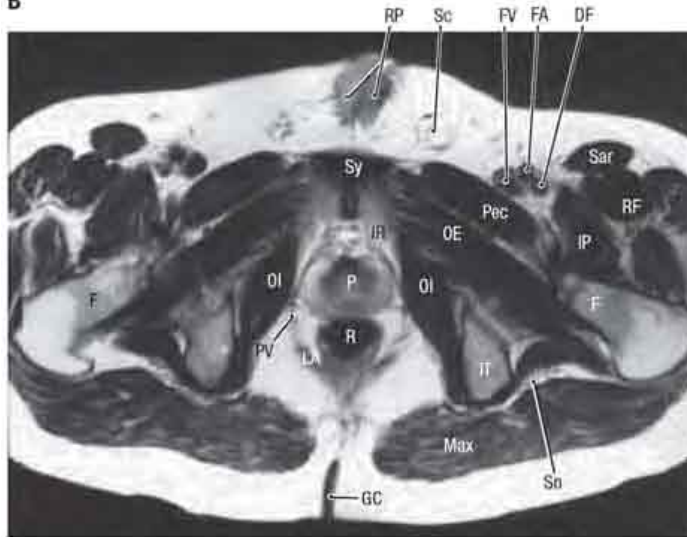
P.277



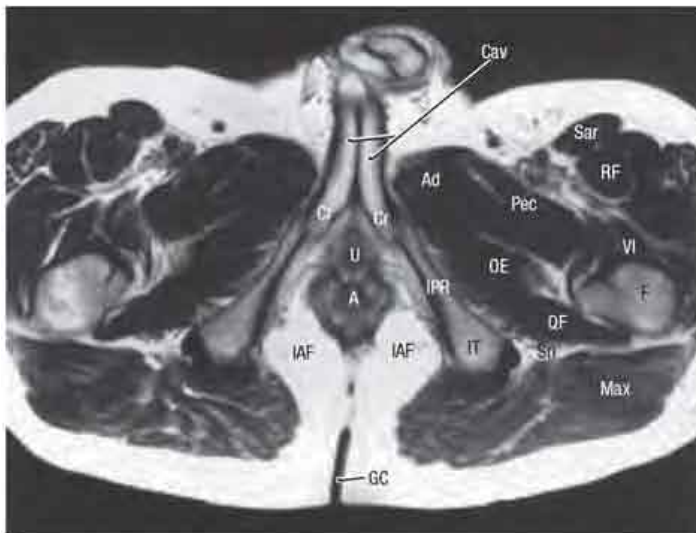
<b>A</b>	<b>Anus</b>	<b>IV</b>	Internal iliac vein
<b>Ad</b>	Adductor muscles	<b>LA</b>	<b>Levator ani</b>
<b>Bi</b>	Biceps femoris tendon	<b>Max</b>	Gluteus maximus
<b>Bu</b>	<b>Bulb of penis</b>	<b>Med</b>	Gluteus medius
<b>Cav</b>	<b>Corpus cavernosum penis</b>	<b>Min</b>	Gluteus minimus
<b>CC</b>	Coccygeus	<b>OE</b>	Obturator externus
<b>Cox</b>	Coccyx	<b>OI</b>	Obturator internus
<b>Cr</b>	<b>Crus of penis</b>	<b>OV</b>	Obturator vessels and nerve
<b>DD</b>	Ductus deferens	<b>P</b>	<b>Prostate</b>
<b>DF</b>	Deep femoral artery	<b>PB</b>	<b>Perineal body</b>
<b>DVP</b>	Dorsal vein of penis	<b>Pec</b>	Pectineus
<b>EA</b>	External iliac artery	<b>Pir</b>	Piriformis
<b>EAS</b>	External anal sphincter	<b>PR</b>	<b>Puborectalis</b>
<b>EV</b>	External iliac vein	<b>PS</b>	Psoas
<b>F</b>	Femur	<b>PV</b>	Pudendal vessels and nerves
<b>FA</b>	Femoral artery	<b>QF</b>	Quadratus femoris
<b>FN</b>	Femoral nerve	<b>R</b>	<b>Rectum</b>
<b>FV</b>	Femoral vein	<b>RA</b>	Rectus abdominis
<b>GC</b>	Gluteal cleft	<b>RF</b>	Rectus femoris
<b>GSV</b>	Great saphenous vein	<b>RP</b>	<b>Root of penis</b>
<b>GT</b>	Greater trochanter	<b>Sar</b>	Sartorius
<b>GV</b>	Superior gluteal vein	<b>Sc</b>	Spermatic cord
<b>HdF</b>	Head of femur	<b>SC</b>	Sigmoid colon
<b>I</b>	Body of ischium	<b>SC</b>	Sigmoid colon
<b>IA</b>	Internal iliac artery	<b>SC</b>	Sigmoid colon



B



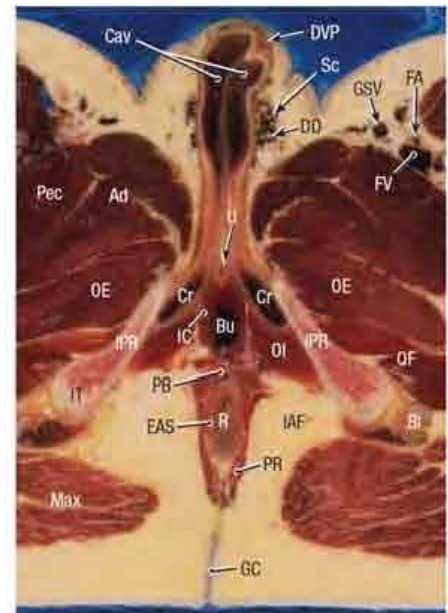
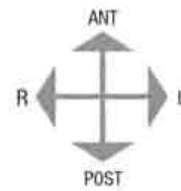
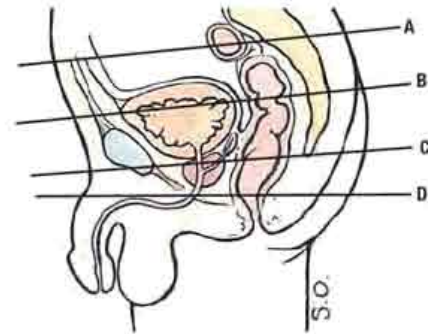
C



D

IA	Internal iliac artery	SG	Sigmoidum
<b>IAF</b>	<b>Ischioanal fossa (pararectal fat)</b>	SM	Sigmoidal vessels in mesentery of sigmoid colon
<b>IC</b>	<b>Ischio cavernosus</b>	Sn	Sclerotic nodule
IE	Inferior epigastric vessels	SP	Superior ramus of pubis
IL	Iliacus	SR	Sacrum
IP	Iliopsoas	Sy	Pubic symphysis
IPR	Ischiopubic ramus	<b>U</b>	<b>Urethra</b>
IR	Inferior pubic ramus	<b>UB</b>	<b>Urinary bladder</b>
IS	Ischial spine	VI	Vastus intermedius
IT	Ischial tuberosity		

(Organs/structures of male pelvis and perineum are in boldface)



E

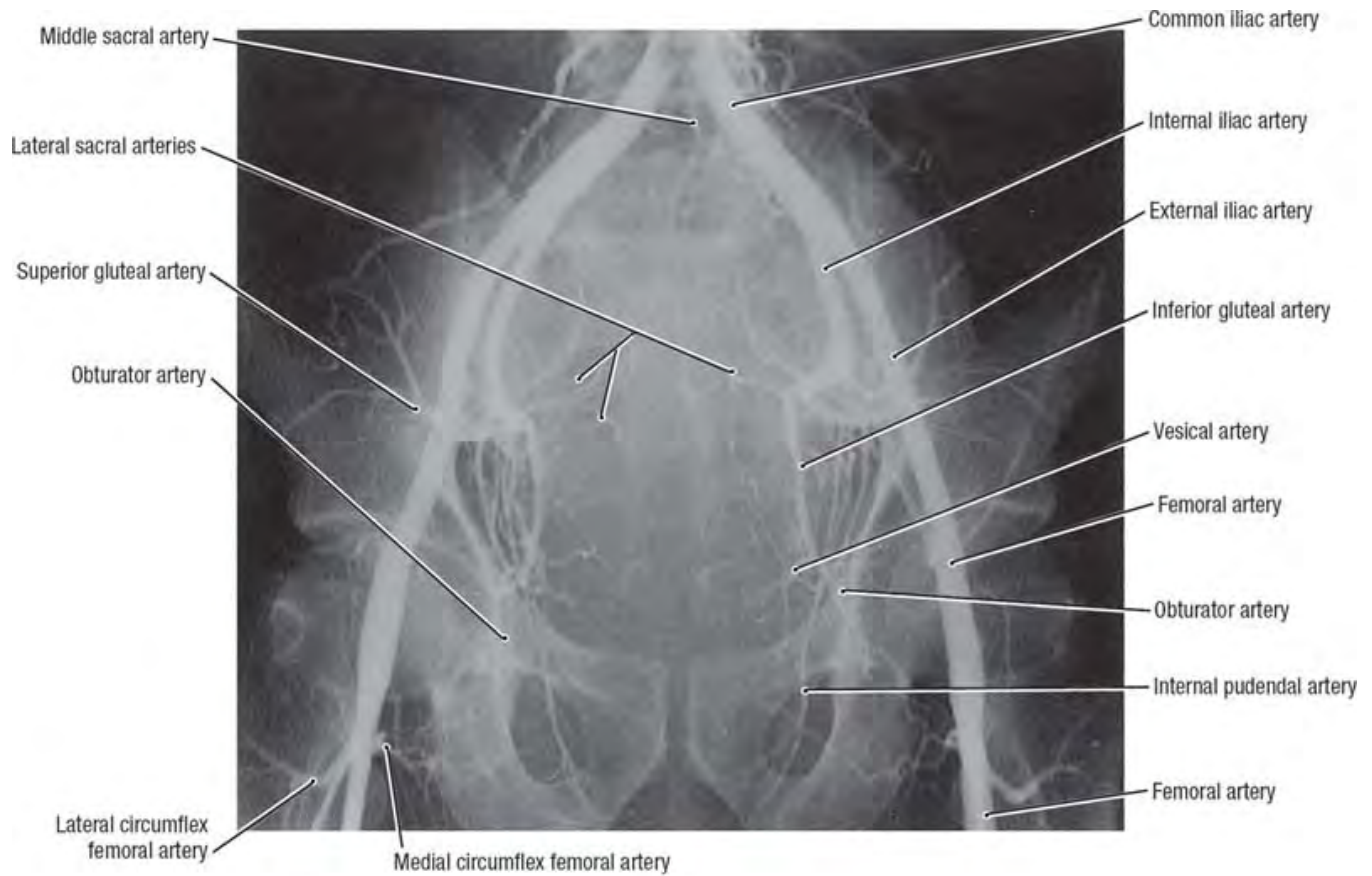
Authors: Agur, Anne M.R.; Dalley, Arthur F.  
Title: *Grant's Atlas of Anatomy, 12th Edition*  
Copyright ©2009 Lippincott Williams & Wilkins

> Table of Contents > Chapter 3 - Pelvis and Perineum > 3.67 Pelvic angiography

## 3.67 Pelvic angiography

Part of "Chapter 3 - Pelvis and Perineum "

P.278



**Anteroposterior View**

Authors: Agur, Anne M.R.; Dalley, Arthur F.

Title: *Grant's Atlas of Anatomy, 12th Edition*

Copyright ©2009 Lippincott Williams & Wilkins

> Table of Contents > Chapter 3 - Pelvis and Perineum > 3.68 Coronal MRIs of the male pelvis and perineum, anterior views

---

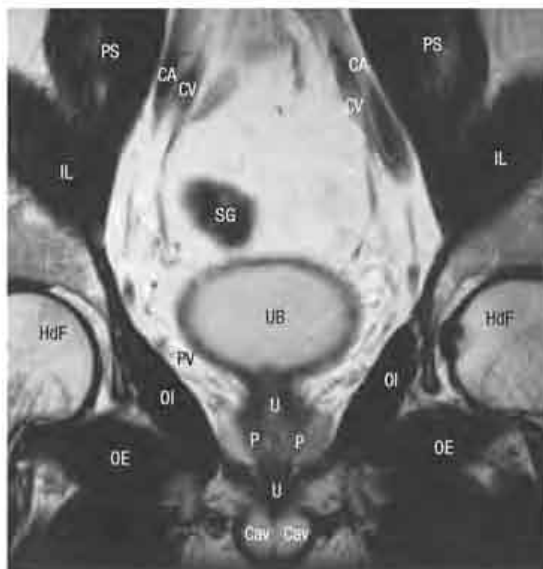
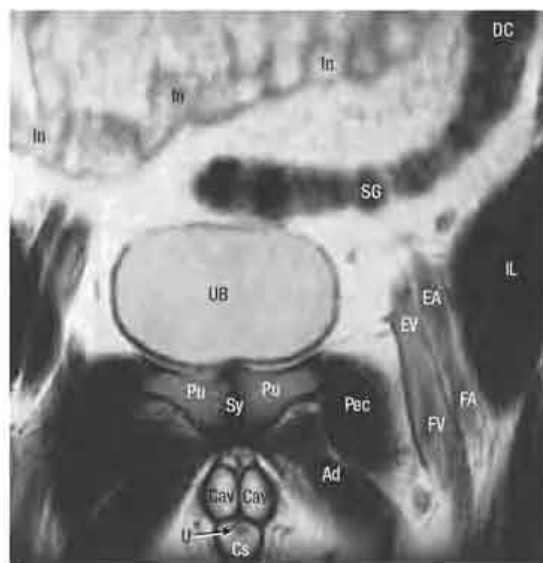
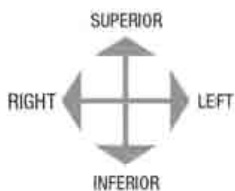
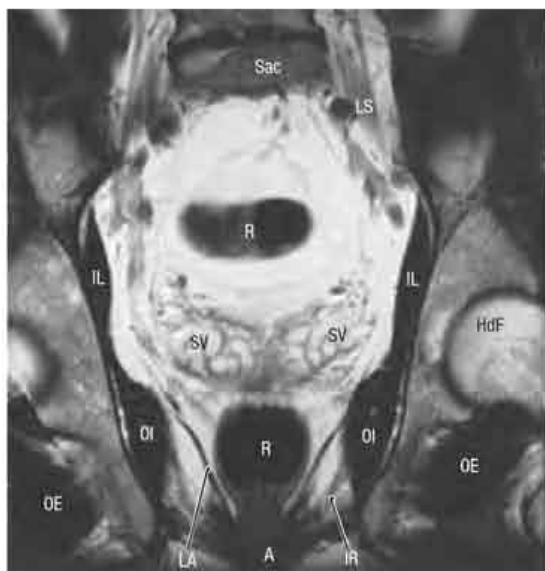
## 3.68 Coronal MRIs of the male pelvis and perineum, anterior views

*Part of* "Chapter 3 - Pelvis and Perineum "

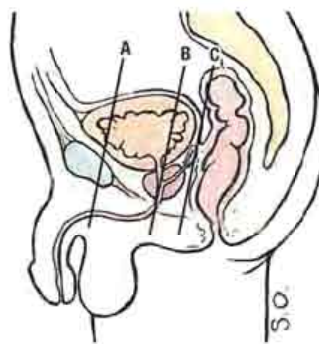---

P.279





<b>A</b>	<b>Anus</b>
<b>Ad</b>	Adductors
<b>CA</b>	Common iliac artery
<b>Cav</b>	<b>Corpus cavernosum penis</b>
<b>Cs</b>	<b>Corpus spongiosum penis</b>
<b>CV</b>	Common iliac vein
<b>DC</b>	Descending colon
<b>EA</b>	External iliac artery
<b>EV</b>	External iliac vein
<b>FA</b>	Femoral artery
<b>FV</b>	Femoral vein
<b>HdF</b>	Head of femur
<b>IL</b>	Iliacus
<b>In</b>	Small intestine
<b>IR</b>	<b>Inferior rectal nerve and vessels</b>
<b>LA</b>	<b>Levator ani</b>
<b>LS</b>	Lumbosacral trunk
<b>OE</b>	Obturator externus
<b>OI</b>	<b>Obturator internus</b>
<b>P</b>	<b>Prostate</b>
<b>Pec</b>	Pectineus
<b>PS</b>	Psoas
<b>Pu</b>	Pubic bone
<b>PV</b>	<b>Pelvic vessels and nerves</b>
<b>R</b>	<b>Rectum</b>
<b>Sac</b>	<b>Sacrum</b>
<b>SC</b>	Sigmoid colon
<b>SG</b>	<b>Seminal vesicle</b>
<b>Sy</b>	Pubic symphysis
<b>U</b>	<b>Urethra</b>
<b>UB</b>	<b>Urinary bladder</b>





Authors: Agur, Anne M.R.; Dalley, Arthur F.

Title: *Grant's Atlas of Anatomy, 12th Edition*

Copyright ©2009 Lippincott Williams & Wilkins

> Table of Contents > Chapter 3 - Pelvis and Perineum > 3.69 Median MRIs of the male and female pelvis and perineum

---

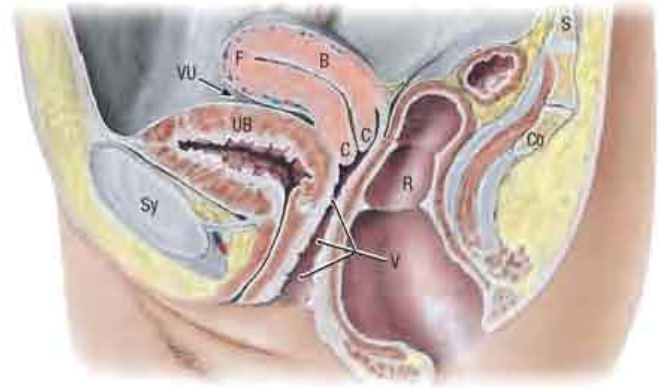
## 3.69 Median MRIs of the male and female pelvis and perineum

*Part of* "Chapter 3 - Pelvis and Perineum "

---

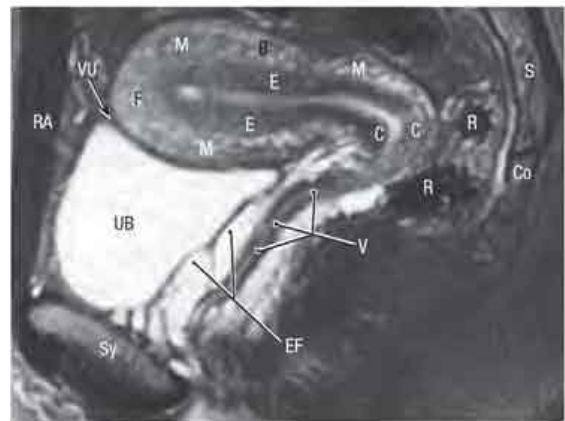
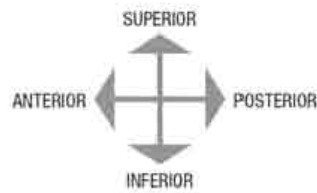
P.280

## FEMALE



### Median Section

B	Body of uterus
C	Cervix of uterus
Co	Coccyx
E	Endometrium
EF	Endopelvic fascia
F	Fundus of uterus
M	Myometrium
R	Rectum
RA	Rectus abdominis
S	Sacrum
Sy	Pubis symphysis
UB	Urinary bladder
V	Vagina
VU	Vesicouterine pouch



### Median MRI Scan

Authors: Agur, Anne M.R.; Dalley, Arthur F.  
 Title: *Grant's Atlas of Anatomy, 12th Edition*  
 Copyright ©2009 Lippincott Williams & Wilkins

> Table of Contents > Chapter 3 - Pelvis and Perineum > 3.70 Transverse (axial) MRIs and sectional specimens of the female pelvis and perineum, inferior views

## 3.70 Transverse (axial) MRIs and sectional specimens of the female pelvis and perineum, inferior views

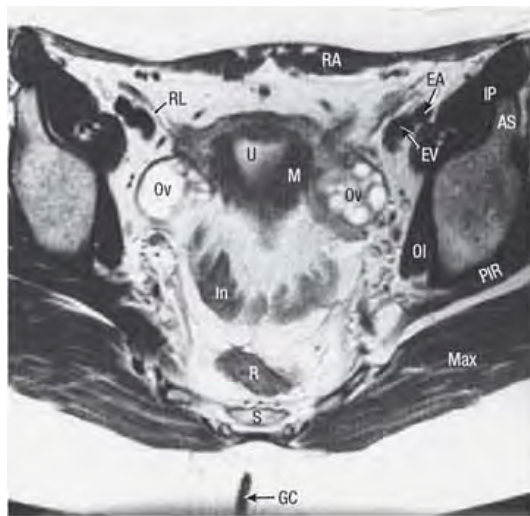
Part of "Chapter 3 - Pelvis and Perineum "

€ C. MRIs.

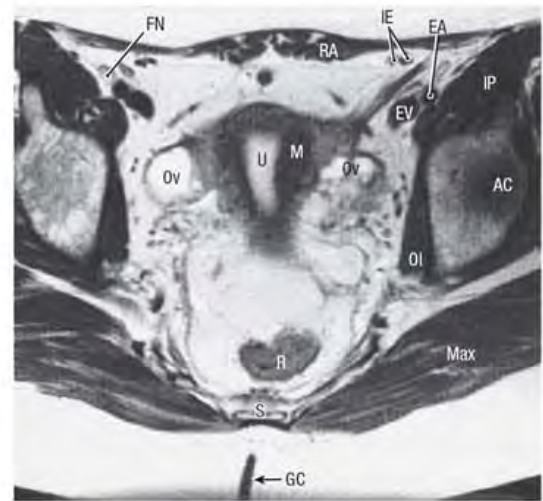
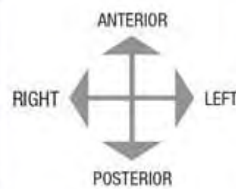
P.281

D and F. MRIs. E and G. Anatomical sections.

P.282



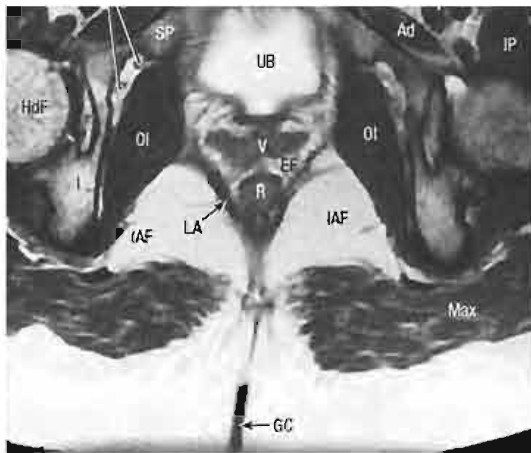
A



B

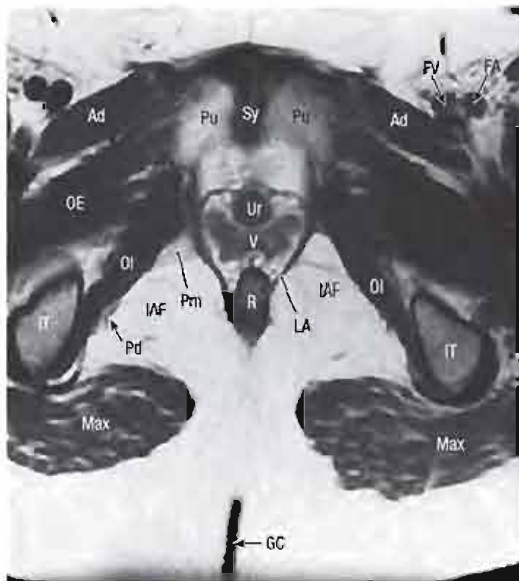
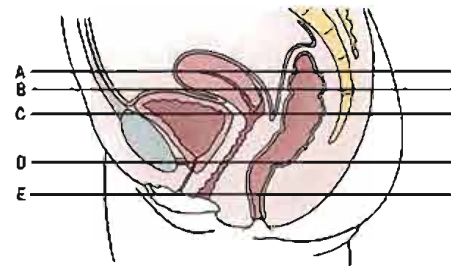


<b>A</b>	<b>Anus</b>	<b>M</b>	<b>Myometrium</b>
AC	Acetabulum	Max	Gluteus maximus
Ad	Adductor muscles	OE	Obturator externus

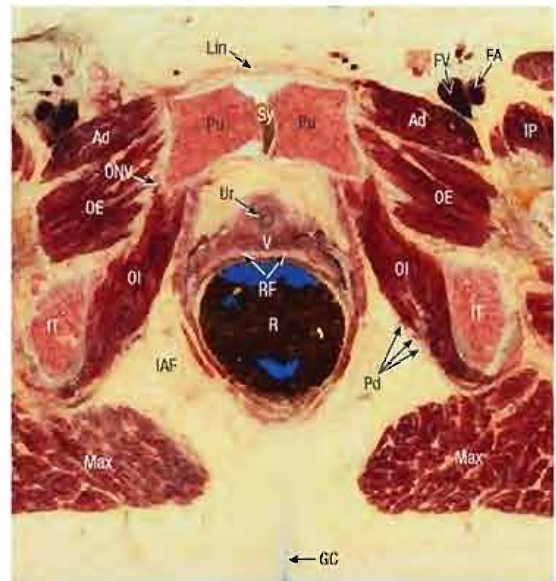


C

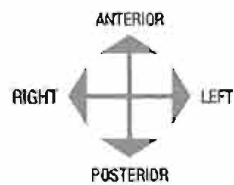
AS	Anterior superior iliac spine	OI	Obturator internus
BC	Body of clitoris	Ov	Ovary
CC	Crus of clitoris	OV	Obturator vessels
EA	External iliac artery	Pd	Pudendal nerve and vessels
EF	Endopelvic fascia	Pec	Pectineus
EV	External iliac vein	PIR	Piniformis
FA	Femoral artery	Pm	Perineal membrane
FN	Femoral nerve	Pu	Pubic bone
FV	Femoral vein	OF	Quadratus femoris
GC	Gluteal cleft	R	Rectum
HdF	Head of femur	RA	Rectus abdominis
I	Ilium	RF	Recto-uterine fold
IAF	Ischioanal fossa	RL	Round ligament
IE	Inferior epigastric vessels	S	Sacrum
In	Intestine	SP	Superior ramus of pubis
IP	Iliopsoas	Sy	Pubic symphysis
IPR	Isochopubic ramus	U	Uterus
IT	Isochial tuberosity	UB	Urinary bladder
LA	Levator ani	Ur	Urethra
Lin	Linea alba	V	Vagina
LM	Labia major	Ve	Vestibule

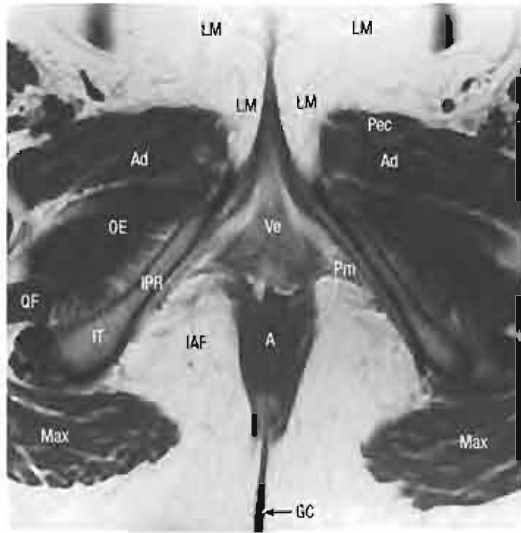

D

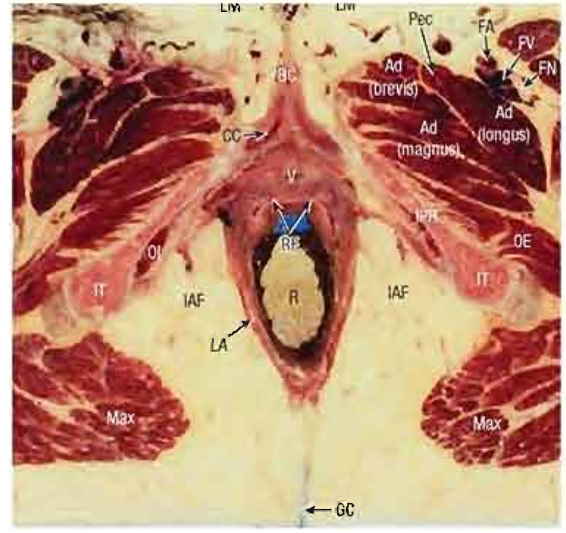


E





F



G

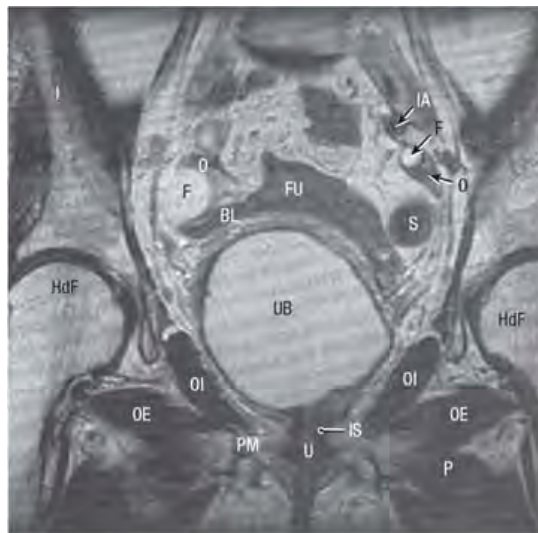


Authors: Agur, Anne M.R.; Dalley, Arthur F.  
 Title: *Grant's Atlas of Anatomy, 12th Edition*  
 Copyright ©2009 Lippincott Williams & Wilkins

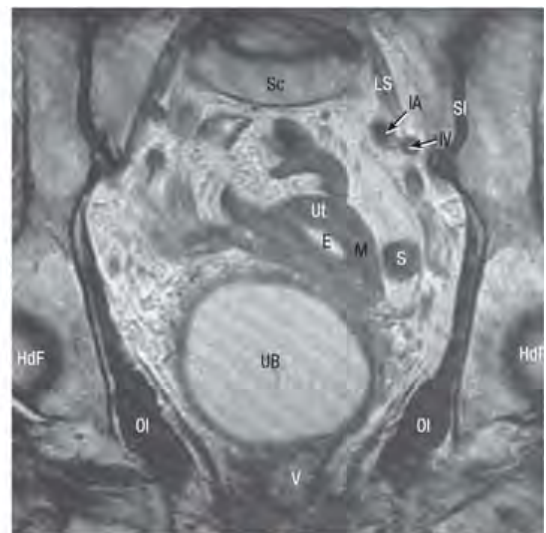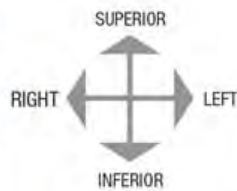
> Table of Contents > Chapter 3 - Pelvis and Perineum > 3.71 Coronal MRIs of the female pelvis and perineum, anterior views

## 3.71 Coronal MRIs of the female pelvis and perineum, anterior views

Part of "Chapter 3 - Pelvis and Perineum "

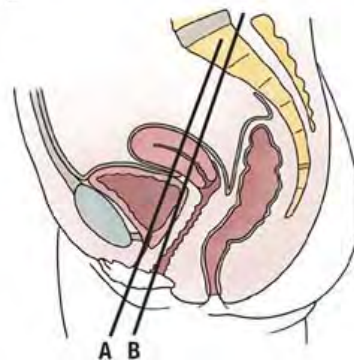


A



B

BL	Broad ligament	OE	Obturator externus
E	Endometrium	OI	Obturator internus
F	Ovarian follicle	P	Pectineus
FU	Fundus of uterus	PM	Perineal membrane
HdF	Head of femur	S	Sigmoid colon
I	Ilium	Sc	Sacrum
IA	Internal iliac artery	SI	Sacroiliac joint
IV	Internal iliac vein	U	Urethra
IS	Internal urethral sphincter	UB	Urinary bladder
LS	Lumbosacral trunk	Ut	Uterus
M	Myometrium	V	Vagina
O	Ovary		



## 3.72 Ultrasound scans of female pelvis

Part of "Chapter 3 - Pelvis and Perineum "

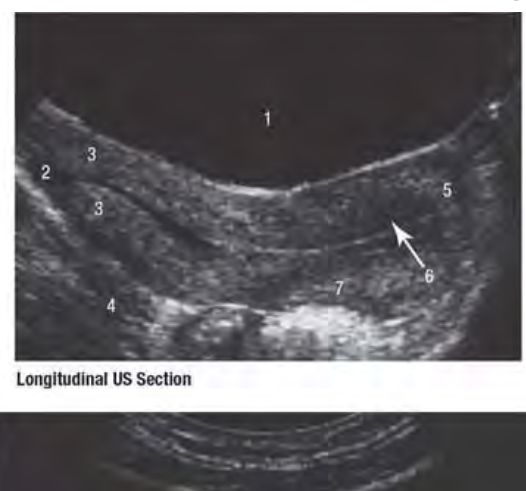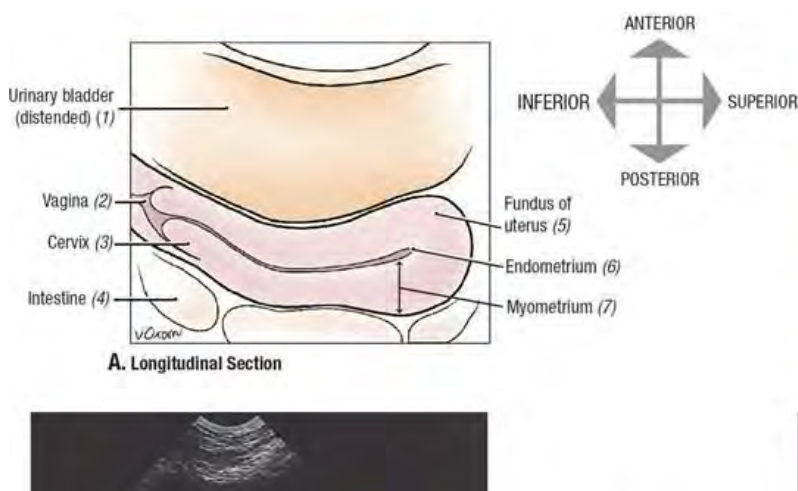
A. Median (transabdominal) ultrasound scan and orientation drawing (numbers in parentheses correspond to labels on the ultrasound scan).

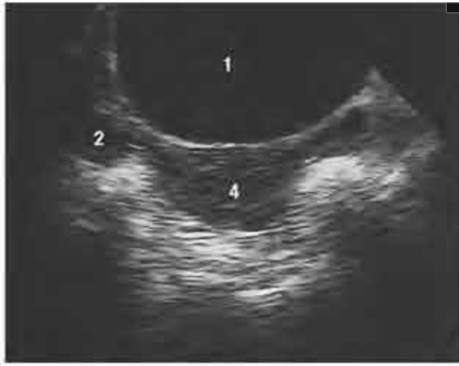P.283

B and C. Transabdominal axial (transverse) scan through uterus and ovaries.  
Transabdominal US scanning requires a fully distended urinary bladder to displace the bowel loops from the pelvis and to provide an acoustical window through which to observe pelvic anatomy.

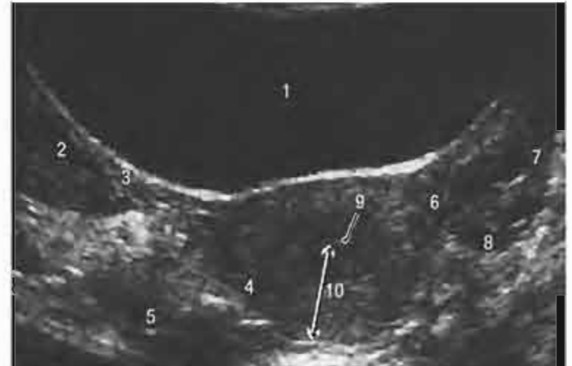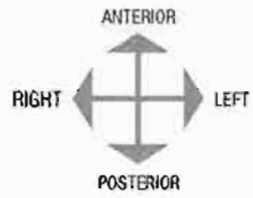
D. Transvaginal sagittal scan of left ovary (numbers in parentheses correspond to labels on the ultrasound scans). Transvaginal and transrectal ultrasonography enables the placing of the probe closer to the structures of interest, allowing increased resolution.

P.284

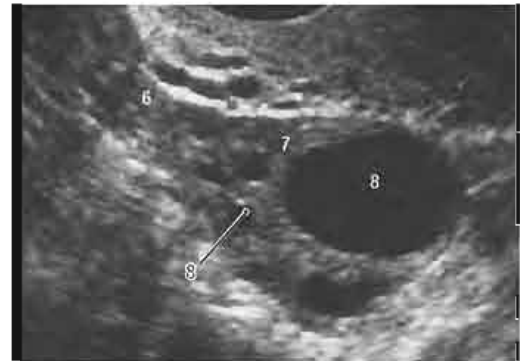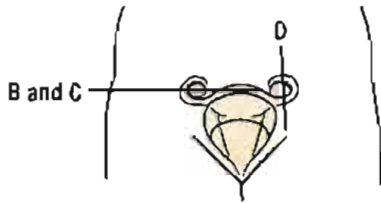
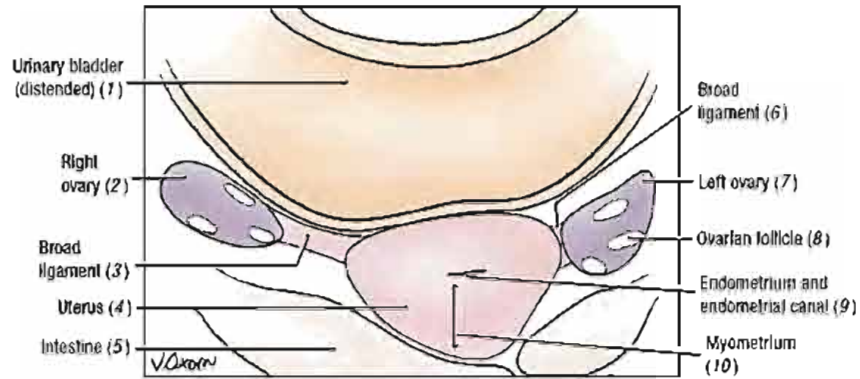




B. Transverse (Axial) Scan



C. Transverse (Axial) Scan



D. Sagittal Scan

Authors: Agur, Anne M.R.; Dalley, Arthur F.

Title: *Grant's Atlas of Anatomy, 12th Edition*

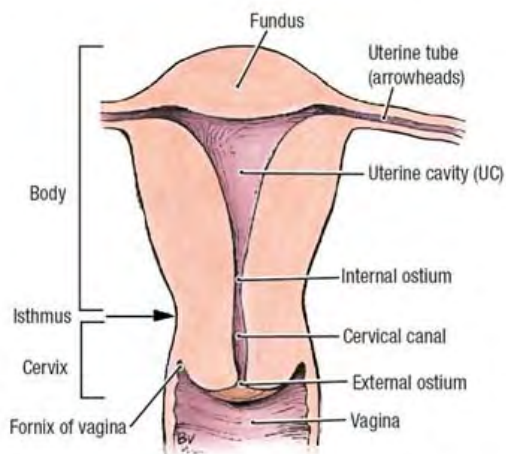
Copyright ©2009 Lippincott Williams & Wilkins

> Table of Contents > Chapter 3 - Pelvis and Perineum > 3.73 Radiograph of uterus and uterine tubes (hysterosalpingogram)

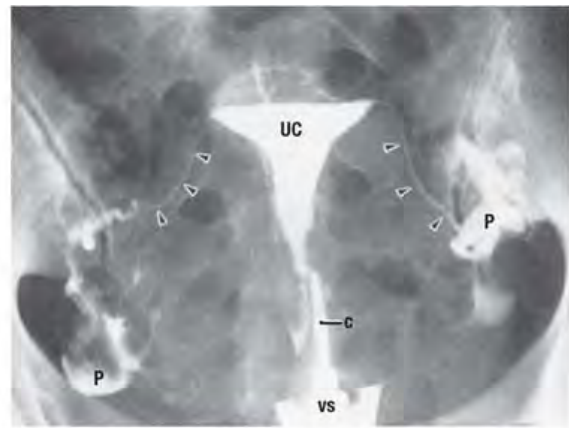
---

## 3.73 Radiograph of uterus and uterine tubes (hysterosalpingogram)

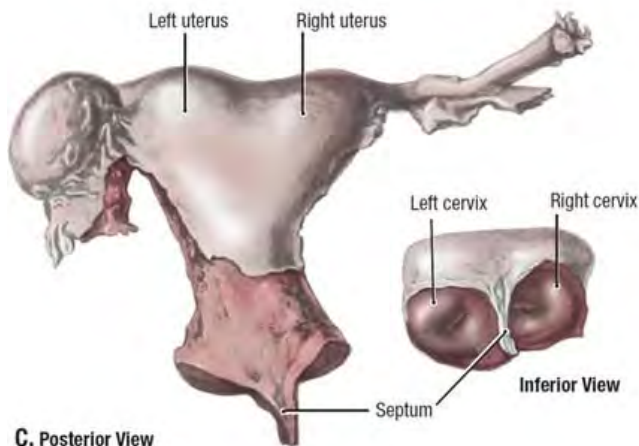
*Part of* "Chapter 3 - Pelvis and Perineum "



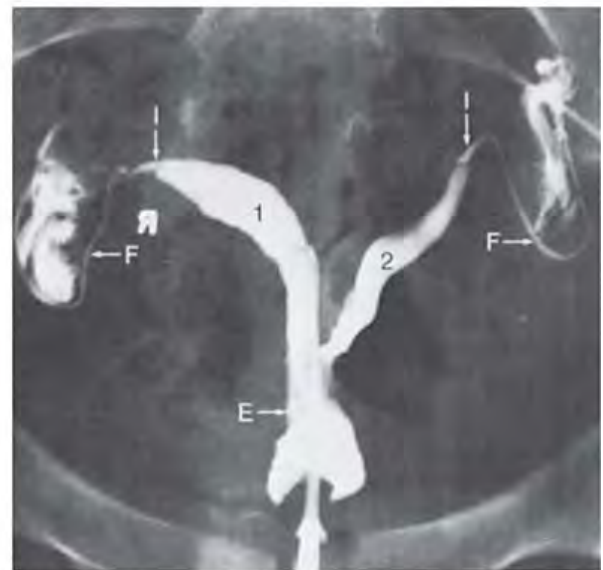**A. Coronal Section**



**B. Hysterosalpingogram of Normal Uterus, Anteroposterior View**



**C. Posterior View**



**D. Hysterosalpingogram of Bicornate Uterus, Anteroposterior View**

A. Coronal section of uterus. B. Radiopaque material was injected into the uterus through external os of the uterus. The contrast medium traveled through the triangular uterine cavity (UC) and uterine tubes (arrowheads) and passed into the pararectal fossae (P) of the peritoneal cavity. c, catheter in the cervical canal; vs, vaginal speculum. The female genital tract is in direct communication with the peritoneal cavity and is, therefore, a potential pathway for the spread of an infection from the vagina and uterus. C. Illustration of duplicated uterus. D. Hysterosalpingogram of a bicornate (â€œtwo hornedâ€•) uterus. 1 and 2, uterine cavities; E, cervical canal; F, uterine tubes; I, isthmus of tubes.



Authors: Agur, Anne M.R.; Dalley, Arthur F.

Title: *Grant's Atlas of Anatomy, 12th Edition*

Copyright ©2009 Lippincott Williams & Wilkins

> Table of Contents > Chapter 4 - Back > Chapter 4 - Back

---

## Chapter 4

### Back

---

P.286

- 4.1 Overview of vertebral column
- 4.2 Curvatures of vertebral column
- 4.3 Three views of the vertebral column
- 4.4 Typical vertebra
- 4.5 Homologous parts of vertebrae
- 4.6 Vertebral features and movements
- 4.7 Surface anatomy with radiographic correlation of selected movements of the cervical spine
- 4.8 Surface anatomy with radiographic correlation of selected movements of the lumbar spine
- 4.9 Cervical vertebrae
- 4.10 Cervical spine
- 4.11 Imaging of the cervical spine
- 4.12 Atlas and axis and the atlantoaxial joint
- 4.13 Craniovertebral joints and vertebral artery
- 4.14 Ligaments of atlanto-occipital and atlantoaxial joints

- 4.15 Thoracic vertebrae
- 4.16 Lumbar vertebrae
- 4.17 Structure and innervation of intervertebral discs and zygapophysial joints
- 4.18 Intervertebral discs: ligaments and movements
- 4.19 Lumbar region of vertebral column
- 4.20 Vertebral venous plexuses
- 4.21 Radiograph of inferior thoracic and lumbosacral spine
- 4.22 Pelvis
- 4.23 Hip bone, sacrum, and coccyx
- 4.24 Sacrum and coccyx
- 4.25 Lumbar and pelvic ligaments
- 4.26 Articular surfaces of sacro-iliac joint and ligaments
- 4.27 Imaging of the sacro-iliac joint
- 4.29 Spondylolysis and spondylolisthesis
- 4.30 Surface anatomy of back
- 4.31 Superficial muscles of back
- 4.32 Intermediate muscles of back
- 4.33 Deep muscles of back: splenius and erector spinae
- 4.34 Transverse section of back muscles and thoracolumbar fascia
- 4.35 Deep muscles of back: semispinalis and multifidus
- 4.36 Back: multifidus, quadratus lumborum, and thoracolumbar fascia
- 4.37 Rotatores and costotransverse ligaments
- 4.38 Suboccipital regionâ€”I
- 4.39 Suboccipital regionâ€”II

- 4.40 Nuchal Region
- 4.41 Spinal cord in situ
- 4.42 Spinal cord and meninges
- 4.43 Inferior end of dural sac – I
- 4.44 Inferior end of dural sac – II
- 4.45 Lower cervical vertebrae and associated structures and nerves
- 4.46 Spinal cord and prevertebral structures
- 4.47 Isolated spinal cord and spinal nerve roots with coverings and regional sections
- 4.48 Blood supply of spinal cord
- 4.49 Overview of somatic nervous system
- 4.50 Spinal cord and spinal nerves
- 4.51 Visceral afferent and visceral efferent (motor) innervation
- 4.52 Dermatomes
- 4.53 Myotomes
- 4.54 Imaging of superior nuchal region at the level of the atlas
- 4.55 Imaging of lumbar spine at L4
- 4.56 Imaging of sacro-iliac joint
- 4.57 Coronal MRI scans of cervical and thoracic spine

Authors: Agur, Anne M.R.; Dalley, Arthur F.

Title: *Grant's Atlas of Anatomy, 12th Edition*

Copyright ©2009 Lippincott Williams & Wilkins

> Table of Contents > Chapter 4 - Back > 4.1 Overview of vertebral column

---

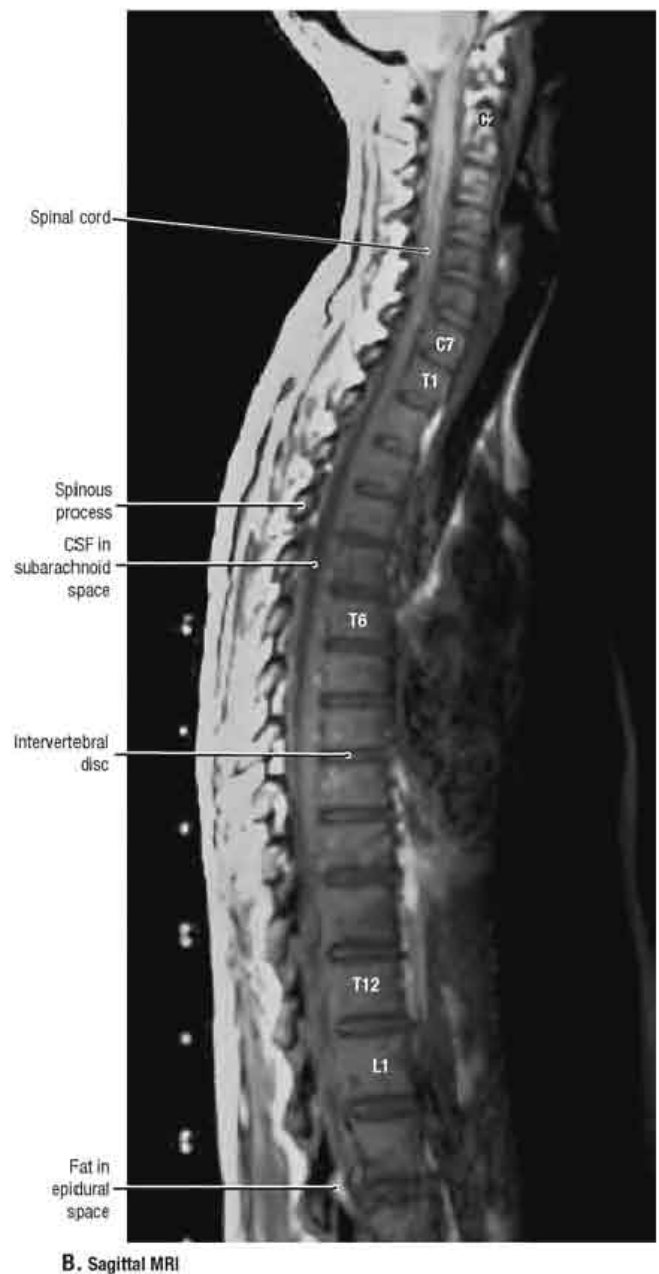
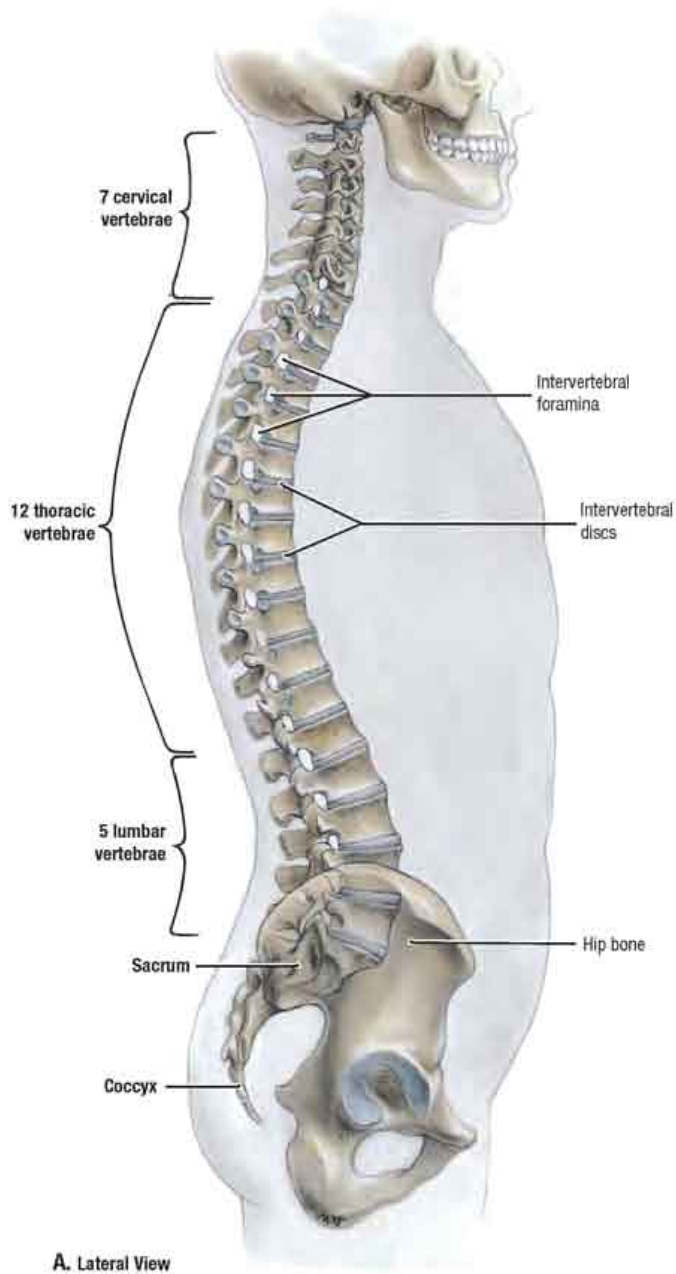
## 4.1 Overview of vertebral column

*Part of* "Chapter 4 - Back "

A. Vertebral column showing articulation with skull and hip bone.

B. Sagittal MRI, lateral view.

- The vertebral column usually consists of 24 separate (presacral) vertebrae, 5 fused vertebrae in the sacrum, and variably 4 fused or separate coccygeal vertebrae. Of the 24 separate vertebrae, 12 support ribs (thoracic), 7 are in the neck (cervical), and 5 are in the lumbar region (lumbar).
- Vertebrae contributing to the posterior walls of the thoracic and pelvic cavities are concave anteriorly; elsewhere (in the cervical and lumbar regions) they are convex anteriorly.
- The spinal nerves exit the vertebral (spinal) canal via the intervertebral foramina. There are 8 cervical, 12 thoracic, 5 lumbar, 5 sacral, and 1 to 2 coccygeal spinal nerves.
- Note the size and shape of the vertebral bodies, the direction of the spinous processes, and the spinal cord in the vertebral canal (in B ).





Authors: Agur, Anne M.R.; Dalley, Arthur F.

Title: *Grant's Atlas of Anatomy, 12th Edition*

Copyright ©2009 Lippincott Williams & Wilkins

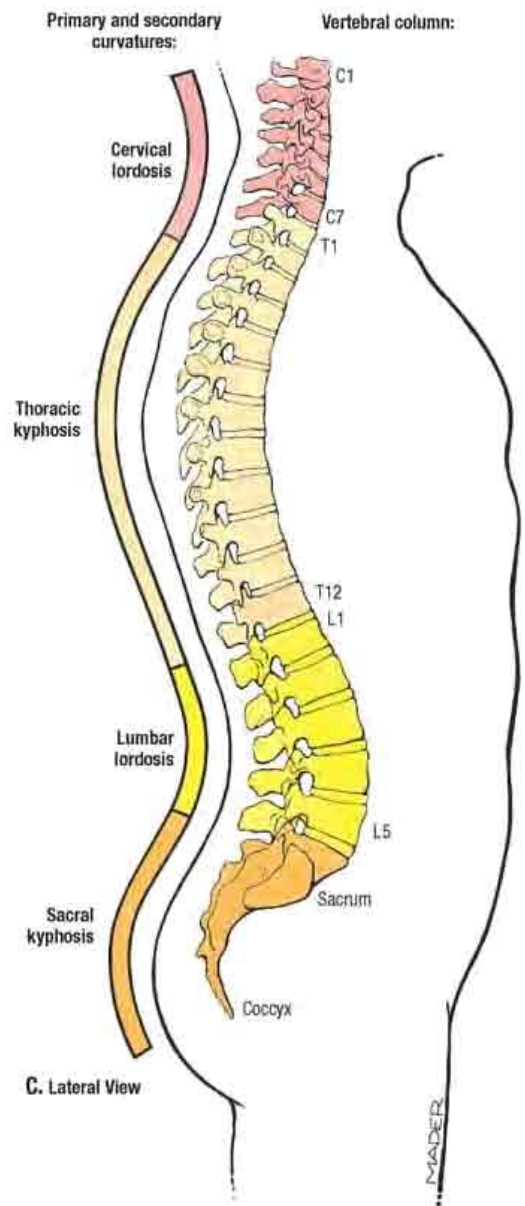
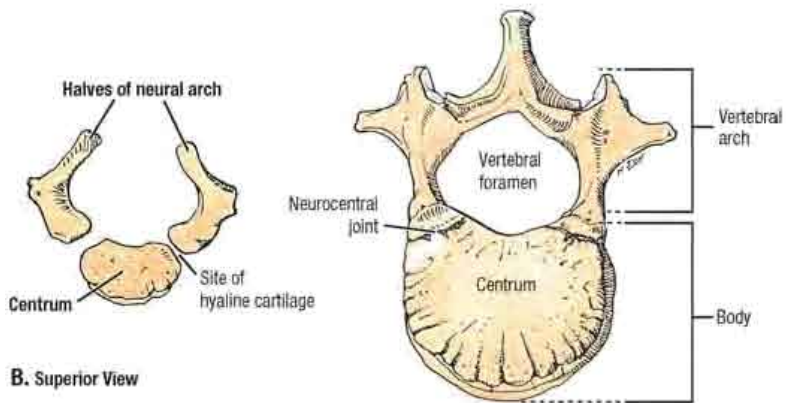
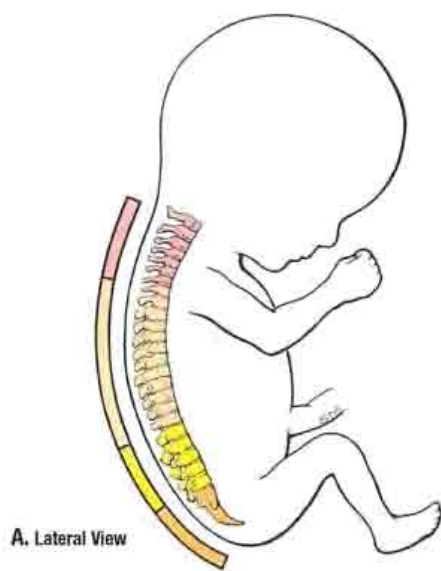
> Table of Contents > Chapter 4 - Back > 4.2 Curvatures of vertebral column

---

## 4.2 Curvatures of vertebral column

*Part of* "Chapter 4 - Back "

A. Fetus. Note the C-shaped curvature of the fetal spine, which is concave anteriorly over its entire length. B. Development of the vertebrae. At birth, a vertebra consists of three bony parts (two halves of the neural arch and the centrum) united by hyaline cartilage. At age 2, the halves of each neural arch begin to fuse, proceeding from the lumbar to the cervical region; at approximately age 7, the arches begin to fuse to the centrum, proceeding from the cervical to lumbar regions. C. Adult. The four curvatures of the adult vertebral column include the cervical lordosis, which is convex anteriorly and lies between vertebrae C1 and T2; the thoracic kyphosis, which is concave anteriorly, between vertebrae T2 and T12; the lumbar lordosis, convex anteriorly and lying between T12 and the lumbosacral joint; and the sacral kyphosis, concave anteriorly and spanning from the lumbosacral joint to the tip of the coccyx. The anteriorly concave thoracic kyphosis and sacrococcygeal kyphosis are primary curves, and the anteriorly convex cervical lordosis and lumbar lordosis are secondary curves that develop after birth. The cervical lordosis develops when the child begins to hold the head up, and the lumbar kyphosis develops when the child begins to walk.



Authors: Agur, Anne M.R.; Dalley, Arthur F.

Title: *Grant's Atlas of Anatomy, 12th Edition*

Copyright ©2009 Lippincott Williams & Wilkins

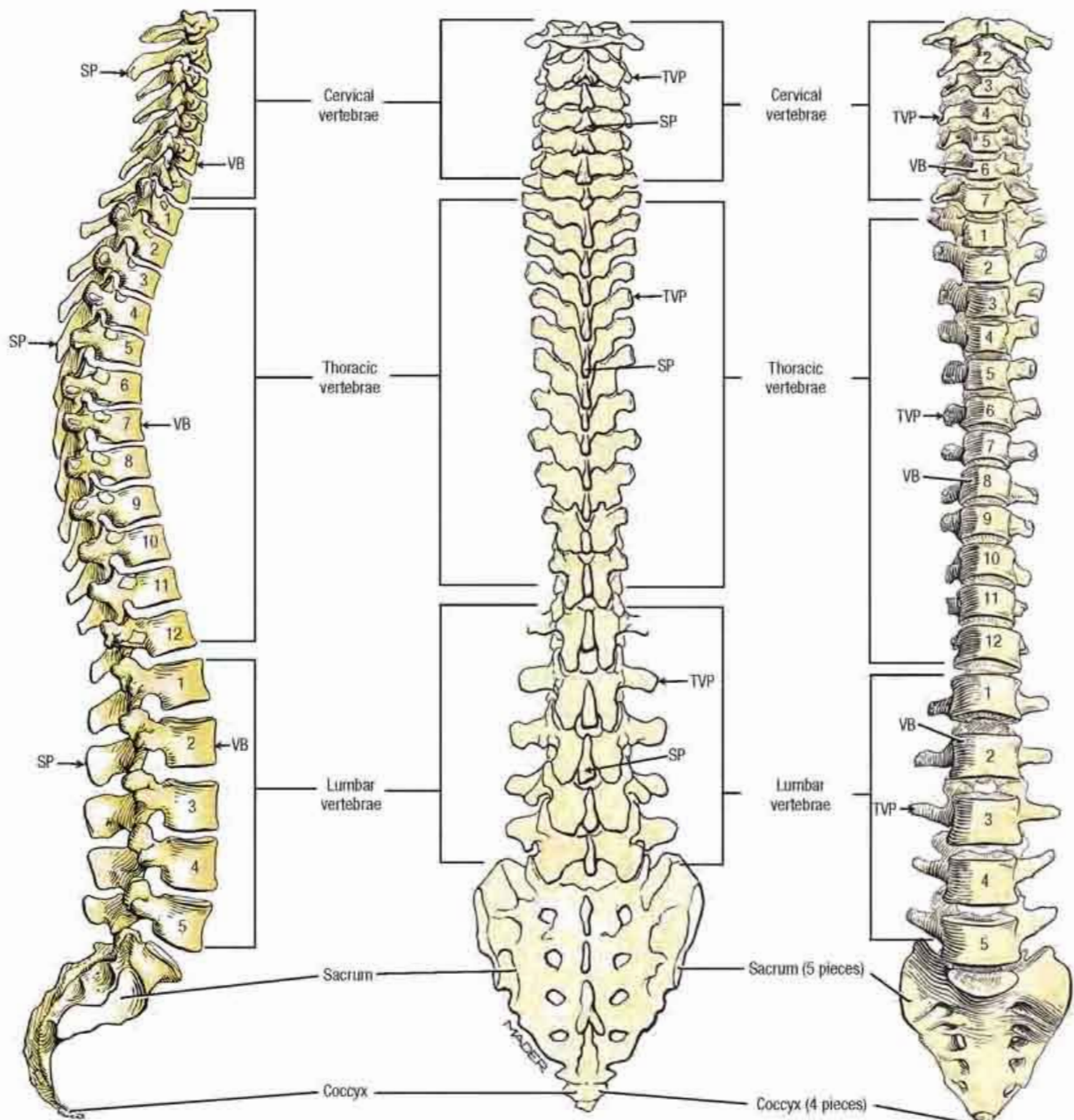
> Table of Contents > Chapter 4 - Back > 4.3 Three views of the vertebral column

---

## 4.3 Three views of the vertebral column

*Part of* "Chapter 4 - Back "

- The vertebral bodies (VB) vary in size and shape.
- Transverse processes (TVP) in the cervical region are directed laterally, inferiorly and anteriorly. In the thoracic region, they are directed laterally posteriorly, and superiorly, have a facet for the tubercle of the rib, and are stout. In the lumbar region, the TVPs point laterally and are long and slender.
- Generally, spinous processes (SP) are bifid in caucasians in the cervical region, long and spinelike in the thoracic region, and stout and oblong in the lumbar region. The cervical and thoracic SPs often overlap the adjacent, inferior vertebrae.



A. Lateral View

B. Posterior View

C. Anterior View

Authors: Agur, Anne M.R.; Dalley, Arthur F.

Title: *Grant's Atlas of Anatomy, 12th Edition*

Copyright ©2009 Lippincott Williams & Wilkins

> Table of Contents > Chapter 4 - Back > 4.4 Typical vertebra

---

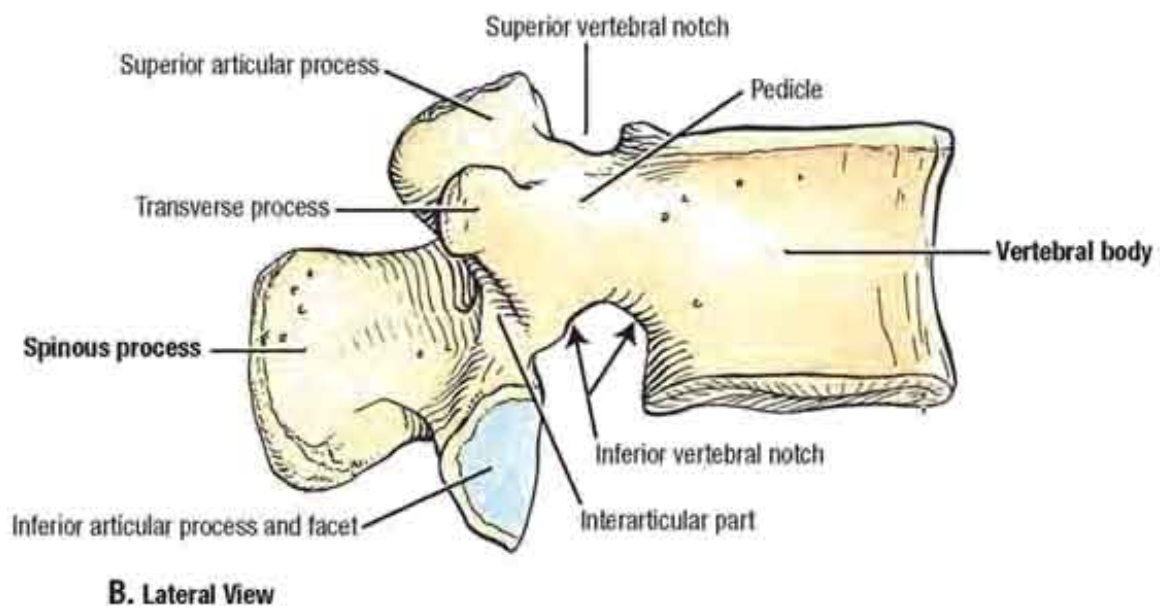
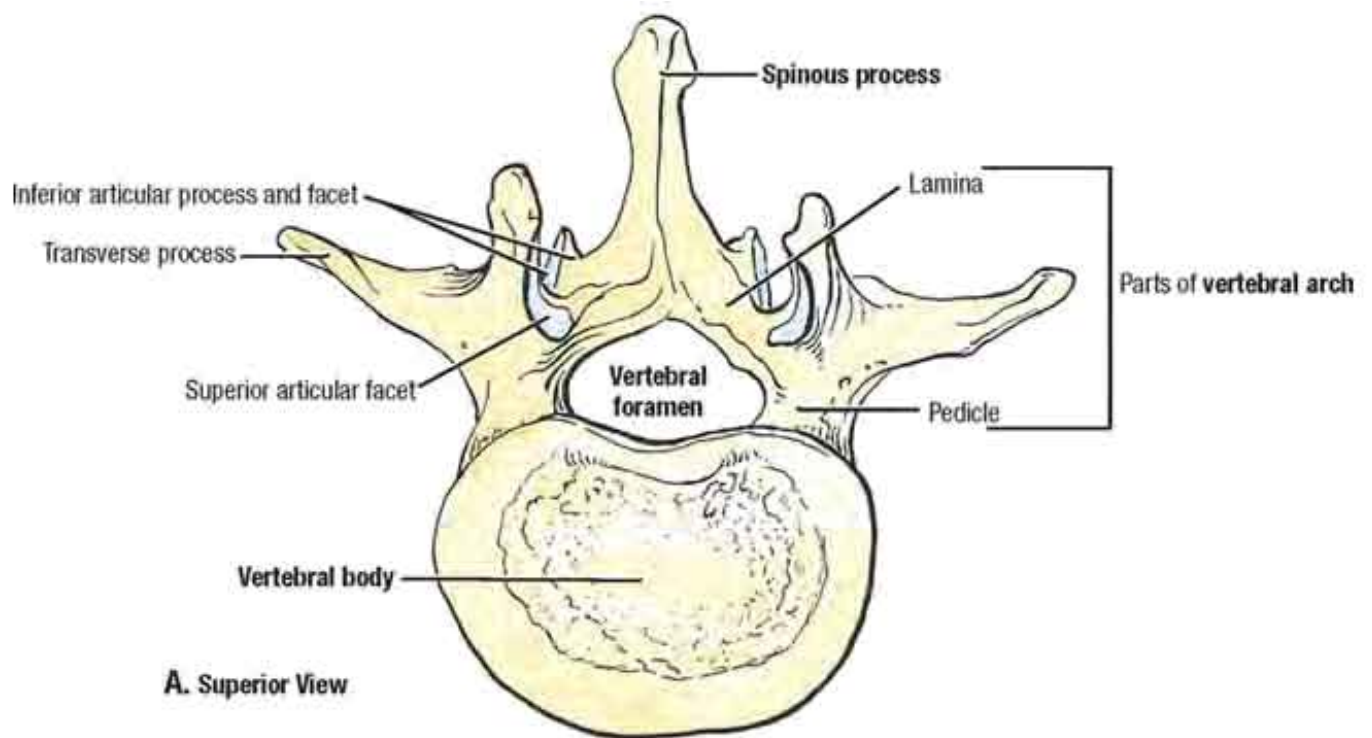
## 4.4 Typical vertebra

*Part of* "Chapter 4 - Back "

A typical vertebra (e.g., the 2nd lumbar vertebra) consists of the following parts:

- A vertebral body, situated anteriorly, functions to support weight.
- A vertebral arch, posterior to the body, with the body, encloses the vertebral foramen. Collectively, the vertebral foramina constitute the vertebral canal, in which the spinal cord lies. The function of a vertebral arch is to protect the spinal cord. The vertebral arch consists of two rounded pedicles, one on each side, which arise from the body, and two flat plates called laminae that unite posteriorly in the midline.
- Three processes, two transverse and one spinous, provide attachment for muscles and are the levers that help move the vertebrae.
- Four articular processes, two superior and two inferior, each have an articular facet. The articular processes project superiorly and inferiorly from the vertebral arch and come into apposition with the articular facet of the corresponding processes of the vertebrae above and below. The direction of the articular facets determines the nature of the movement between adjacent vertebrae and prevents the vertebrae from slipping anteriorly.



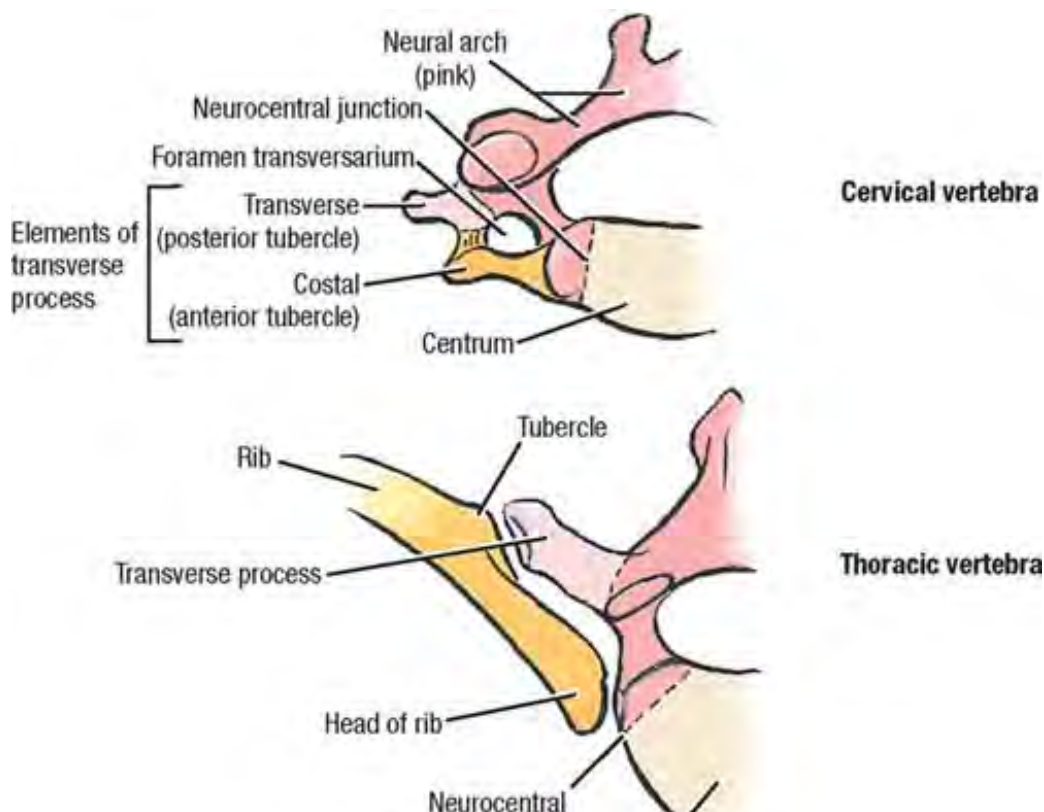


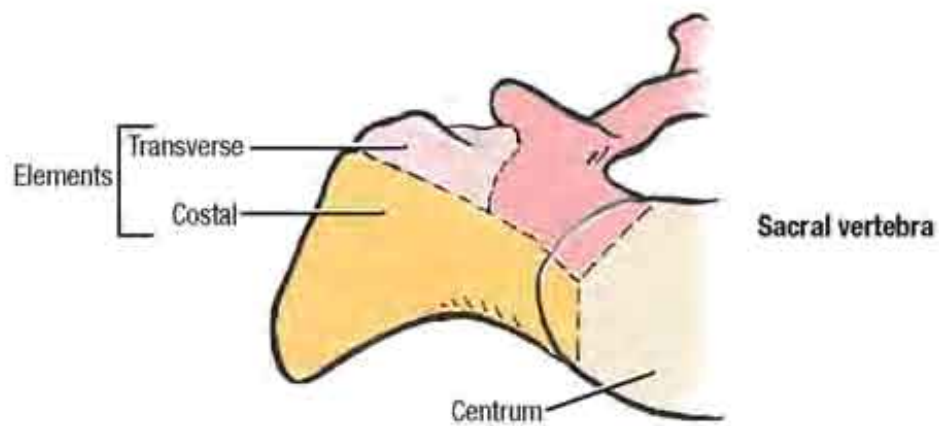
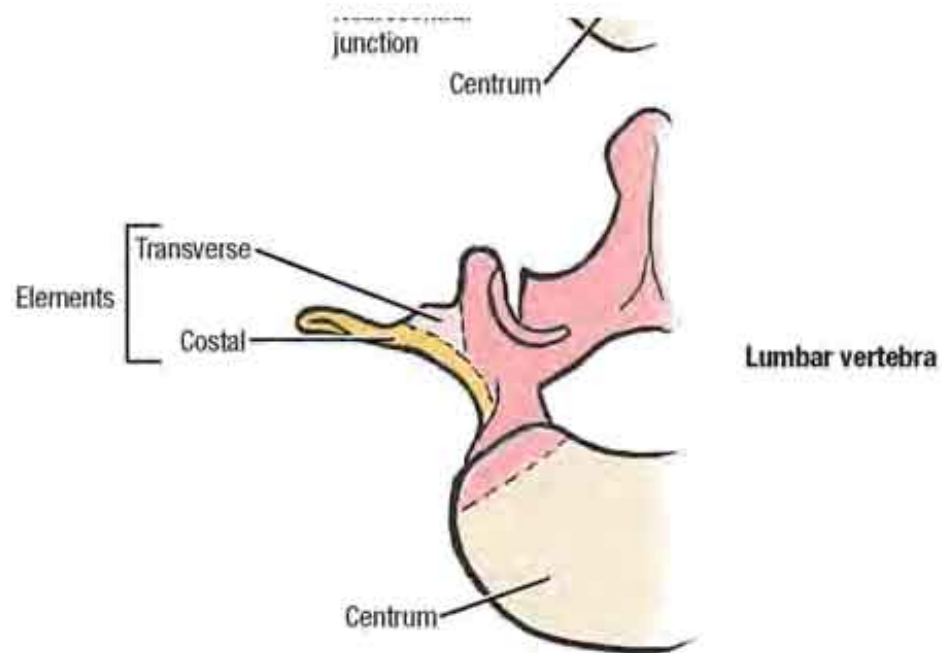
## 4.5 Homologous parts of vertebrae

*Part of "Chapter 4 - Back"*

A rib is a free costal element in the thoracic region; in the cervical and lumbar regions, it is represented by the anterior part of a transverse process, and in the sacrum, by the anterior part of the lateral mass. The heads of the ribs (thoracic region) articulate with the sides of the vertebral bodies posterior to the neurocentral junctions.

P.291





**Superior Views**

Authors: Agur, Anne M.R.; Dalley, Arthur F.

Title: *Grant's Atlas of Anatomy, 12th Edition*

Copyright ©2009 Lippincott Williams & Wilkins

> Table of Contents > Chapter 4 - Back > 4.6 Vertebral features and movements

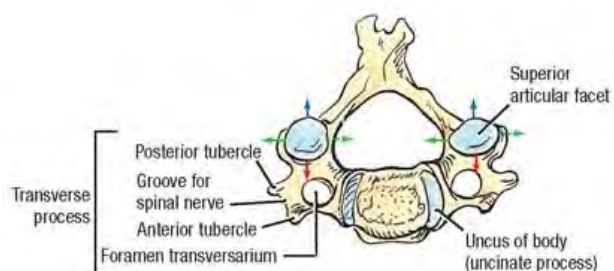
---

## 4.6 Vertebral features and movements

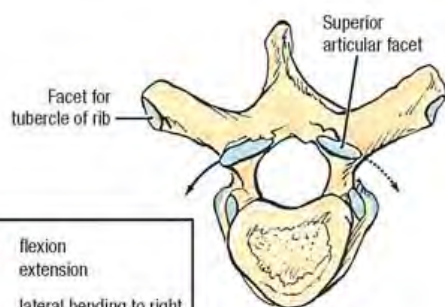
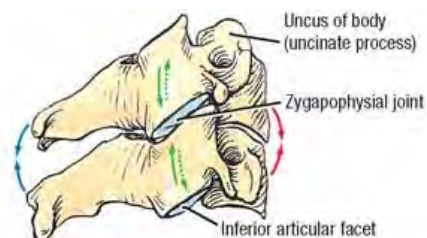
*Part of "Chapter 4 - Back "*

Direction of movement is indicated by *arrows*.

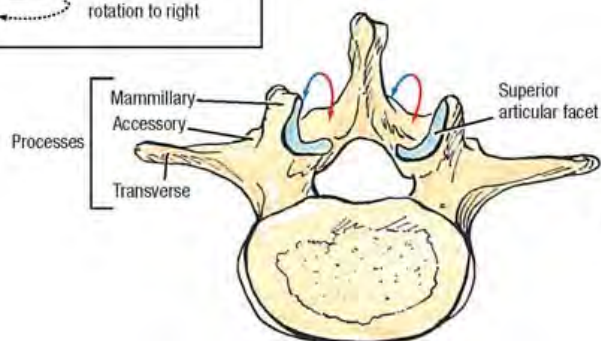
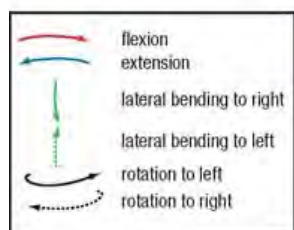
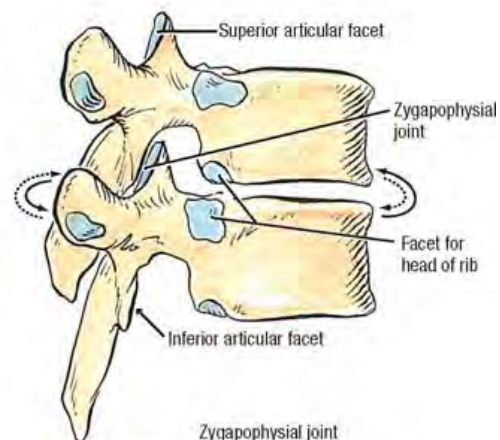
- In the thoracic and lumbar regions, the superior articular facets lie posterior to the pedicles, and the inferior facets are anterior to the laminae. Superior articular facets in the cervical region face mainly superiorly, in the thoracic region, mainly posteriorly, and in the lumbar region, mainly medially. The change in direction is gradual from cervical to thoracic but abrupt from thoracic to lumbar.
  - Although movements between adjacent vertebrae are relatively small, especially in the thoracic region, the summation of all the small movements produces a considerable range of movement of the vertebral column as a whole.
  - Movements of the vertebral column are freer in the cervical and lumbar regions than in the thoracic region. Lateral bending is freest in the cervical and lumbar regions; flexion of the vertebral column is greatest in the cervical region; extension is most marked in the lumbar region, but the interlocking articular processes prevent rotation.
  - The thoracic region is most stable because of the external support gained from the articulations of the ribs and costal cartilages with the sternum. The direction of the articular facets permits rotation, but flexion, extension, and lateral bending is severely restricted.
-



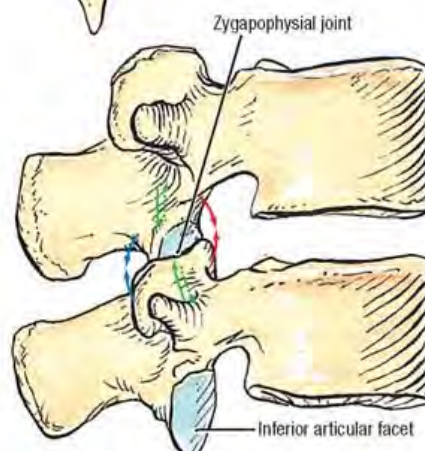
Cervical vertebrae



Thoracic vertebrae



Lumbar vertebrae



**Superior Views** - arrows indicate direction of movement of superior adjacent vertebra (not shown) relative to the inferior vertebra (shown here)

**Lateral Views** - arrows indicate direction of movement of the superior and inferior vertebra relative to each other



Authors: Agur, Anne M.R.; Dalley, Arthur F.

Title: *Grant's Atlas of Anatomy, 12th Edition*

Copyright ©2009 Lippincott Williams & Wilkins

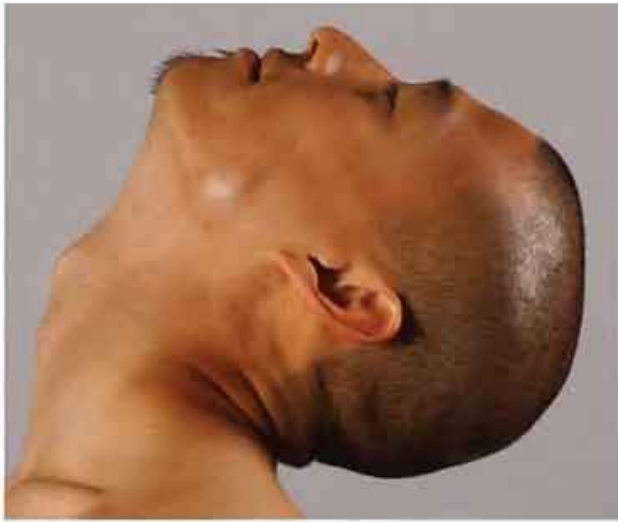
> Table of Contents > Chapter 4 - Back > 4.7 Surface anatomy with radiographic correlation of selected movements of the cervical spine

---

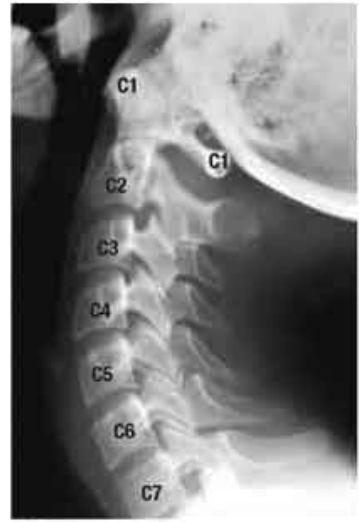## 4.7 Surface anatomy with radiographic correlation of selected movements of the cervical spine

*Part of* "Chapter 4 - Back "

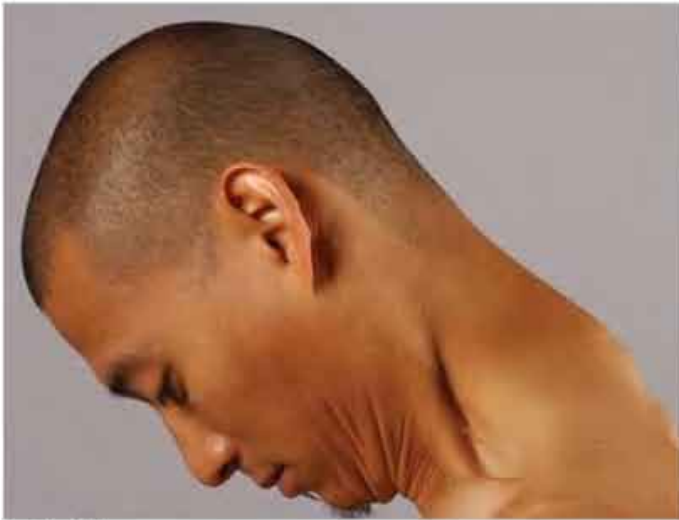
A. Extension of the neck. B. Radiograph of the extended cervical spine. C. Flexion of the neck. D. Radiograph of the flexed cervical spine. E. Head turned (rotated) to left. F. Radiograph of cervical spine rotated to left.



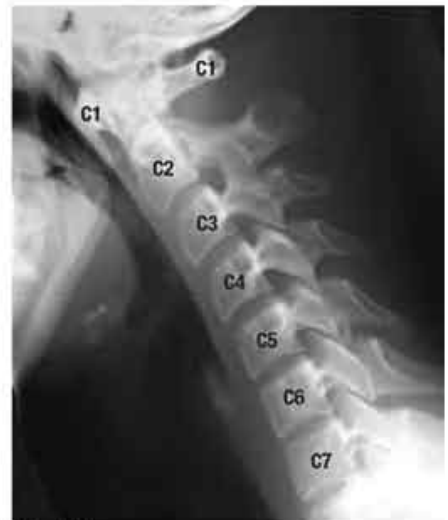A. Lateral View



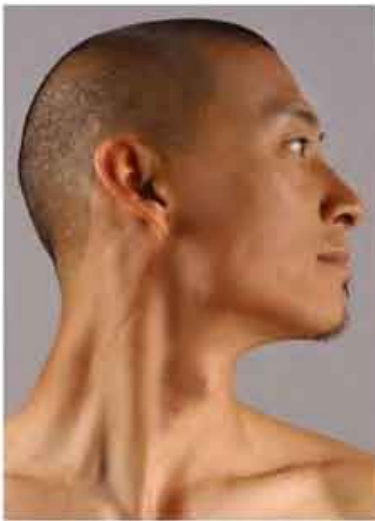B. Lateral View



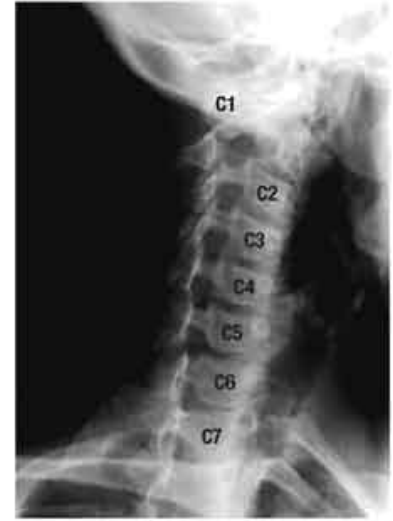C. Lateral View



D. Lateral View



E. Anterior View



F. Oblique View

Authors: Agur, Anne M.R.; Dalley, Arthur F.

Title: *Grant's Atlas of Anatomy, 12th Edition*

Copyright ©2009 Lippincott Williams & Wilkins

> Table of Contents > Chapter 4 - Back > 4.8 Surface anatomy with radiographic correlation of selected movements of the lumbar spine

---

## 4.8 Surface anatomy with radiographic correlation of selected movements of the lumbar spine

*Part of* "Chapter 4 - Back "

A. Flexion and extension of the trunk. B. Radiograph of the extended lumbar spine. C. Radiograph of the flexed lumbar spine. D. Lateral bending of the trunk. E. Radiograph of the lumbar spine during lateral bending.

---

P.294

### Body

Small and wider from side to side than anteroposteriorly; superior surface is concave with uncinate process; inferior surface is convex

### Vertebral foramen

Large and triangular

### Transverse processes

Foramina transversaria small or absent in C7; vertebral arteries and accompanying venous and sympathetic plexuses pass through foramina, except C7, which transmits only small accessory vertebral veins; anterior and posterior tubercles separated by groove for spinal nerve

### Articular processes

Superior articular facets directed superoposteriorly; inferior articular facets directed inferoanteriorly; obliquely placed facets are most nearly horizontal in this region

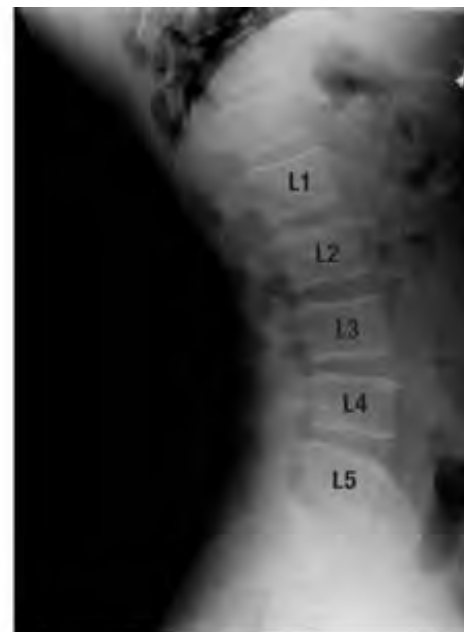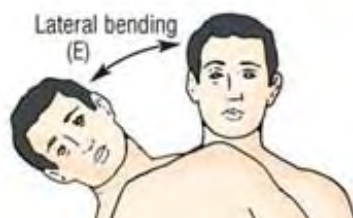
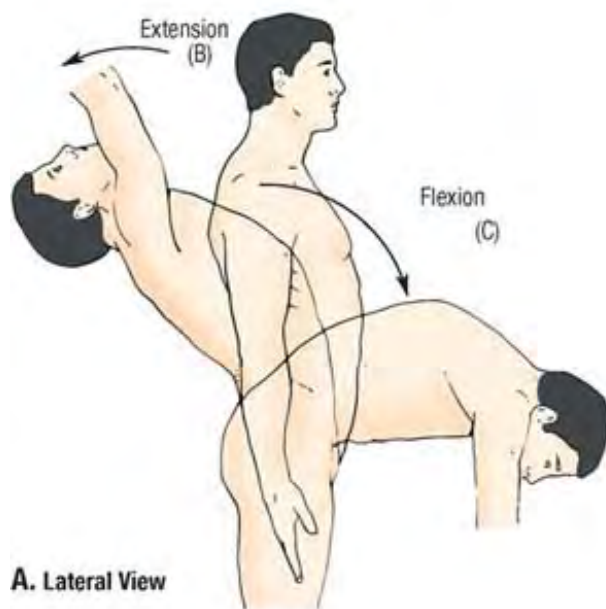
### Spinous process

Short (C3–C5) and bifid, only in Caucasians (C3–C5); process of C6 is long but that of C7 longer; C7 is called "vertebra prominens".

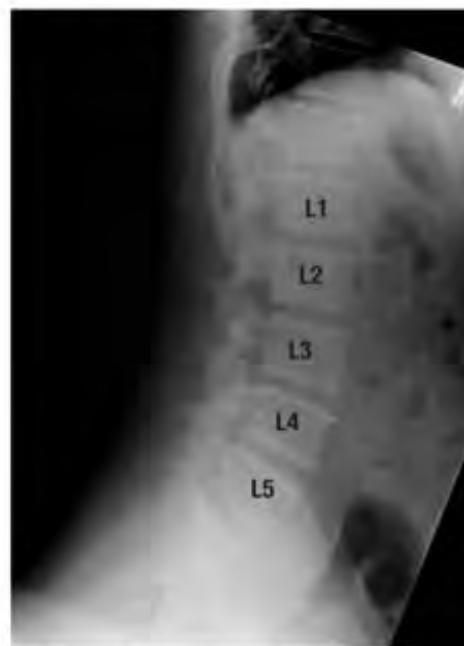<sup>a</sup> C1 and C2 vertebrae are atypical.

## Part Distinctive Characteristics

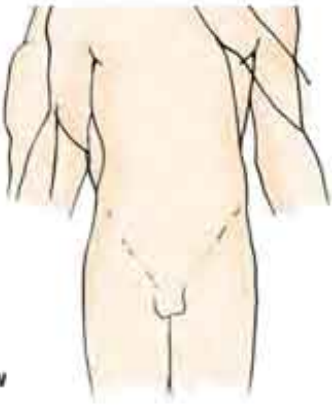
Table 4.1 Typical Cervical Vertebrae (C3-C7) <sup>a</sup>



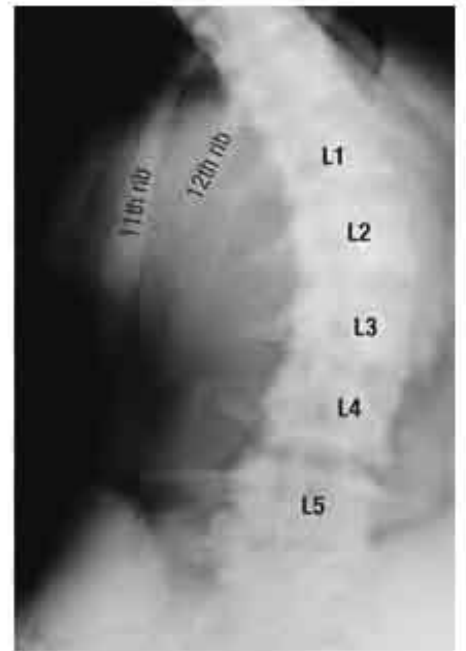
**B. Lateral View**



**C. Lateral View**



D. Anterior View



E. Anteroposterior View



Authors: Agur, Anne M.R.; Dalley, Arthur F.

Title: *Grant's Atlas of Anatomy, 12th Edition*

Copyright ©2009 Lippincott Williams & Wilkins

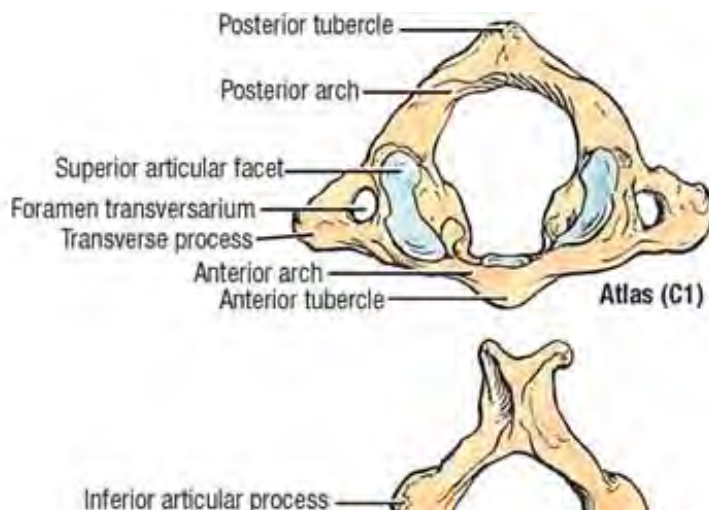
> Table of Contents > Chapter 4 - Back > 4.9 Cervical vertebrae

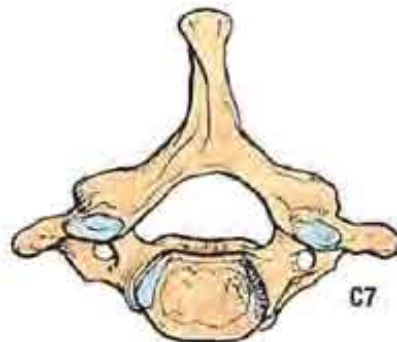
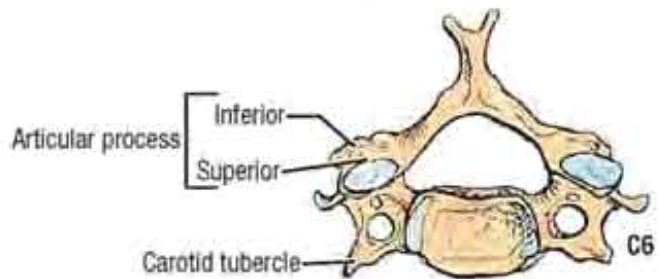
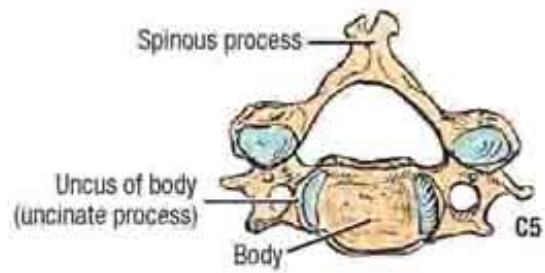
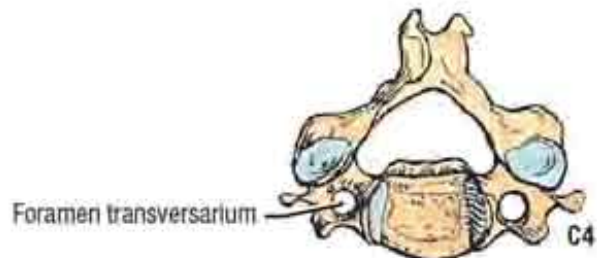
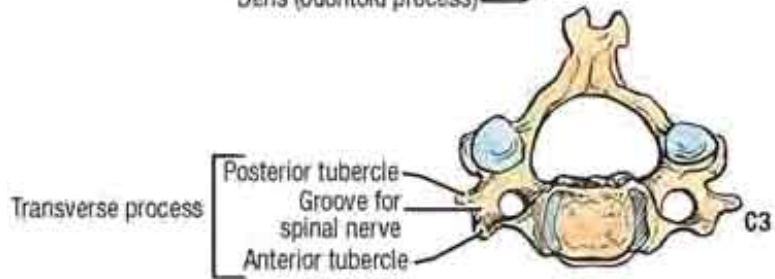
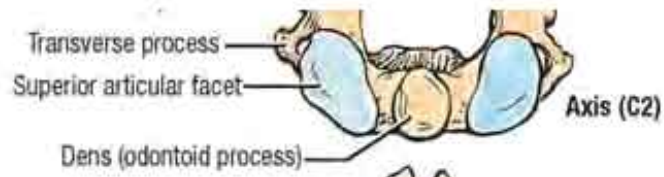## 4.9 Cervical vertebrae

Part of "Chapter 4 - Back"

The bodies of the cervical vertebrae can be dislocated in neck injuries with less force than is required to fracture them. Because of the large vertebral canal in the cervical region, slight dislocation can occur without damaging the spinal cord. When a cervical vertebra is severely dislocated, it injures the spinal cord. If the dislocation does not result in "facet jumping" with locking of the displaced articular processes, the cervical vertebrae may self-reduce (slip back into place) so that a radiograph may not indicate that the cord has been injured. MRI may reveal the resulting soft tissue damage.

P.295





**Superior Views**



Authors: Agur, Anne M.R.; Dalley, Arthur F.

Title: *Grant's Atlas of Anatomy, 12th Edition*

Copyright ©2009 Lippincott Williams & Wilkins

> Table of Contents > Chapter 4 - Back > 4.10 Cervical spine

---

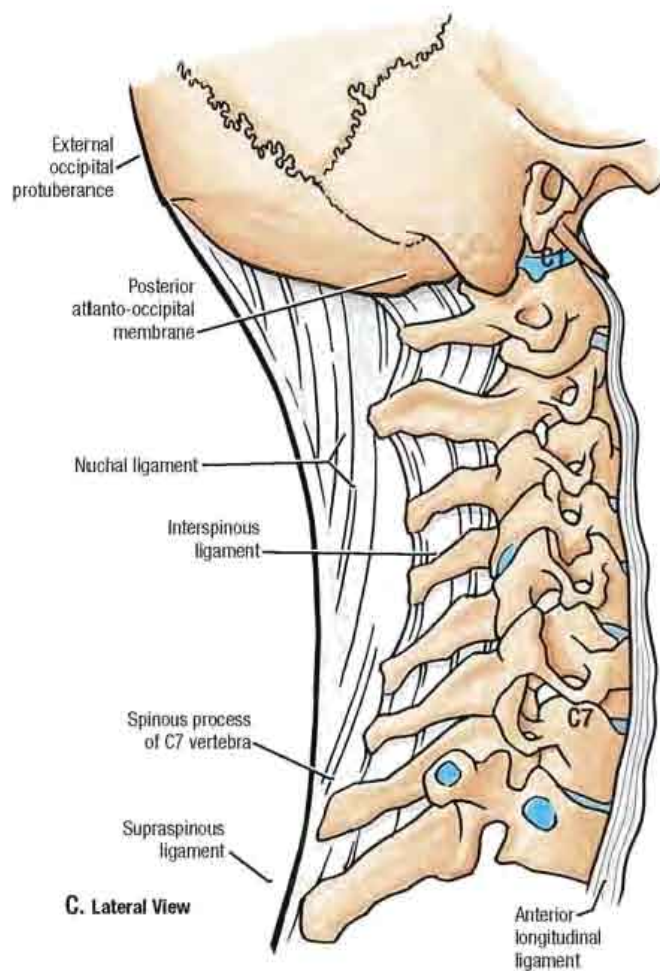
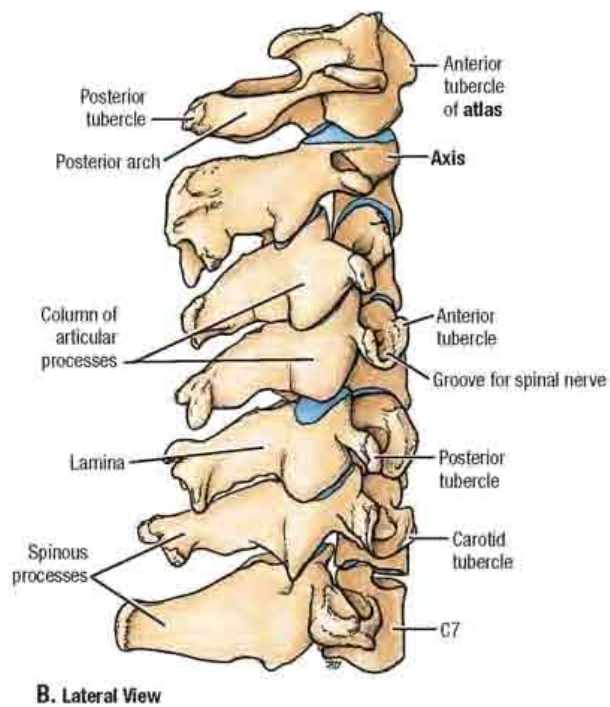
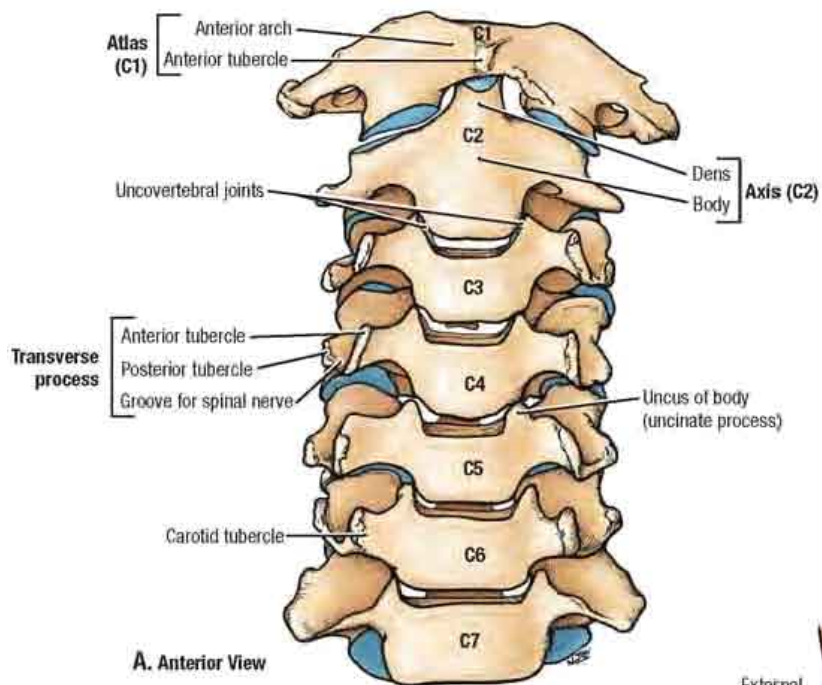
## 4.10 Cervical spine

*Part of* "Chapter 4 - Back "

A and B. Articulated cervical vertebrae. C. Ligaments.

---

P.296





Authors: Agur, Anne M.R.; Dalley, Arthur F.

Title: *Grant's Atlas of Anatomy, 12th Edition*

Copyright ©2009 Lippincott Williams & Wilkins

> Table of Contents > Chapter 4 - Back > 4.11 Imaging of the cervical spine

---

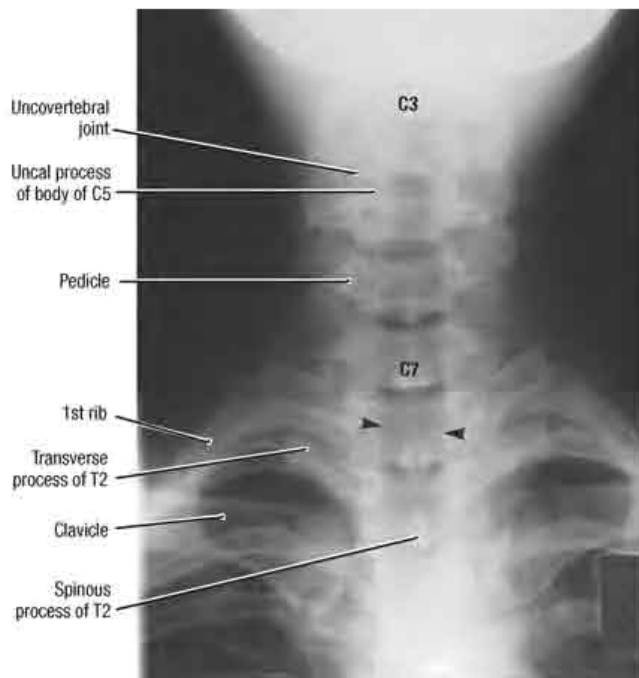
## 4.11 Imaging of the cervical spine

*Part of* "Chapter 4 - Back "

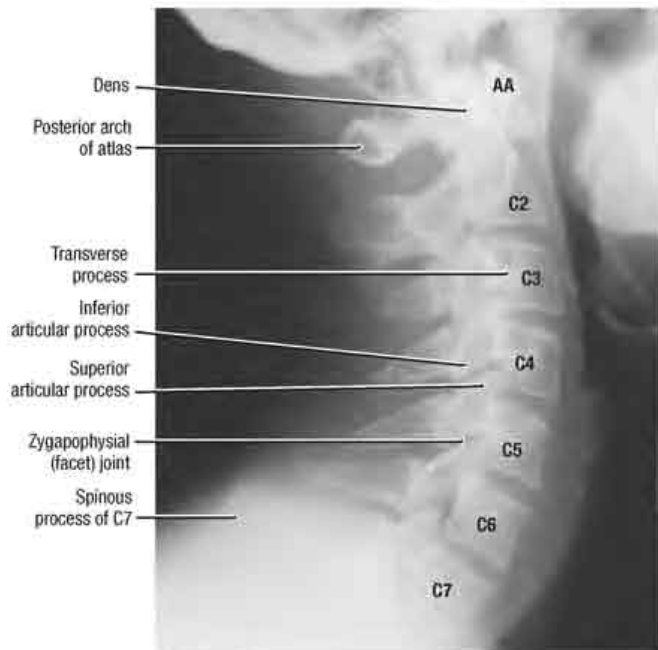
A and B. Radiographs. The arrowheads demarcate the margins of the (*black*) column of air in the trachea. C and D. Three-dimensional (3D) reconstructed computed tomographic (CT) images.

---

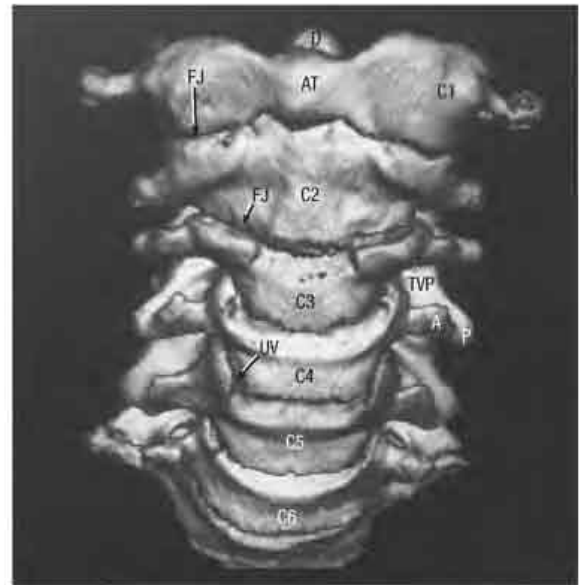
P.297



**A. Anteroposterior View**

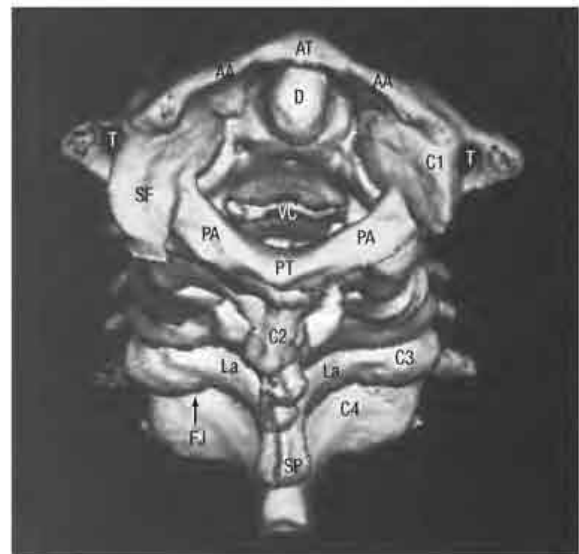


**B. Lateral View**



**C. Anterior View**

A	Anterior tubercle of transverse process	PA	Posterior arch of C1
AA	Anterior arch of C1	PT	Posterior tubercle of C1
AT	Anterior tubercle of C1	SF	Superior articular facet of C1
C1-C7	Vertebrae	SP	Spinous process
D	Dens (odontoid) process of C2	T	Foramen transversarium
FJ	Zygapophysial (facet) joint	TVP	Transverse process
La	Lamina	UV	Uncovertebral joint
P	Posterior tubercle of transverse process	VC	Vertebral canal



**D. Posterior View**

Authors: Agur, Anne M.R.; Dalley, Arthur F.

Title: *Grant's Atlas of Anatomy, 12th Edition*

Copyright ©2009 Lippincott Williams & Wilkins

> Table of Contents > Chapter 4 - Back > 4.12 Atlas and axis and the atlantoaxial joint

---

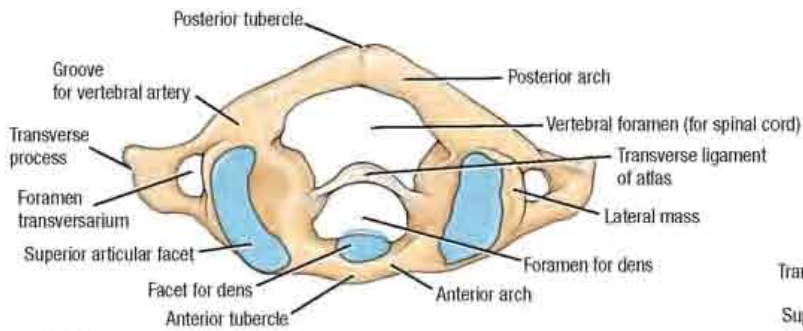
## 4.12 Atlas and axis and the atlantoaxial joint

*Part of* "Chapter 4 - Back "

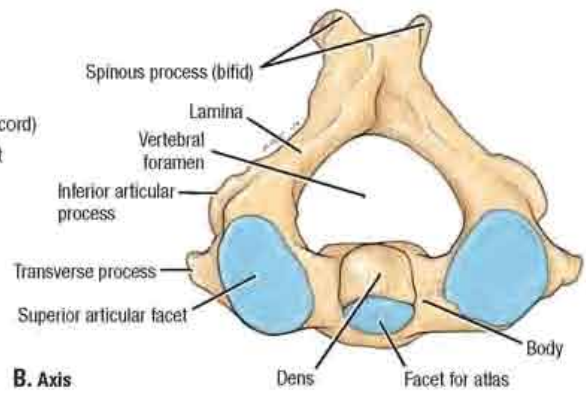
A. Atlas. B. Axis. C. Radiograph taken through the open mouth. D. Articulated atlas and axis. E. Median section with ligaments.

---

P.298

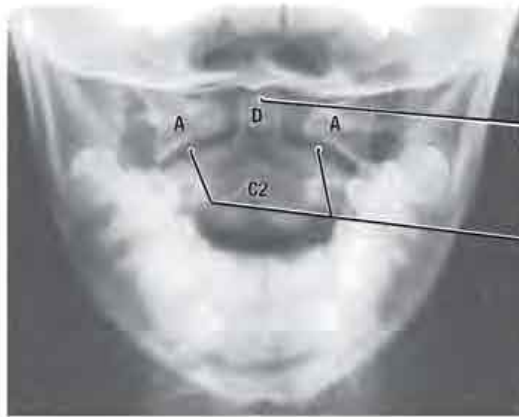


**A. Atlas**

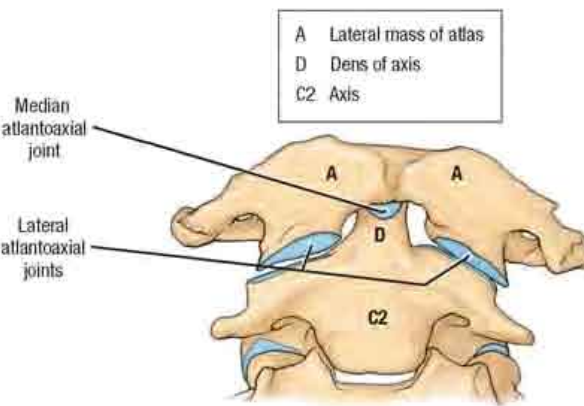


**B. Axis**

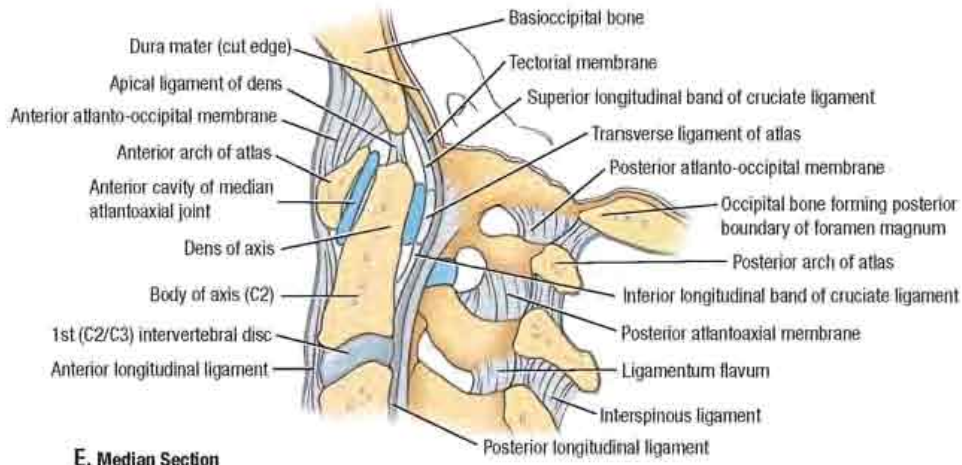
**Superior Views**



**C. Anteroposterior View**



**D. Anterior View**



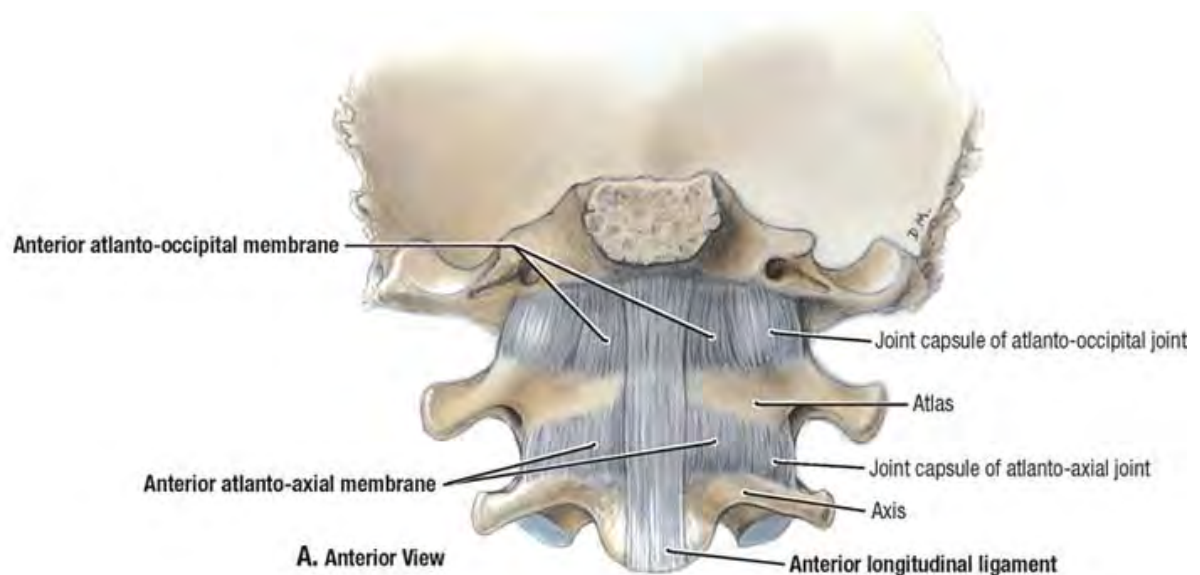
**E. Median Section**

## 4.13 Craniovertebral joints and vertebral artery

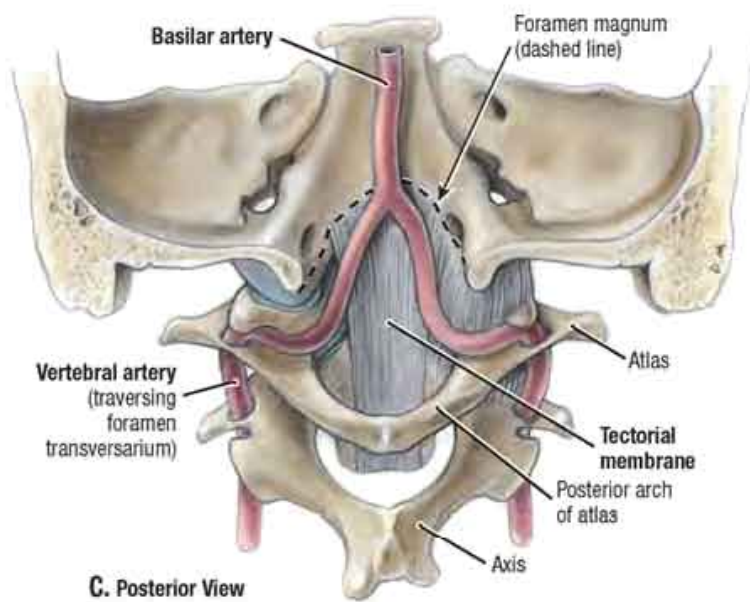
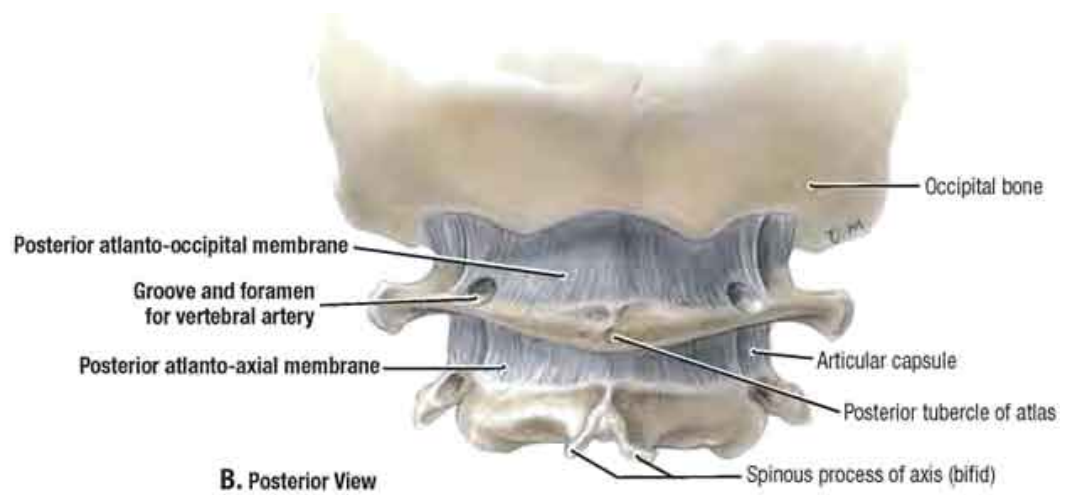
Part of "Chapter 4 - Back "

A. Anterior atlanto-axial and atlanto-occipital membranes. The anterior longitudinal ligament ascends to blend with, and form a central thickening in, the anterior atlanto-axial and atlanto-occipital membranes. B. Posterior atlanto-axial and atlanto-occipital membranes. Inferior to the axis (C2 vertebra), ligamenta flava occur in this position. C. Tectorial membrane and vertebral artery. The tectorial membrane is a superior continuation of the posterior longitudinal ligament superior to the axis. After coursing through the foramina transversaria of vertebrae C6–C1, the arteries turning medially, grooving the superior aspect of the posterior arch of the atlas and piercing the posterior atlanto-occipital membrane (B). The right and left vertebral arteries traverse the foramen magnum and merge to form the intracranial basilar artery.

P.299







Authors: Agur, Anne M.R.; Dalley, Arthur F.  
Title: *Grant's Atlas of Anatomy, 12th Edition*  
Copyright ©2009 Lippincott Williams & Wilkins

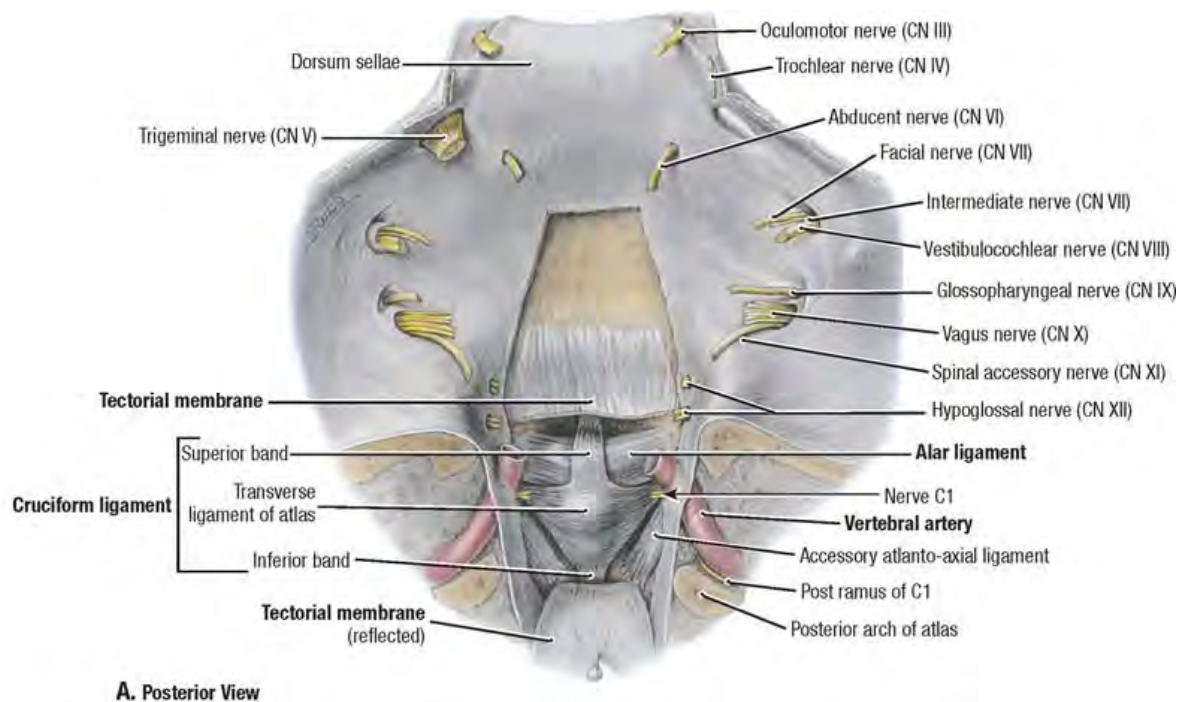
> Table of Contents > Chapter 4 - Back > 4.14 Ligaments of atlanto-occipital and atlantoaxial joints

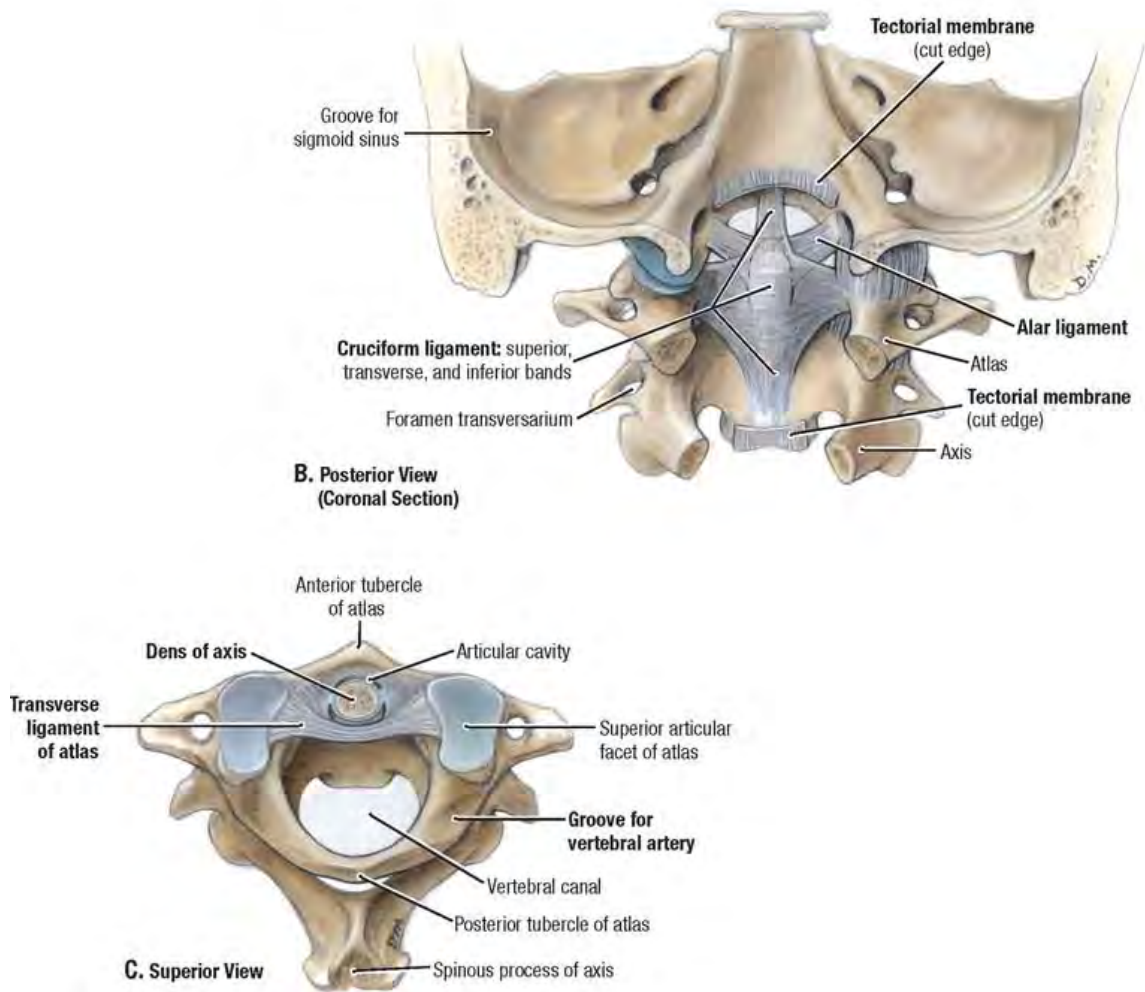
## 4.14 Ligaments of atlanto-occipital and atlantoaxial joints

Part of "Chapter 4 - Back "

A. Cranial nerves and dura mater of posterior cranial fossa with dura mater and tentorial membrane incised and removed to reveal the medial atlanto-axial joint. B. The alar ligaments serve as check ligaments for the rotary movements of the atlanto-axial joints. B and C. The transverse ligament (band) of the cruciform ligament provides the posterior wall of a socket that receives the dens of the axis, forming a pivot joint.

P. 300





## Body

Heart-shaped; has one or two costal facets for articulation with head of rib

Vertebral foramen

Circular and smaller than those of cervical and lumbar vertebrae

Transverse processes

Long and strong and extend posterolaterally; length diminishes from T1 to T12; T1–T10 have transverse costal facets for articulation with tubercle of a rib

Articular processes

Superior articular facets directed posteriorly and slightly laterally; inferior articular facets directed anteriorly and slightly medially

Spinous process

Long and slopes posteroinferiorly; tip extends to level of vertebral body below

## Table 4.2 Thoracic Vertebrae

## 4.15 Thoracic vertebrae

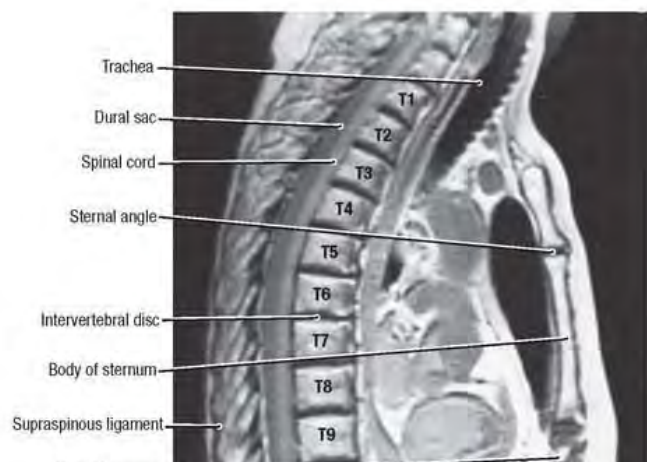
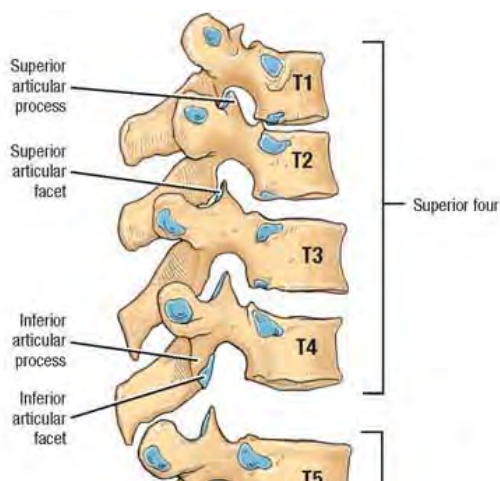
Part of "Chapter 4 - Back "

A. Features. B. MRI scan of thoracic spine, median section.

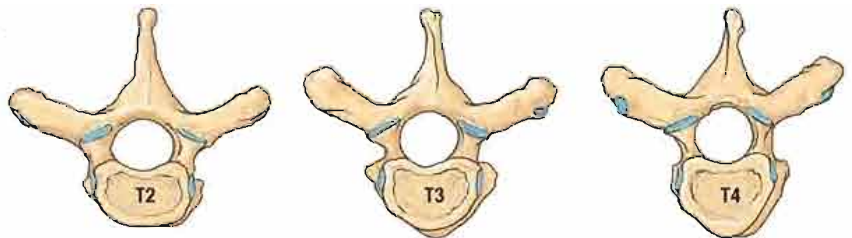
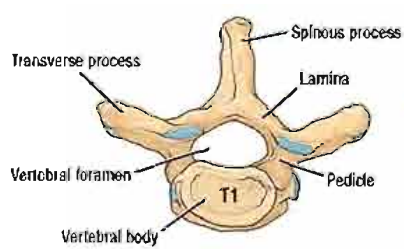
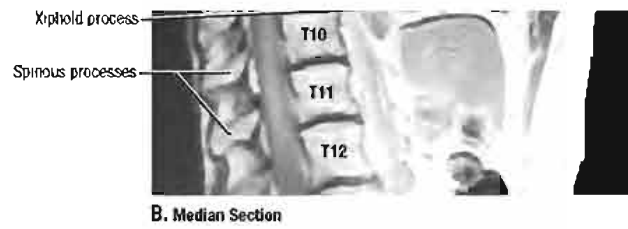
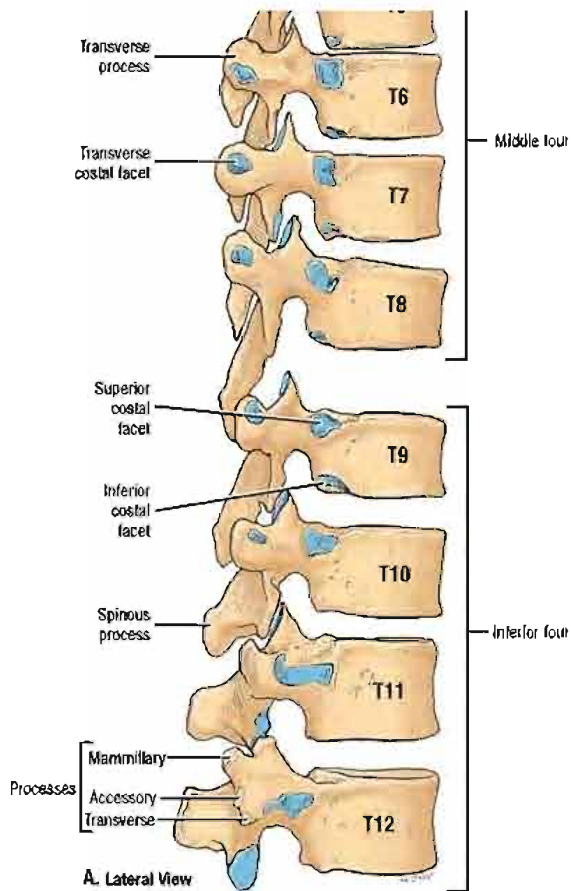
P.301

C. Comparative anatomy. The vertebral bodies increase in size as the vertebral column descends, each bearing an increasing amount of weight transferred by the vertebra above. Although the characteristics of the superior aspect of vertebra T12 are distinctly thoracic, its inferior aspect has lumbar characteristics for articulation with vertebra L1. The abrupt transition allowing primarily rotational movements with vertebra T11 while disallowing rotational movements with vertebral L1 makes vertebra T12 especially susceptible to fracture. D. Intra- and extra-articular ligaments of the costovertebral articulations. Typically, the head of each rib articulates with the bodies of two adjacent vertebrae and the intervertebral disc between them, and the tubercle of the rib articulates with the transverse process of the inferior vertebra.

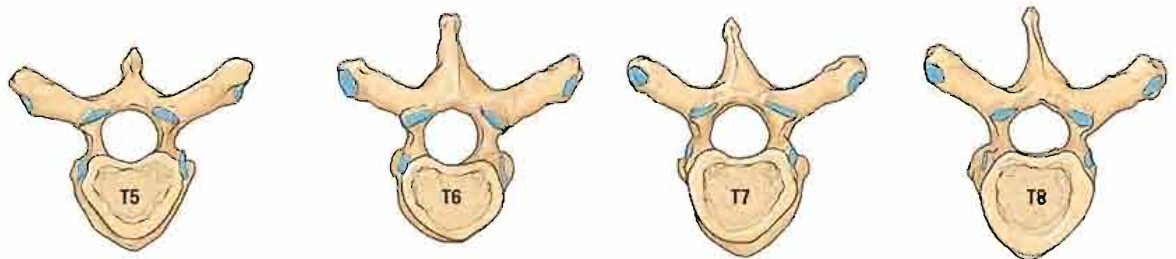
P.302



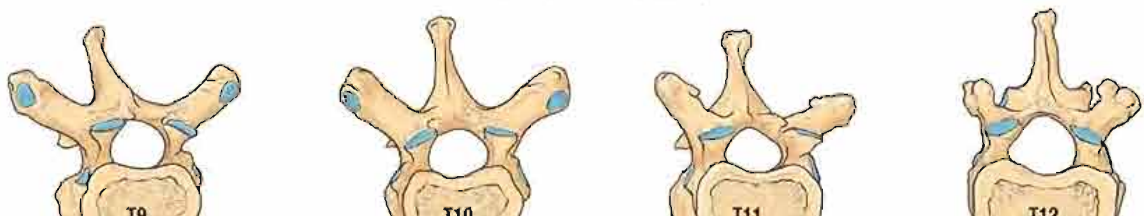


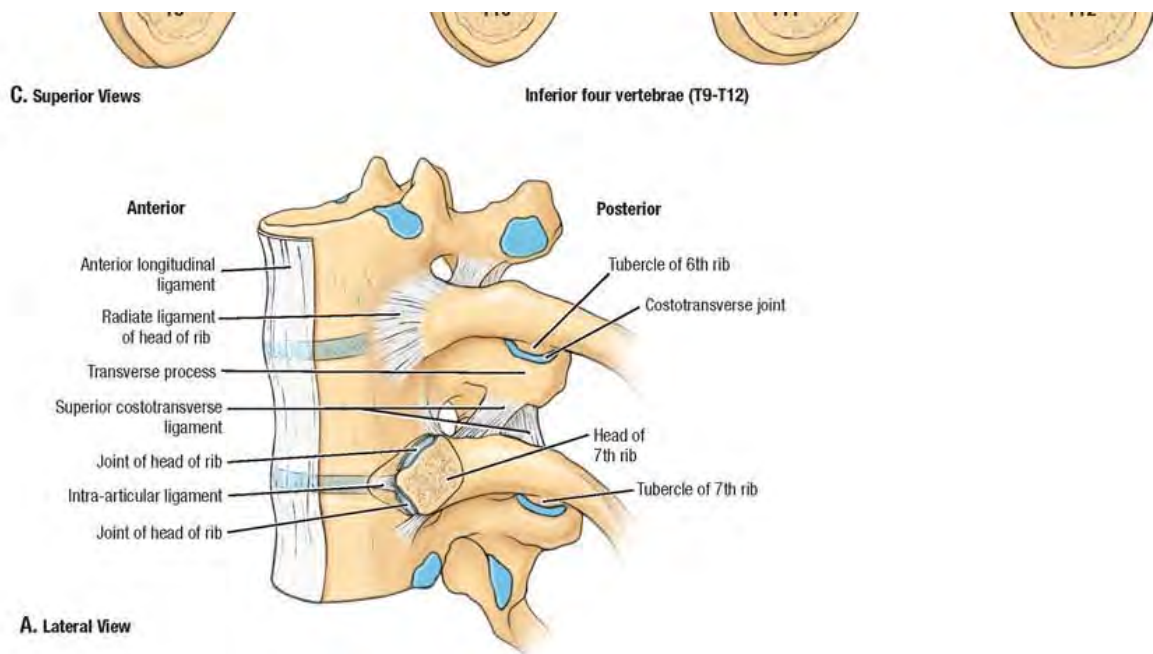


**Superior four vertebrae (T1-T4)**



**Middle four vertebrae (T5-T8)**





Body

Massive; kidney-shaped when viewed superiorly

Vertebral foramen

Triangular; larger than in thoracic vertebrae and smaller than in cervical vertebrae

Transverse processes

Long and slender; accessory process on posterior surface of base of each transverse process

Articular processes

Superior articular facets directed posteromedially (or medially); inferior articular facets directed anterolaterally (or laterally); mamillary process on posterior surface of each superior articular process

Spinous process

Short and sturdy; thick, broad, and rectangular

Part Distinctive Characteristics

## Table 4.3 Lumbar Vertebrae

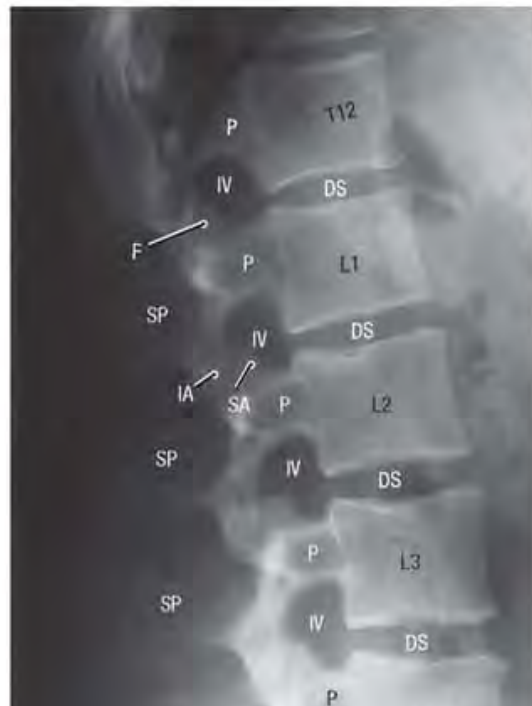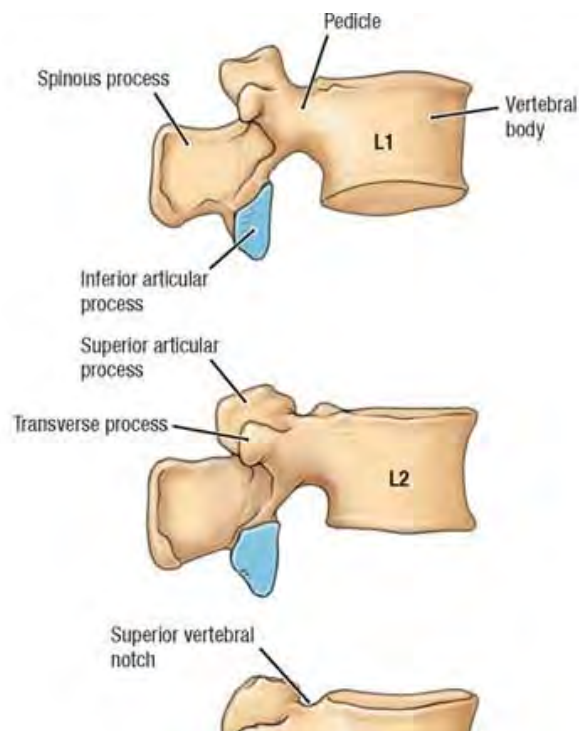
## 4.16 Lumbar vertebrae

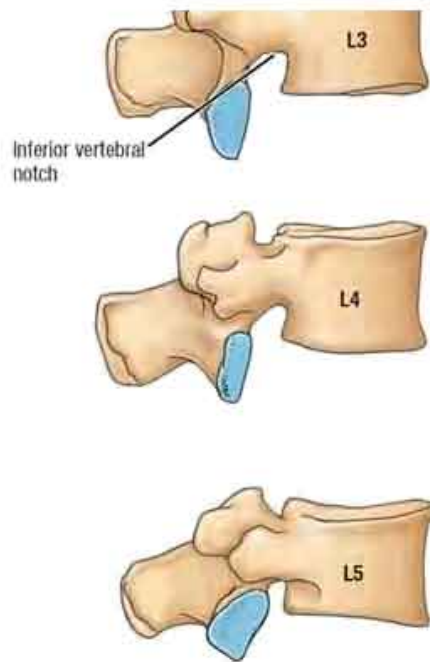
Part of "Chapter 4 - Back "

A, C , and D. Features. B. Radiograph. A laminectomy is the surgical excision of one or more spinous processes and their supporting laminae in a particular region of the vertebral column i.e., removal of most of the vertebral arch by transecting the pedicles. Laminectomies provide access to the vertebral canal to relieve pressure on the spinal cord or nerve roots, commonly caused by a tumor, herniated IV disc, or bony hypertrophy (excess growth). Laminectomies are most commonly performed in the lumbar region.

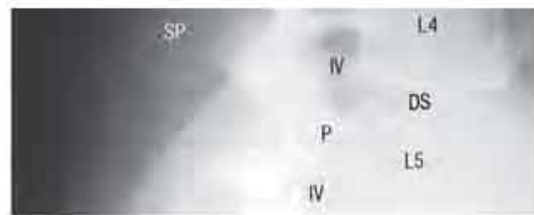
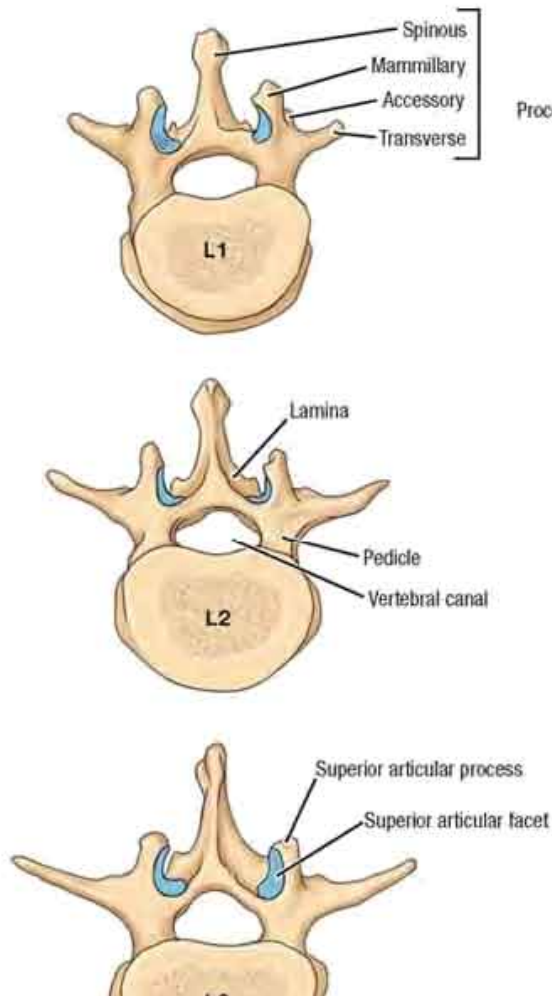
P.303

P.304





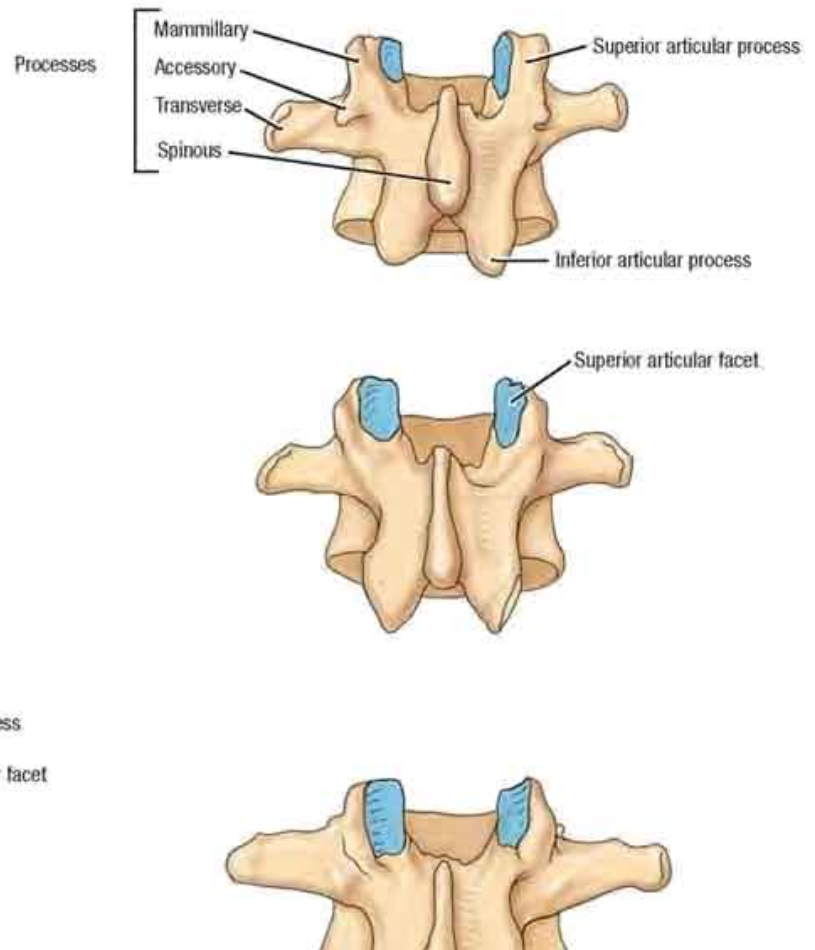
**A. Lateral Views**



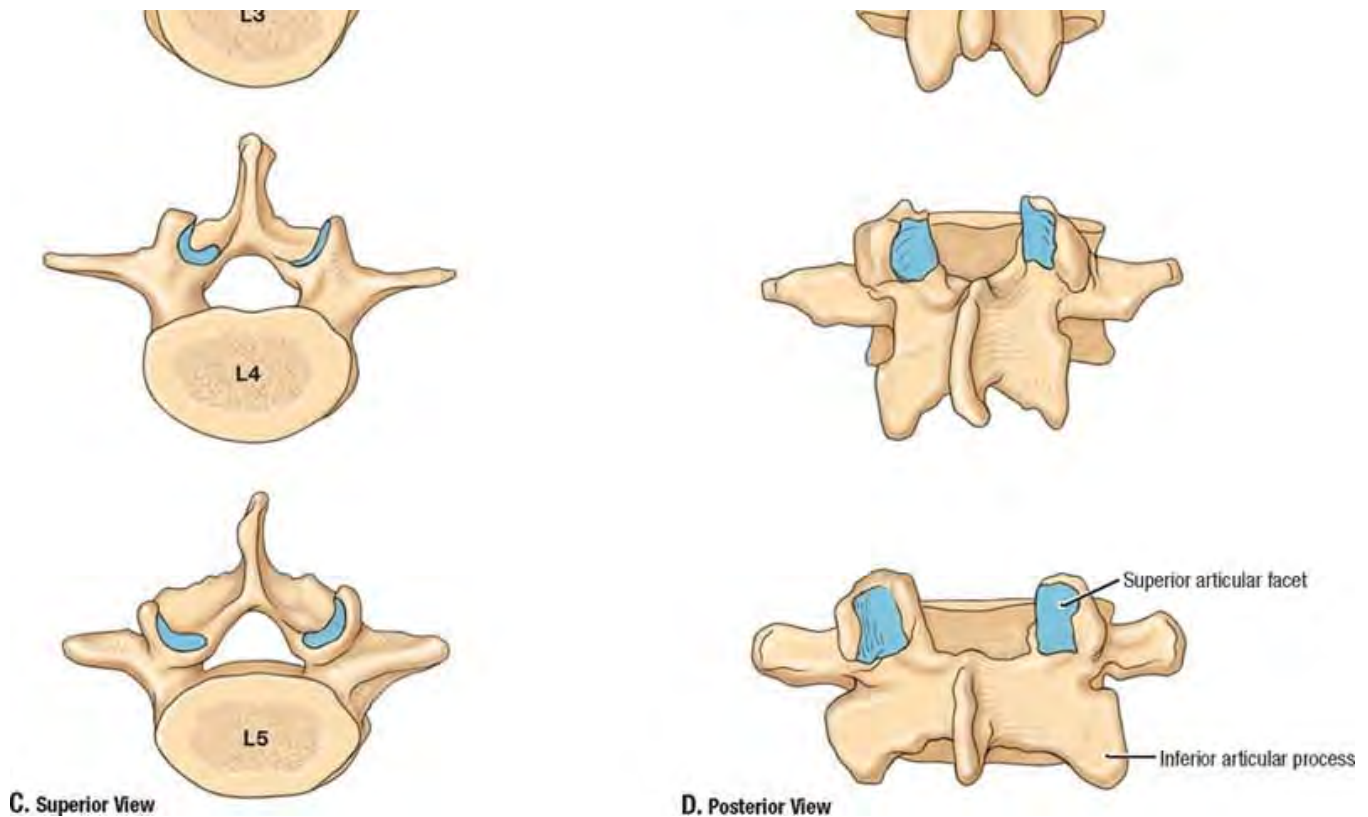
**B. Lateral View**

**Key for B**

F	Zygapophysial (facet) joint
DS	Intervertebral disc space
IA	Inferior articular process
IV	Intervertebral foramen
P	Pedicle
SA	Superior articular process
SP	Spinous process
T12-L5	Vertebral bodies







When the zygapophyseal joints are injured or develop osteophytes during aging (osteoarthritis), the related spinal nerves are affected. This causes pain along the distribution pattern of the dermatomes and spasm in the muscles derived from the associated myotomes (a myotome consists of all the muscles or parts of muscles receiving innervation from one spinal nerve). Denervation of lumbar zygapophysial joints is a procedure that may be used for treatment of back pain caused by disease of these joints. The nerves are sectioned near the joints or are destroyed by radiofrequency percutaneous rhizolysis (root dissolution). The denervation process is directed at the articular branches of two adjacent posterior rami of the spinal nerves because each joint receives innervation from both the nerve exiting that level and the superadjacent nerve.



Authors: Agur, Anne M.R.; Dalley, Arthur F.

Title: *Grant's Atlas of Anatomy, 12th Edition*

Copyright ©2009 Lippincott Williams & Wilkins

> Table of Contents > Chapter 4 - Back > 4.17 Structure and innervation of intervertebral discs and zygapophysial joints

---

## 4.17 Structure and innervation of intervertebral discs and zygapophysial joints

*Part of "Chapter 4 - Back "*

A. Anulus fibrosus and intervertebral foramen. Sections have been removed from the superficial layers of the inferior intervertebral disc to show the change in direction of the fibers in the concentric layers of the anulus fibrosus. B. Innervation of zygapophysial joint and intervertebral disc.

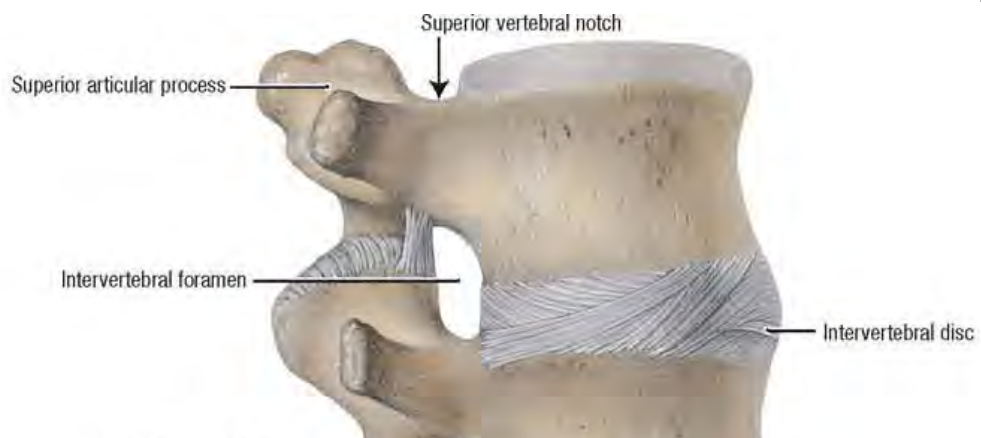
---

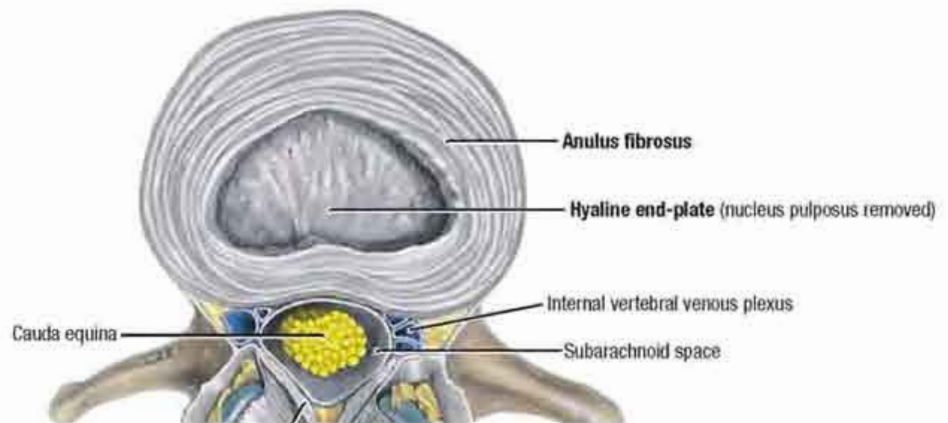
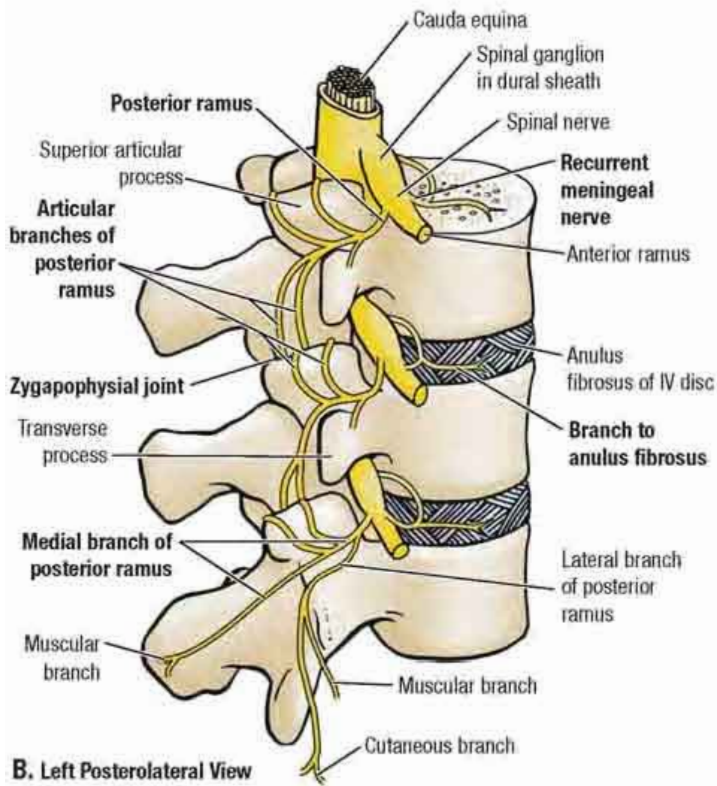
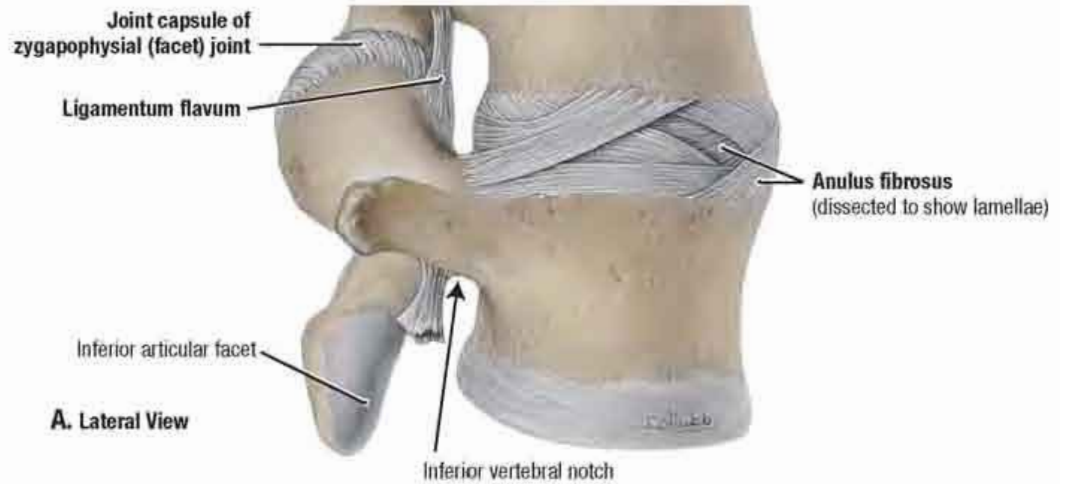
P.305

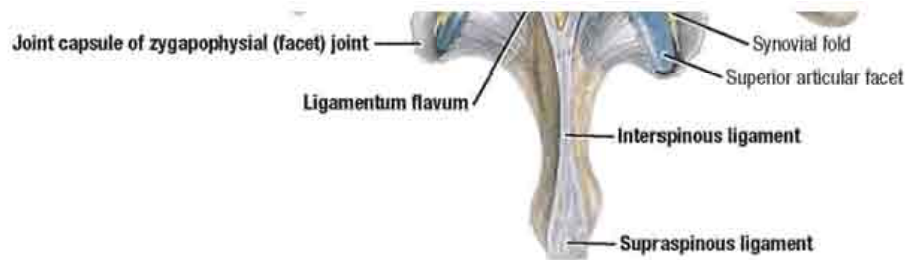
C. Transverse section. The nucleus pulposus has been removed, and the cartilaginous epiphyseal plate exposed. There are fewer rings of the anulus fibrosus posteriorly, and consequently, this portion of the annulus fibrosus is thinner. The ligamentum flavum, interspinous, and supraspinous ligaments are continuous. D. CT image of L4/L5 intervertebral disc.

---

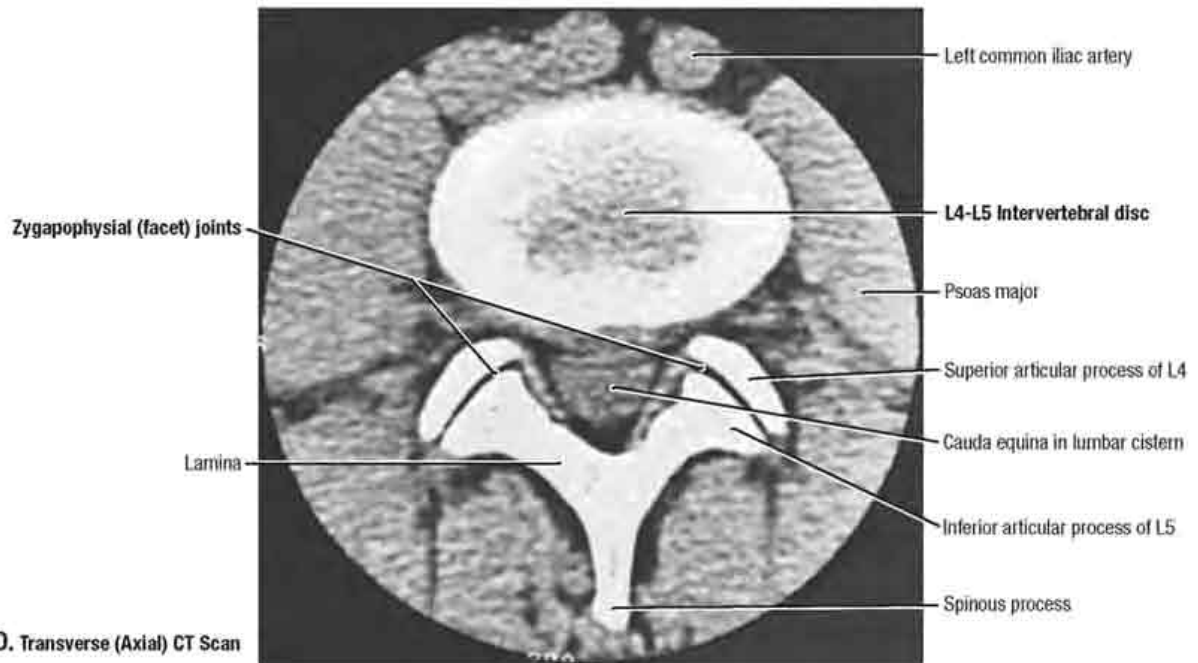
P.306







**C. Transverse Section, Superior View**



**D. Transverse (Axial) CT Scan**

Authors: Agur, Anne M.R.; Dalley, Arthur F.

Title: *Grant's Atlas of Anatomy, 12th Edition*

Copyright ©2009 Lippincott Williams & Wilkins

> Table of Contents > Chapter 4 - Back > 4.18 Intervertebral discs: ligaments and movements

---

## 4.18 Intervertebral discs: ligaments and movements

*Part of* "Chapter 4 - Back "

A. Anterior longitudinal ligament and ligamenta flava. The pedicles of T9 to T11 were sawed through, and the posterior aspect of the bodies is shown in B.

B. Posterior longitudinal ligament. C. Intervertebral disc during loading and movement.

- The anterior and posterior longitudinal ligaments are ligaments of the vertebral bodies; the ligamenta flava are ligaments of the vertebral arches.
- The anterior longitudinal ligament consists of broad, strong, fibrous bands that are attached to the intervertebral discs and vertebral bodies anteriorly and are perforated by the foramina for arteries and veins passing to and from the vertebral bodies.
- The ligamenta flava, composed of elastic fibers, extend between adjacent laminae; right and left ligaments converge in the median plane. They extend laterally to the articular processes, where they blend with the joint capsule of the zygapophysial joint.

---

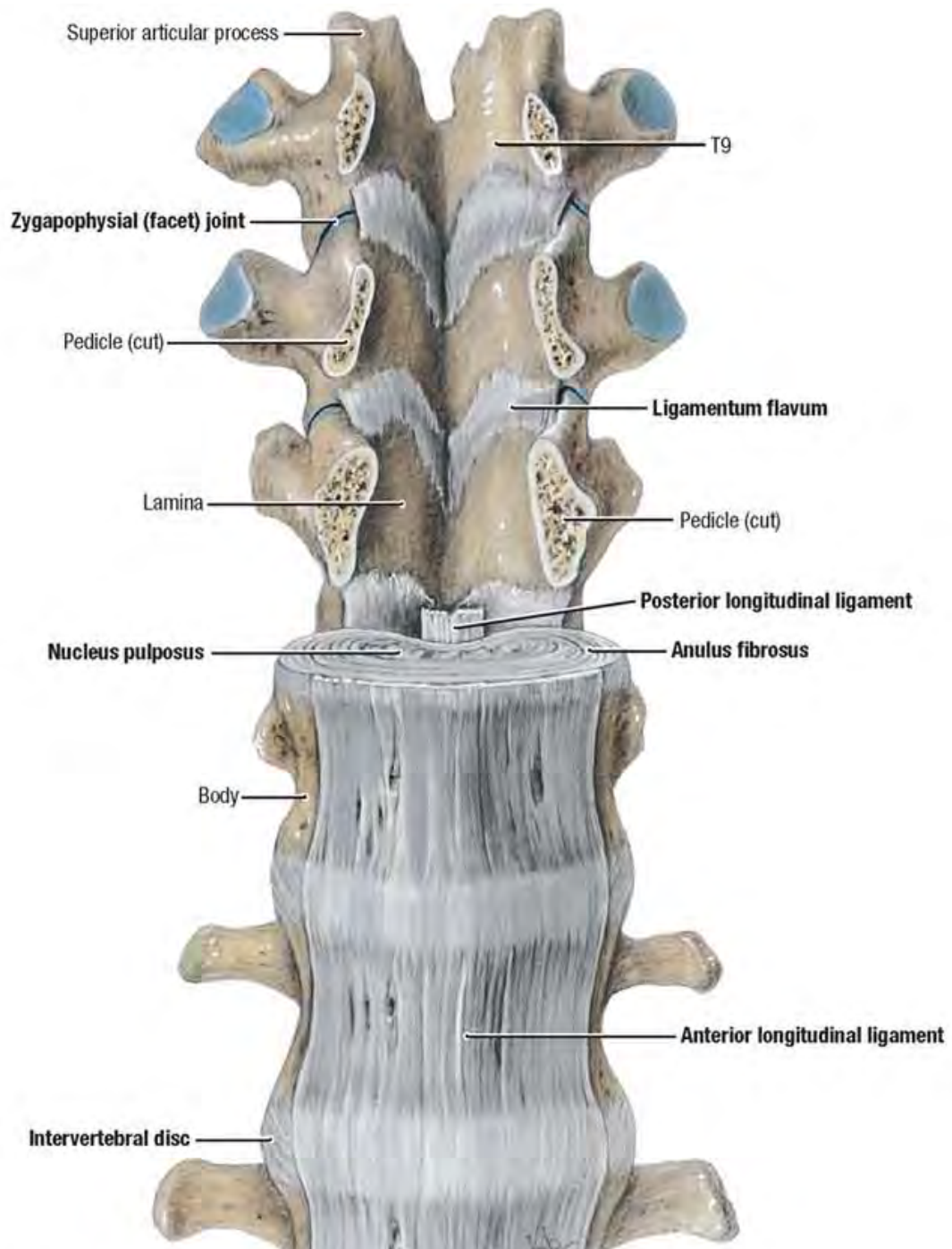
P.307

- The posterior longitudinal ligament is a narrow band passing from disc to disc, spanning the posterior surfaces of the vertebral bodies (in B ). The ligament is diamond shaped posterior to each intervertebral disc, where it exchanges fibers with the anulus fibrosus; the ligament extends to the sacrum inferiorly and

becomes the tectorial membrane cranially.

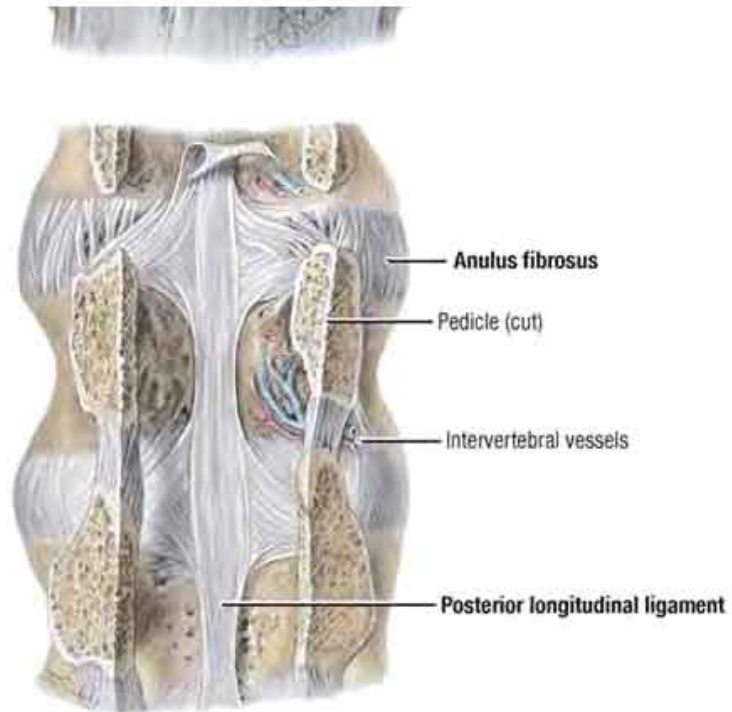
- The movement or loading of the intervertebral disc changes its shape and the position of the nucleus pulposus. Flexion and extension movements cause compression and elongation simultaneously.

P.308

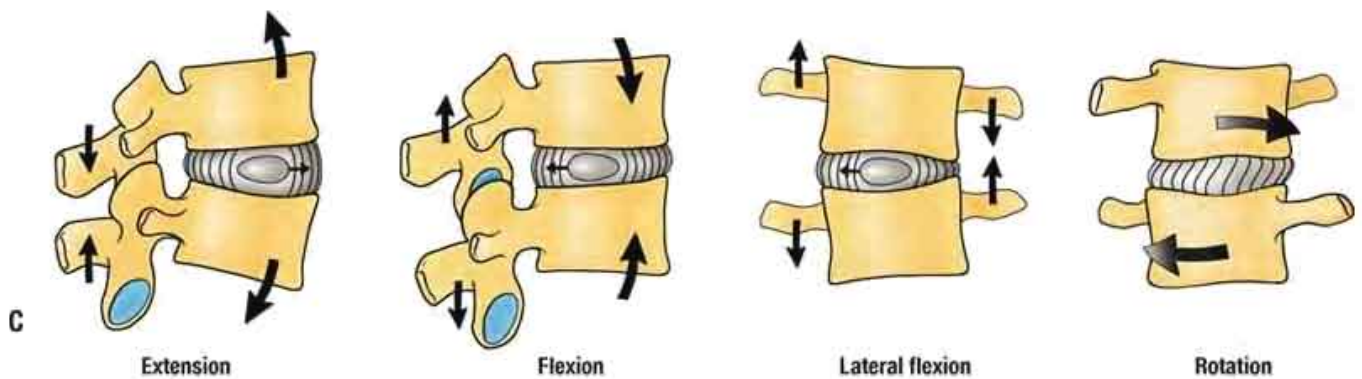
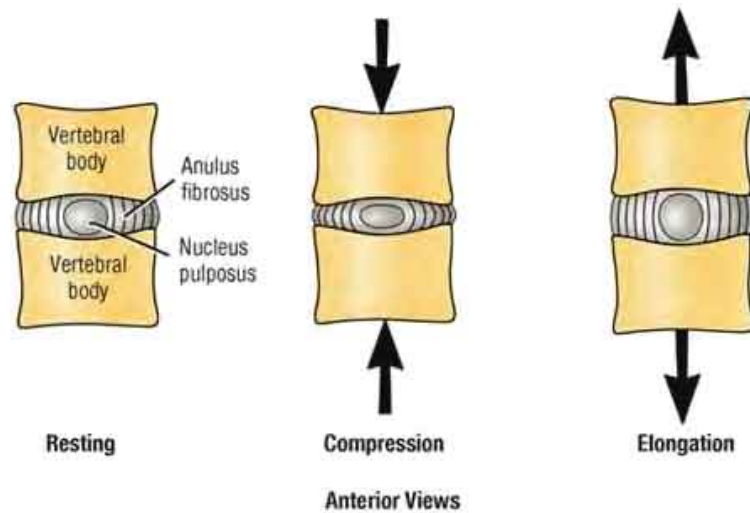




**A. Anterior View**



**B. Posterior View**



**Lateral Views**

**Anterior Views**

Authors: Agur, Anne M.R.; Dalley, Arthur F.

Title: *Grant's Atlas of Anatomy, 12th Edition*

Copyright ©2009 Lippincott Williams & Wilkins

> Table of Contents > Chapter 4 - Back > 4.19 Lumbar region of vertebral column

---

## 4.19 Lumbar region of vertebral column

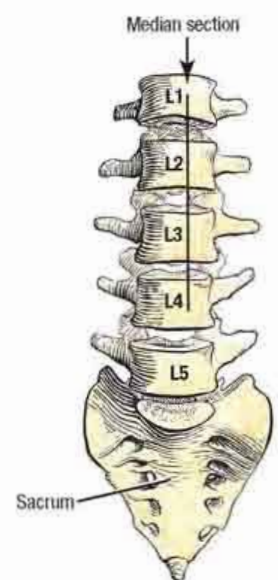
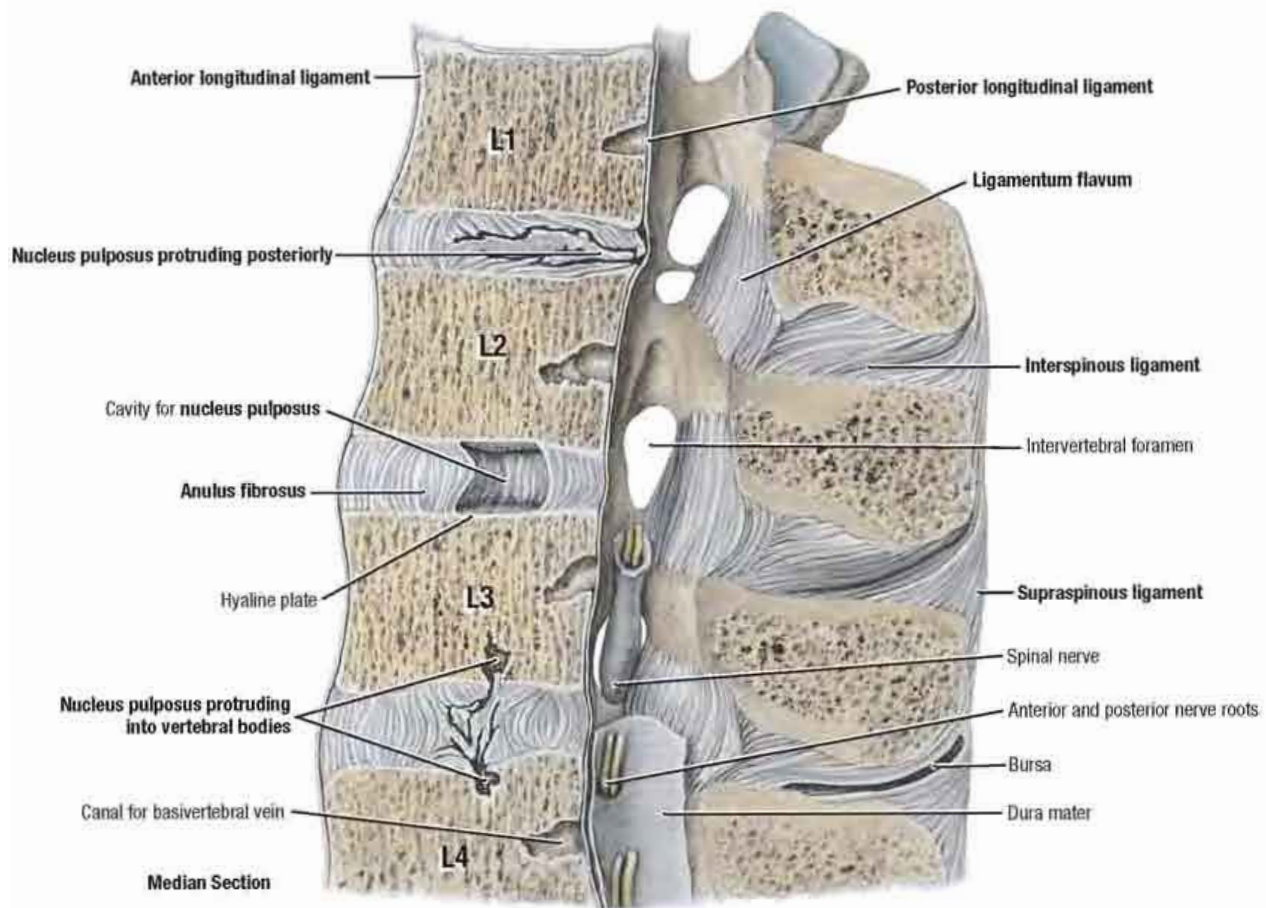
*Part of* "Chapter 4 - Back "

The nucleus pulposus of the normal disc between L2 and L3 has been removed from the enclosing anulus fibrosus.

- The ligamentum flavum extends from the superior border and adjacent part of the posterior aspect of one lamina to the inferior border and adjacent part of the anterior aspect of the lamina above and extends laterally to become continuous with the fibrous capsule of the zygapophysial joint.
- The obliquely placed interspinous ligament unites the superior and inferior borders of two adjacent spines.
- The bursa between L3 and L4 spines is presumably the result of habitual hyperextension, which brings the lumbar spines into contact.

The nucleus pulposus of the disc between L1 and L2 has herniated posteriorly through the anulus. Herniation or protrusion of the gelatinous nucleus pulposus into or through the anulus fibrosus is a well-recognized cause of low back and lower limb pain. If degeneration of the posterior longitudinal ligament and wearing of the anulus fibrosus has occurred, the nucleus pulposus may herniate into the vertebral canal and compress the spinal cord or nerve roots of spinal nerves in the cauda equina. Herniations usually occur posterolaterally, where the anulus is relatively thin and does not receive support from the posterior or anterior longitudinal ligaments.







Authors: Agur, Anne M.R.; Dalley, Arthur F.

Title: *Grant's Atlas of Anatomy, 12th Edition*

Copyright ©2009 Lippincott Williams & Wilkins

> Table of Contents > Chapter 4 - Back > 4.20 Vertebral venous plexuses

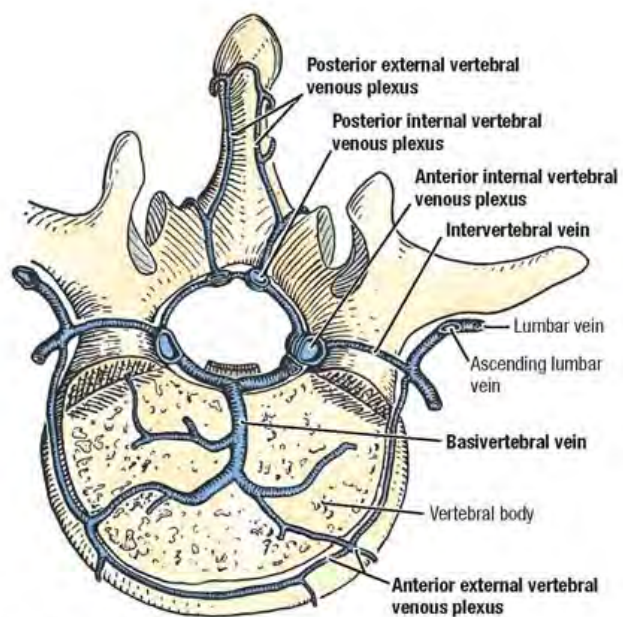
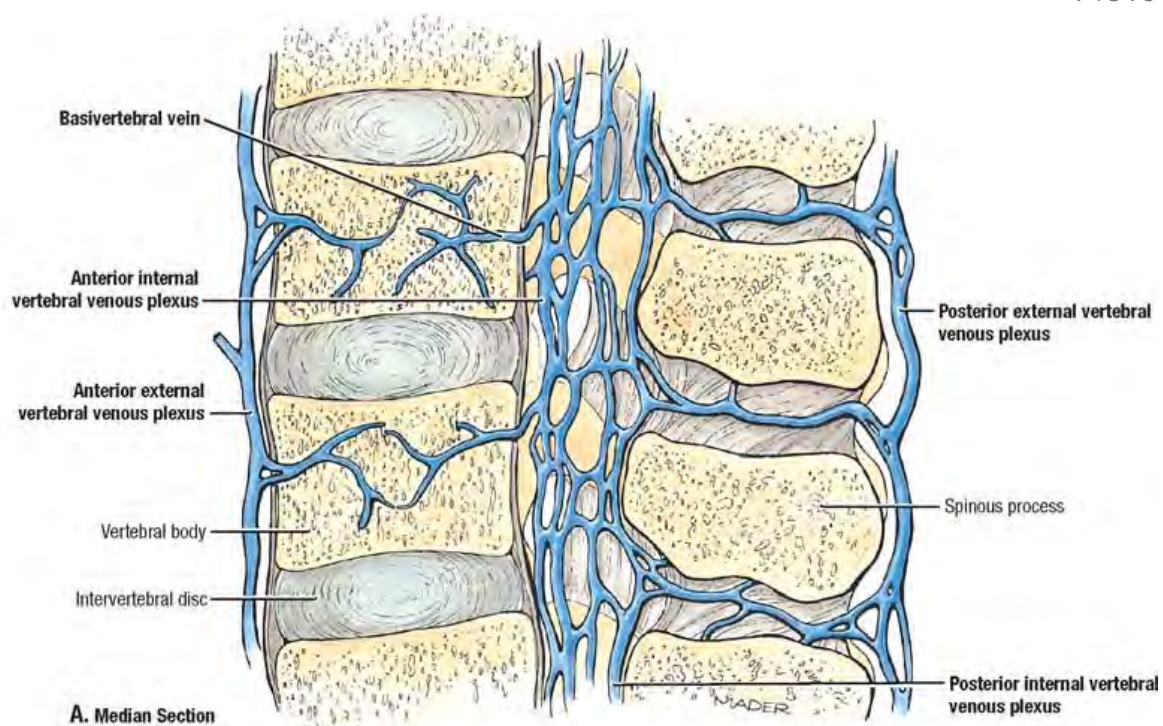
---

## 4.20 Vertebral venous plexuses

*Part of* "Chapter 4 - Back "

A. Median section of lumbar spine. B. Superior view of lumbar vertebra with the vertebral body sectioned transversely.

- There are internal and external vertebral venous plexuses, communicating with each other and with both systemic veins and the portal system. Infection and tumors can spread from the areas drained by the systemic and portal veins to the vertebral venous system and lodge in the vertebrae, spinal cord, brain, or skull.
  - The internal vertebral venous plexus, located in the vertebral canal, consists of a plexus of thin-walled, valveless veins that surround the dura mater. Cranially, the internal venous plexus communicates through the foramen magnum with the occipital and basilar sinuses; at each spinal segment, the plexus receives veins from the spinal cord and a basivertebral vein from the vertebral body. The plexus is drained by intervertebral veins that pass through the intervertebral and sacral foramina to the vertebral, intercostal, lumbar, and lateral sacral veins.
  - The anterior external vertebral venous plexus is formed by veins that course through the body of each vertebra. Veins that pass through the ligamenta flava form the posterior external vertebral venous plexus. In the cervical region, these plexuses communicate with the occipital and deep cervical veins. In the thoracic, lumbar, and pelvic regions, the azygos (or hemiazygos), ascending lumbar, and lateral sacral veins, respectively, further link segment to segment.
-



**B. Superior View**

Authors: Agur, Anne M.R.; Dalley, Arthur F.

Title: *Grant's Atlas of Anatomy, 12th Edition*

Copyright ©2009 Lippincott Williams & Wilkins

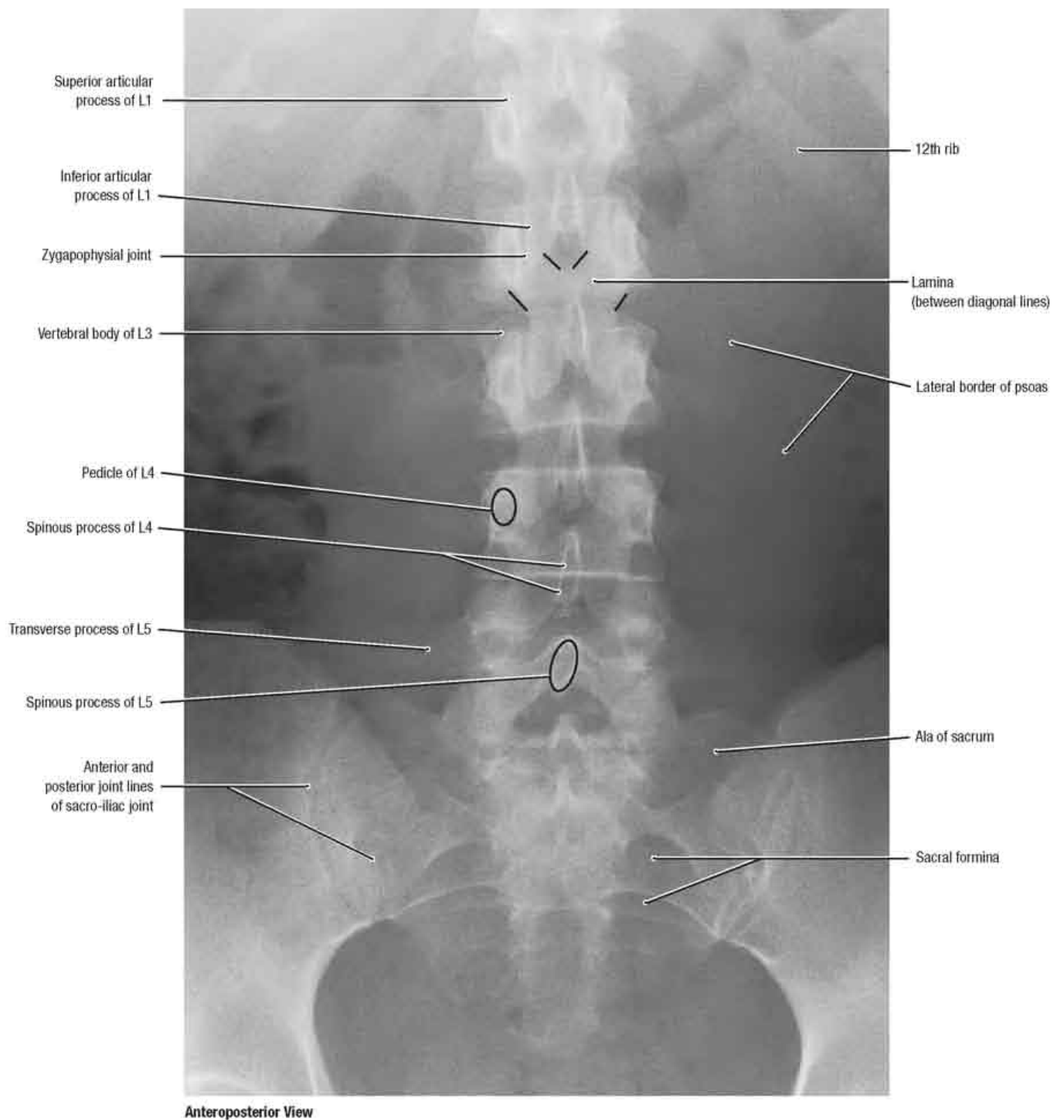
> Table of Contents > Chapter 4 - Back > 4.21 Radiograph of inferior thoracic and lumbosacral spine

---

## 4.21 Radiograph of inferior thoracic and lumbosacral spine

*Part of* "Chapter 4 - Back "

Note the bodies and processes of the five lumbar vertebrae, the labeled spinous and transverse processes of L5, the sinuous sacro-iliac joint, the lateral margin of the right and left psoas muscles, and the 12th rib.



**Anteroposterior View**

Authors: Agur, Anne M.R.; Dalley, Arthur F.

Title: *Grant's Atlas of Anatomy, 12th Edition*

Copyright ©2009 Lippincott Williams & Wilkins

> Table of Contents > Chapter 4 - Back > 4.22 Pelvis

---

## 4.22 Pelvis

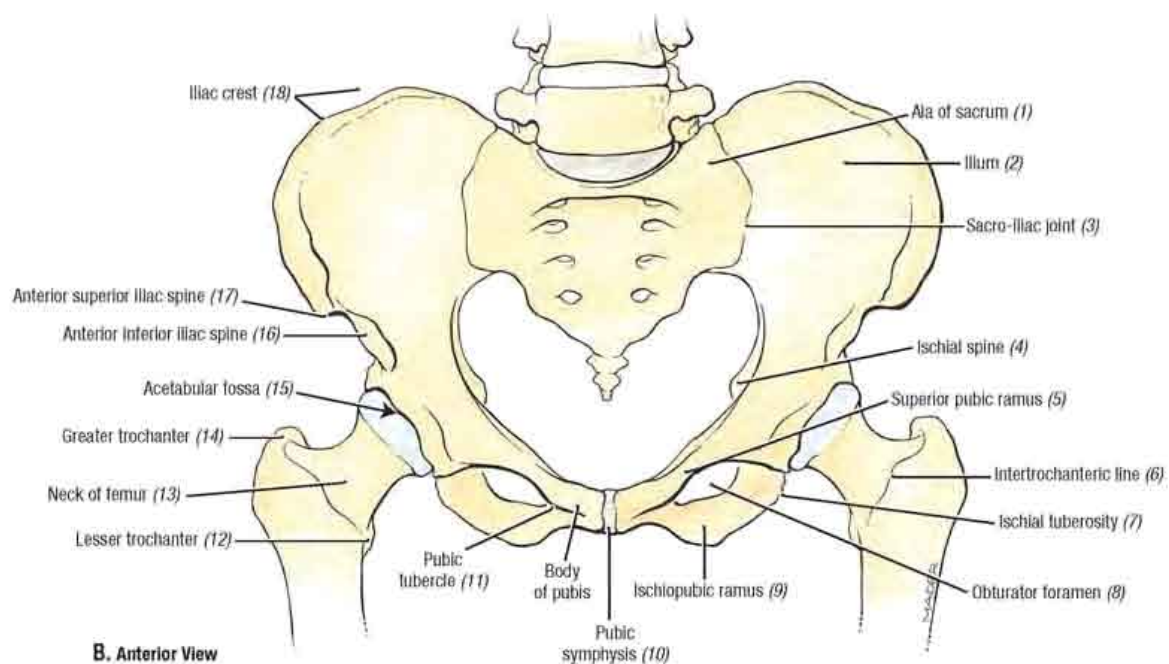
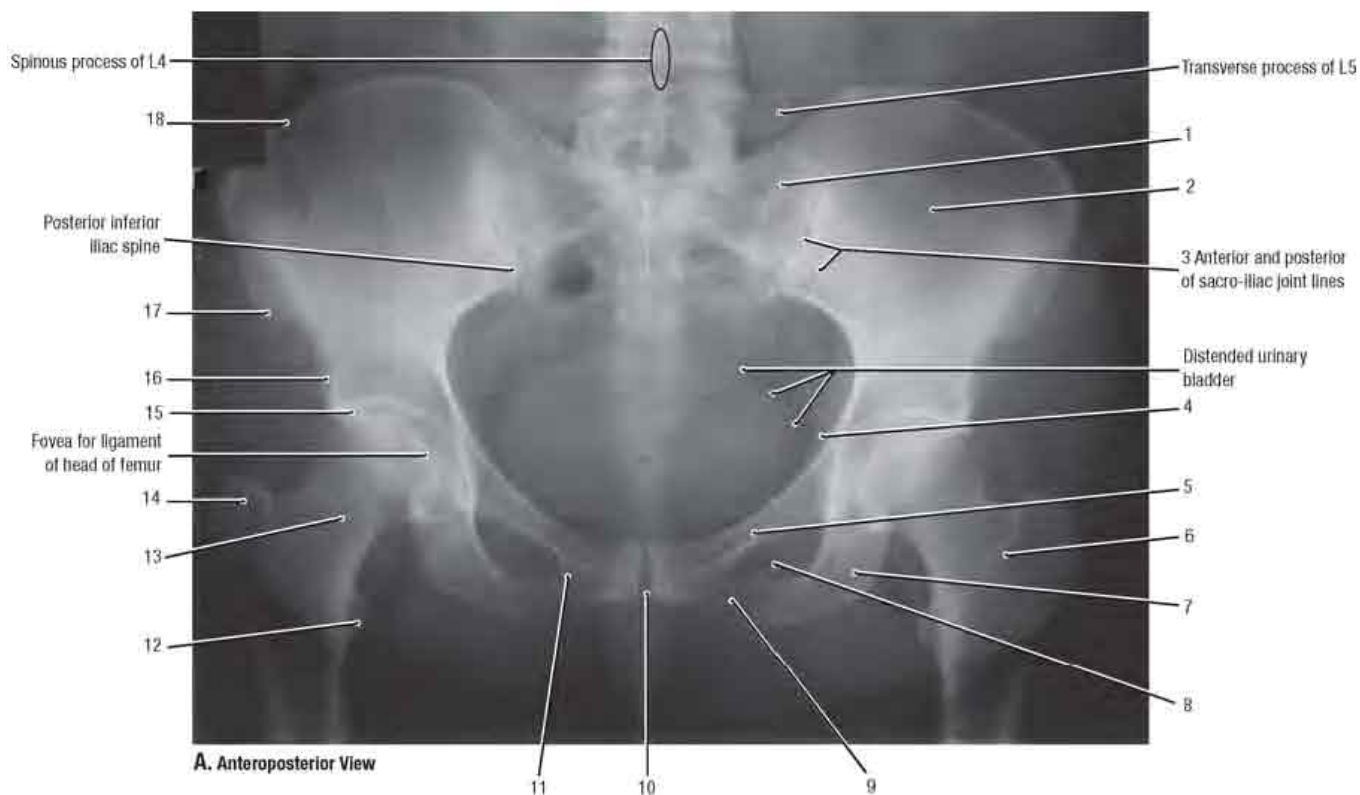
*Part of* "Chapter 4 - Back "

A. Radiograph of pelvis. B. Bony pelvis with articulated femora.

---

P.312





Authors: Agur, Anne M.R.; Dalley, Arthur F.

Title: *Grant's Atlas of Anatomy, 12th Edition*

Copyright ©2009 Lippincott Williams & Wilkins

> Table of Contents > Chapter 4 - Back > 4.23 Hip bone, sacrum, and coccyx

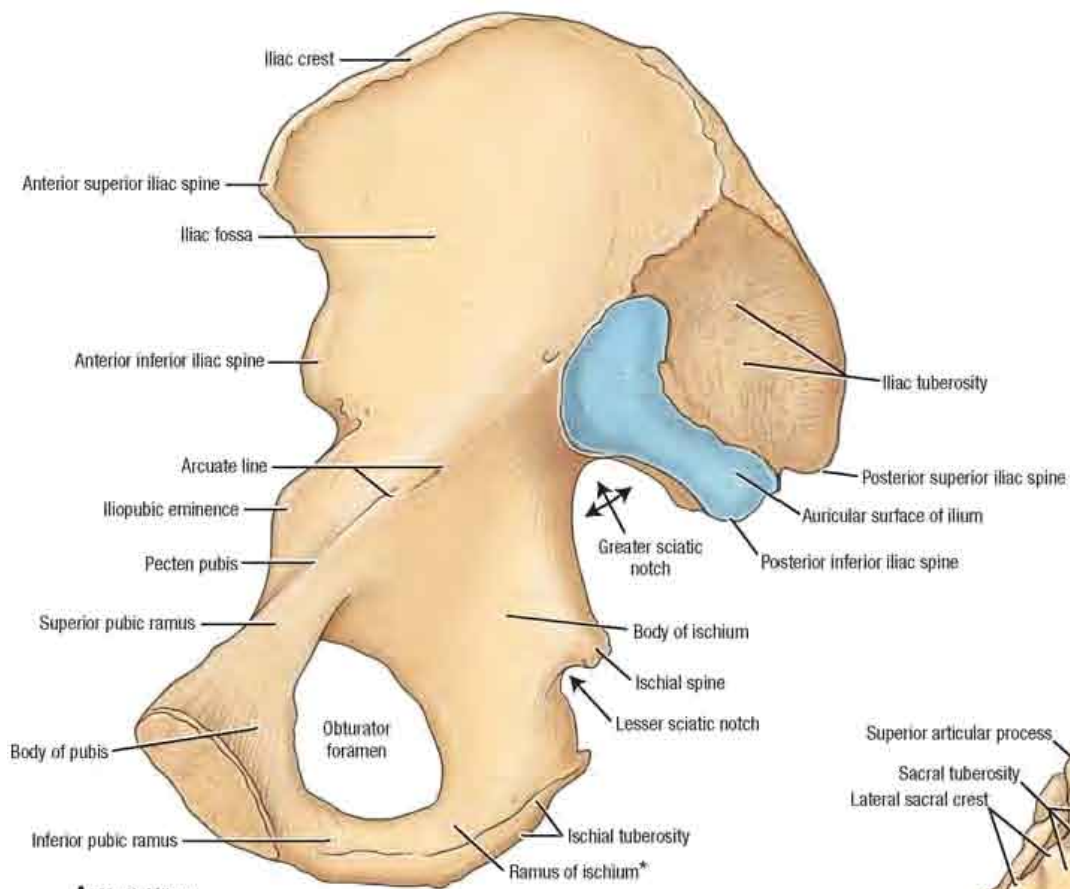
---

## 4.23 Hip bone, sacrum, and coccyx

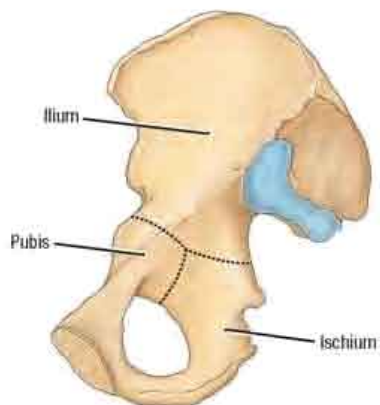
*Part of* "Chapter 4 - Back "

A. Features of hip bone. B. Ilium, ischium, and pubis. C. Sacrum and coccyx.

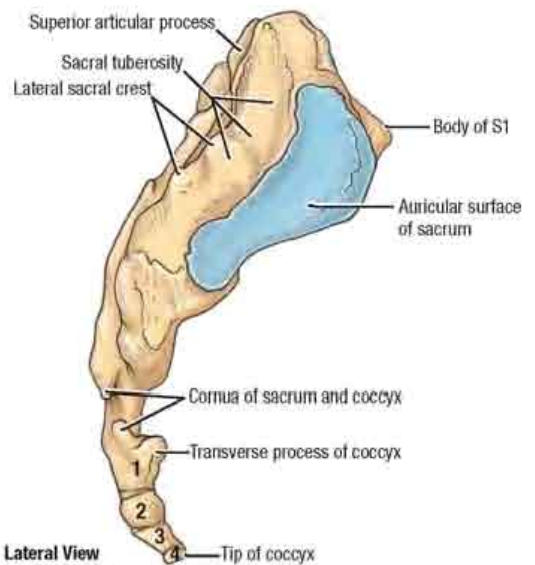
- Each hip bone consists of three bones: ilium, ischium, and pubis. The ilium is the superior, larger part of the hip bone, forming the superior part of the acetabulum, the deep socket on the lateral aspect of the hip bone that articulates with the head of the femur. The ischium forms the posteroinferior part of the acetabulum and hip bone. The pubis forms the anterior part of the acetabulum and anteromedial part of the hip bone.
- Anterosuperiorly, the auricular, ear-shaped surface of the sacrum articulates with the auricular surface of the ilium; the sacral and iliac tuberosities are for the attachment of the posterior sacro-iliac and interosseous sacro-iliac ligaments.



**A. Medial View**



**B. Medial View**



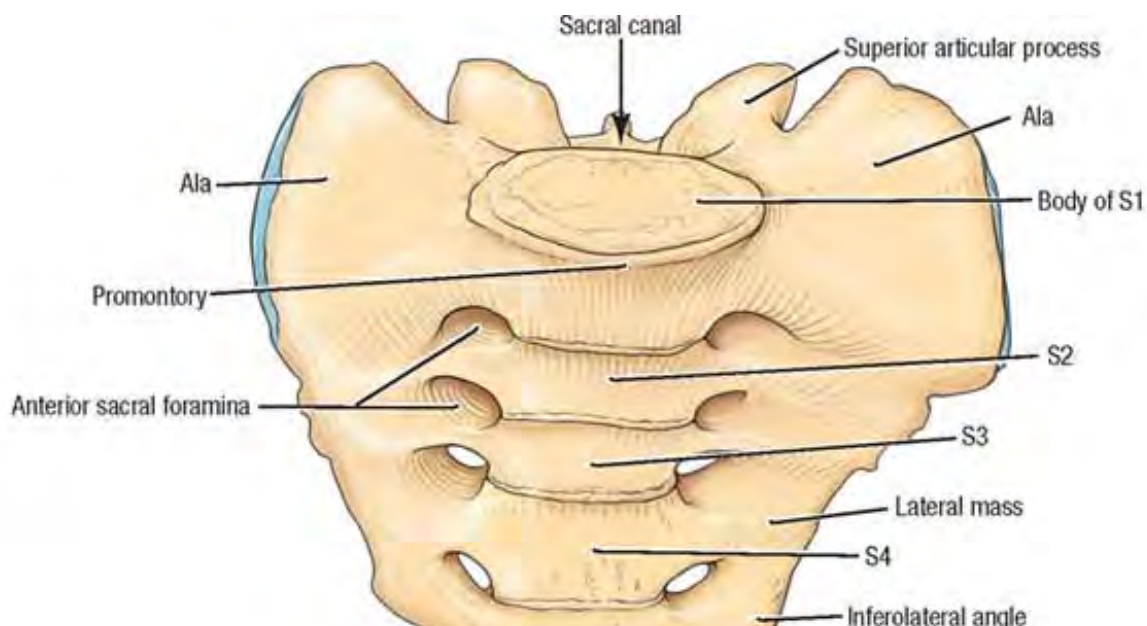
**C. Lateral View**

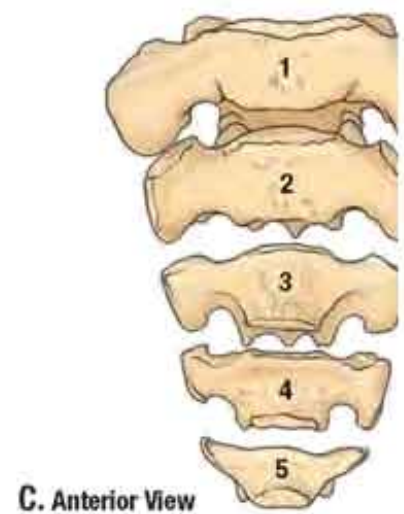
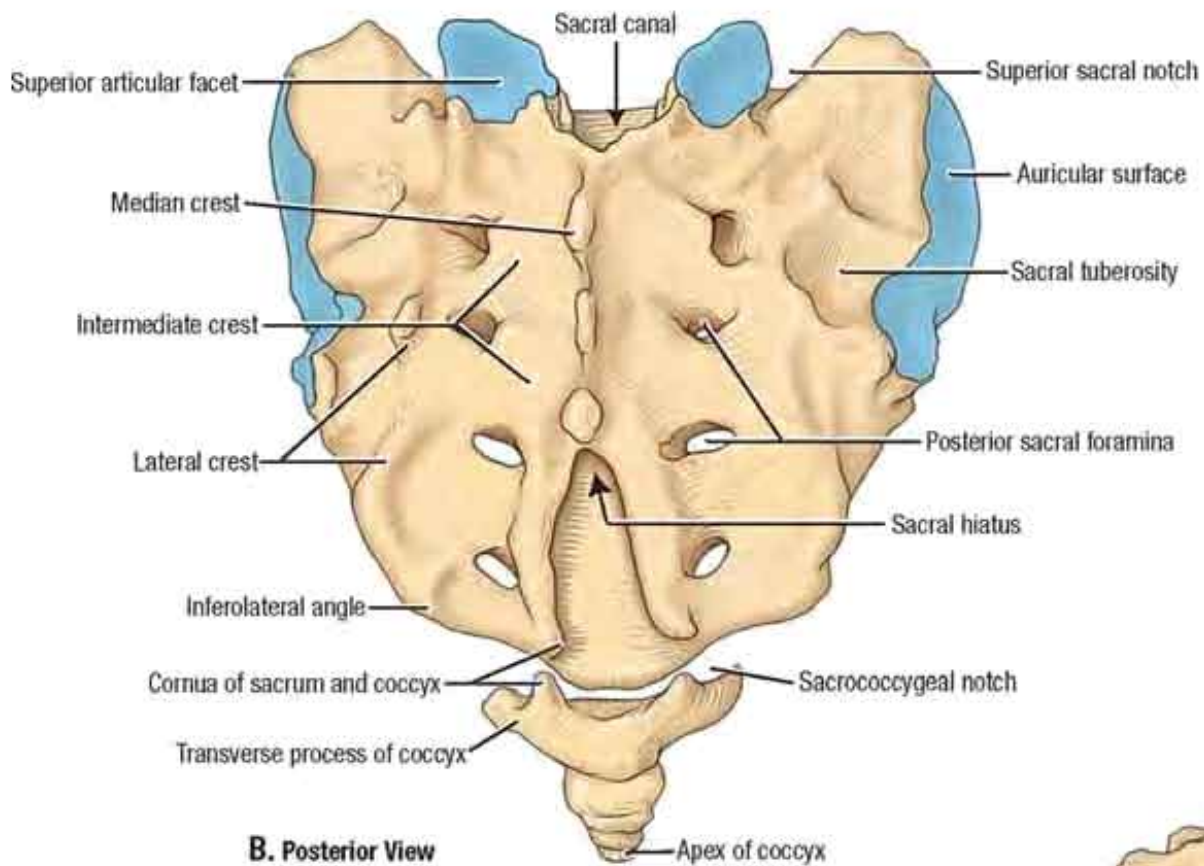
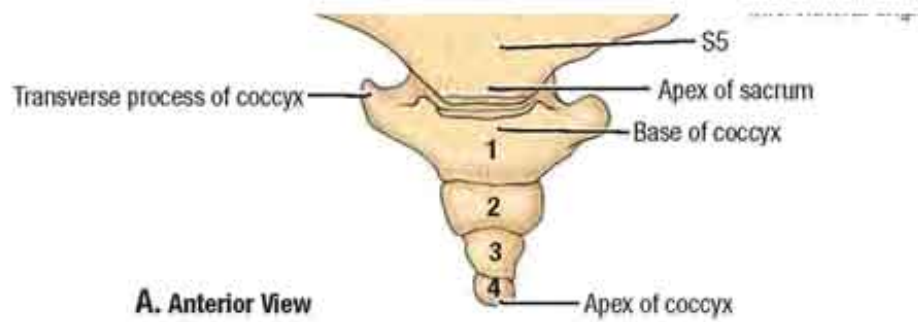
## 4.24 Sacrum and coccyx

Part of "Chapter 4 - Back "

A. Pelvic (anterior) surface. B. Dorsal (posterior surface). C. Sacrum in youth.

- In A the five sacral bodies are demarcated in the mature sacrum by four transverse lines ending laterally in four pairs of anterior sacral foramina. The coccyx has four pieces—the first having a pair of transverse processes and a pair of cornua (horns).
- The costal (lateral) elements begin to fuse around puberty. The bodies begin to fuse from inferior to superior at about the 17th to 18th year, with fusion usually complete by the 23rd year.









Authors: Agur, Anne M.R.; Dalley, Arthur F.

Title: *Grant's Atlas of Anatomy, 12th Edition*

Copyright ©2009 Lippincott Williams & Wilkins

> Table of Contents > Chapter 4 - Back > 4.25 Lumbar and pelvic ligaments

---

## 4.25 Lumbar and pelvic ligaments

*Part of* "Chapter 4 - Back "

- The anterior sacro-iliac ligament is part of the fibrous capsule anteriorly and spans between the lateral aspect of the sacrum and the ilium, anterior to the auricular surfaces.

During pregnancy, the pelvic joint and ligaments relax, and pelvic movements increase. The sacro-iliac interlocking mechanism is less effective because the relaxation permits greater rotation of the pelvis and contributes to the lordotic posture often assumed during pregnancy with the change in the center of gravity. Relaxation of the sacro-iliac joints and pubic symphysis permits as much as 10–15% increase in diameters (mostly transverse), facilitating passage of the fetus through the pelvic canal. The coccyx is also allowed to move posteriorly.

---

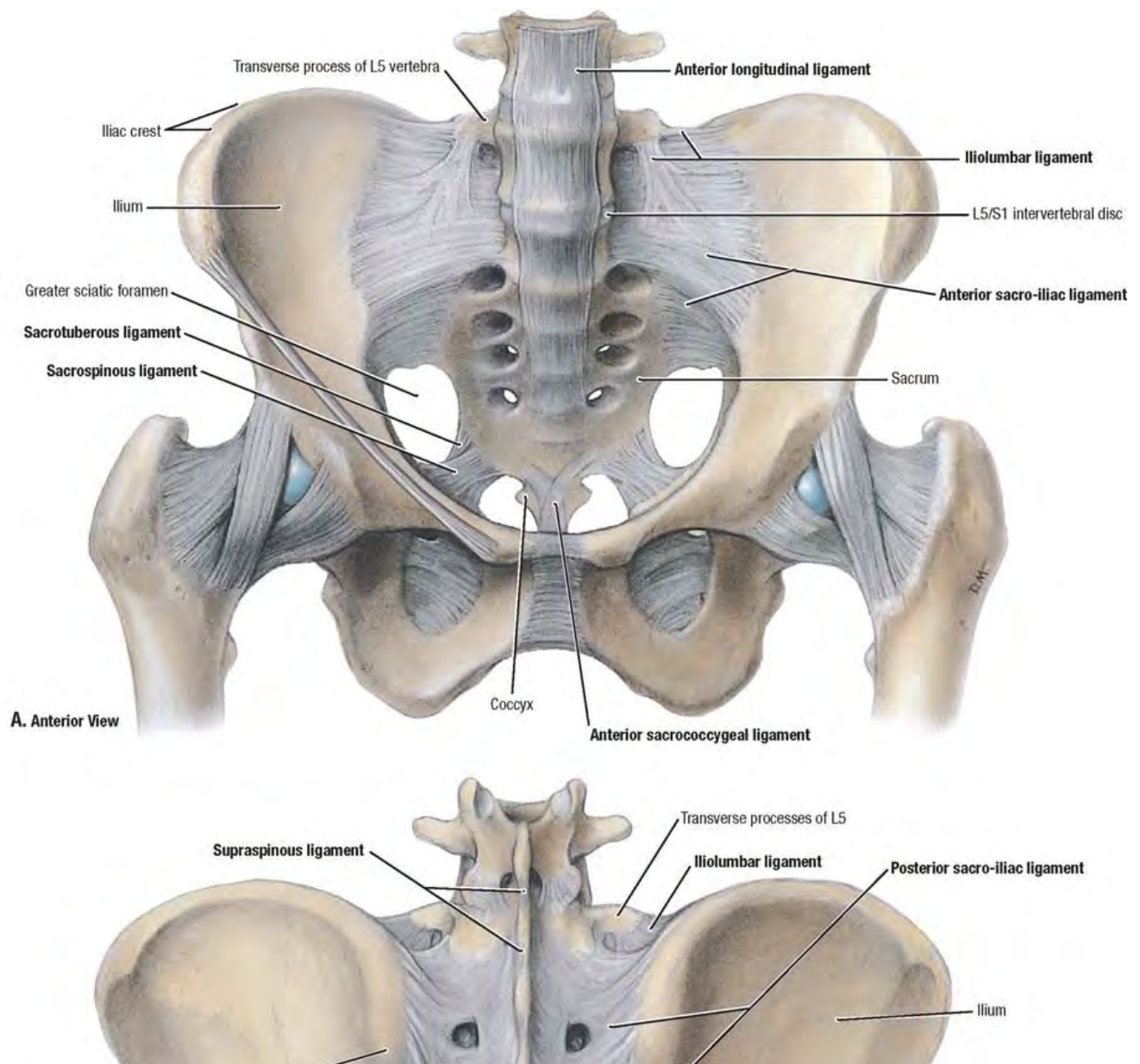
P.315

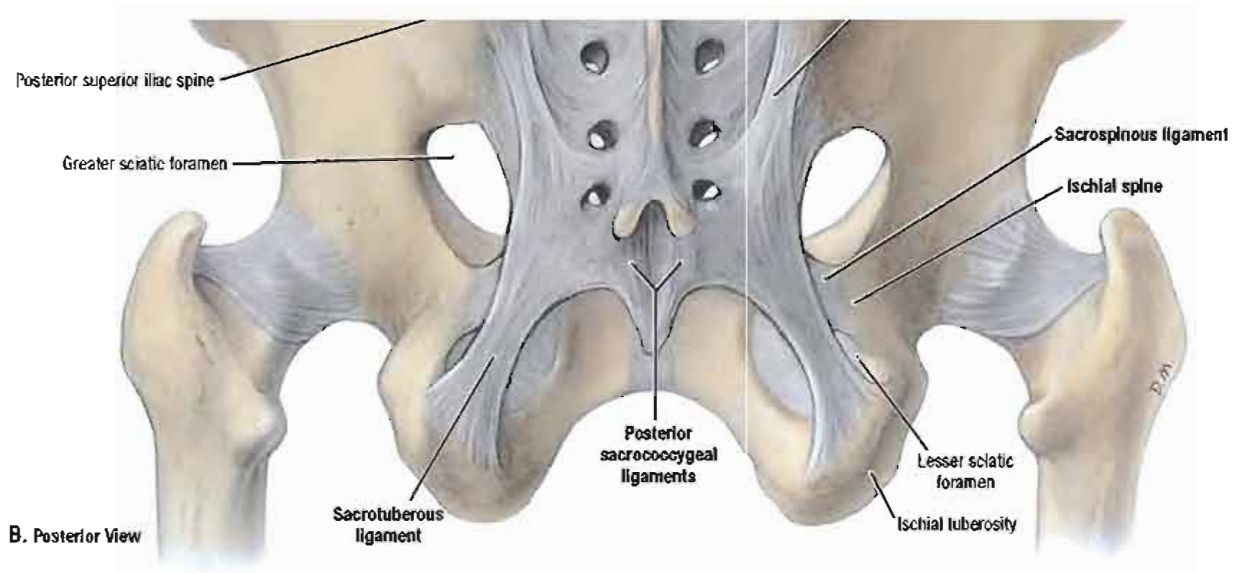
- The sacrotuberous ligaments attach the sacrum, ilium, and coccyx to the ischial tuberosity; the sacrospinous ligaments unite the sacrum and coccyx to the ischial spine. The sacrotuberous and sacrospinous ligaments convert the sciatic notches of the hip bones into greater and lesser sciatic foramina.
- The fibers of the posterior sacro-iliac ligament vary in obliquity; the superior fibers are shorter and lie between the ilium and superior part of the sacrum; the longer, obliquely oriented inferior fibers span between the posterior superior iliac

spine and the inferior part of the sacrum, also blending with the sacrotuberous ligament.

- The interosseous sacro-iliac ligament lies deep to the posterior sacro-iliac ligament (see Fig. 4.26 ).
- The iliolumbar ligaments unite the ilia and transverse processes of L5; the lumbosacral portions of the ligaments descend to the alae of the sacrum and blend with the anterior sacro-iliac ligaments.

P.316





Authors: Agur, Anne M.R.; Dalley, Arthur F.

Title: *Grant's Atlas of Anatomy, 12th Edition*

Copyright ©2009 Lippincott Williams & Wilkins

> Table of Contents > Chapter 4 - Back > 4.26 Articular surfaces of sacro-iliac joint and ligaments

---

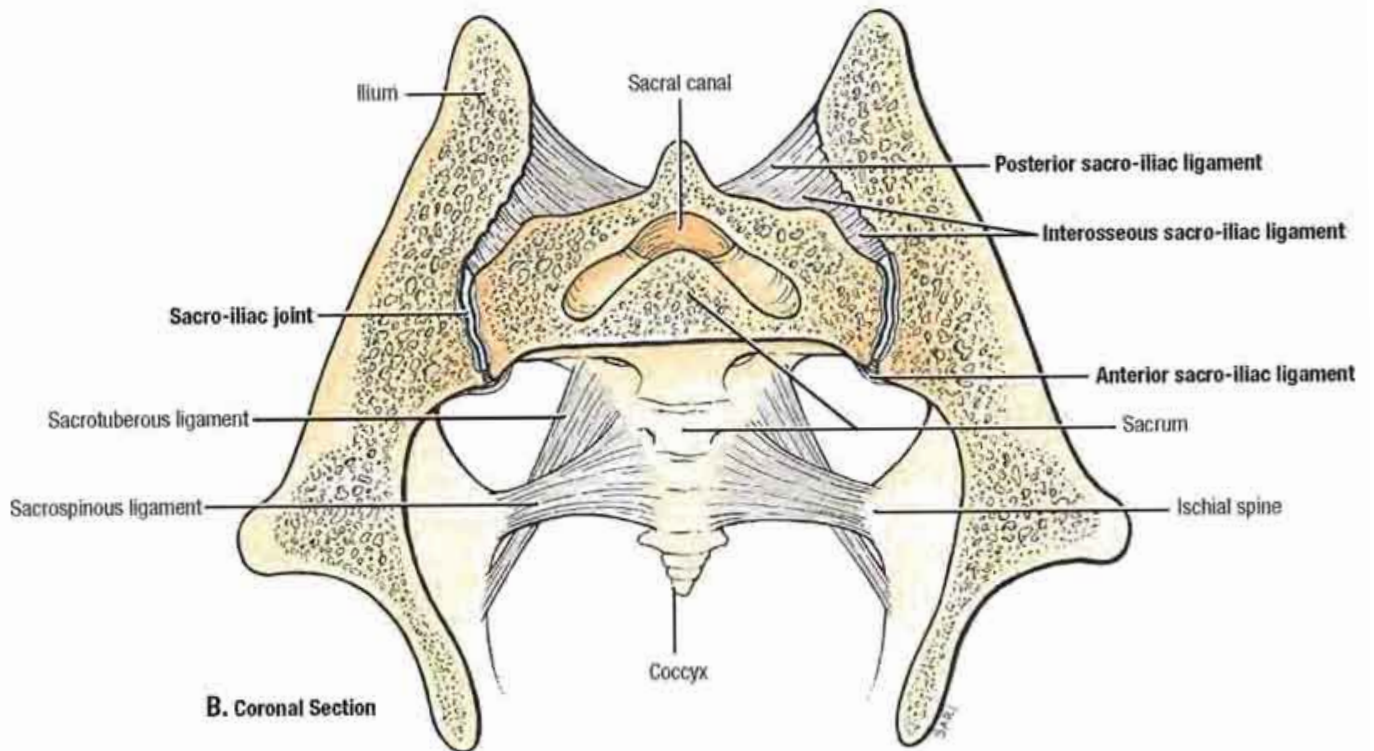
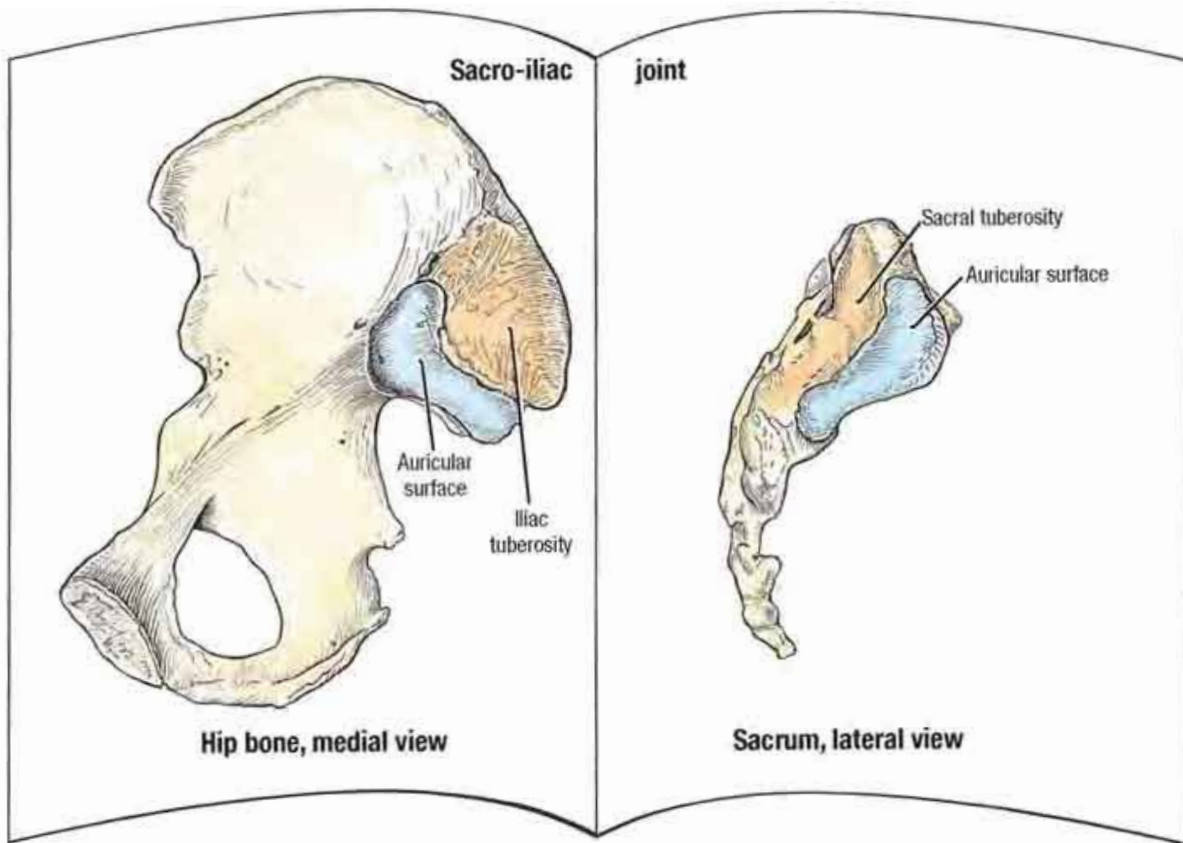
## 4.26 Articular surfaces of sacro-iliac joint and ligaments

*Part of* "Chapter 4 - Back "

A. Articular surfaces. Note the auricular surface (articular area, *blue*) of the sacrum and hip bone and the roughened areas superior and posterior to the auricular areas (*orange*) for the attachment of the interosseous sacro-iliac ligament. B. Sacro-iliac ligaments. Note the sacro-iliac joints and the strong interosseous sacro-iliac ligament that lies inferior and anterior to the posterior sacro-iliac ligament. The interosseous sacro-iliac ligament consists of short fibers connecting the sacral tuberosity to the iliac tuberosity. The sacrum is suspended from the ilia by the sacro-iliac ligaments.



A



Authors: Agur, Anne M.R.; Dalley, Arthur F.

Title: *Grant's Atlas of Anatomy, 12th Edition*

Copyright ©2009 Lippincott Williams & Wilkins

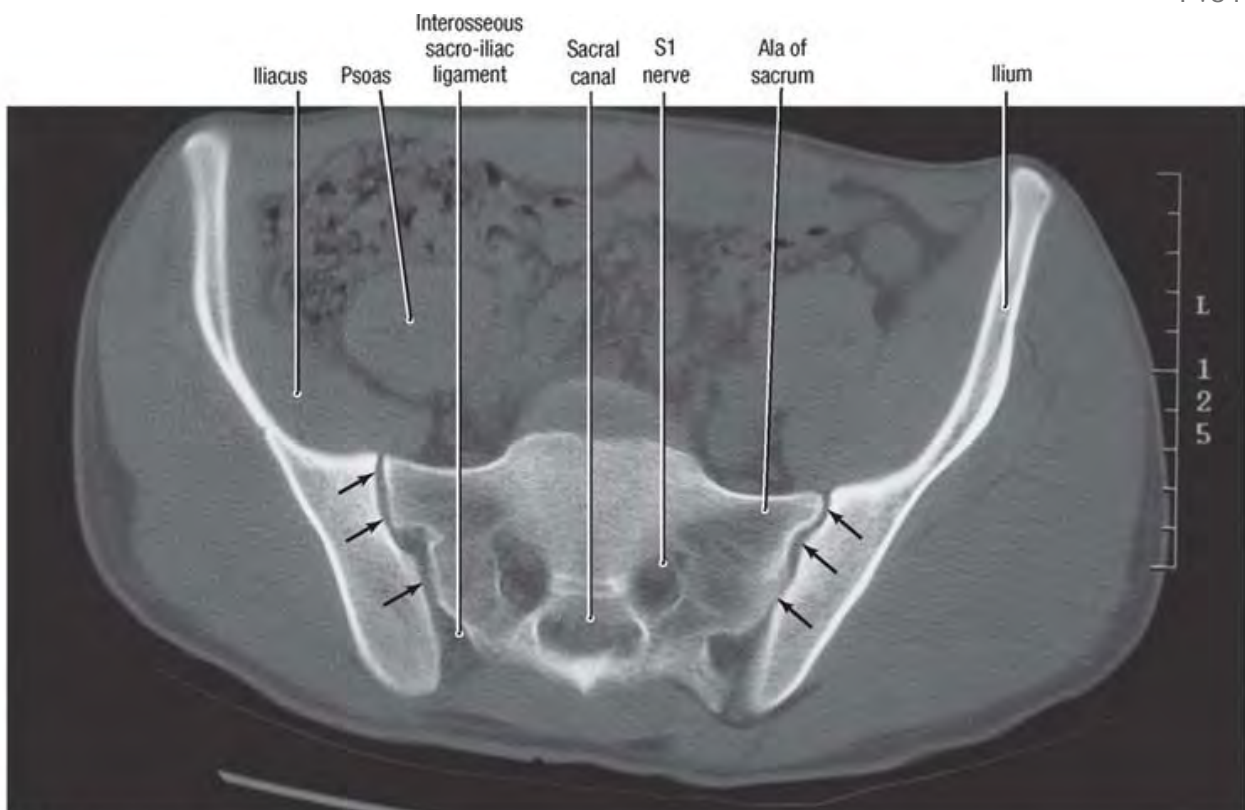
> Table of Contents > Chapter 4 - Back > 4.27 Imaging of the sacro-iliac joint

## 4.27 Imaging of the sacro-iliac joint

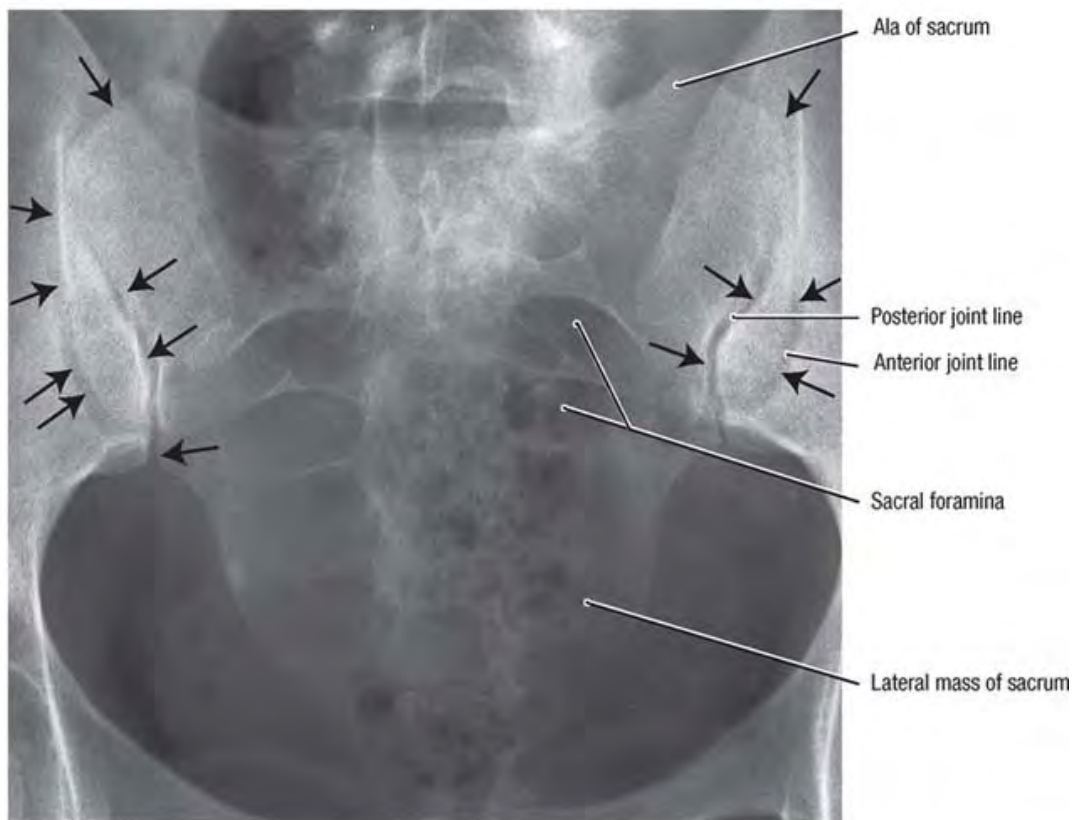
Part of "Chapter 4 - Back "

A. CT scan. The sacro-iliac joint is indicated by *arrows*. Note that the articular surfaces of the ilium and sacrum have irregular shapes that result in partial interlocking of the bones. The sacro-iliac joint is oblique, with the anterior aspect of the joint situated lateral to the posterior aspect of the joint. B. Radiograph. Due to the oblique placement of the sacro-iliac joints, the anterior and posterior joint lines appear separately.

P.318

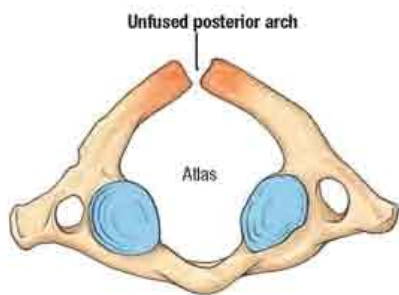


A. Transverse (axial) CT Scan

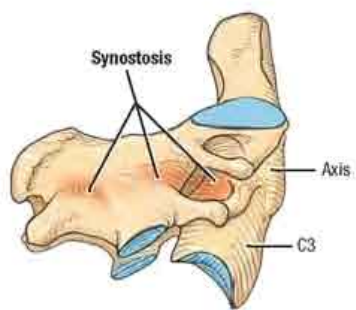


B. Anteroposterior View

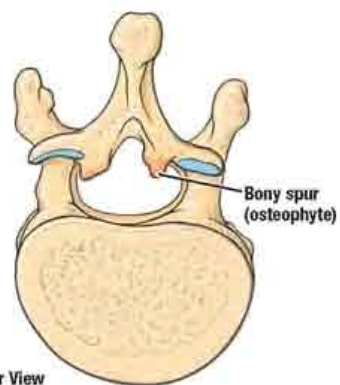
A. Unfused posterior arch of the atlas. The centrum fused to the right and left halves of the neural arch, but the arch did not fuse in the midline posteriorly. B. Synostosis (fusion) of vertebrae C2 (axis) and C3. C. Bony spurs. Sharp bony spurs may grow from the laminae inferiorly into the ligamenta flava, thereby reducing the lengths of the functional portions of these ligaments. When the vertebral column is flexed, the ligaments may be torn. D. Hemivertebra. The entire right half of T3 and the corresponding rib are absent. The left lamina and the spine are fused with those of T4, and the left intervertebral foramen is reduced in size. Observe the associated scoliosis (lateral curvature of the spine). E. Transitional lumbosacral vertebra. Here, the 1st sacral vertebra is partly free (lumbarized). Not uncommonly, the 5th lumbar vertebra may be partly fused to the sacrum (sacralized).



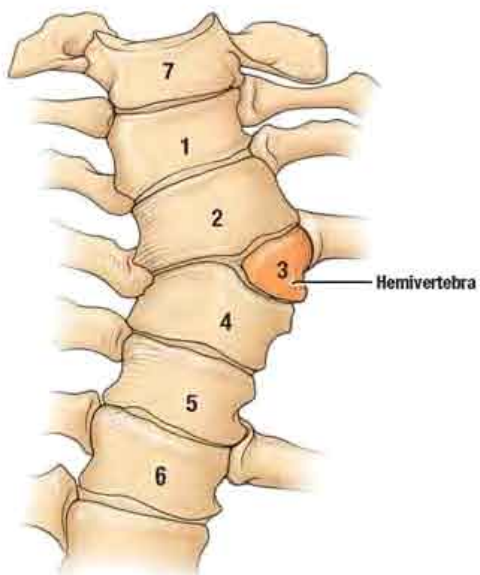
A. Inferior View



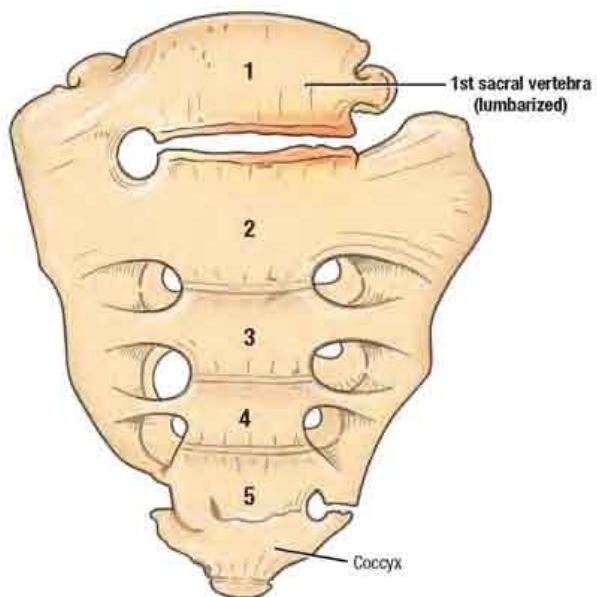
B. Lateral View



C. Superior View



D. Anterior View



E. Anterior View

Authors: Agur, Anne M.R.; Dalley, Arthur F.

Title: *Grant's Atlas of Anatomy, 12th Edition*

Copyright ©2009 Lippincott Williams & Wilkins

> Table of Contents > Chapter 4 - Back > 4.29 Spondylolysis and spondylolisthesis

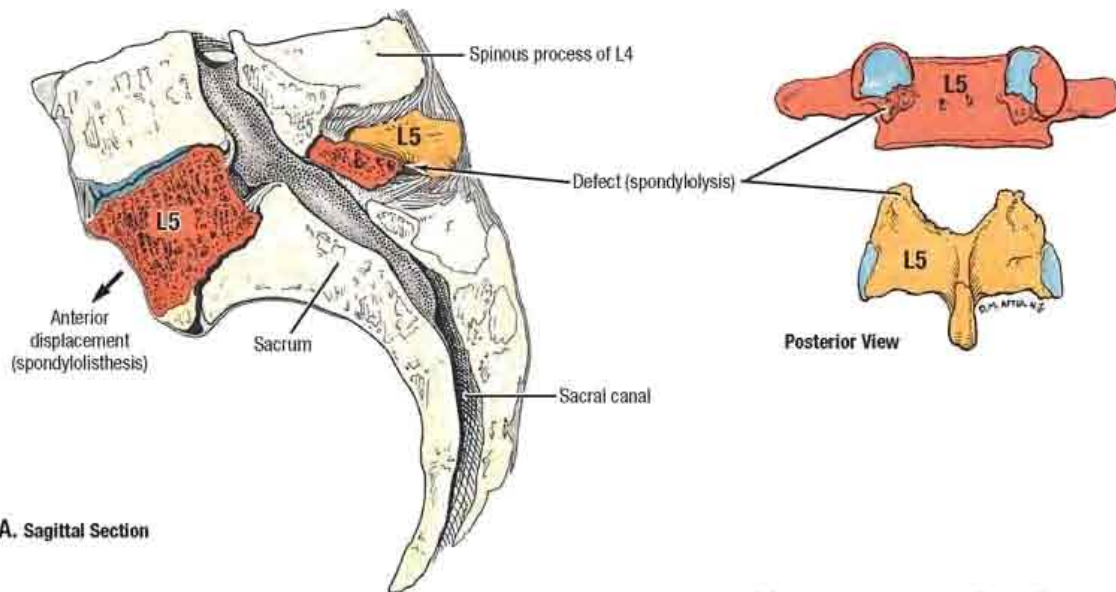
---

## 4.29 Spondylolysis and spondylolisthesis

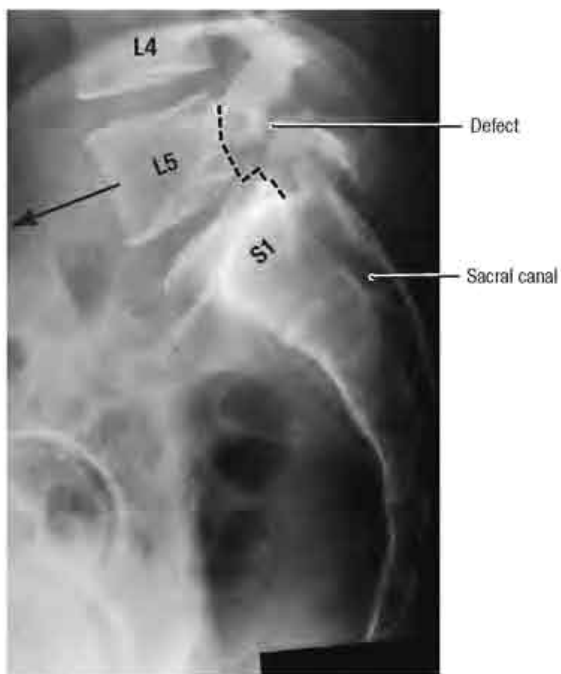
*Part of "Chapter 4 - Back "*

A. Articulated and isolated spondylolytic L5 vertebra. The vertebra has an oblique defect (spondylolysis) through the interarticular part (pars interarticularis). The defect may be traumatic or congenital in origin. The interarticular part is the region of the lamina of a lumbar vertebra between the superior and inferior articular processes. Also, the vertebral body of L5 has slipped anteriorly (spondylolisthesis). B and C. Radiographs. In B, the *dotted line* following the posterior vertebral margins of L5 and the sacrum shows the anterior displacement of L5 (*arrow*). In C, note the superimposed outline of a dog: the head is the transverse process, the eye is the pedicle, and the ear is the superior articular process. The lucent (dark) cleft across the "neck" of the dog is the spondylolysis; the anterior displacement (*arrow*) is the spondylolisthesis.

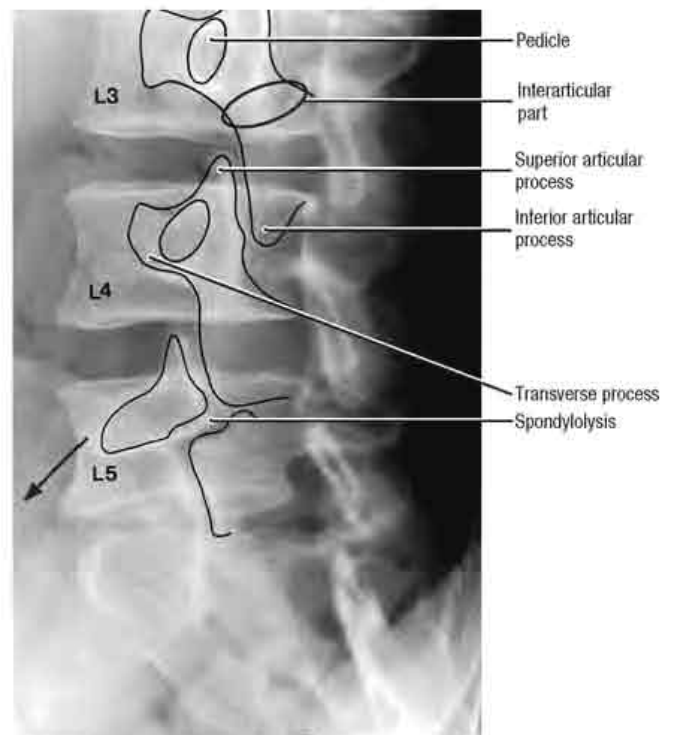




**A. Sagittal Section**



**B. Lateral View**



**C. Oblique View**

Authors: Agur, Anne M.R.; Dalley, Arthur F.

Title: *Grant's Atlas of Anatomy, 12th Edition*

Copyright ©2009 Lippincott Williams & Wilkins

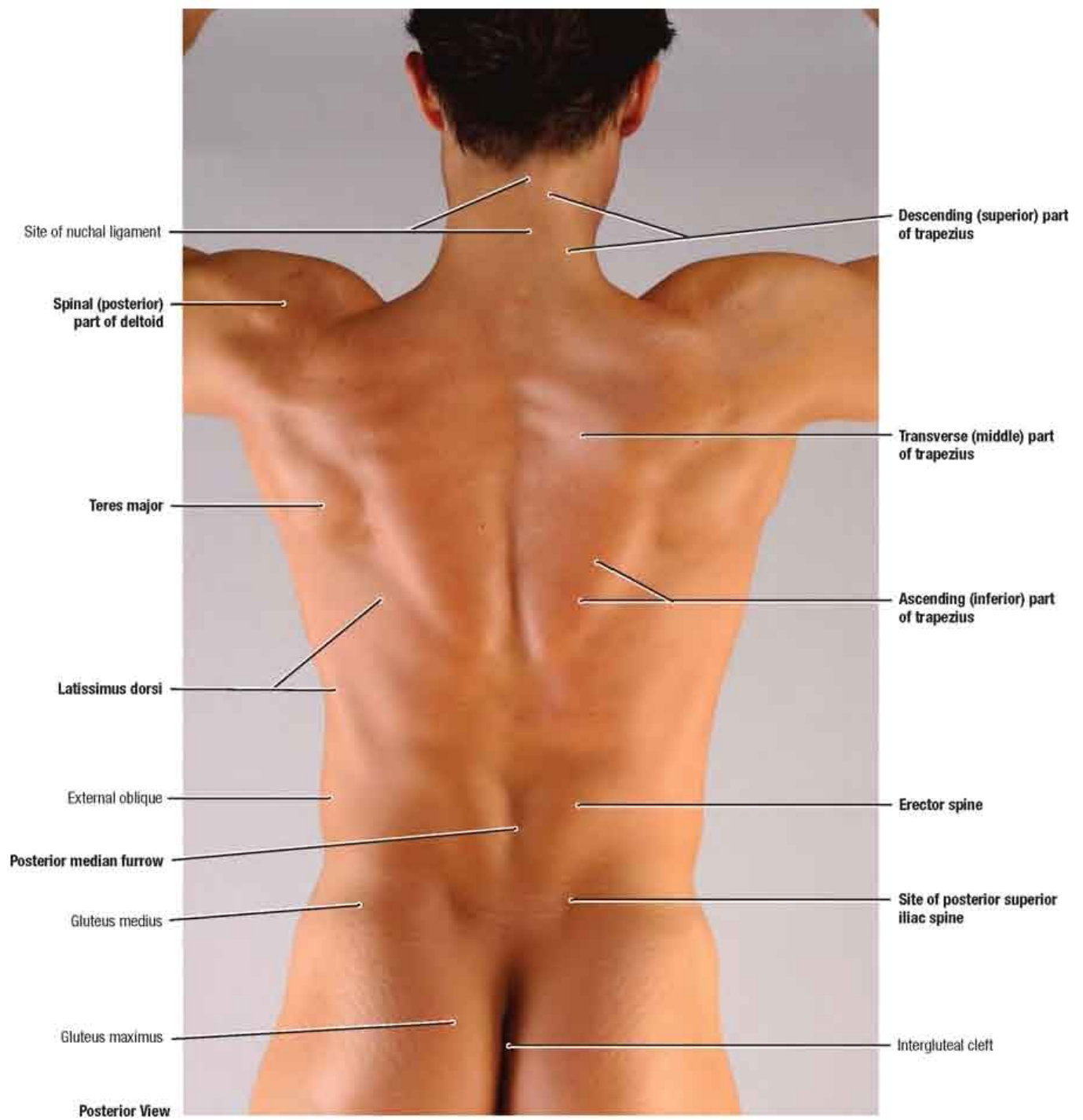
> Table of Contents > Chapter 4 - Back > 4.30 Surface anatomy of back

---

## 4.30 Surface anatomy of back

*Part of* "Chapter 4 - Back "

- The arms are abducted, so the scapulae have rotated superiorly on the thoracic wall.
- The latissimus dorsi and teres major muscles form the posterior axillary fold.
- The trapezius muscle has three parts: descending, transverse, and ascending.
- Note the deep median furrow that separates the longitudinal bulges formed by the contracted erector spinae group of muscles;
- Dimples (depressions) indicate the site of the posterior superior iliac spines, which usually lie at the level of the sacro-iliac joint.



Authors: Agur, Anne M.R.; Dalley, Arthur F.

Title: *Grant's Atlas of Anatomy, 12th Edition*

Copyright ©2009 Lippincott Williams & Wilkins

> Table of Contents > Chapter 4 - Back > 4.31 Superficial muscles of back

---

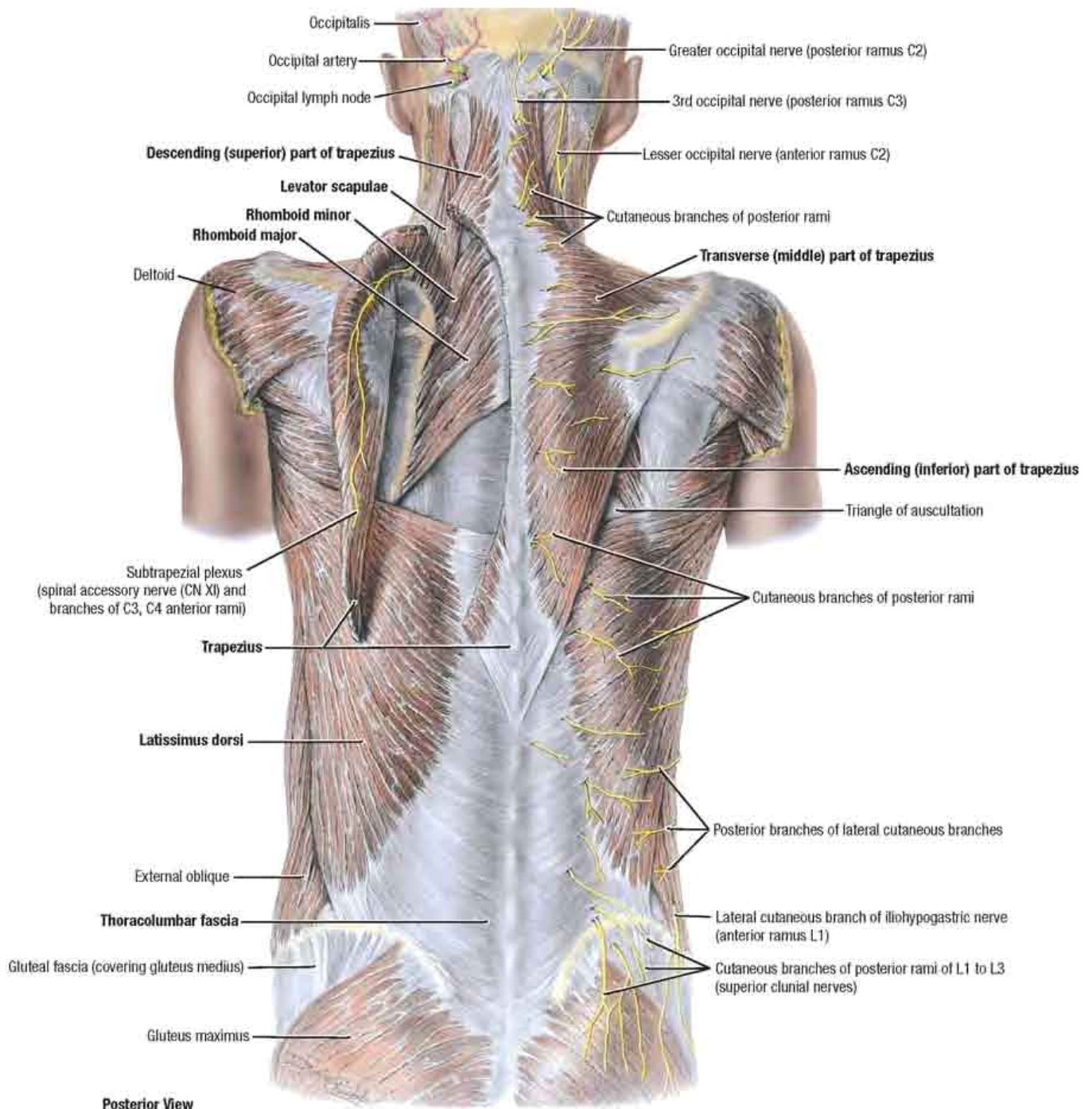
## 4.31 Superficial muscles of back

*Part of* "Chapter 4 - Back "

On the *left*, the trapezius muscle is reflected. Observe two layers: the trapezius and latissimus dorsi muscles, and the levator scapulae and rhomboids minor and major. These axial appendicular muscles help attach the upper limb to the trunk.

---

P.322



**Posterior View**



Authors: Agur, Anne M.R.; Dalley, Arthur F.

Title: *Grant's Atlas of Anatomy, 12th Edition*

Copyright ©2009 Lippincott Williams & Wilkins

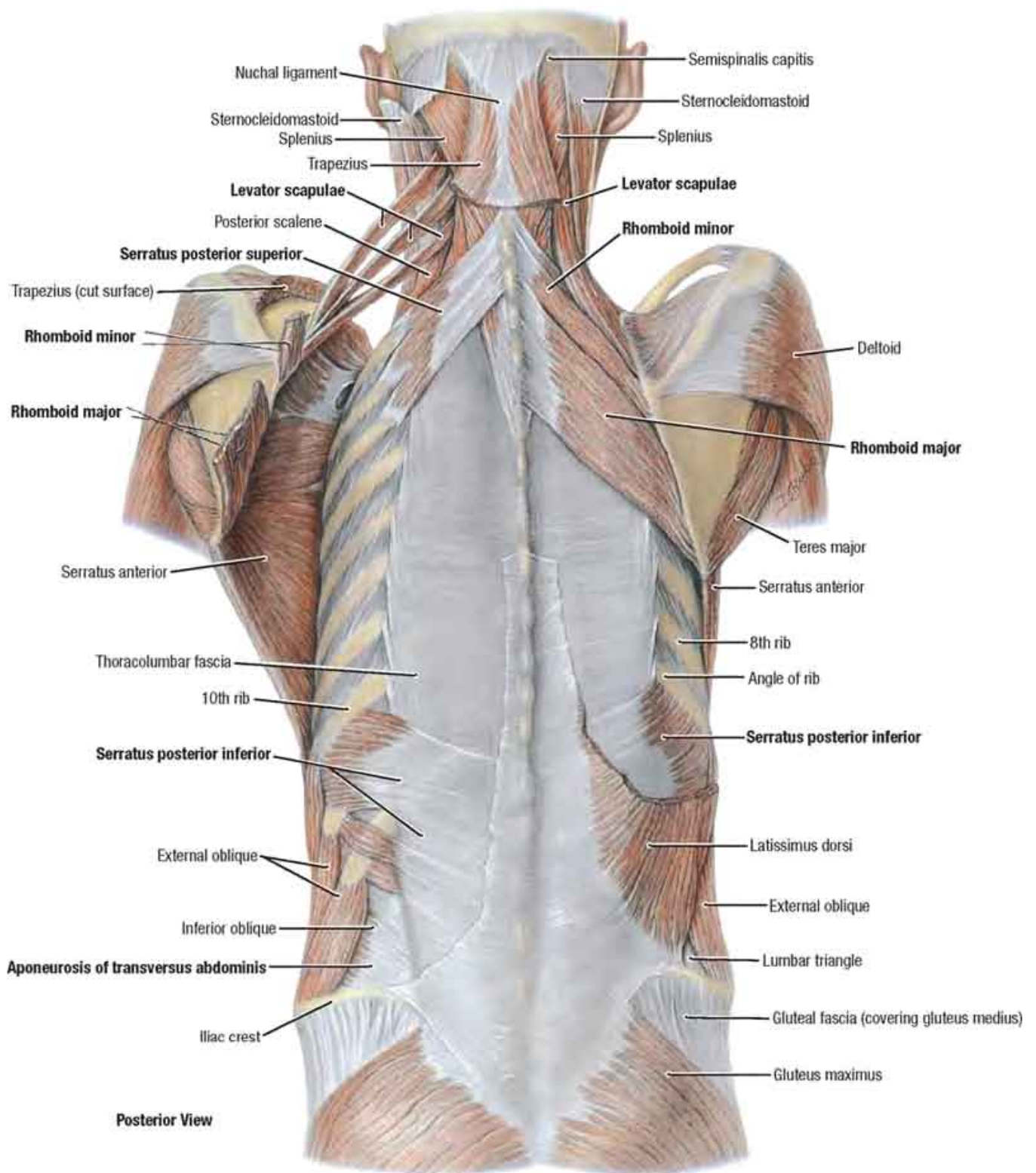
> Table of Contents > Chapter 4 - Back > 4.32 Intermediate muscles of back

---

## 4.32 Intermediate muscles of back

*Part of "Chapter 4 - Back "*

The trapezius and latissimus dorsi muscles are largely cut away on both sides. On the *left*, the rhomboid muscles have been severed, allowing the vertebral border of the scapula to be raised from the thoracic wall. The serratus posterior superior and inferior form the intermediate layer of muscles, passing from the vertebral spines to the ribs; the two muscles slope in opposite directions and are muscles of respiration. The thoracolumbar fascia extends laterally to the angles of the ribs, becoming thin superiorly and passing deep to the serratus posterior superior muscle. The fascia gives attachment to the latissimus dorsi and serratus posterior inferior muscles (see Fig. 4.34 ).



Authors: Agur, Anne M.R.; Dalley, Arthur F.

Title: *Grant's Atlas of Anatomy, 12th Edition*

Copyright ©2009 Lippincott Williams & Wilkins

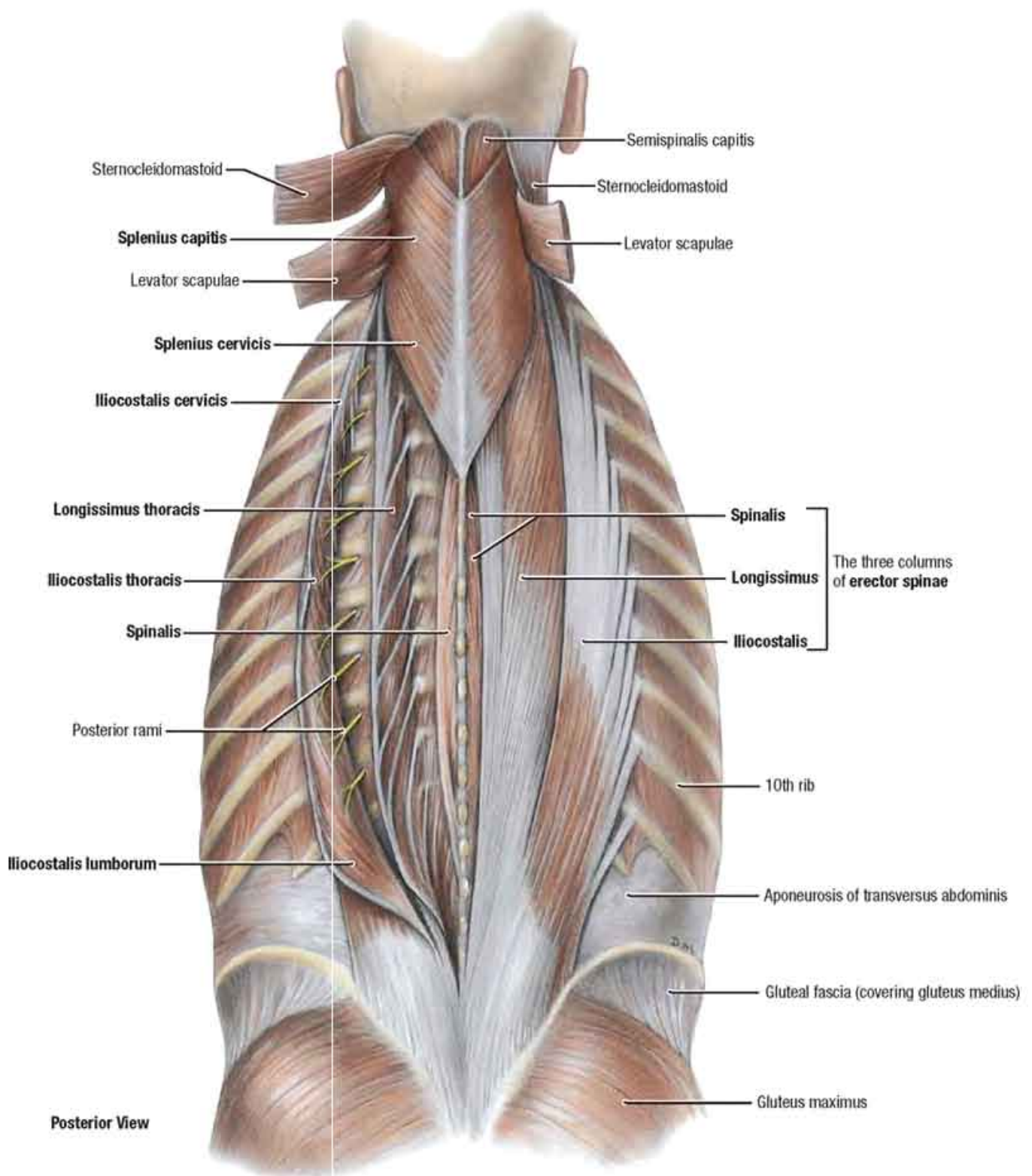
> Table of Contents > Chapter 4 - Back > 4.33 Deep muscles of back: splenius and erector spinae

---

## 4.33 Deep muscles of back: splenius and erector spinae

*Part of* "Chapter 4 - Back "

On the *right* of the body, the erector spinae muscles are in situ, lying between the spinous processes medially and the angles of the ribs laterally. The erector spinae split into three longitudinal columns: iliocostalis laterally, longissimus in the middle, and spinalis medially. On the *left*, the longissimus muscle is pulled laterally to show the insertion into the transverse processes and ribs; not shown here are its extensions to the neck and head, longissimus cervicis and capitis.



Authors: Agur, Anne M.R.; Dalley, Arthur F.

Title: *Grant's Atlas of Anatomy, 12th Edition*

Copyright ©2009 Lippincott Williams & Wilkins

> Table of Contents > Chapter 4 - Back > 4.34 Transverse section of back muscles and thoracolumbar fascia

---

## 4.34 Transverse section of back muscles and thoracolumbar fascia

*Part of* "Chapter 4 - Back "

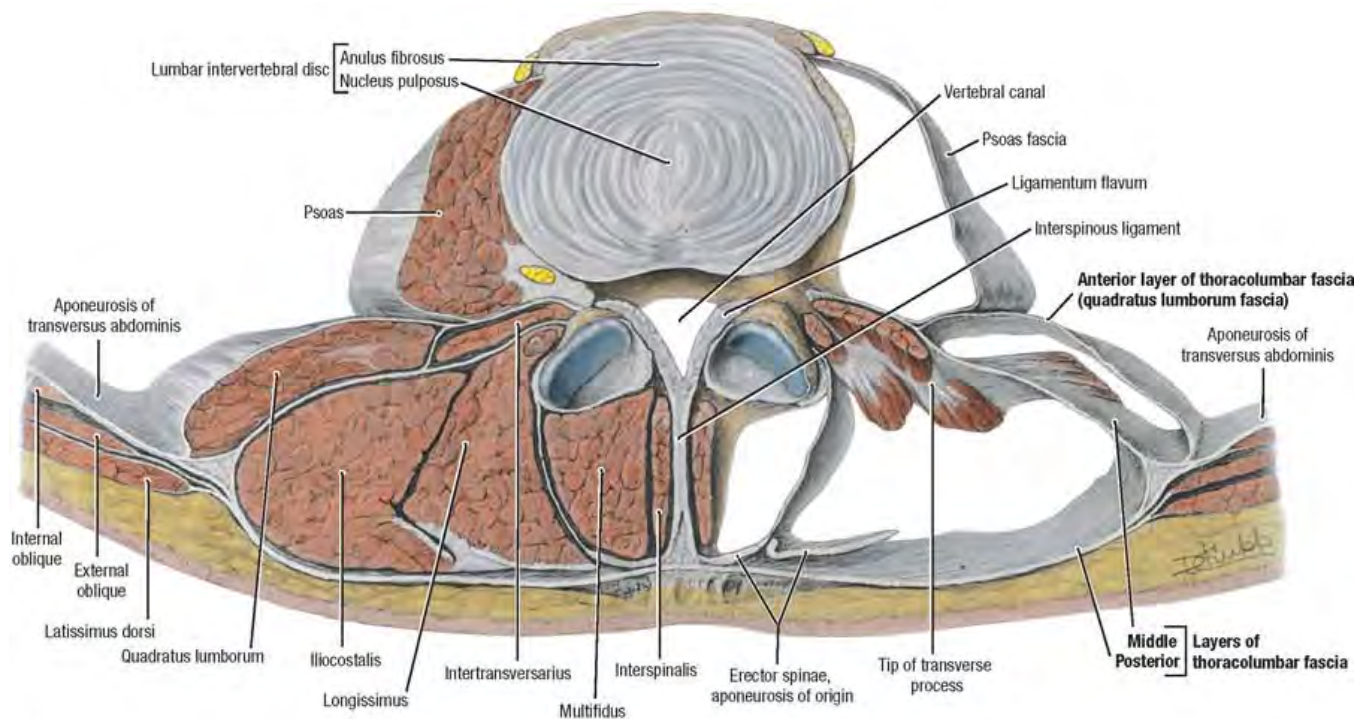
- On the *left*, the muscles are seen in their fascial sheaths or compartments; on the *right*, the muscles have been removed from their sheaths.
- The deep back muscles extend from the pelvis to the cranium and are enclosed in fascia. This fascia attaches medially to the nuchal ligament, the tips of the spinous processes, the supraspinous ligament, and the median crest of the sacrum. The lateral attachment of the fascia is to the cervical transverse processes, the angles of the ribs and to the aponeurosis of transversus abdominis. The thoracic and lumbar parts of the fascia are named thoracolumbar fascia.
- The aponeurosis of transversus abdominis and posterior aponeurosis of internal oblique muscles split into two strong sheets, the middle and posterior layers of the thoracolumbar fascia. The anterior layer of thoracolumbar fascia is the deep fascia of the quadratus lumborum (quadratus lumborum fascia). The posterior layer of the thoracolumbar fascia provides proximal attachment for the latissimus dorsi muscle and, at a higher level, the serratus posterior inferior muscle.

Back strain is a common back problem that usually results from extreme movements of the vertebral column, such as extension or rotation. Back strain refers to some stretching or microscopic tearing of muscle fibers



and/or ligaments of the back. The muscles usually involved are those producing movements of the lumbar IV joints.

P.325



Transverse Section (Dissected),  
Superior View

Authors: Agur, Anne M.R.; Dalley, Arthur F.

Title: *Grant's Atlas of Anatomy, 12th Edition*

Copyright ©2009 Lippincott Williams & Wilkins

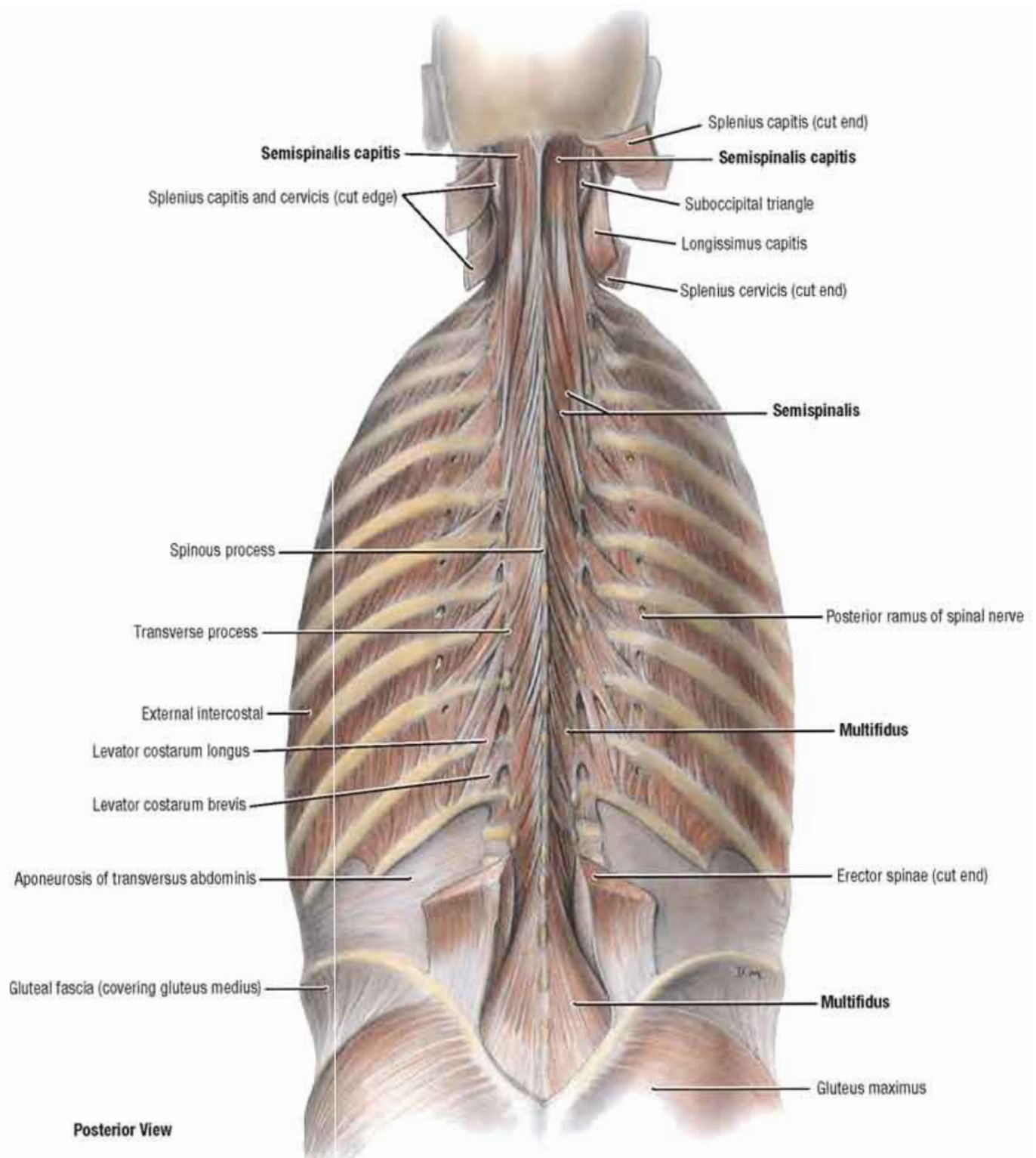
> Table of Contents > Chapter 4 - Back > 4.35 Deep muscles of back: semispinalis and multifidus

---

## 4.35 Deep muscles of back: semispinalis and multifidus

*Part of* "Chapter 4 - Back "

- The semispinalis, multifidus, and rotatores muscles constitute the transversospinalis group of deep muscles. In general, their bundles pass obliquely in a superomedial direction, from transverse processes to spinous processes in successively deeper layers. The bundles of semispinalis span approximately five interspaces, those of multifidus approximately three, and those of rotatores, one or two.
- The semispinalis (thoracis, cervicis, and capitis) muscles extend from the lower thoracic region to the skull; the semispinalis capitis, a powerful extensor muscle, originates from the lower cervical and upper thoracic vertebrae and inserts into the occipital bone between the superior and inferior nuchal lines.
- The multifidus muscle extends from the sacrum to the spine of the axis. In the lumbosacral region it emerges from the aponeurosis of the erector spinae, and extends from the sacrum, and mammillary processes of the lumbar vertebrae, to insert into spinous processes approximately three segments higher.



**Authors:** Agur, Anne M.R.; Dalley, Arthur F.

**Title:** *Grant's Atlas of Anatomy, 12th Edition*

Copyright ©2009 Lippincott Williams & Wilkins

> Table of Contents > Chapter 4 - Back > 4.36 Back: multifidus, quadratus lumborum, and thoracolumbar fascia

---

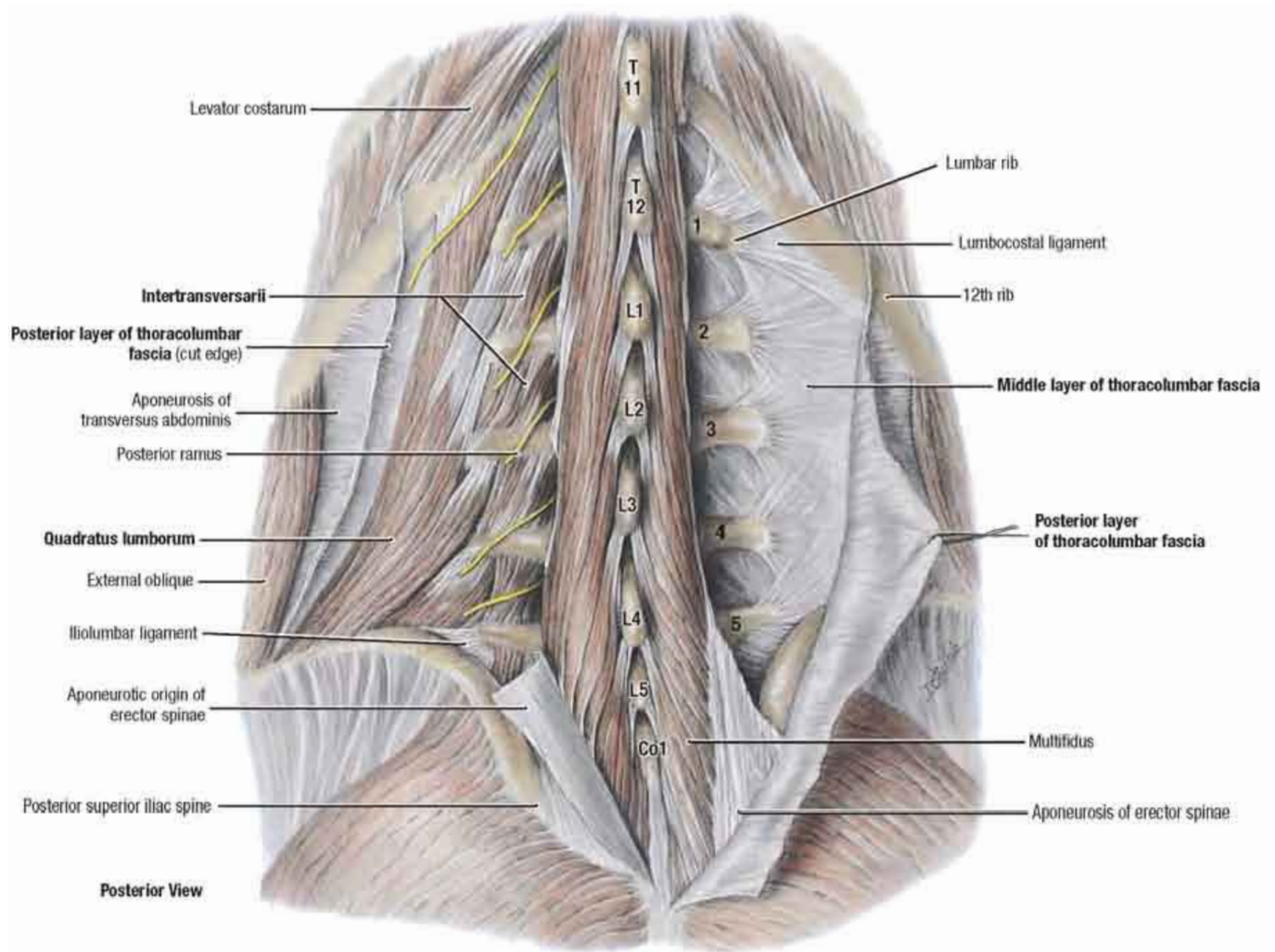
## 4.36 Back: multifidus, quadratus lumborum, and thoracolumbar fascia

*Part of* "Chapter 4 - Back "

*Right:* After removal of erector spinae at the L1 level, the middle layer of thoracolumbar fascia extends from the tip of each lumbar transverse process in a fan-shaped manner. A short lumbar rib is present at the level of L1. *Left:* After removal of the posterior and middle layers of thoracolumbar fascia, the lateral border of the quadratus lumborum muscle is oblique, and the medial border is in continuity with the intertransversarii.

---

P.327





Authors: Agur, Anne M.R.; Dalley, Arthur F.

Title: *Grant's Atlas of Anatomy, 12th Edition*

Copyright ©2009 Lippincott Williams & Wilkins

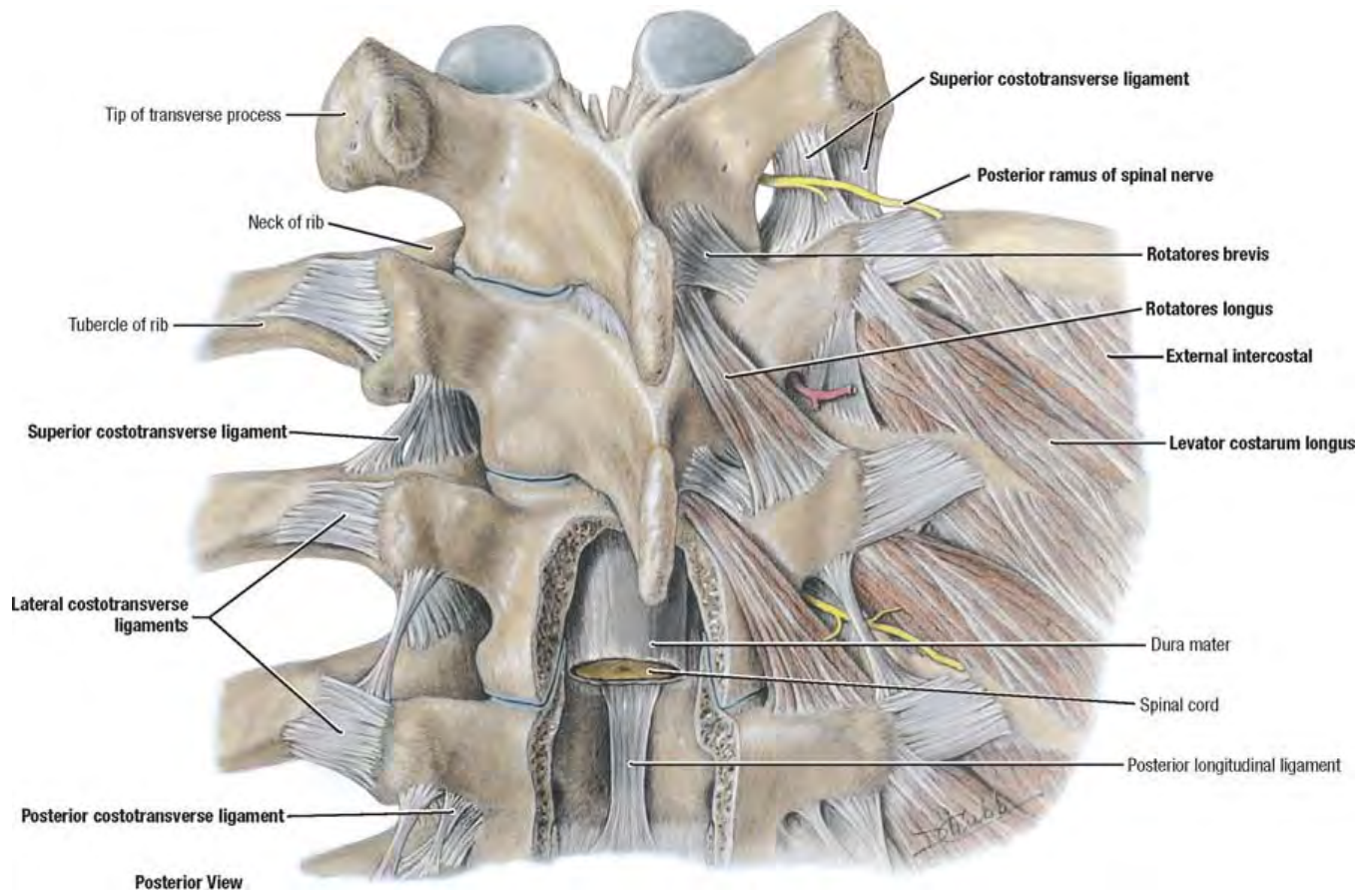
> Table of Contents > Chapter 4 - Back > 4.37 Rotatores and costotransverse ligaments

---

## 4.37 Rotatores and costotransverse ligaments

*Part of* "Chapter 4 - Back "

- Of the three layers of transversospinalis, or oblique muscles of the back (semispinalis, multifidus, rotatores), the rotatores are the deepest and shortest. They pass from the root of one transverse process superomedially to the junction of the transverse process and lamina of the vertebra above. Rotatores longus span two vertebrae.
- The levatores costarum pass from the tip of one transverse process inferiorly to the rib below; some span two ribs.
- The superior costotransverse ligament splits laterally into two sheets, between which lie the levatores costarum and external intercostal muscles; the posterior ramus passes posterior to this ligament.
- The lateral costotransverse ligament is strong and joins the tubercle of the rib to the tip of the transverse process. It forms the posterior aspect of the joint capsule of the costotransverse joint.



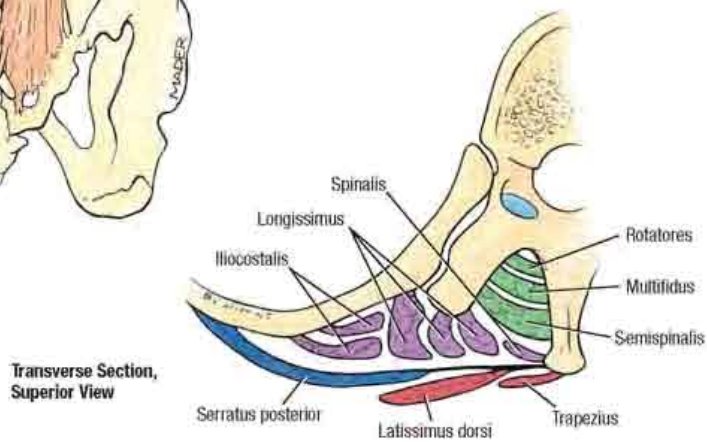
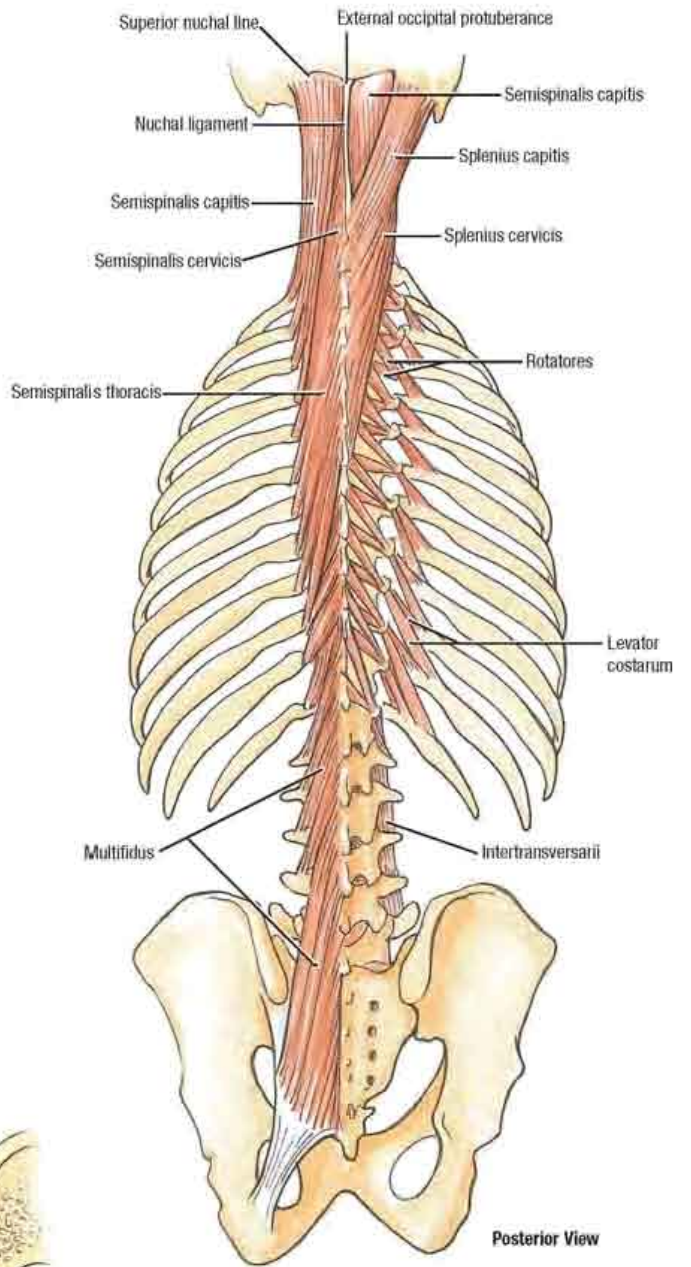
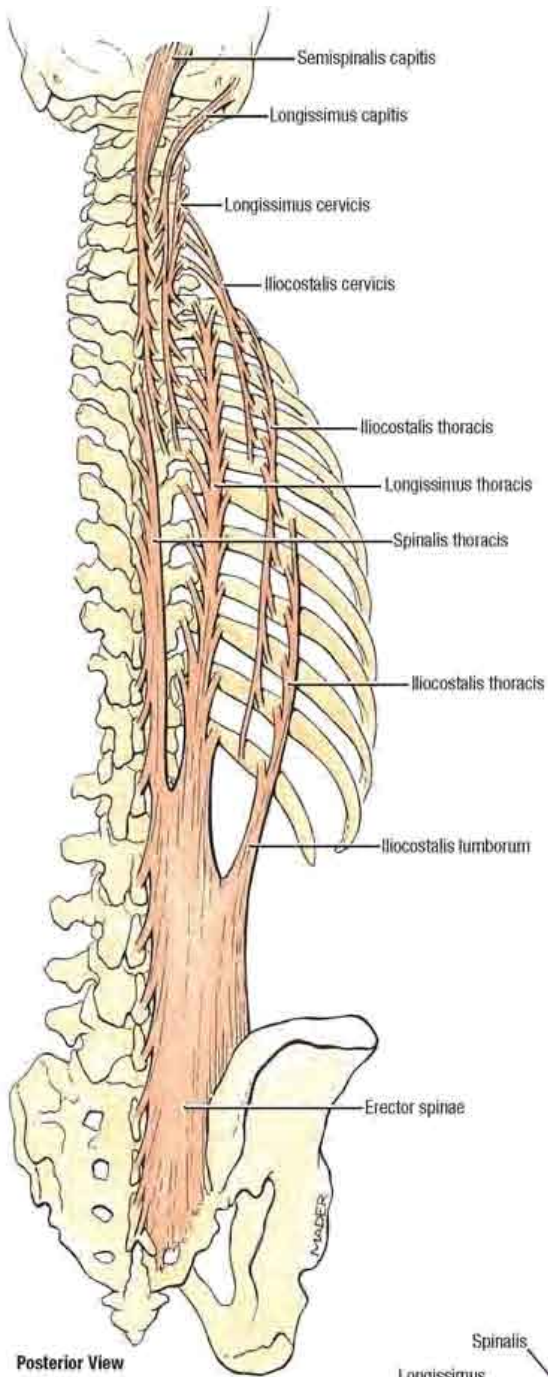
MUSCLES	ORIGIN	INSERTION	NERVE SUPPLY <sup>b</sup>	MAIN ACTIONS
<b>Superficial layer</b> Splenius	Arises from nuchal ligament and spinous processes of C7–T3 or T4 vertebrae	<i>Splenius capitis</i> : fibers run superolaterally to mastoid process of temporal bone and lateral third of superior nuchal line of occipital bone. <i>Splenius cervicis</i> : posterior tubercles of transverse processes of C1–C3 or C4 vertebrae	Posterior rami of spinal nerves	<i>Acting unilaterally</i> : laterally bend to side of active muscles; <i>Acting bilaterally</i> : extend head and neck
<b>Intermediate layer</b> Erector spinae	Arises by a broad tendon from posterior part of iliac crest, posterior surface of sacrum, sacral and inferior lumbar spinous processes, and supraspinous ligament	<i>Iliocostalis (lumborum, thoracis, and cervicis)</i> : fibers run superiorly to angles of lower ribs and cervical transverse processes <i>Longissimus (thoracis, cervicis, and capitis)</i> : fibers run superiorly to ribs between tubercles and angles to transverse processes in thoracic and cervical regions, and to mastoid process of temporal bone <i>Spinalis (thoracis, cervicis, and capitis)</i> : fibers run superiorly to spinous processes in the upper thoracic region and to skull		<i>Acting unilaterally</i> : laterally bend vertebral column to side of active muscles; <i>Acting bilaterally</i> : extend vertebral column and head; as back is flexed, control movement by gradually lengthening their fibers
<b>Deep layer</b> Transversospinalis	<i>Semispinalis</i> : arises from thoracic and cervical transverse processes.  <i>Multifidus</i> : arises from sacrum and ilium, transverse processes of T1–L5, and articular processes of C4–C7  <i>Rotatores</i> : arise from transverse processes of vertebrae; best developed in thoracic region	<i>Semispinalis</i> : thoracis, cervicis, and capitis: fibers run superomedially and attach to occipital bone and spinous processes in thoracic and cervical regions, spanning four to six segments <i>Multifidus (lumborum, thoracis, and cervicis)</i> : fibers pass superomedially to spinous processes, spanning two to four segments  <i>Rotatores (thoracis and cervicis)</i> : Pass superomedially and attach to junction of lamina and transverse process of vertebra of origin or into spinous process above their origin, spanning one to two segments		<i>Acting unilaterally</i> : rotate head and neck contralaterally; <i>Acting bilaterally</i> : extend head and thoracic cervical regions Stabilizes vertebrae during local movements of vertebral column  Stabilize vertebrae and assist with local extension and rotary movements
<b>Minor deep layer</b> Interspinales	Superior surfaces of spinous processes of cervical and lumbar vertebrae	Inferior surfaces of spinous processes of vertebrae superior to vertebrae of origin	Posterior rami of spinal nerves	Aid in extension and rotation of vertebral column
Intertransversarii	Transverse processes of cervical and lumbar vertebrae	Transverse processes of adjacent vertebrae	Posterior and anterior rami of spinal nerves	Aid in lateral bending of vertebral column; <i>Acting bilaterally</i> : stabilize vertebral column
Levatores costarum	Tips of transverse processes of C7 and T1–T11 vertebrae	Pass inferolaterally and insert on rib between its tubercle and angle	Posterior rami of C8–T11 spinal nerves	Elevate ribs, assisting inspiration Assist with lateral bending of vertebral column

<sup>a</sup>See figures on opposite page.

<sup>b</sup>Most back muscles are innervated by dorsal rami of spinal nerves, but a few are innervated by anterior rami. Intertransversarii of cervical region are supplied by anterior rami.

Table 4.4 Intrinsic Back Muscles <sup>a</sup>





Red	Superficial extrinsic
Blue	Intermediate extrinsic
Purple	Erector spinae (intermediate intrinsic)
Green	Transversospinal (deep intrinsic)

Authors: Agur, Anne M.R.; Dalley, Arthur F.

Title: *Grant's Atlas of Anatomy, 12th Edition*

Copyright ©2009 Lippincott Williams & Wilkins

> Table of Contents > Chapter 4 - Back > 4.38 Suboccipital region

---

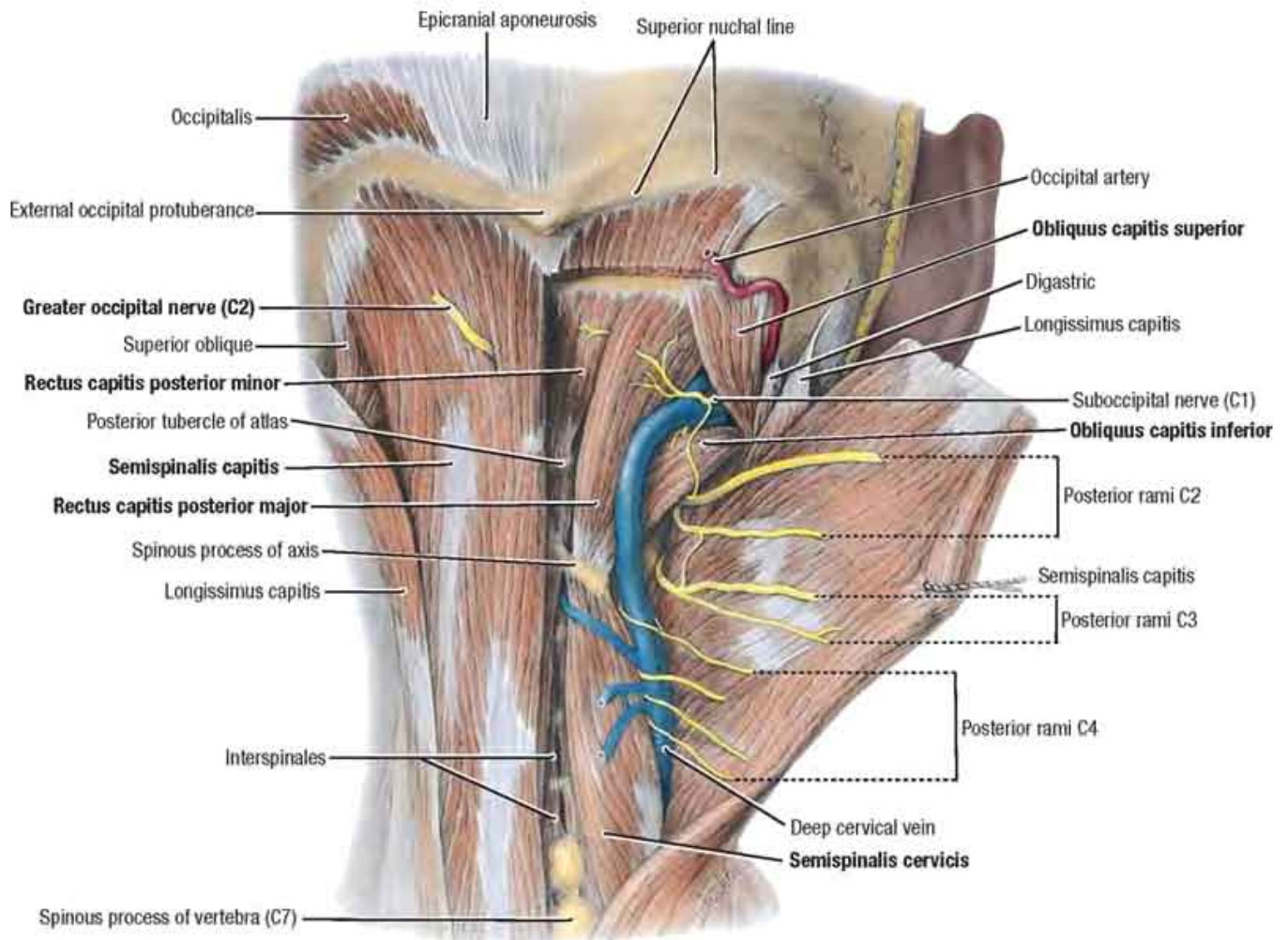
## 4.38 Suboccipital region

Part of "Chapter 4 - Back "

The trapezius, sternocleidomastoid, and splenius muscles are removed. The right semispinalis capitis muscle is cut and turned laterally.

- The semispinalis capitis, the great extensor muscle of the head and neck, forms the posterior wall of the suboccipital region. It is pierced by the greater occipital nerve (posterior ramus of C2) and has free medial and lateral borders at this level.
- The greater occipital nerve, when followed caudally, leads to the inferior border of the obliquus capitis inferior muscle, around which it turns. Following the inferior border of the obliquus capitis inferior muscle medially from the nerve leads to the spinous process of the axis; followed laterally, this leads to the transverse process of the atlas.
- Five muscles (all paired) are attached to the spinous process of the axis: obliquus capitis inferior, rectus capitis posterior major, semispinalis cervicis, multifidus, and interspinalis; the latter two are largely concealed by the semispinalis cervicis.





**Posterior View**

Authors: Agur, Anne M.R.; Dalley, Arthur F.

Title: *Grant's Atlas of Anatomy, 12th Edition*

Copyright ©2009 Lippincott Williams & Wilkins

> Table of Contents > Chapter 4 - Back > 4.39 Suboccipital region

---

## 4.39 Suboccipital region

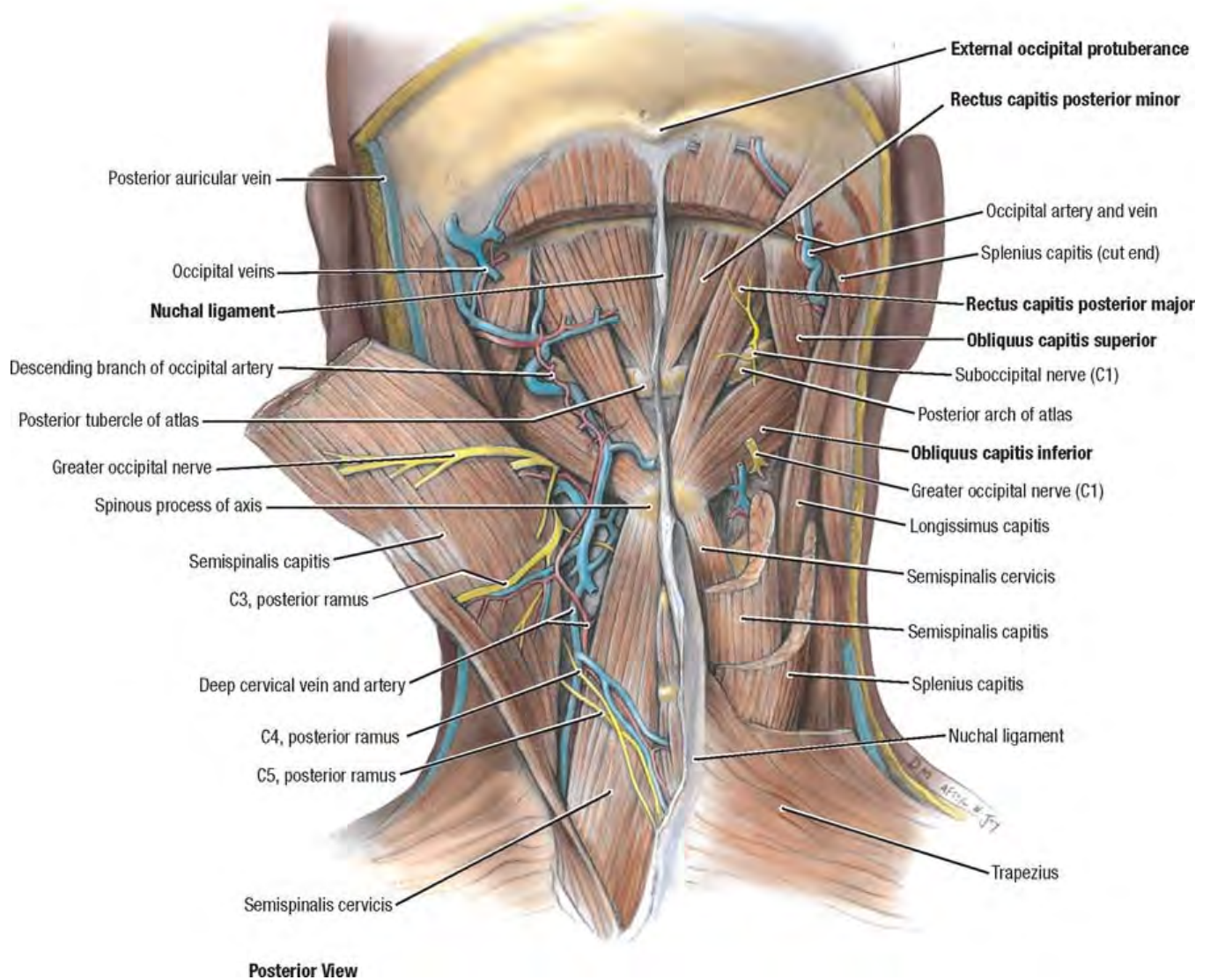
Part of "Chapter 4 - Back "

The semispinalis capitis is reflected on the *left* and removed on the *right* side of the body.

- The suboccipital region contains four pairs of structures: two straight muscles, the rectus capitis posterior major and minor; two oblique muscles, the obliquus capitis superior and obliquus capitis inferior; two nerves (posterior rami), C1 suboccipital (motor) and C2 greater occipital (sensory); and two arteries, the occipital and vertebral.
- The nuchal ligament, which represents the cervical part of the supraspinous ligament, is a median, thin, fibrous partition attached to the spinous processes of cervical vertebrae and the external occipital crest; its posterior border gives origin to the trapezius muscle and extends superiorly to the external occipital protuberance.
- The suboccipital triangle is bounded by three muscles: obliquus capitis superior and inferior, and rectus capitis posterior major.
- The suboccipital nerve (posterior ramus of C1) supplies the three muscles bounding the suboccipital triangle and also the rectus capitis minor muscle and communicates with the greater occipital nerve.
- The occipital veins along with the suboccipital nerve (posterior ramus of C1) emerge through the suboccipital triangle to join the deep cervical vein.

- The posterior arch of the atlas forms the floor of the suboccipital triangle.

P.332



## Movements of Atlanto-occipital Joints

*Flexion*

*Extension*

*Lateral Bending*

Longus capitis

Rectus capitis anterior

Anterior fibers of  
sternocleidomastoid

Rectus capitis posterior major and minor

Obliquus capitis superior

Semispinalis capitis

Splenius capitis

Longissimus capitis

Trapezius

Sternocleidomastoid

Obliquus capitis superior and inferior

Rectus capitis lateralis

Splenius capitis

Rotation of Atlantoaxial Joints <sup>a</sup>

*Ipsilateral*<sup>b</sup>

*Contralateral*

Obliquus capitis inferior

Rectus capitis posterior, major and minor

Longissimus capitis

Splenius capitis

Sternocleidomastoid

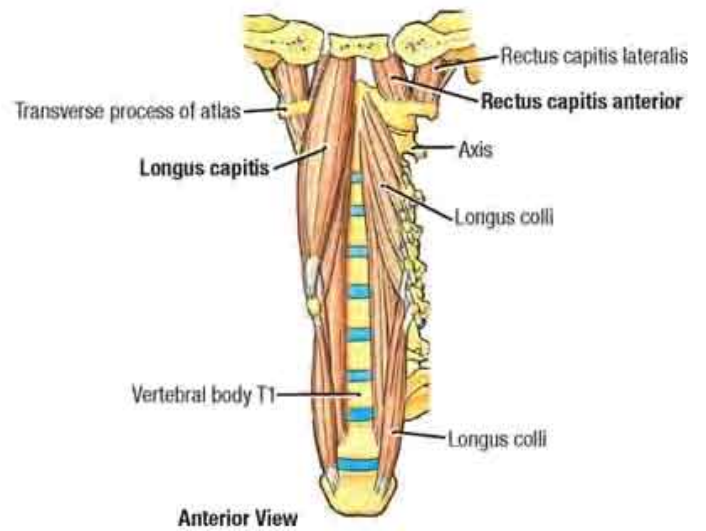
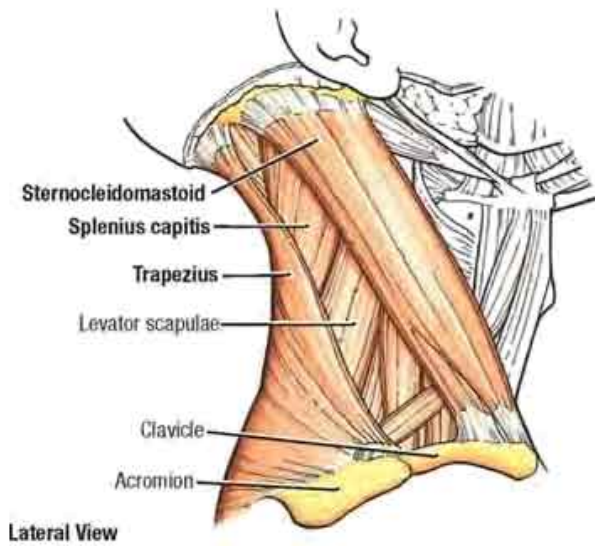
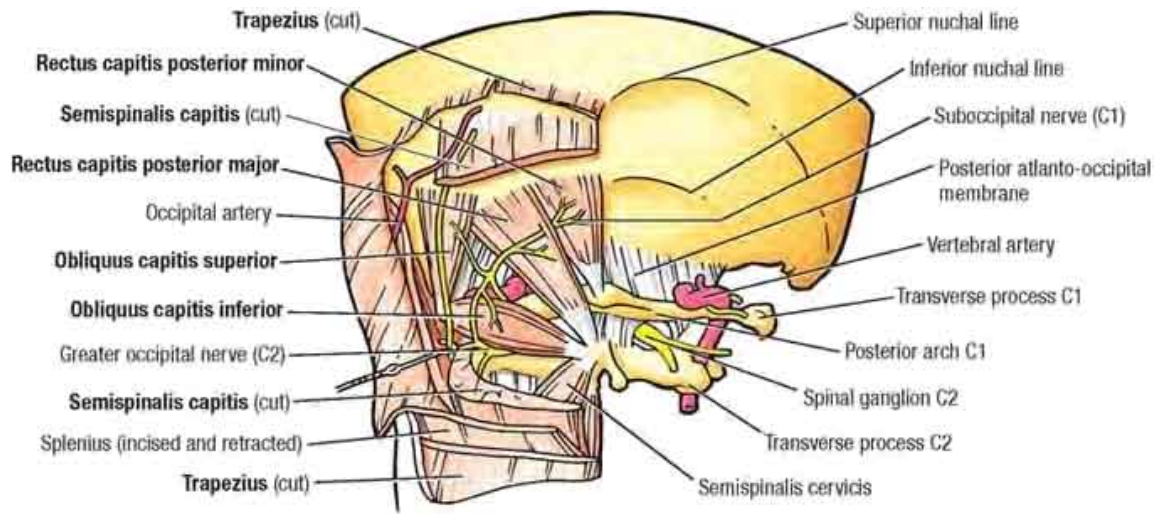
Semispinalis capitis

<sup>a</sup> Rotation is the specialized movement at these joints. Movement of one joint involves the other.

<sup>b</sup> Same side to which head is rotated.

## Table 4.5 Muscles of the Atlanto-Occipital and Atlantoaxial Joints







Authors: Agur, Anne M.R.; Dalley, Arthur F.

Title: *Grant's Atlas of Anatomy, 12th Edition*

Copyright ©2009 Lippincott Williams & Wilkins

> Table of Contents > Chapter 4 - Back > 4.40 Nuchal Region

---

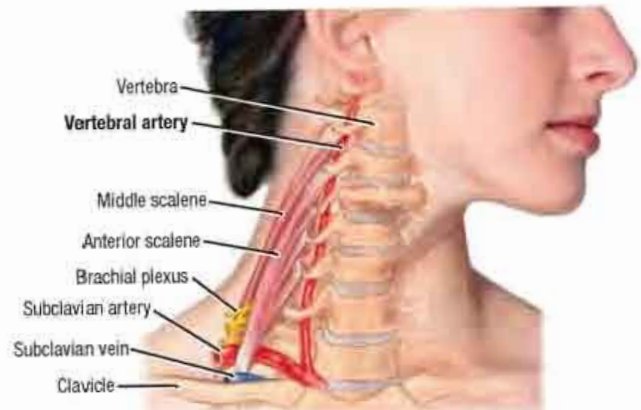
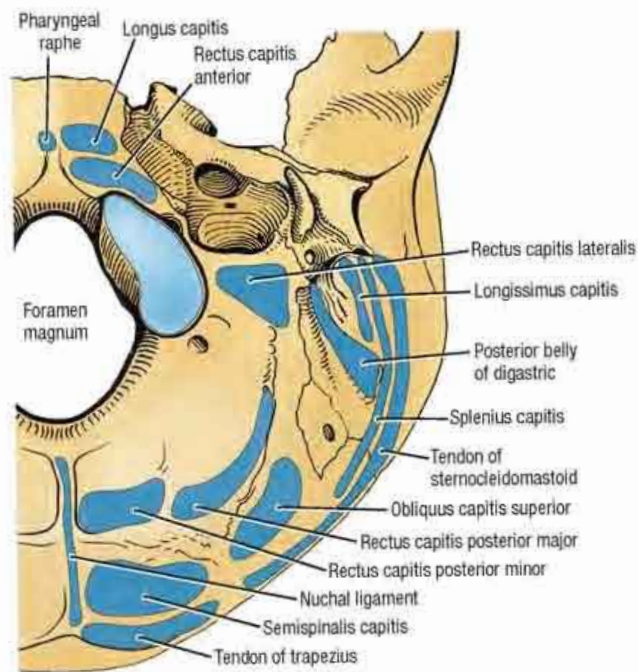
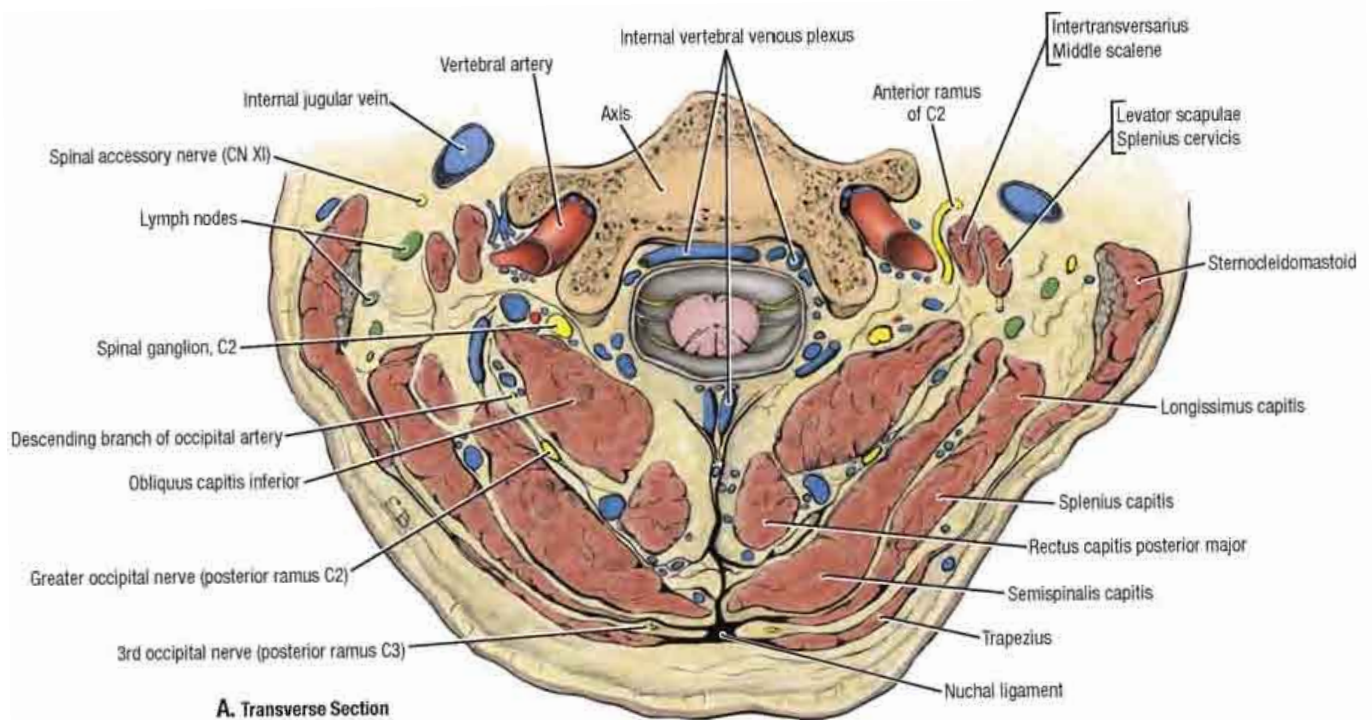
## 4.40 Nuchal Region

*Part of* "Chapter 4 - Back "

A. Transverse section at the level of the axis. B. Muscle attachments to inferior aspect of skull. C. Vertebral artery.

---

P.334



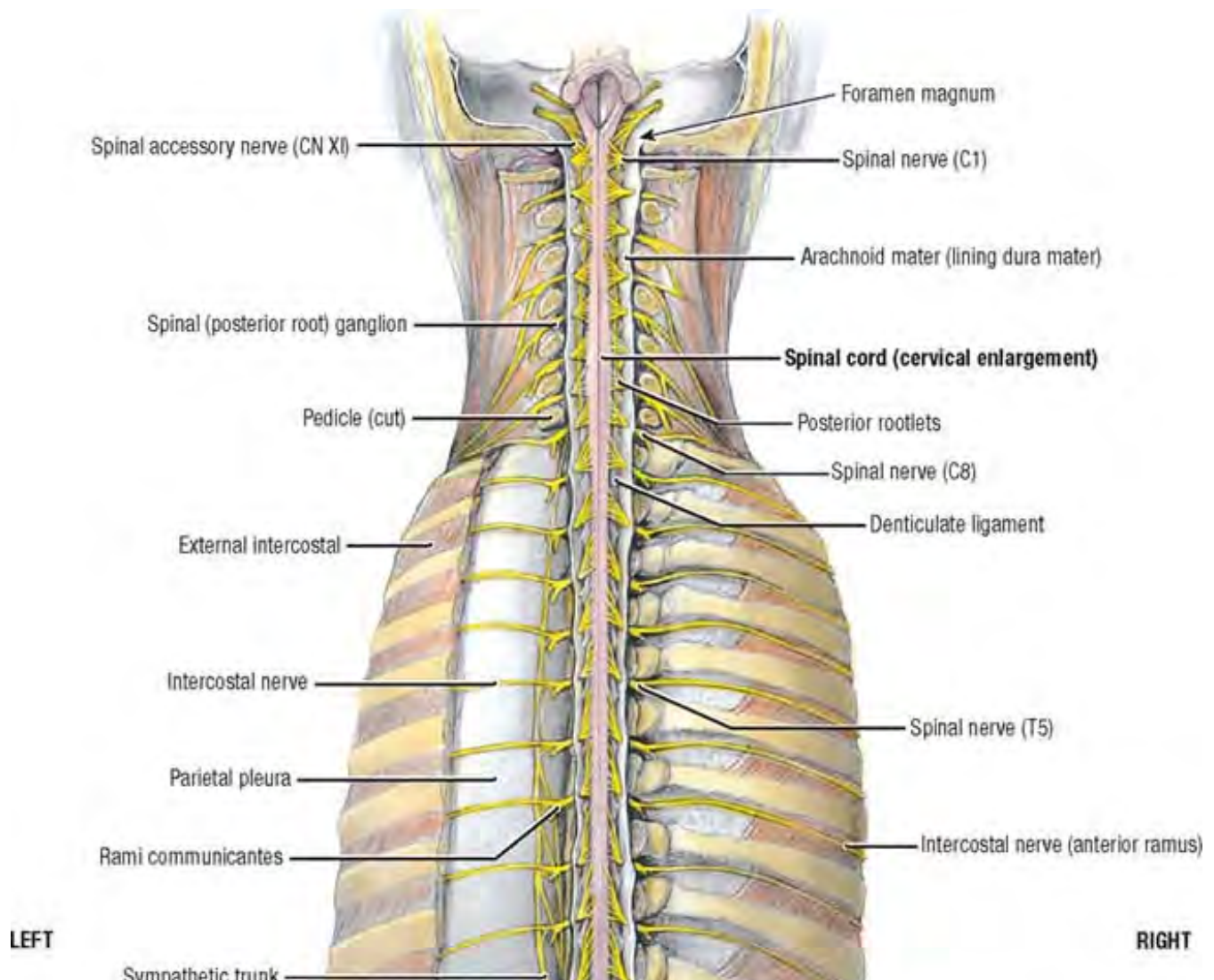
Authors: Agur, Anne M.R.; Dalley, Arthur F.  
Title: *Grant's Atlas of Anatomy, 12th Edition*  
Copyright ©2009 Lippincott Williams & Wilkins

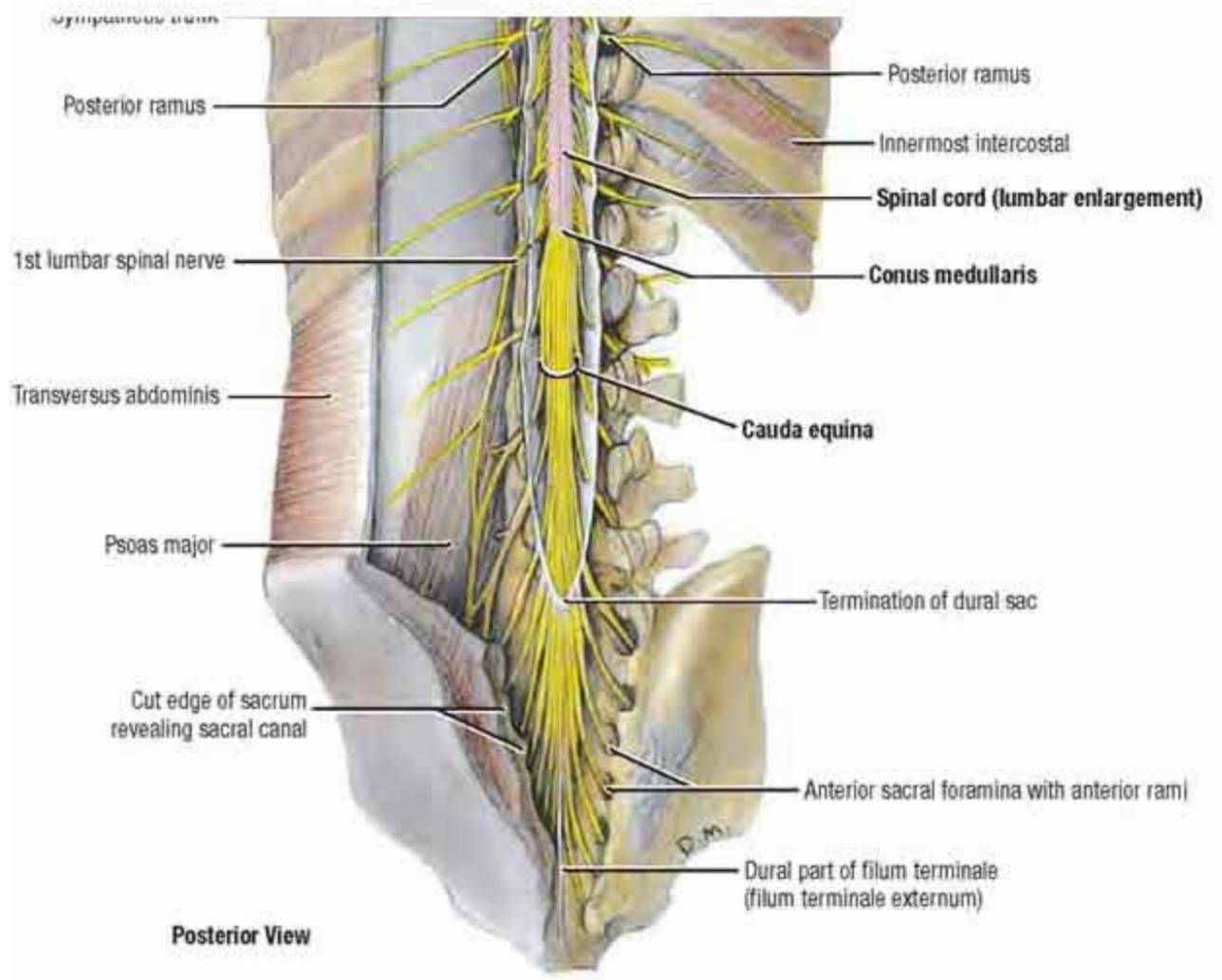
> Table of Contents > Chapter 4 - Back > 4.41 Spinal cord in situ

## 4.41 Spinal cord in situ

Part of "Chapter 4 - Back "

P.335





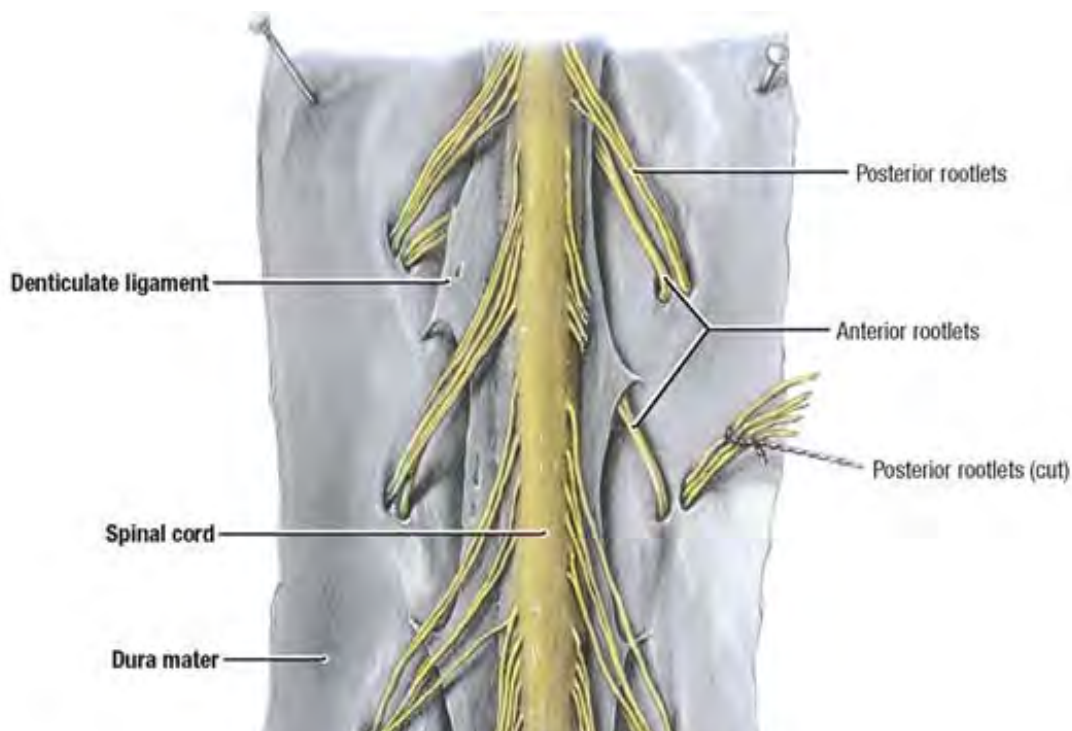


## 4.42 Spinal cord and meninges

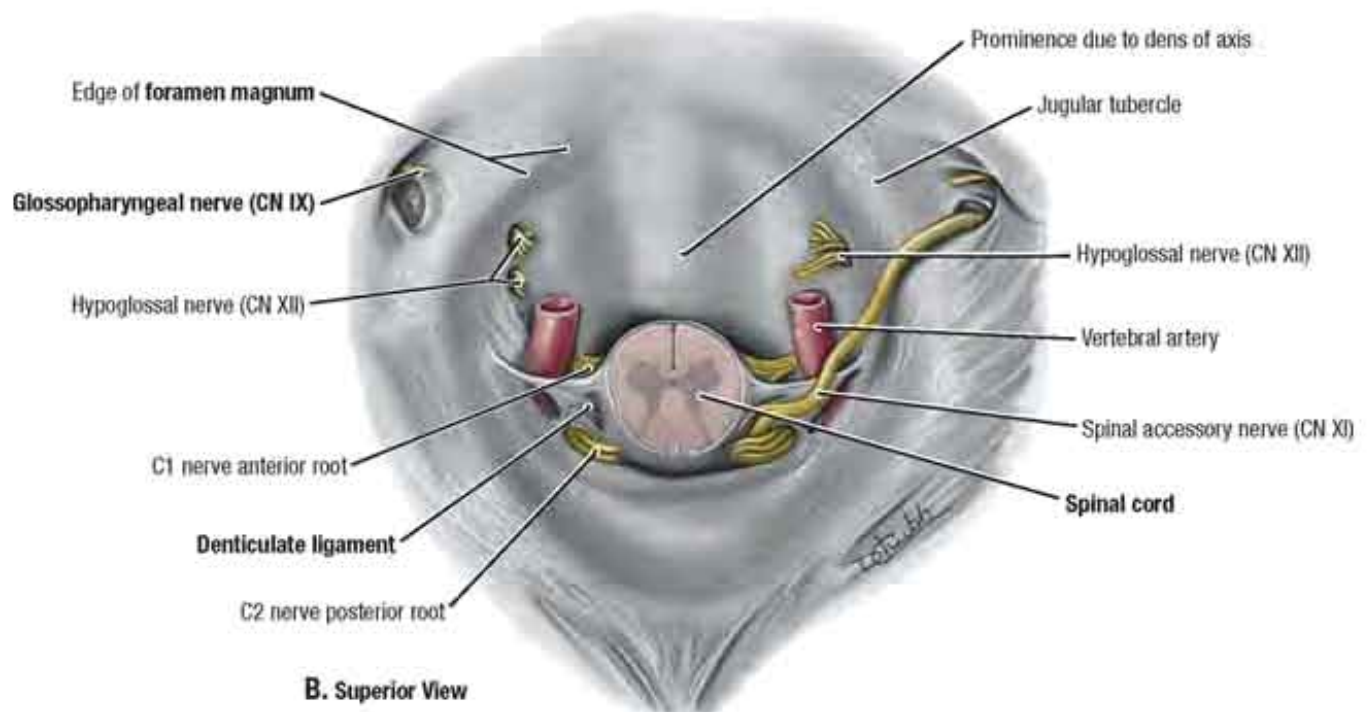
Part of "Chapter 4 - Back "

A. Dural sac cut open. The denticulate ligament anchors the cord to the dural sac between successive nerve roots by means of strong, toothlike processes. The anterior nerve roots lie anterior to the denticulate ligament, and the posterior nerve roots lie posterior to the ligament. B. Structures of vertebral canal seen through foramen magnum. The spinal cord, vertebral arteries, spinal accessory nerve (CN XI), and most superior part of the denticulate ligament pass through the foramen magnum within the meninges.

P.336







Authors: Agur, Anne M.R.; Dalley, Arthur F.

Title: *Grant's Atlas of Anatomy, 12th Edition*

Copyright ©2009 Lippincott Williams & Wilkins

> Table of Contents > Chapter 4 - Back > 4.43 Inferior end of dural sac

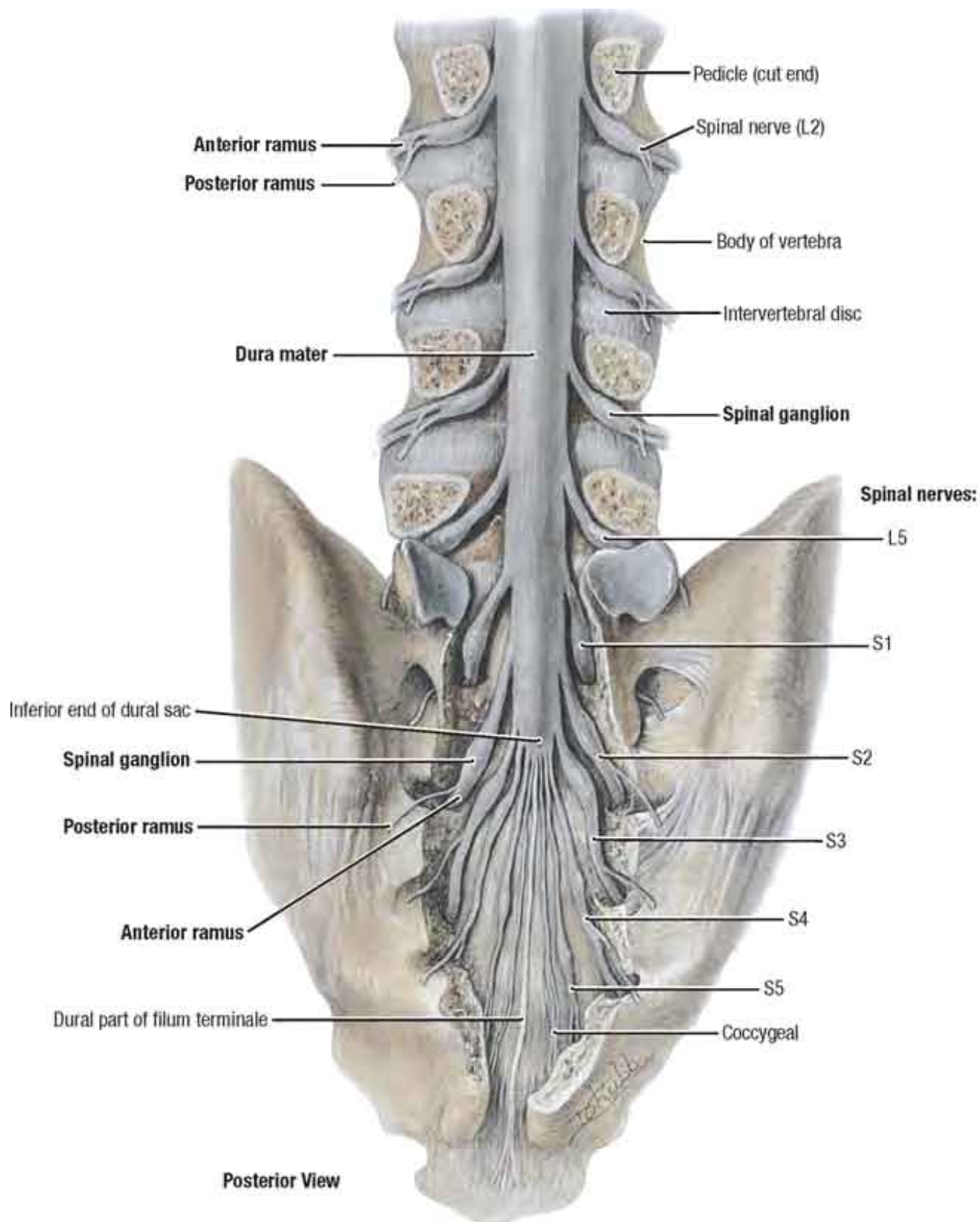
---

## 4.43 Inferior end of dural sac

*Part of* "Chapter 4 - Back "

The posterior parts of the lumbar vertebrae and sacrum were removed.

- The inferior limit of the dural sac is at the level of the posterior superior iliac spine (body of 2nd sacral vertebra); the dura continues as the dural part of the filum terminale (filum terminale externum).
- The lumbar spinal ganglia are in the intervertebral foramina, and the sacral spinal ganglia are somewhat asymmetrically placed within the sacral canal.
- The posterior rami are smaller than the anterior rami.





Authors: Agur, Anne M.R.; Dalley, Arthur F.

Title: *Grant's Atlas of Anatomy, 12th Edition*

Copyright ©2009 Lippincott Williams & Wilkins

> Table of Contents > Chapter 4 - Back > 4.44 Inferior end of dural sac " II

---

## 4.44 Inferior end of dural sac " II

*Part of* "Chapter 4 - Back "

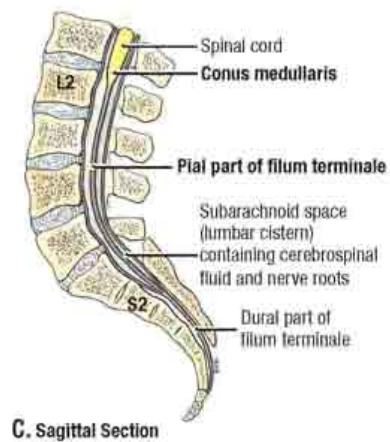
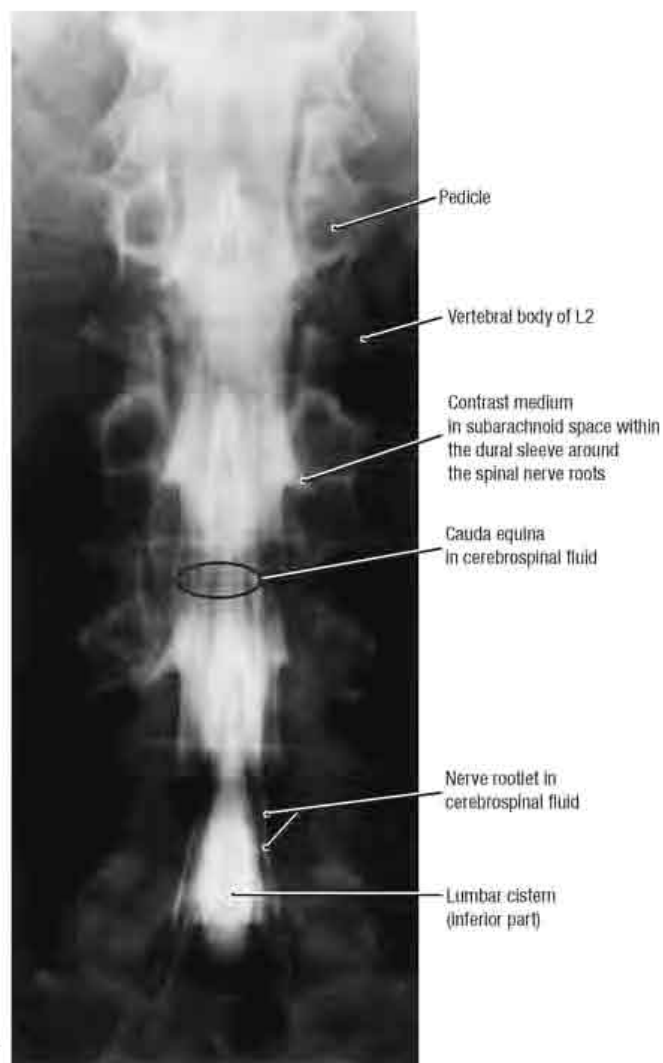
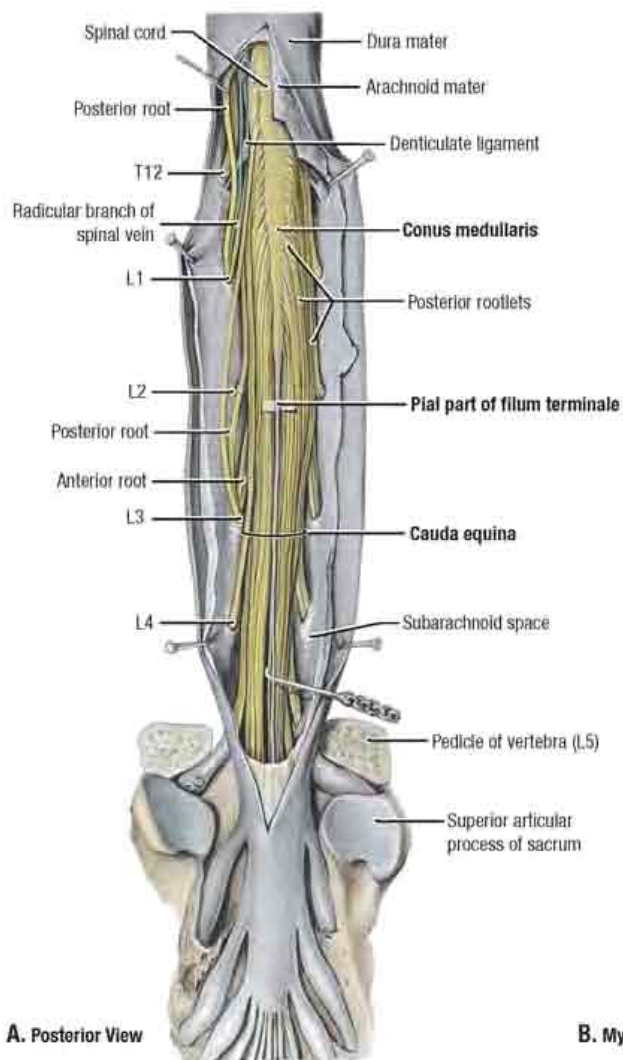
A. Inferior dural sac and lumbar cistern of subarachnoid space, opened. B. Myelogram of the lumbar region of the vertebral column. Contrast medium was injected into the subarachnoid space. C. Termination of spinal cord, in situ, sagittal section.

- The conus medullaris, or conical lower end of the spinal cord, continues as a glistening thread, the filial part of the filum terminale (filum terminale internum), which descends with the posterior and anterior nerve roots; these constitute the cauda equina.
- In the adult, the spinal cord usually ends at the level of the disc between L1 and L2. Variations: 95% of cords end within the limits of the bodies of L1 and L2, whereas 3% end posterior to the inferior half of T12, and 2% posterior to L3.
- The subarachnoid space usually ends at the level of the disc between S1 and S2, but it can be more inferior.

To obtain a sample of CSF from the lumbar cistern, a lumbar puncture needle, fitted with a stylet, is inserted into the subarachnoid space. Flexion of the vertebral column facilitates insertion of the needle by stretching the ligamenta flava and spreading the laminae and spinous processes apart. The needle is inserted in the midline between the spinous processes of the L3 and L4 (or the L4 and L5) vertebrae. At these levels in adults, there is little danger of damaging the spinal cord.







Authors: Agur, Anne M.R.; Dalley, Arthur F.

Title: *Grant's Atlas of Anatomy, 12th Edition*

Copyright ©2009 Lippincott Williams & Wilkins

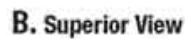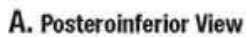> Table of Contents > Chapter 4 - Back > 4.45 Lower cervical vertebrae and associated structures and nerves

---

## 4.45 Lower cervical vertebrae and associated structures and nerves

*Part of* "Chapter 4 - Back "

A. Relationship of cervical spinal cord, spinal nerves, and coverings. The anterior and posterior roots, in a common or separate dural sleeve, unite beyond the spinal ganglion to form a spinal nerve that immediately divides into a small posterior and large anterior ramus. The roots pass anterior to the zygapophysial joints and unite as they exit the intervertebral foramina and pass posterior to the vertebral artery. The posterior ramus curves dorsally around the superior articular process, and the anterior ramus rests on the transverse process, which is grooved to support it. B. Transverse section of spinal cord in situ. Note the vulnerability of the vertebral artery, spinal cord, and nerve roots to arthritic expansion from articular processes and the vertebral body, particularly the lateral edge of the superior surface of the body, the uncovertebral joint (joint of Luschka).



Authors: Agur, Anne M.R.; Dalley, Arthur F.

Title: *Grant's Atlas of Anatomy, 12th Edition*

Copyright ©2009 Lippincott Williams & Wilkins

> Table of Contents > Chapter 4 - Back > 4.46 Spinal cord and prevertebral structures

---

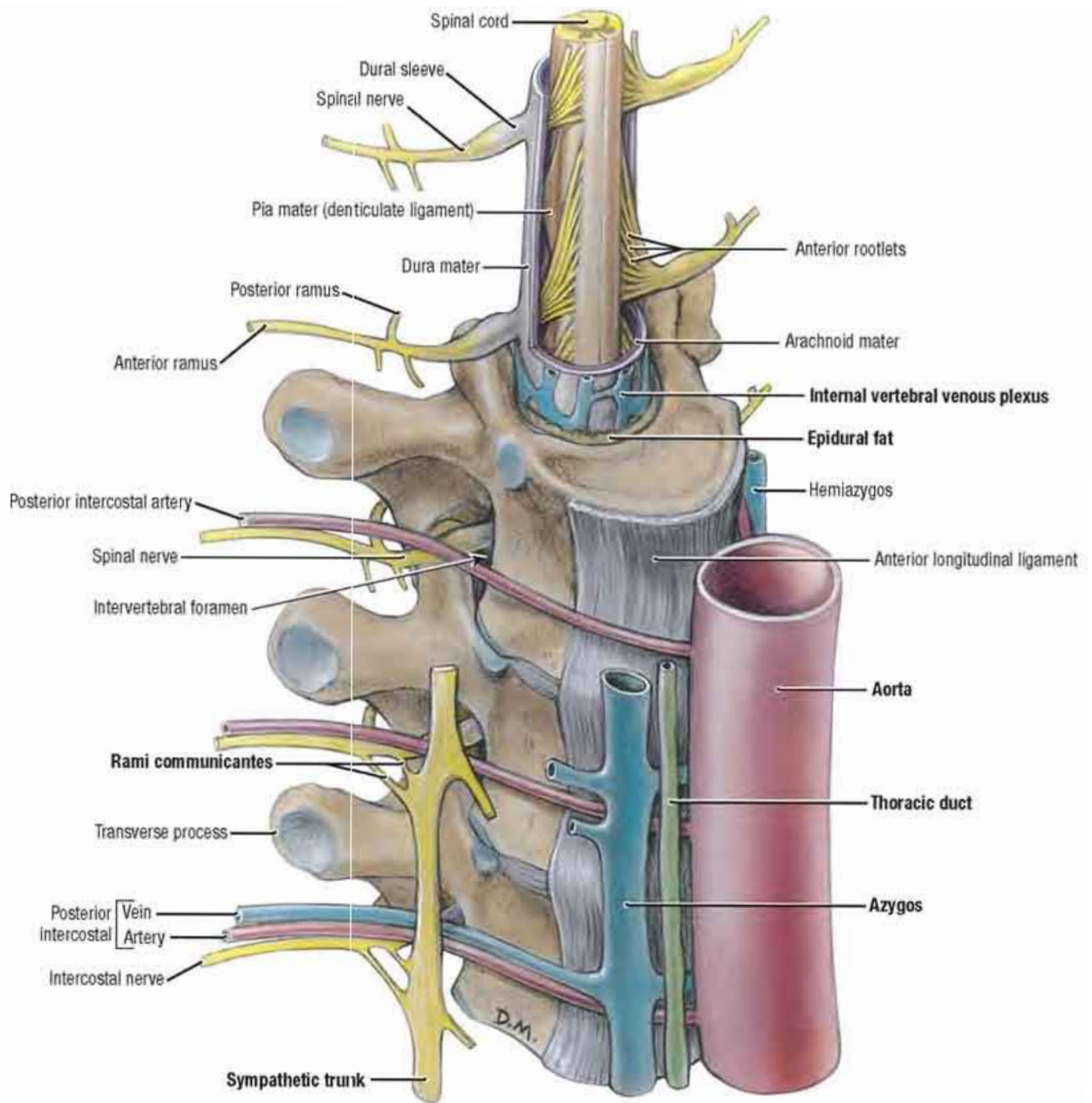
## 4.46 Spinal cord and prevertebral structures

*Part of* "Chapter 4 - Back "

The vertebrae have been removed superiorly to expose the spinal cord and meninges.

- The aorta descends to the left of the midline, with the thoracic duct and azygos vein to its right.
- Typically, the azygos vein is on the right side of the vertebral bodies, and the hemiazygous vein is on the left.
- The thoracic sympathetic trunk and ganglia lie lateral to the thoracic vertebrae; the rami communicantes connect the sympathetic ganglia with the spinal nerve.
- A sleeve of dura mater surrounds the spinal nerves and blends with the sheath (epineurium) of the spinal nerve.
- The dura mater is separated from the walls of the vertebral canal by epidural fat and the internal vertebral venous plexus.





**Right Anterolateral View**

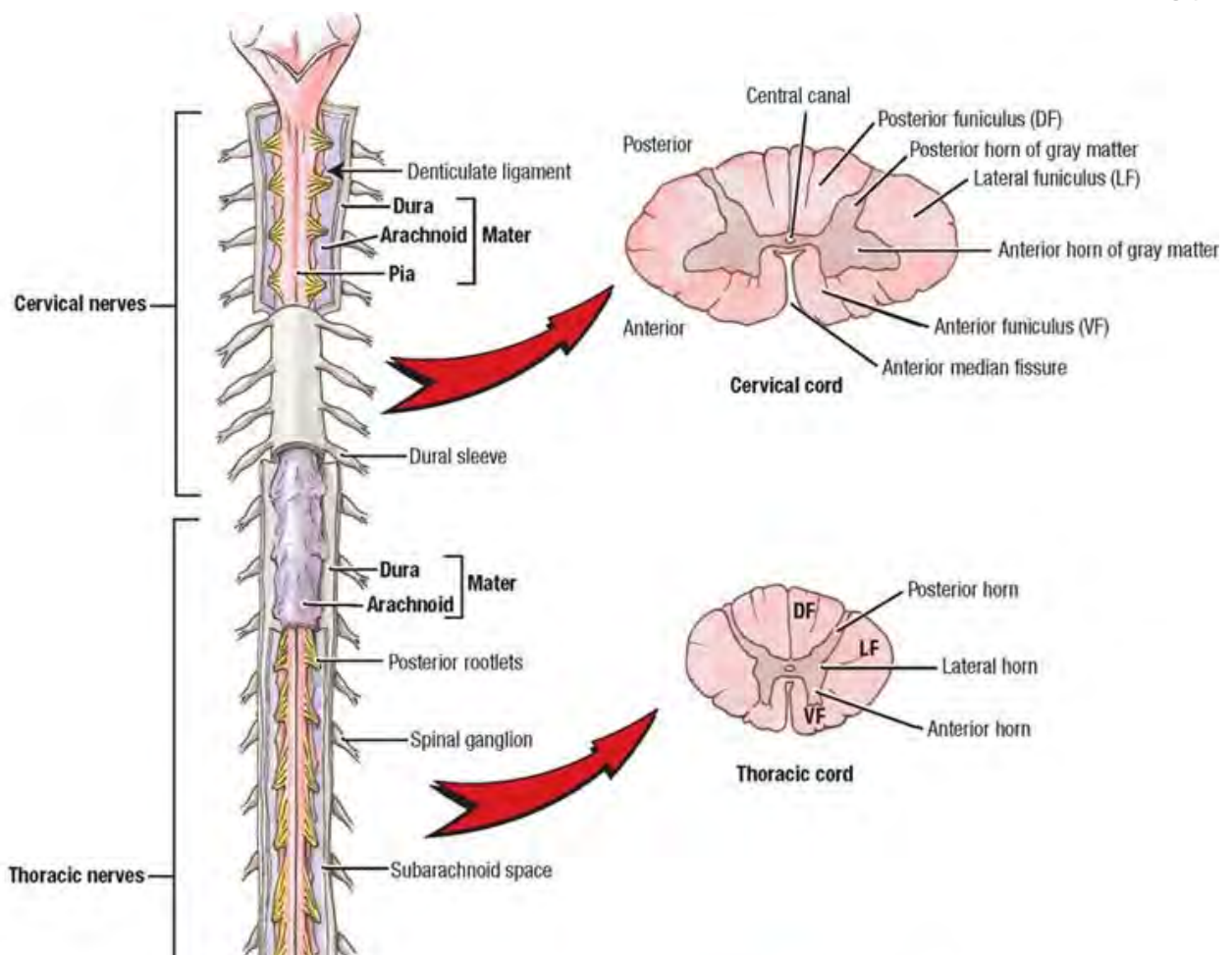
Authors: Agur, Anne M.R.; Dalley, Arthur F.  
Title: *Grant's Atlas of Anatomy, 12th Edition*  
Copyright ©2009 Lippincott Williams & Wilkins

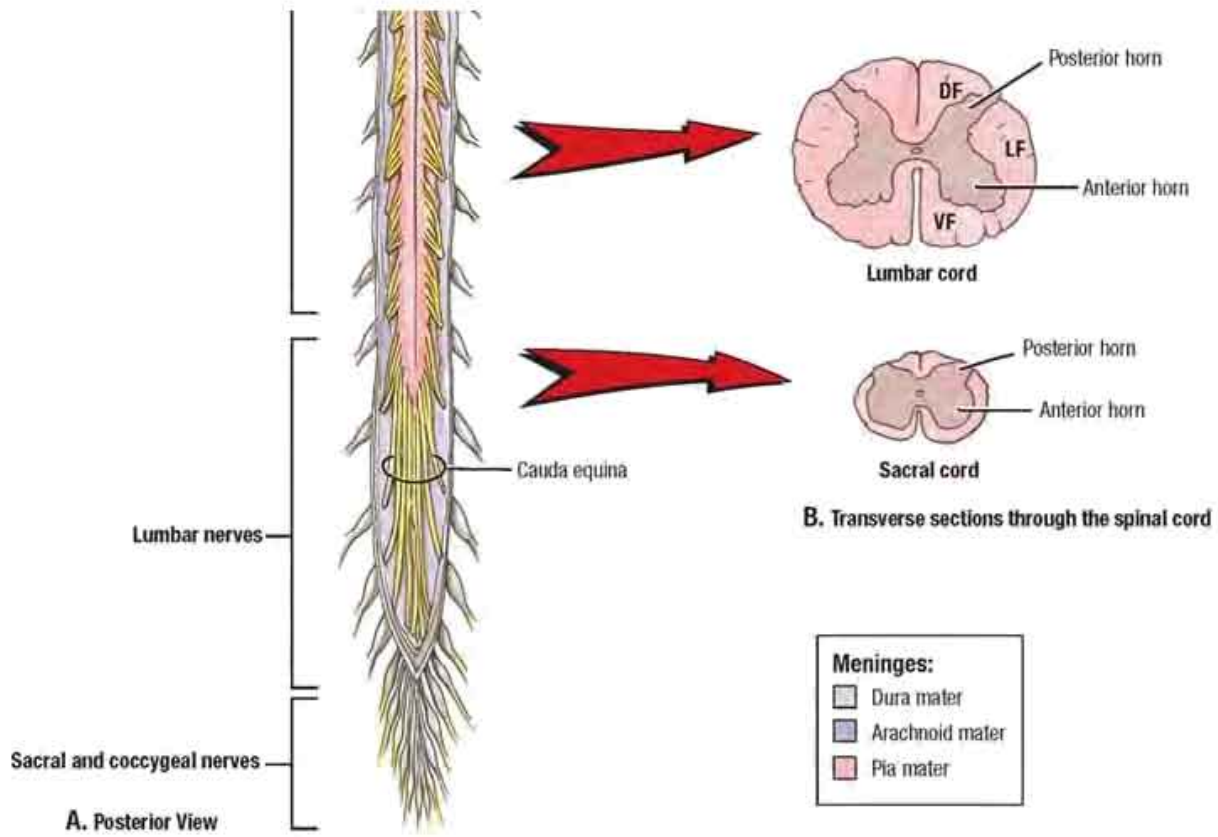
> Table of Contents > Chapter 4 - Back > 4.47 Isolated spinal cord and spinal nerve roots with coverings and regional sections

## 4.47 Isolated spinal cord and spinal nerve roots with coverings and regional sections

Part of "Chapter 4 - Back "

P.341





Authors: Agur, Anne M.R.; Dalley, Arthur F.

Title: *Grant's Atlas of Anatomy, 12th Edition*

Copyright ©2009 Lippincott Williams & Wilkins

> Table of Contents > Chapter 4 - Back > 4.48 Blood supply of spinal cord

---

## 4.48 Blood supply of spinal cord

*Part of* "Chapter 4 - Back "

A. Arteries of spinal cord. The segmental reinforcements of blood supply from the segmental medullary arteries are important in supplying blood to the anterior and posterior spinal arteries. Fractures, dislocations, and fracture-dislocations may interfere with the blood supply to the spinal cord from the spinal and medullary arteries. Deficiency of blood supply (ischemia) of the spinal cord affects its function and can lead to muscle weakness and paralysis. The spinal cord may also suffer circulatory impairment if the segmental medullary arteries, particularly the great anterior segmental medullary artery (of Adamkiewicz), are narrowed by obstructive arterial disease.

---

P.342

B. Arterial supply and venous drainage. C. Segmental medullary and radicular arteries. Three longitudinal arteries supply the spinal cord: an anterior spinal artery, formed by the union of branches of vertebral arteries, and paired posterior spinal arteries, each of which is a branch of either the vertebral artery or the posterior inferior cerebellar artery.

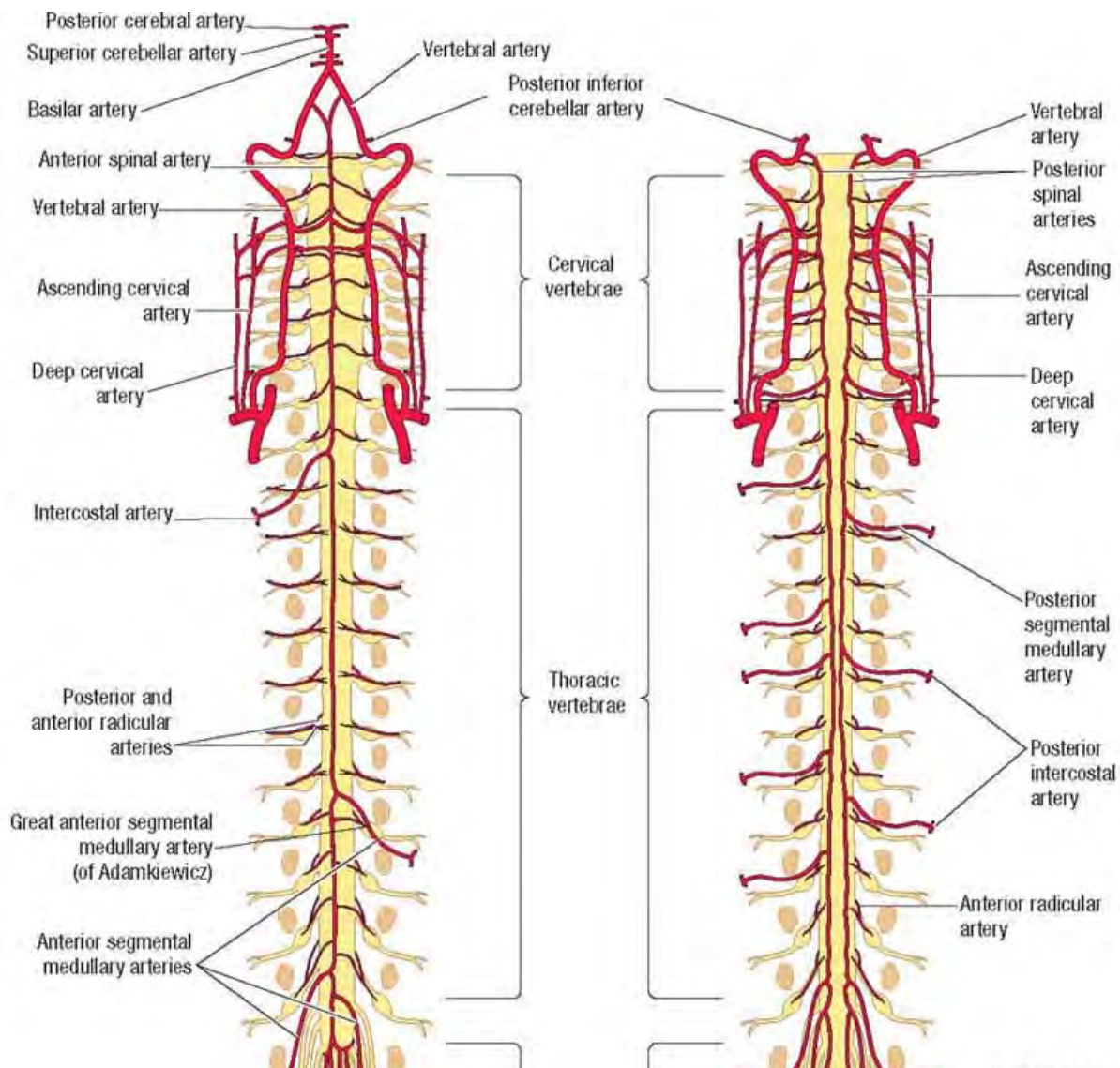
- The spinal arteries run longitudinally from the medulla oblongata of the brainstem to the conus medullaris of the spinal cord. By themselves, the anterior and posterior spinal arteries supply only the short superior part of the spinal cord. The circulation to much of the spinal cord depends on segmental medullary and radicular arteries.
- The anterior and posterior segmental medullary arteries enter the intervertebral foramen to unite with the spinal arteries to supply blood to the spinal cord. The great anterior segmented medullary artery (Adamkiewicz artery) occurs on the



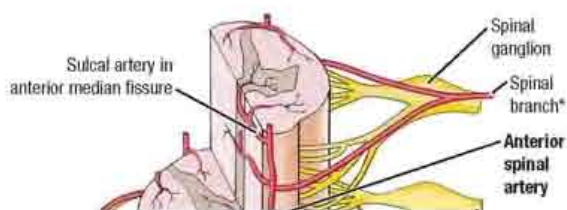
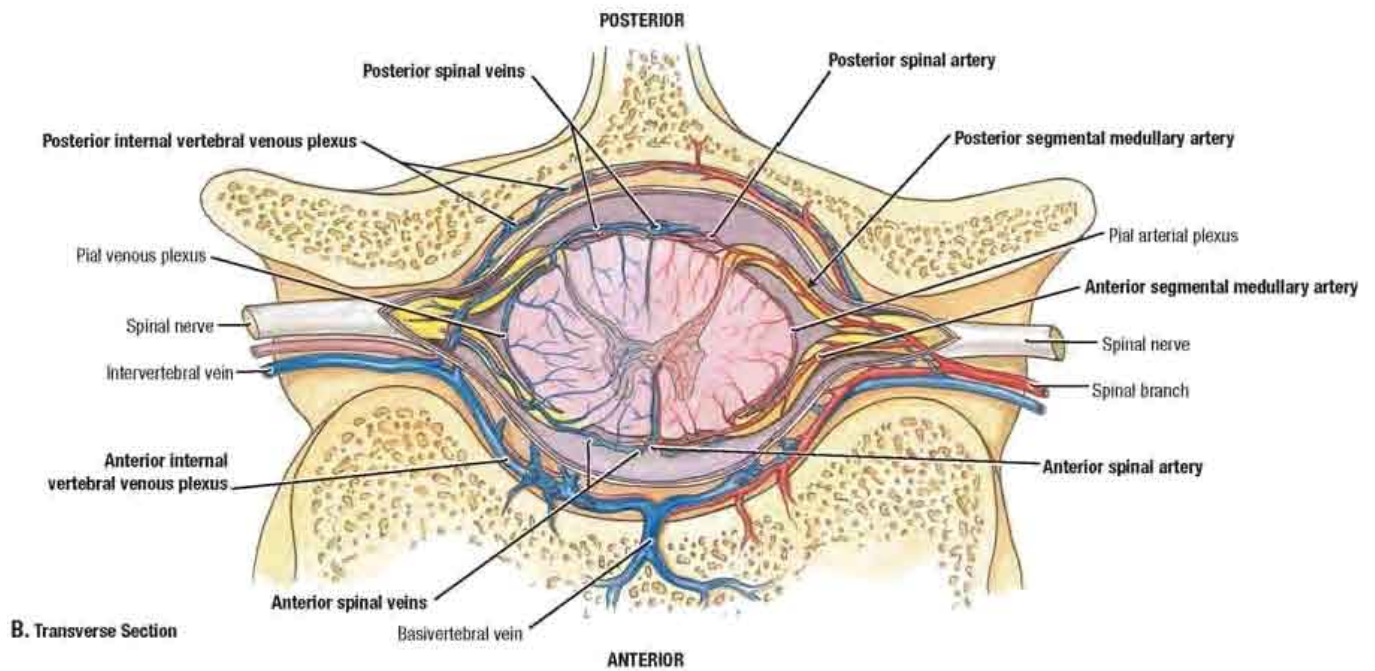
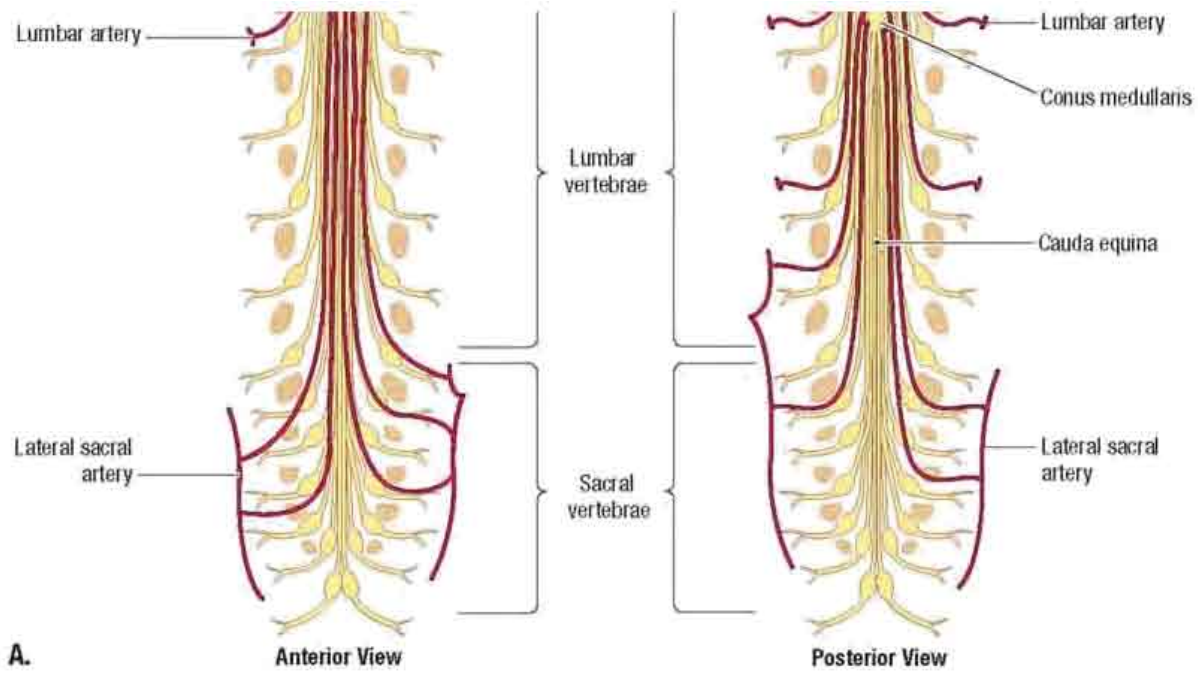
left side in 65% of people. It reinforces the circulation to two thirds of the spinal cord.

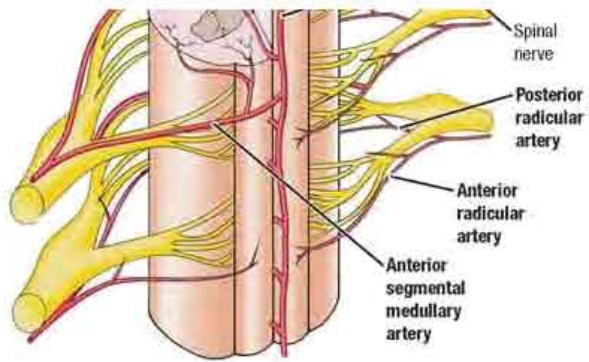
- Posterior and anterior roots of the spinal nerves and their coverings are supplied by posterior and anterior radicular arteries, which run along the nerve roots. These vessels do not reach the posterior or anterior spinal arteries.
- The 3 anterior and 3 posterior spinal veins are arranged longitudinally; they communicate freely with each other and are drained by up to 12 anterior and posterior medullary and radicular veins. The veins draining the spinal cord join the internal vertebral plexus in the epidural space.

P.343









\* Spinal branches arise from the vertebral, intercostal, lumbar, or sacral artery, depending on level of spinal cord.

### C. Anterolateral View

Authors: Agur, Anne M.R.; Dalley, Arthur F.

Title: *Grant's Atlas of Anatomy, 12th Edition*

Copyright ©2009 Lippincott Williams & Wilkins

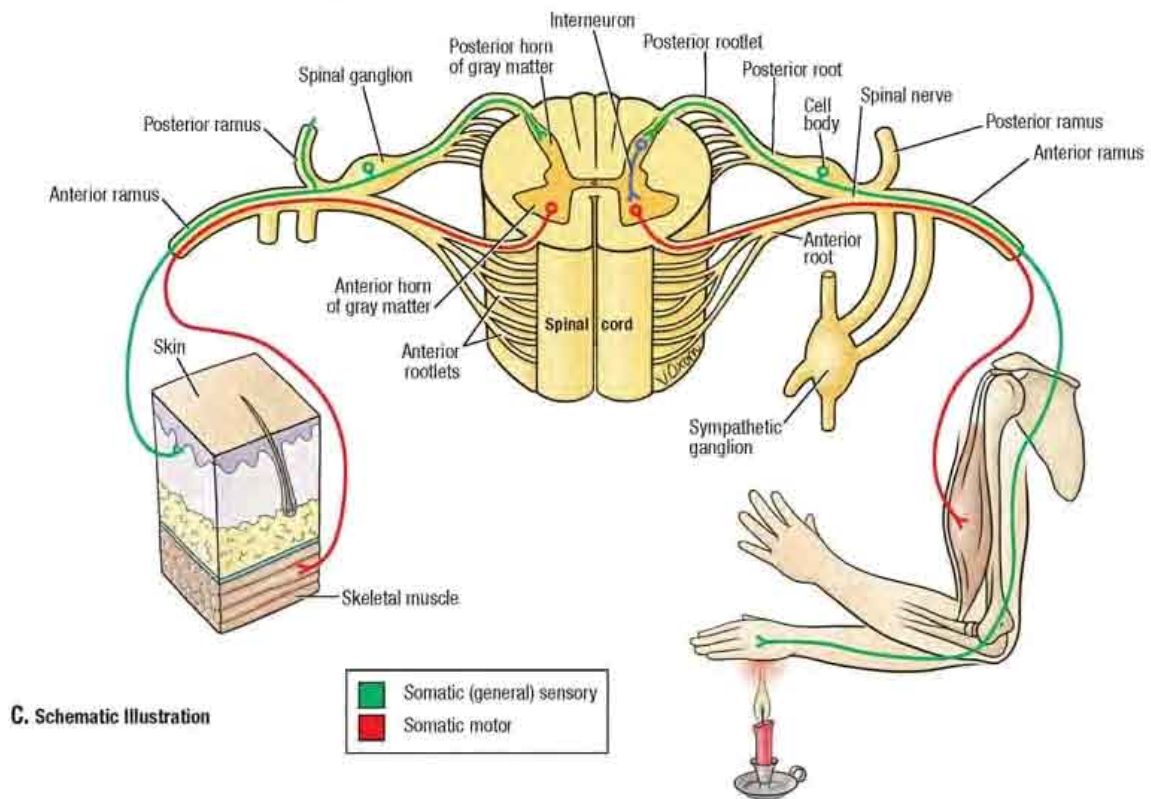
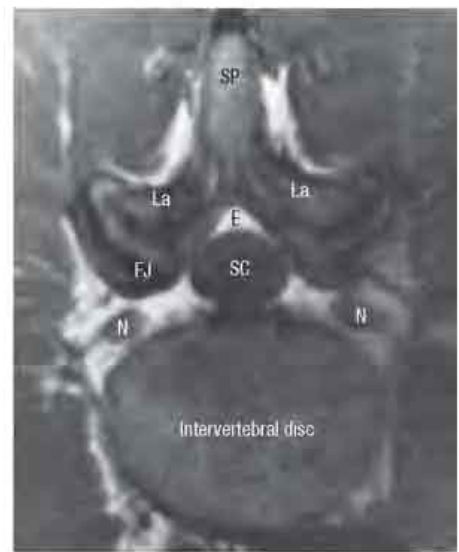
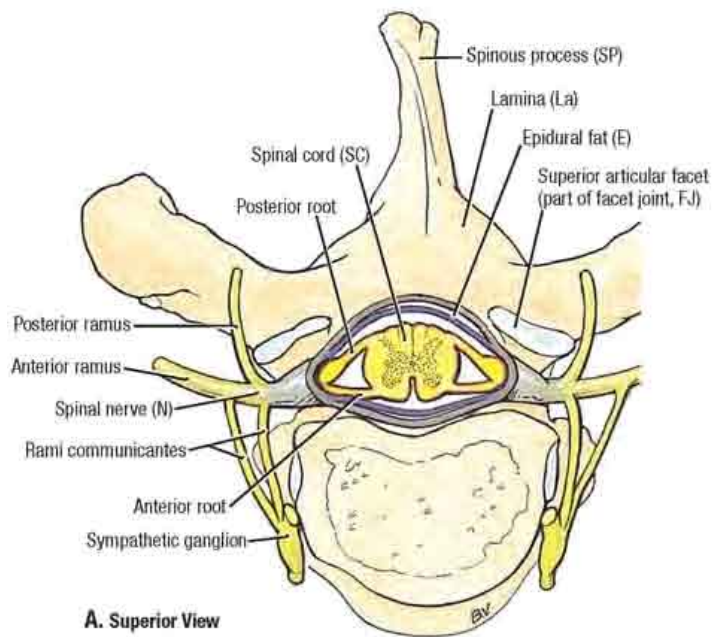
> Table of Contents > Chapter 4 - Back > 4.49 Overview of somatic nervous system

---

## 4.49 Overview of somatic nervous system

*Part of* "Chapter 4 - Back "

A. Spinal cord in situ in vertebral canal. B. T1 axial (transverse) MRI of lumbar spine. C. Components of typical spinal nerve. The somatic nervous system, or voluntary nervous system, composed of somatic parts of the CNS and PNS, provides general sensory and motor innervation to all parts of the body (G. *soma*), except the viscera in the body cavities, smooth muscle, and glands. The somatic (general) sensory fibers transmit sensations of touch, pain, temperature, and position from sensory receptors. The somatic motor fibers permit voluntary and reflexive movement by causing contraction of skeletal muscles, such as occurs when one touches a candle flame.



Authors: Agur, Anne M.R.; Dalley, Arthur F.

Title: *Grant's Atlas of Anatomy, 12th Edition*

Copyright ©2009 Lippincott Williams & Wilkins

> Table of Contents > Chapter 4 - Back > 4.50 Spinal cord and spinal nerves

---

## 4.50 Spinal cord and spinal nerves

Part of "Chapter 4 - Back "

A. Spinal cord at 12 weeks gestation. B. Spinal cord of an adult.

- Early in development, the spinal cord and vertebral (spinal) canal are nearly equal in length. The canal grows longer, so spinal nerves have an increasingly longer course to reach the intervertebral foramen at the correct level for their exit. The spinal cord of adults terminates between vertebral bodies L1–L2. The remaining spinal nerves, seeking their intervertebral foramen of exit, form the cauda equina.
- All 31 pairs of spinal nerves—8 cervical (C), 12 thoracic (T), 5 lumbar (L), 5 sacral (S), and 1 coccygeal (Co)—arise from the spinal cord and exit through the intervertebral foramina in the vertebral column.

---

P.345

C and D. Peripheral nerves.

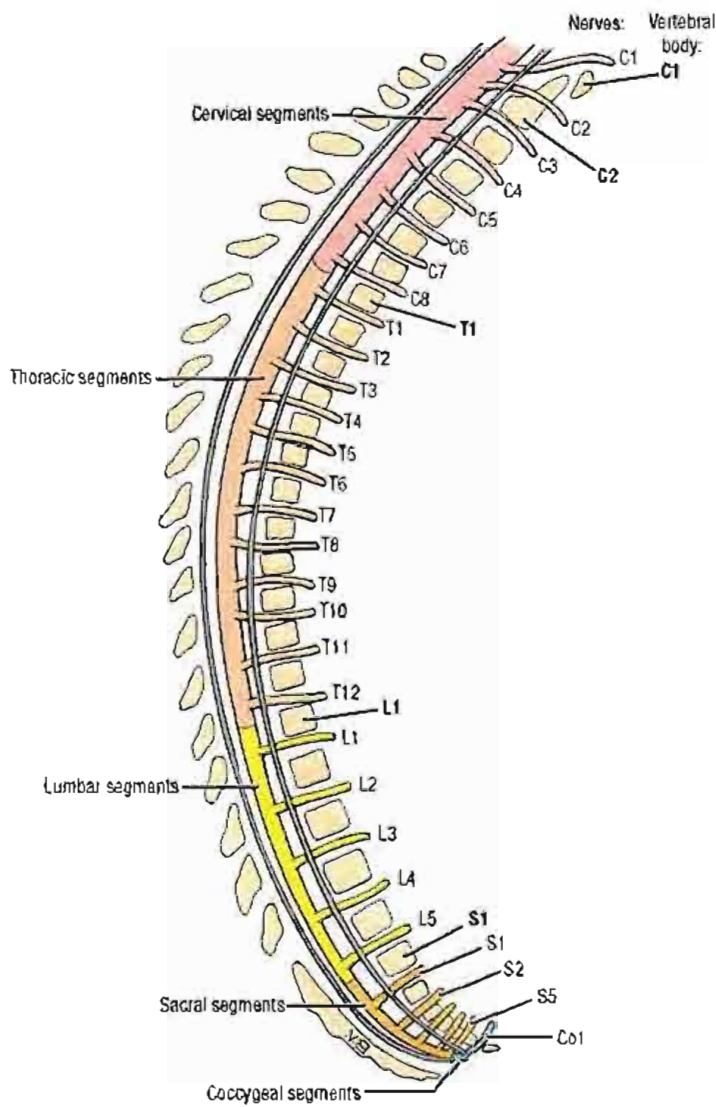
- The anterior rami supply nerve fibers to the anterior and lateral regions of the trunk and upper and lower limbs.
- The posterior rami supply nerve fibers to synovial joints of the vertebral column, deep muscles of the back, and overlying skin.

---

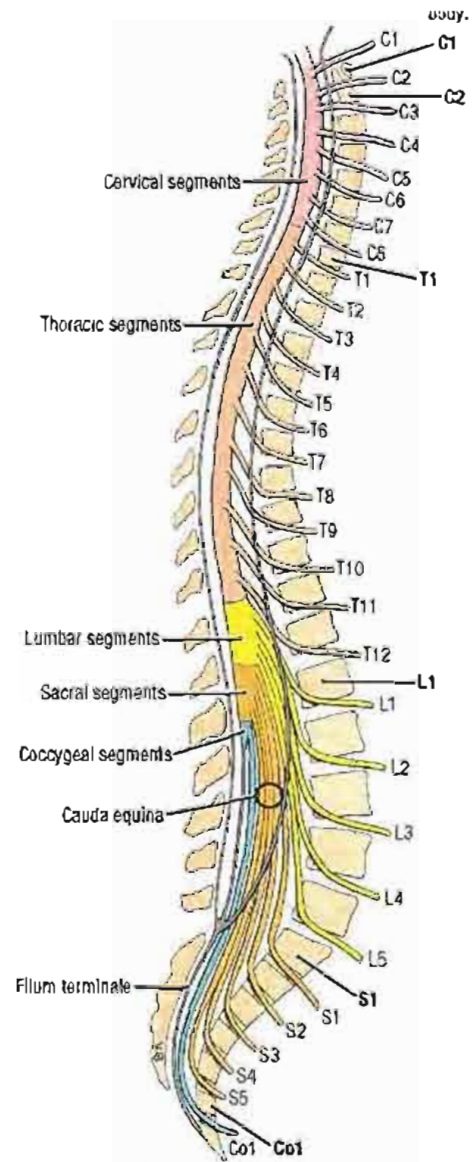
P.346

Nerves: Vertebral

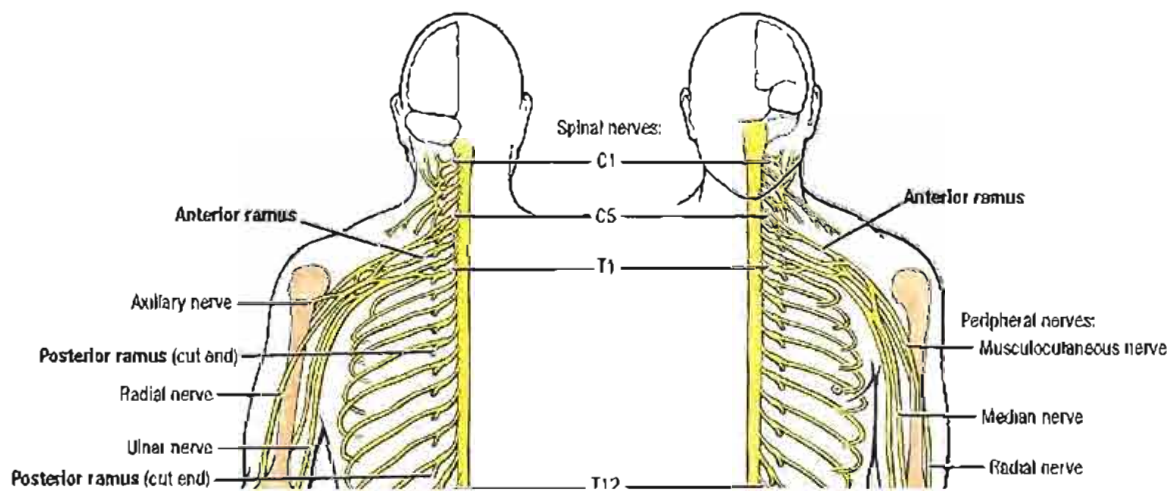


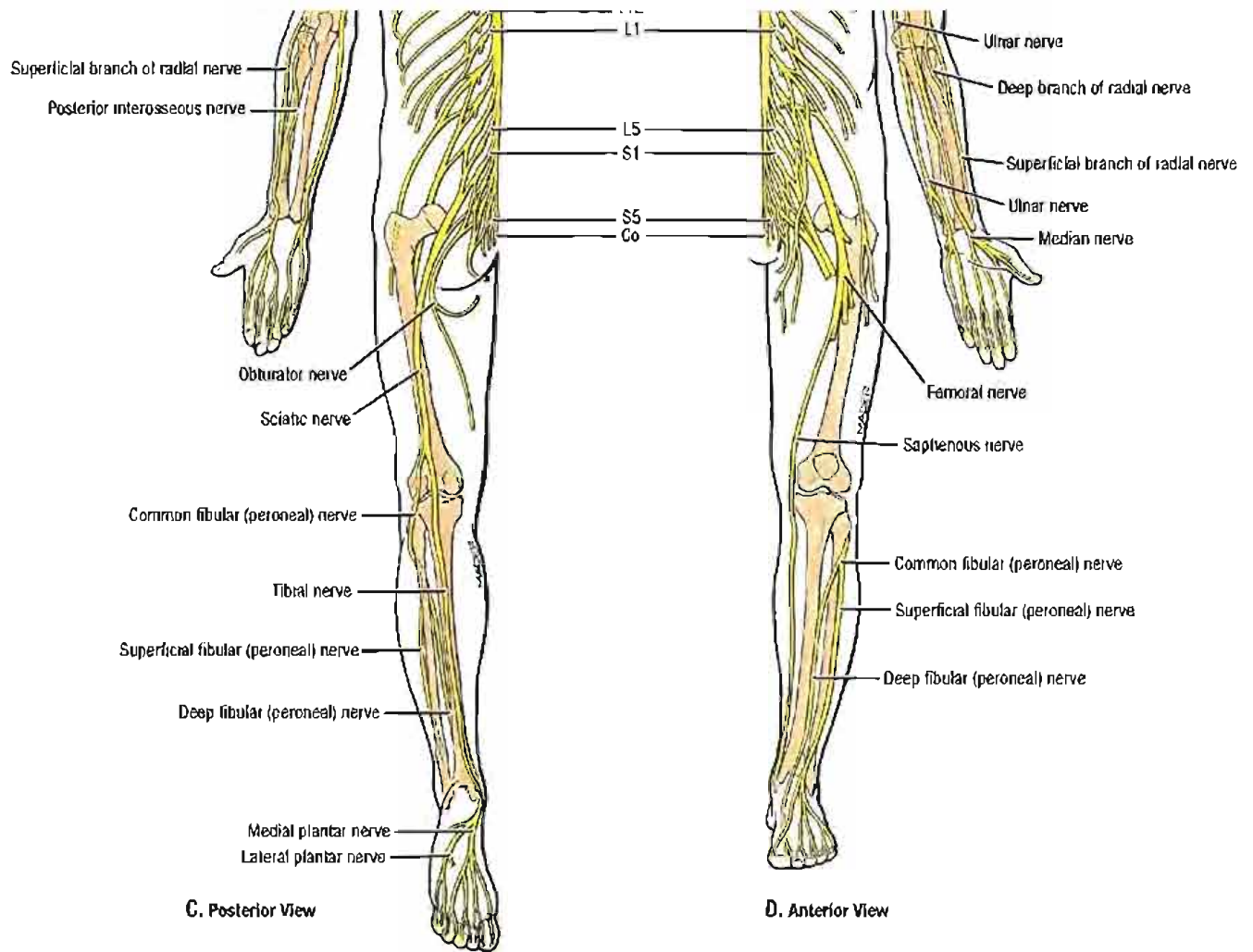


A. Sagittal Section



B. Sagittal Section





Authors: Agur, Anne M.R.; Dalley, Arthur F.

Title: *Grant's Atlas of Anatomy, 12th Edition*

Copyright ©2009 Lippincott Williams & Wilkins

> Table of Contents > Chapter 4 - Back > 4.51 Visceral afferent and visceral efferent (motor) innervation

---

## 4.51 Visceral afferent and visceral efferent (motor) innervation

*Part of* "Chapter 4 - Back "

A. Schematic illustration. Visceral afferent fibers have important relationships to the CNS, both anatomically and functionally. We are usually unaware of the sensory input of these fibers, which provides information about the condition of the body's internal environment. This information is integrated in the CNS, often triggering visceral or somatic reflexes or both. Visceral reflexes regulate blood pressure and chemistry by altering such functions as heart and respiratory rates and vascular resistance. Visceral sensation that reaches a conscious level is generally categorized as pain that is usually poorly localized and may be perceived as hunger or nausea. However, adequate stimulation may elicit true pain. Most visceral/reflex (unconscious) sensation and some pain travel in visceral afferent fibers that accompany the parasympathetic fibers retrograde. Most visceral pain impulses (from the heart and most organs of the peritoneal cavity) travel along visceral afferent fibers accompanying sympathetic fibers.

Visceral efferent (motor) innervation. The efferent nerve fibers and ganglia of the ANS are organized into two systems or divisions.

- Sympathetic (thoracolumbar) division. In general, the effects of sympathetic stimulation are catabolic (preparing the body for "fight or flight").
- Parasympathetic (craniosacral) division. In general, the effects of parasympathetic stimulation are anabolic (promoting normal function and

conserving energy).

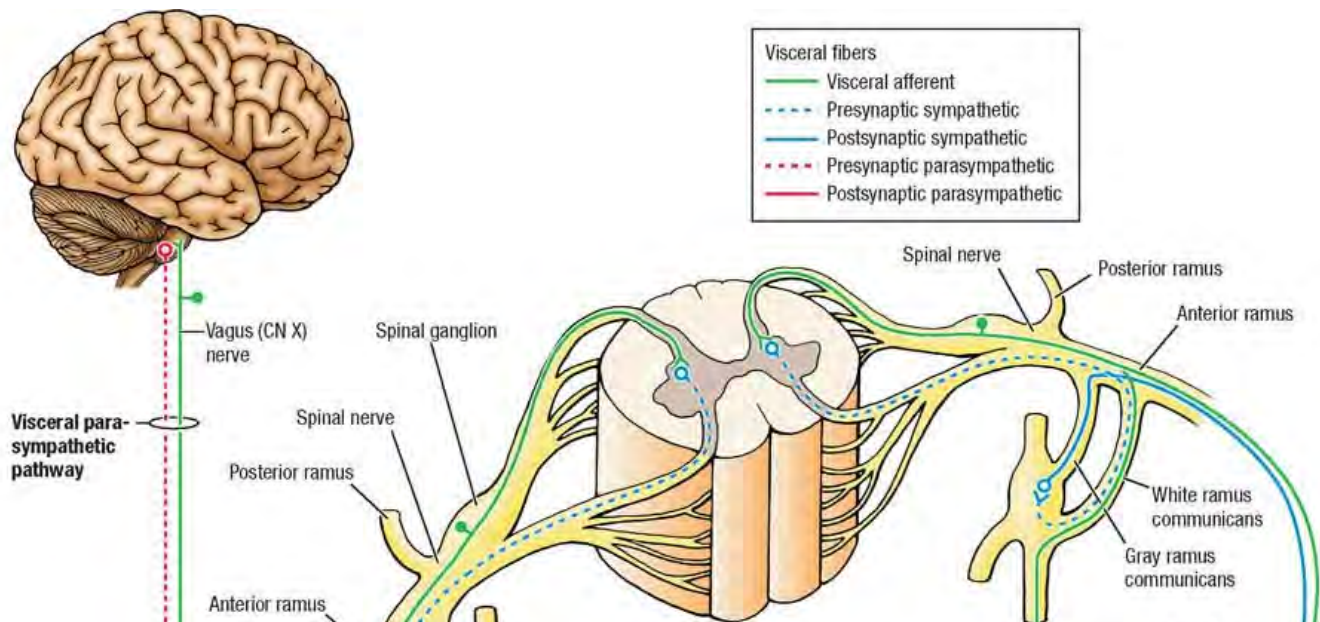
Conduction of impulses from the CNS to the effector organ involves a series of two neurons in both sympathetic and parasympathetic systems. The cell body of the presynaptic (preganglionic) neuron (first neuron) is located in the gray matter of the CNS. Its fiber (axon) synapses on the cell body of a postsynaptic (postganglionic) neuron, the second neuron in the series. The cell bodies of such second neurons are located in autonomic ganglia outside the CNS, and the postsynaptic fibers terminate on the effector organ (smooth muscle, modified cardiac muscle, or glands).

P.347

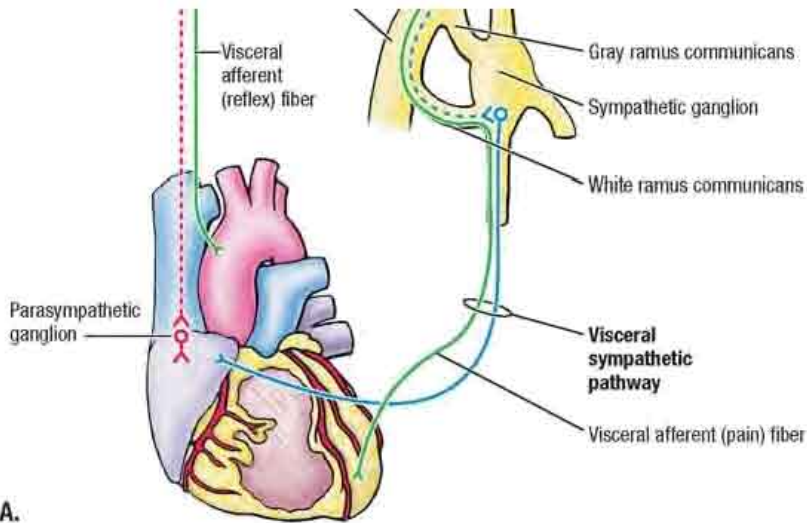
## B. Courses taken by sympathetic motor fibers

Presynaptic fibers all follow the same course until they reach the sympathetic trunks. In the sympathetic trunks, they follow one of four possible courses. Fibers involved in providing sympathetic innervation to the body wall and limbs or viscera above the level of the diaphragm follow paths 1–3. They synapse in the paravertebral ganglia of the sympathetic trunks. Fibers involved in innervating abdominopelvic viscera follow path 4 to prevertebral ganglion via abdominopelvic splanchnic nerves.

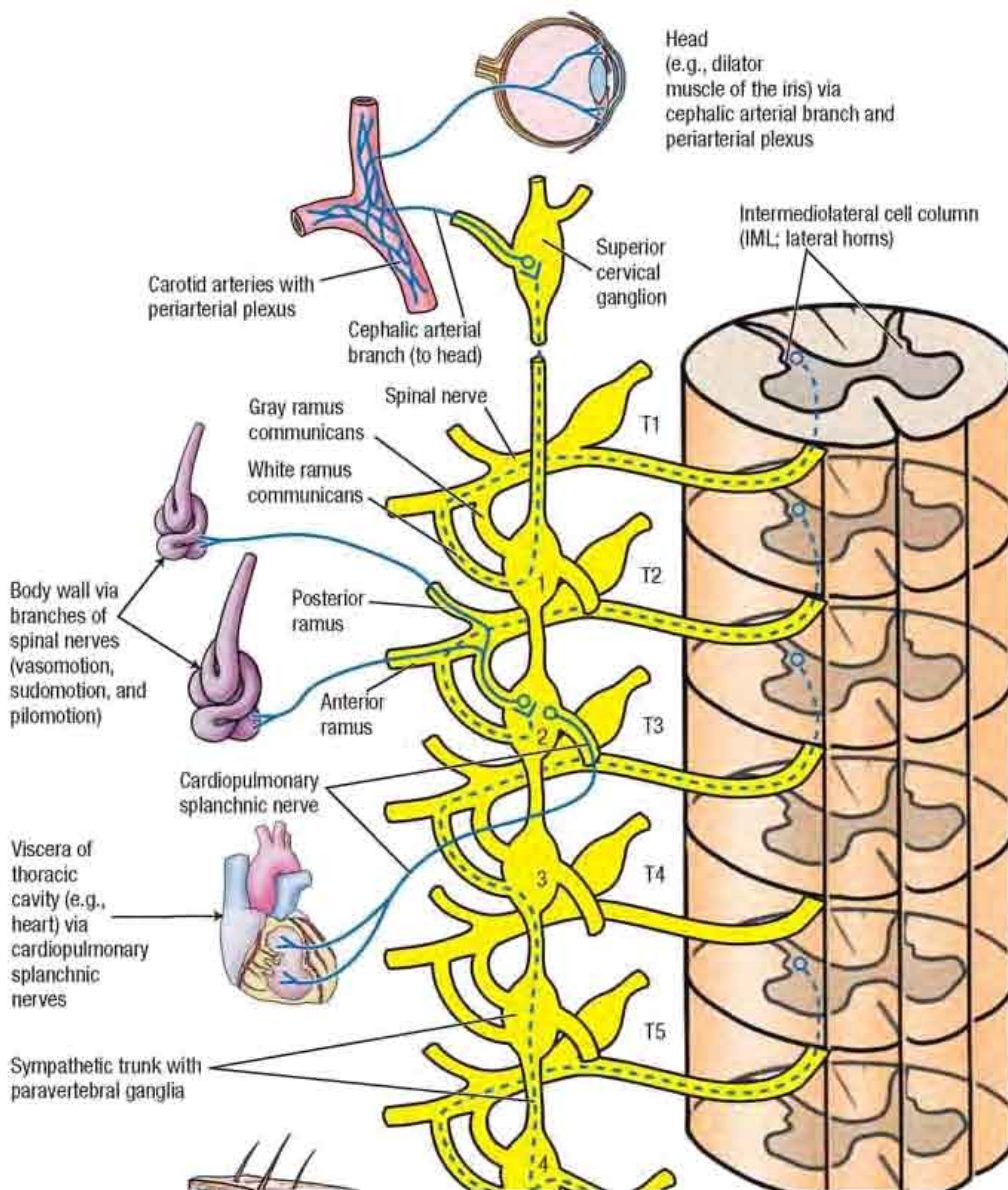
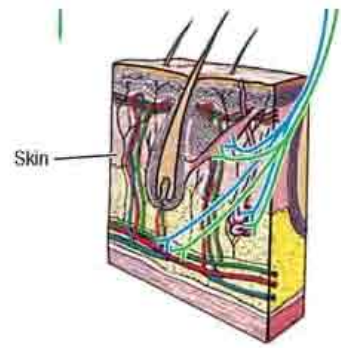
P.348







A.



Sympathetic nerve fibers

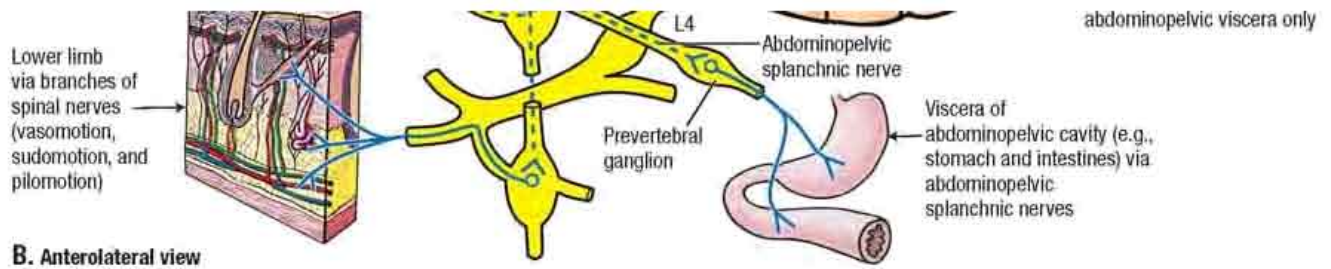
--- Presynaptic

— Postsynaptic

**Courses taken by presynaptic sympathetic fibers within the sympathetic trunks:**

- 1. Ascend and then synapse**  
for innervation of head, when cervical cardiopulmonary splanchnic nerves are involved, or when spinal nerves involved are superior to the part of the IML involved (e.g., innervation of neck and upper limb)
- 2. Synapse at level of entry**  
when thoracic cardiopulmonary splanchnic nerves are involved, or when spinal nerves involved are at approximately the same level as the part of the IML involved (e.g., innervation of middle trunk)
- 3. Descend and then synapse**  
when spinal nerves involved are inferior to the part of the IML involved (e.g., innervation of lower limb)
- 4. Pass through sympathetic trunk without synapsing to enter an abdominopelvic splanchnic nerve**  
for innervation of





Authors: Agur, Anne M.R.; Dalley, Arthur F.

Title: *Grant's Atlas of Anatomy, 12th Edition*

Copyright ©2009 Lippincott Williams & Wilkins

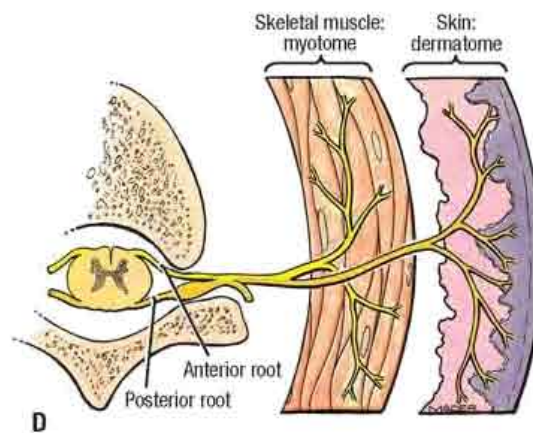
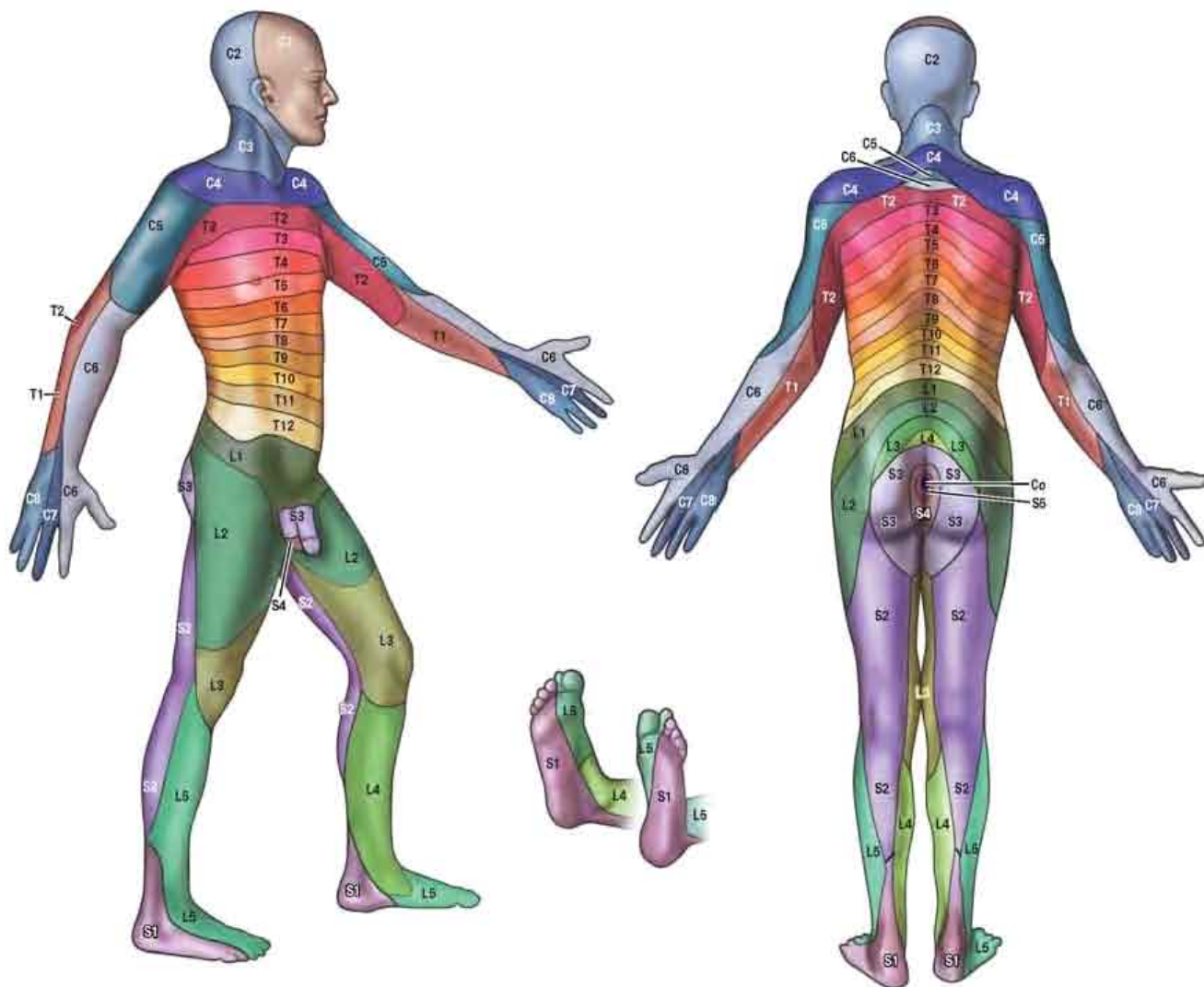
> Table of Contents > Chapter 4 - Back > 4.52 Dermatomes

---

## 4.52 Dermatomes

*Part of* "Chapter 4 - Back "

A€" C. Dermatome map (Foerster, 1933). The Keegan and Garrett (1948) dermatome map is not included here. The two schemes are similar in the trunk but differ in the limbs, where both are presented. D. Schematic illustration of a dermatome and myotome. The unilateral area of skin innervated by the general sensory fibers of a single spinal nerve is called a dermatome. From clinical studies of lesions in the posterior roots or spinal nerves, dermatome maps have been devised that indicate the typical patterns of innervation of the skin by specific spinal nerves.



Authors: Agur, Anne M.R.; Dalley, Arthur F.

Title: *Grant's Atlas of Anatomy, 12th Edition*

Copyright ©2009 Lippincott Williams & Wilkins

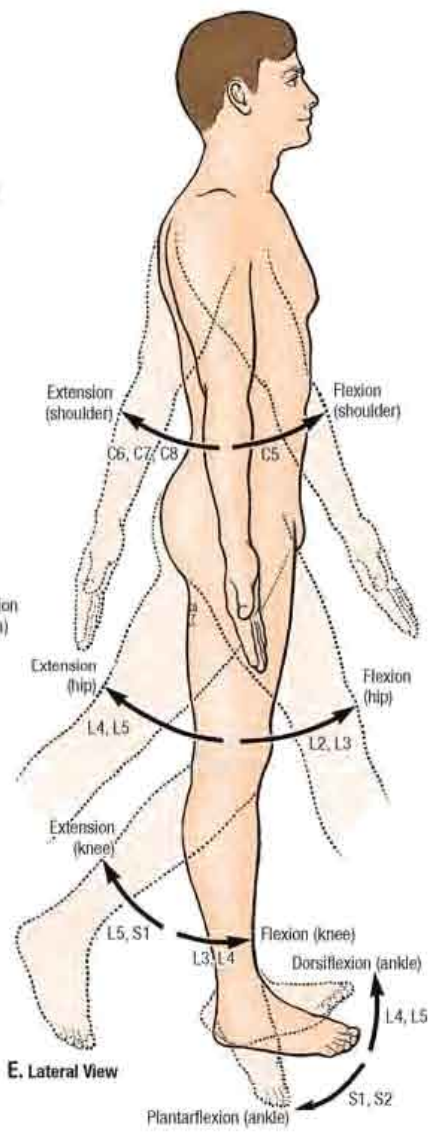
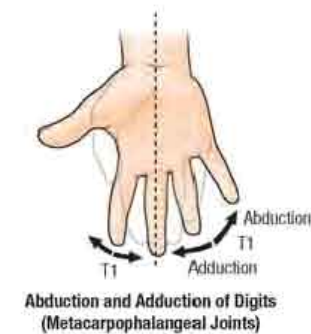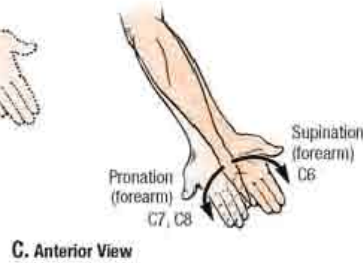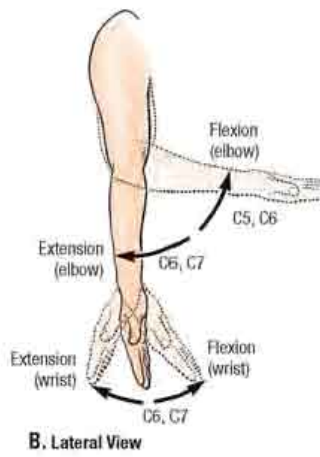
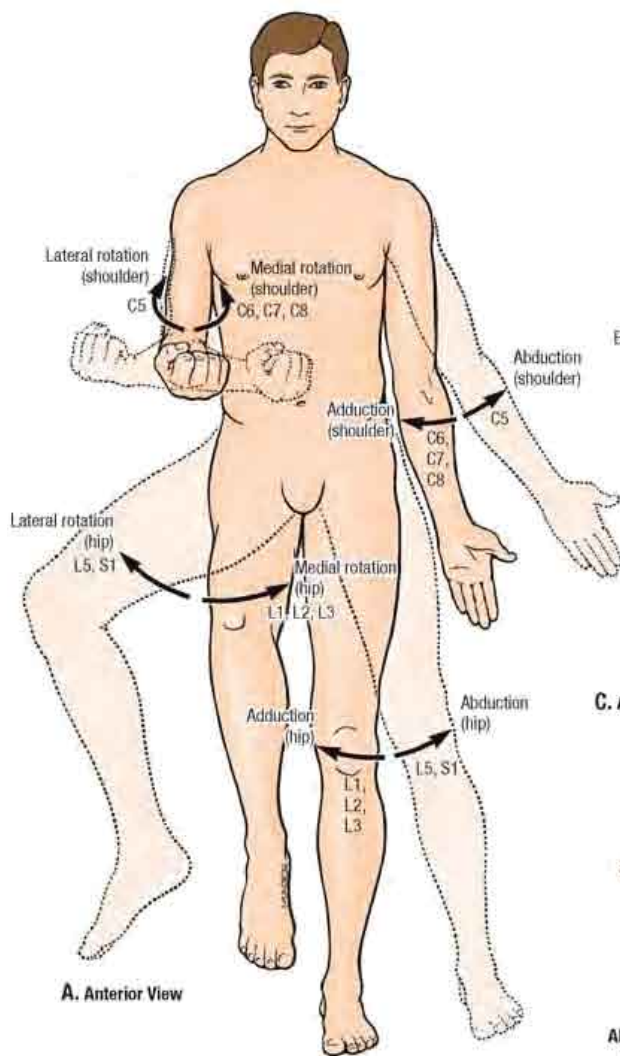
> Table of Contents > Chapter 4 - Back > 4.53 Myotomes

---

## 4.53 Myotomes

*Part of* "Chapter 4 - Back "

Somatic motor (general somatic efferent) fibers transmit impulses to skeletal (voluntary) muscles. The unilateral muscle mass receiving innervation from the somatic motor fibers conveyed by a single spinal nerve is a myotome. Each skeletal muscle is innervated by the somatic motor fibers of several spinal nerves; therefore, the muscle myotome will consist of several segments. The muscle myotomes have been grouped by joint movement to facilitate clinical testing. The intrinsic muscles of the hand constitute a single myotome—T1.





Authors: Agur, Anne M.R.; Dalley, Arthur F.

Title: *Grant's Atlas of Anatomy, 12th Edition*

Copyright ©2009 Lippincott Williams & Wilkins

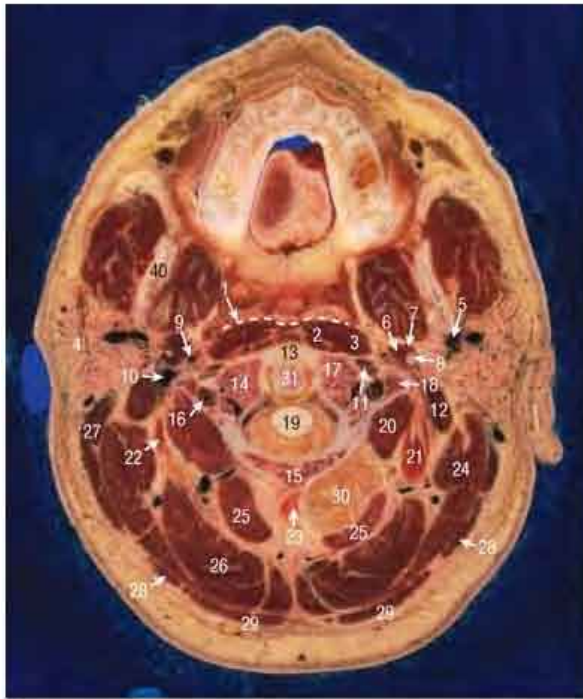
> Table of Contents > Chapter 4 - Back > 4.54 Imaging of superior nuchal region at the level of the atlas

---

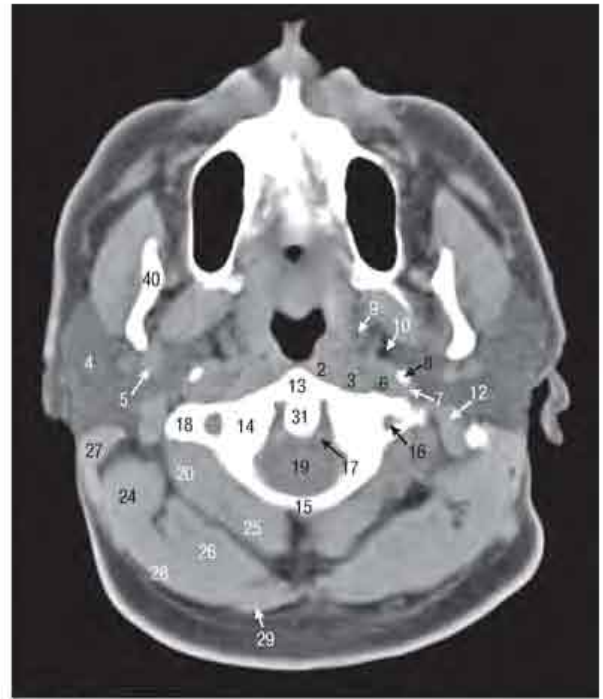
## 4.54 Imaging of superior nuchal region at the level of the atlas

*Part of* "Chapter 4 - Back "

A. Transverse section of specimen. B. Transverse computed tomographic (CT) scan. C. Three-dimensional (3D) CT of the base of the skull and atlas.

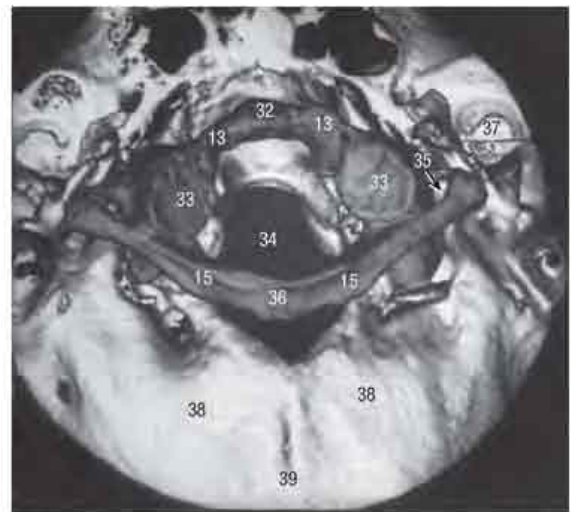
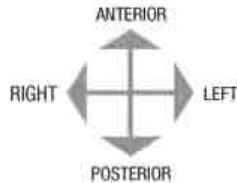


A. Inferior View



B. Inferior View

- 1 Site of retropharyngeal space
- 2 Longus colli
- 3 Longus capitis
- 4 Parotid gland
- 5 Retromandibular vein
- 6 Stylopharyngeus
- 7 Styloglossus
- 8 Stylohyoid muscle and ligament/process
- 9 Internal carotid artery
- 10 Internal jugular vein
- 11 Rectus capitis lateralis
- 12 Posterior belly of digastric
- 13 Anterior arch of atlas (C1)
- 14 Lateral mass of atlas (C1)
- 15 Posterior arch of atlas (C1)
- 16 Vertebral artery
- 17 Transverse ligament of atlas (C1)
- 18 Transverse process of atlas (C1)
- 19 Spinal cord
- 20 Rectus capitis posterior major
- 21 Obliquus capitis inferior
- 22 Obliquus capitis superior
- 23 Spinous process of atlas (C1)
- 24 Longissimus capitis
- 25 Rectus capitis posterior minor
- 26 Semispinalis capitis
- 27 Sternocleidomastoid
- 28 Splenius capitis
- 29 Trapezius
- 30 Fatty mass
- 31 Dens of axis (C2)
- 32 Anterior tubercle of atlas (C1)
- 33 Inferior articular facet of atlas (C1)
- 34 Foramen magnum
- 35 Foramen transversarium
- 36 Posterior tubercle of atlas (C1)
- 37 Mastoid process
- 38 Occipital bone of skull
- 39 External occipital protuberance
- 40 Ramus of mandible



C. Posteroinferior View

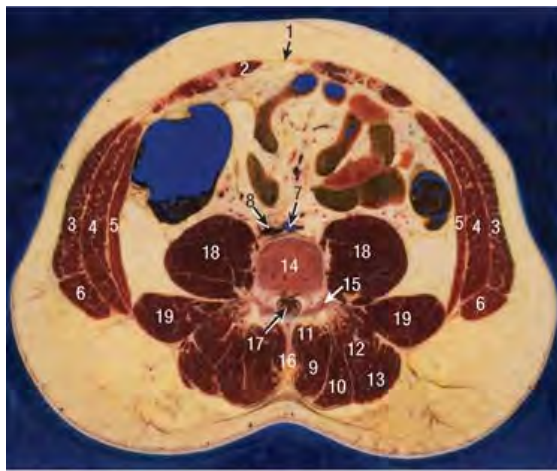
Authors: Agur, Anne M.R.; Dalley, Arthur F.  
 Title: *Grant's Atlas of Anatomy, 12th Edition*  
 Copyright ©2009 Lippincott Williams & Wilkins

> Table of Contents > Chapter 4 - Back > 4.55 Imaging of lumbar spine at L4

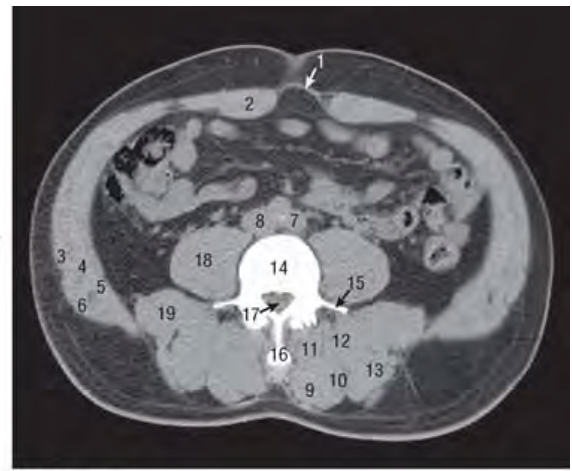
## 4.55 Imaging of lumbar spine at L4

Part of "Chapter 4 - Back "

A. Transverse section of specimen. B. Transverse computed tomographic (CT) scan.



A. Inferior View



B. Inferior View

1	Linea alba	6	Latissimus dorsi	11	Multifidus	16	Spinous process
2	Rectus abdominis	7	Descending aorta	12	Rotatores	17	Cauda equina
3	External oblique	8	Inferior vena cava	13	Iliocostalis	18	Psoas major
4	Internal oblique	9	Spinalis	14	4th lumbar vertebra	19	Quadratus lumborum
5	Transversus abdominis	10	Longissimus	15	Transverse process		

Authors: Agur, Anne M.R.; Dalley, Arthur F.  
 Title: *Grant's Atlas of Anatomy, 12th Edition*  
 Copyright ©2009 Lippincott Williams & Wilkins

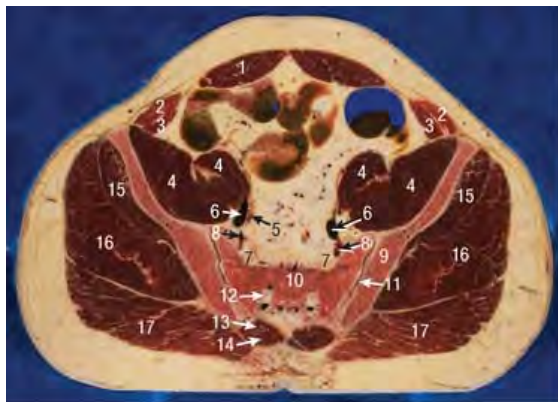
> Table of Contents > Chapter 4 - Back > 4.56 Imaging of sacro-iliac joint

## 4.56 Imaging of sacro-iliac joint

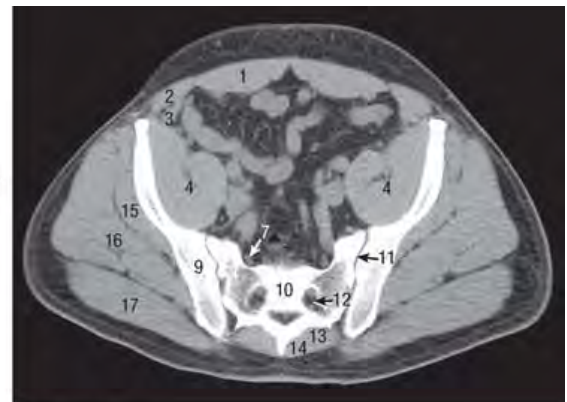
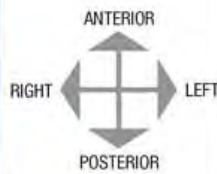
Part of "Chapter 4 - Back "

A. Transverse section of specimen. B. Transverse computed tomographic (CT) scan.

P.352



A. Inferior View



B. Inferior View

1 Rectus abdominis	6 Internal iliac vein	10 2nd sacral vertebra	14 Erector spinae
2 External oblique	7 Anterior rami	11 Sacro-iliac joint	15 Gluteus minimus
3 Internal oblique	8 Superior gluteal vessels	12 Sacral nerve root	16 Gluteus medius
4 Iliopsoas	9 Body of ilium	13 Multifidus	17 Gluteus maximus
5 Internal iliac artery			

Authors: Agur, Anne M.R.; Dalley, Arthur F.

Title: *Grant's Atlas of Anatomy, 12th Edition*

Copyright ©2009 Lippincott Williams & Wilkins

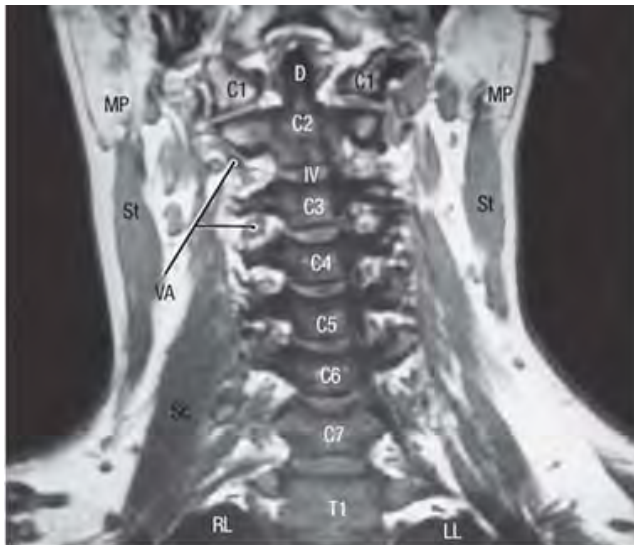
> Table of Contents > Chapter 4 - Back > 4.57 Coronal MRI scans of cervical and thoracic spine

---

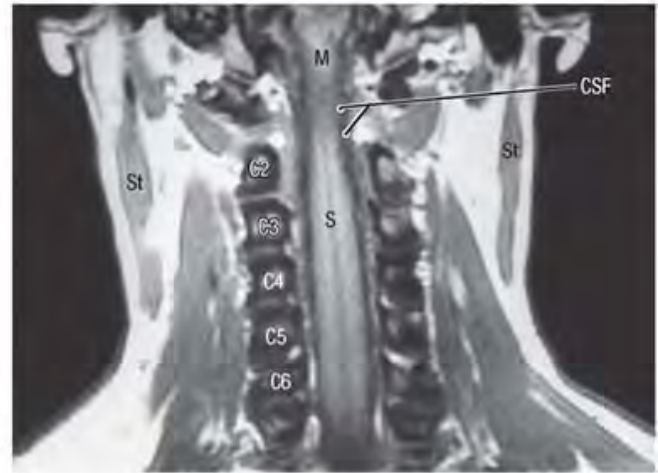
## 4.57 Coronal MRI scans of cervical and thoracic spine

*Part of* "Chapter 4 - Back "

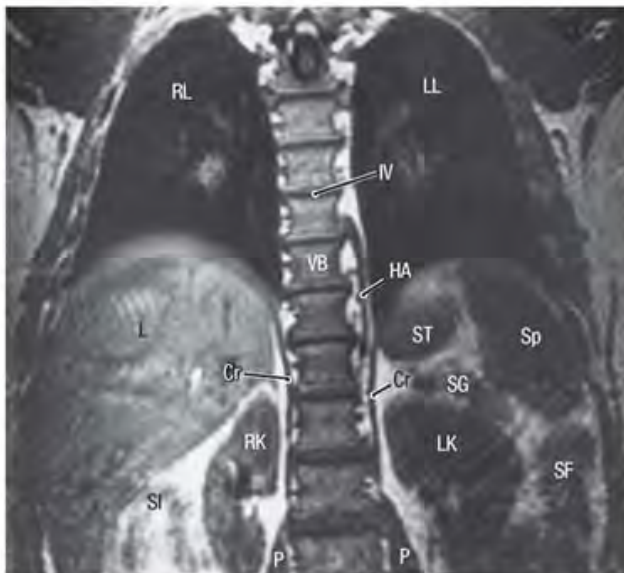



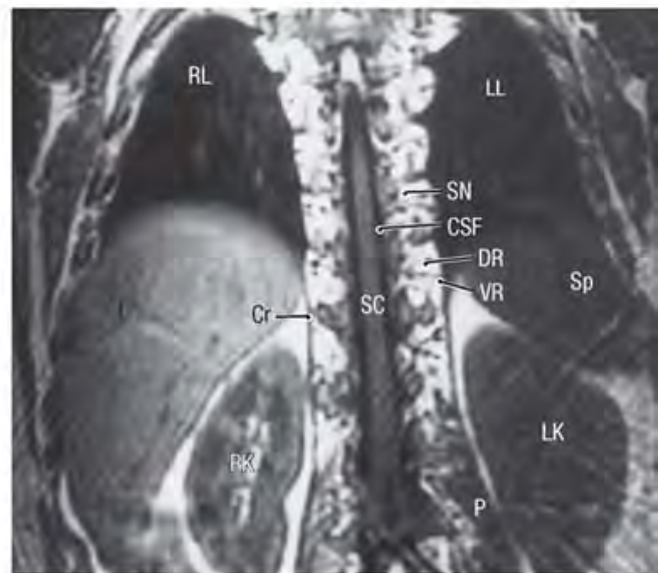
A.



B.



C.



D.

C1-T1 Vertebrae	LL Left lung	SI Small intestine
Cr Crus of diaphragm	M Medulla oblongata	SN Spinal nerve
CSF Cerebrospinal fluid in subarachnoid space	MP Mastoid process	Sp Spleen
D Dens (odontoid) process of C2	P Psoas muscle	St Sternocleidomastoid
DR Posterior ramus	RK Right kidney	ST Stomach
HA Hemiazygos vein	RL Right lung	VA Vertebral artery
IV Intervertebral disc	S Spinal cord	VR Anterior ramus
L Liver	SF Splenic flexure	
LK Left kidney	SG Suprarenal gland	

A and B. Cervical spine. C and D. Thoracic spine.

Authors: Agur, Anne M.R.; Dalley, Arthur F.

Title: *Grant's Atlas of Anatomy, 12th Edition*

Copyright ©2009 Lippincott Williams & Wilkins

> Table of Contents > Chapter 5 - Lower Limb > Chapter 5 - Lower Limb

---

# Chapter 5

## Lower Limb

- 5.1 Regions, bones, and major joints of lower limb
- 5.2 Features of bones of lower limb
- 5.3 Overview of motor innervation of lower limb
- 5.4 Myotomes and deep tendon reflexes
- 5.5 Cutaneous nerves of lower limb
- 5.6 Rotation of limbs during development; effect on lower limb dermatome pattern
- 5.7 Dermatomes of lower limb
- 5.8 Overview of arteries of lower limb
- 5.9 Deep veins of lower limb
- 5.10 Superficial veins of lower limb
- 5.11 Drainage and surface anatomy of superficial veins of lower limb
- 5.12 Superficial lymphatic drainage of lower limb
- 5.13 Inguinal lymph nodes
- 5.14 Fascia and musculofascial compartments of lower limb
- 5.15 Superficial inguinal vessels and saphenous opening

- 5.16 Femoral sheath and inguinal ligament
- 5.17 Structures passing to/from femoral triangle via retroinguinal passage
- 5.18 Floor of femoral canal and retroinguinal passage
- 5.19 Surface anatomy of anterior and medial aspects of thigh
- 5.20 Anterior and medial thigh muscles
- Table 5.2 Anterior and medial thigh muscles, in situ.
- 5.21 Muscles of medial aspect of thigh
- 5.22 Bones of the thigh and proximal leg
- 5.23 Anteromedial aspect of thigh
- 5.24 Lateral aspect of thigh
- 5.25 Muscles of the gluteal region and posterior aspect of thighâ€”I
- 5.26 Muscles of gluteal region and posterior aspect of thighâ€”IV
- 5.27 Muscles of gluteal region and posterior aspect of thighâ€”V
- 5.28 Lateral rotators of hip, sciatic nerve, and ligaments of gluteal region
- 5.29 Hip joint
- 5.30 Acetabular region
- 5.31 Hip bone
- 5.32 Radiograph and coronal section of hip joint
- 5.33 Transverse section through thigh at level of hip joint
- 5.34 Blood supply to head of femur
- 5.35 Blood vessels of acetabular fossa and ligament of head of femur
- 5.36 Popliteal fossa
- 5.37 Nerves of popliteal fossa
- 5.38 Deep dissection of popliteal fossa

- 5.39 Attachment of muscles of popliteal region
- 5.40 Anterior aspect of knee
- 5.41 Medial aspect of knee
- 5.42 Lateral aspect of knee
- 5.43 Fibrous layer and synovial membrane of joint capsule
- 5.44 Articular surfaces and ligaments of knee joint
- 5.45 Ligaments of knee joint
- 5.46 Cruciate ligaments and menisci
- 5.47 Articularis genu and suprapatellar bursa
- 5.48 Anastomoses around knee
- 5.49 Imaging of the knee and patellofemoral articulation
- 5.50 Coronal section and MRIs of knee
- 5.51 Radiograph of knee
- 5.52 Sagittal section and MRIs of knee
- 5.53 Anterior leg "superficial muscles
- 5.54 Anterior leg "deep muscles, nerves and vessels
- 5.55 Dorsum of foot
- 5.56 Attachments of muscles and arteries of the dorsum of foot
- 5.57 Muscles of lateral aspect of leg and foot
- 5.58 Synovial sheaths and tendons at ankle
- 5.59 Bones of the posterior aspect of leg
- 5.60 Posterior leg, superficial muscles of posterior compartment
- 5.61 Posterior leg, deep muscles of posterior compartment
- 5.62 Medial ankle region

- 5.63 Medial ankle and foot
- 5.64 Popliteal arteriogram and arterial anomalies
- 5.65 Superior tibiofibular joint and tibiofibular syndesmosis
- 5.66 Sole of foot, superficial
- 5.67 First layer of muscles of sole of foot
- 5.68 Second layer of muscles of sole of foot
- 5.69 Third layer of muscles and arterial supply of sole of foot
- 5.70 Fourth layer of muscles of sole of foot
- 5.71 Joint cavity of ankle joint
- 5.72 Ankle joint and ligaments of dorsum of foot
- 5.73 Posterior aspect of ankle joint
- 5.74 Posteromedial ankle
- 5.75 Medial ligaments of ankle region
- 5.76 Radiographs of ankle and foot
- 5.77 Lateral ligaments of ankle region
- 5.78 Articular surfaces of ankle joint
- 5.79 Coronal section and MRI through ankle
- 5.80 Transverse section and MRI through ankle
- 5.81 Joints of inversion and eversion
- 5.82 Talocalcaneal joint
- 5.83 Transverse tarsal joint
- 5.84 Cuneonavicular, cubonavicular, and tarsometatarsal joints
- 5.85 Metatarsophalangeal joint of great toe
- 5.86 Ligaments of sole of foot



- 5.87 Arches of foot
- 5.88 Bony anomalies
- 5.89 Postnatal lower limb development
- 5.90 Transverse sections and MRIs of thigh
- 5.91 Transverse sections and MRI of leg

Authors: Agur, Anne M.R.; Dalley, Arthur F.

Title: *Grant's Atlas of Anatomy, 12th Edition*

Copyright ©2009 Lippincott Williams & Wilkins

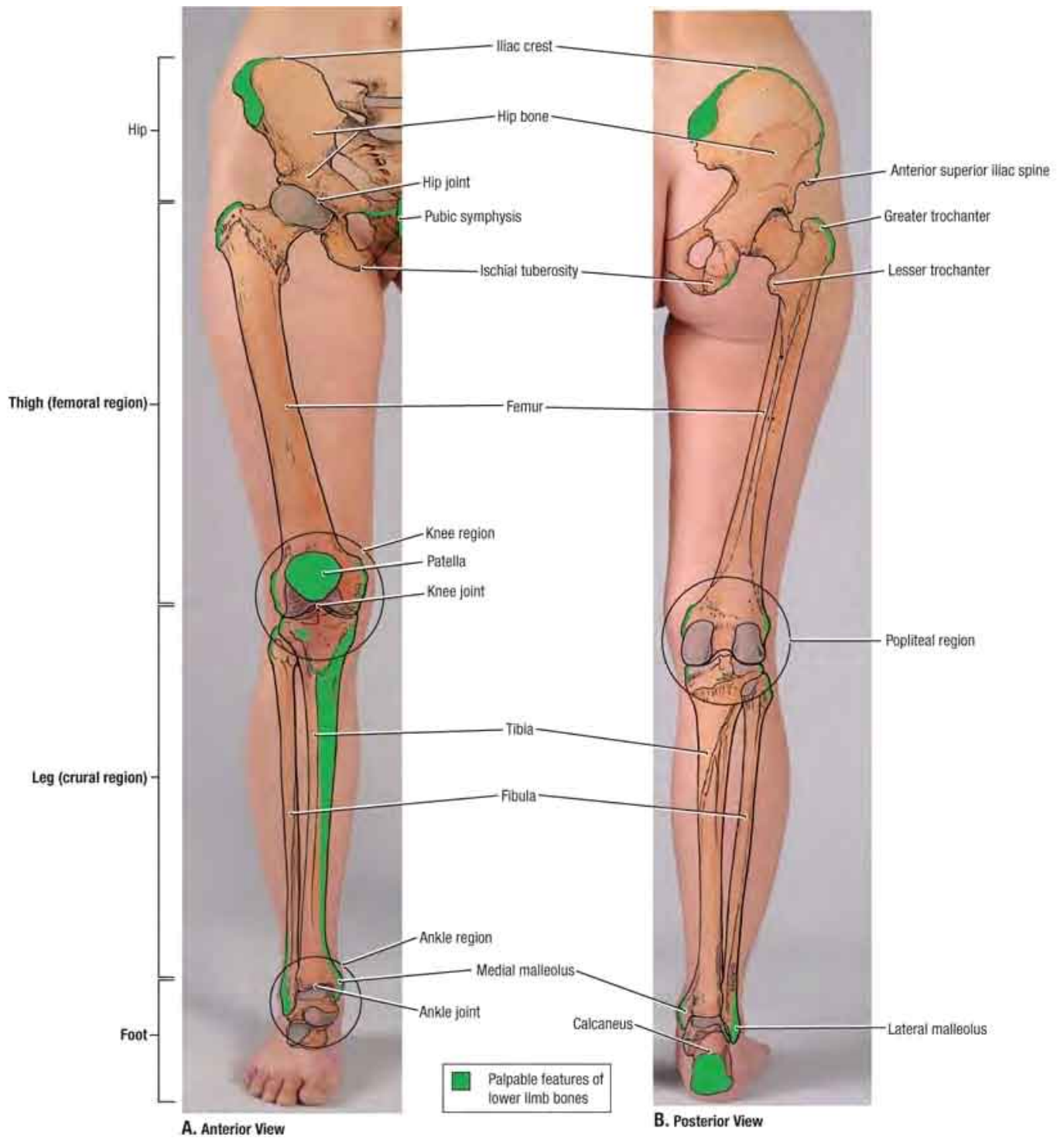
> Table of Contents > Chapter 5 - Lower Limb > 5.1 Regions, bones, and major joints of lower limb

---

## 5.1 Regions, bones, and major joints of lower limb

*Part of* "Chapter 5 - Lower Limb "

The hip bones meet anteriorly at the symphysis pubis and articulate with the sacrum posteriorly. The femur articulates with the hip bone proximally and the tibia distally. The tibia and fibula are the bones of the leg that join the foot at the ankle.



Authors: Agur, Anne M.R.; Dalley, Arthur F.

Title: *Grant's Atlas of Anatomy, 12th Edition*

Copyright ©2009 Lippincott Williams & Wilkins

> Table of Contents > Chapter 5 - Lower Limb > 5.2 Features of bones of lower limb

---

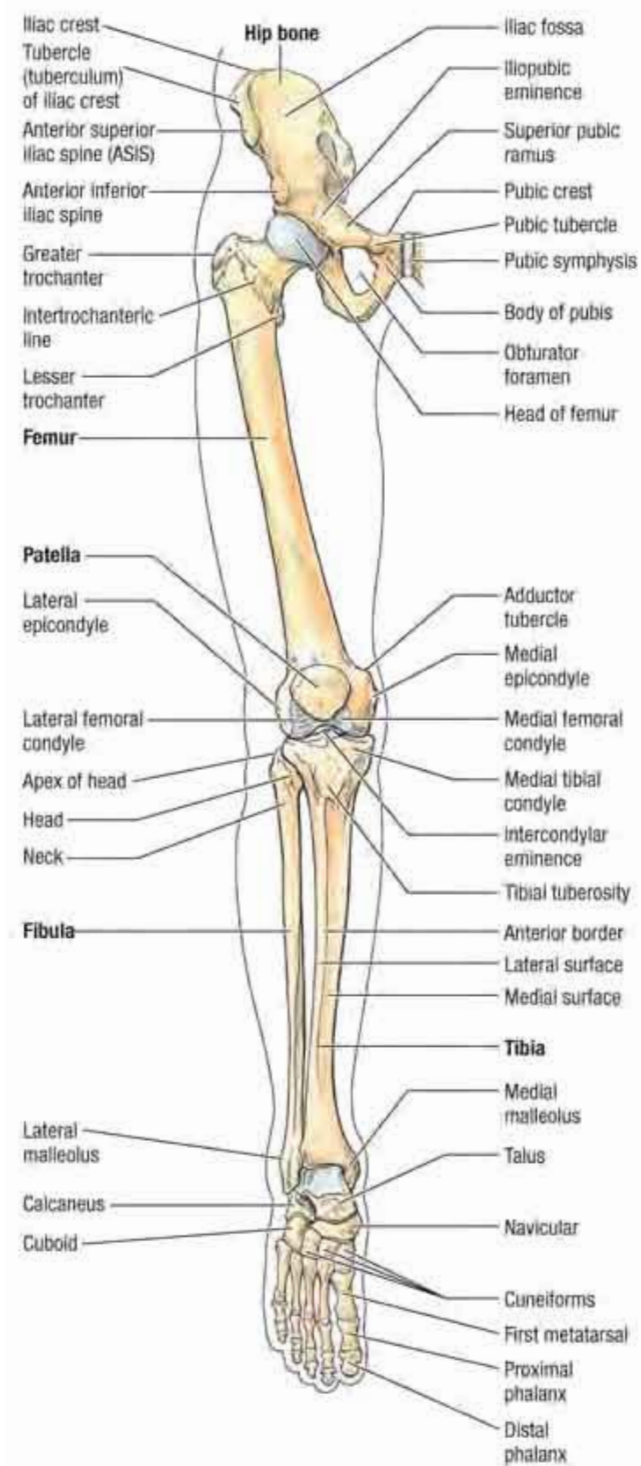
## 5.2 Features of bones of lower limb

*Part of* "Chapter 5 - Lower Limb "

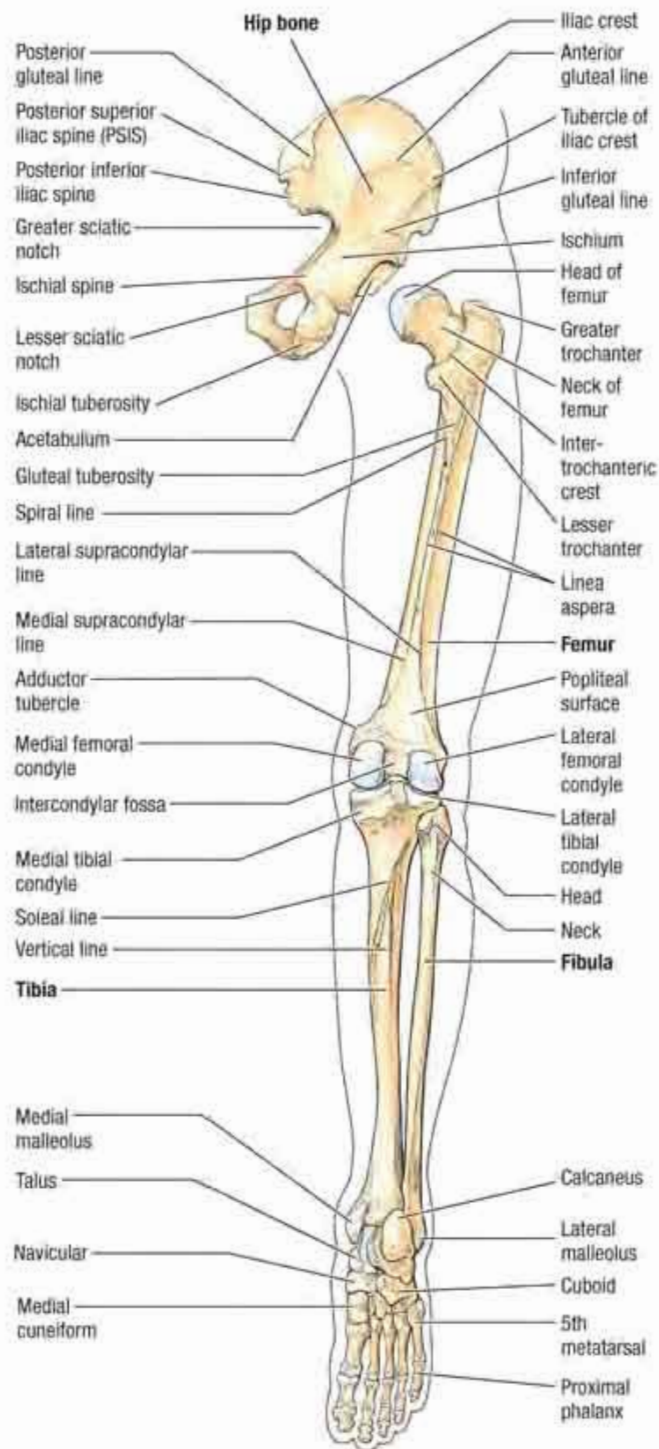
The foot is in full plantarflexion. The hip joint is disarticulated in B to demonstrate the acetabulum of the hip bone and the entire head of the femur.

---

P.356



**A. Anterior View**



**B. Posterior View**



Authors: Agur, Anne M.R.; Dalley, Arthur F.

Title: *Grant's Atlas of Anatomy, 12th Edition*

Copyright ©2009 Lippincott Williams & Wilkins

> Table of Contents > Chapter 5 - Lower Limb > 5.3 Overview of motor innervation of lower limb

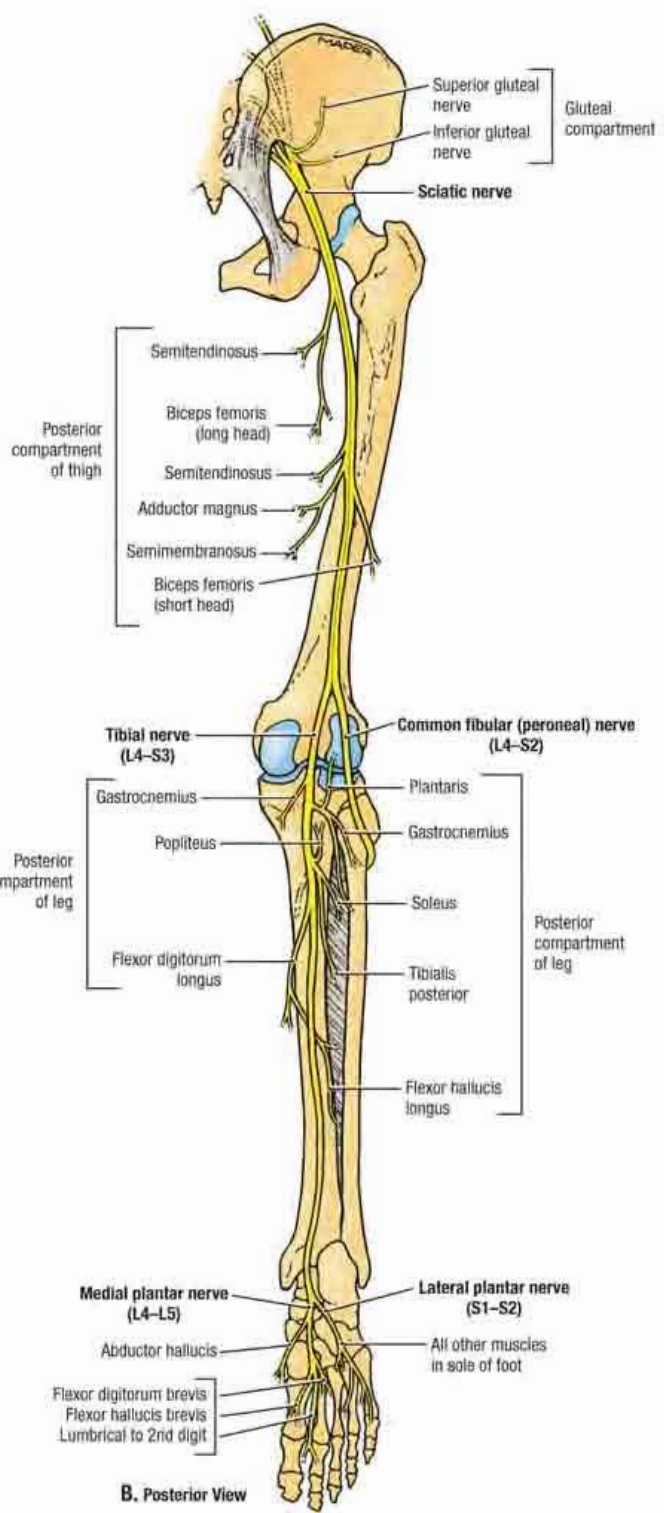
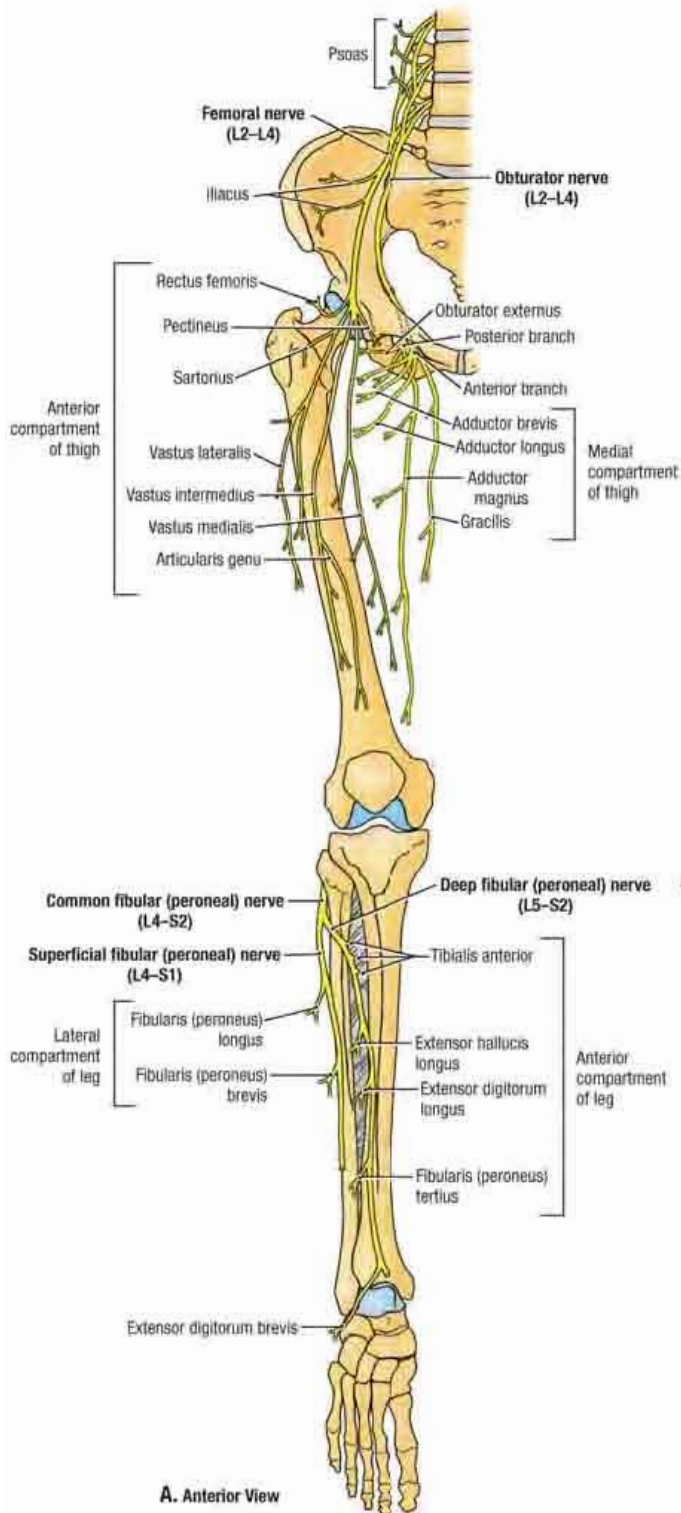
---

## 5.3 Overview of motor innervation of lower limb

*Part of* "Chapter 5 - Lower Limb "

---

P.357



Authors: Agur, Anne M.R.; Dalley, Arthur F.

Title: *Grant's Atlas of Anatomy, 12th Edition*

Copyright ©2009 Lippincott Williams & Wilkins

> Table of Contents > Chapter 5 - Lower Limb > 5.4 Myotomes and deep tendon reflexes

---

## 5.4 Myotomes and deep tendon reflexes

*Part of* "Chapter 5 - Lower Limb "

A. Myotomes. Somatic motor (general somatic efferent) fibers transmit impulses to skeletal (voluntary) muscles. The unilateral muscle mass receiving innervation from the somatic motor fibers conveyed by a single spinal nerve is a myotome. Each skeletal muscle is usually innervated by the somatic motor fibers of several spinal nerves; therefore, the muscle myotome will consist of several segments. The muscle myotomes have been grouped by joint movement to facilitate clinical testing.

B. Myotactic (deep tendon) reflexes. A myotatic (stretch) reflex is an involuntary contraction of a muscle in response to being stretched. Deep tendon reflexes (e.g., â€œknee jerkâ€•) are monosynaptic stretch reflexes that are elicited by briskly tapping the tendon with a reflex hammer. Each tendon reflex is mediated by specific spinal nerves. Stretch reflexes control muscle tone (e.g., in antigravity, muscles that keep the body upright against gravity).

---

P.358

Femoral

Lumbar plexus (L2â€”L4)

Passes deep to midpoint of inguinal ligament, lateral to femoral vessels, dividing into muscular and cutaneous branches in femoral triangle

Anterior thigh muscles, hip and knee joints

Obturator

Lumbar plexus (L2â€”L4)

Enters thigh via obturator foramen and divides; its anterior branch descends between

adductor longus and adductor brevis; its posterior branch descends between adductor brevis and adductor magnus

*Anterior branch:* adductor longus, adductor brevis, gracilis, and pectineus; *posterior branch:* obturator externus, and adductor magnus

Sciatic

Sacral plexus (L4–S3)

Enters gluteal region through greater sciatic foramen, usually passing inferior to piriformis, descends in posterior compartment of thigh, bifurcating at apex of popliteal fossa into tibial and common fibular (peroneal) nerves

Muscles of posterior thigh, leg and foot; skin of posterolateral leg and foot

Tibial

Sciatic nerve

Terminal branch of sciatic nerve arising at apex of popliteal fossa; descends through popliteal fossa with popliteal vessels, continuing in deep posterior compartment of leg with posterior tibial vessels; bifurcates into medial and lateral plantar nerves

Hamstring muscles of posterior compartment of thigh, muscles of posterior compartment of leg, and sole of foot

Common fibular

Sciatic nerve

Terminal branch of sciatic nerve arising at apex of popliteal fossa; follows medial border of biceps femoris and its tendon to wind around neck of fibula deep to fibularis longus, where it bifurcates into superficial and deep fibular nerves

Short head of biceps femoris, muscles of anterior and lateral leg, and dorsum of foot

Superficial fibular

Common fibular nerve

Arises deep to fibularis longus on neck of fibula and descends in lateral compartment of the leg; pierces crural fascia in distal third of leg to become cutaneous

Fibularis longus and brevis muscles

Deep fibular

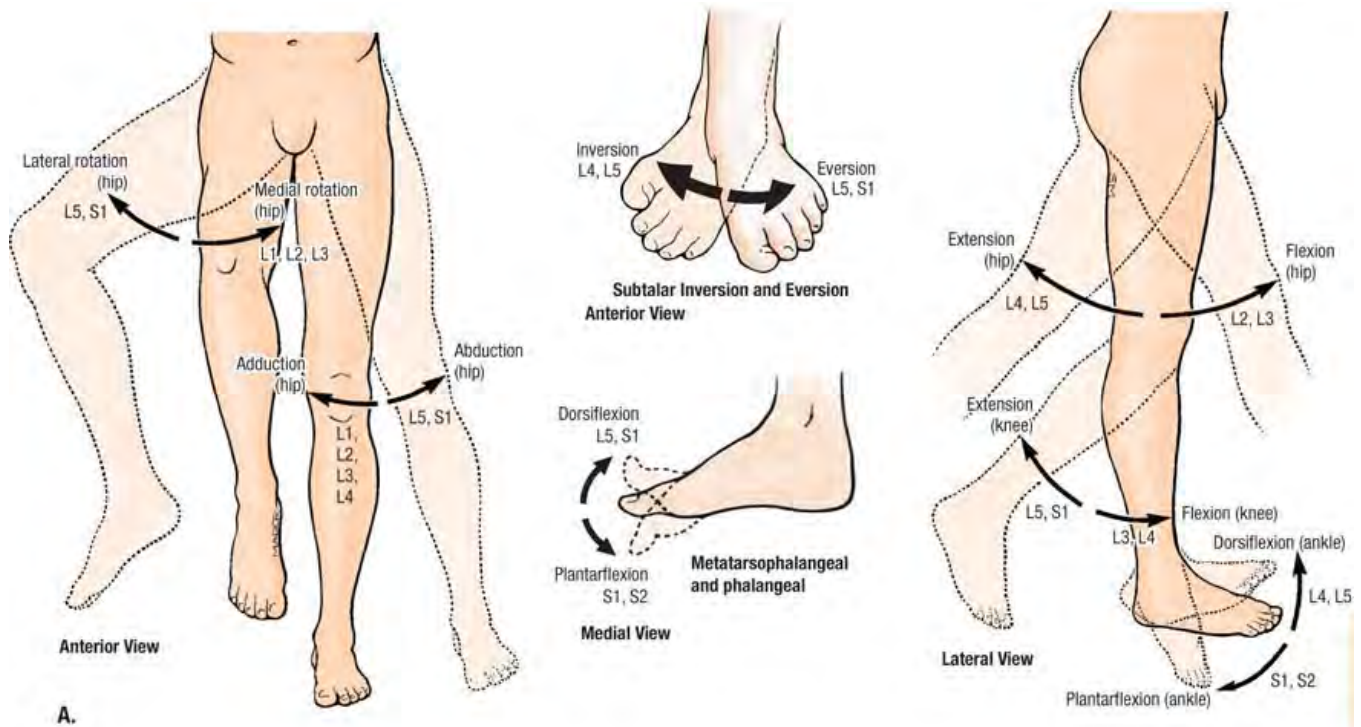
Common fibular nerve

Arises deep to fibularis longus on neck of fibula; passes through extensor digitorum longus into anterior compartment, descending on interosseous membrane; crosses ankle joint and enters dorsum of foot

Muscles of anterior compartment of leg and dorsum of foot

Table 5.1 Motor Nerves of Lower Limb

P.359



Myotatic (Deep Tendon) Reflex	Spinal Cord Segments
Quadriceps	L3/L4
Calcaneal (Achilles)	S1/S2



Authors: Agur, Anne M.R.; Dalley, Arthur F.

Title: *Grant's Atlas of Anatomy, 12th Edition*

Copyright ©2009 Lippincott Williams & Wilkins

> Table of Contents > Chapter 5 - Lower Limb > 5.5 Cutaneous nerves of lower limb

---

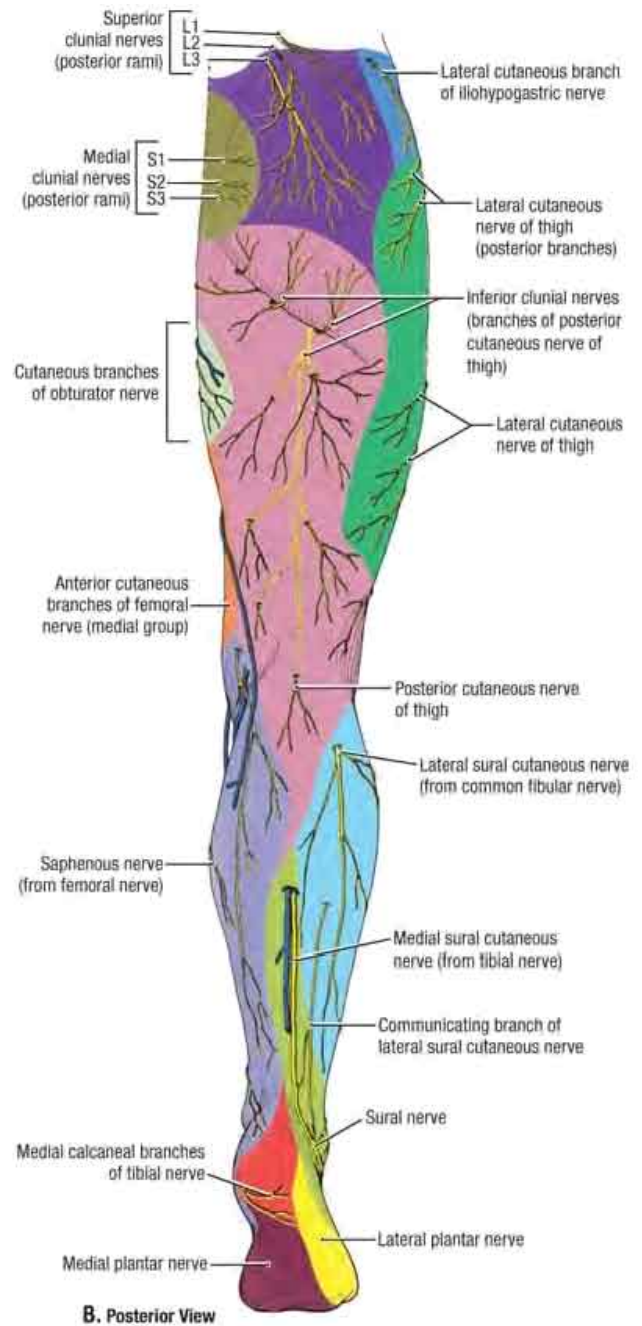
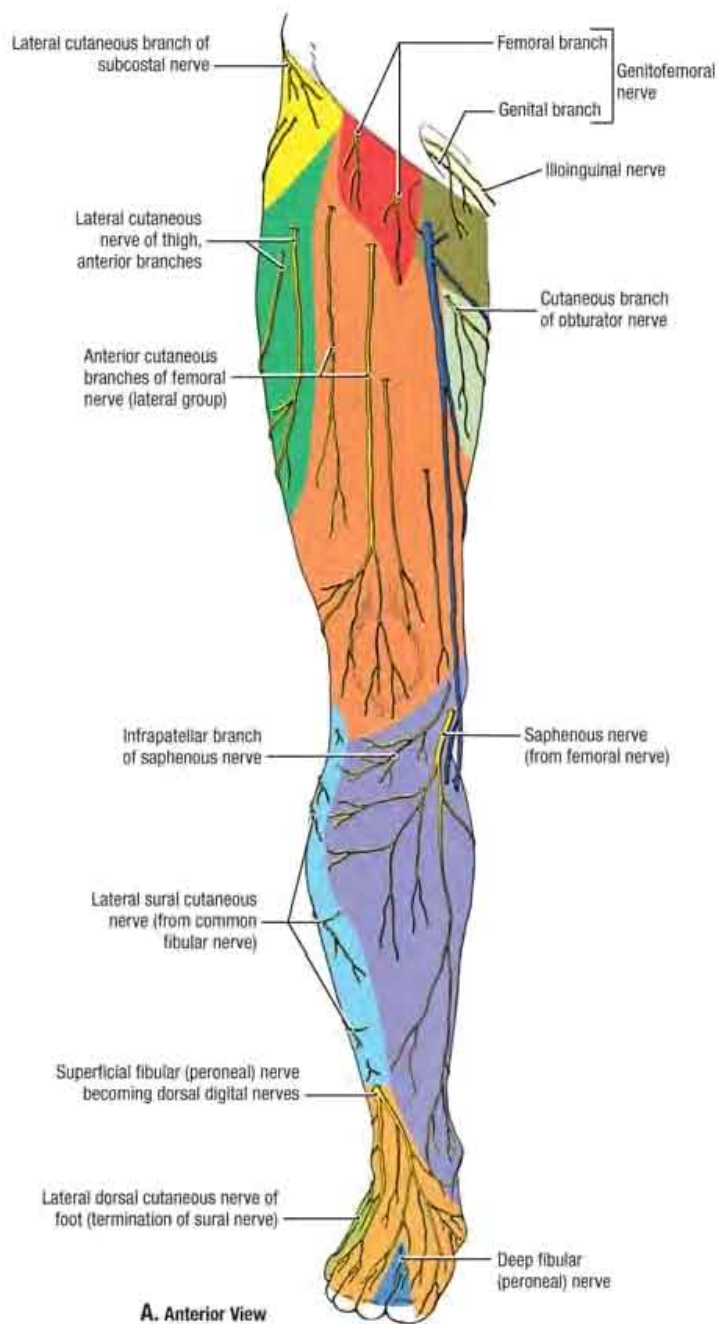
## 5.5 Cutaneous nerves of lower limb

*Part of* "Chapter 5 - Lower Limb "

Cutaneous nerves in the subcutaneous tissue supply the skin of the lower limb. The cutaneous innervation of the lower limb reflects both the original segmental innervation of the skin via separate spinal nerves in its dermatomal pattern (Fig. 5.7 ) and the result of plexus formation of segmental peripheral nerves. In B , the medial sural cutaneous nerve (*sura*/is Latin for calf) is joined between the popliteal fossa and posterior aspect of the ankle by a communicating branch of the lateral sural cutaneous nerve to form the sural nerve. The level of the junction is variable and is low in this specimen.

---

P.360



Authors: Agur, Anne M.R.; Dalley, Arthur F.

Title: *Grant's Atlas of Anatomy, 12th Edition*

Copyright ©2009 Lippincott Williams & Wilkins

> Table of Contents > Chapter 5 - Lower Limb > 5.6 Rotation of limbs during development;  
effect on lower limb dermatome pattern

---

## 5.6 Rotation of limbs during development; effect on lower limb dermatome pattern

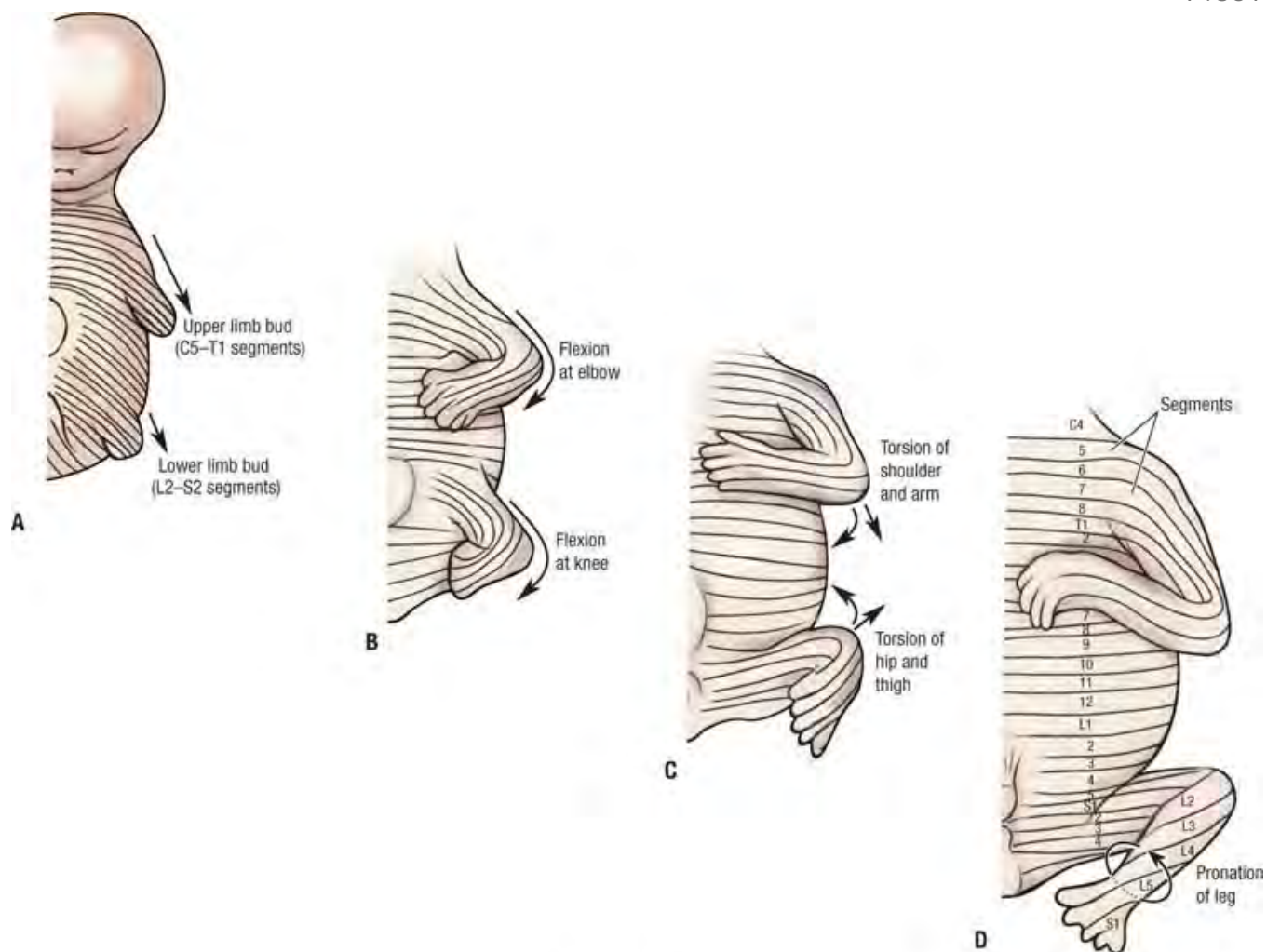
*Part of* "Chapter 5 - Lower Limb "

A. During early development, the trunk is divided into segments (metameres) that correspond to, and receive innervation from, the corresponding spinal cord segments. During the 4th week of development, the upper limb buds appear as elevations of the C5 to T1 segments of the ventrolateral body wall. Following the cranial-to-caudal pattern of development the lower limb buds appear about a week later (5th week). The lower limb buds grow laterally from broader bases formed by the L2 to S2 segments.

B. The distal ends of the limb buds flatten into paddlelike hand plates and foot plates that are elongated in the craniocaudal axis. Initially, both the thumb and the great toe are on the cranial sides of the developing hand and foot, directed superiorly, with the palms and soles directed anteriorly. Where gaps develop between the precursors of the long bones (future elbow and knee joints), flexures occur. At first, the limbs bend anteriorly, so that the elbow and knee are directed laterally, causing the palm and sole to be directed medially (toward the trunk).

C. By the end of the 7th week, the proximal parts of the upper and lower limbs undergo a 90-degree torsion around their long axes, but in opposite directions, so that the elbow becomes directed caudally and the knee cranially.

D. In the lower limb, the torsion of the proximal limb is accompanied by a permanent pronation (twisting) of the leg, so that the foot becomes oriented with the great toe on the medial side.



Anterior (Ventral) Views

Authors: Agur, Anne M.R.; Dalley, Arthur F.

Title: *Grant's Atlas of Anatomy, 12th Edition*

Copyright ©2009 Lippincott Williams & Wilkins

> Table of Contents > Chapter 5 - Lower Limb > 5.7 Dermatomes of lower limb

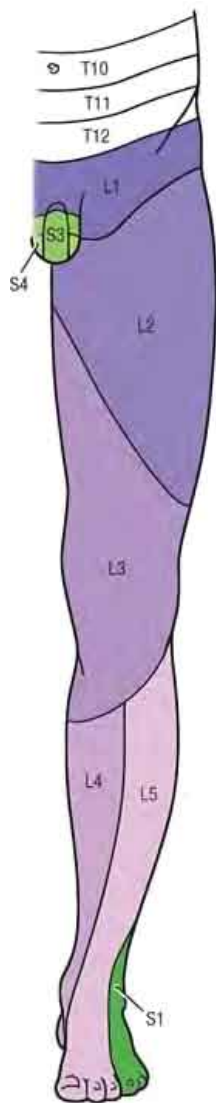
---

## 5.7 Dermatomes of lower limb

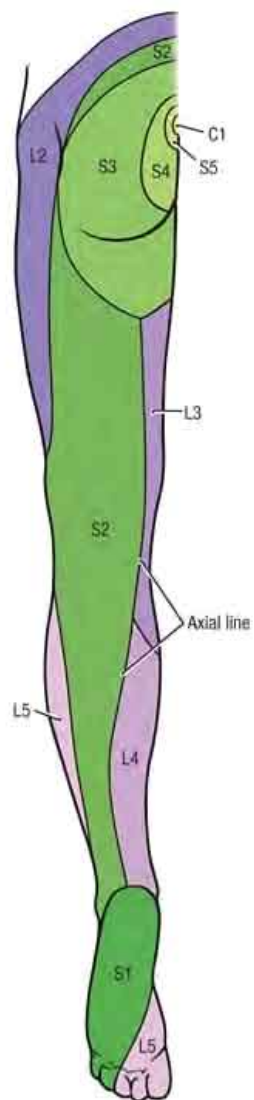
*Part of* "Chapter 5 - Lower Limb "

The dermatomal, or segmental, pattern of distribution of sensory nerve fibers persists despite the merging of spinal nerves in plexus formation during development. Two different dermatome maps are commonly used. A and B. The dermatome pattern of the lower limb according to Foerster (1933) is preferred by many because of its correlation with clinical findings. C and D. The dermatome pattern of the lower limb according to Keegan and Garrett (1948) is preferred by others for its aesthetic uniformity and obvious correlation with development. Although depicted as distinct zones, adjacent dermatomes overlap considerably, except along the axial line.

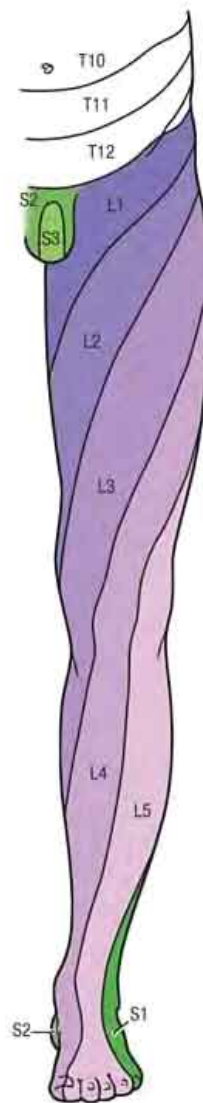




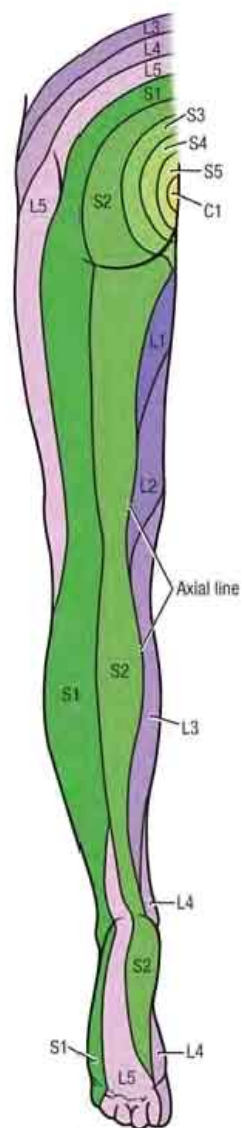
A. Anterior View



B. Posterior View



C. Anterior View



D. Posterior View

Authors: Agur, Anne M.R.; Dalley, Arthur F.

Title: *Grant's Atlas of Anatomy, 12th Edition*

Copyright ©2009 Lippincott Williams & Wilkins

> Table of Contents > Chapter 5 - Lower Limb > 5.8 Overview of arteries of lower limb

---

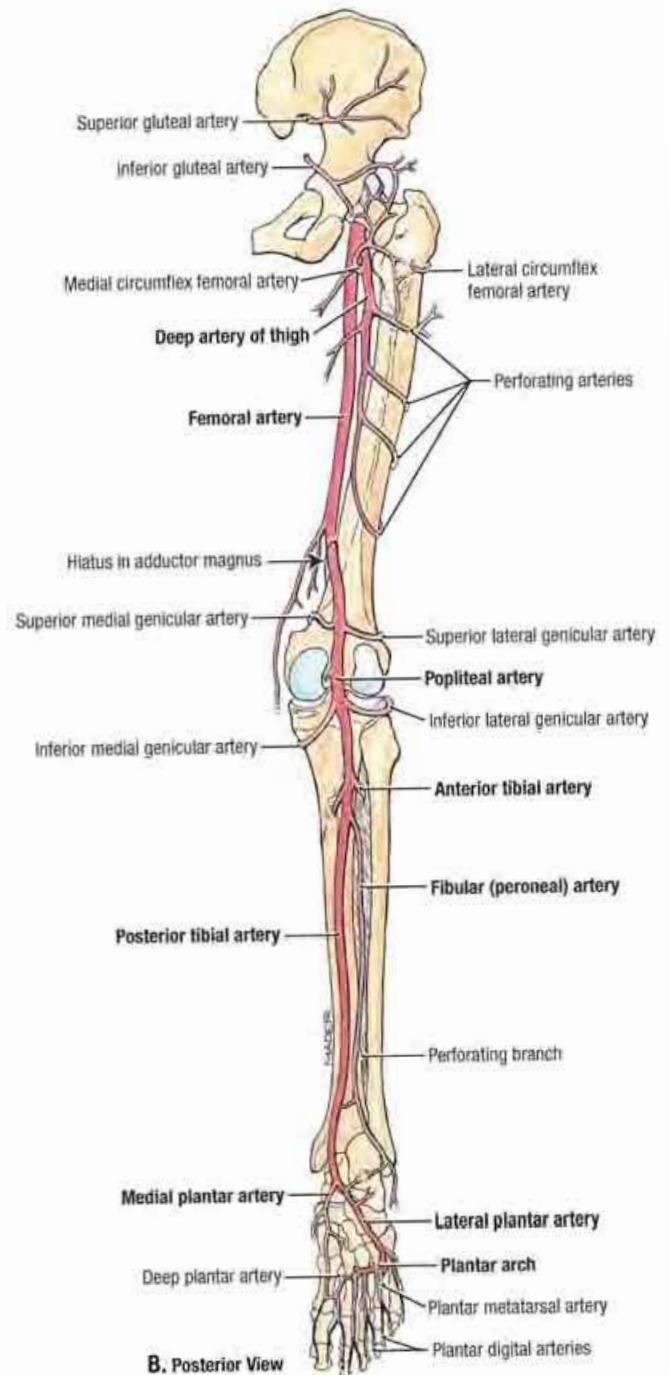
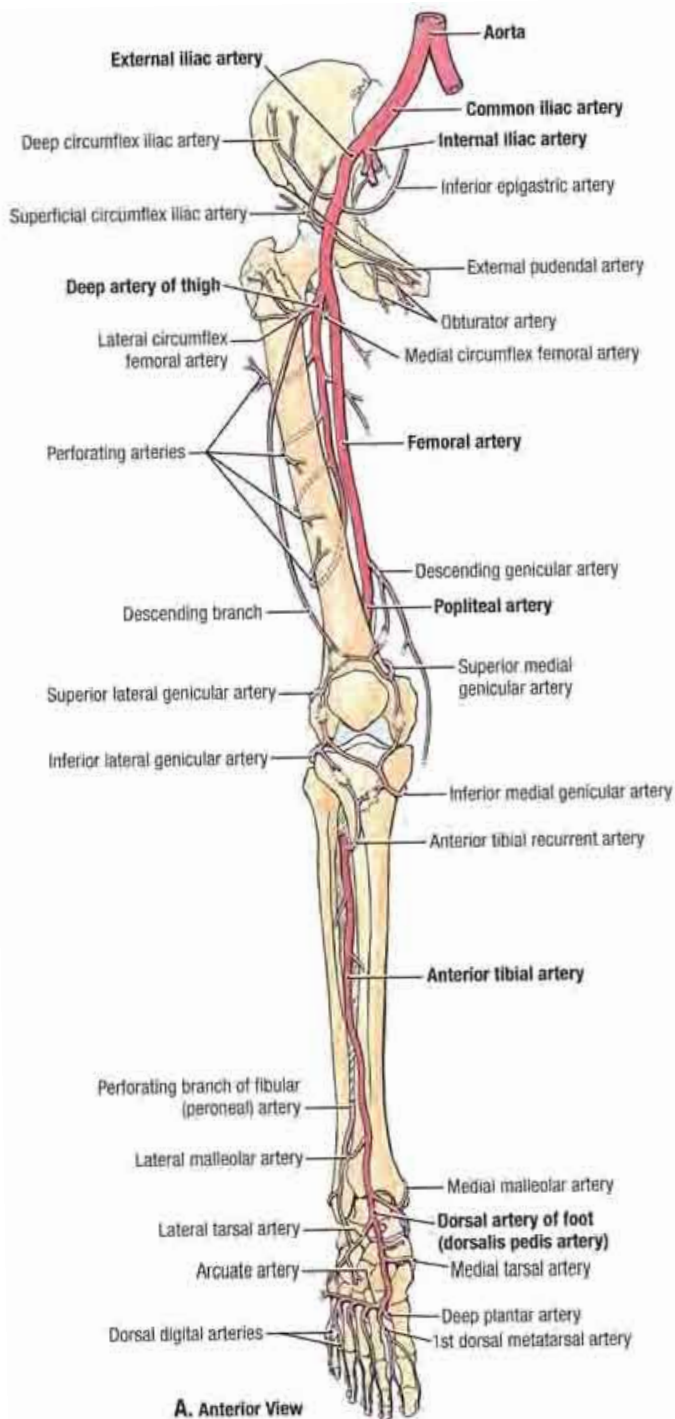
## 5.8 Overview of arteries of lower limb

*Part of* "Chapter 5 - Lower Limb "

The arteries often anastomose or communicate to form networks to ensure blood supply distal to the joint throughout the range of movement. If a main channel is slowly occluded, the smaller alternate channels can usually increase in size, providing a collateral circulation that ensures the blood supply to structures distal to the blockage.

---

P.363



Authors: Agur, Anne M.R.; Dalley, Arthur F.

Title: *Grant's Atlas of Anatomy, 12th Edition*

Copyright ©2009 Lippincott Williams & Wilkins

> Table of Contents > Chapter 5 - Lower Limb > 5.9 Deep veins of lower limb

---

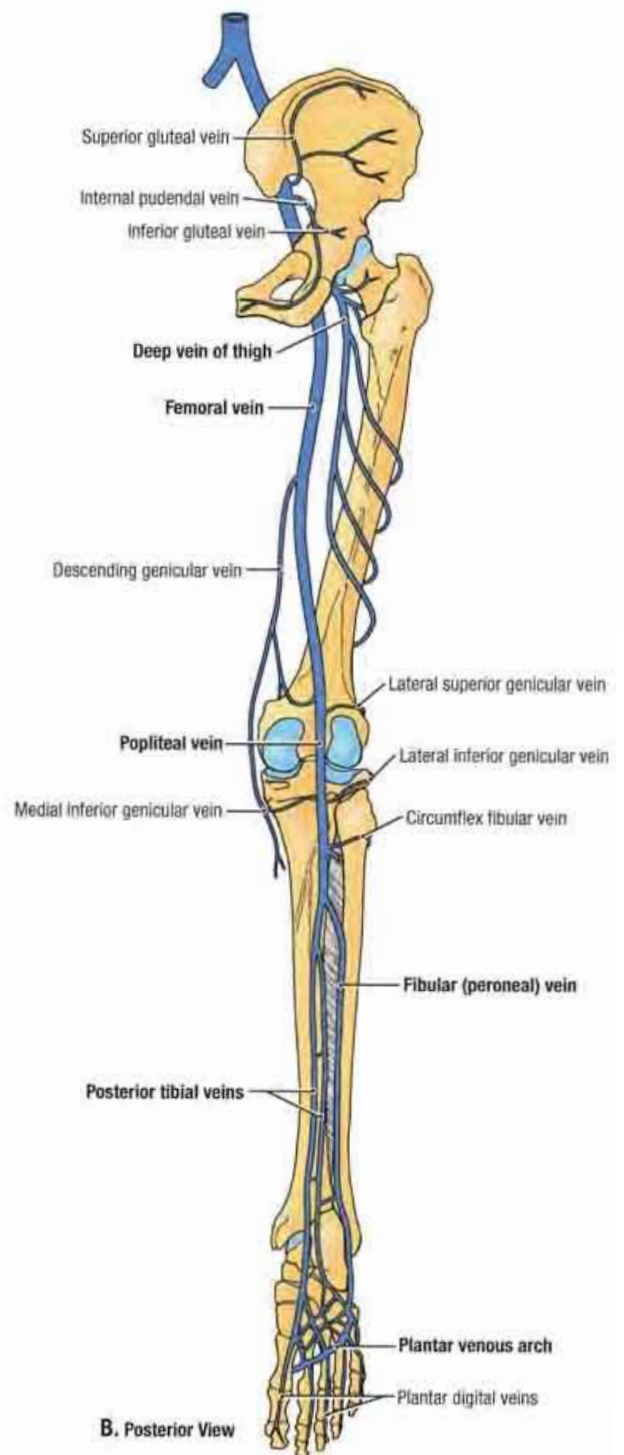
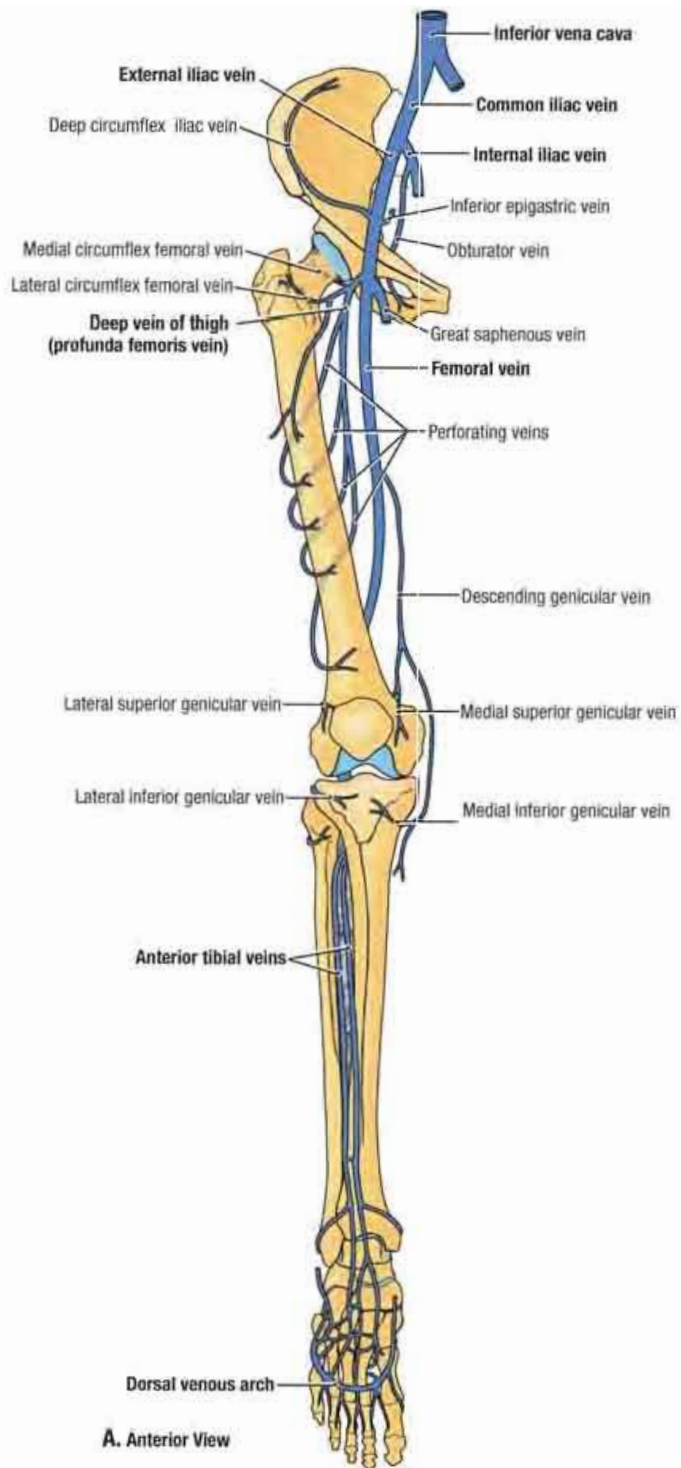
## 5.9 Deep veins of lower limb

*Part of* "Chapter 5 - Lower Limb "

Deep veins lie internal to the deep fascia. Although only the anterior and posterior tibial veins are depicted as paired structures in this schematic illustration, typically in the limbs deep veins occur as paired, continually interanastomosing accompanying veins (L., *venae comitantes*) surrounding and sharing the name of the artery they accompany.

---

P.364





Authors: Agur, Anne M.R.; Dalley, Arthur F.

Title: *Grant's Atlas of Anatomy, 12th Edition*

Copyright ©2009 Lippincott Williams & Wilkins

> Table of Contents > Chapter 5 - Lower Limb > 5.10 Superficial veins of lower limb

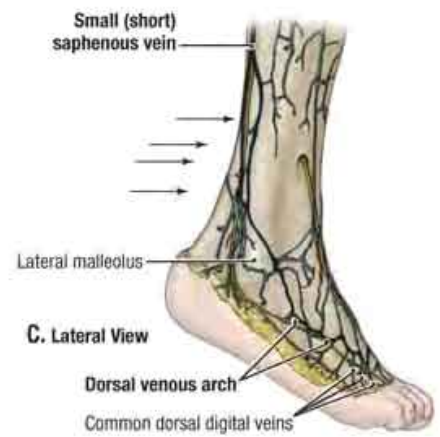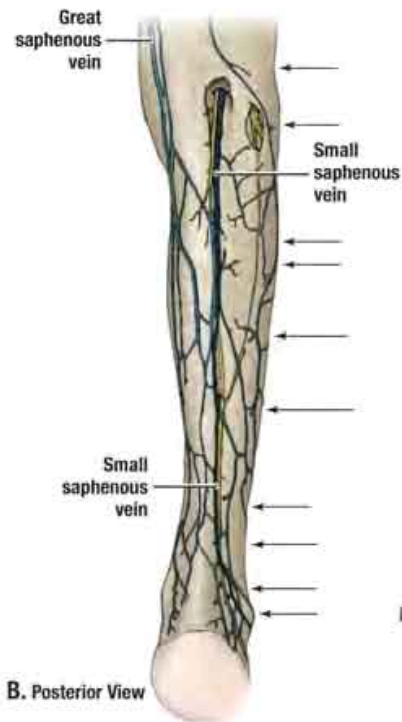
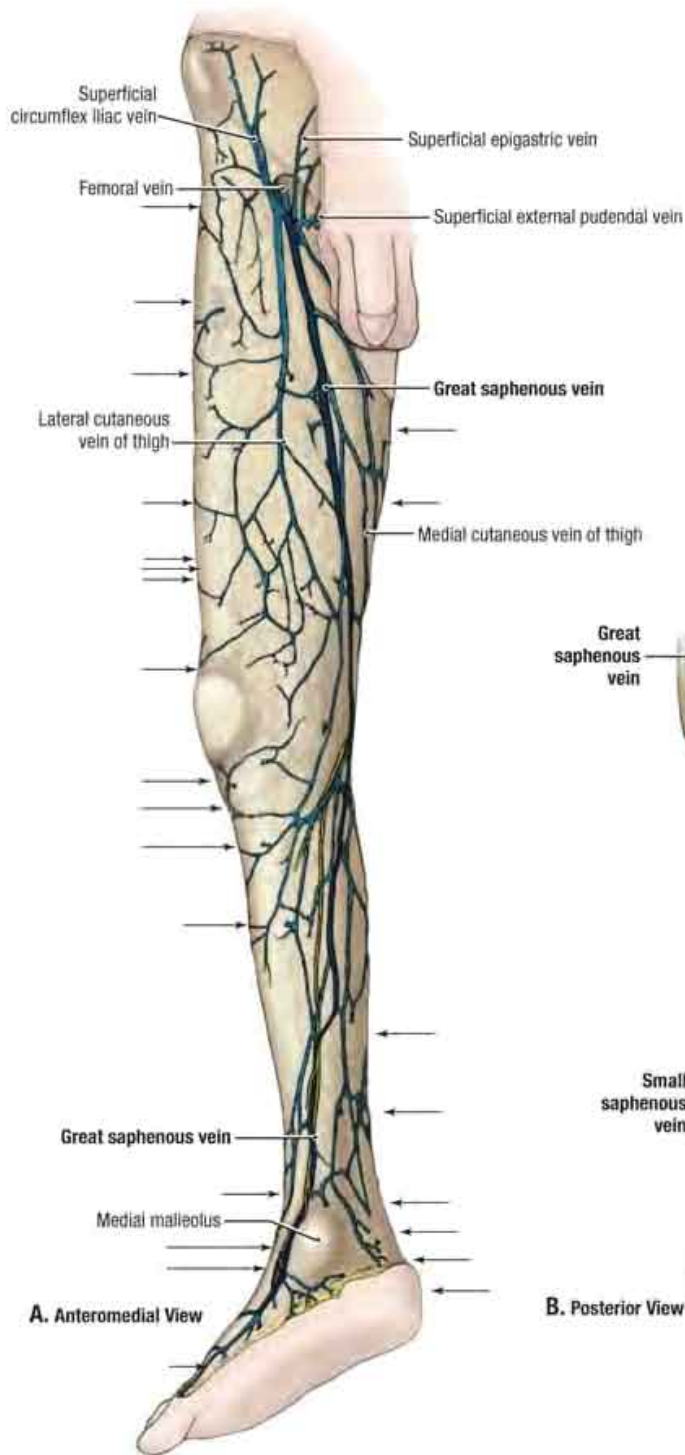
---

## 5.10 Superficial veins of lower limb

*Part of* "Chapter 5 - Lower Limb "

The *arrows* indicate where perforating veins penetrate the deep fascia. Blood is continuously shunted from these superficial veins in the subcutaneous tissue to deep veins via the perforating veins.

Vein grafts obtained by surgically harvesting parts of the great saphenous vein are used to bypass obstructions in blood vessels (e.g., an occlusion of a coronary artery or its branches). When part of the vein is used as a bypass, it is reversed so that the valves do not obstruct blood flow. Because there are so many anastomosing leg veins, removal of the great saphenous vein rarely affects circulation seriously, provided the deep veins are intact.



Authors: Agur, Anne M.R.; Dalley, Arthur F.

Title: *Grant's Atlas of Anatomy, 12th Edition*

Copyright ©2009 Lippincott Williams & Wilkins

> Table of Contents > Chapter 5 - Lower Limb > 5.11 Drainage and surface anatomy of superficial veins of lower limb

---

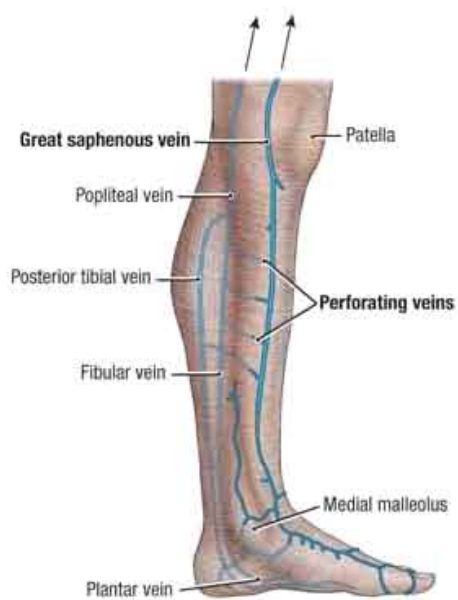## 5.11 Drainage and surface anatomy of superficial veins of lower limb

*Part of "Chapter 5 - Lower Limb "*

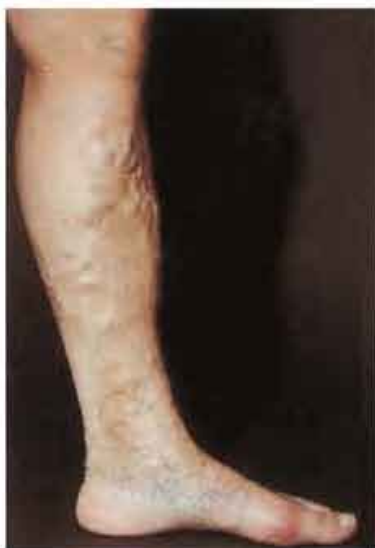A. Schematic diagram of drainage of superficial veins. Blood is repeatedly shunted from the superficial veins (e.g., great saphenous vein) to the deep veins (e.g., fibular and posterior tibial veins) via perforating veins that penetrate the deep fascia. Muscular compression of deep veins assists return of blood to the heart against gravity.

B. Varicose veins form when either the deep fascia or the valves of the perforating veins are incompetent. This allows the muscular compression that normally propels blood toward the heart to push blood from the deep to the superficial veins. Consequently, superficial veins become enlarged and tortuous.

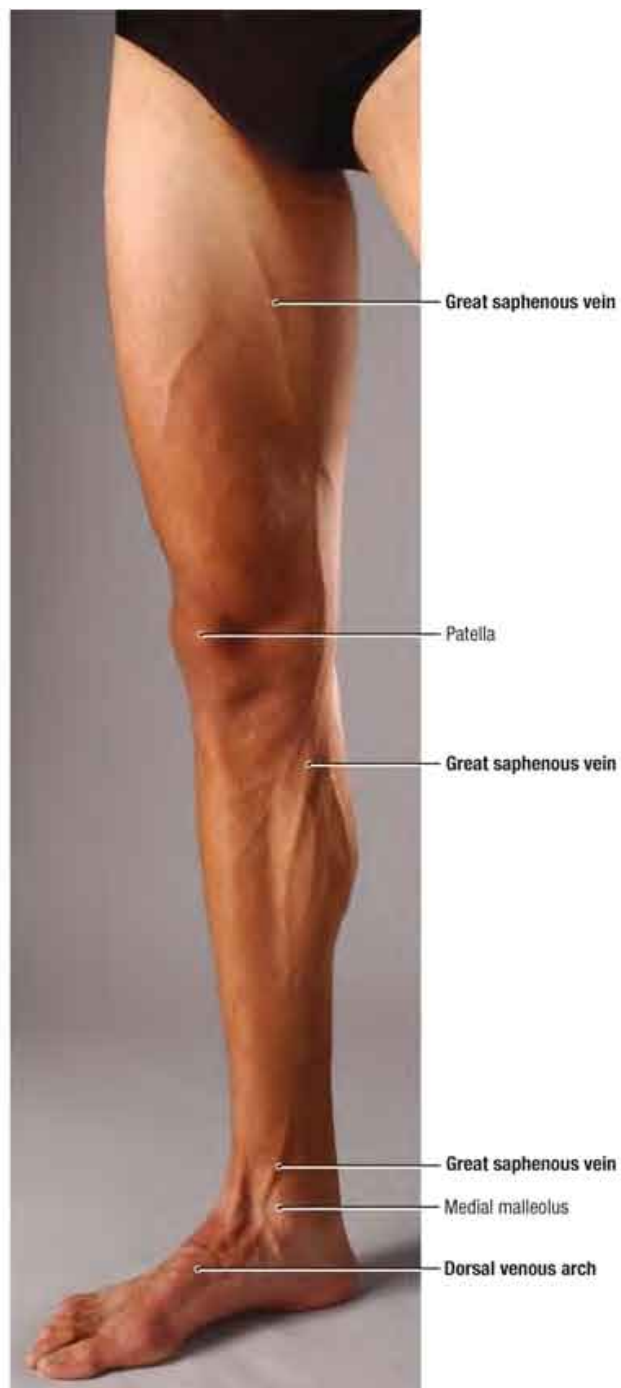C. Normal veins, distended following exercise.



**A. Medial View**



**B. Medial View, Varicose Veins**



**C. Anteromedial View, Normal Veins  
(distended following exercise)**

Authors: Agur, Anne M.R.; Dalley, Arthur F.

Title: *Grant's Atlas of Anatomy, 12th Edition*

Copyright ©2009 Lippincott Williams & Wilkins

> Table of Contents > Chapter 5 - Lower Limb > 5.12 Superficial lymphatic drainage of lower limb

---

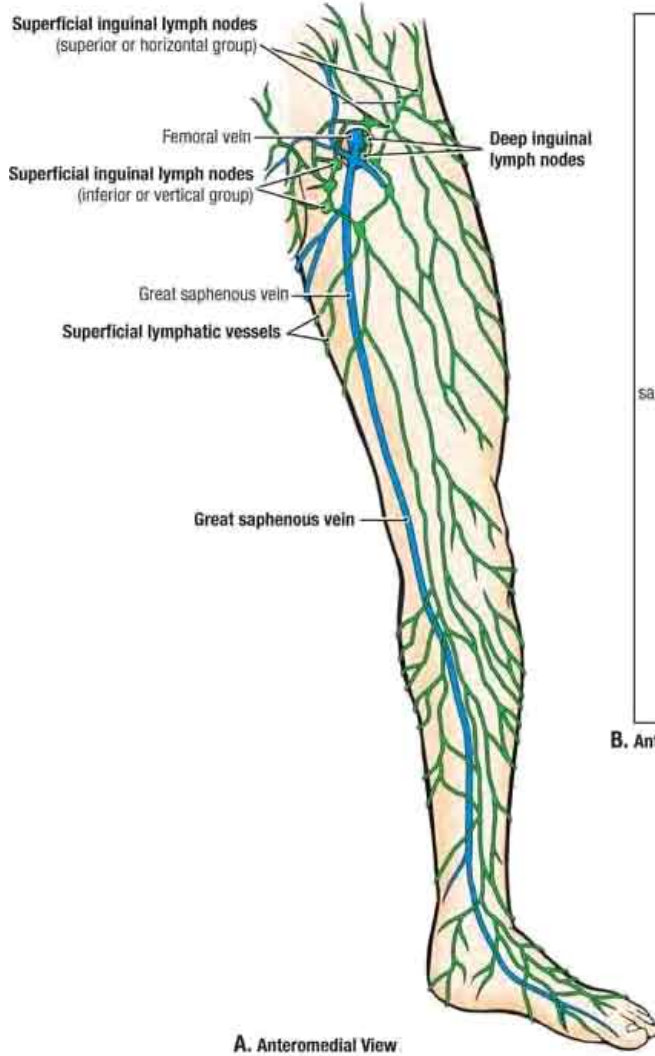
## 5.12 Superficial lymphatic drainage of lower limb

*Part of "Chapter 5 - Lower Limb "*

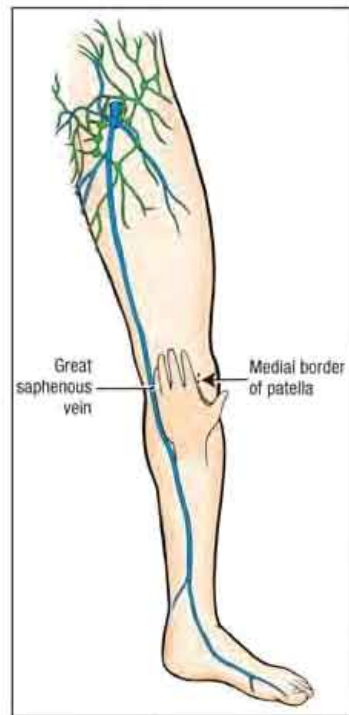
The superficial lymphatic vessels converge on and accompany the saphenous veins and their tributaries in the superficial fascia. The lymphatic vessels along the great saphenous vein drain into the superficial inguinal lymph nodes; those along the small saphenous vein drain into the popliteal lymph nodes. Lymph from the superficial inguinal nodes drains to the deep inguinal and external iliac nodes. Lymph from the popliteal nodes ascends through deep lymphatic vessels accompanying the deep blood vessels to the deep inguinal nodes. In B , note that the great saphenous vein lies anterior to the medial malleolus and a hand's breadth posterior to the medial aspect of the patella.

Lymph nodes enlarge when diseased. Abrasions and minor sepsis, caused by pathogenic microorganisms or their toxins in the blood or other tissues, may produce slight enlargement of the superficial inguinal nodes (lymphadenopathy) in otherwise healthy people. Malignancies (e.g., of the external genitalia and uterus) and perineal abscesses also result in enlargement of these nodes.

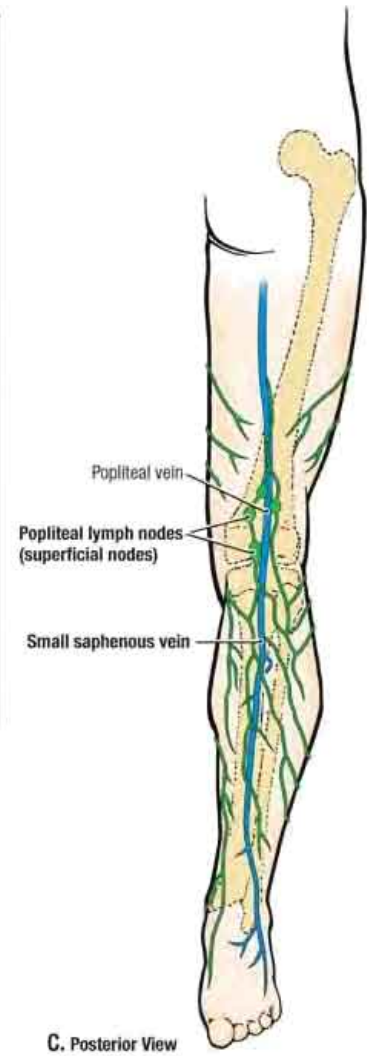




**A. Anteromedial View**



**B. Anteromedial View**



**C. Posterior View**

Authors: Agur, Anne M.R.; Dalley, Arthur F.

Title: *Grant's Atlas of Anatomy, 12th Edition*

Copyright ©2009 Lippincott Williams & Wilkins

> Table of Contents > Chapter 5 - Lower Limb > 5.13 Inguinal lymph nodes

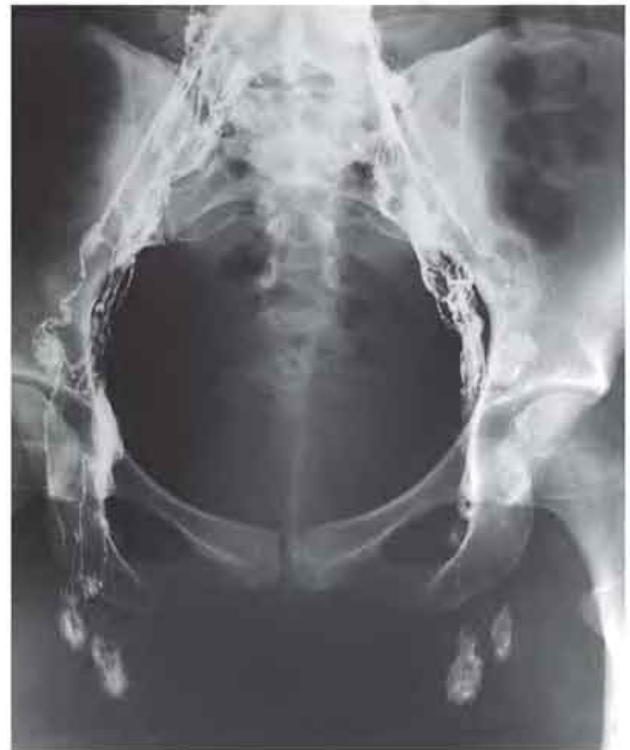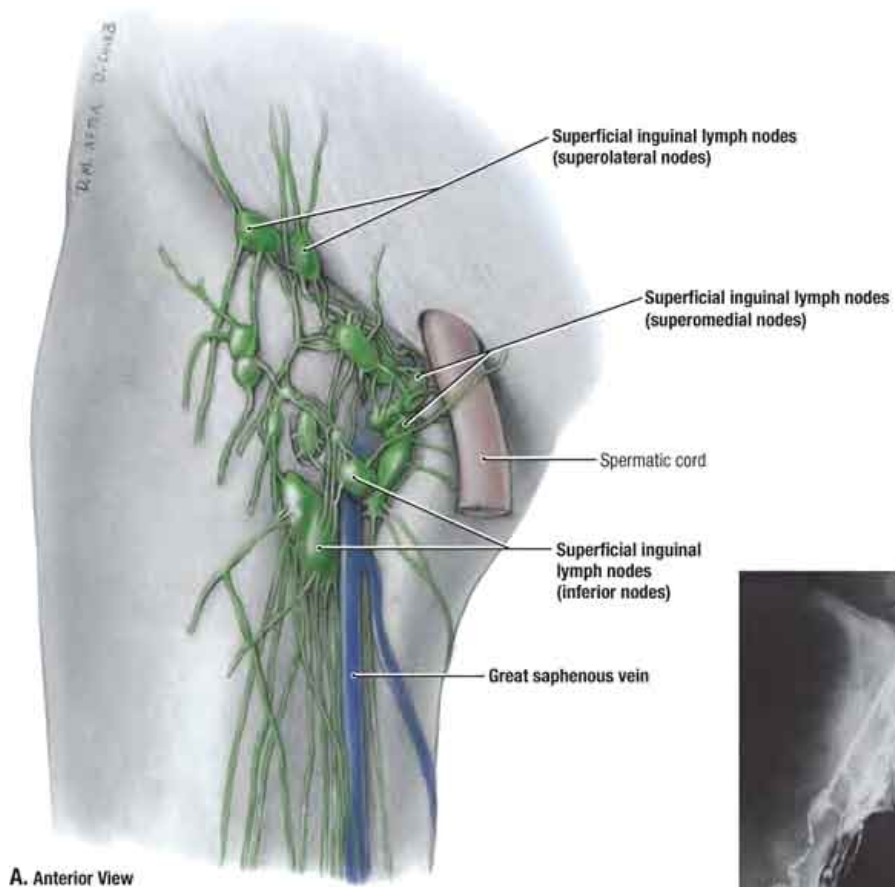
---

## 5.13 Inguinal lymph nodes

*Part of* "Chapter 5 - Lower Limb "

A. Dissection. B. Lymphangiogram.

- Observe the arrangement of the nodes: a proximal chain parallel to the inguinal ligament (superolateral and superomedial superficial inguinal lymph nodes) and a distal chain on the sides of the great saphenous vein (inferior superficial inguinal lymph nodes). Efferent vessels leave these nodes and pass deep to the inguinal ligament to enter the external iliac nodes. Some of the lymphatic vessels traverse the femoral canal, and others ascend alongside the femoral artery and vein, some inside the femoral sheath, and some outside it.
- Note the anastomosis between the lymph vessels.



Authors: Agur, Anne M.R.; Dalley, Arthur F.

Title: *Grant's Atlas of Anatomy, 12th Edition*

Copyright ©2009 Lippincott Williams & Wilkins

> Table of Contents > Chapter 5 - Lower Limb > 5.14 Fascia and musculofascial compartments of lower limb

---

## 5.14 Fascia and musculofascial compartments of lower limb

*Part of "Chapter 5 - Lower Limb "*

A. Anterior skin and subcutaneous tissue have been removed to reveal the deep fascia of the thigh (fascia lata) and leg (crural fascia). B. Lateral skin and subcutaneous tissue have been removed to reveal the fascia lata. The fascia lata is thick laterally and forms the iliotibial tract. The iliotibial tract serves as a common aponeurosis for the gluteus maximus and tensor fasciae latae muscles.

---

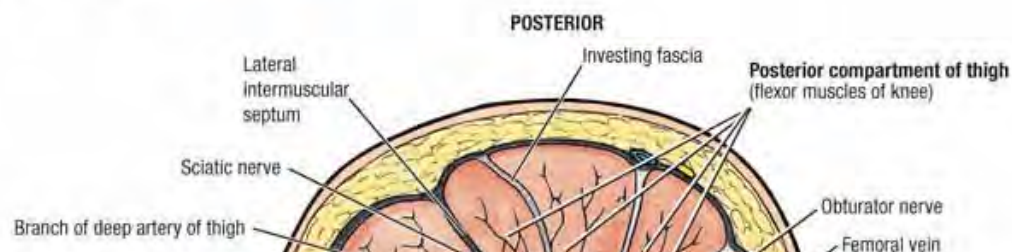
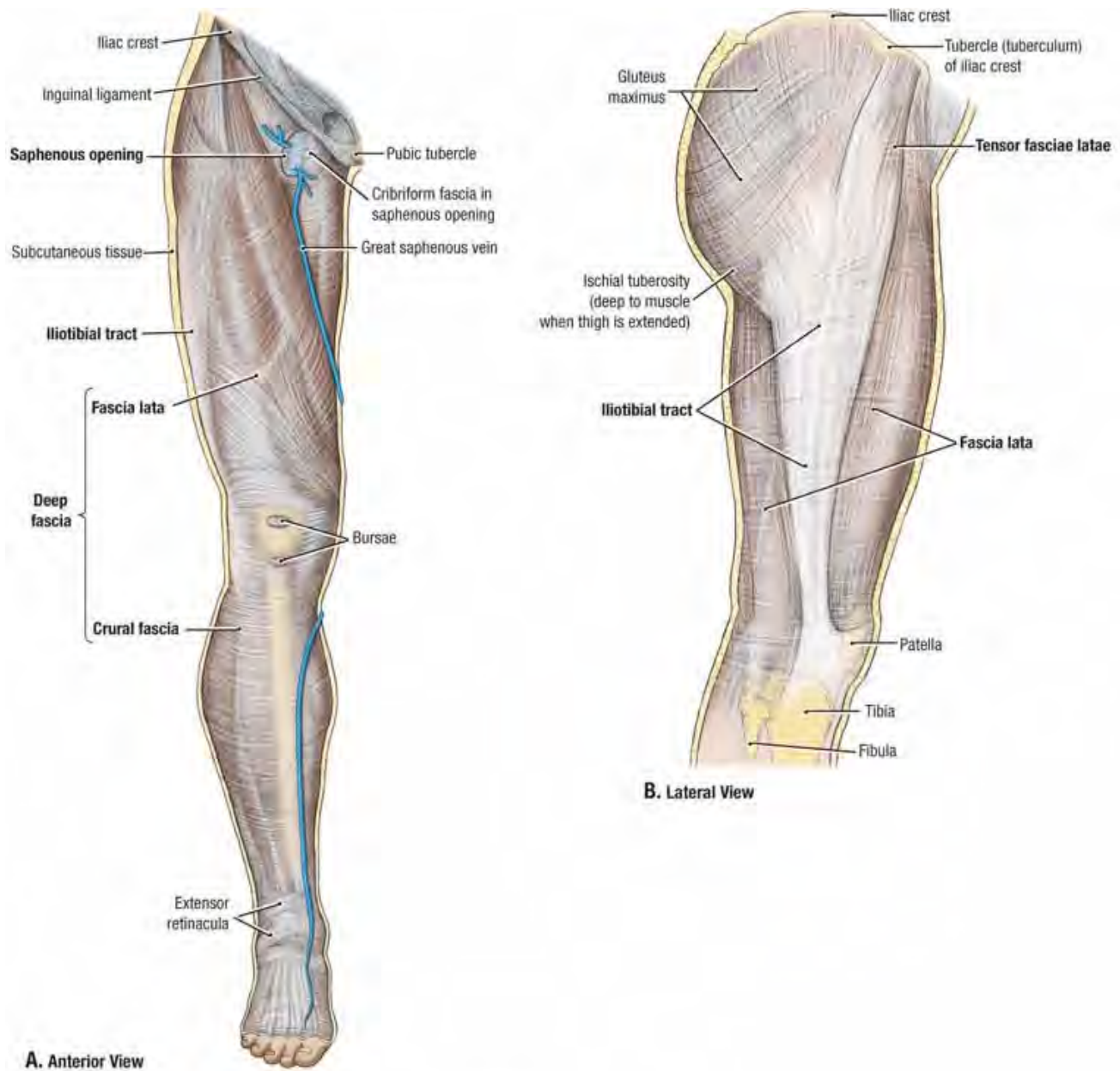
P.369

C and D. The fascial compartments of the thigh (C) and leg (D) are demonstrated in transverse section. The fascial compartments contain muscles that generally perform common functions and share common innervation, and contain the spread of infection. While both thigh and leg have anterior and posterior compartments, the thigh also includes a medial compartment and the leg a lateral compartment.

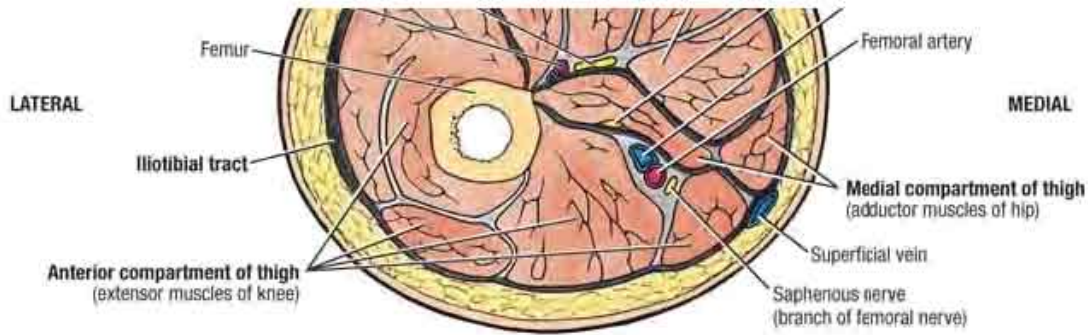
Trauma to muscles and/or vessels in the compartments may product hemorrhage, edema, and inflammation of the muscles. Because the septa, deep fascia, and bony attachments firmly bound the compartments, increased volume resulting from these processes raises intracompartmental pressure. In compartment syndromes, structures within or distal to the compressed area become ischemic and may become permanently injured (e.g., compression of capillary beds results in denervation and consequent paralysis of muscles). A fasciotomy (incision of bounding fascia or septum)

may be performed to relieve the pressure in the compartment and restore circulation.

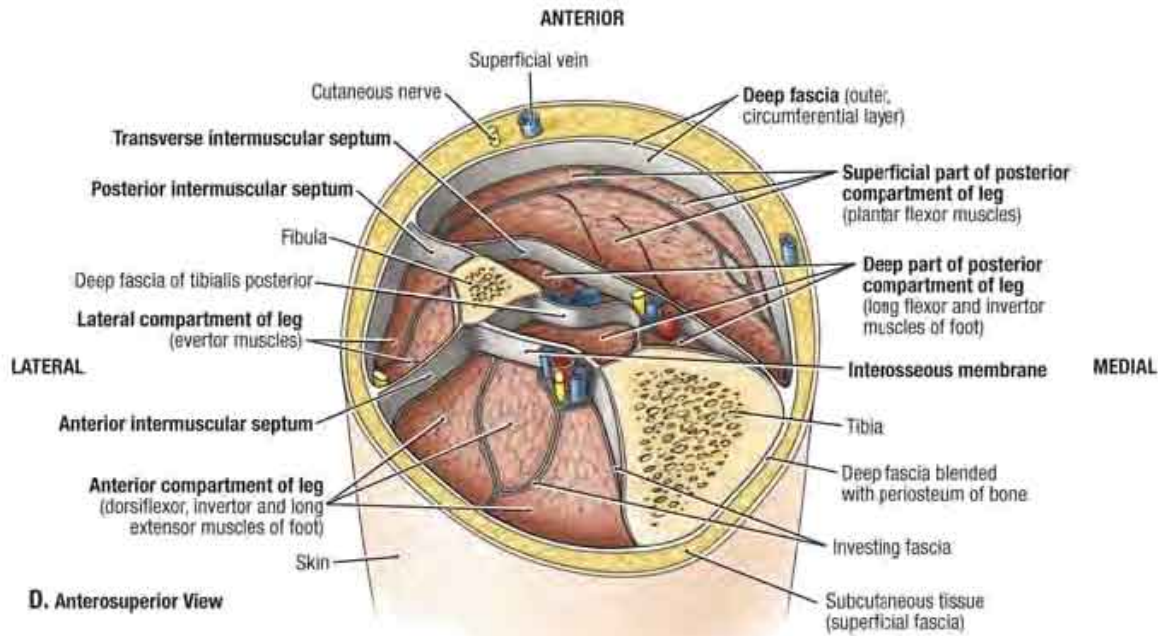
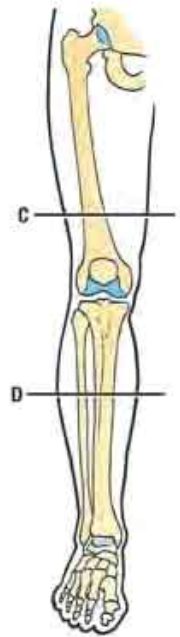P.370







**C. Superior View**



**D. Anterosuperior View**

Authors: Agur, Anne M.R.; Dalley, Arthur F.

Title: *Grant's Atlas of Anatomy, 12th Edition*

Copyright ©2009 Lippincott Williams & Wilkins

> Table of Contents > Chapter 5 - Lower Limb > 5.15 Superficial inguinal vessels and saphenous opening

---

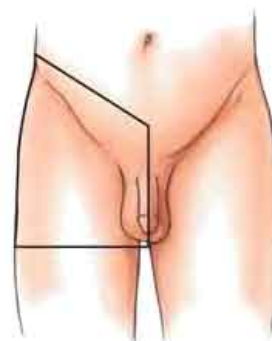
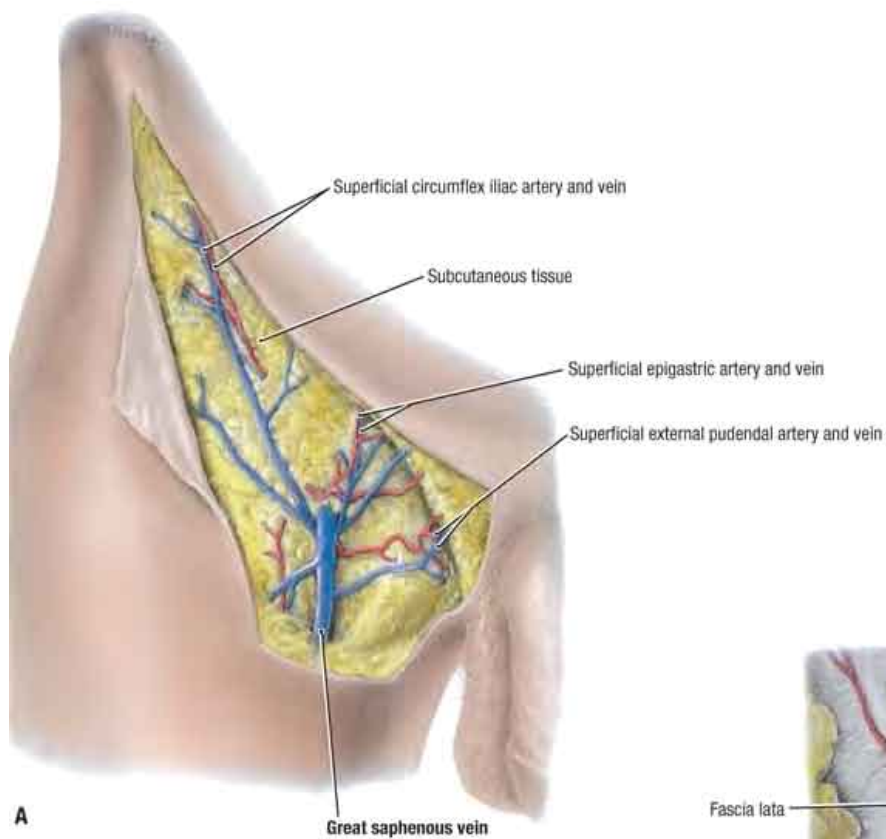
## 5.15 Superficial inguinal vessels and saphenous opening

*Part of* "Chapter 5 - Lower Limb "

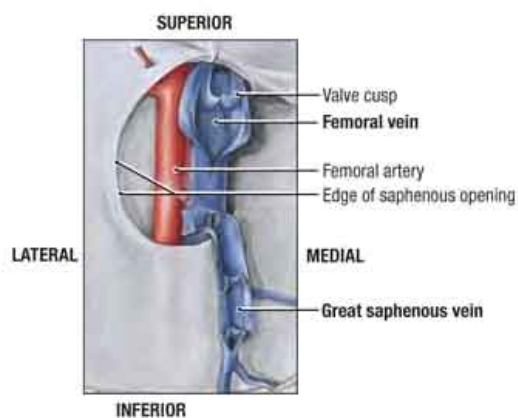
A. Superficial inguinal vessels. The arteries are branches of the femoral artery, and the veins are tributaries of the great saphenous vein. B. Valves of the proximal part of femoral and great saphenous veins. C. Saphenous opening.

---

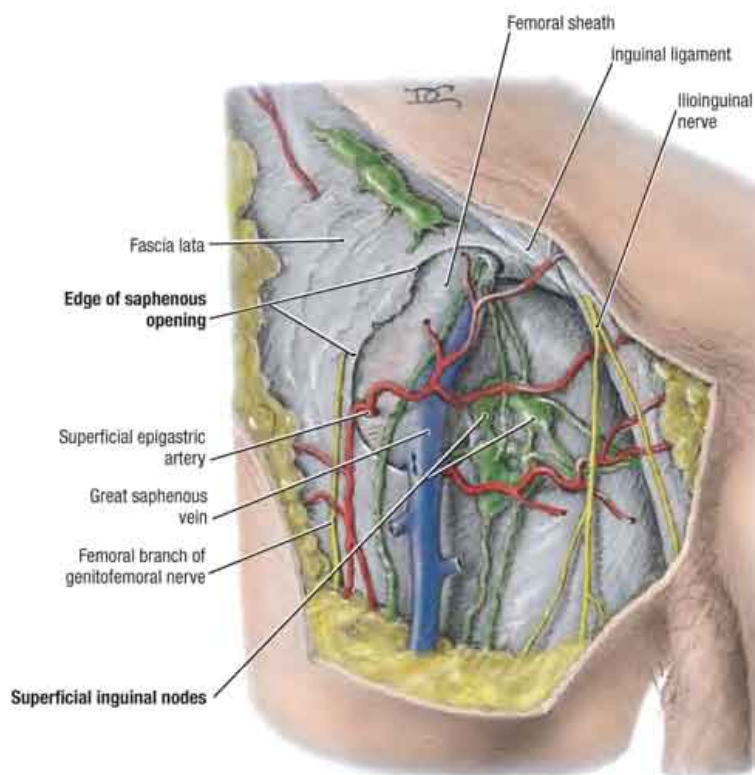
P.371



A



B



C

Authors: Agur, Anne M.R.; Dalley, Arthur F.

Title: *Grant's Atlas of Anatomy, 12th Edition*

Copyright ©2009 Lippincott Williams & Wilkins

> Table of Contents > Chapter 5 - Lower Limb > 5.16 Femoral sheath and inguinal ligament

---

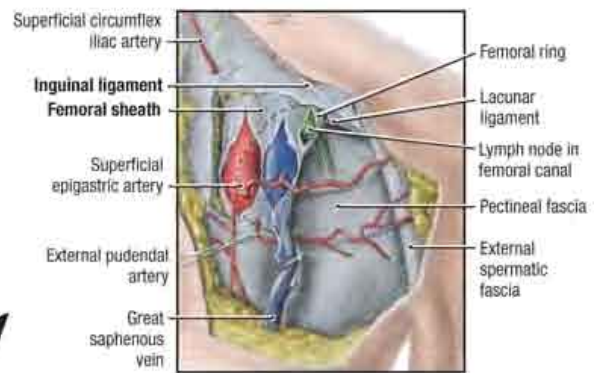
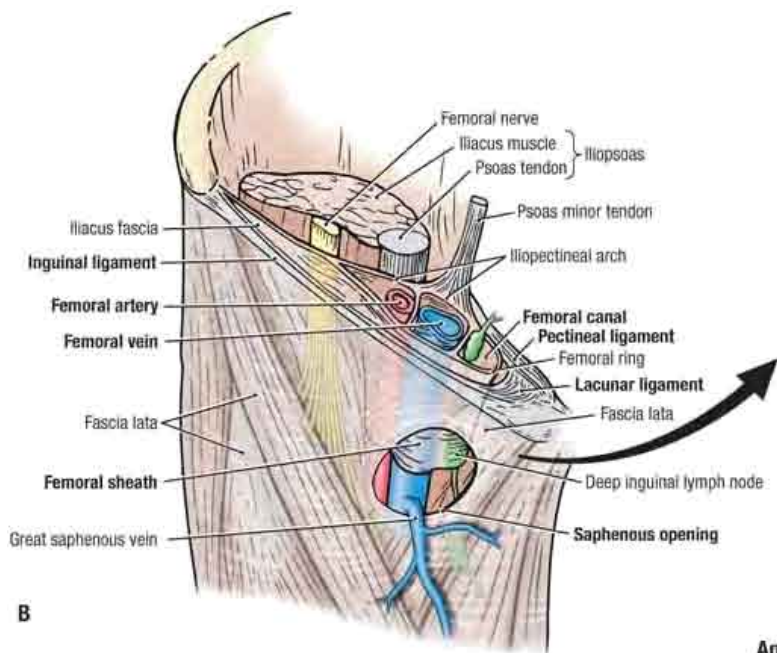
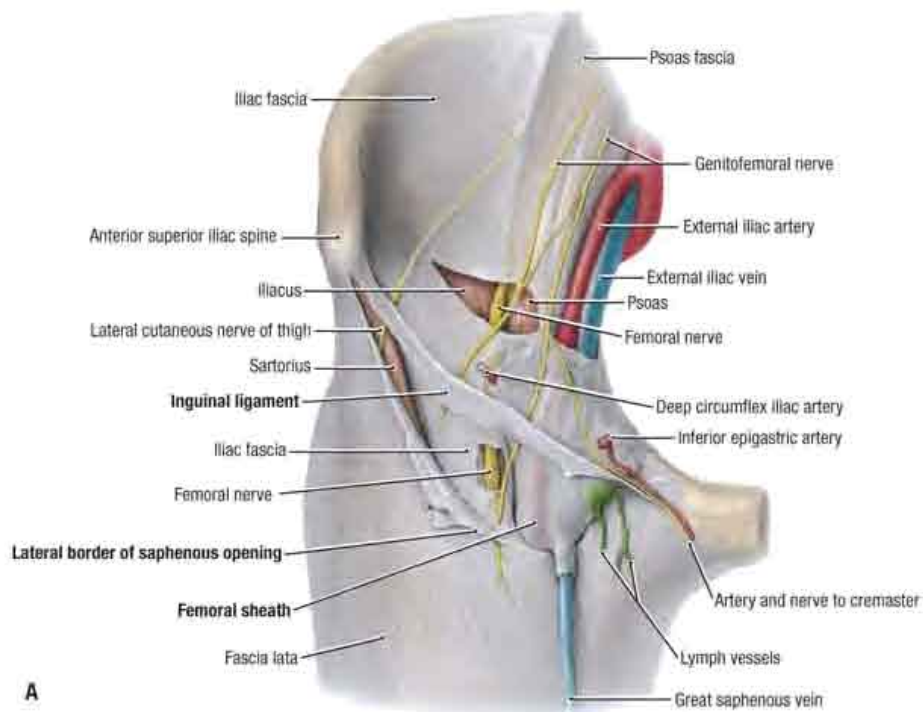
## 5.16 Femoral sheath and inguinal ligament

*Part of* "Chapter 5 - Lower Limb "

A. Dissection. B. Schematic illustration. The femoral sheath contains the femoral artery, vein, and lymph vessels, but the femoral nerve, lying posterior to the iliacus fascia, is outside the femoral sheath. C. Femoral sheath and femoral ring.

---

P.372



**Anterior views**



Authors: Agur, Anne M.R.; Dalley, Arthur F.

Title: *Grant's Atlas of Anatomy, 12th Edition*

Copyright ©2009 Lippincott Williams & Wilkins

> Table of Contents > Chapter 5 - Lower Limb > 5.17 Structures passing to/from femoral triangle via retroinguinal passage

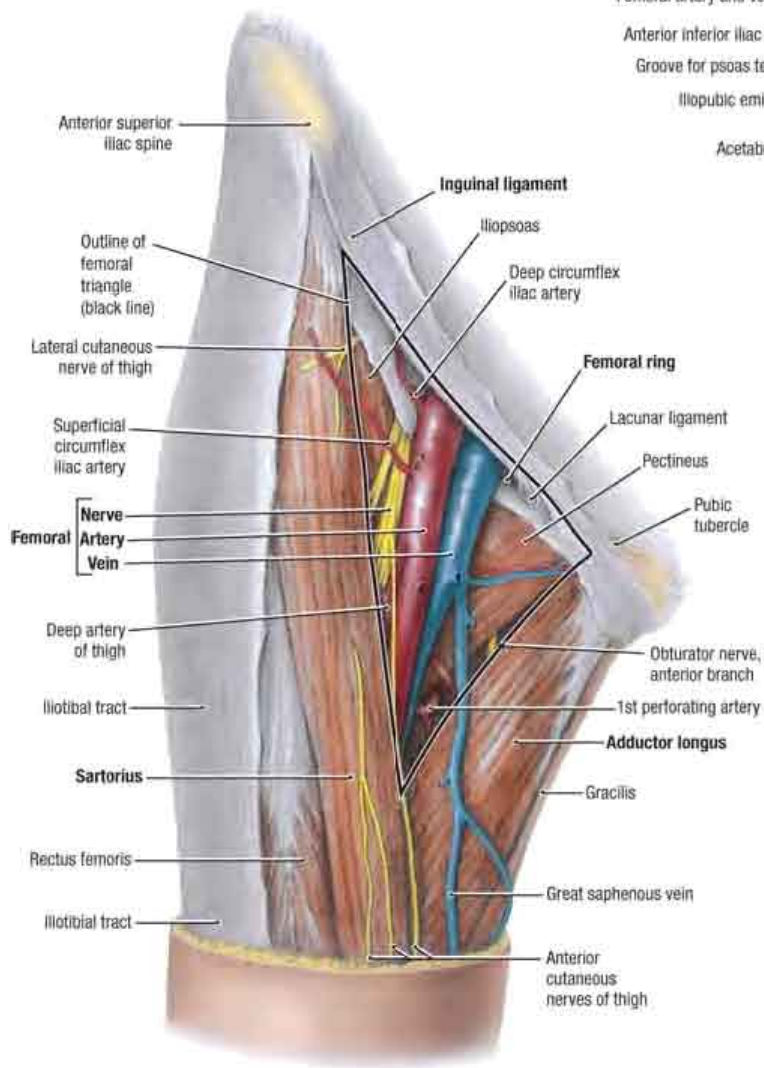
---

## 5.17 Structures passing to/from femoral triangle via retroinguinal passage

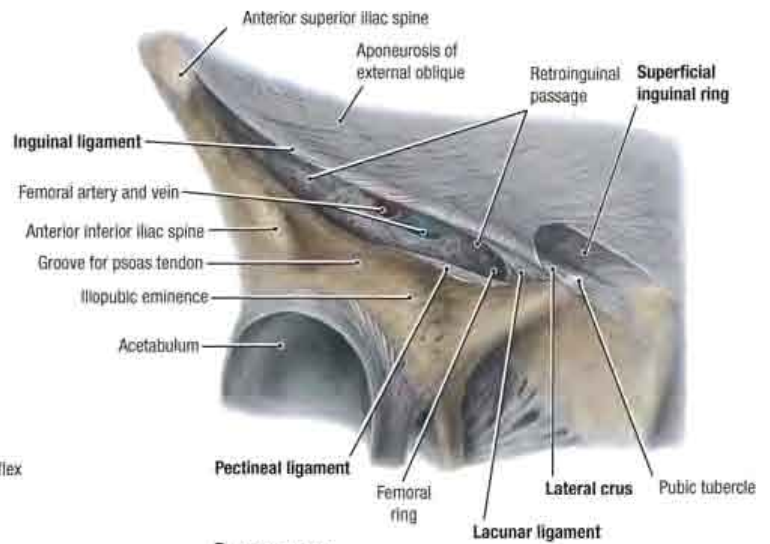
*Part of* "Chapter 5 - Lower Limb "

A. Dissection. The boundaries of the femoral triangle are the inguinal ligament superiorly (base of triangle), the medial border of the sartorius (lateral side), and the lateral border of the adductor longus (medial side). The point at which the lateral and medial sides converge inferiorly forms the apex. The femoral triangle is bisected by the femoral vessels. B. Retroinguinal passage between the inguinal ligament anteriorly and the bony pelvis posteriorly. C. The iliopsoas muscle, the femoral nerve, artery, and vein, and the lymphatic vessels draining the inguinal nodes pass deep to the inguinal ligament to enter the anterior thigh or return to the trunk.

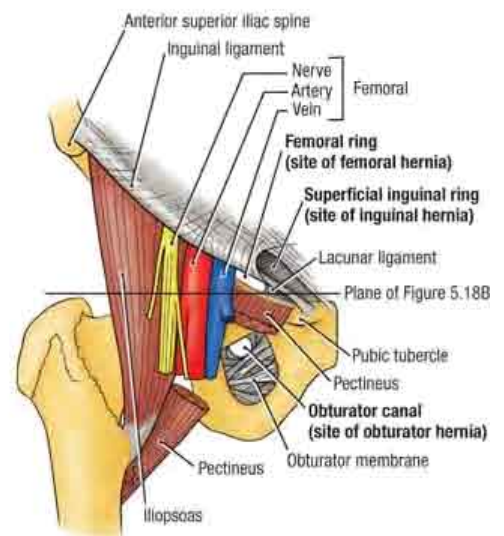
Three potential sites for hernia formation are indicated. Pulsations of the femoral artery can be felt distal to the inguinal ligament, midway between the anterior superior iliac spine and the pubic tubercle.



**A. Anterior View**



**B. Anterior View**



**C. Anterior View**

Authors: Agur, Anne M.R.; Dalley, Arthur F.

Title: *Grant's Atlas of Anatomy, 12th Edition*

Copyright ©2009 Lippincott Williams & Wilkins

> Table of Contents > Chapter 5 - Lower Limb > 5.18 Floor of femoral canal and retroinguinal passage

---

## 5.18 Floor of femoral canal and retroinguinal passage

*Part of* "Chapter 5 - Lower Limb "

A. Dissection. Portions of the sartorius muscle, femoral vessels, and femoral nerve have been removed revealing the floor of the femoral triangle, formed by the iliopsoas laterally and the pectineus medially. At the apex of the triangle the femoral vessels, saphenous nerve, and the nerve to the vastus medialis pass deep to the sartorius into the adductor (subsartorial) canal. B. Transverse section of the femoral triangle at the level of head of femur. (Level of section is indicated in Fig. 5.17C. ) The ilio-psoas and femoral nerve traverse the retroinguinal passage and femoral triangle in a fascial sheath separate from the femoral vessels, which are contained within the femoral sheath. C. Schematic illustration of course of femoral vessels. The adductor canal extends from the triangle's apex to the adductor hiatus, by which the vessels enter and leave the popliteal fossa.



**Authors:** Agur, Anne M.R.; Dalley, Arthur F.

**Title:** *Grant's Atlas of Anatomy, 12th Edition*

Copyright ©2009 Lippincott Williams & Wilkins

> Table of Contents > Chapter 5 - Lower Limb > 5.19 Surface anatomy of anterior and medial aspects of thigh

---

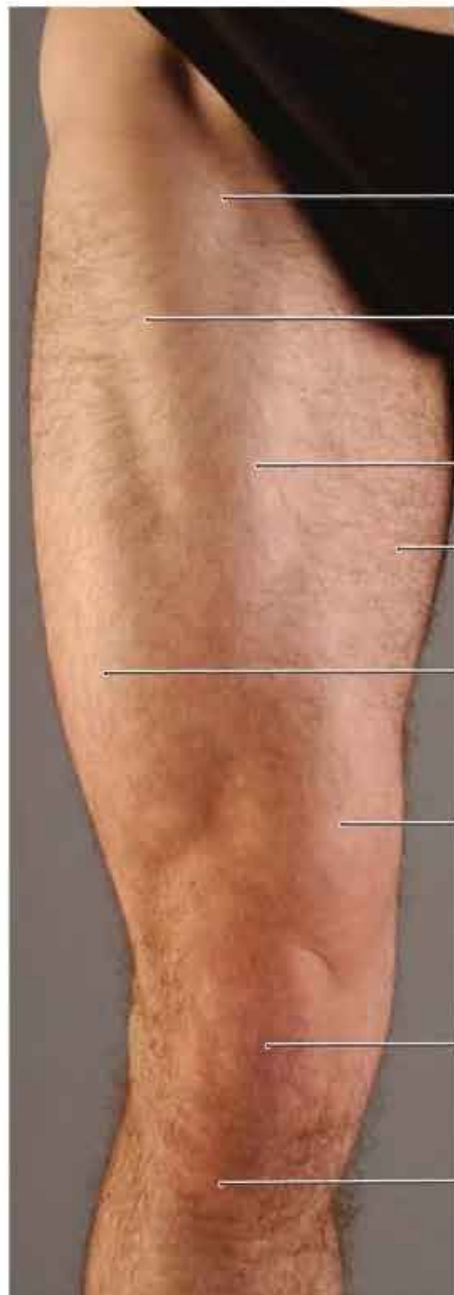## 5.19 Surface anatomy of anterior and medial aspects of thigh

*Part of* "Chapter 5 - Lower Limb "

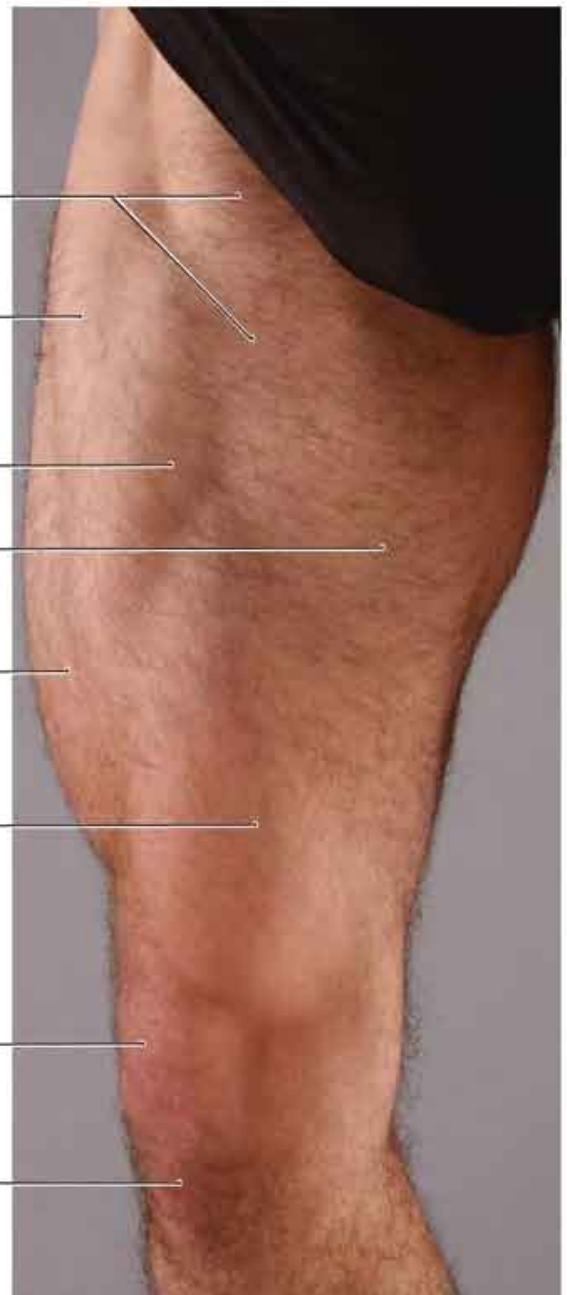---

P.375





**A. Anterior View**



**B. Anteromedial View**

Sartorius

Rectus femoris

Vastus intermedius

Adductor longus

Vastus lateralis

Vastus medialis

Patella

Patellar ligament

Authors: Agur, Anne M.R.; Dalley, Arthur F.

Title: *Grant's Atlas of Anatomy, 12th Edition*

Copyright ©2009 Lippincott Williams & Wilkins

> Table of Contents > Chapter 5 - Lower Limb > 5.20 Anterior and medial thigh muscles

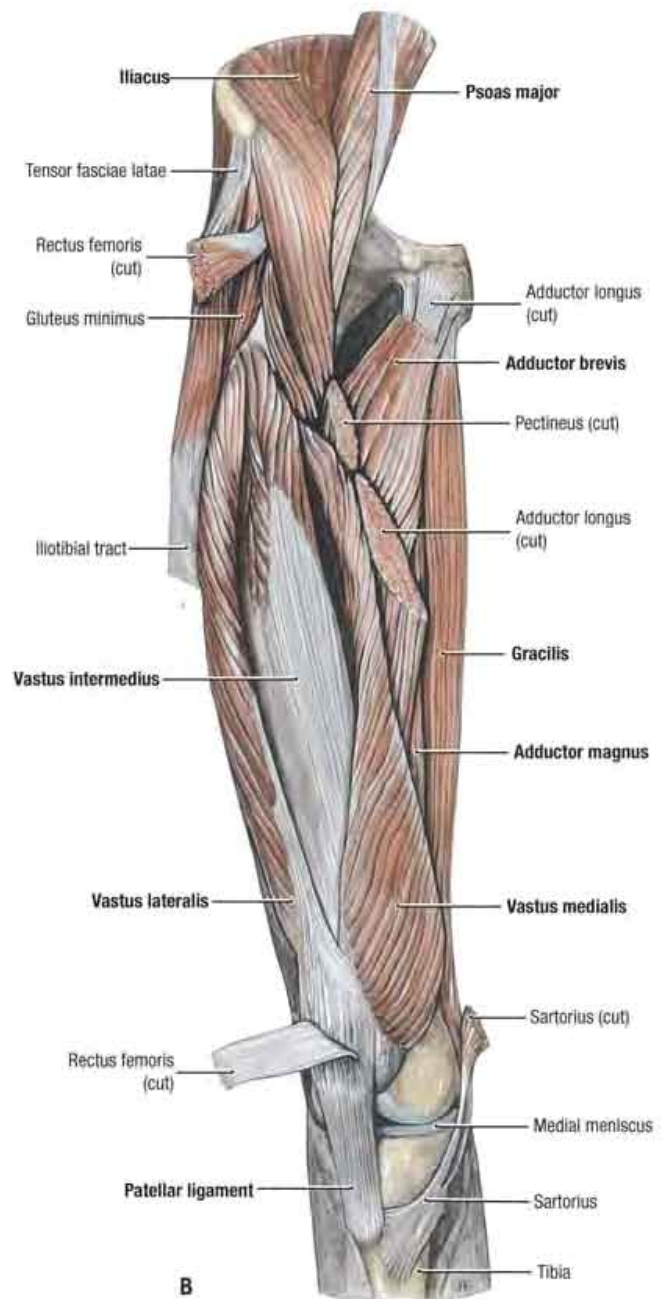
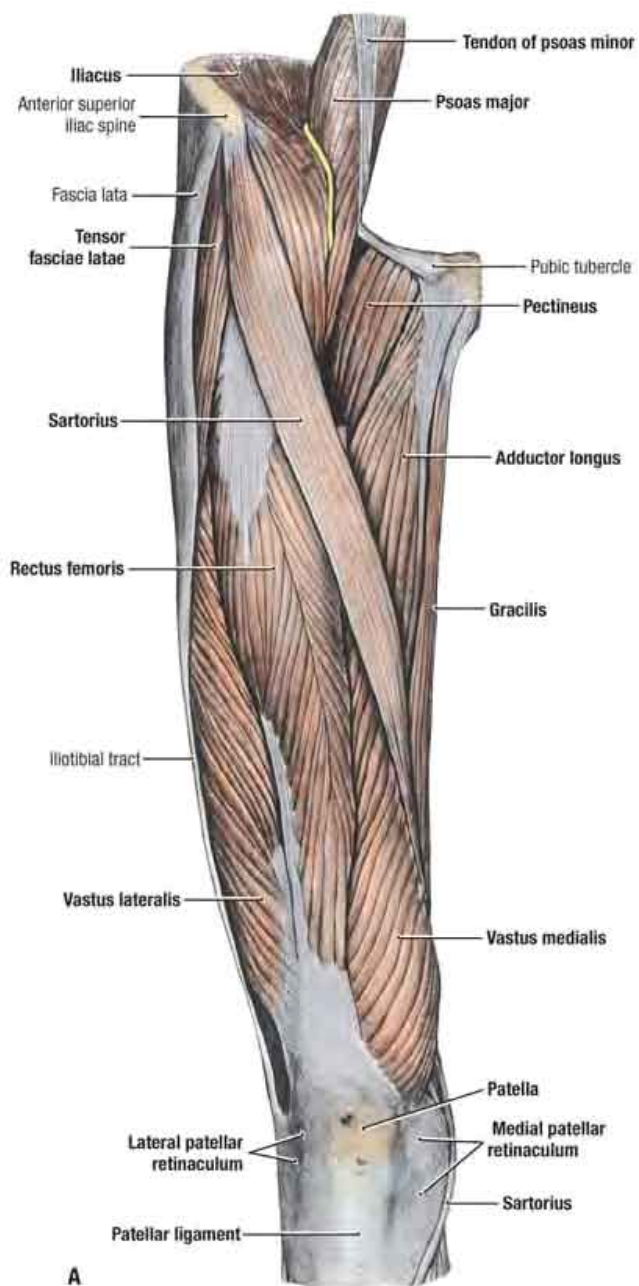
---

## 5.20 Anterior and medial thigh muscles

*Part of* "Chapter 5 - Lower Limb "

A. Superficial dissection. B. Deep dissection. The central portions of the muscle bellies of the sartorius, rectus femoris, pectineus, and adductor longus muscles have been removed.

Weakness of the vastus medialis or vastus lateralis, resulting from arthritis or trauma to the knee joint, for example, can result in abnormal patellar movement and loss of joint stability.



Anterior Views

Authors: Agur, Anne M.R.; Dalley, Arthur F.

Title: *Grant's Atlas of Anatomy, 12th Edition*

Copyright ©2009 Lippincott Williams & Wilkins

> Table of Contents > Chapter 5 - Lower Limb > 5.21 Muscles of medial aspect of thigh

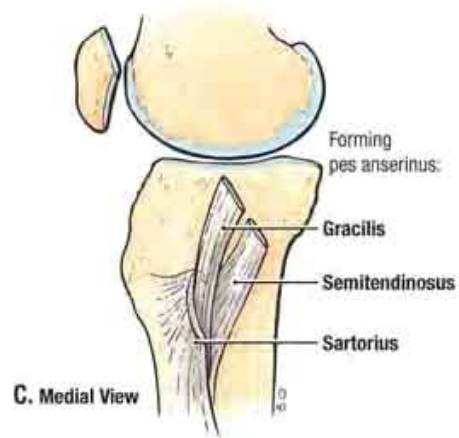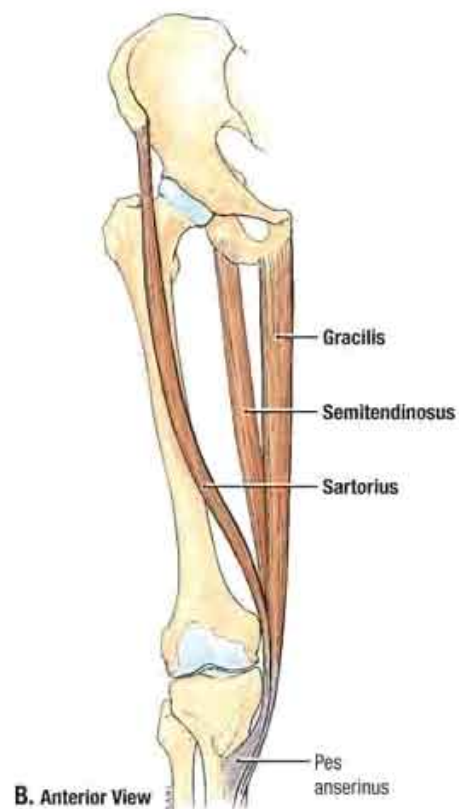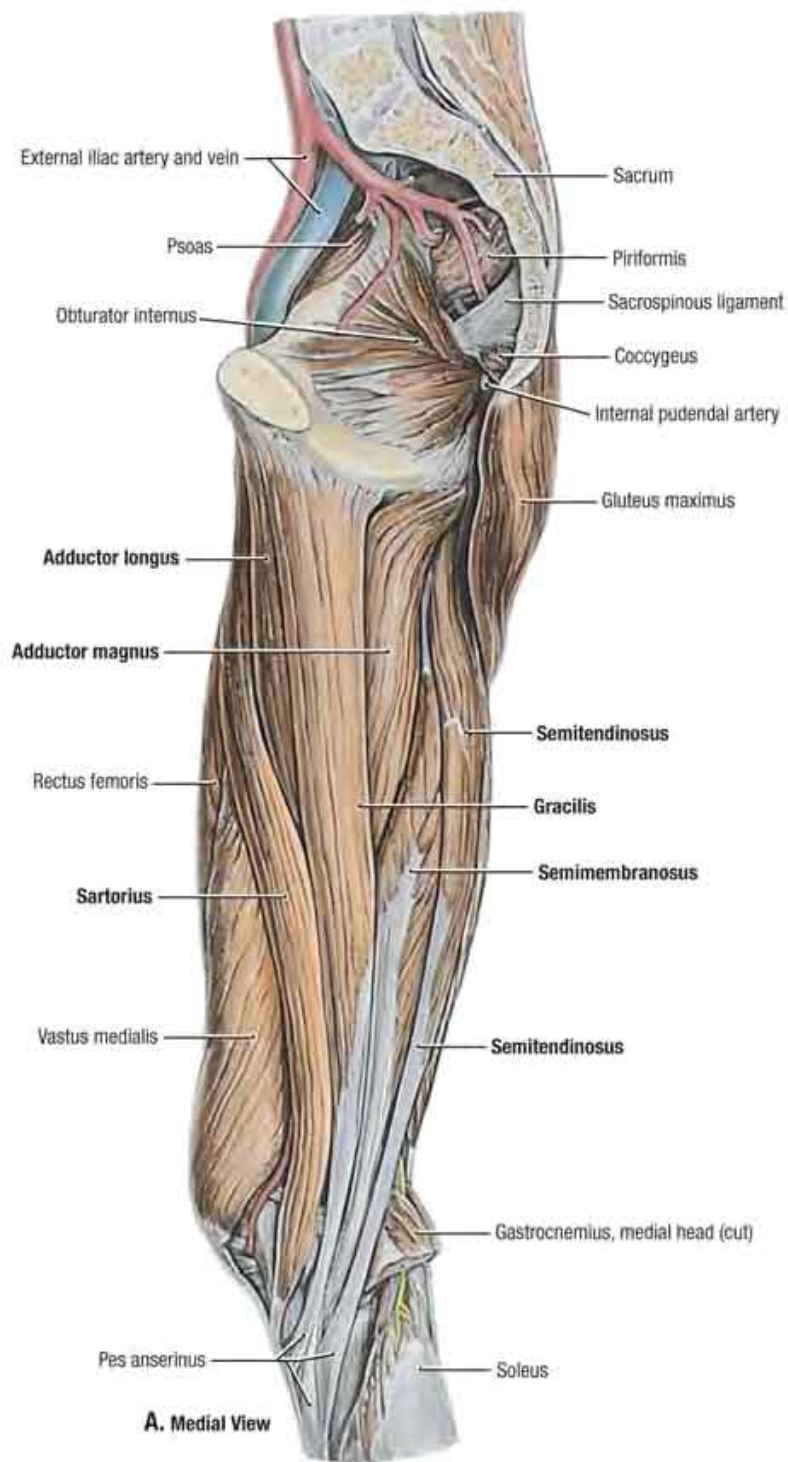
---

## 5.21 Muscles of medial aspect of thigh

*Part of* "Chapter 5 - Lower Limb "

A. Dissection. B. Muscular tripod. The sartorius, gracilis, and semitendinosus muscles form an inverted tripod arising from three different components of the hip bone. These muscles course within three different compartments, perform three different functions, and are innervated by three different nerves yet share a common distal attachment. C. Distal attachment of sartorius, gracilis, and semitendinosus muscles. All three tendons become thin and aponeurotic and are collectively referred to as the pes anserinus.

The gracilis is a relatively weak member of the adductor group and hence can be removed without noticeable loss of its actions on the leg. Surgeons often transplant the gracilis, or part of it, with its nerve and blood vessels to replace a damaged muscle in the hand, for example.





Authors: Agur, Anne M.R.; Dalley, Arthur F.  
Title: *Grant's Atlas of Anatomy, 12th Edition*  
Copyright ©2009 Lippincott Williams & Wilkins

> Table of Contents > Chapter 5 - Lower Limb > 5.22 Bones of the thigh and proximal leg

## 5.22 Bones of the thigh and proximal leg

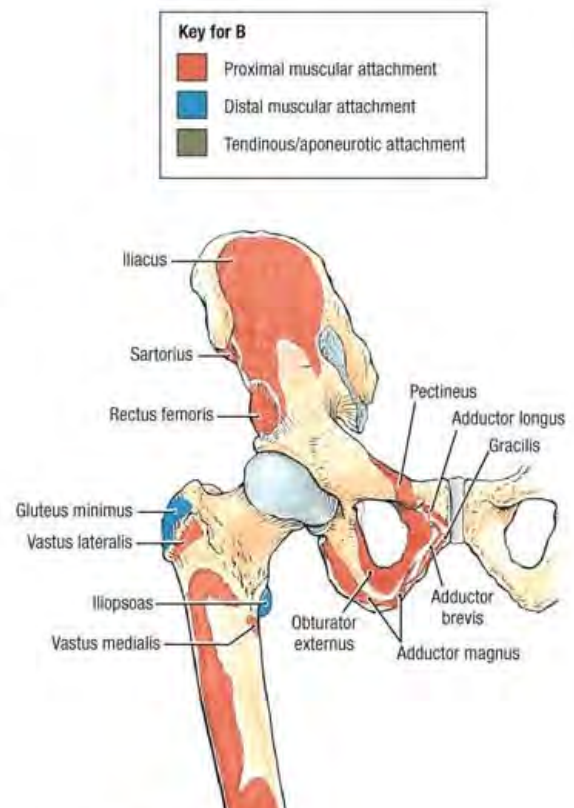
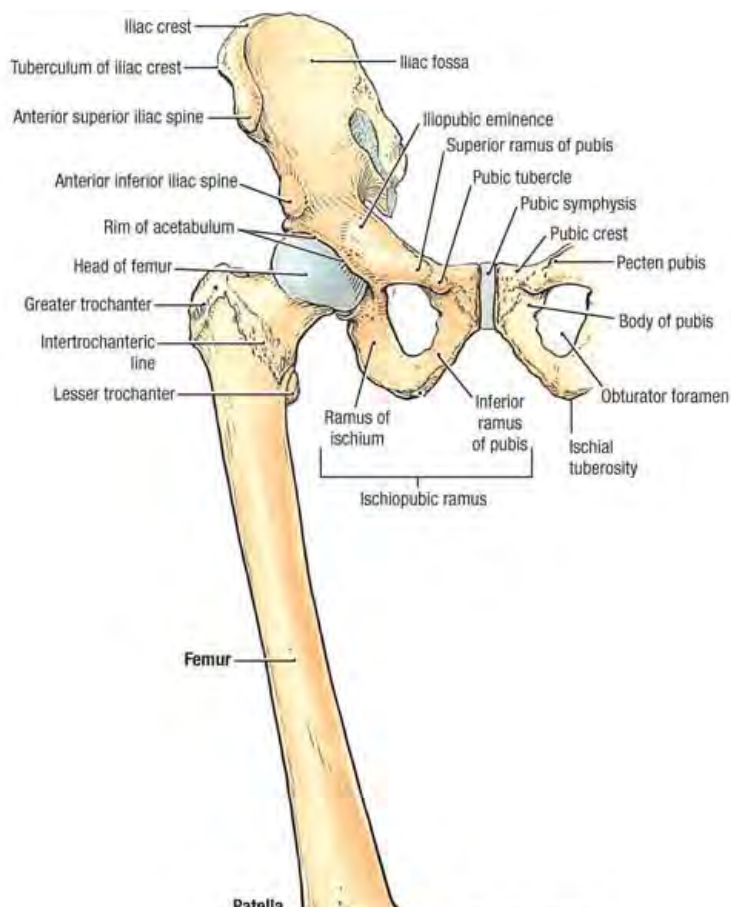
Part of "Chapter 5 - Lower Limb "

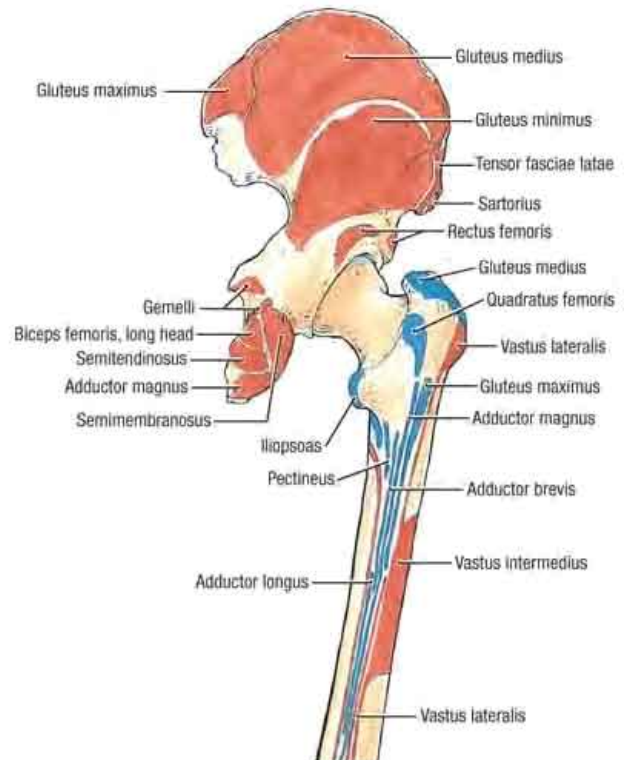
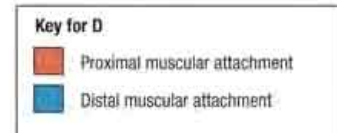
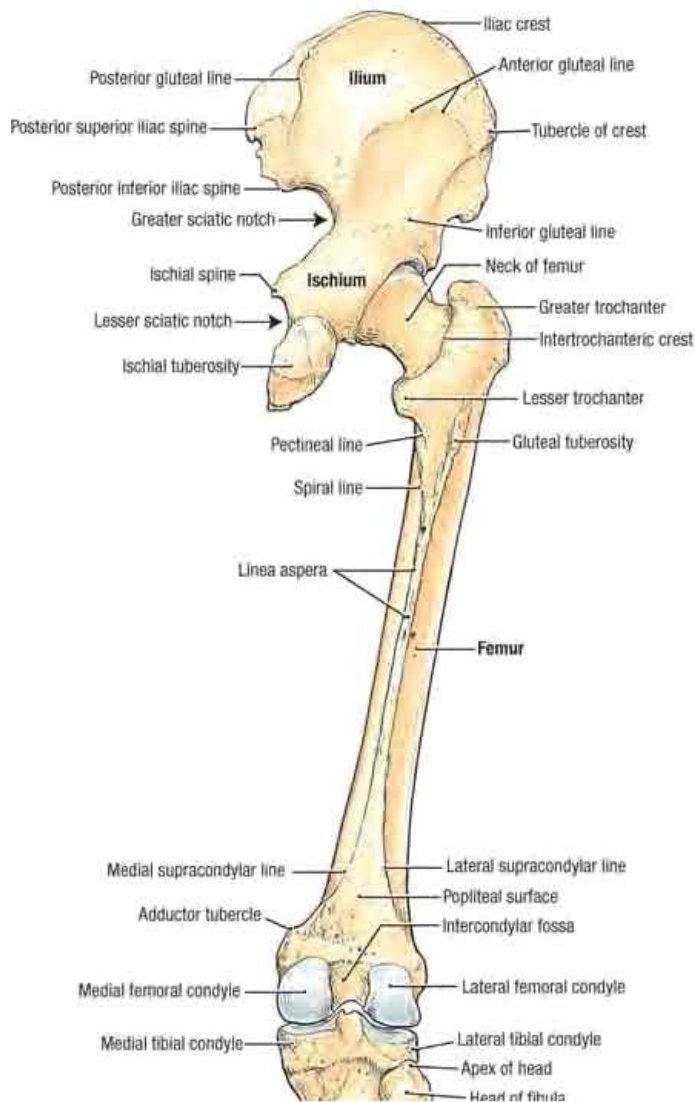
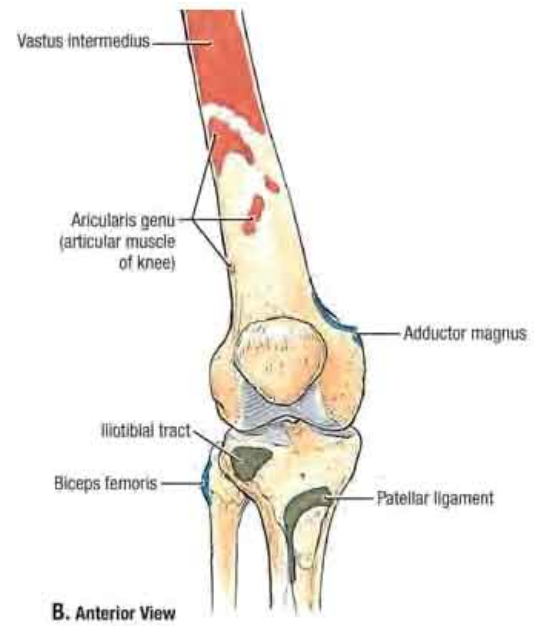
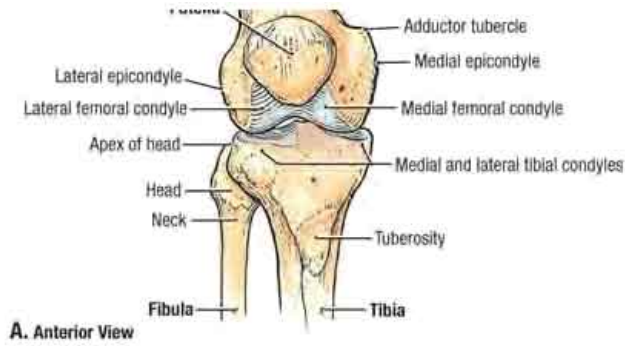
A. Bony features. B. Muscle attachment sites.

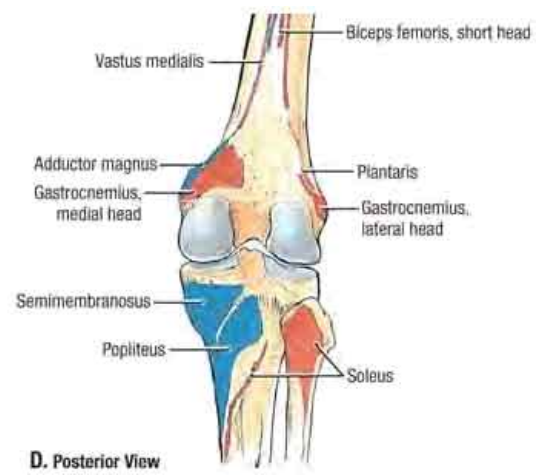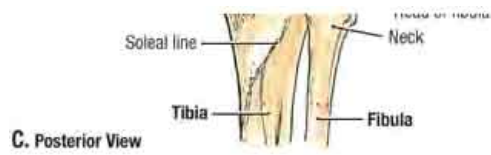
P.381

C. Bony features. D. Muscle attachment sites.

P.382







Authors: Agur, Anne M.R.; Dalley, Arthur F.

Title: *Grant's Atlas of Anatomy, 12th Edition*

Copyright ©2009 Lippincott Williams & Wilkins

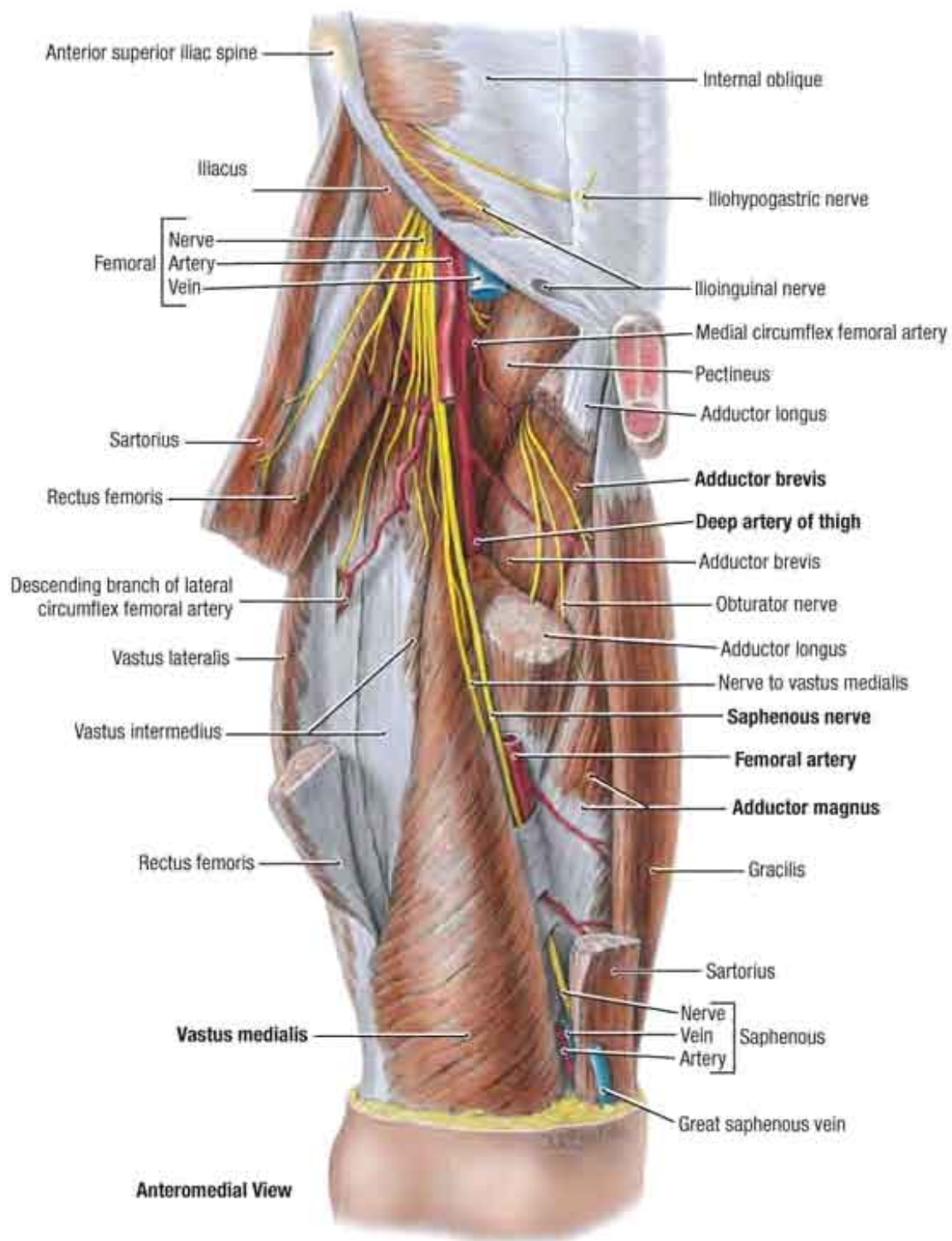
> Table of Contents > Chapter 5 - Lower Limb > 5.23 Anteromedial aspect of thigh

---

## 5.23 Anteromedial aspect of thigh

*Part of* "Chapter 5 - Lower Limb"

- The limb is rotated laterally.
- The femoral nerve breaks up into several nerves on entering the thigh.
- The femoral artery lies between two motor territories: that of the obturator nerve, which is medial, and that of the femoral nerve, which is lateral. No motor nerve crosses anterior to the femoral artery, but the twig to the pectineus muscle crosses posterior to the femoral artery.
- The nerve to the vastus medialis muscle and the saphenous nerve accompany the femoral artery into the adductor canal. The saphenous nerve and artery and their anastomotic accompanying vein emerge from the canal distally between the sartorius and gracilis muscles.
- The deep artery of the thigh arises approximately 4 cm distal to the inguinal ligament, lies posterior to the femoral artery, and disappears posterior to the adductor longus muscle. It supplies the thigh through the medial and lateral circumflex femoral branches and the perforating arteries that pass through the adductor magnus muscle on their way to the posterior aspect of the thigh.





Authors: Agur, Anne M.R.; Dalley, Arthur F.

Title: *Grant's Atlas of Anatomy, 12th Edition*

Copyright ©2009 Lippincott Williams & Wilkins

> Table of Contents > Chapter 5 - Lower Limb > 5.24 Lateral aspect of thigh

---

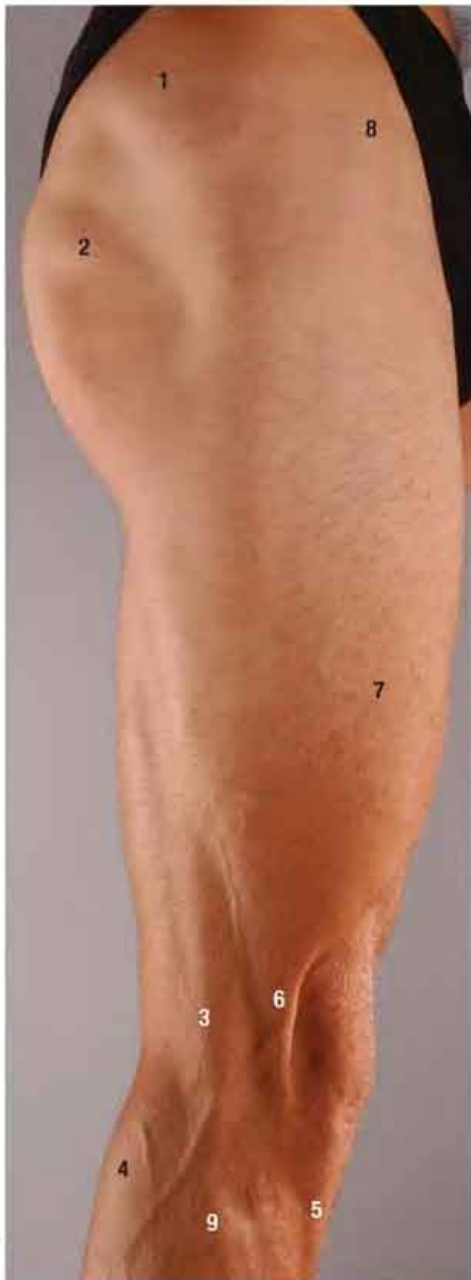## 5.24 Lateral aspect of thigh

*Part of* "Chapter 5 - Lower Limb "

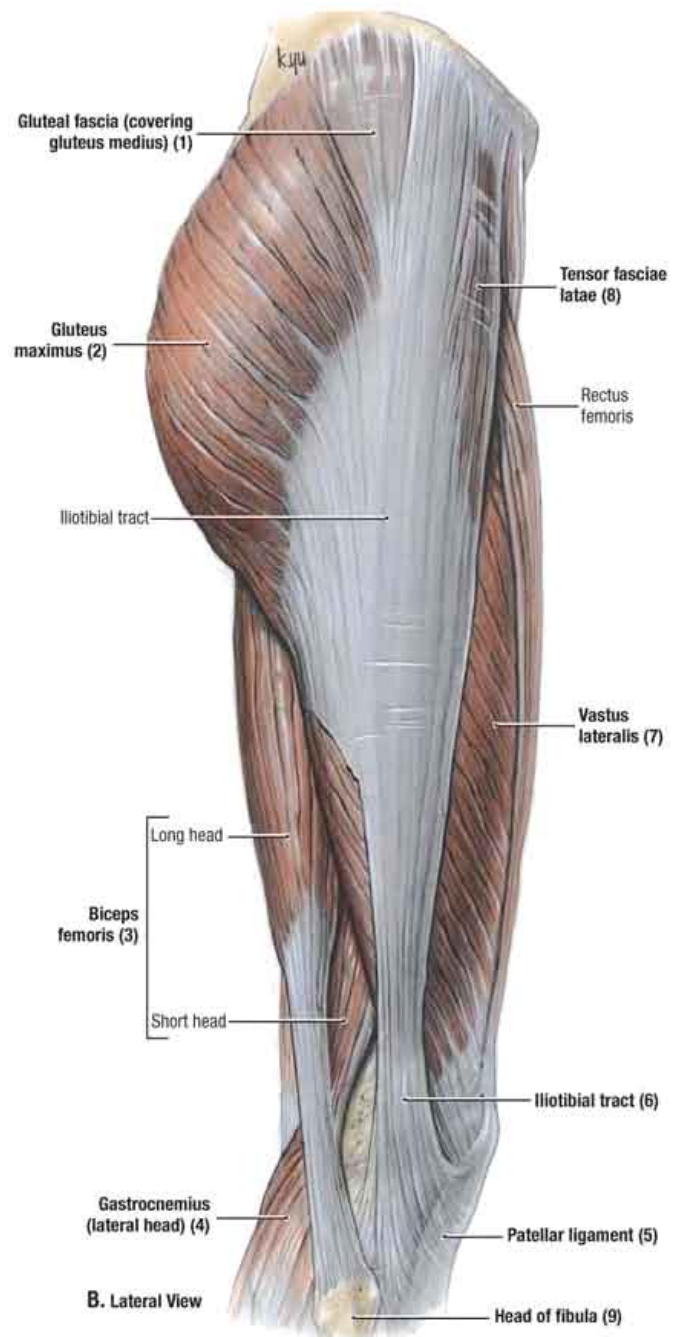
A. Surface anatomy (*numbers* refer to structures in B ). B. Dissection showing the iliotibial tract, a thickening of the fascia lata, which serves as a tendon for the gluteus maximus and tensor fasciae latae. The iliotibial tract attaches to the anterolateral (Gerdy) tubercle of the lateral condyle of the tibia. The biceps femoris tendon attaches on the head of the fibula.

---

P.384



A. Lateral View



B. Lateral View

**Authors:** Agur, Anne M.R.; Dalley, Arthur F.

**Title:** *Grant's Atlas of Anatomy, 12th Edition*

Copyright ©2009 Lippincott Williams & Wilkins

> Table of Contents > Chapter 5 - Lower Limb > 5.25 Muscles of the gluteal region and posterior aspect of thigh

---

## 5.25 Muscles of the gluteal region and posterior aspect of thigh

*Part of* "Chapter 5 - Lower Limb "

A. Surface anatomy (*numbers* refer to structures in B ). B. Superficial dissection of muscles of gluteal region and posterior thigh (hamstring muscles consisting of semimembranosus, semitendinosus, and biceps femoris).

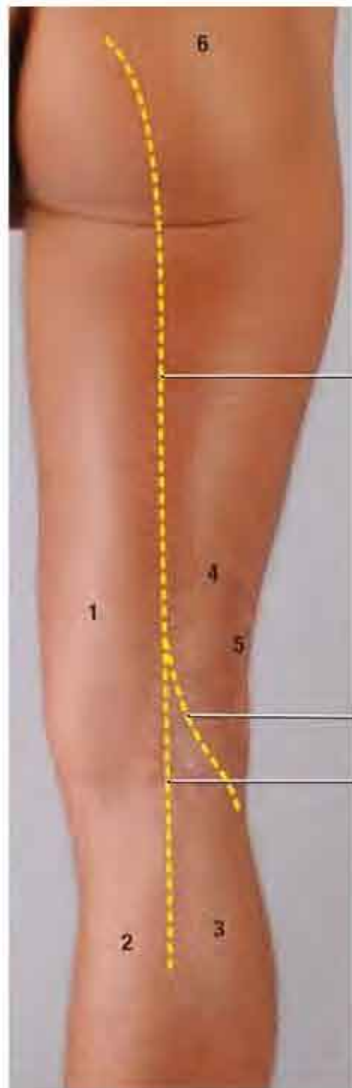
Hamstring strains (pulled and/or torn hamstrings) are common in running, jumping, and quick-start sports. The muscular exertion required to excel in these sports may tear part of the proximal attachments of the hamstrings from the ischial tuberosity.

P.385

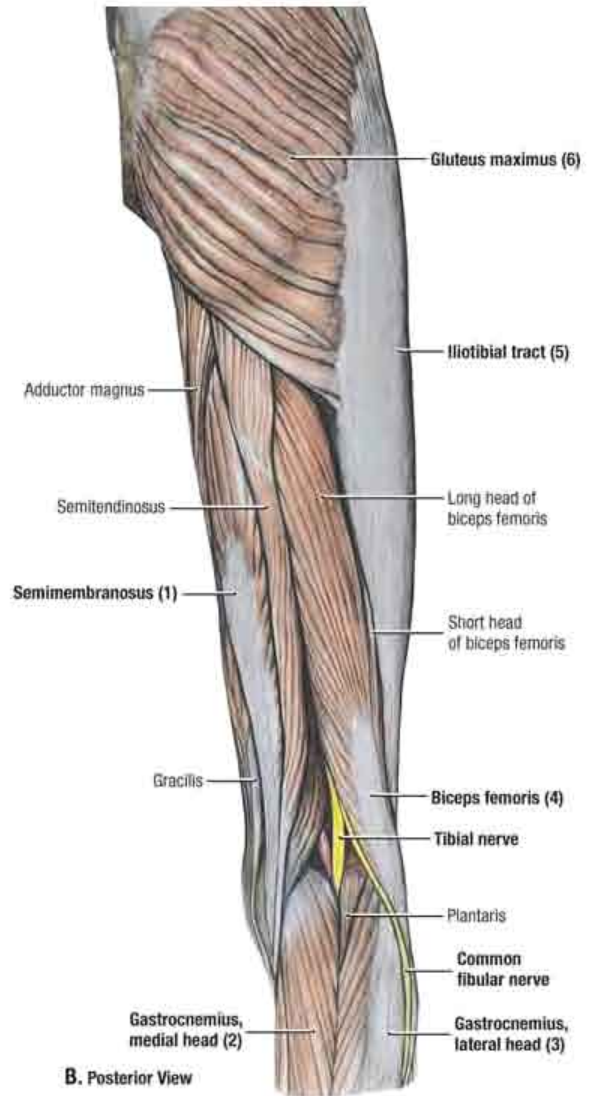
C. Muscles of gluteal region and posterior thigh with gluteus maximus reflected. D. Adductor magnus muscle. The adductor magnus is a large muscle with two parts: one belongs to the adductor group and the other to the hamstring group. The adductor part is innervated by the obturator nerve and the hamstring part by the tibial portion of the sciatic nerve. The trochanteric bursa separates the superior fibers of the gluteus maximus from the greater trochanter of the femur.

P.386

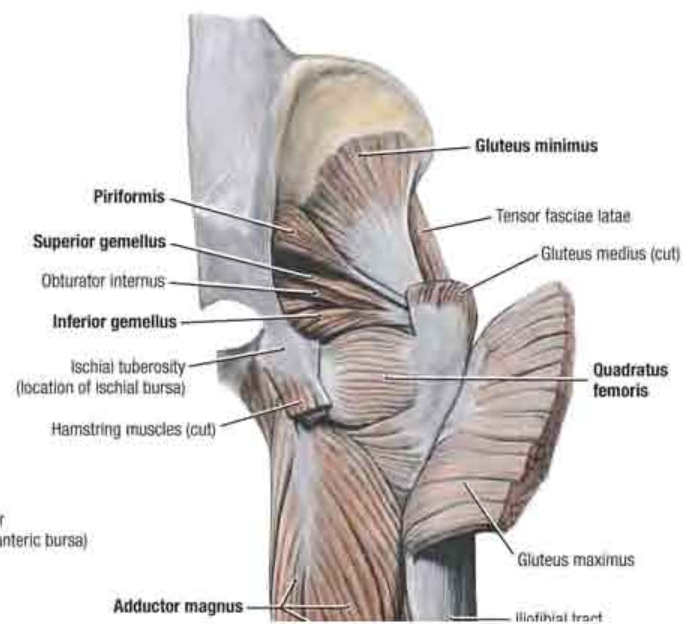
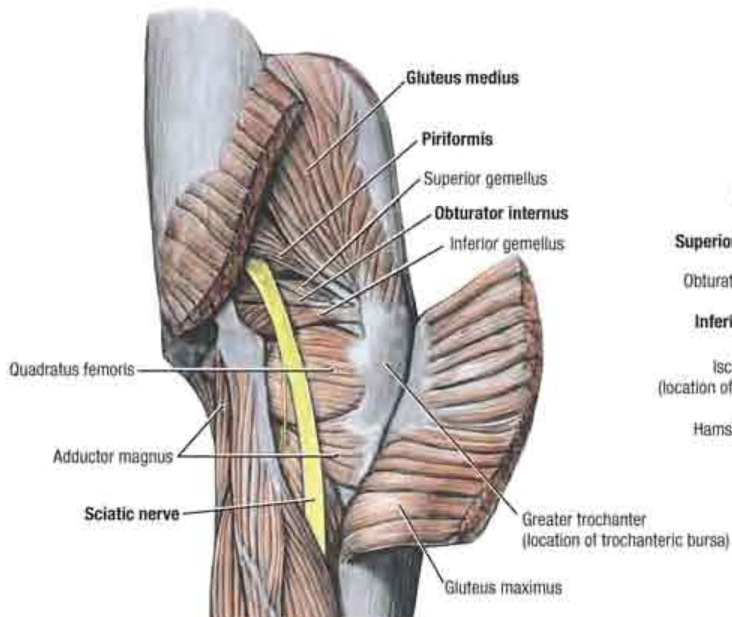


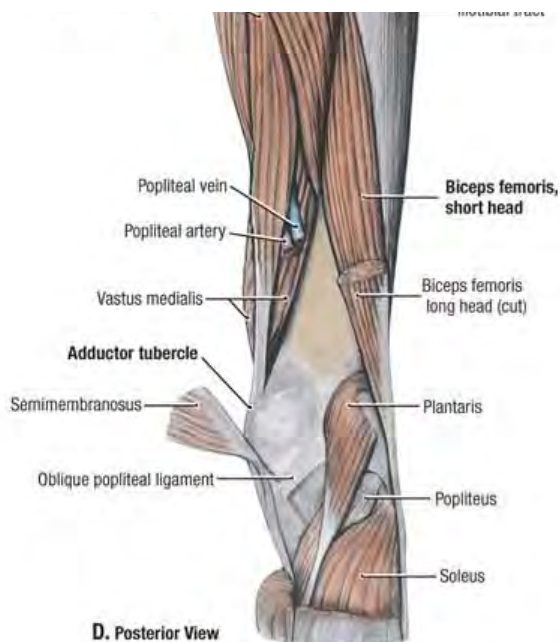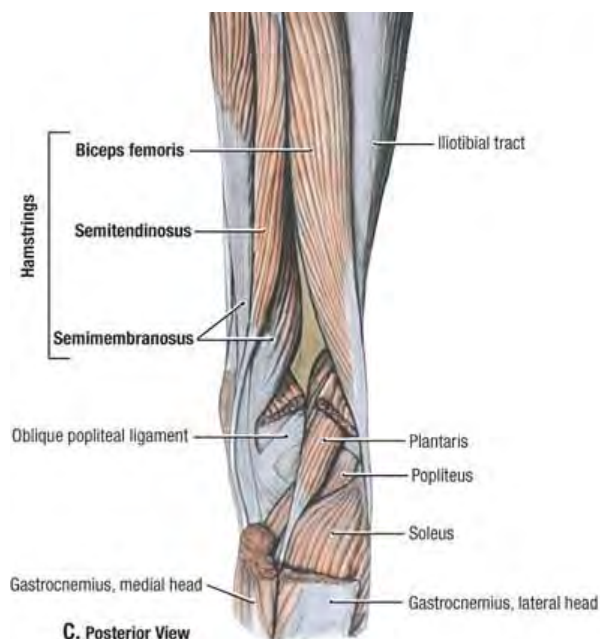


A. Posterior View



B. Posterior View





## Gluteus maximus

Ilium posterior to posterior

gluteal line, dorsal surface of sacrum and coccyx, sacrotuberous ligament

Iliotibial tract that inserts

into lateral condyle of tibia; some fibers to gluteal tuberosity

Inferior gluteal nerve (L5, S1, S2 )

Extends thigh and assists

in lateral rotation; steadies thigh and assists in raising trunk from flexed position

## Gluteus medius

External surface of ilium between anterior and posterior gluteal lines; gluteal fascia

Lateral surface of greater trochanter of femur

Superior gluteal nerve (L5 , S1)

Abducts and medially rotates thigh; keeps pelvis level when opposite leg is off ground and advances pelvis during swing phase of gait; TFL also contributes to stability of extended knee

## Gluteus minimus

External surface of ilium between anterior and inferior gluteal lines

Anterior surface of greater trochanter of femur

Tensor fasciae latae (TFL)

Anterior superior iliac spine and iliac crest

Iliotibial tract that attaches to lateral condyle (Gerdy tubercle) of tibia



Piriformis

Anterior surface of sacrum and sacrotuberous ligament

Superior border of greater trochanter of femur

Anterior rami of S1 and S2

Laterally rotate extended thigh and abduct flexed thigh; steady femoral head in acetabulum

Obturator internus

Pelvic surface of obturator membrane and surrounding bones

Medial surface of greater trochanter of femur by common tendons

Nerve to obturator internus (L5, S1) Nerve to quadratus femoris (L5, S1)

Superior gemellus

Ischial spine

Inferior gemellus

Ischial tuberosity

Quadratus femoris

Lateral border of ischial tuberosity

Quadratus tubercle on intertrochanteric crest of femur

Laterally rotates thigh,<sup>c</sup> steadies femoral head in acetabulum

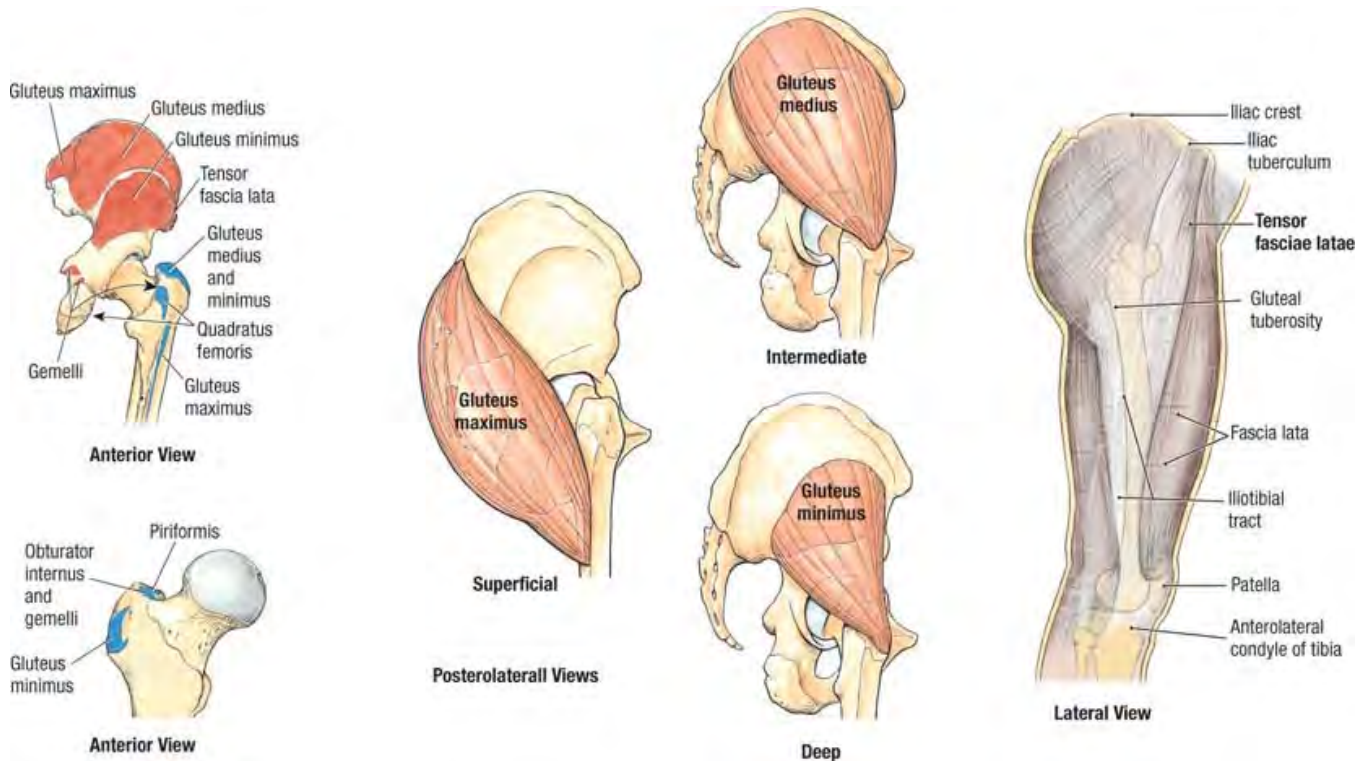
<sup>b</sup>See Figure 5.22 for muscle attachments.

<sup>b</sup>See Table 5.1 for explanation of segmental innervation.

<sup>c</sup>There are six lateral rotators of the thigh: piriformis, obturator internus, gemelli (superior and inferior), quadratus femoris, and obturator externus. These muscles also stabilize the hip joint.

Muscle	Proximal Attachment <sup>a</sup> (red)	Distal Attachment <sup>a</sup> (blue)	Innervation <sup>b</sup>	Main Actions
--------	---	--	--------------------------	-----------------

Table 5.4 Muscles of Gluteal Region



Semitendinosus

Ischial tuberosity

Medial surface of superior part of tibia

Tibial division of sciatic nerve (L5, S1, and S2)

Extend thigh; flex leg and rotate it medially; when thigh and leg are flexed, can extend trunk

Semimembranosus

Posterior part of medial condyle of tibia; reflected attachment forms oblique popliteal ligament to lateral femoral condyle

Biceps femoris

*Long head:* ischial tuberosity; *Short head:* linea aspera and lateral supracondylar line of femur

Lateral side of head of fibula; tendon is split at this site by fibular collateral ligament of knee

*Long head:* tibial division of sciatic nerve (L5, S1, and S2);

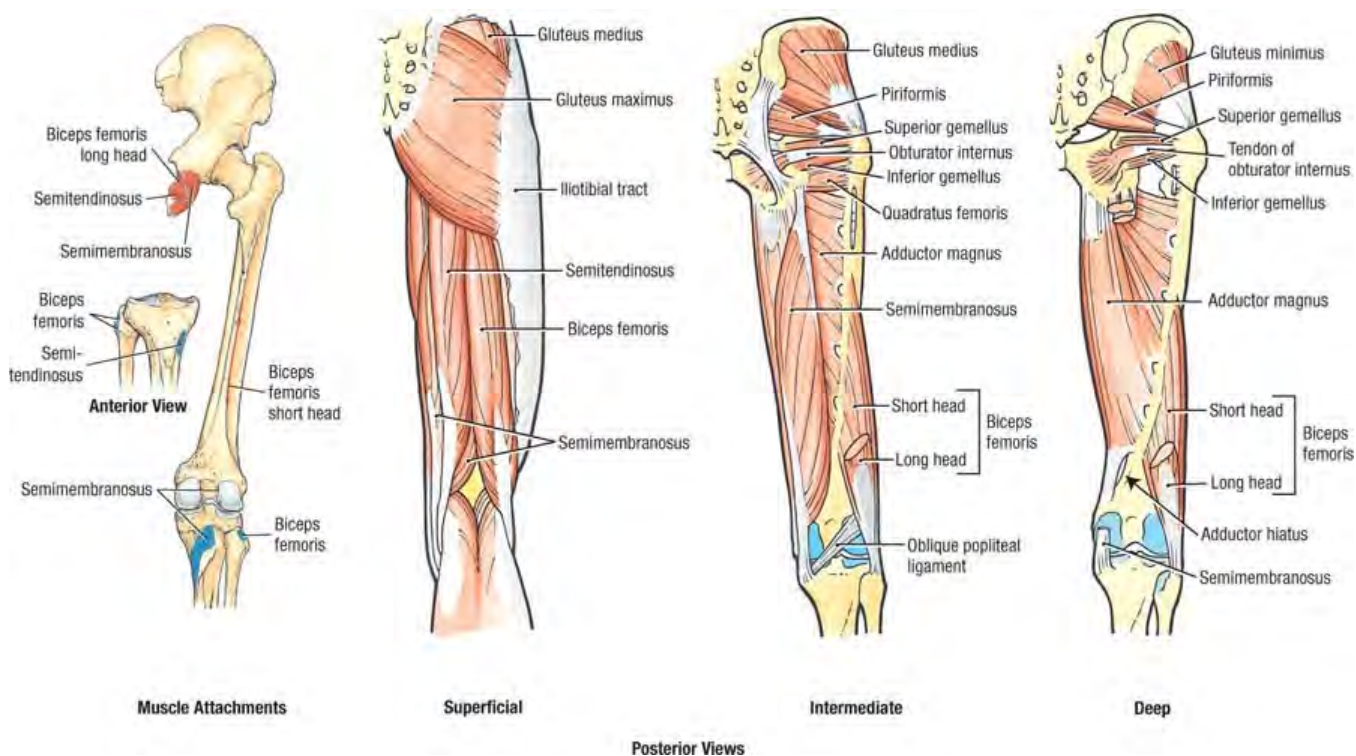
*Short head:* common fibular (peroneal) division of sciatic nerve (L5, S1 , and S2)  
 Flexes leg and rotates it laterally; extends thigh (e.g., when initiating a walking gait)

<sup>a</sup>See Figure 5.22 for muscle attachments.

<sup>b</sup>See Table 5.1 for explanation of segmental innervation.

Muscle <sup>a</sup>	Proximal Attachment <sup>a</sup> (red)	Distal Attachment <sup>a</sup> (blue)	Innervation <sup>b</sup>	Main Actions
Table 5.5 Muscles of Posterior Thigh (Hamstring)				

P.388



Authors: Agur, Anne M.R.; Dalley, Arthur F.

Title: *Grant's Atlas of Anatomy, 12th Edition*

Copyright ©2009 Lippincott Williams & Wilkins

> Table of Contents > Chapter 5 - Lower Limb > 5.26 Muscles of gluteal region and posterior aspect of thigh "IV

---

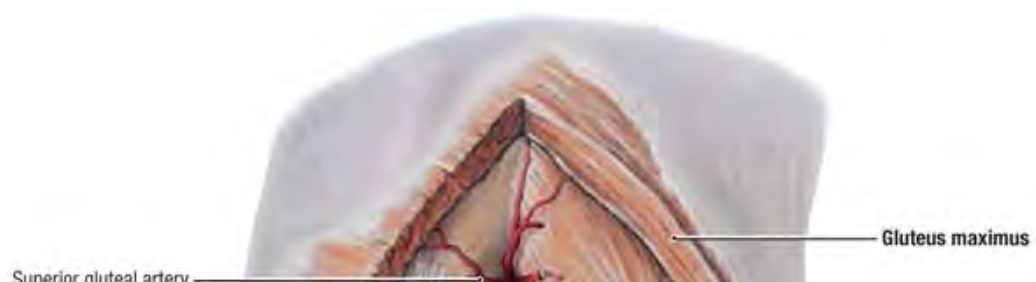
## 5.26 Muscles of gluteal region and posterior aspect of thigh "IV

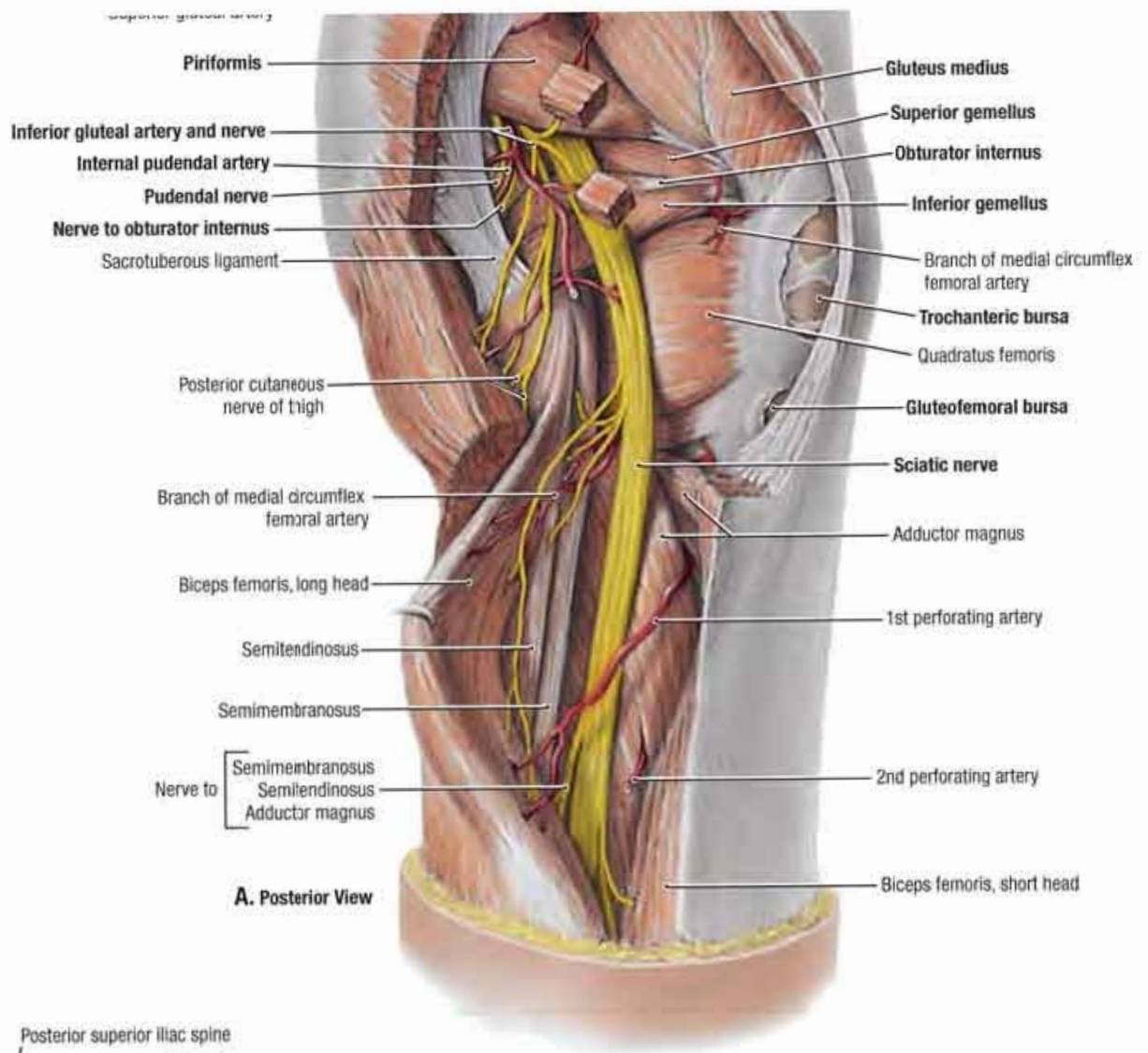
*Part of "Chapter 5 - Lower Limb "*

A. Dissection. The gluteus maximus muscle is split superiorly and inferiorly, and the middle part is excised; two cubes remain to identify its nerve. The gluteus maximus is the only muscle to cover the greater trochanter; it is aponeurotic and has underlying bursae where it glides on the trochanter (trochanteric bursa) and the aponeurosis of the vastus lateralis muscle (gluteofemoral bursa).

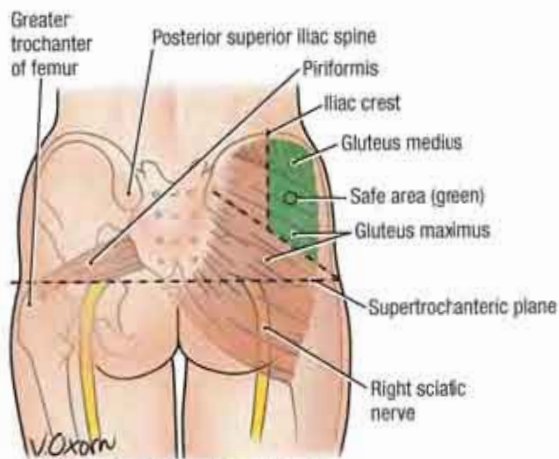
Diffuse deep pain in the lateral thigh region, especially during stair climbing or rising from a seated position, may be caused by trochanteric bursitis. This type of friction bursitis is characterized by point tenderness over the greater trochanter; however, the pain radiates along the iliotibial tract. B. Intragluteal injection. Injections can be made safely only into the superolateral part of the buttock, avoiding injury to the sciatic and gluteal nerves.

P.389





**A. Posterior View**



**B. Posterior View, Intragluteal Injection**



Authors: Agur, Anne M.R.; Dalley, Arthur F.

Title: *Grant's Atlas of Anatomy, 12th Edition*

Copyright ©2009 Lippincott Williams & Wilkins

> Table of Contents > Chapter 5 - Lower Limb > 5.27 Muscles of gluteal region and posterior aspect of thigh " V

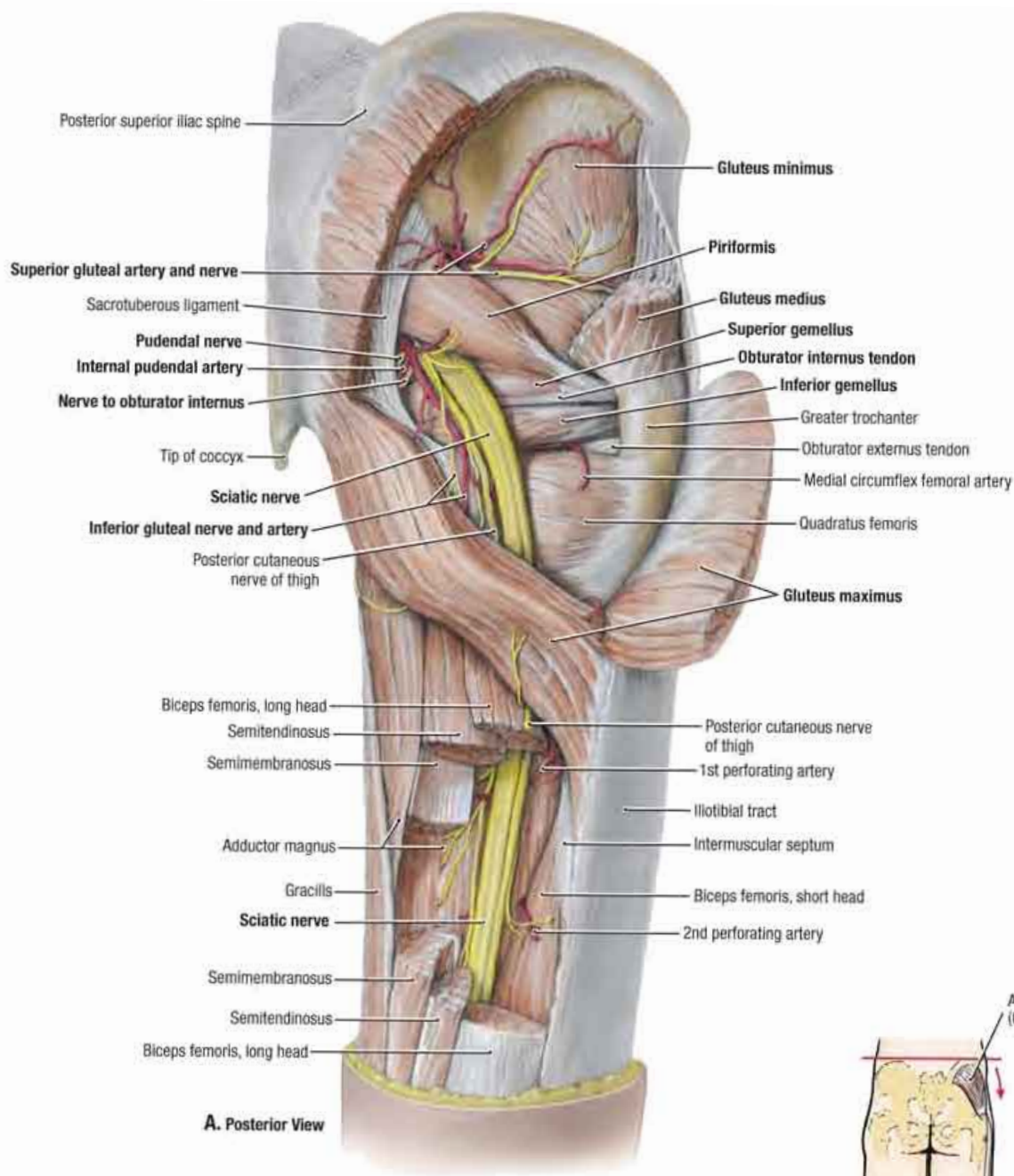
---

## 5.27 Muscles of gluteal region and posterior aspect of thigh " V

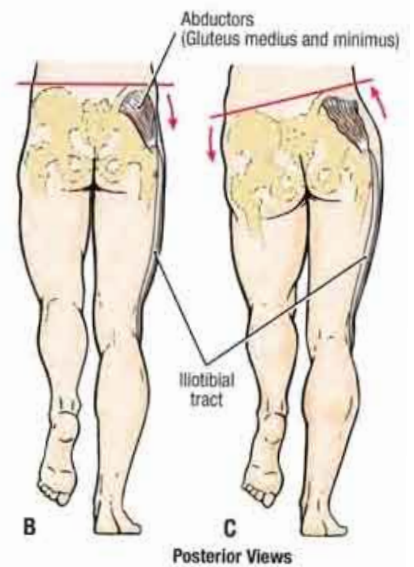*Part of* "Chapter 5 - Lower Limb "

A. The proximal three quarters of the gluteus maximus muscle is reflected, and parts of the gluteus medius and the three hamstring muscles are excised. The superior gluteal vessels and nerves emerge superior to the piriformis muscle; all other vessels and nerves emerge inferior to it.

B. When the weight is borne by one limb, the muscles on the supported side fix the pelvis so that it does not sag to the unsupported side, keeping the pelvis level. C. When the right abductors are paralyzed, owing to a lesion of the right superior gluteal nerve, fixation by these muscles is lost and the pelvis tilts to the unsupported left side (positive Trendelenburg sign).



**A. Posterior View**



Authors: Agur, Anne M.R.; Dalley, Arthur F.

Title: *Grant's Atlas of Anatomy, 12th Edition*

Copyright ©2009 Lippincott Williams & Wilkins

> Table of Contents > Chapter 5 - Lower Limb > 5.28 Lateral rotators of hip, sciatic nerve, and ligaments of gluteal region

---

## 5.28 Lateral rotators of hip, sciatic nerve, and ligaments of gluteal region

*Part of "Chapter 5 - Lower Limb "*

A. Piriformis and quadratus femoris. In the anatomical position the tip of the coccyx lies superior to the level of the ischial tuberosity and inferior to that of the ischial spine. The lateral border of the sciatic nerve lies midway between the lateral surface of the greater trochanter and the medial surface of the ischial tuberosity.

B. Relationship of sciatic nerve to piriformis muscle. Of 640 limbs studied in Dr. Grant's laboratory, in 87%, the tibial and fibular (peroneal) divisions passed inferior to the piriformis (*left*); in 12.2%, the fibular (peroneal) division passed through the piriformis (*center*); and in 0.5% the fibular (peroneal) division passed superior to the piriformis (*right*).

---

P.391

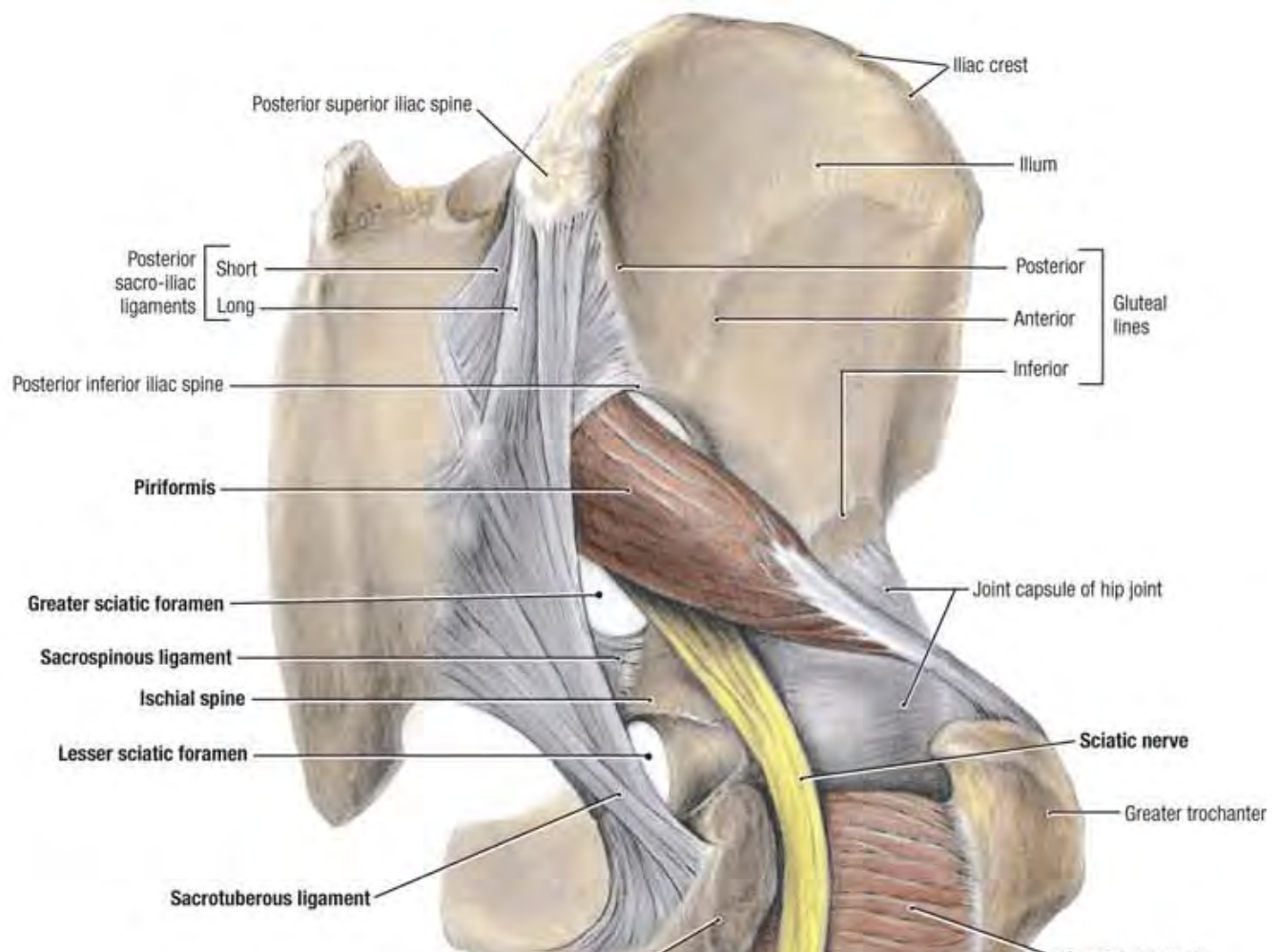
C. Obturator internus, obturator externus, and superior and inferior gemelli.

- The obturator internus is located partly in the pelvis, where it covers most of the lateral wall of the lesser pelvis. It leaves the pelvis through the lesser sciatic foramen, makes a right-angle turn, becomes tendinous, and receives the distal attachments of the gemelli before attaching to the medial surface of the greater trochanter (trochanteric fossa).
- The obturator externus extends from the external surface of the obturator membrane and surrounding bone of the pelvis to the posterior aspect of the

greater trochanter, passing directly under the acetabulum and neck of the femur.

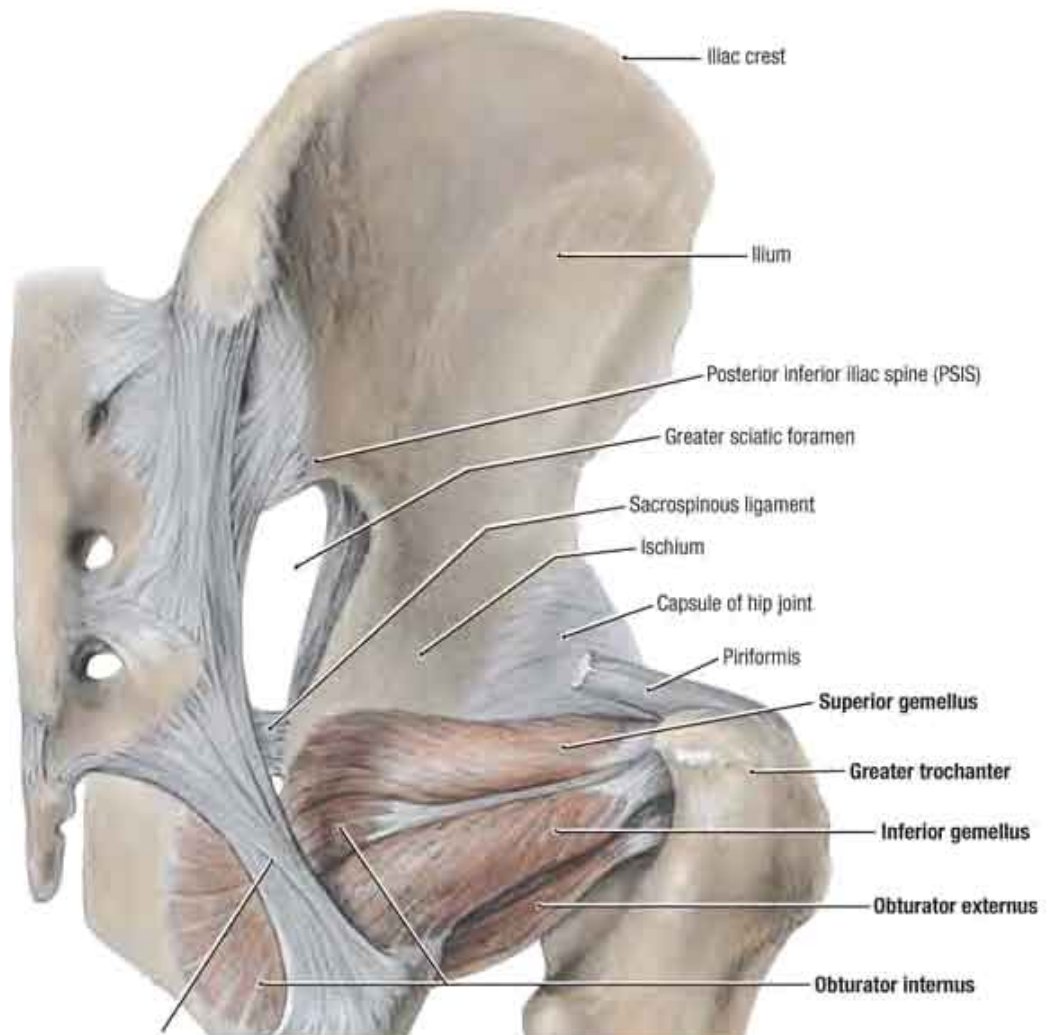
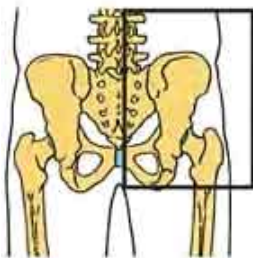
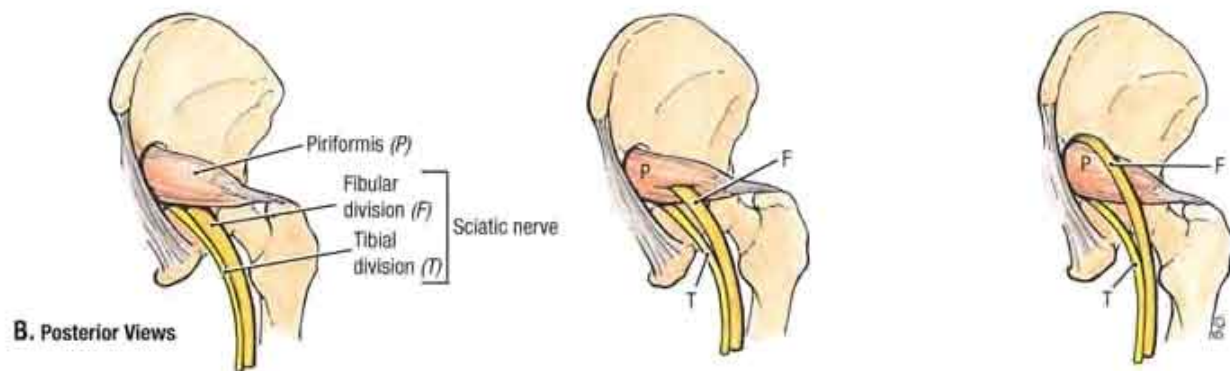
- Sensation conveyed by the sciatic nerve can be blocked by injecting an anesthetic agent a few centimeters inferior to the midpoint of the line joining the PSIS and the superior border of the greater trochanter. Paresthesia radiates to the foot because of anesthesia of the plantar nerves, which are terminal branches of the tibial nerve derived from the sciatic nerve.
- In the approximately 12% of people in whom the common fibular division of the sciatic nerve passes through the piriformis, this muscle may compress the nerve.

P.392

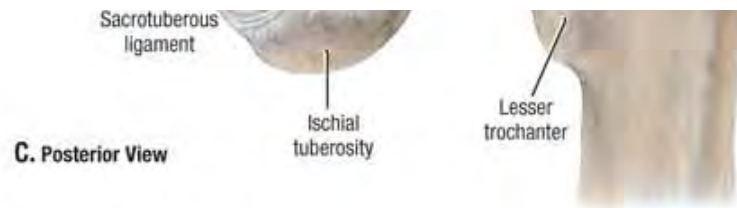



**A. Posterior View**







Clunial (superior, middle, and inferior)

*Superior:* posterior rami of L1–L3 nerves

*Middle:* posterior rami of S1–S3 nerves

*Inferior:* posterior cutaneous nerve of thigh

*Superior nerves* cross iliac crest; *middle nerves* exit through posterior sacral foramina and enter gluteal region; *inferior nerves* curve around inferior border of gluteus maximus  
Gluteal region as far laterally as greater trochanter

Sciatic

Sacral plexus (L4–S3)

Exits pelvis via greater sciatic foramen inferior to piriformis to enter gluteal region

No muscles in gluteal region

Posterior cutaneous nerve of thigh

Sacral plexus (S1–S3)

Exits pelvis via greater sciatic foramen inferior to piriformis, emerges from inferior border of gluteus maximus coursing deep to fascia lata

Skin of buttock via inferior cluneal branches, skin over posterior thigh and popliteal fossa; skin of lateral perineum and upper medial thigh via perineal branch

Superior gluteal

Anterior rami of L4–S1 nerves

Exits pelvis via greater sciatic foramen superior to piriformis; courses between gluteus medius and minimus

Gluteus medius, gluteus minimus, and tensor fasciae latae

Inferior gluteal

Anterior rami of L5–S2 nerves

Exits pelvis via greater sciatic foramen inferior to piriformis, dividing into multiple branches

Gluteus maximus

Nerve to quadratus femoris

Anterior rami of L4–S1 nerves

Exits pelvis via greater sciatic foramen deep to sciatic nerve  
 Posterior hip joint, inferior gemellus, and quadratus femoris  
 Pudendal

Anterior rami of S2–S4 nerves

Exits pelvis via greater sciatic foramen inferior to piriformis; descends posterior to sacrospinous ligament; enters perineum (pudendal canal) through lesser sciatic foramen  
 No structures in gluteal region (supplies most of perineum)

Nerve to obturator internus

Anterior rami of L5–S2 nerves

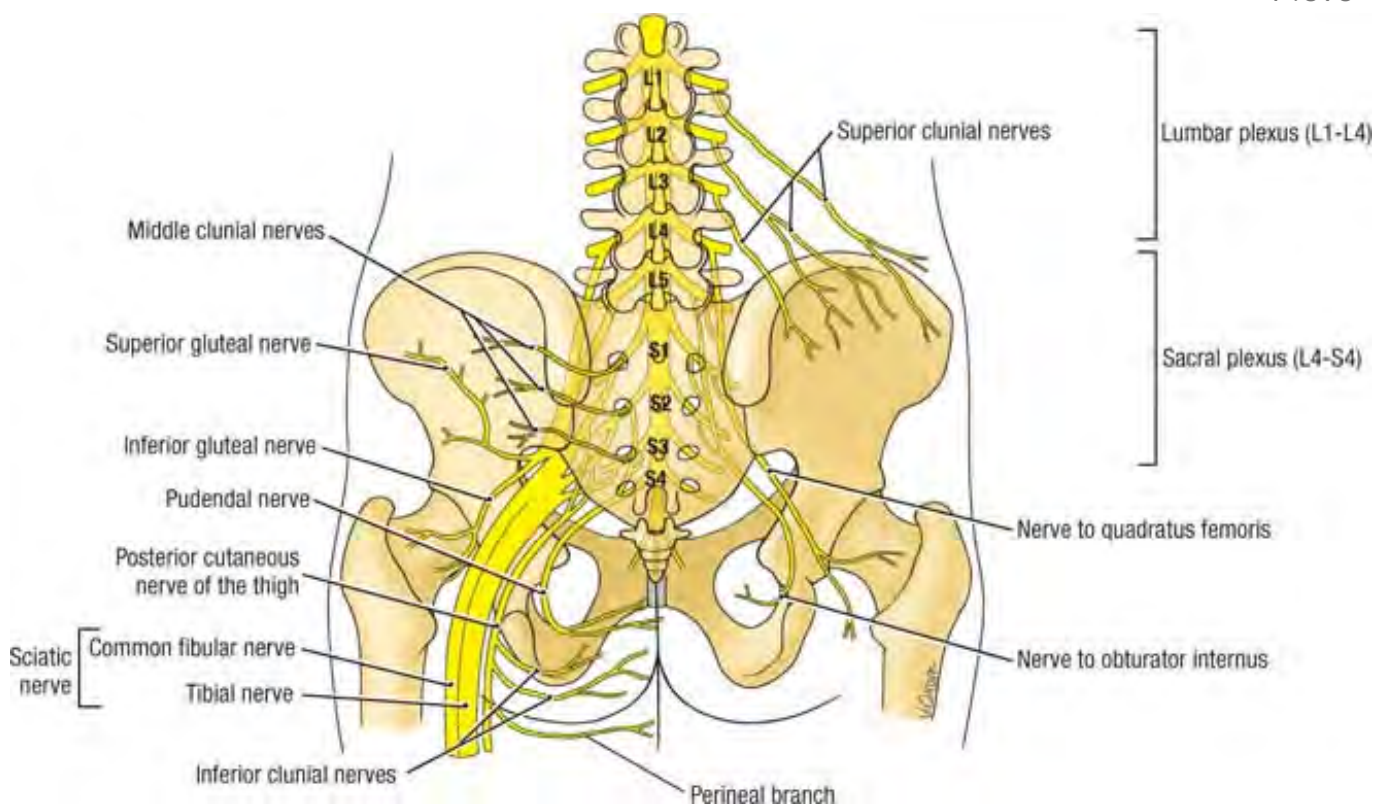
Exits pelvis via greater sciatic foramen inferior to piriformis; descends posterior to ischial spine; enters lesser sciatic foramen and passes to obturator internus

Superior gemellus and obturator internus

Nerve    Origin    Course    Distribution in Gluteal Region

Table 5.6 Nerves of Gluteal Region

P.393



### Superior gluteal

Enters gluteal region through greater sciatic foramen superior to piriformis; divides into superficial and deep branches; anastomoses with inferior gluteal and medial circumflex femoral arteries

*Superficial branch:* superior gluteus maximus *Deep branch:* runs between gluteus medius and minimus, supplying both and tensor fasciae latae

### Inferior gluteal

Enters gluteal region through greater sciatic foramen inferior to piriformis; descends on medial side of sciatic nerve; anastomoses with superior gluteal artery and participates in cruciate anastomosis of thigh

Inferior gluteus maximus, obturator internus, quadratus femoris, and superior parts of hamstring muscles

### Internal pudendal

Enters gluteal region through greater sciatic foramen; descends posterior to ischial spine; exits gluteal region via lesser sciatic foramen to perineum

No structures in gluteal region (supplies external genitalia and muscles in perineal region)

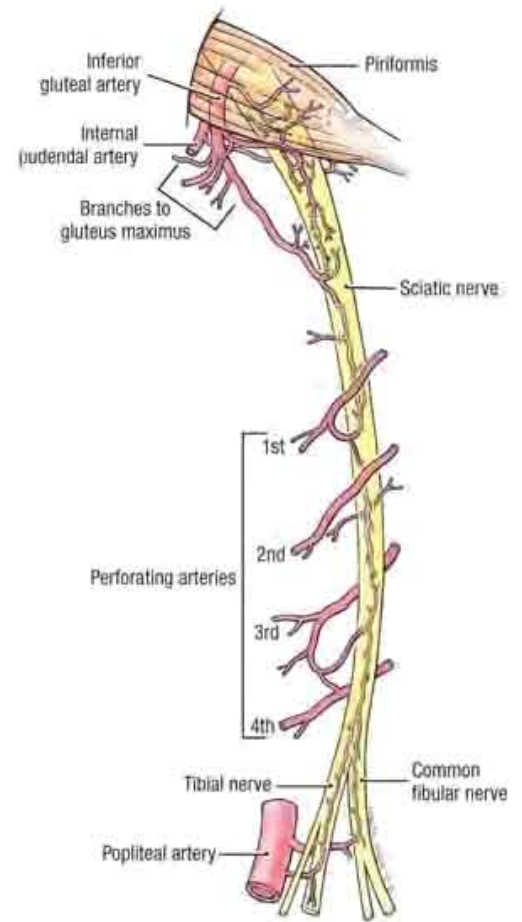
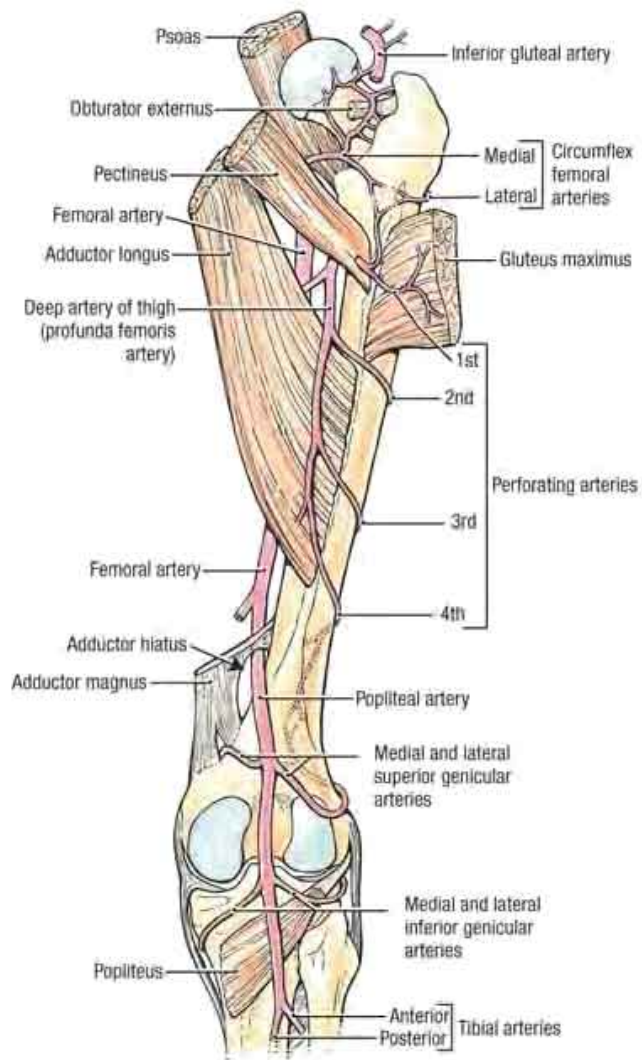
Perforating arteries (from deep femoral artery)

Perforate aponeurotic portion of adductor magnus attachment and medial intermuscular septum to enter and supply muscular branches to posterior compartment; then pierce lateral intermuscular septum to enter posterolateral aspect of anterior compartment

Majority (central portions) of hamstring muscles in posterior compartment; posterior portion of vastus lateralis in anterior compartment; femur (via femoral nutrient arteries); reinforce arterial supply of sciatic nerve

Artery	Course	Distribution/Structures Supplied
--------	--------	----------------------------------

Table 5.7 Arteries of Gluteal Region and Posterior Thigh
--



Posterior Views

Authors: Agur, Anne M.R.; Dalley, Arthur F.

Title: *Grant's Atlas of Anatomy, 12th Edition*

Copyright ©2009 Lippincott Williams & Wilkins

> Table of Contents > Chapter 5 - Lower Limb > 5.29 Hip joint

---

## 5.29 Hip joint

*Part of* "Chapter 5 - Lower Limb "

A. Iliofemoral ligament. B. Muscle attachments of anterior aspect of the proximal femur.

In A :

- The head of the femur is exposed just medial to the iliofemoral ligament and faces superiorly, medially, and anteriorly. At the site of the subtendinous bursa of psoas, the capsule is weak or (as in this specimen) partially deficient, but it is guarded by the psoas tendon.
- The iliofemoral ligament, shaped like an inverted "Y". Superiorly it is attached deep to the rectus femoris muscle; the ligament becomes tight on medial rotation of the femur.
- The pectineus muscle is thin, and its fascia blends with the pectineal ligament.

---

P.395

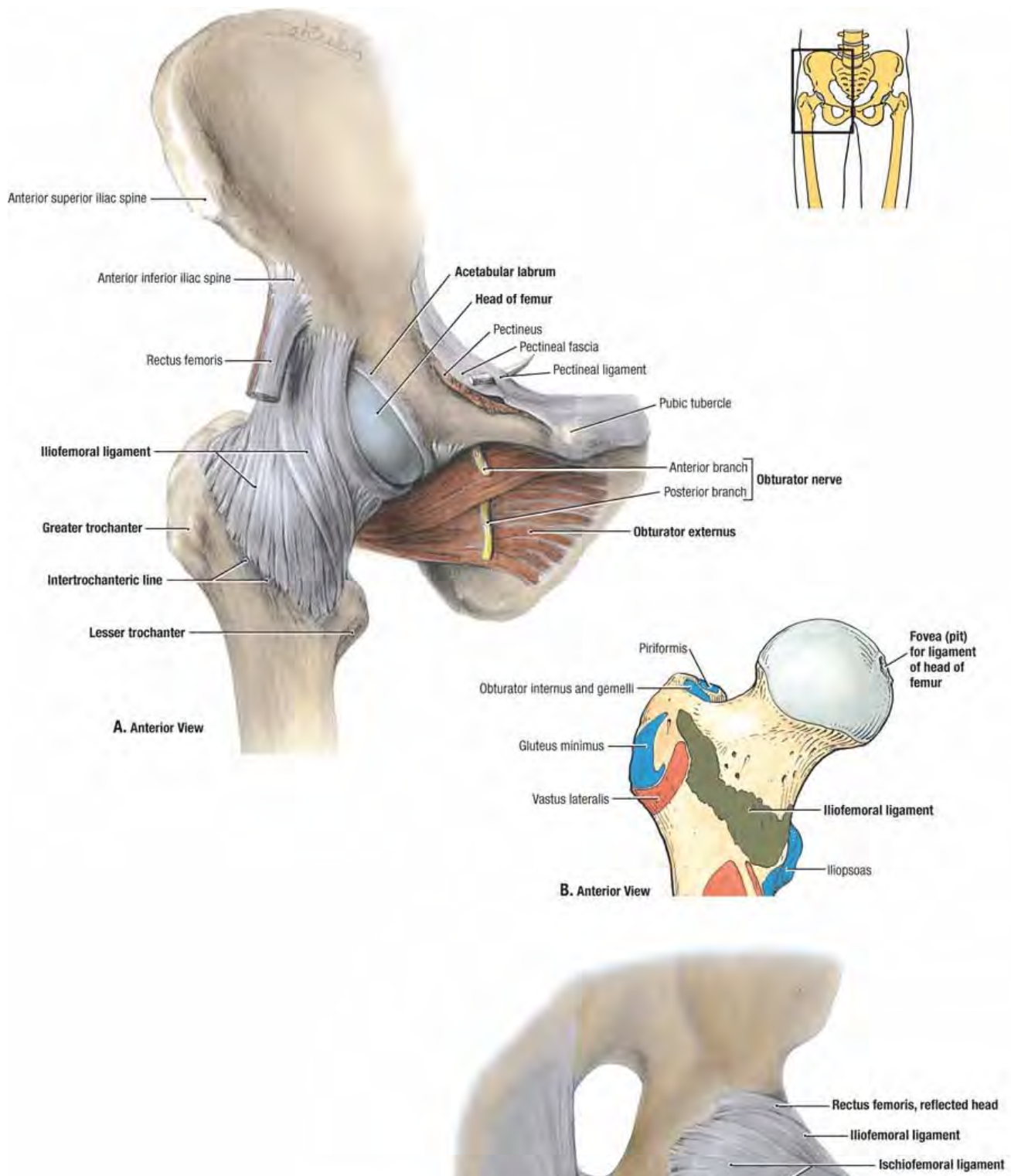
C. Ischiofemoral ligament. D. Muscle attachments onto the posterior aspect of proximal femur. In C :

- The fibers of the capsule spiral to become taut during extension and medial rotation of the femur.
- The synovial membrane protrudes inferior to the fibrous capsule and forms a bursa for the tendon of the obturator externus muscle. Note the large



subtendinous bursa of the obturator internus at the lesser sciatic notch, where the tendon turns 90° to attach to the greater trochanter.

P.396





Authors: Agur, Anne M.R.; Dalley, Arthur F.

Title: *Grant's Atlas of Anatomy, 12th Edition*

Copyright ©2009 Lippincott Williams & Wilkins

> Table of Contents > Chapter 5 - Lower Limb > 5.30 Acetabular region

---

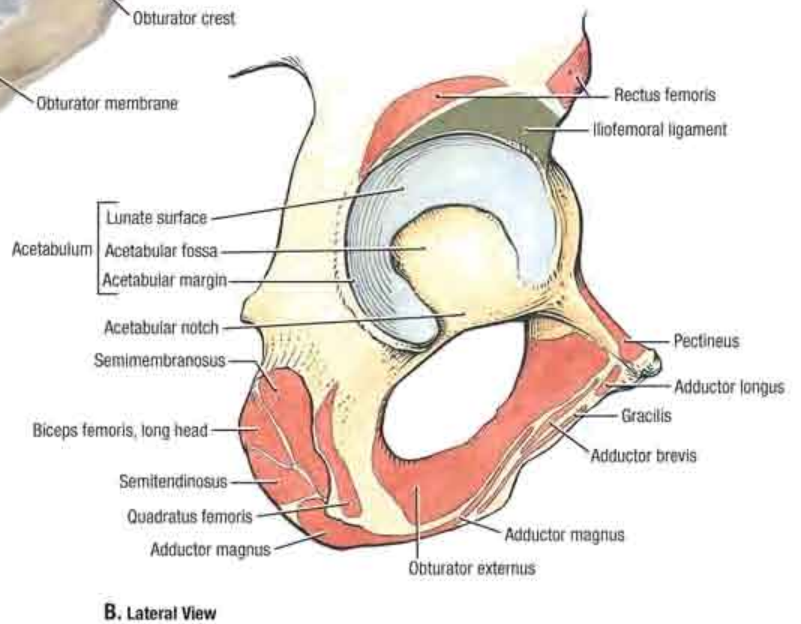
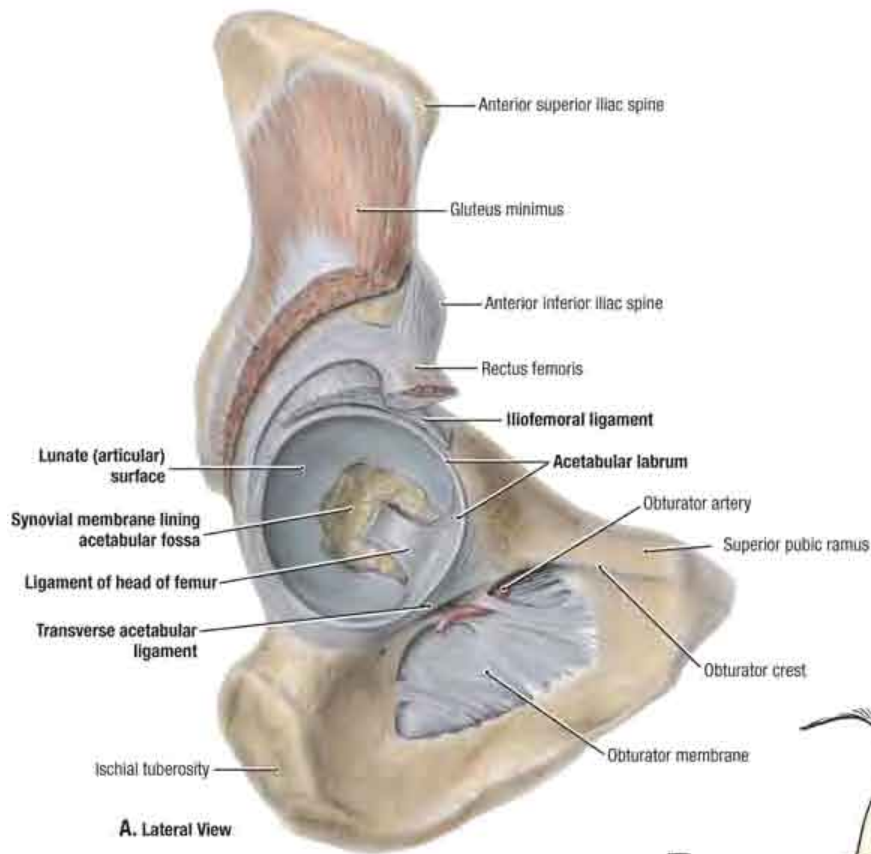
## 5.30 Acetabular region

*Part of* "Chapter 5 - Lower Limb "

A. Dissection of acetabulum. B. Muscle attachments of acetabular region.

In A :

- The transverse acetabular ligament bridges the acetabular notch.
- The acetabular labrum is attached to the acetabular rim and transverse acetabular ligament and forms a complete ring around the head of the femur.
- The ligament of the head of the femur lies between the head of the femur and the acetabulum. These fibers are attached superiorly to the pit (fovea) on the head of the femur and inferiorly to the transverse acetabular ligament and the margins of the acetabular notch. The artery of the ligament of the head of the femur passes through the acetabular notch and into the ligament of the head of the femur.



Authors: Agur, Anne M.R.; Dalley, Arthur F.

Title: *Grant's Atlas of Anatomy, 12th Edition*

Copyright ©2009 Lippincott Williams & Wilkins

> Table of Contents > Chapter 5 - Lower Limb > 5.31 Hip bone

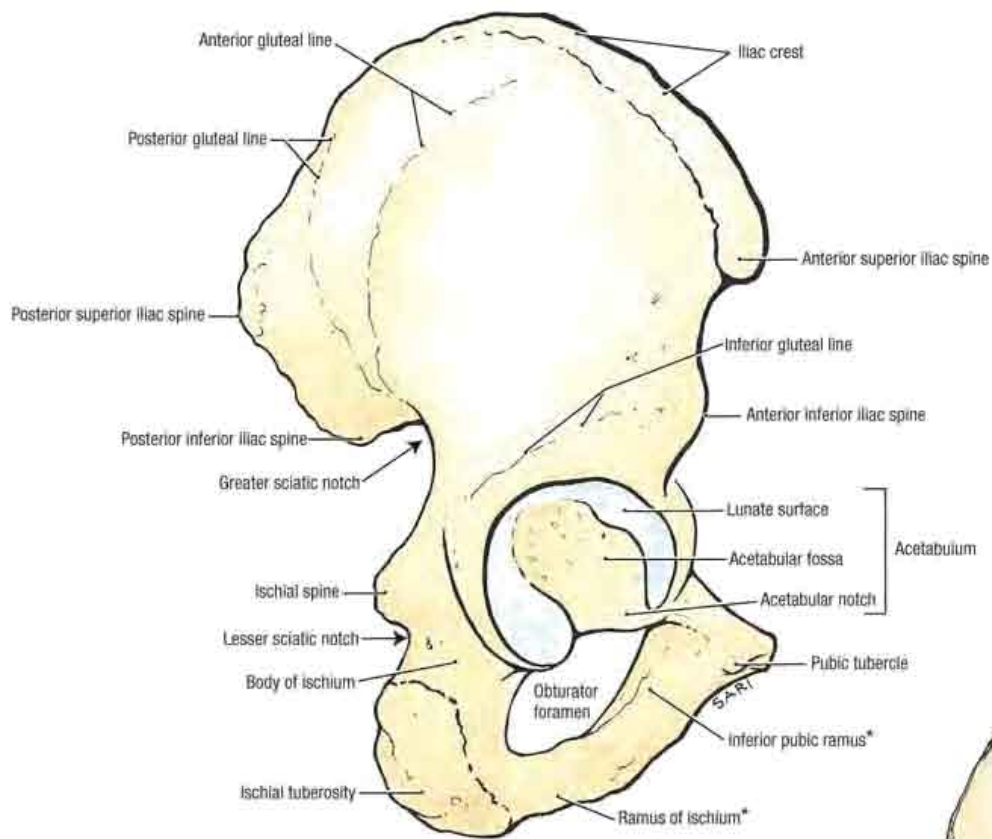
---

## 5.31 Hip bone

*Part of "Chapter 5 - Lower Limb "*

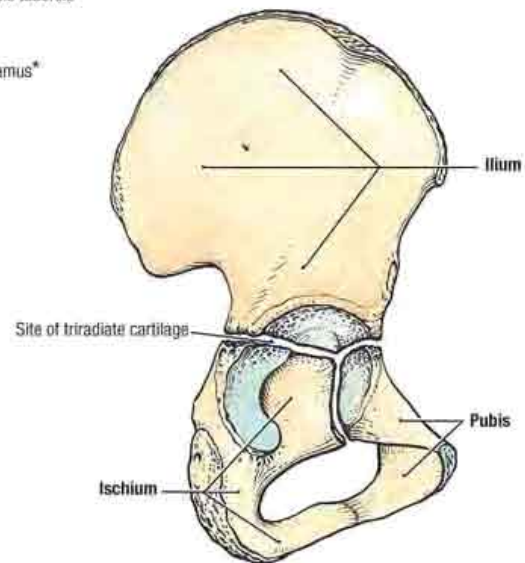
A. Features of the lateral aspect. In the anatomical position, the anterior superior iliac spine and pubic tubercle are in the same coronal plane, and the ischial spine and superior end of the pubic symphysis are in the same horizontal plane; the internal aspect of the body of the pubis faces superiorly, and the acetabulum faces inferolaterally. B. Hip bone in youth. The three parts of the hip bone (ilium, ischium, and pubis) meet in the acetabulum at the triradiate synchondrosis. One or more primary centers of ossification appear in the triradiate cartilage at approximately the 12th year. Secondary centers of ossification appear along the length of the iliac crest, at the anterior inferior iliac spine, the ischial tuberosity, and the symphysis pubis at about puberty; fusion is usually complete by age 23.





**A. Lateral View**

\*Ischiopubic ramus



**B. Lateral View**

Authors: Agur, Anne M.R.; Dalley, Arthur F.

Title: *Grant's Atlas of Anatomy, 12th Edition*

Copyright ©2009 Lippincott Williams & Wilkins

> Table of Contents > Chapter 5 - Lower Limb > 5.32 Radiograph and coronal section of hip joint

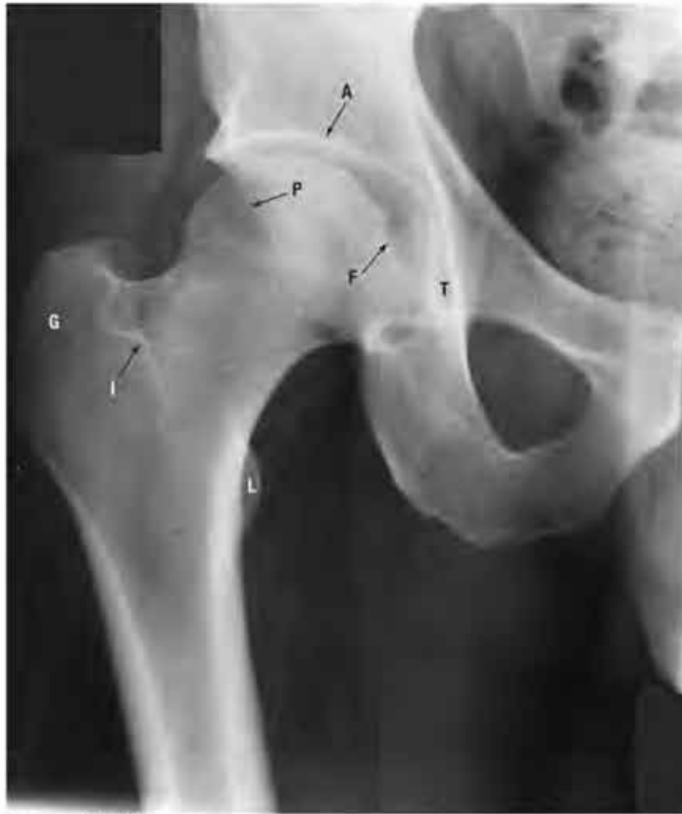---

## 5.32 Radiograph and coronal section of hip joint

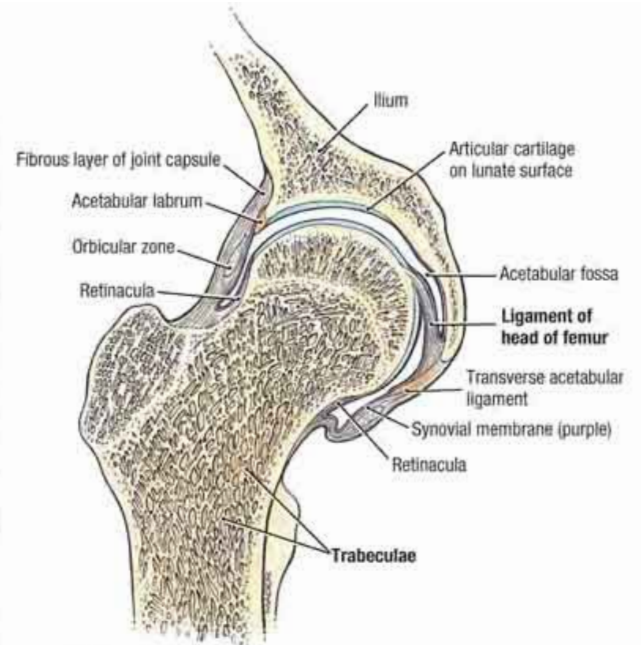
*Part of "Chapter 5 - Lower Limb "*

A. Radiograph. On the femur, note the greater (*G*) and lesser (*L*) trochanters, the intertrochanteric crest (*I*), and the pit or fovea (*F*) for the ligament of the head. On the pelvis, note the roof (*A*) and posterior rim (*P*) of the acetabulum and the "teardrop" appearance (*T*) caused by the superimposition of structures at the inferior margin of the acetabulum. B. Coronal section. Observe the bony trabeculae projecting into the head of the femur. The ligament of the head of the femur becomes taut during adduction of the hip joint, such as when crossing the legs.

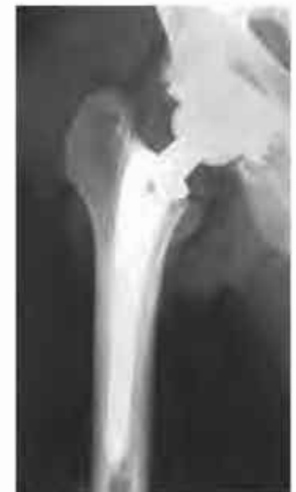C. Hip replacement. The hip joint is subject to severe traumatic injury and degenerative disease. Osteoarthritis of the hip joint, characterized by pain, edema, limitation of motion, and erosion of articular cartilage, is a common cause of disability. During hip replacement, a metal prosthesis anchored to the person's femur by bone cement replaces the femoral head and neck. A plastic socket is cemented to the hip bone to replace the acetabulum. See Figure 5.34 blue box .



**A. Anteroposterior View**



**B. Coronal Section**



**C. Hip Prosthesis**

Authors: Agur, Anne M.R.; Dalley, Arthur F.

Title: *Grant's Atlas of Anatomy, 12th Edition*

Copyright ©2009 Lippincott Williams & Wilkins

> Table of Contents > Chapter 5 - Lower Limb > 5.33 Transverse section through thigh at level of hip joint

---

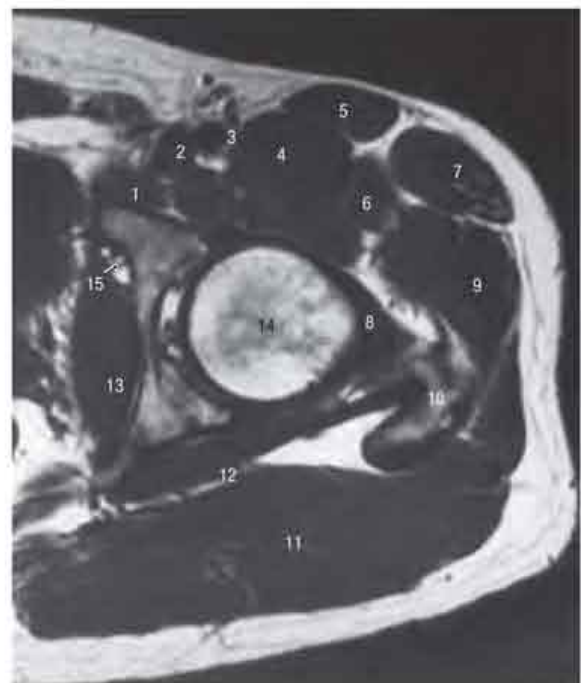
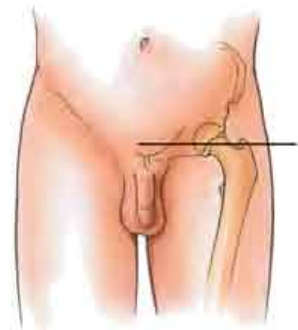
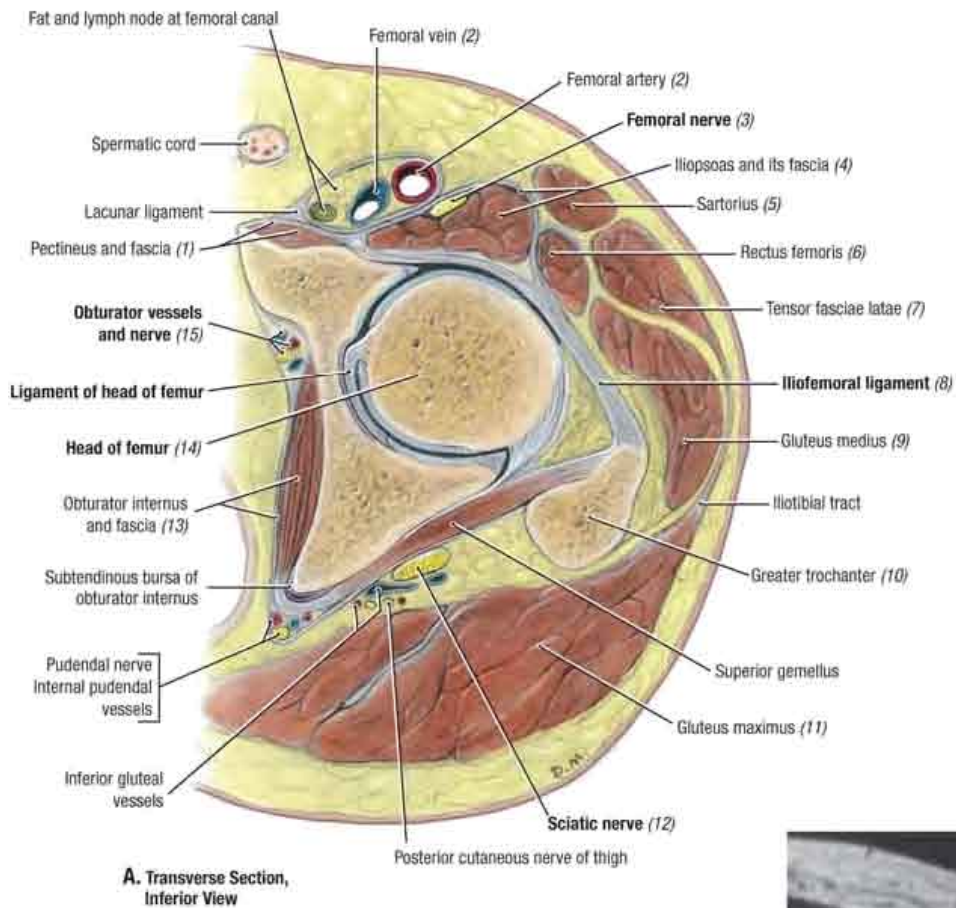
## 5.33 Transverse section through thigh at level of hip joint

*Part of* "Chapter 5 - Lower Limb "

A. Transverse section. B. MRI (*numbers* refer to structures in A).

In A :

- The fibrous capsule of the joint is thick where it forms the iliofemoral ligament and thin posterior to the subtendinous bursa of psoas and tendon.
- The femoral sheath, enclosing the femoral artery, vein, lymph node, lymph vessels, and fat, is free, except posteriorly where, between the psoas and pectineus muscles, it is attached to the capsule of the hip joint.
- The femoral vein is located at the interval between the psoas and pectineus muscles. The femoral nerve lies between the iliacus muscle and fascia.



**B. Transverse MRI**



Authors: Agur, Anne M.R.; Dalley, Arthur F.

Title: *Grant's Atlas of Anatomy, 12th Edition*

Copyright ©2009 Lippincott Williams & Wilkins

> Table of Contents > Chapter 5 - Lower Limb > 5.34 Blood supply to head of femur

---

## 5.34 Blood supply to head of femur

*Part of* "Chapter 5 - Lower Limb "

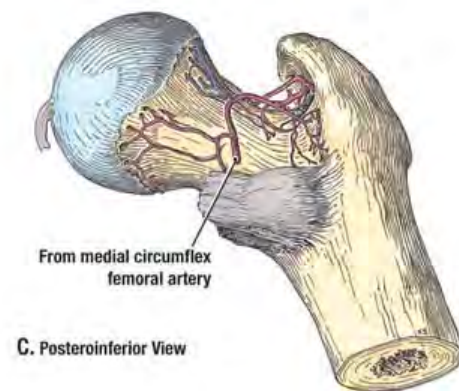
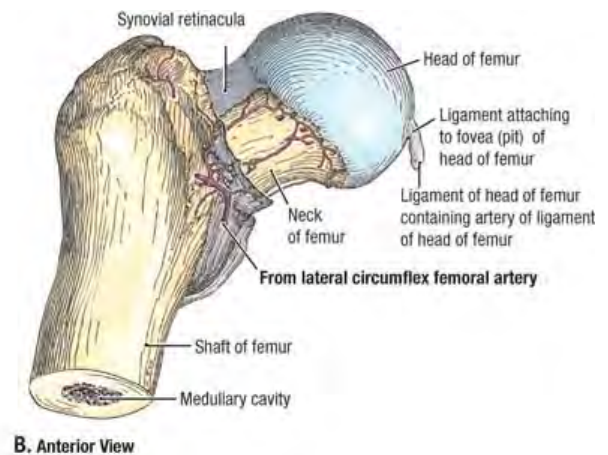
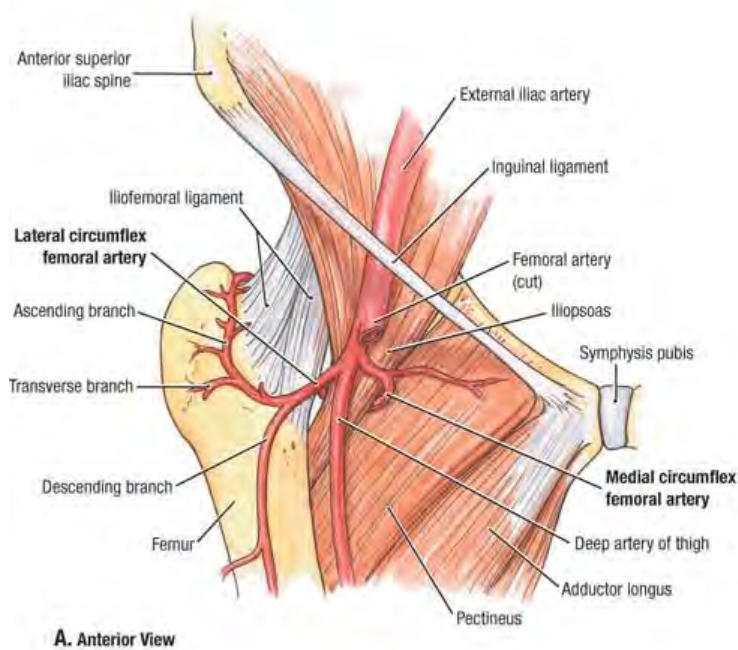
A. Medial and lateral circumflex femoral arteries in femoral triangle. B. Branches of lateral circumflex femoral artery. C. Branches of medial circumflex femoral artery.

- Branches of the medial and lateral circumflex femoral arteries ascend on the posterosuperior and posteroinferior parts of the neck of the femur. The vessels ascend in synovial retinacula—reflections of synovial membrane along the neck of the femur. The retinacula (in B and C ) have been mostly removed; thus, the vessels can be clearly visualized.
- The branches of the medial and lateral circumflex femoral arteries perforate the bone just distal to the head of the femur, where they anastomose with branches from the artery of the ligament of the head of the femur and with medullary branches located within the shaft of the femur.
- The ligament of the head of the femur usually contains the artery of the ligament of the head of the femur, a branch of the obturator artery. The artery enters the head of the femur only when the center of the ossification has extended to the pit (fovea) for the ligament of the head (12th to 14th year). When present, this anastomosis persists even in advanced age; however, in 20% of persons, it is never established.

Fractures of the femoral neck often disrupt the blood supply to the head of the femur. The medial circumflex femoral artery supplies most of the blood

to the head and neck of the femur and is often torn when the femoral neck is fractured. In some cases, the blood supplied by the artery of the ligament of the head may be the only blood received by the proximal fragment of the femoral head, which may be inadequate. If the blood vessels are ruptured, the fragment of bone may receive no blood and undergo aseptic necrosis.

P.401



Authors: Agur, Anne M.R.; Dalley, Arthur F.

Title: *Grant's Atlas of Anatomy, 12th Edition*

Copyright ©2009 Lippincott Williams & Wilkins

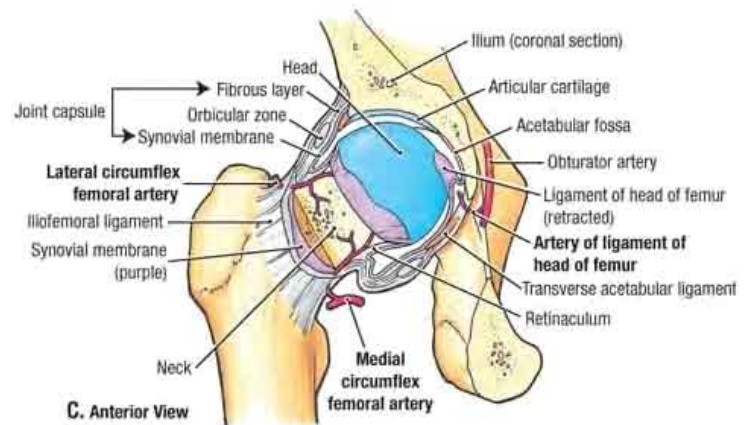
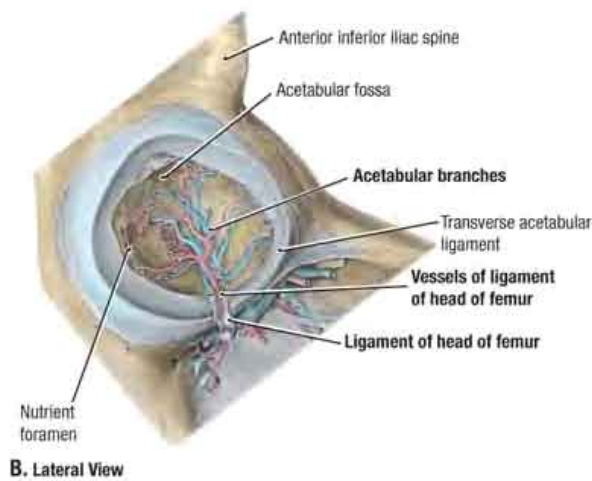
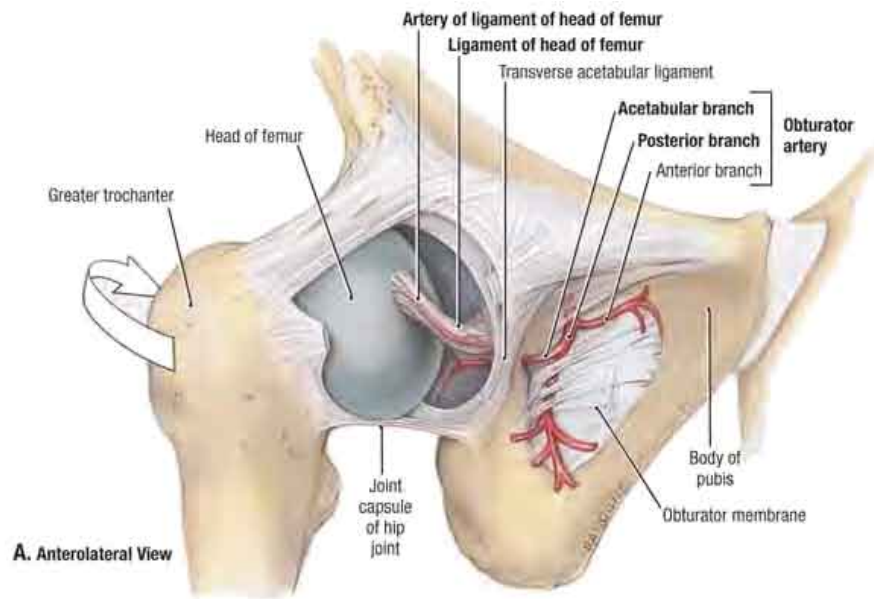
> Table of Contents > Chapter 5 - Lower Limb > 5.35 Blood vessels of acetabular fossa and ligament of head of femur

---

## 5.35 Blood vessels of acetabular fossa and ligament of head of femur

*Part of "Chapter 5 - Lower Limb "*

A. Obturator artery. The hip joint has been dislocated to reveal the ligament of the head of the femur. The obturator artery divides into anterior and posterior branches, and the acetabular branch arises from the posterior branch. The artery of the ligament of the head of the femur is a branch of the acetabular artery and can be seen traveling in the ligament to the head of the femur. B. Acetabular artery and vein. The acetabular branches (artery and vein) pass through the acetabular foramen and enter the acetabular fossa, where they diverge in the fatty areolar tissue. The branches radiate to the margin of the fossa, where they enter nutrient foramina. C. Blood supply of the head and neck of the femur. A section of bone has been removed from the femoral neck.



Authors: Agur, Anne M.R.; Dalley, Arthur F.

Title: *Grant's Atlas of Anatomy, 12th Edition*

Copyright ©2009 Lippincott Williams & Wilkins

> Table of Contents > Chapter 5 - Lower Limb > 5.36 Popliteal fossa

---

## 5.36 Popliteal fossa

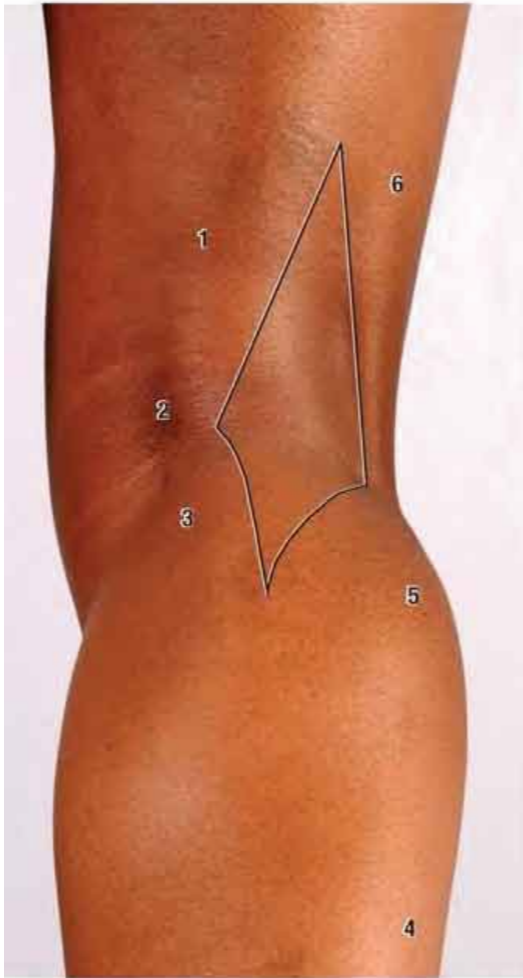
*Part of* "Chapter 5 - Lower Limb "

A. Surface anatomy (*numbers* refer to structures in B). B. Superficial dissection.

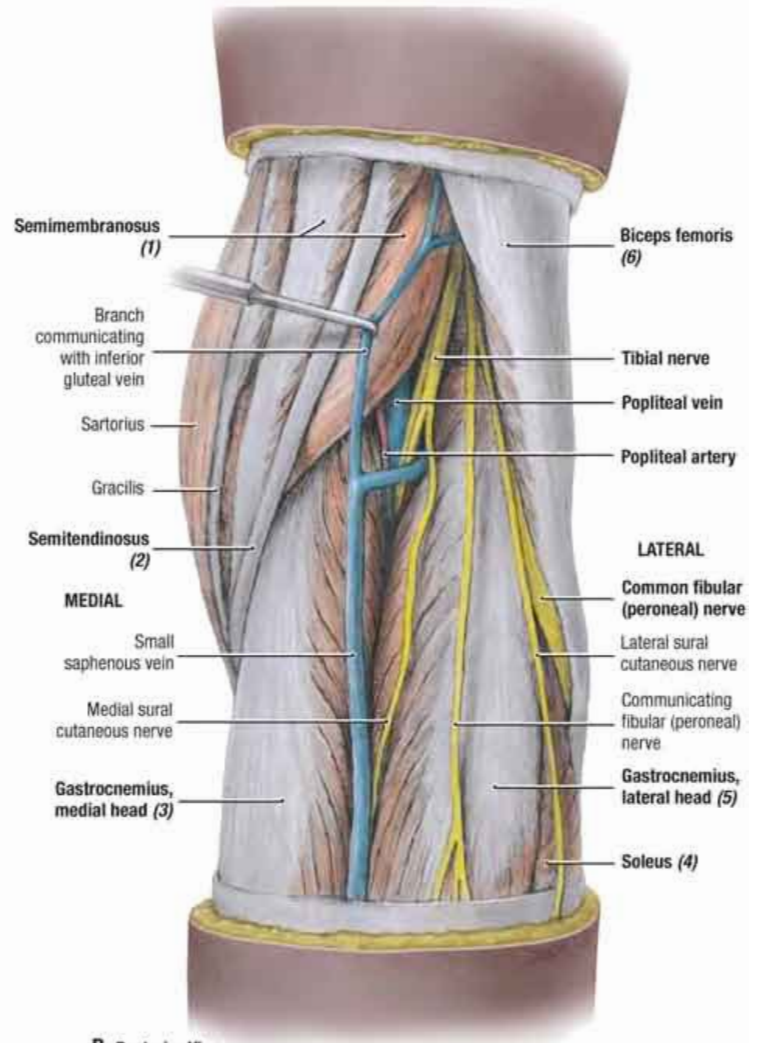
- The two heads of the gastrocnemius muscle are embraced on the medial side by the semimembranosus muscle, which is overlaid by the semitendinosus muscle, and on the lateral side by the biceps femoris muscle.
- The small saphenous vein runs between the two heads of the gastrocnemius muscle. Deep to this vein is the medial sural cutaneous nerve, which, followed proximally, leads to the tibial nerve. The tibial nerve is superficial to the popliteal vein, which, in turn, is superficial to the popliteal artery.

Because the popliteal artery is deep in the popliteal fossa, it may be difficult to feel the popliteal pulse. Palpation of this pulse is commonly performed by placing the person in the prone position with the knee flexed to relax the popliteal fascia and hamstrings. The pulsations are best felt in the inferior part of the fossa. Weakening or loss of the popliteal pulse is a sign of femoral artery obstruction.





A. Posterior View



B. Posterior View

Authors: Agur, Anne M.R.; Dalley, Arthur F.

Title: *Grant's Atlas of Anatomy, 12th Edition*

Copyright ©2009 Lippincott Williams & Wilkins

> Table of Contents > Chapter 5 - Lower Limb > 5.37 Nerves of popliteal fossa

---

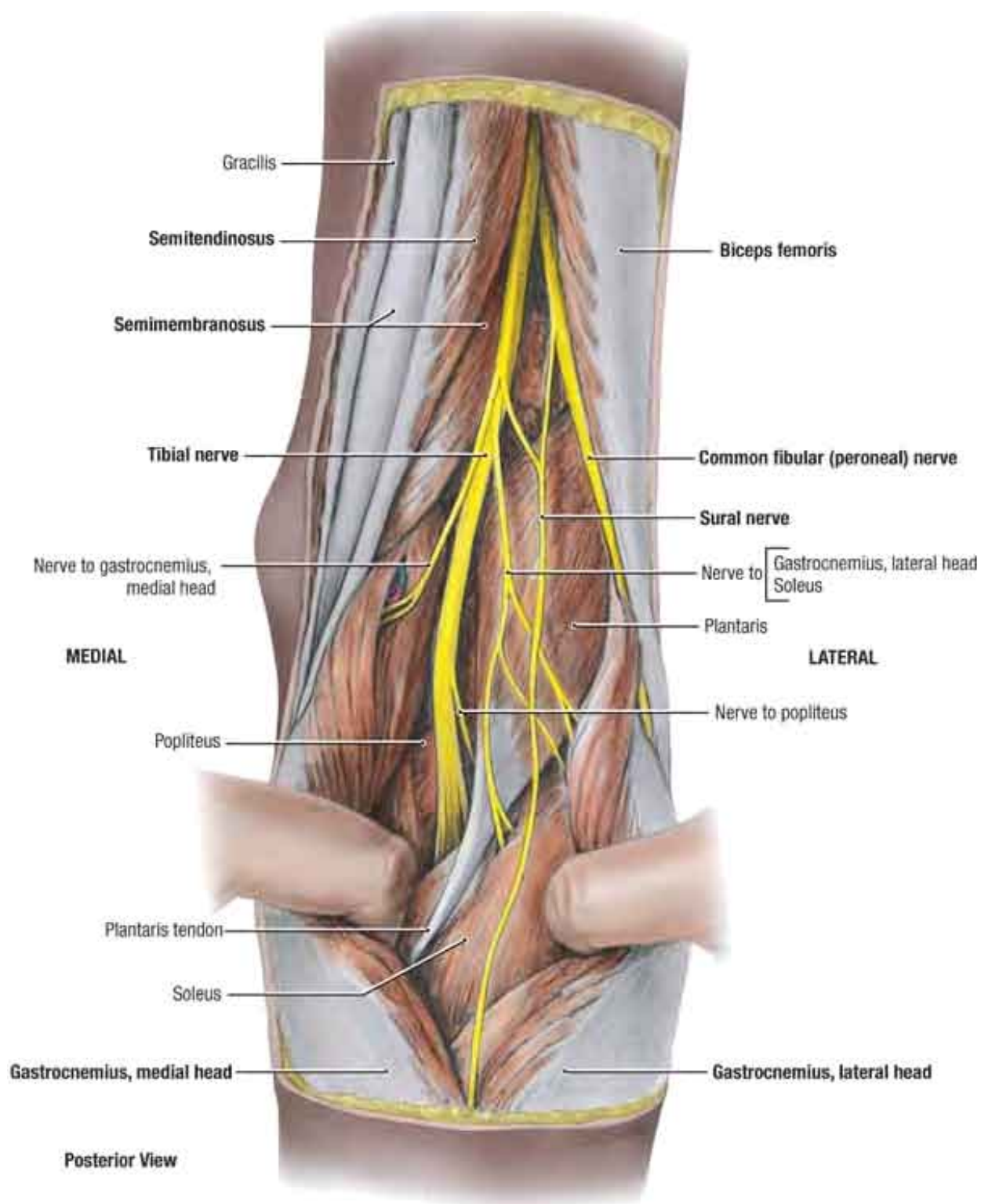
## 5.37 Nerves of popliteal fossa

*Part of* "Chapter 5 - Lower Limb"

The two heads of the gastrocnemius muscle are separated.

- A cutaneous branch of the tibial nerve joins a cutaneous branch of the common fibular (peroneal) nerve to form the sural nerve. In this specimen, the junction is high; usually it is 5 to 8 cm proximal to the ankle.

All motor branches in this region emerge from the tibial nerve, one branch from its medial side and the others from its lateral side; hence, it is safer to dissect on the medial side.



Authors: Agur, Anne M.R.; Dalley, Arthur F.

Title: *Grant's Atlas of Anatomy, 12th Edition*

Copyright ©2009 Lippincott Williams & Wilkins

> Table of Contents > Chapter 5 - Lower Limb > 5.38 Deep dissection of popliteal fossa

---

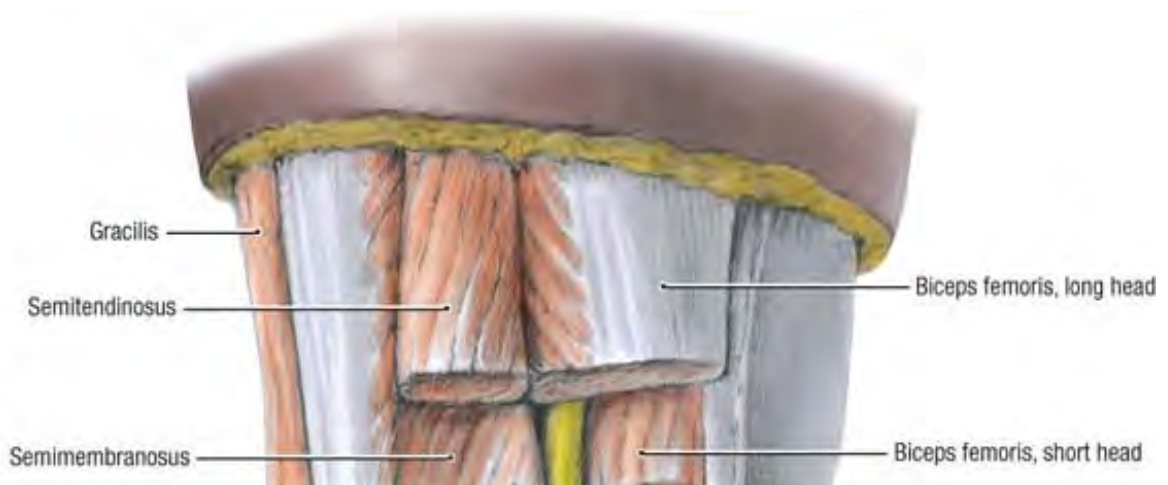
## 5.38 Deep dissection of popliteal fossa

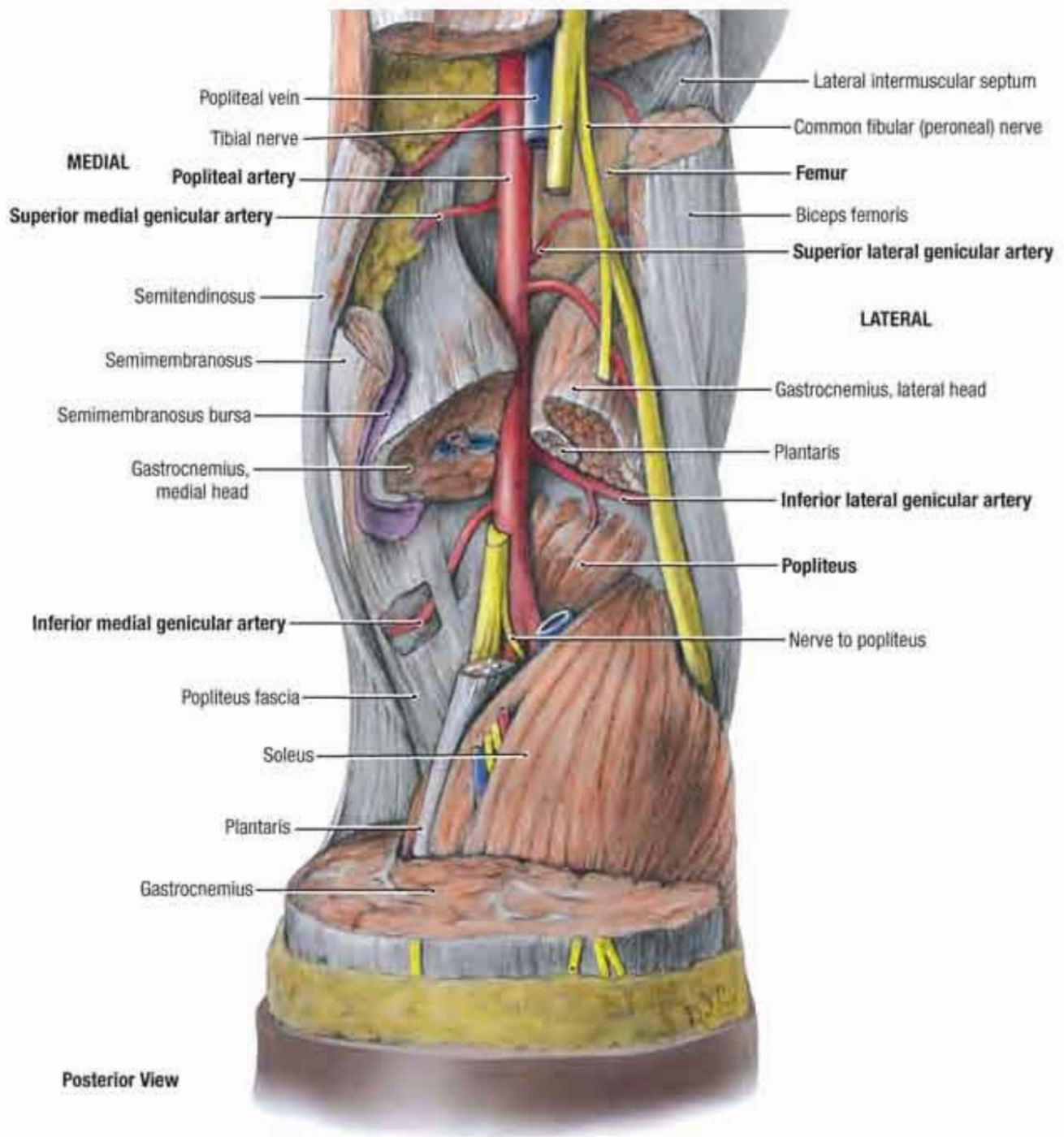
*Part of* "Chapter 5 - Lower Limb"

The common fibular (peroneal) nerve follows the posterior border of the biceps femoris muscle and, in this specimen, gives off two cutaneous branches. The popliteal artery lies on the floor of the popliteal fossa. The floor is formed by the femur, capsule of the knee joint, and popliteus muscle and fascia. The popliteal artery gives off genicular branches that also lie on the floor of the fossa.

A popliteal aneurysm (abnormal dilation of all or part of the popliteal artery) usually causes edema (swelling) and pain in the popliteal fossa. If the femoral artery has to be ligated, blood can bypass the occlusion through the genicular anastomosis and reach the popliteal artery distal to the ligation.

P.405







Authors: Agur, Anne M.R.; Dalley, Arthur F.

Title: *Grant's Atlas of Anatomy, 12th Edition*

Copyright ©2009 Lippincott Williams & Wilkins

> Table of Contents > Chapter 5 - Lower Limb > 5.39 Attachment of muscles of popliteal region

---

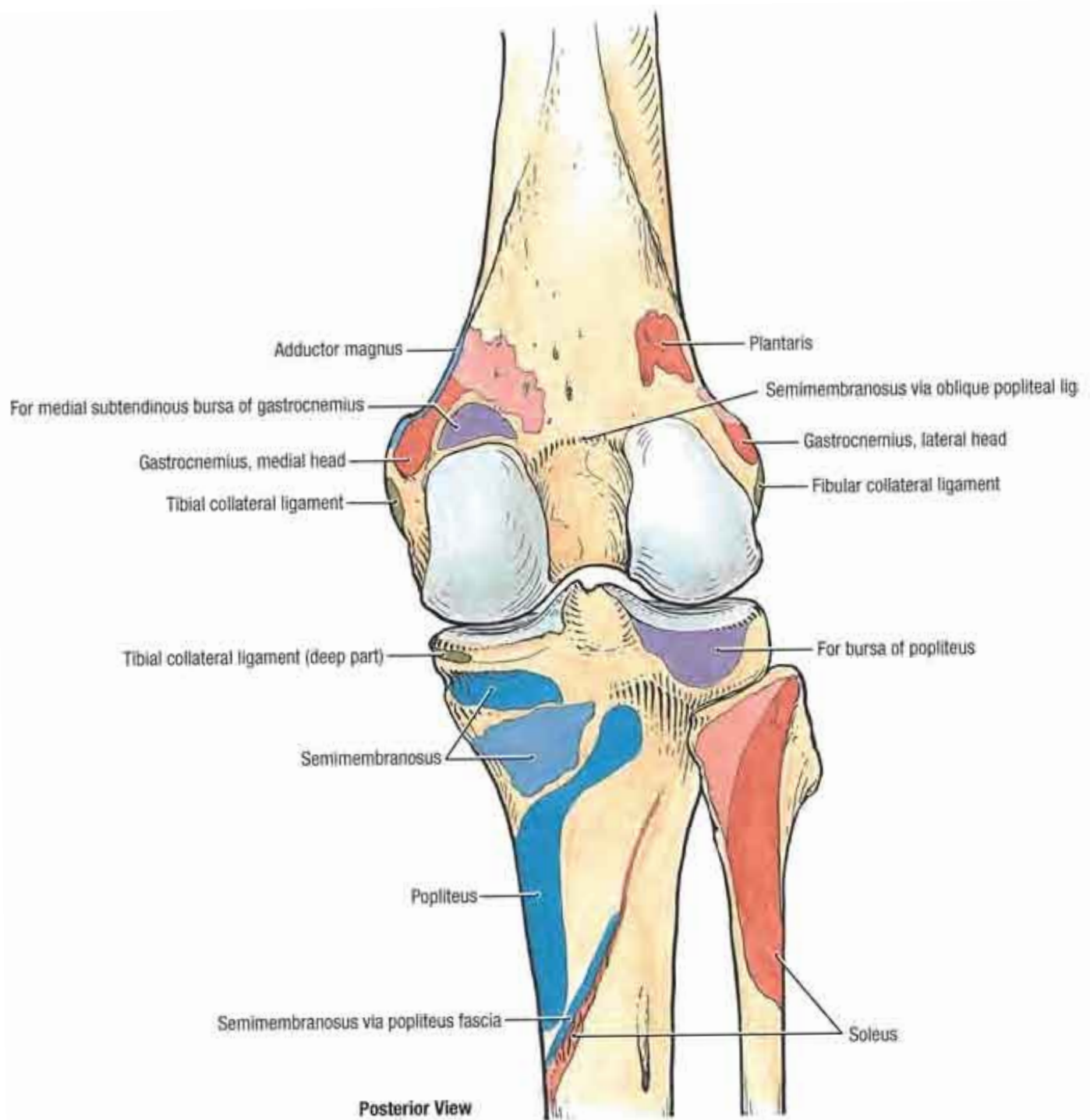
## 5.39 Attachment of muscles of popliteal region

*Part of* "Chapter 5 - Lower Limb "

Lighter tones are secondary attachments.

---

P.406



Authors: Agur, Anne M.R.; Dalley, Arthur F.

Title: *Grant's Atlas of Anatomy, 12th Edition*

Copyright ©2009 Lippincott Williams & Wilkins

> Table of Contents > Chapter 5 - Lower Limb > 5.40 Anterior aspect of knee

---

## 5.40 Anterior aspect of knee

*Part of* "Chapter 5 - Lower Limb "

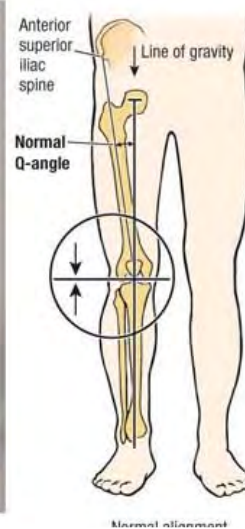
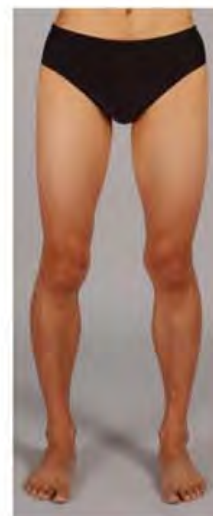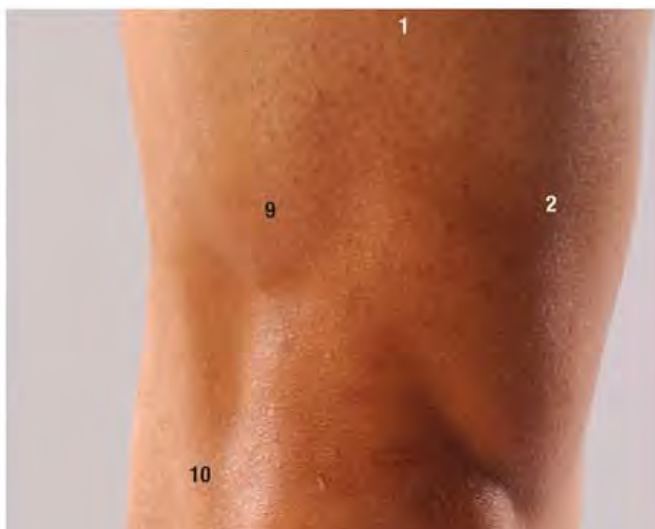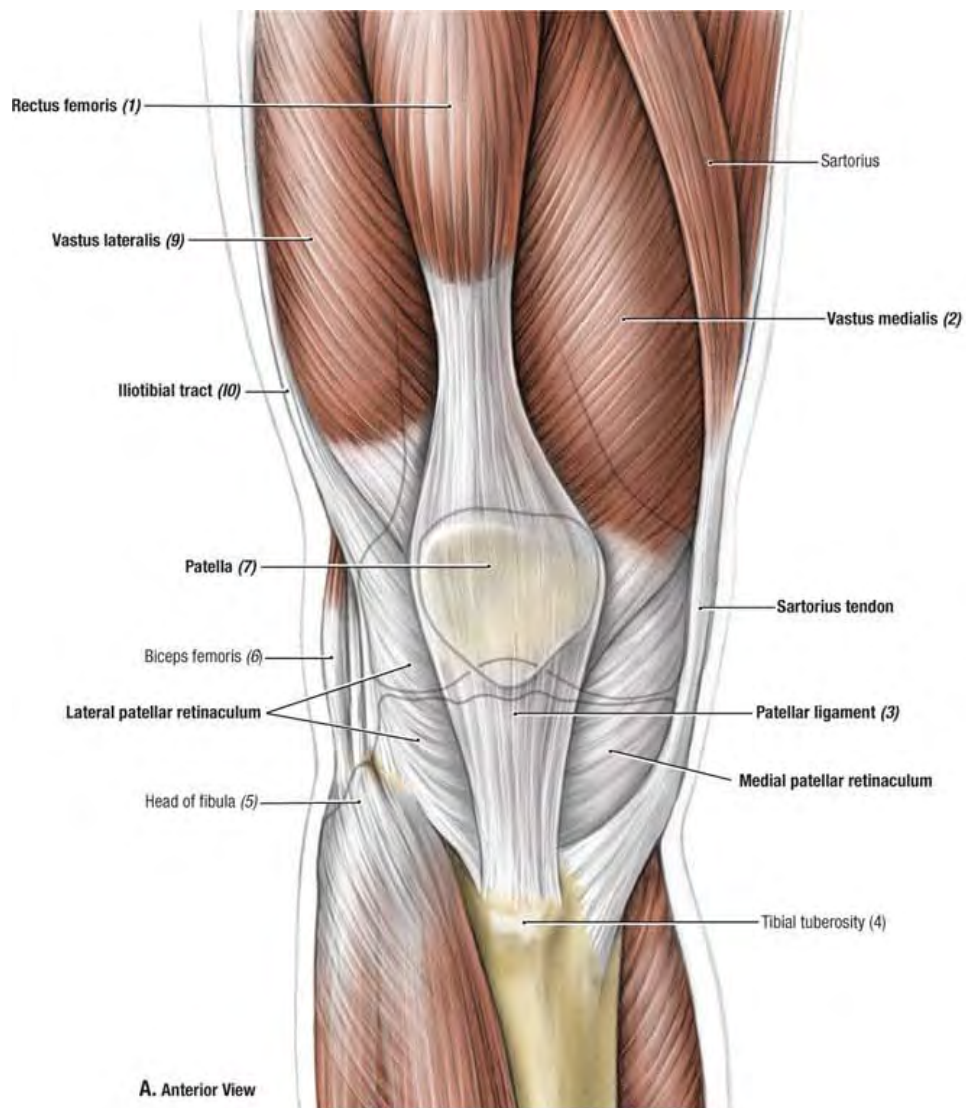
### A. Distal thigh and knee regions.

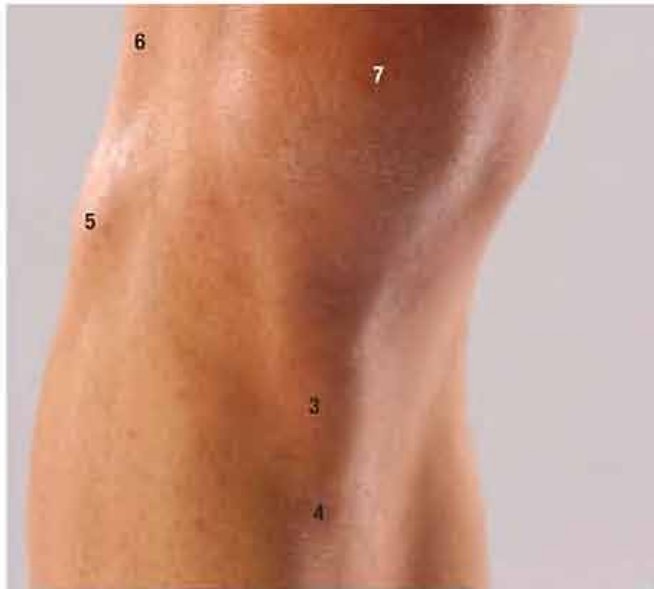
Note that the tendons of the four parts of the quadriceps unite to form the quadriceps tendon, a broad band that attaches to the patella. The patellar ligament, a continuation of the quadriceps tendon, attaches the patella to the tibial tuberosity. The lateral and medial patellar retinacula, formed largely by continuation of the iliotibial tract, and investing fascia of the vasti muscles, maintains alignment of the patella and patellar ligament. The retinacula also form the anterolateral and anteromedial portions of the fibrous layer of the joint capsule of the knee.

---

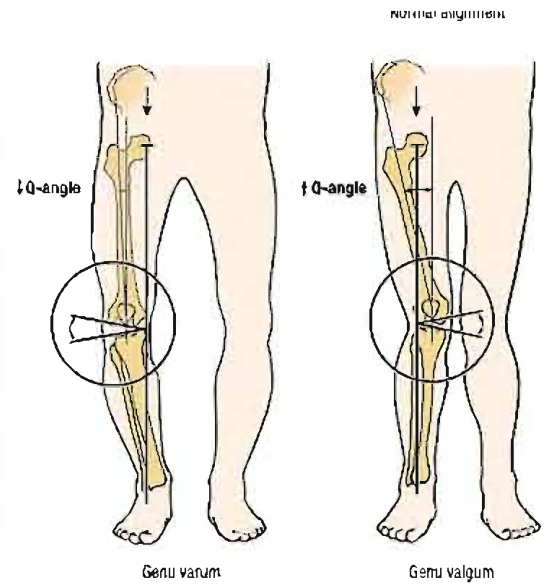
P.407

B. Surface anatomy (numbers refer to structures in A ). The femur is placed diagonally within the thigh, whereas the tibia is almost vertical within the leg, creating an angle at the knee between the long axes of the bones. The angle between the two bones, referred to clinically as the Q-angle, is assessed by drawing a line from the anterior superior iliac spine to the middle of the patella and extrapolating a second (vertical) line passing through the middle of the patella and tibial tuberosity. The Q-angle is typically greater in adult females, owing to their wider pelvises. C. Genu valgum and genu varum. A medial angulation of the leg in relation to the thigh, in which the femur is abnormally vertical and the Q-angle is small, is a deformity called genu varum (bowleg) that causes unequal weight bearing resulting in arthrosis (destruction of knee cartilages), and an overstressed fibular collateral ligament. A lateral angulation of the leg (large Q-angle,  $>17^{\circ}$ ) in relation to the thigh is called genu valgum (knock-knee). This results in excess stress and degeneration of the lateral structures of the knee joint.





B. Anterior Views



C. Anterior Views



Authors: Agur, Anne M.R.; Dalley, Arthur F.

Title: *Grant's Atlas of Anatomy, 12th Edition*

Copyright ©2009 Lippincott Williams & Wilkins

> Table of Contents > Chapter 5 - Lower Limb > 5.41 Medial aspect of knee

---

## 5.41 Medial aspect of knee

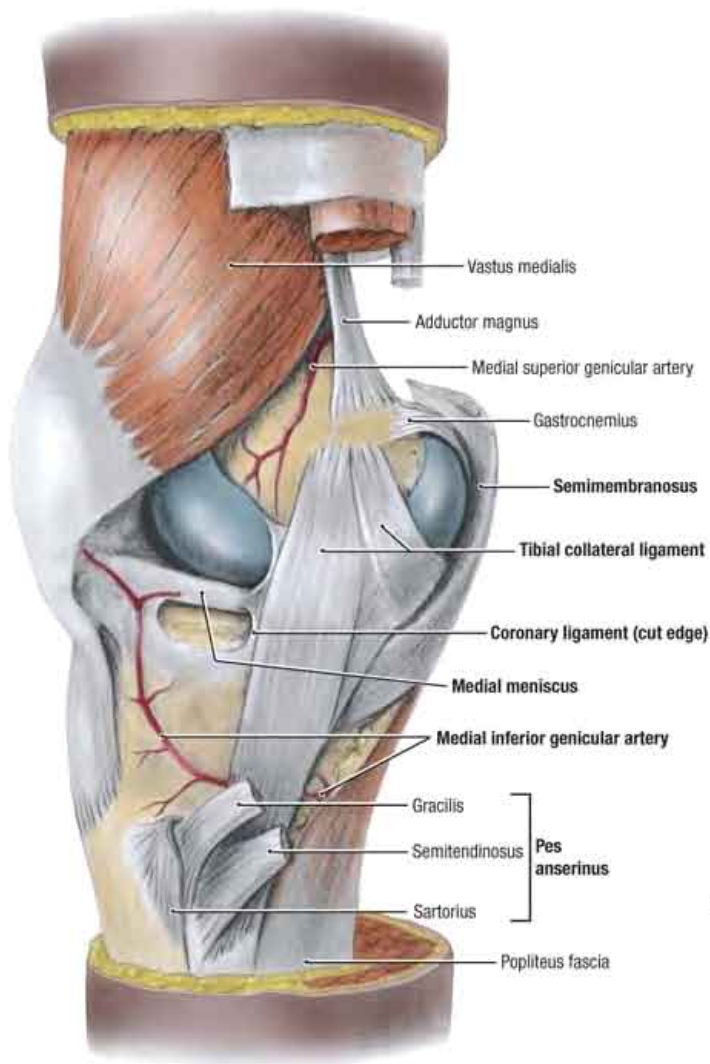
*Part of* "Chapter 5 - Lower Limb "

A. Dissection. The bandlike part of the tibial collateral ligament attaches to the medial epicondyle of the femur, bridges superficial to the insertion of the semimembranosus muscle, and crosses the medial inferior genicular artery. Distally, the ligament is crossed by the three tendons forming the pes anserinus (sartorius, gracilis, and semitendinosus).

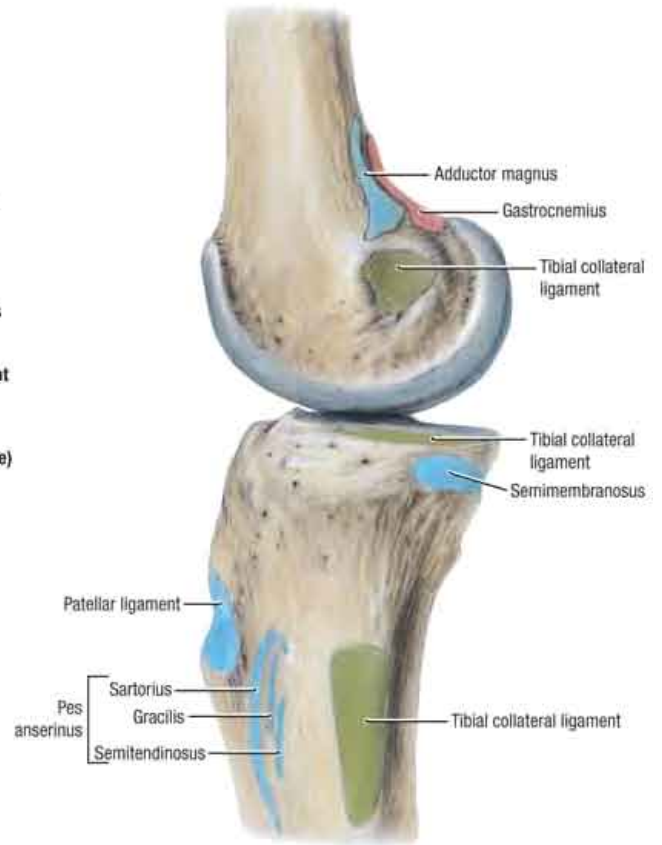B. Bones, showing muscle and ligament attachment sites.

---

P.409



**A. Medial View**



**B. Medial View**

Authors: Agur, Anne M.R.; Dalley, Arthur F.

Title: *Grant's Atlas of Anatomy, 12th Edition*

Copyright ©2009 Lippincott Williams & Wilkins

> Table of Contents > Chapter 5 - Lower Limb > 5.42 Lateral aspect of knee

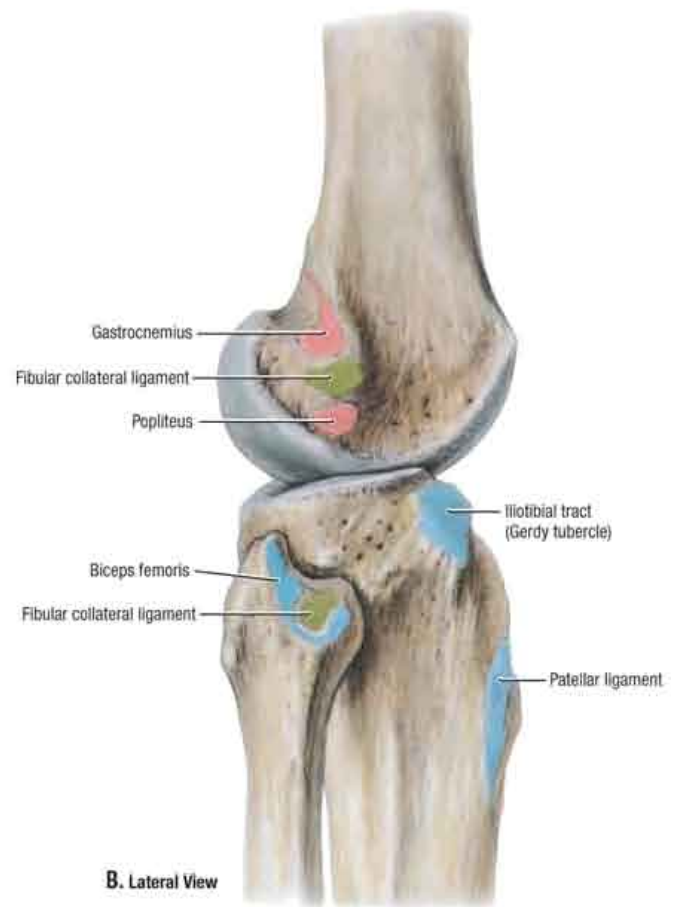
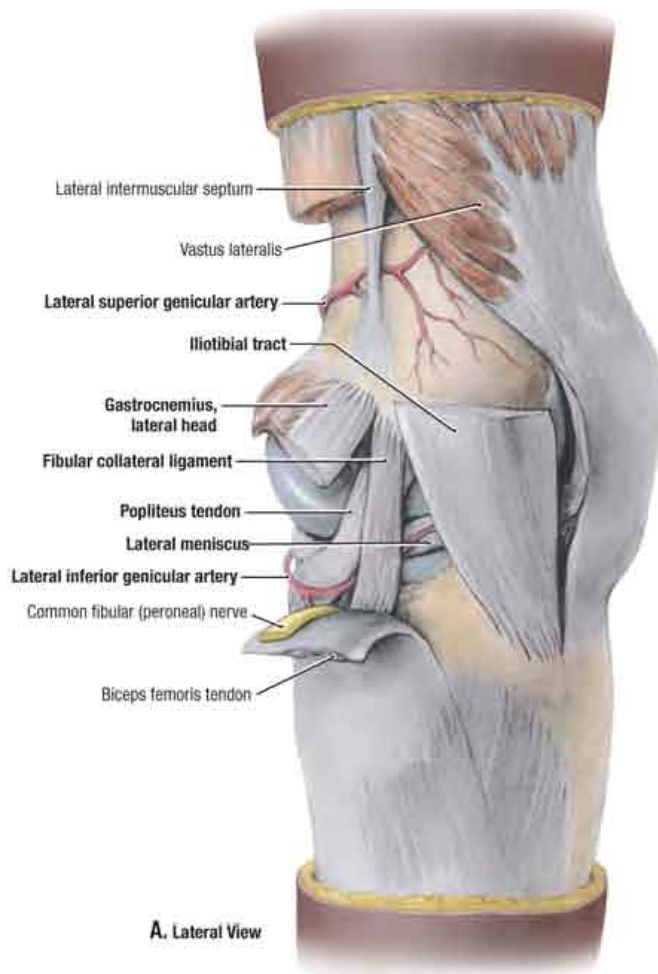
---

## 5.42 Lateral aspect of knee

*Part of* "Chapter 5 - Lower Limb "

A. Dissection. B. Bones, showing muscle and ligament attachments.

Three structures arise from the lateral epicondyle and are uncovered by reflecting the biceps muscle: the gastrocnemius muscle is posterosuperior; the popliteus muscle is anteroinferior; and the fibular collateral ligament is in between, crossing superficial to the popliteus muscle. The lateral inferior genicular artery courses along the lateral meniscus.



Authors: Agur, Anne M.R.; Dalley, Arthur F.

Title: *Grant's Atlas of Anatomy, 12th Edition*

Copyright ©2009 Lippincott Williams & Wilkins

> Table of Contents > Chapter 5 - Lower Limb > 5.43 Fibrous layer and synovial membrane of joint capsule

---

## 5.43 Fibrous layer and synovial membrane of joint capsule

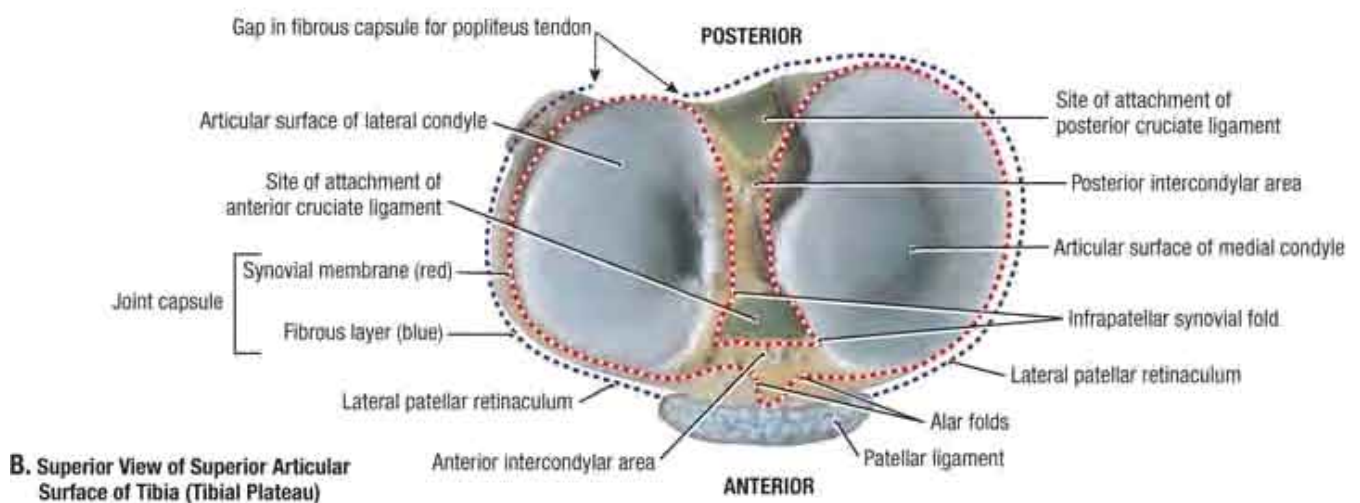
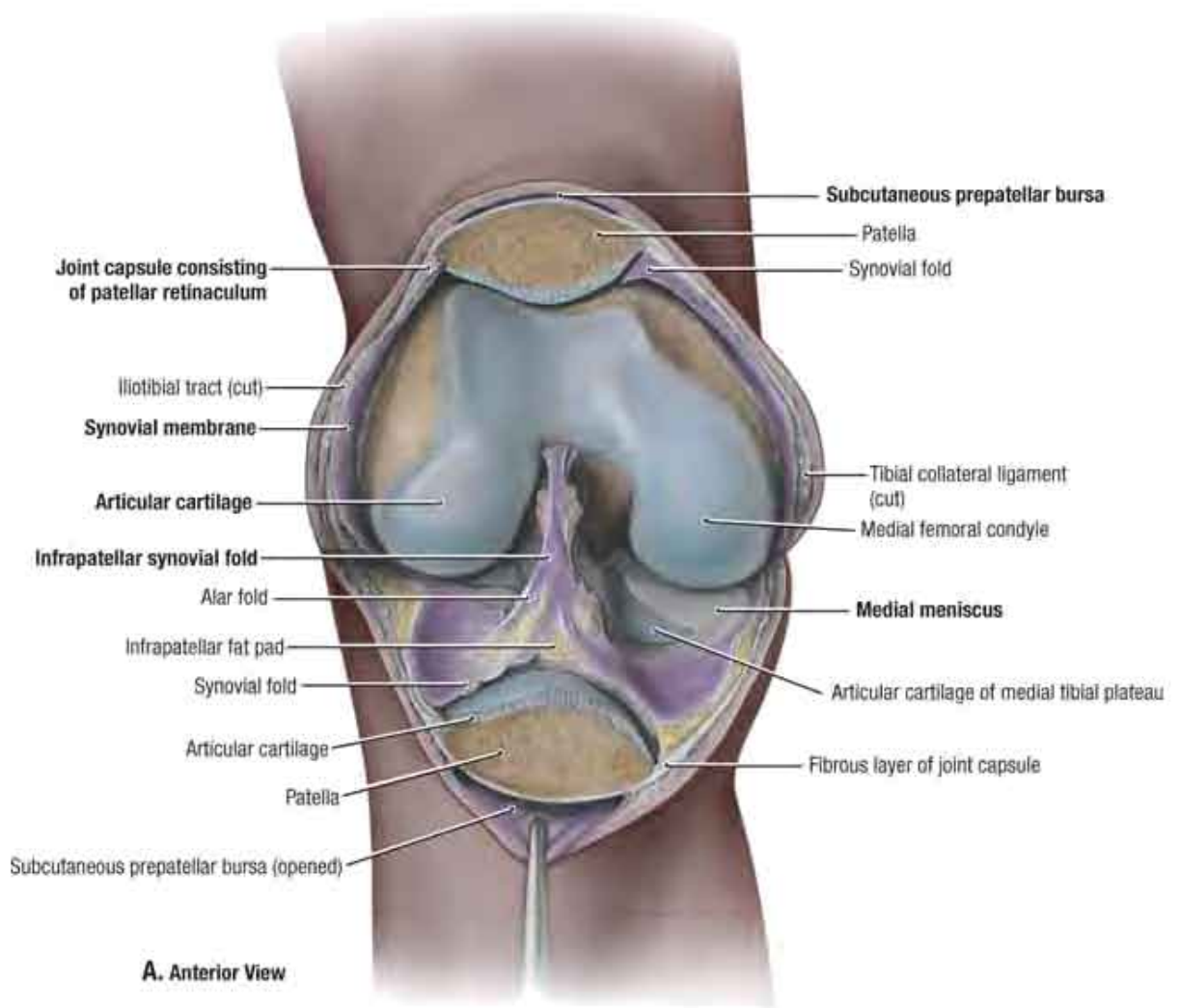
*Part of "Chapter 5 - Lower Limb "*

A. Dissection. B. Attachment of the layers of the joint capsule to the tibia. The fibrous layer (blue dotted line) and synovial membrane (red dotted line) are adjacent on each side, but they part company centrally to accommodate intercondylar and infrapatellar structures that are intracapsular (inside the fibrous layer) but extra-articular (excluded from the articular cavity by synovial membrane).

---

P.411





Authors: Agur, Anne M.R.; Dalley, Arthur F.

Title: *Grant's Atlas of Anatomy, 12th Edition*

Copyright ©2009 Lippincott Williams & Wilkins

> Table of Contents > Chapter 5 - Lower Limb > 5.44 Articular surfaces and ligaments of knee joint

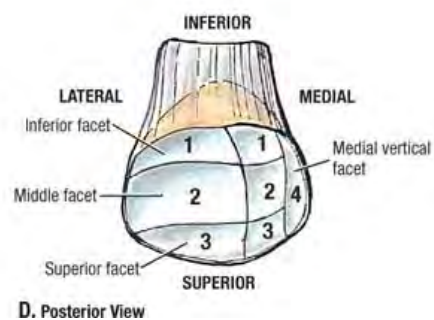
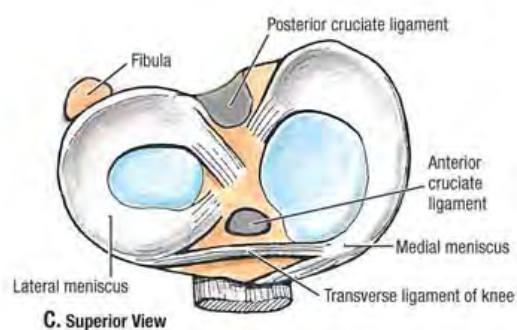
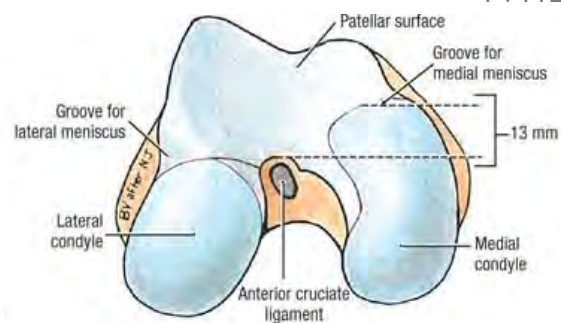
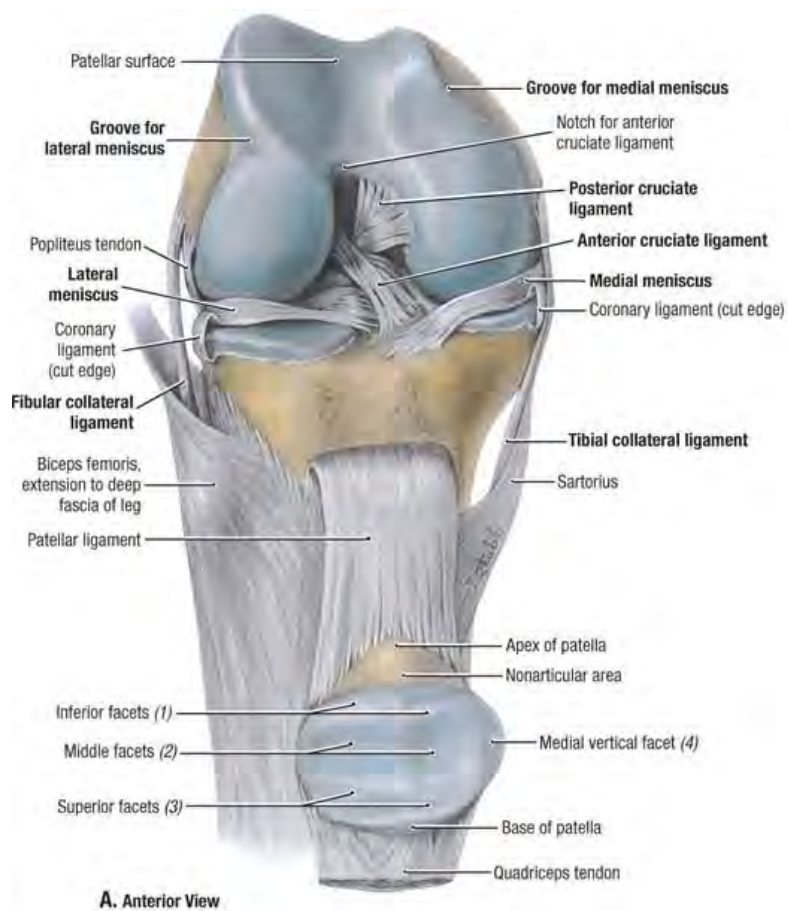
---

## 5.44 Articular surfaces and ligaments of knee joint

*Part of* "Chapter 5 - Lower Limb "

A. Flexed knee joint with patella reflected. There are indentations on the sides of the femoral condyles at the junction of the patellar and tibial articular areas. The lateral tibial articular area is shorter than the medial one. The notch at the anterolateral part of the intercondylar notch is for the anterior cruciate ligament on full extension. B. Distal femur. C. Tibial plateaus. D. Articular surfaces of patella. The three paired facets (superior, middle, and inferior) on the posterior surface of the patella articulate with the patellar surface of the femur successively during (1) extension, (2) slight flexion, (3) flexion, and the most medial vertical facet on the patella (4) articulates during full flexion with the crescentic facet on the medial margin of the intercondylar notch of the femur.

When the patella is dislocated, it nearly always dislocates laterally. The tendency toward lateral dislocation is normally counterbalanced by the medial, more horizontal pull of the powerful vastus medialis. In addition, the more anterior projection of the lateral femoral condyle and deeper slope for the large lateral patellar facet provides a mechanical deterrent to lateral dislocation. An imbalance of the lateral pull and the mechanisms resisting it result in abnormal tracking of the patella within the patellar groove and chronic patellar pain, even if actual dislocation does not occur. See Figure 5.49 blue box .



Authors: Agur, Anne M.R.; Dalley, Arthur F.

Title: *Grant's Atlas of Anatomy, 12th Edition*

Copyright ©2009 Lippincott Williams & Wilkins

> Table of Contents > Chapter 5 - Lower Limb > 5.45 Ligaments of knee joint

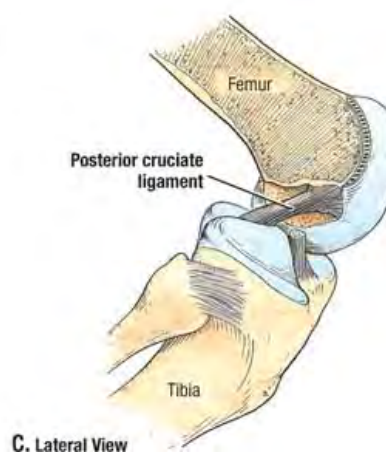
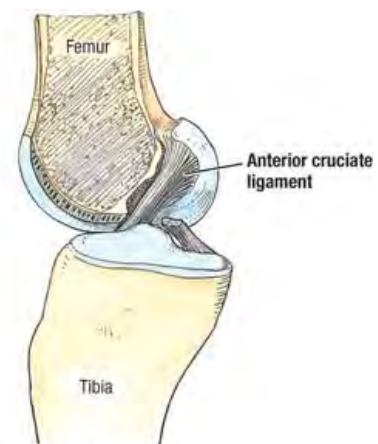
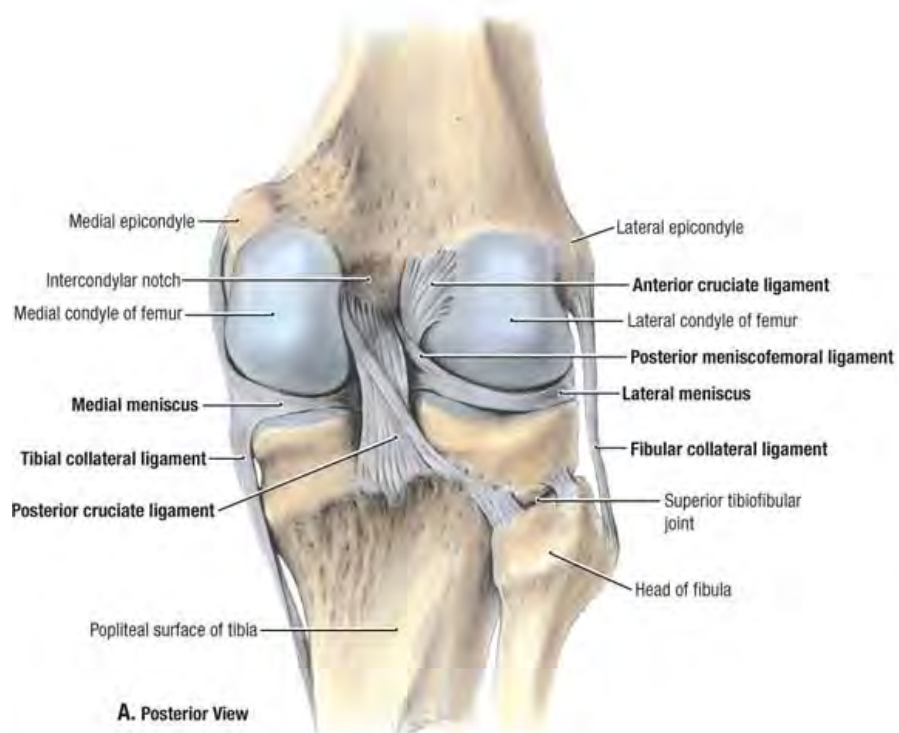
---

## 5.45 Ligaments of knee joint

*Part of "Chapter 5 - Lower Limb "*

A. Posterior aspect of joint. The bandlike tibial (medial) collateral ligament is attached to the medial meniscus, and the cordlike fibular (lateral) collateral ligament is separated from the lateral meniscus by the width of the popliteus tendon (removed). The posterior cruciate ligament is joined by a cord from the lateral meniscus called the posterior meniscomfemoral ligament. The posterior meniscomfemoral ligament attaches to the medial condyle of the femur just posterior to the attachment of the posterior cruciate ligament. B. Anterior cruciate ligament. C. Posterior cruciate ligament. In each illustration, half the femur is sagittally sectioned and removed with the proximal part of the corresponding cruciate ligament. Note that the posterior cruciate ligament prevents the femur from sliding anteriorly on the tibia, particularly when the knee is flexed. The anterior cruciate ligament prevents the femur from sliding posteriorly on the tibia, preventing hyperextension of the knee, and limits medial rotation of the femur when the foot is on the ground (i.e., when the leg is fixed).

Injury to the knee joint is frequently caused by a blow to the lateral side of the extended knee or excessive lateral twisting of the flexed knee, which disrupts the tibial collateral ligament and concomitantly tears and/or detaches the medial meniscus from the joint capsule. This injury is common in athletes who twist their flexed knees while running (e.g., in football and soccer). The anterior cruciate ligament, which serves as a pivot for rotary movements of the knee, is taut during flexion and may also tear subsequent to the rupture of the tibial collateral ligament, creating an "unhappy triad" of knee injuries.





Authors: Agur, Anne M.R.; Dalley, Arthur F.

Title: *Grant's Atlas of Anatomy, 12th Edition*

Copyright ©2009 Lippincott Williams & Wilkins

> Table of Contents > Chapter 5 - Lower Limb > 5.46 Cruciate ligaments and menisci

---

## 5.46 Cruciate ligaments and menisci

*Part of* "Chapter 5 - Lower Limb "

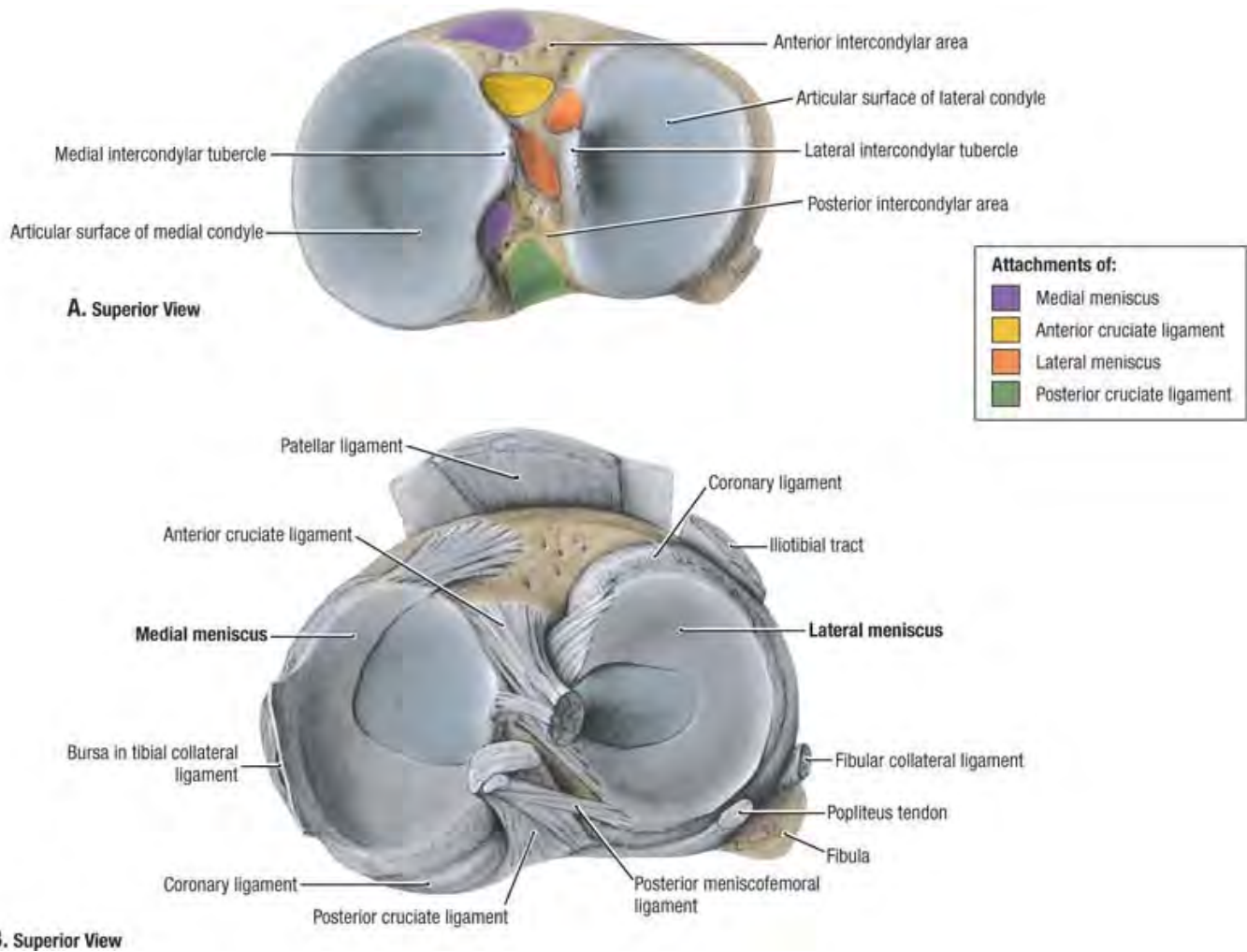
A. Attachments sites on tibia. B. Menisci in situ.

- The lateral tibial condyle is flatter, shorter from anterior to posterior, and more circular. The medial condyle is concave, longer from anterior to posterior, and more oval.

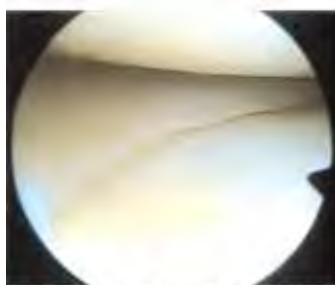
Arthroscopy is an endoscopic examination that allows visualization of the interior of the knee joint cavity with minimal disruption of tissue. The arthroscope and one (or more) additional canula(e) are inserted through tiny incisions, known as portals. The second canula is for passage of specialized tools (e.g., manipulative probes or forceps) or equipment for trimming, shaping, or removing damaged tissue. This technique allows removal of torn menisci, loose bodies in the joint such as bone chips, and debridement (the excision of devitalized articular cartilaginous material in advanced cases of arthritis). Ligament repair or replacement may also be performed using an arthroscope.

- The menisci conform to the shapes of the surfaces on which they rest. Because the horns of the lateral meniscus are attached close together and its coronary ligament is slack, this meniscus can slide anteriorly and posteriorly on the (flat) condyle; because the horns of the medial meniscus are attached further apart, its

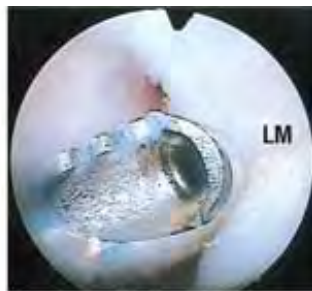
movements on the (concave) condyle are restricted.



P.414



Normal lateral meniscus of the knee



Trimming of a torn lateral meniscus (LM)

Authors: Agur, Anne M.R.; Dalley, Arthur F.

Title: *Grant's Atlas of Anatomy, 12th Edition*

Copyright ©2009 Lippincott Williams & Wilkins

> Table of Contents > Chapter 5 - Lower Limb > 5.47 Articularis genu and suprapatellar bursa

---

## 5.47 Articularis genu and suprapatellar bursa

*Part of* "Chapter 5 - Lower Limb "

A. Articularis genu (articular muscle of the knee). This muscle lies deep to the vastus intermedius muscle and consists of fibers arising from the anterior surface of the femur proximally and attaching into the synovial membrane distally. The articularis genu pulls the synovial membrane of the suprapatellar bursa (*dotted line*) superiorly during extension of the knee so that it will not be caught between the patella and femur within the knee joint. B. Lateral aspect of knee. Latex was injected into the articular cavity and fixed with acetic acid. The distended synovial membrane was exposed and cleaned. The gastrocnemius muscle was reflected proximally, and the biceps femoris muscle and the iliotibial tract were reflected distally. The extent of the synovial capsule: superiorly, it rises superior to the patella, where it rests on a layer of fat that allows it to glide freely with movements of the joint; this superior part is called the suprapatellar bursa; posteriorly, it rises as high as the origin of the gastrocnemius muscle; laterally, it curves inferior to the lateral femoral epicondyle, where the popliteus tendon and fibular collateral ligament are attached; and inferiorly, it bulges inferior to the lateral meniscus, overlapping the tibia (the coronary ligament is removed to show this).

Prepatellar bursitis (housemaid's knee) is usually a friction bursitis caused by friction between the skin and the patella. The suprapatellar bursa communicates with the articular cavity of the knee joint; consequently, abrasions or penetrating wounds superior to the patella may result in suprapatellar bursitis caused by bacteria entering the bursa from the torn skin. The infection may spread to the knee joint.

### Suprapatellar

Between femur and tendon of quadriceps femoris

Held in position by articular muscle of knee; communicates freely with synovial cavity of knee joint

### Popliteus

Between tendon of popliteus and lateral condyle of tibia

Opens into synovial cavity of knee joint, inferior to lateral meniscus

### Anserine

Separates tendons of sartorius, gracilis, and semitendinosus from tibia and tibial collateral ligament

Area where tendons of these muscles attach to tibia resembles the foot of a goose (L. *pes*, foot; L. *anser*, goose)

### Medial subtendinous bursa of gastrocnemius

Lies deep to proximal attachment of tendon of medial head of gastrocnemius

This bursa is an extension of synovial cavity of knee joint

### Semimembranosus

Located between medial head of gastrocnemius and semimembranosus tendon

Related to the distal attachment of semimembranosus

### Subcutaneous prepatellar

Lies between skin and anterior surface of patella

Allows free movement of skin over patella during movements of leg

### Subcutaneous infrapatellar

Located between skin and tibial tuberosity

Helps knee to withstand pressure when kneeling

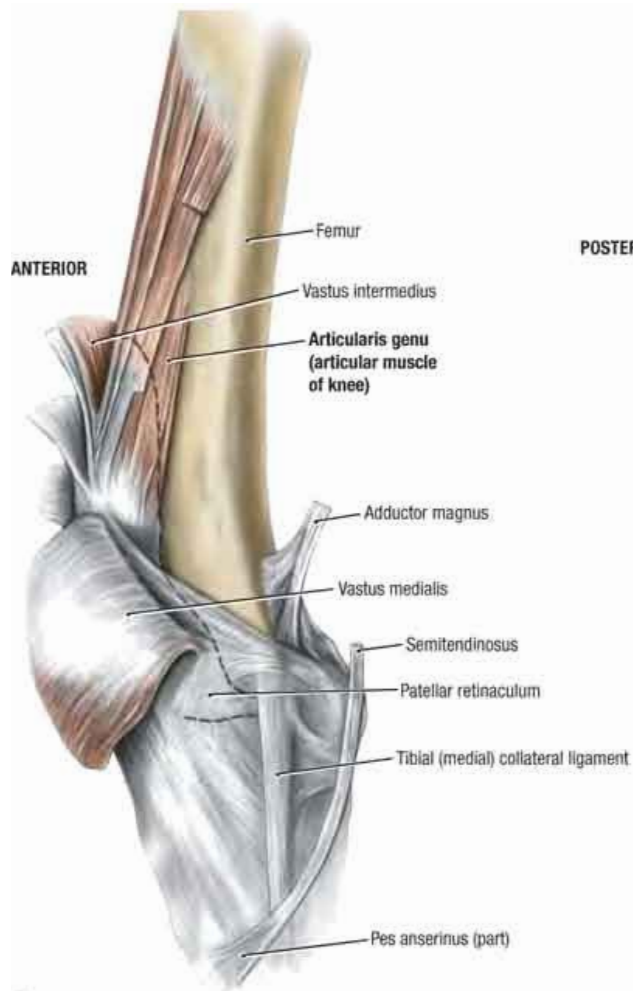### Deep infrapatellar

Lies between patellar ligament and anterior surface of tibia

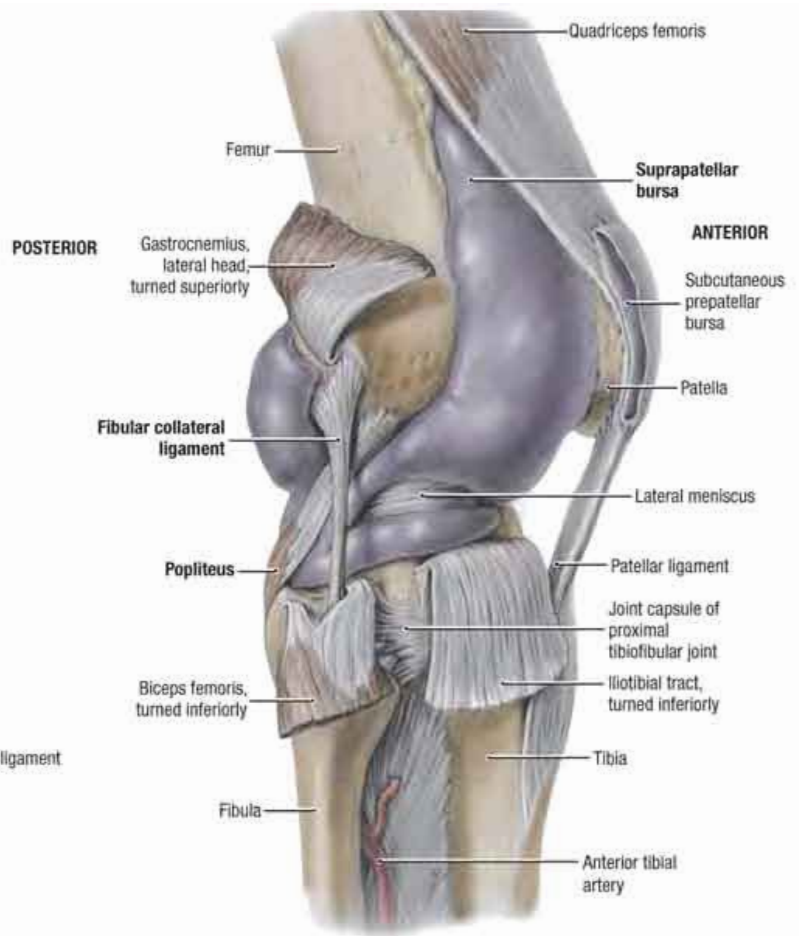
Separated from knee joint by infrapatellar fat-pad

Bursa	Location	Structural Features or Functions
-------	----------	----------------------------------

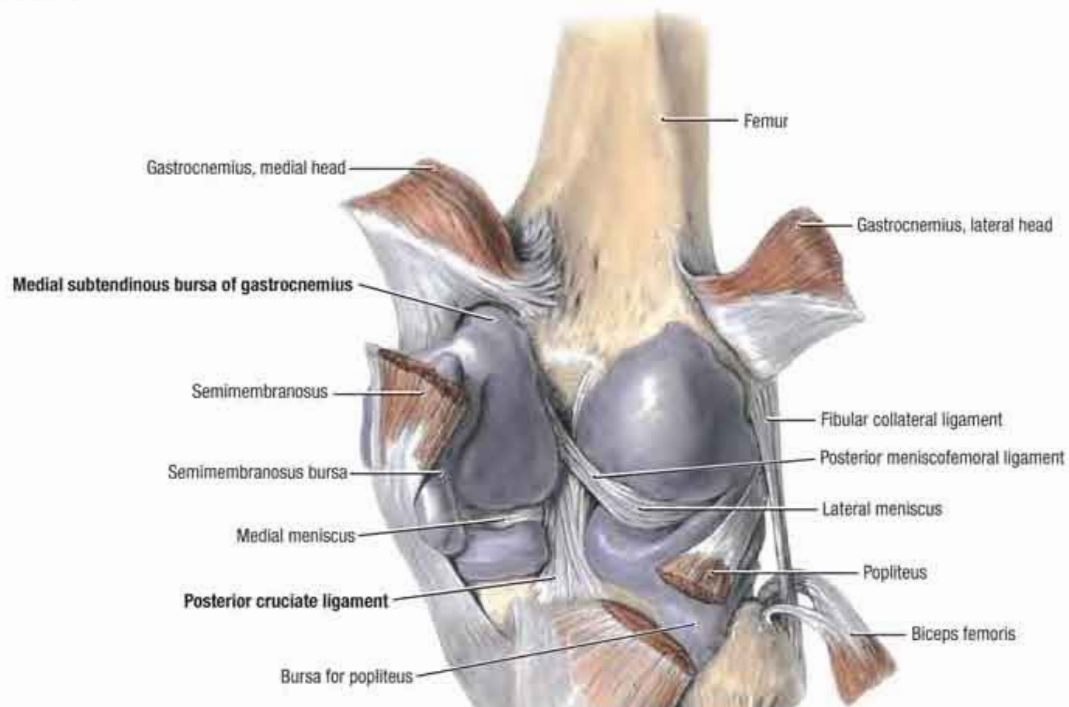
Table 5.8 Bursae Around Knee



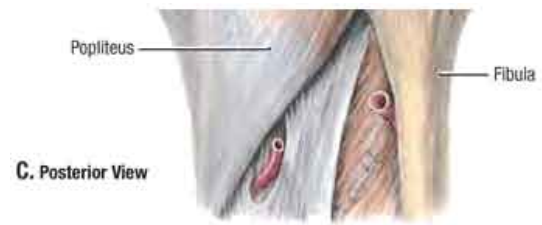
**A. Medial View**



**B. Lateral View**







Authors: Agur, Anne M.R.; Dalley, Arthur F.

Title: *Grant's Atlas of Anatomy, 12th Edition*

Copyright ©2009 Lippincott Williams & Wilkins

> Table of Contents > Chapter 5 - Lower Limb > 5.48 Anastomoses around knee

---

## 5.48 Anastomoses around knee

*Part of* "Chapter 5 - Lower Limb "

A. Genicular anastomosis on the anterior aspect of the knee. B. Popliteal artery in popliteal fossa.

- The popliteal artery runs from the adductor hiatus (in the adductor magnus muscle) proximally to the inferior border of the popliteus muscle distally, where it bifurcates into the anterior and posterior tibial arteries.
- The three anterior relations of the popliteal artery include the femur (fat intervening), the joint capsule of the knee; and the popliteus muscle.
- Five genicular branches of the popliteal artery supply the capsule and ligaments of the knee joint. The genicular arteries are the superior lateral, superior medial, middle, inferior lateral, and inferior medial genicular arteries.

---

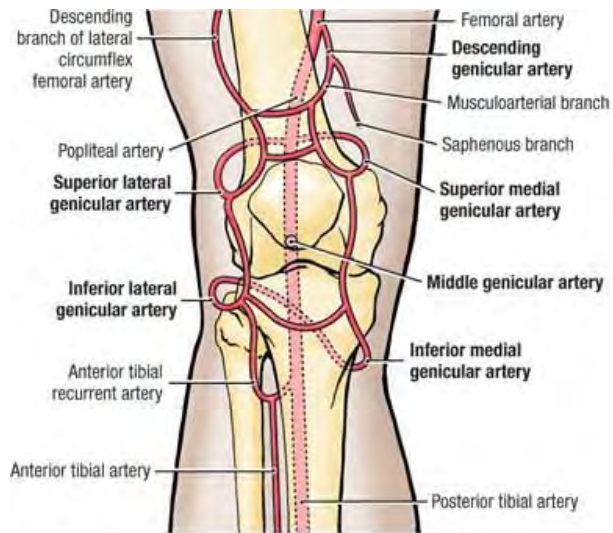
P.417

C. Medial aspect of the knee showing superior and inferior medial genicular arteries. D. Lateral aspect of the knee showing superior and inferior lateral genicular arteries.

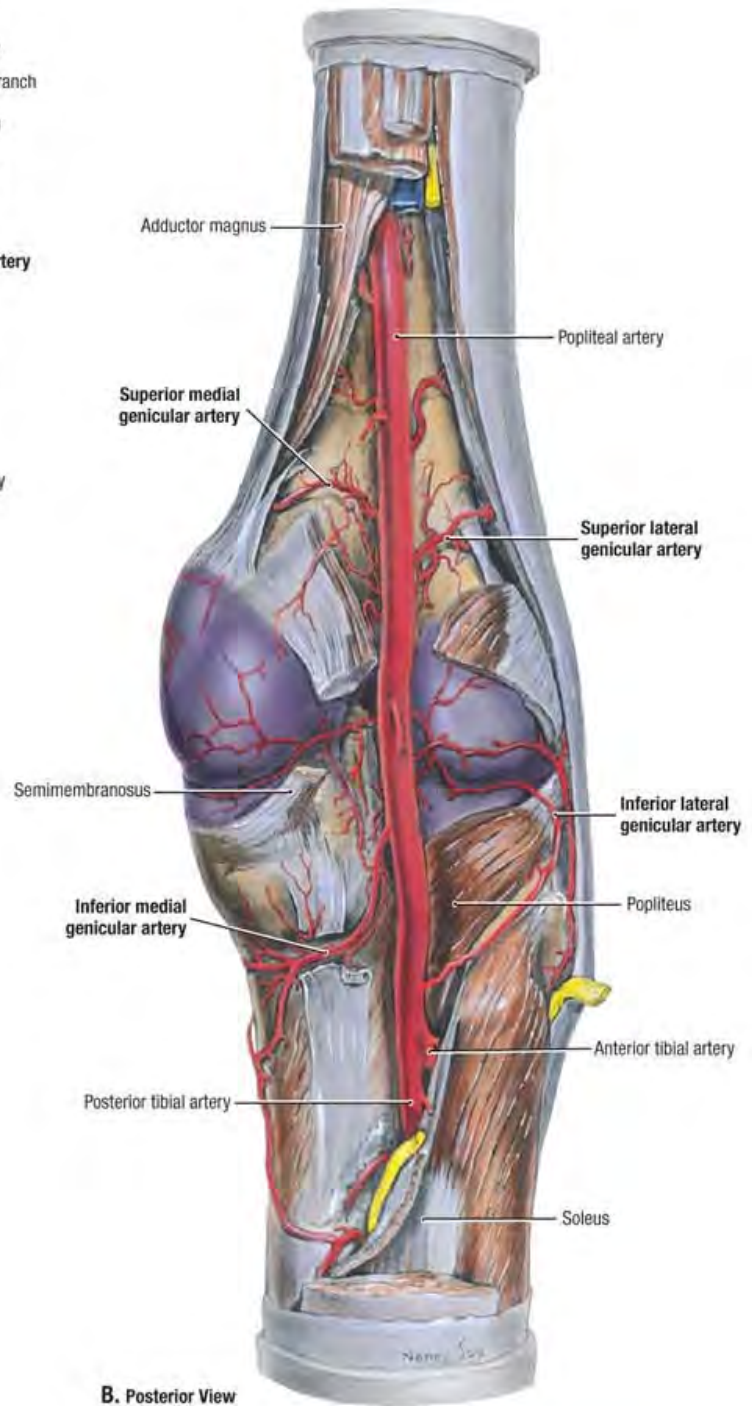
The genicular arteries participate in the formation of the periarticular genicular anastomosis, a network of vessels surrounding the knee that provides collateral circulation capable of maintaining blood supply to the leg during full knee flexion, which may kink the popliteal artery. Other contributors to this important anastomosis are the descending genicular artery, a branch of the femoral artery, superomedially; descending branch of the lateral circumflex femoral artery, superolaterally; and anterior tibial

recurrent artery, a branch of the anterior tibial artery, inferolaterally.

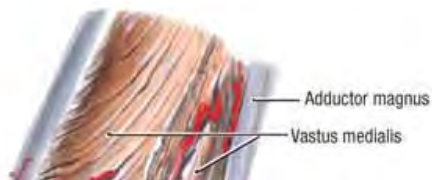
P.418

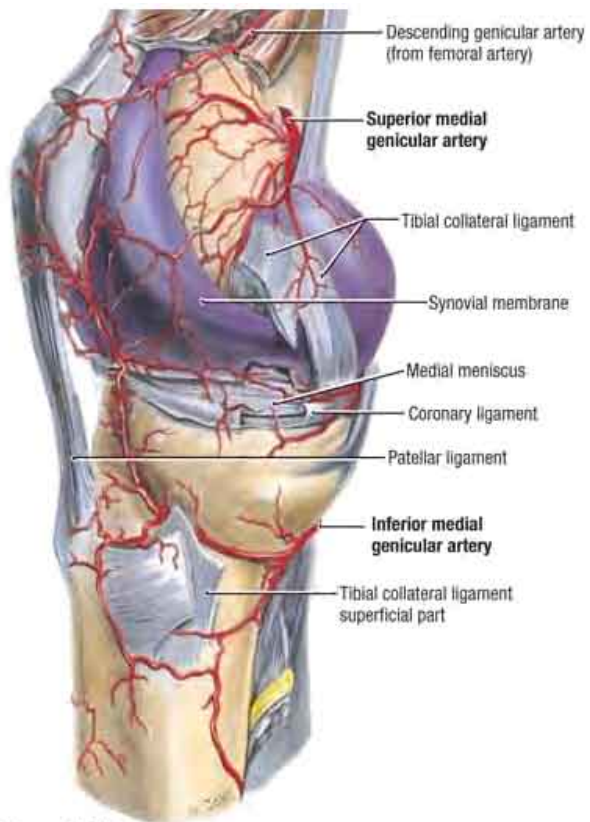


**A. Anterior View**

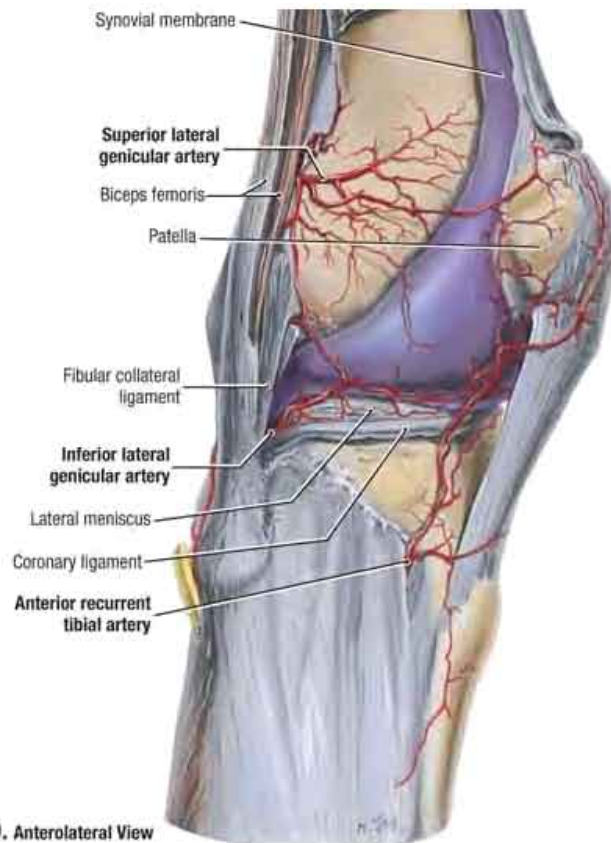


**B. Posterior View**





**C. Anteromedial View**



**D. Anterolateral View**

Authors: Agur, Anne M.R.; Dalley, Arthur F.

Title: *Grant's Atlas of Anatomy, 12th Edition*

Copyright ©2009 Lippincott Williams & Wilkins

> Table of Contents > Chapter 5 - Lower Limb > 5.49 Imaging of the knee and patellofemoral articulation

---

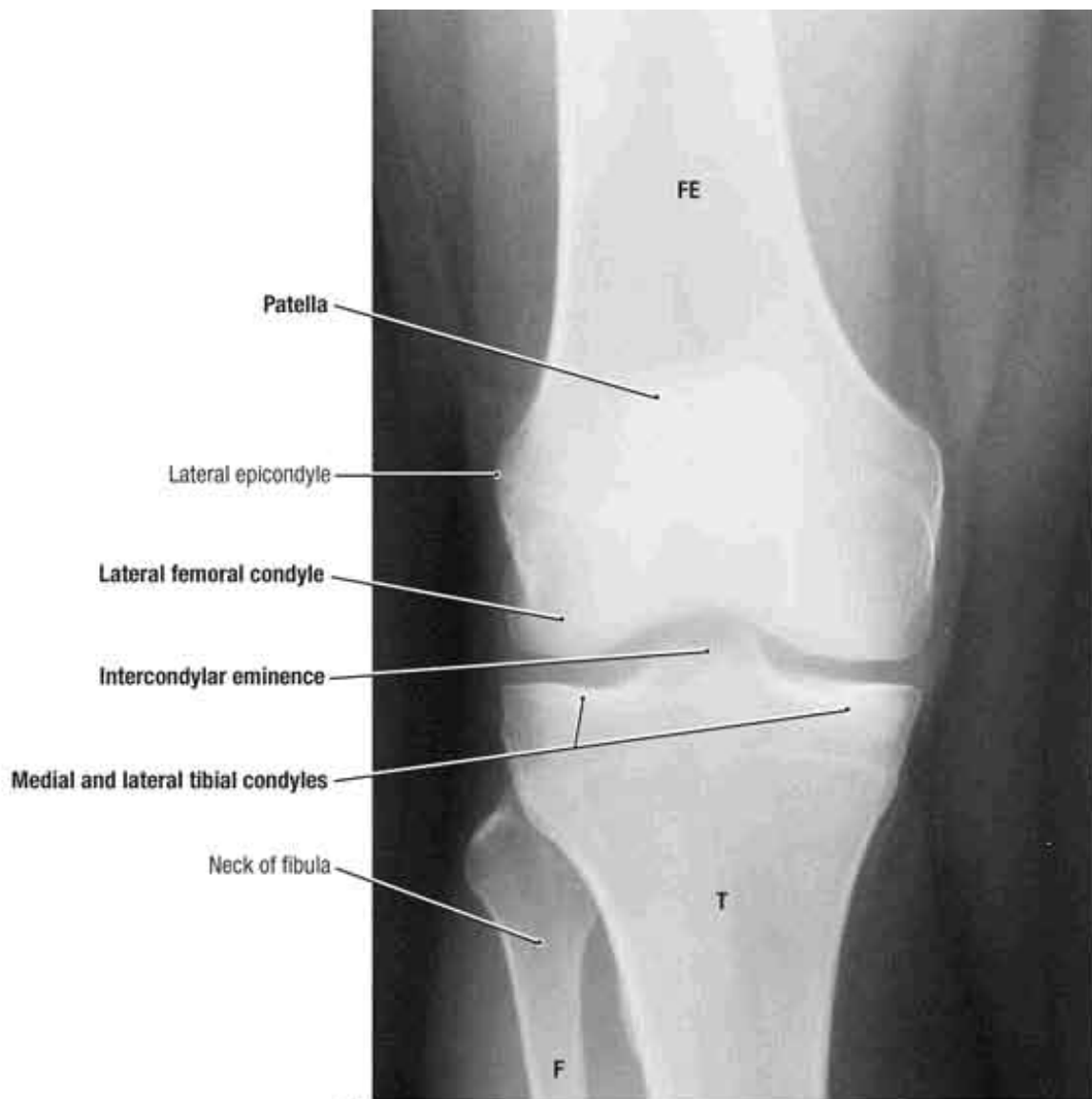
## 5.49 Imaging of the knee and patellofemoral articulation

*Part of* "Chapter 5 - Lower Limb "

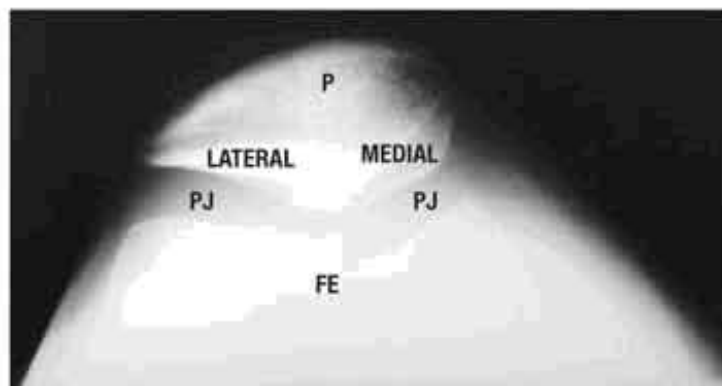
A. Anteroposterior radiograph of knee. B. Radiograph of patella (knee joint flexed). *FE*, femur; *FP*, fat pad; *P*, patella; *PJ*, patellofemoral joint. C. Transverse MRI showing the patellofemoral joint.

Pain deep to the patella often results from excessive running, especially downhill; hence, this type of pain is often called "runner's knee." The pain results from repetitive microtrauma caused by abnormal tracking of the patella relative to the patellar surface of the femur, a condition known as the patellofemoral syndrome. This syndrome may also result from a direct blow to the patella and from osteoarthritis of the patellofemoral compartment (degenerative wear and tear of articular cartilages). In some cases, strengthening of the vastus medialis corrects patellofemoral dysfunction. This muscle tends to prevent lateral dislocation of the patella resulting from the Q-angle because the vastus medialis attaches to and pulls on the medial border of the patella. Hence, weakness of the vastus medialis predisposes the individual to patellofemoral dysfunction and patellar dislocation.

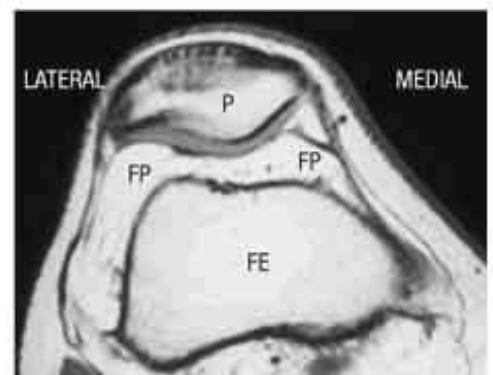




**A. Anteroposterior View**



**B. Skyline View (Knee in Flexion)**



**C. Transverse MRI**

Authors: Agur, Anne M.R.; Dalley, Arthur F.

Title: *Grant's Atlas of Anatomy, 12th Edition*

Copyright ©2009 Lippincott Williams & Wilkins

> Table of Contents > Chapter 5 - Lower Limb > 5.50 Coronal section and MRIs of knee

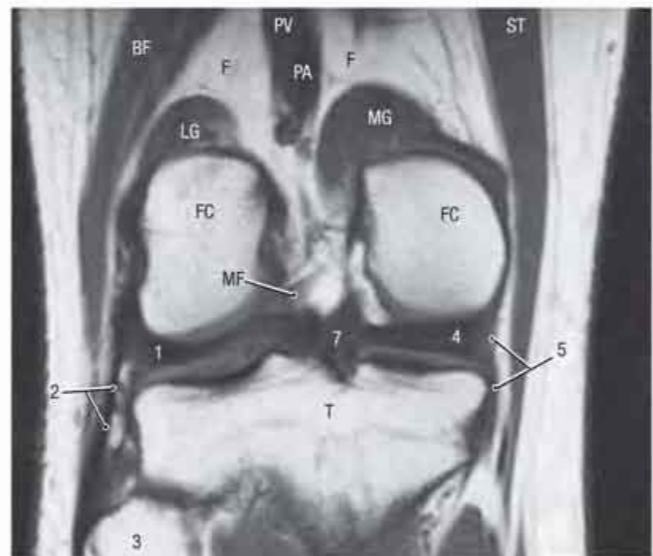
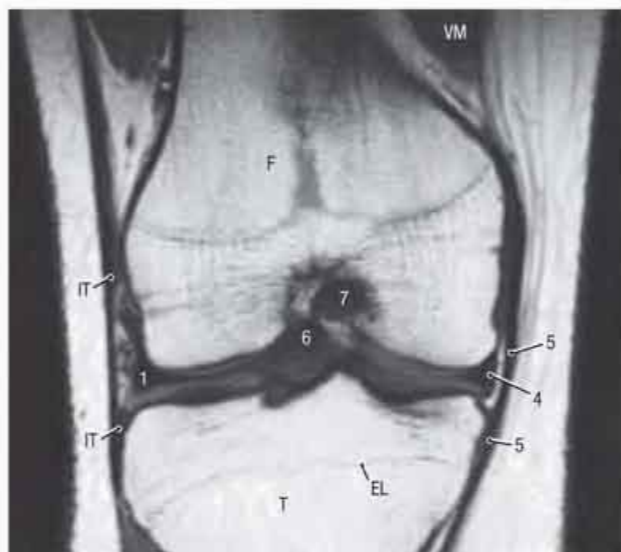
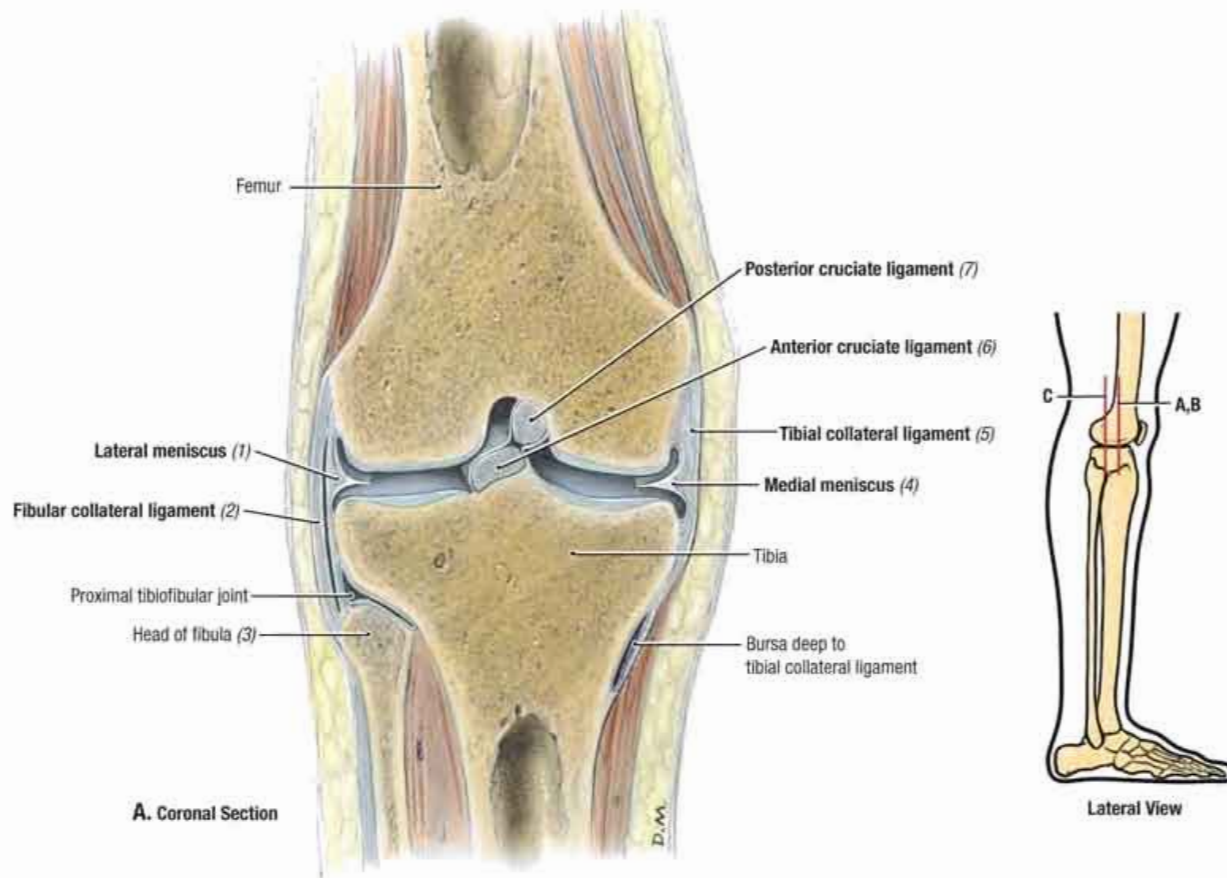
---

## 5.50 Coronal section and MRIs of knee

*Part of "Chapter 5 - Lower Limb "*

A. Section through intercondylar notch of femur, tibia, and fibula. B. MRI through intercondylar notch of femur and tibia. C. MRI through femoral condyles tibia and fibula.

*Numbers* in MRIs refer to structures in A. *VM*, vastus medialis; *EL*, epiphyseal line; *IT*, iliotibial tract; *FC*, femoral condyle; *BF*, biceps femoris; *ST*, semitendinosus; *LG*, lateral head of gastrocnemius; *MG*, medial head of gastrocnemius; *PV*, popliteal vein; *PA*, popliteal artery; *F*, fat in popliteal fossa; *MF*, meniscofemoral ligament.



B. Coronal MRI

C. Coronal MRI

Authors: Agur, Anne M.R.; Dalley, Arthur F.

Title: *Grant's Atlas of Anatomy, 12th Edition*

Copyright ©2009 Lippincott Williams & Wilkins

> Table of Contents > Chapter 5 - Lower Limb > 5.51 Radiograph of knee

---

## 5.51 Radiograph of knee

*Part of* "Chapter 5 - Lower Limb"

Lateral radiograph of flexed knee. *FE*, femur; *T*, tibia; *F*, fibula; *A*, apex of fibula; *S*, fabella; *P*, patella. The fabella is a sesamoid bone in the lateral head of gastrocnemius muscle.

Quadriceps femoris

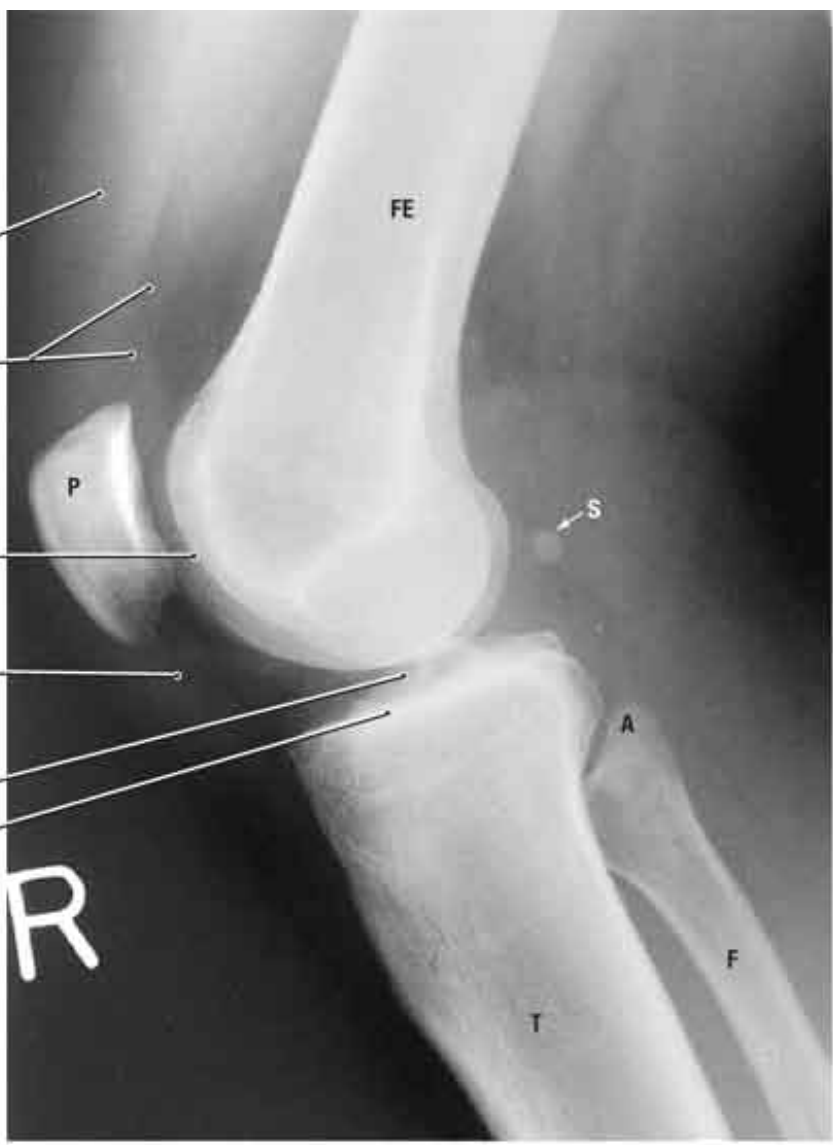Suprapatellar bursa

Medial femoral condyle

Patellar ligament

Intercondylar eminence

Medial tibial condyle



Lateral View



## 5.52 Sagittal section and MRIs of knee

*Part of* "Chapter 5 - Lower Limb "

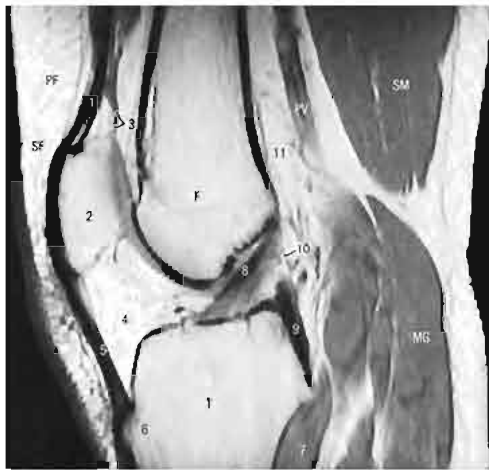A. (*Opposite page*). Section through lateral aspect of intercondylar notch of femur. B. MRI through medial aspect of intercondylar notch of femur showing cruciate ligaments. C. MRI through medial femoral and tibial condyles. *Numbers* in MRIs refer to structures in A. *SM*, semimembranosus; *ST*, semitendinosus; *MG*, medial head of gastrocnemius; *VM*, vastus medialis; *PF*, prefemoral fat; *SF*, suprapatellar fat; *AM*, anterior horn of medial meniscus; *PM*, posterior horn of medial meniscus; *PV*, popliteal vessels.

---

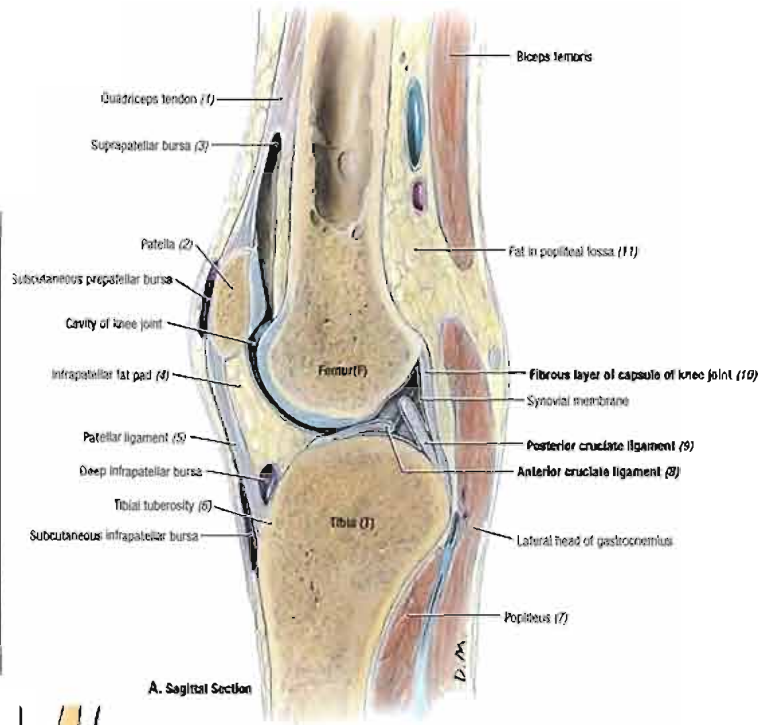
P.421

---


P.422



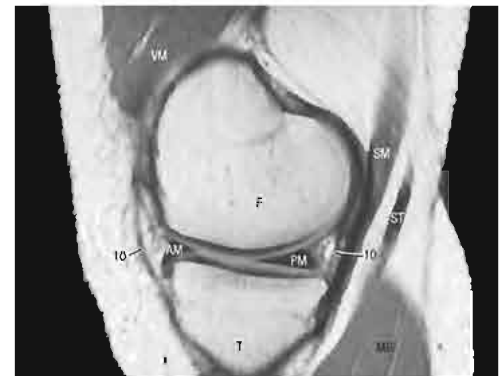B. Sagittal MRI



A. Sagittal Section



Anterior View



C. Sagittal MRI

Authors: Agur, Anne M.R.; Dalley, Arthur F.

Title: *Grant's Atlas of Anatomy, 12th Edition*

Copyright ©2009 Lippincott Williams & Wilkins

> Table of Contents > Chapter 5 - Lower Limb > 5.53 Anterior leg's superficial muscles

---

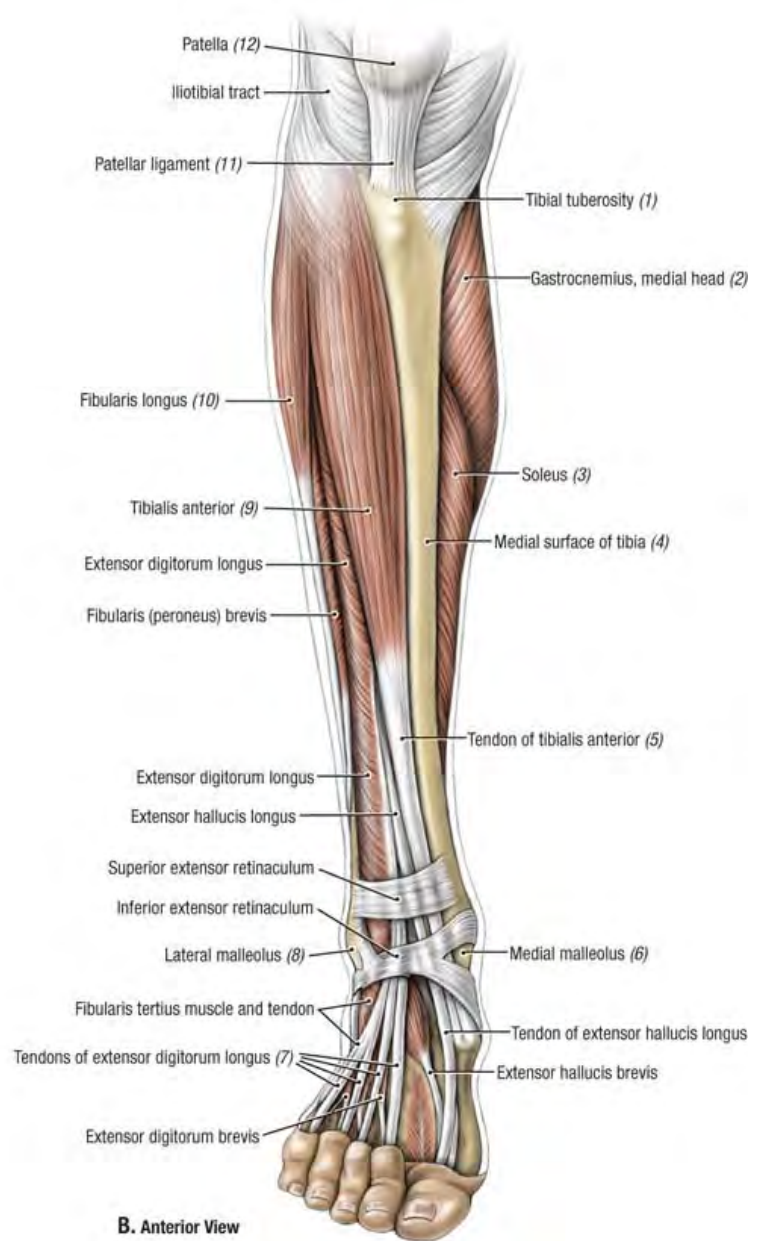
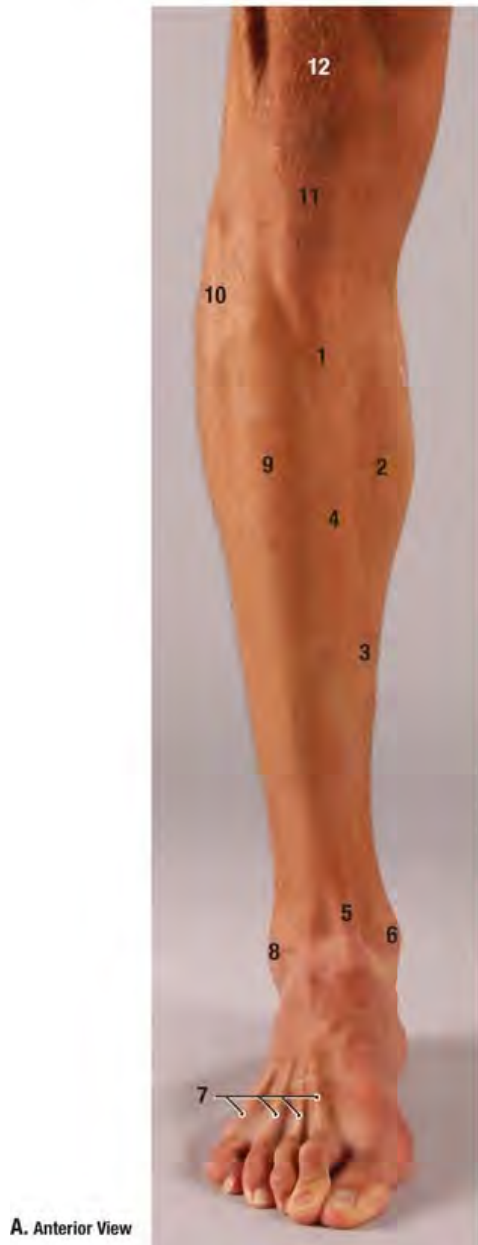## 5.53 Anterior leg's superficial muscles

*Part of* "Chapter 5 - Lower Limb "

A. Surface anatomy (*numbers* refer to structures labeled in B ). B. Dissection.

The muscles of the anterior compartment are ankle dorsiflexors/toe extensors. They are active in walking as they concentrically contract to raise the forefoot to clear the ground during the swing phase of the gait cycle and eccentrically contract to lower the forefoot to the ground after the heel strike of the stance phase.

Shin splints, edema, and pain in the area of the distal third of the tibia, result from repetitive microtrauma of the anterior compartment muscles, especially the tibialis anterior. This produces a mild form of anterior compartment syndrome. The pain commonly occurs during traumatic injury or athletic overexertion of the muscles. Edema and muscle-tendon inflammation causes swelling that reduces blood flow to the muscles. The swollen ischemic muscles are painful and tender to pressure.



Tibialis anterior

Lateral condyle and superior half of lateral surface of tibia

Medial and inferior surfaces of medial cuneiform and base of first metatarsal

Deep fibular (peroneal) nerve (L4 – L5)

Dorsiflexes ankle and inverts foot

Extensor hallucis longus

Middle part of anterior surface of fibula and interosseous membrane

Dorsal aspect of base of distal phalanx of great toe (hallux)

Deep fibular (peroneal) nerve (L5–S1)

Extends great toe and dorsiflexes ankle

Extensor digitorum longus

Lateral condyle of tibia and superior three fourths of anterior surface of interosseous membrane

Middle and distal phalanges of lateral four digits

Extends lateral four digits and dorsiflexes ankle

Fibularis (peroneus) tertius

Inferior third of anterior surface of fibula and interosseus membrane

Dorsum of base of fifth metatarsal

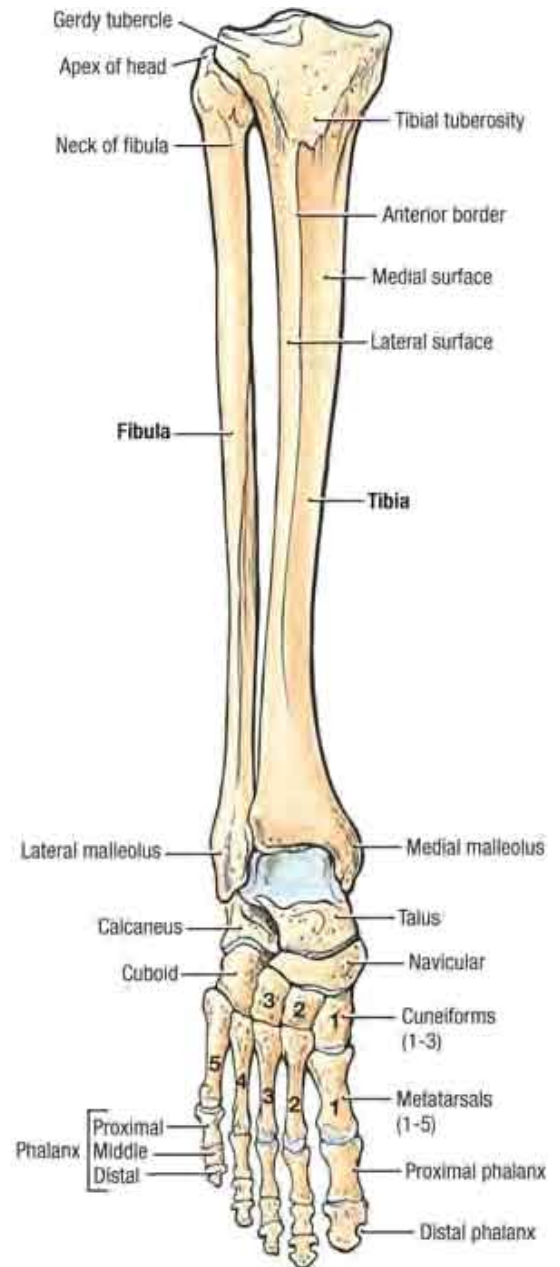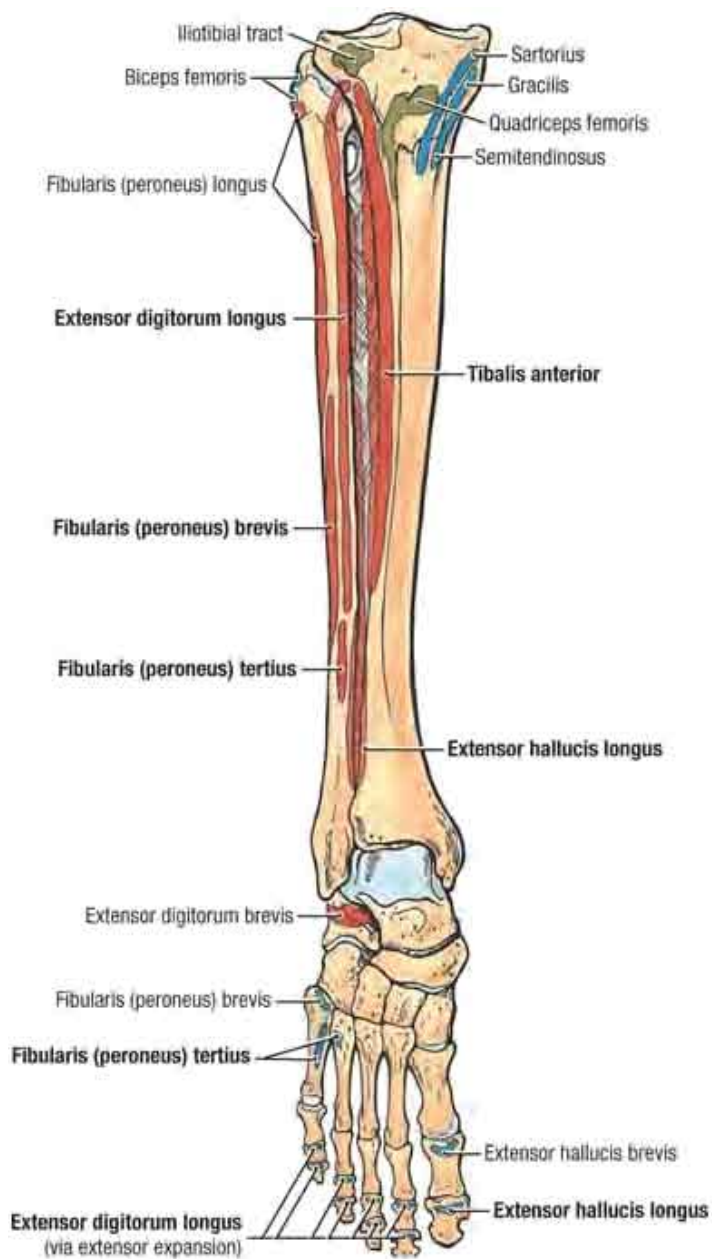
Dorsiflexes ankle and aids in eversion of foot

<sup>a</sup>See Table 5.1 for explanation of segmental innervation.

Muscle	Proximal Attachment	Distal Attachment	Innervation <sup>a</sup>	Main Actions
--------	---------------------	-------------------	--------------------------	--------------

<h2>Table 5.9 Muscles of the Anterior Compartment of Leg</h2>
---





Anterior Views

Authors: Agur, Anne M.R.; Dalley, Arthur F.

Title: *Grant's Atlas of Anatomy, 12th Edition*

Copyright ©2009 Lippincott Williams & Wilkins

> Table of Contents > Chapter 5 - Lower Limb > 5.54 Anterior leg "deep muscles, nerves and vessels

---

## 5.54 Anterior leg "deep muscles, nerves and vessels

*Part of* "Chapter 5 - Lower Limb "

Common fibular

Sciatic nerve

Forms as sciatic nerve bifurcates at apex of popliteal fossa and follows medial border of biceps femoris; winds around neck of fibula, dividing into superficial and deep fibular nerves

Skin on lateral part of posterior aspect of leg via the lateral sural nerve; lateral aspect of knee joint via its articular branch

Superficial fibular

Common fibular nerve

Arises deep to fibularis longus and descends in lateral compartment of leg; pierces crural fascia at distal third of leg to become cutaneous

Fibularis longus and brevis and skin on distal third of anterolateral surface of leg and dorsum of foot

Deep fibular

Common fibular nerve

Arises deep to fibularis longus; passes through extensor digitorum longus, descends on interosseous membrane, and enters dorsum of foot

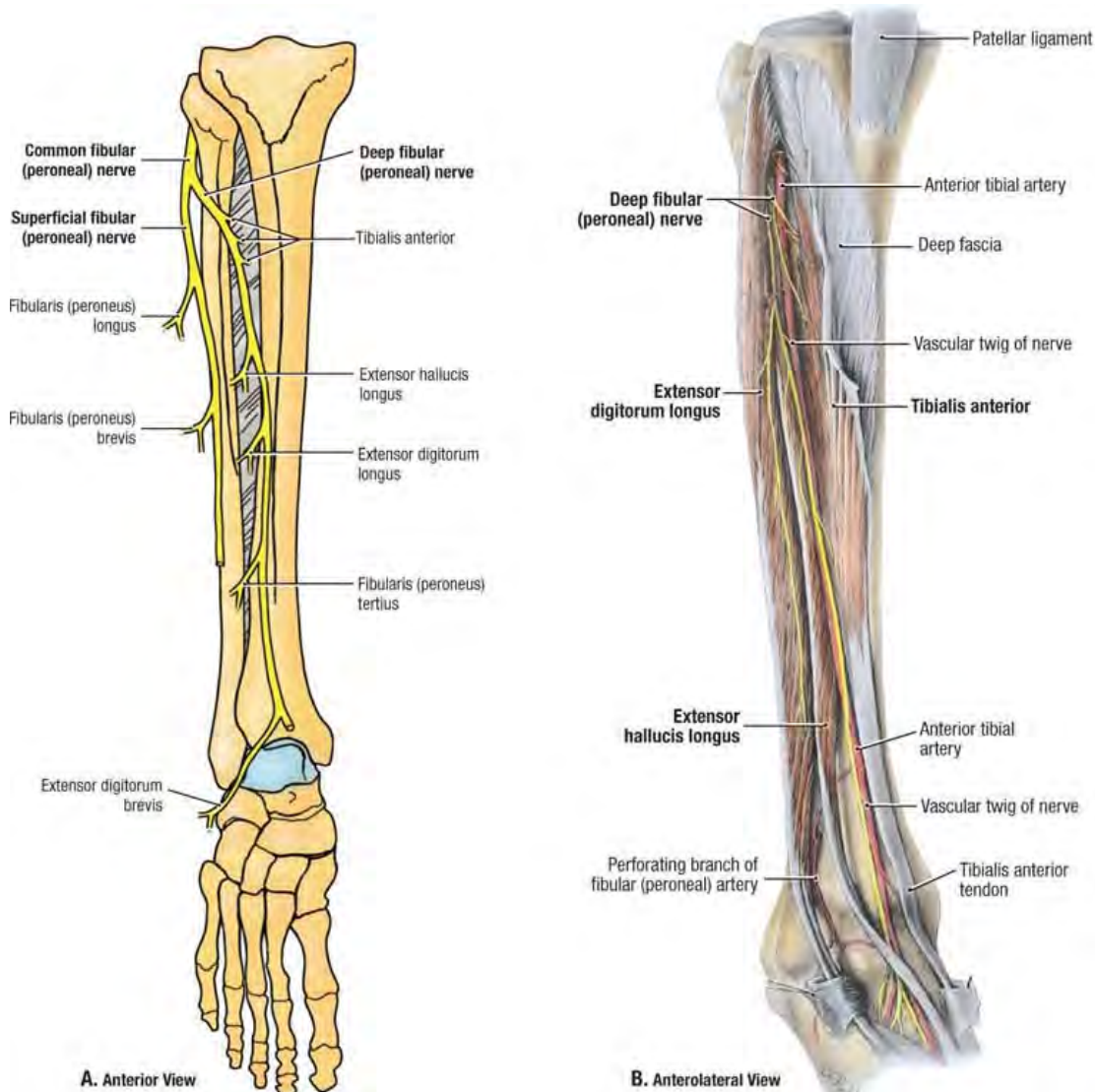
Anterior muscles of leg, dorsum of foot, and skin of first interdigital cleft; dorsal aspect of joints crossed via articular branches

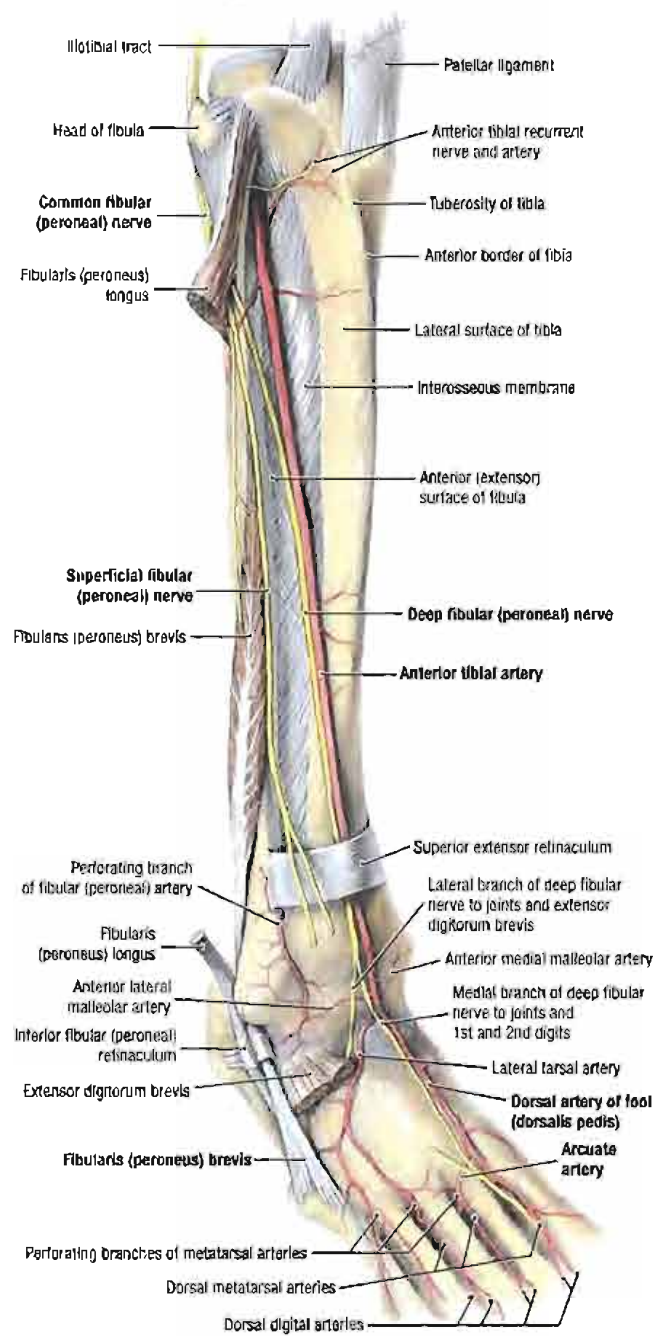
Table 5.10 Common, Superficial, and Deep Fibular Nerves

P.425

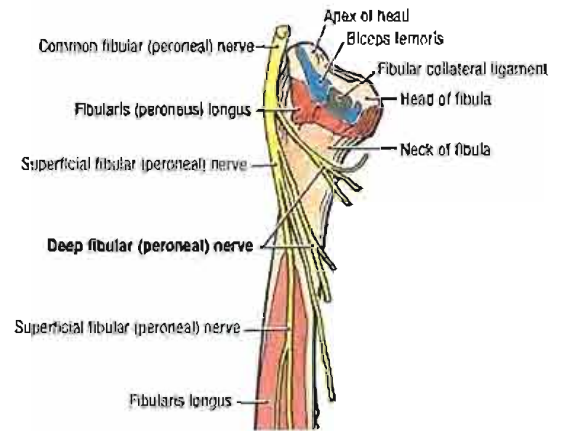
A. Overview of motor innervation. B. Deep dissection of the anterior compartment of the leg. The muscles are separated to display the anterior tibial artery and deep fibular nerve. C. Neurovascular structures. D. Relations of common fibular nerve and branches to the proximal fibula.

P.426





**C. Anterolateral View**



**D. Lateral View**

Authors: Agur, Anne M.R.; Dalley, Arthur F.

Title: *Grant's Atlas of Anatomy, 12th Edition*

Copyright ©2009 Lippincott Williams & Wilkins

> Table of Contents > Chapter 5 - Lower Limb > 5.55 Dorsum of foot

---

## 5.55 Dorsum of foot

*Part of* "Chapter 5 - Lower Limb "

A. Surface anatomy (*numbers* refer to structures labeled in B ). B. Dissection. The dorsal vein of foot and deep fibular nerve are cut.

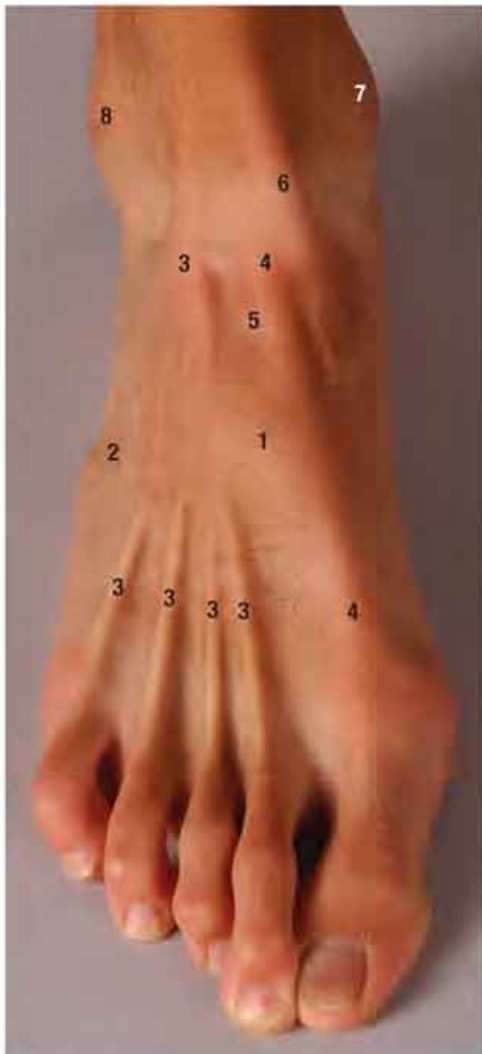
At the ankle, the dorsalis pedis artery (dorsal artery of foot) and deep fibular nerve lie midway between the malleoli. On the dorsum of the foot, the dorsal artery of foot is crossed by the extensor hallucis brevis muscle and disappears between the two heads of the first dorsal interosseous muscle.

Clinically, knowing the location of the belly of the extensor digitorum brevis is important for distinguishing this muscle from abnormal edema.

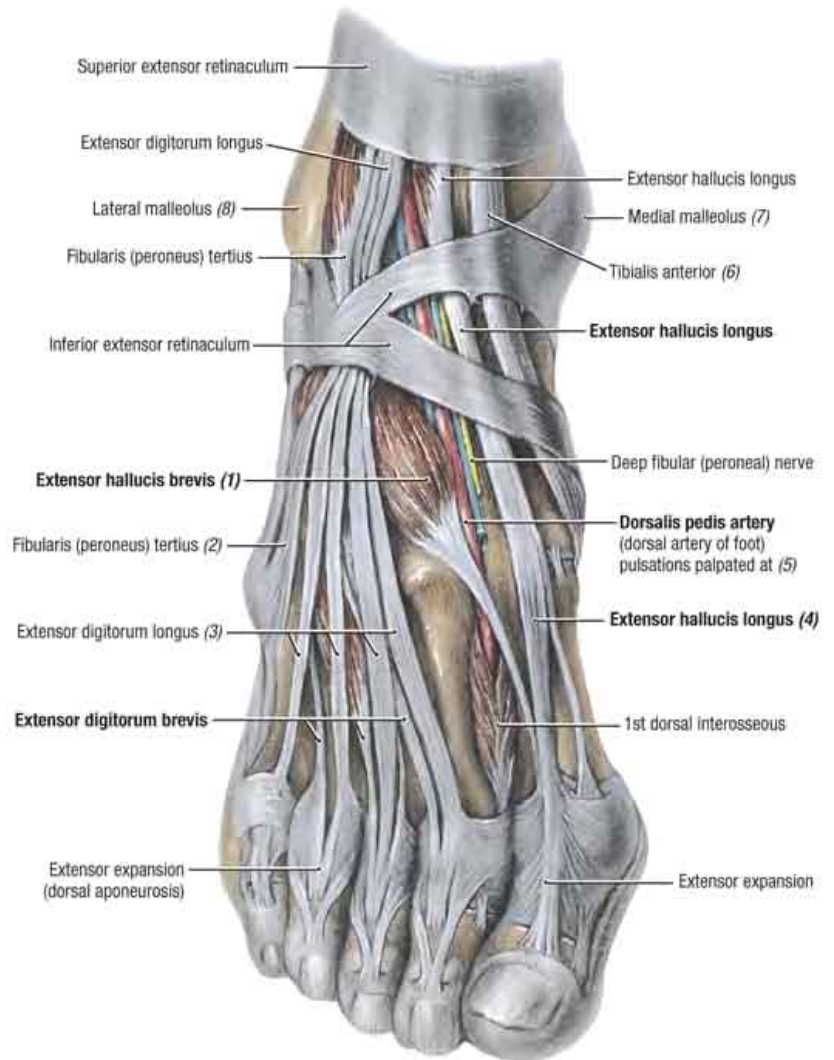
Contusion and tearing of the muscle fibers and associated blood vessels result in a hematoma, producing edema anteromedial to the lateral malleolus. Most people who have not seen this inflamed muscle assume they have a severely sprained ankle.

Dorsalis pedis pulses may be palpated with the feet slightly dorsiflexed. The pulses are usually easy to palpate because the dorsal arteries of the foot are subcutaneous and pass along a line from the extensor retinaculum to a point just lateral to the extensor hallucis longus tendon. A diminished or absent dorsalis pedis pulse usually suggests vascular insufficiency resulting from arterial disease.





**A. Superior View**



**B. Superior View**

Authors: Agur, Anne M.R.; Dalley, Arthur F.

Title: *Grant's Atlas of Anatomy, 12th Edition*

Copyright ©2009 Lippincott Williams & Wilkins

> Table of Contents > Chapter 5 - Lower Limb > 5.56 Attachments of muscles and arteries of the dorsum of foot

---

## 5.56 Attachments of muscles and arteries of the dorsum of foot

*Part of* "Chapter 5 - Lower Limb "

A. Attachments. B. Arterial supply.

(L. *dorsalis pedis*) Dorsal artery of foot

Continuation of anterior tibial artery distal to talocrural joint

Descends anteromedially to 1st interosseous space and divides into plantar and arcuate arteries

Lateral tarsal artery

Dorsal artery of foot

Runs an arched course laterally beneath extensor digitorum brevis to anastomose with branches of arcuate artery

Arcuate artery

Runs laterally from 1st interosseous space across bases of lateral four metatarsals, deep to extensor tendons

Deep plantar artery

Passes to sole of foot and joins plantar arch

Metatarsal arteries

1st

Deep plantar artery

Run between metatarsals to clefts of toes where each vessel divides into two dorsal

digital arteries.

2nd to 4th

Arcuate artery

Perforating arteries connect to plantar arch and plantar metatarsal arteries.

Dorsal digital arteries

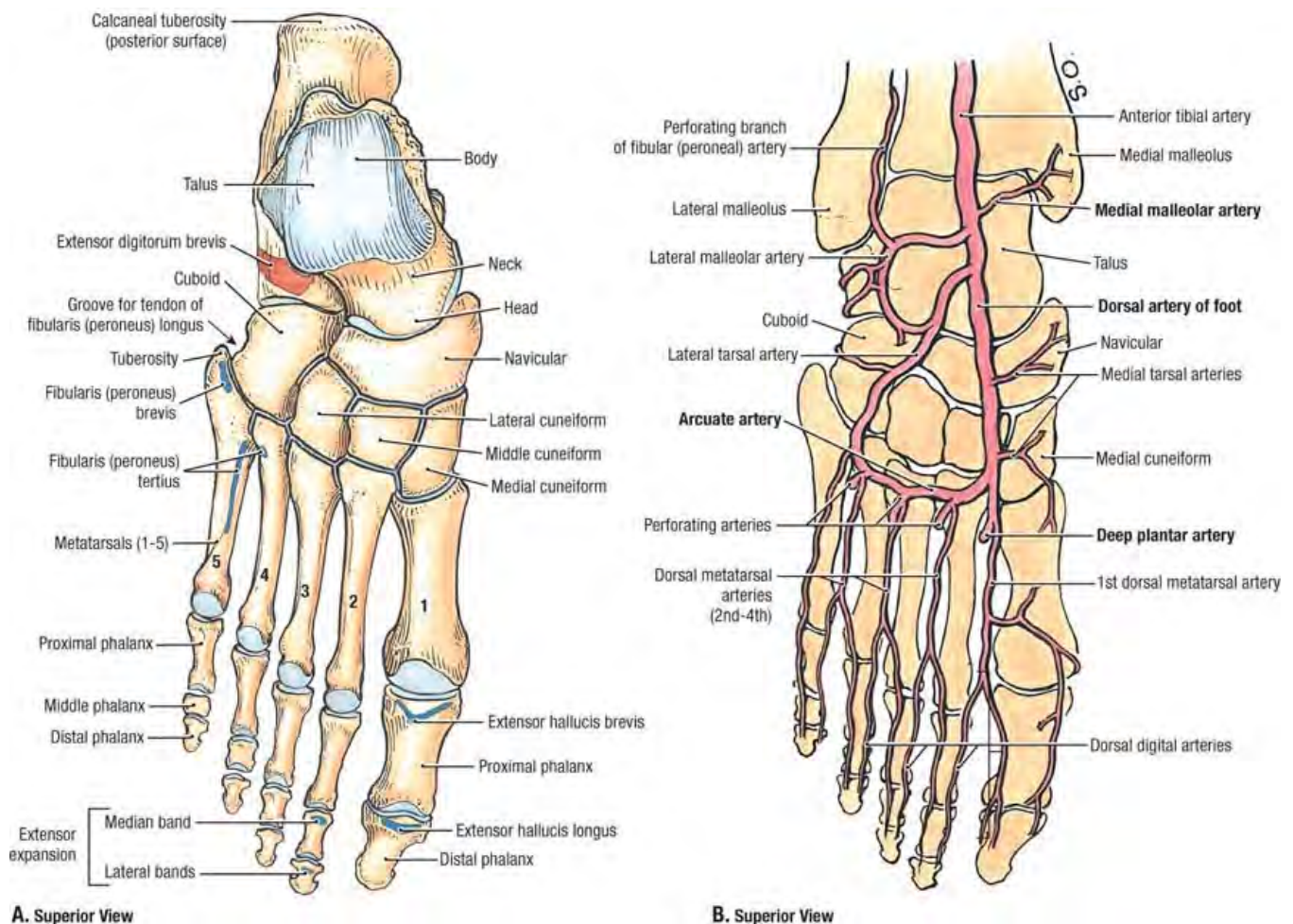
Metatarsal arteries

Pass to sides of adjoining toes

Artery    Origin    Course and Distribution

Table 5.11 Arterial Supply To Dorsum Of Foot

P.428



Authors: Agur, Anne M.R.; Dalley, Arthur F.

Title: *Grant's Atlas of Anatomy, 12th Edition*

Copyright ©2009 Lippincott Williams & Wilkins

> Table of Contents > Chapter 5 - Lower Limb > 5.57 Muscles of lateral aspect of leg and foot

---

## 5.57 Muscles of lateral aspect of leg and foot

*Part of* "Chapter 5 - Lower Limb "

A. Surface anatomy. B. Dissection

- The two fibular (peroneal) muscles both attach to two thirds of the fibula, the fibularis (peroneus) longus muscle to the proximal two thirds, and the fibularis (peroneus) brevis muscle to the distal two thirds. Where they overlap, the fibularis brevis muscle lies anteriorly.
- The fibularis (peroneus) longus muscle enters the foot by hooking around the cuboid and traveling medially to the base of the first metatarsal and medial cuneiform.

The common fibular (peroneal) nerve is in contact with the neck of the fibula deep to the fibularis longus muscle. Here it is vulnerable to injury with serious implications; because it supplies the extensor and everter muscle groups, loss of function results in foot-drop (inability to dorsiflex the ankle) and difficulty in everting the foot.

---

P.429

C. Fibularis (peroneus) longus. D. Fibularis (peroneus) brevis. E. Attachments sites on fibula.

Fibularis (peroneus) longus

Head and superior two thirds of lateral surface of fibula

Base of first metatarsal and medial cuneiform

Superficial fibular (peroneal) nerve (L5, S1 , and S2 )

Evert foot and weakly plantarflex ankle

Fibularis (peroneus) brevis

Inferior two thirds of lateral surface of fibula

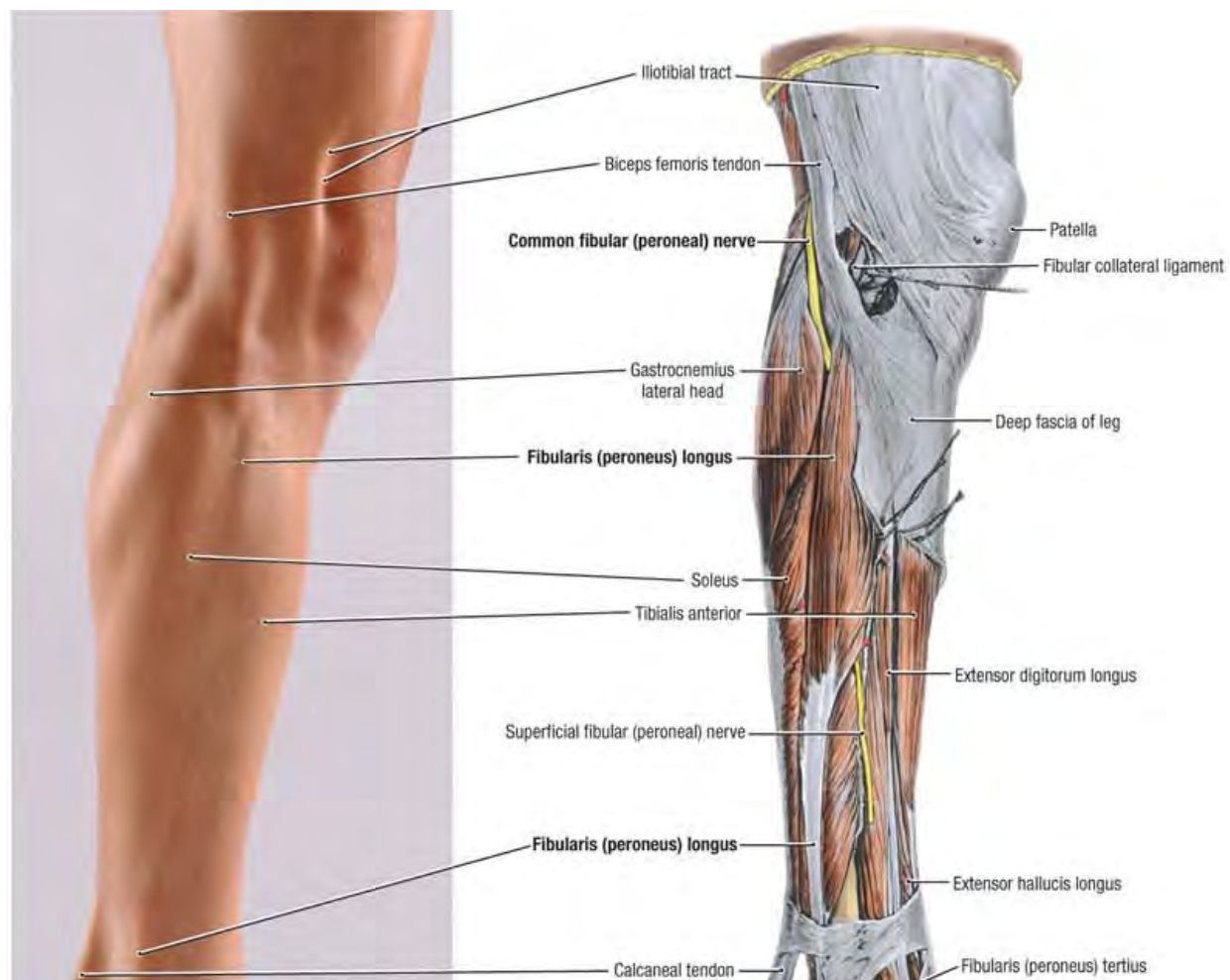
Dorsal surface of tuberosity on lateral side of base of fifth metatarsal

<sup>a</sup>See Table 5.1 for explanation of segmental innervation

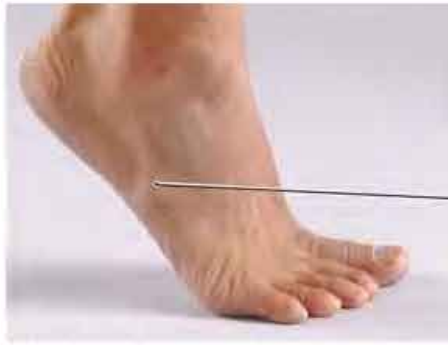Muscle	Proximal Attachment	Distal Attachment	Innervation <sup>a</sup>	Main Actions
--------	---------------------	-------------------	--------------------------	--------------

Table 5.12 Muscles of the Lateral Compartment of Leg

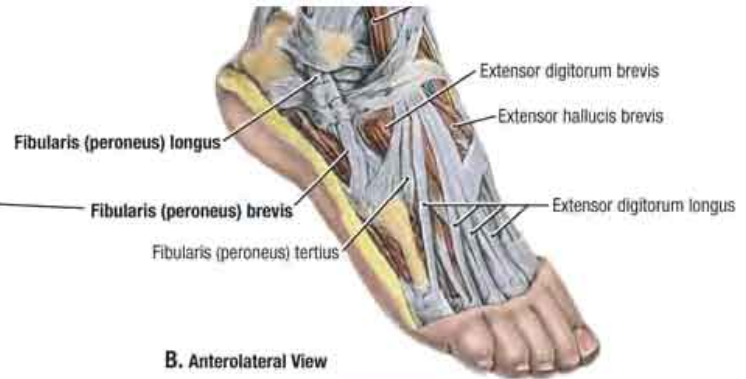
P.430



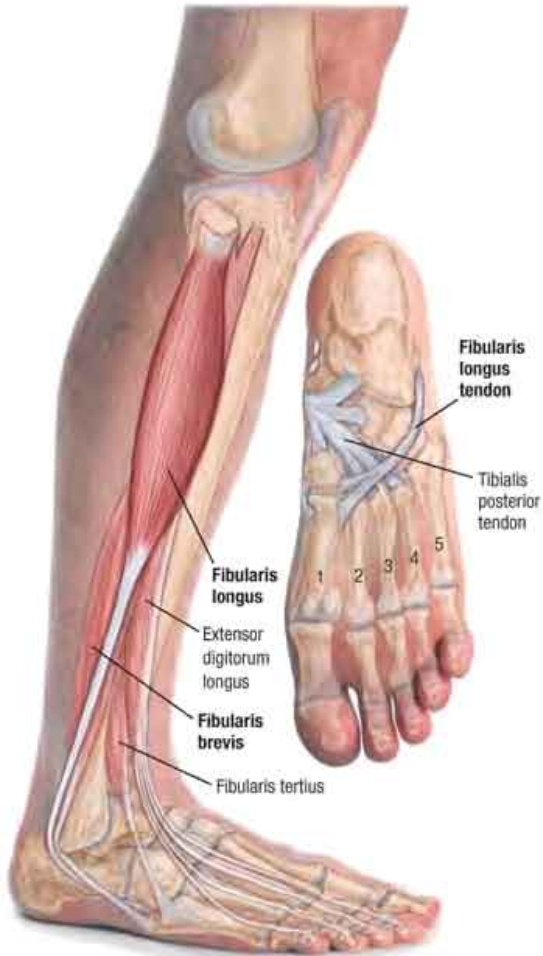




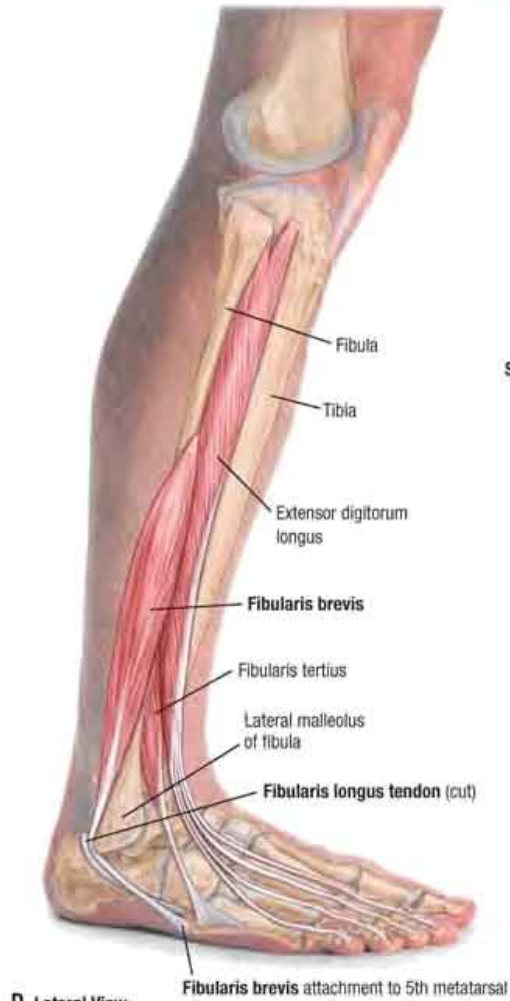
**A. Anterolateral View**



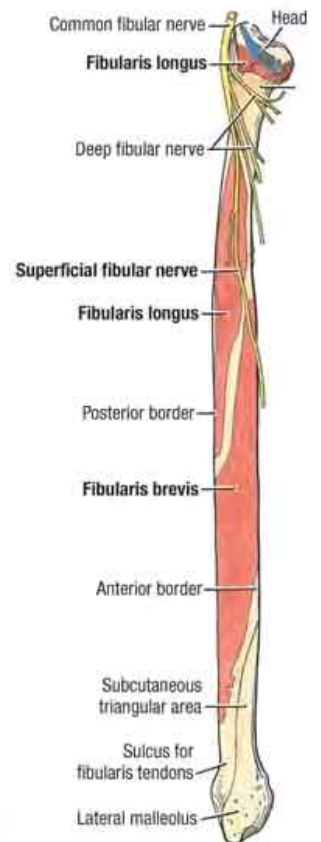
**B. Anterolateral View**



**C. Lateral View**



**D. Lateral View**



**E. Lateral View**

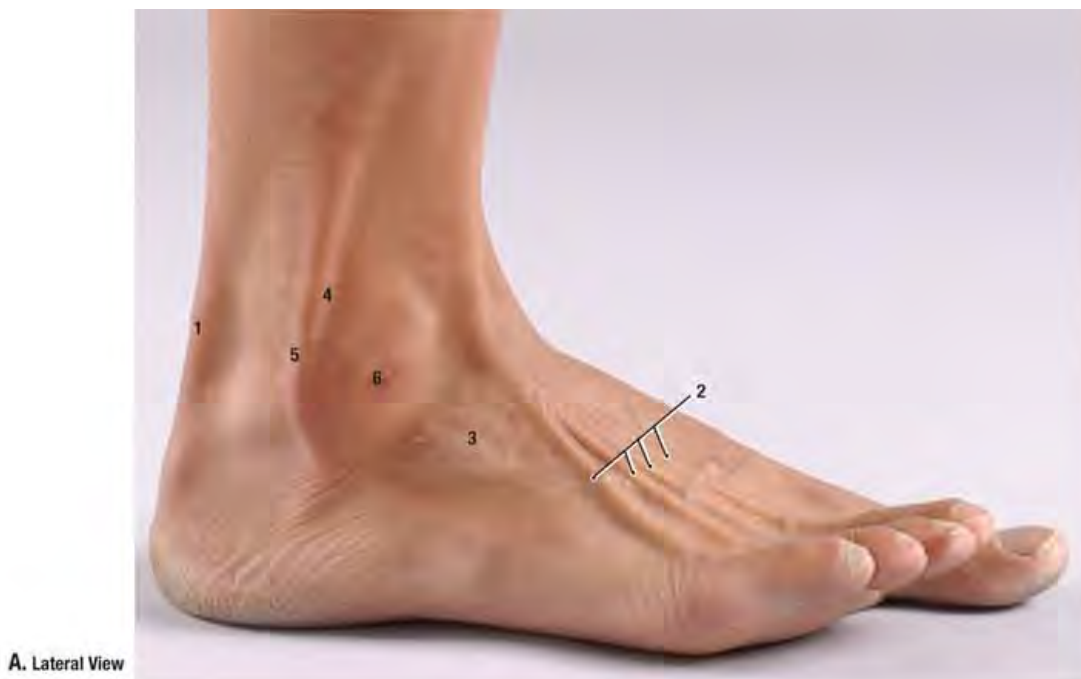## 5.58 Synovial sheaths and tendons at ankle


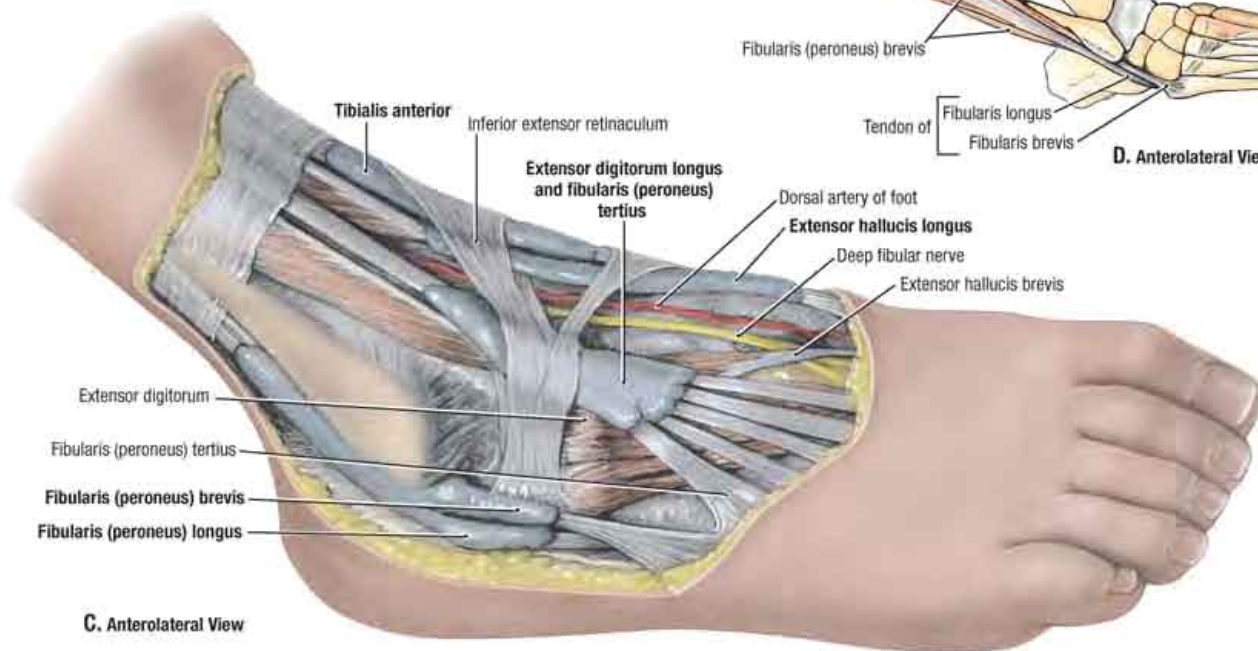
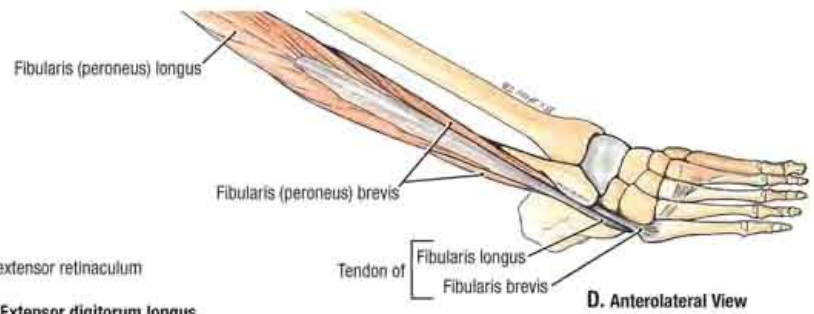
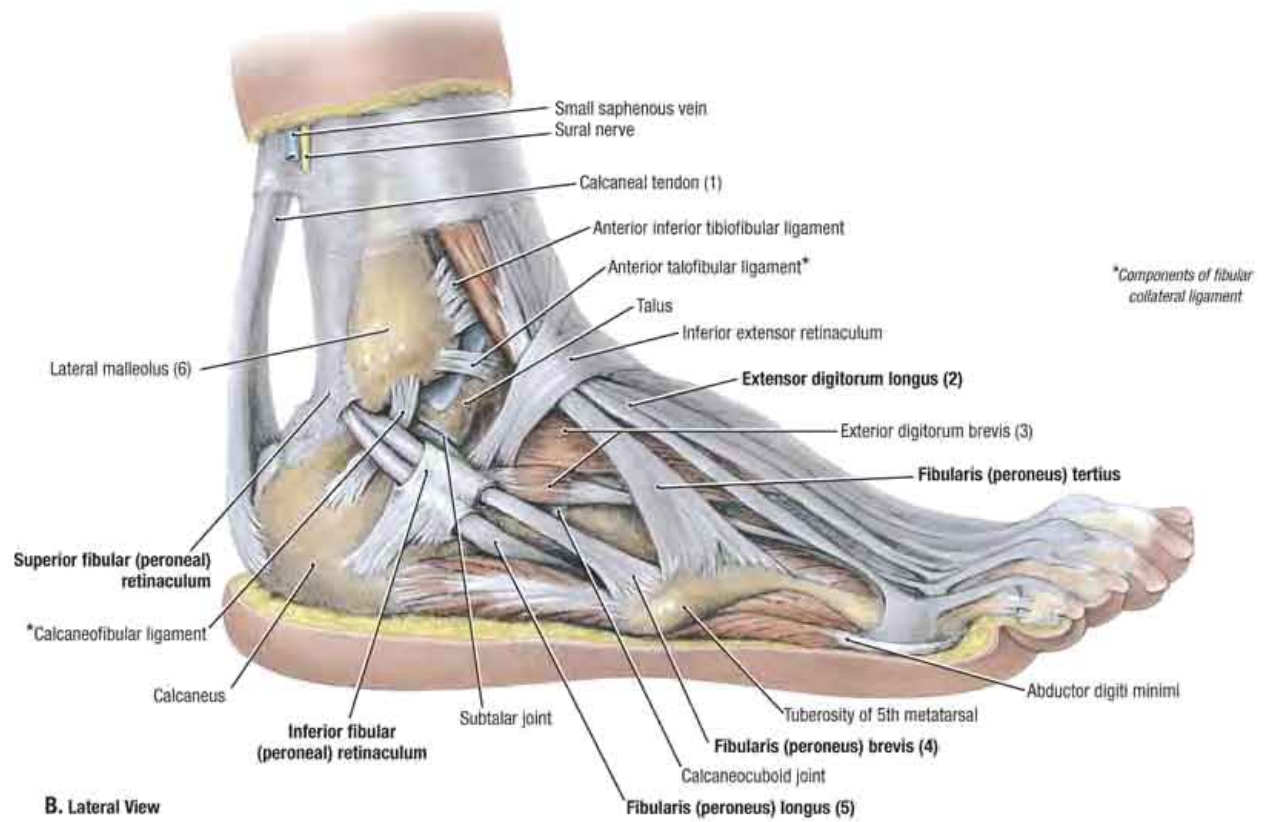
Part of "Chapter 5 - Lower Limb "

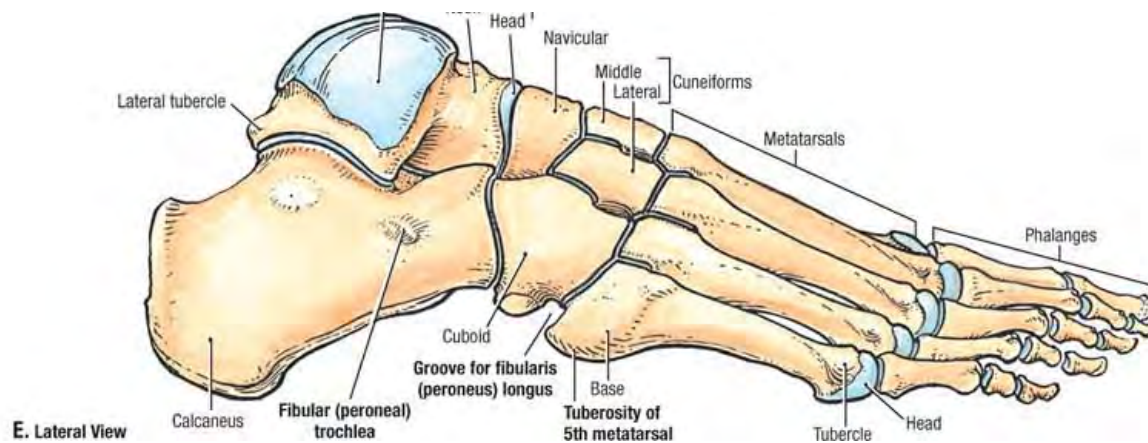
P.431

A. Surface anatomy (*numbers* refer to structures labeled in B ). B. Tendons at the lateral aspect of the ankle. C. Synovial sheaths of tendons on the anterolateral aspect of the ankle. The tendons of the fibularis (peroneus) longus and fibularis (peroneus) brevis muscles are enclosed in a common synovial sheath posterior to the lateral malleolus. This sheath splits into two, one for each tendon, posterior to the fibular (peroneal) trochlea. D. Schematic illustration of fibularis longus and brevis. E. Lateral aspect of bones of foot.

P.432







## Superficial muscles

### Gastrocnemius

*Lateral head:* lateral aspect of lateral condyle of femur

Posterior surface of calcaneus with calcaneal tendon (tendocalcaneus)

Tibial nerve (S1 and S2)

Plantarflexes ankle when knee is extended; raises heel during walking, and flexes leg at knee joint

*Medial head:* popliteal surface of femur, superior to medial condyle to medial condyle

### Soleus

Posterior aspect of head of fibula, superior fourth of posterior surface of fibula, soleal line and medial border of tibia

Plantarflexes ankle (independent of knee position) and steadies leg on foot

### Plantaris

Inferior end of lateral supracondylar supracondylar line of femur and oblique popliteal ligament

Weakly assists gastrocnemius in plantarflexing ankle and flexing knee

## Deep muscles

### Popliteus

Lateral surface of lateral condyle of femur and lateral meniscus

Posterior surface of tibia, superior to soleal line

Tibial nerve (L4, L5, and S1)

Unlocks fully extended knee (laterally rotates femur 5° on planted tibia); weakly flexes knee

### Flexor hallucis longus

Inferior two thirds of posterior surface of fibula and inferior part of interosseous



membrane

Base of distal phalanx of great toe (hallux)

Flexes great toe at all joints and plantarflexes ankle; supports medial longitudinal arch of foot

Flexor digitorum longus

Medial part of posterior surface of tibia inferior to soleal line, and by a broad tendon to fibula

Bases of distal phalanges of lateral four digits

Tibial nerve (S2 and S3)

Flexes lateral four digits and plantarflexes ankle; supports longitudinal arches of foot

Tibialis posterior

Interosseous membrane, posterior surface of tibia inferior to soleal line and posterior surface of fibula

Tuberosity of navicular, cuneiform, and cuboid and bases of metatarsals 2–4

Tibial nerve (L4 and L5)

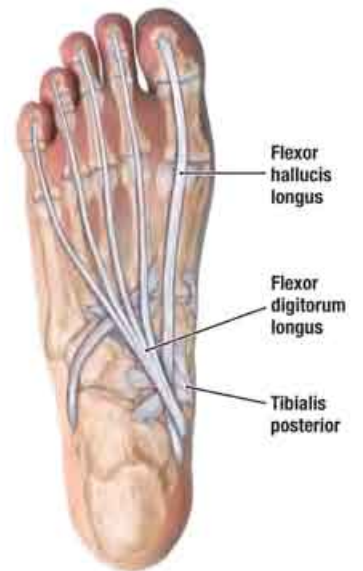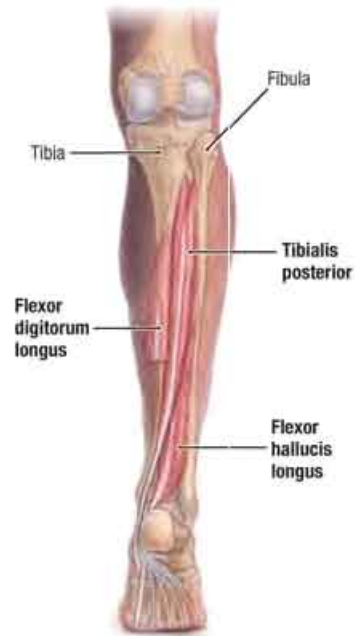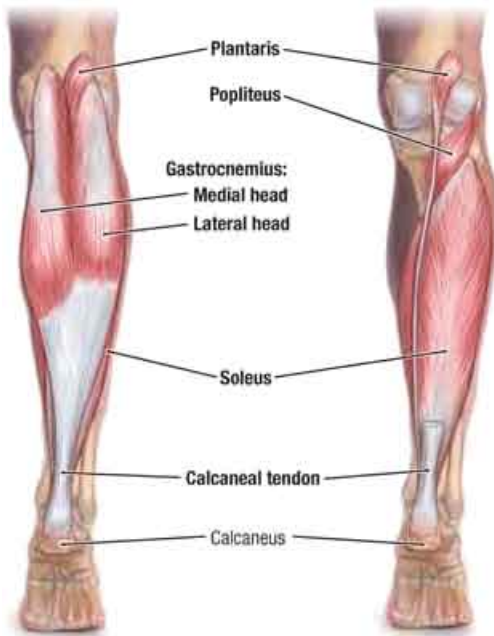Plantarflexes ankle and inverts foot

<sup>a</sup>See Table 5.1 for explanation of segmental innervation.

Muscle	Proximal Attachment	Distal Attachment	Innervation <sup>a</sup>	Main Actions
--------	---------------------	-------------------	--------------------------	--------------

<p>Table 5.13 Muscles of the Posterior Compartment of Leg</p>
---





Authors: Agur, Anne M.R.; Dalley, Arthur F.

Title: *Grant's Atlas of Anatomy, 12th Edition*

Copyright ©2009 Lippincott Williams & Wilkins

> Table of Contents > Chapter 5 - Lower Limb > 5.59 Bones of the posterior aspect of leg

---

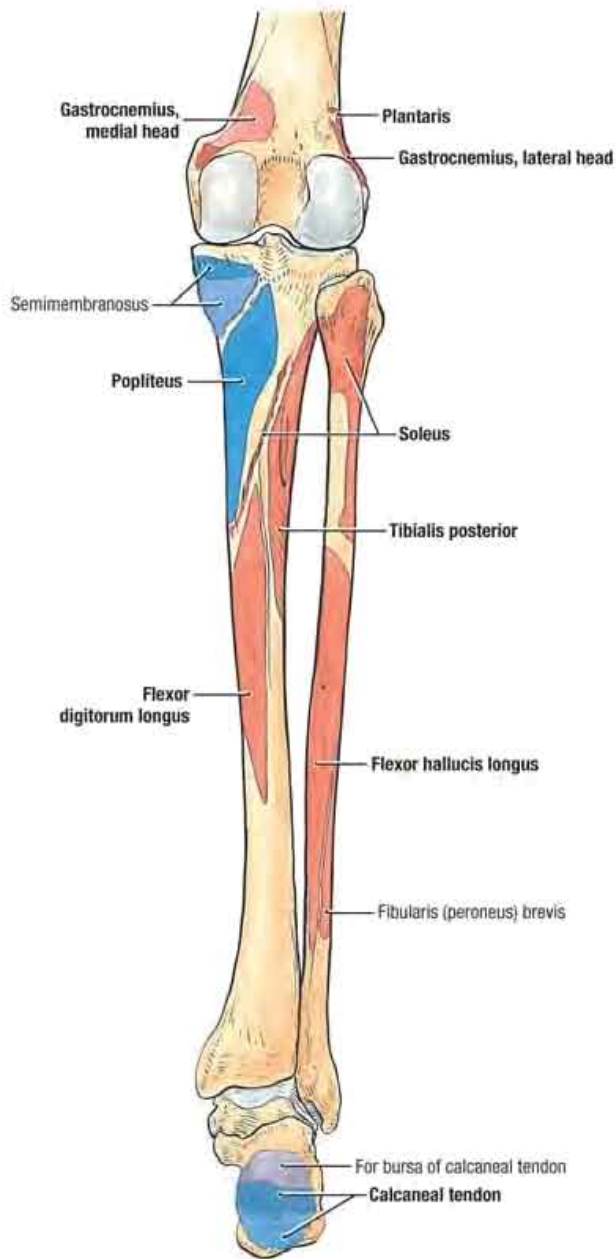
## 5.59 Bones of the posterior aspect of leg

*Part of* "Chapter 5 - Lower Limb "

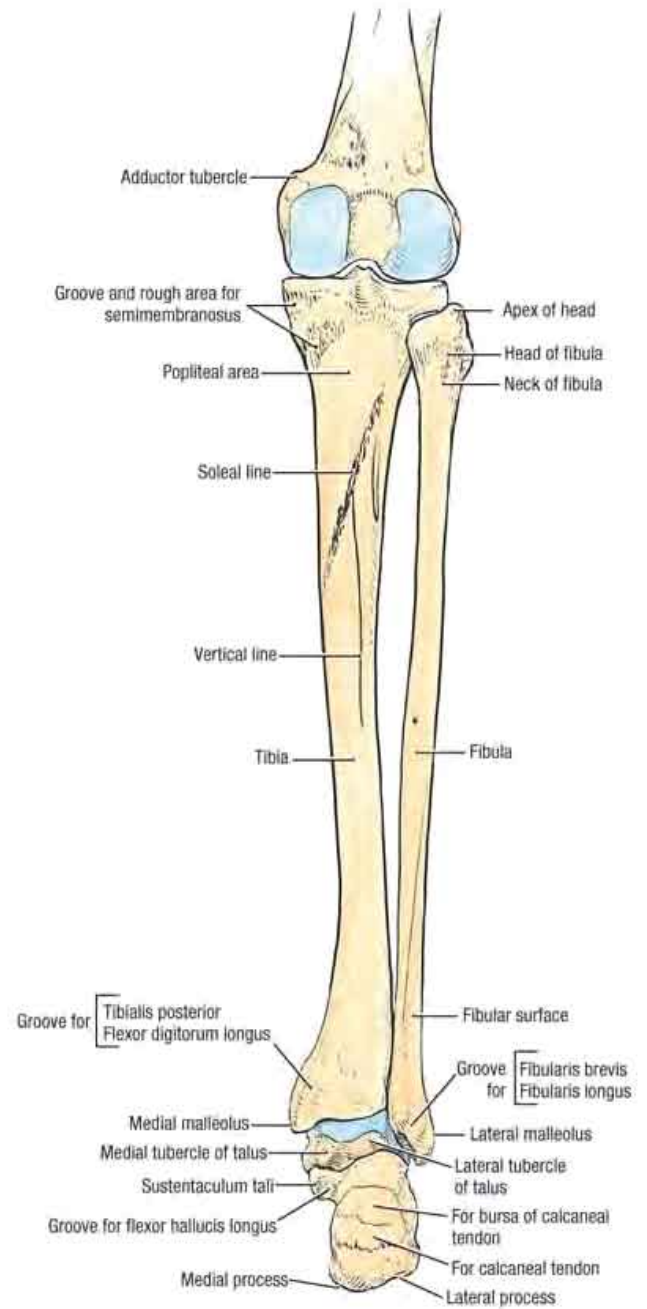
A. Muscle attachments. B. Features of bones.

The tibial shaft is narrowest at the junction of its middle and inferior thirds, which is the most frequent site of fracture. Unfortunately, this area of the bone also has the poorest blood supply.

Fibular fractures commonly occur 2–6 cm proximal to the distal end of the lateral malleolus and are often associated with fracture/dislocations of the ankle joint, which are combined with tibial fractures. When a person slips and the foot is forced into an excessively inverted position, the ankle ligaments tear, forcibly tilting the talus against the lateral malleolus and shearing it off.



A. Posterior View



B. Posterior View

Authors: Agur, Anne M.R.; Dalley, Arthur F.

Title: *Grant's Atlas of Anatomy, 12th Edition*

Copyright ©2009 Lippincott Williams & Wilkins

> Table of Contents > Chapter 5 - Lower Limb > 5.60 Posterior leg, superficial muscles of posterior compartment

---

## 5.60 Posterior leg, superficial muscles of posterior compartment

Part of "Chapter 5 - Lower Limb "

A. Surface anatomy (*numbers* refer to structures labeled in B ). B. Dissection.

Gastrocnemius strain (tennis leg) is a painful calf injury resulting from partial tearing of the medial belly of the muscle at or near its musculotendinous junction. It is caused by overstretching the muscle during simultaneous full extension of the knee and dorsiflexion of the ankle.

---

P.435

C. Dissection revealing soleus. D. Bones of leg showing muscle attachments.

Inflammation of the calcaneal tendon due to microscopic tears of collagen fibers in the tendon, particularly just superior to its attachment to the calcaneus, results in tendinitis, which causes pain during walking. Calcaneal tendon rupture is probably the most severe acute muscular problem of the leg. Following complete rupture of the tendon, passive dorsiflexion is excessive, and the person cannot plantarflex against resistance.

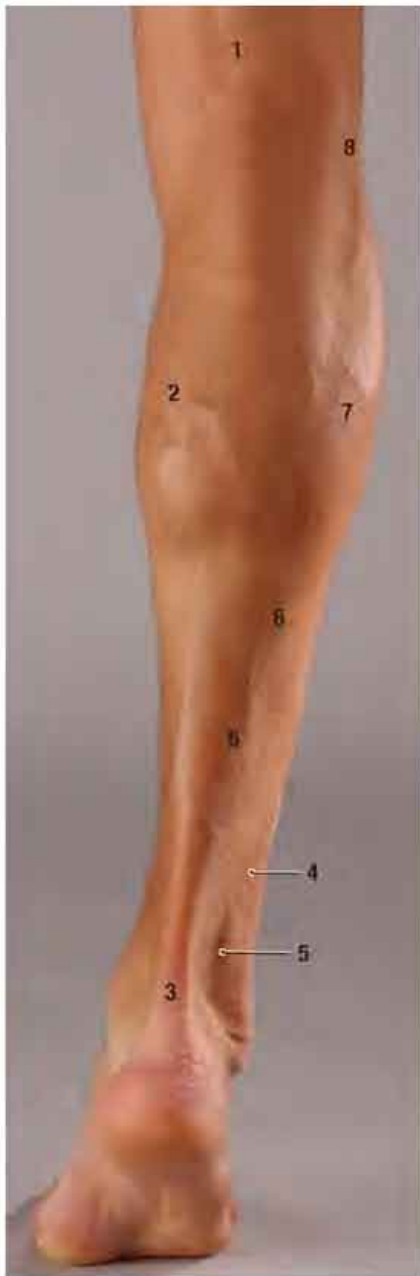---

P.436

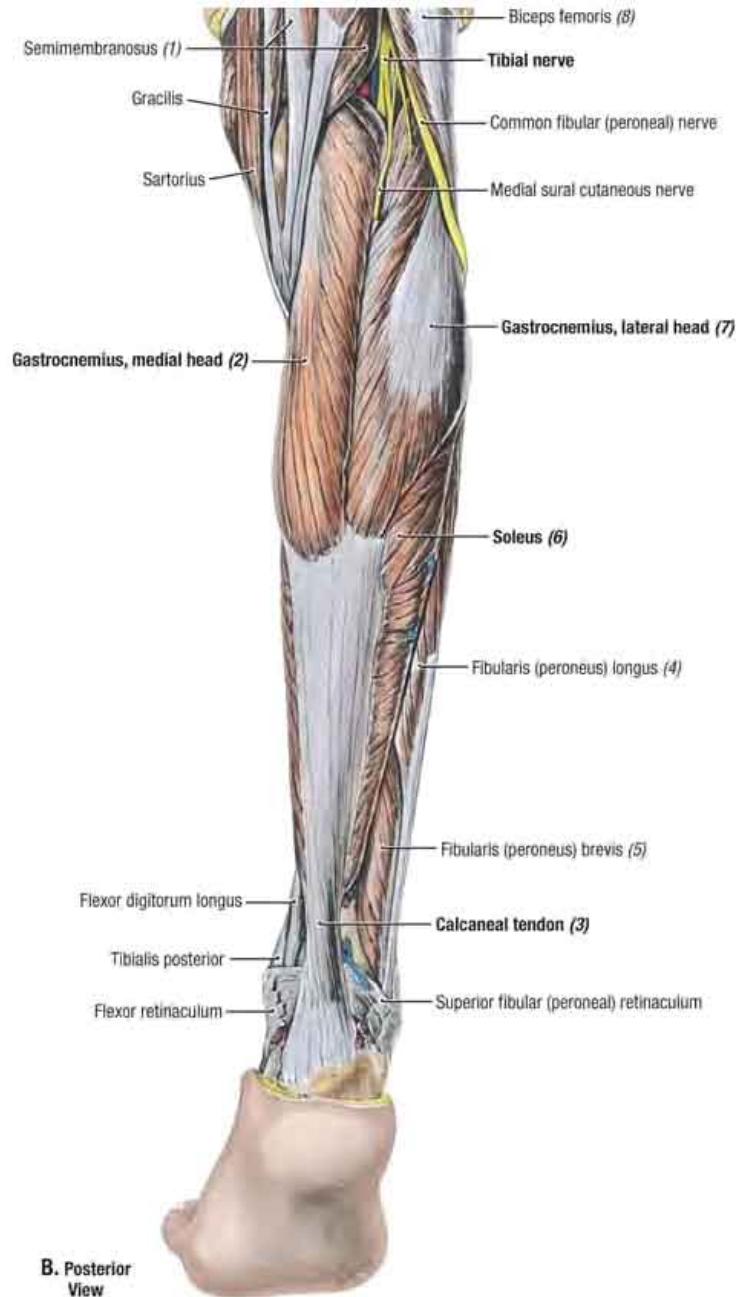


Semitendinosus

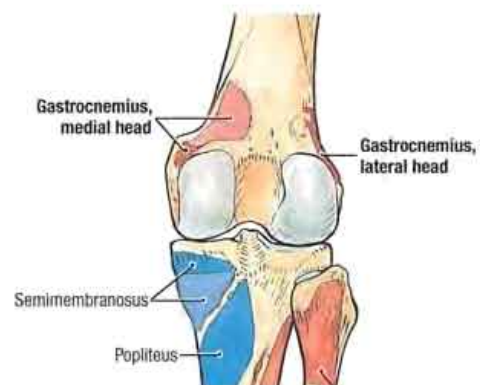
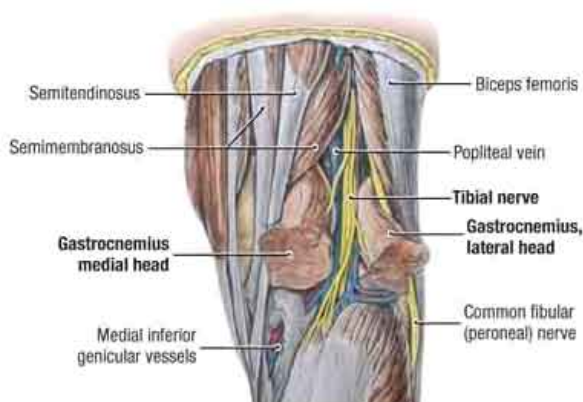




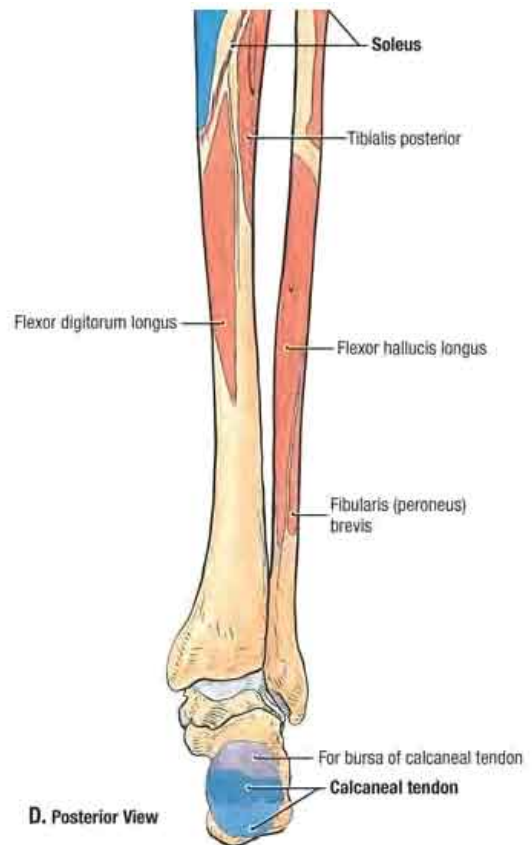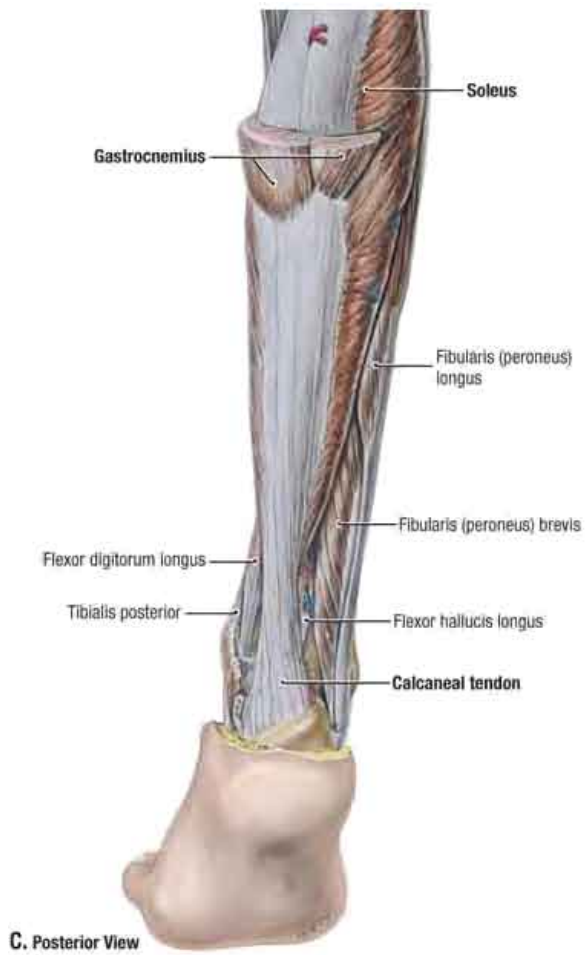
**A. Posterior View**



**B. Posterior View**







## 5.61 Posterior leg, deep muscles of posterior compartment

*Part of* "Chapter 5 - Lower Limb "

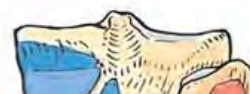A. Superficial dissection. The calcaneal tendon (Achilles tendon) is cut, the gastrocnemius muscle is removed, and only a horseshoe-shaped proximal part of the soleus muscle remains in place. B. Bones of leg showing muscle attachments.

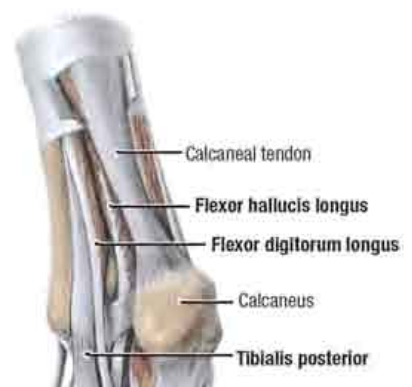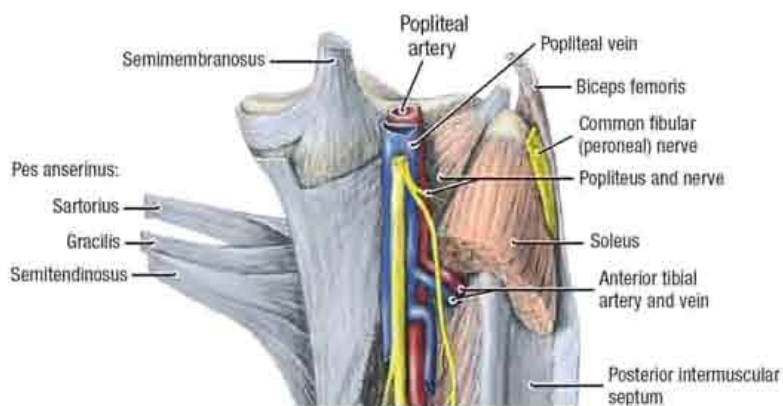
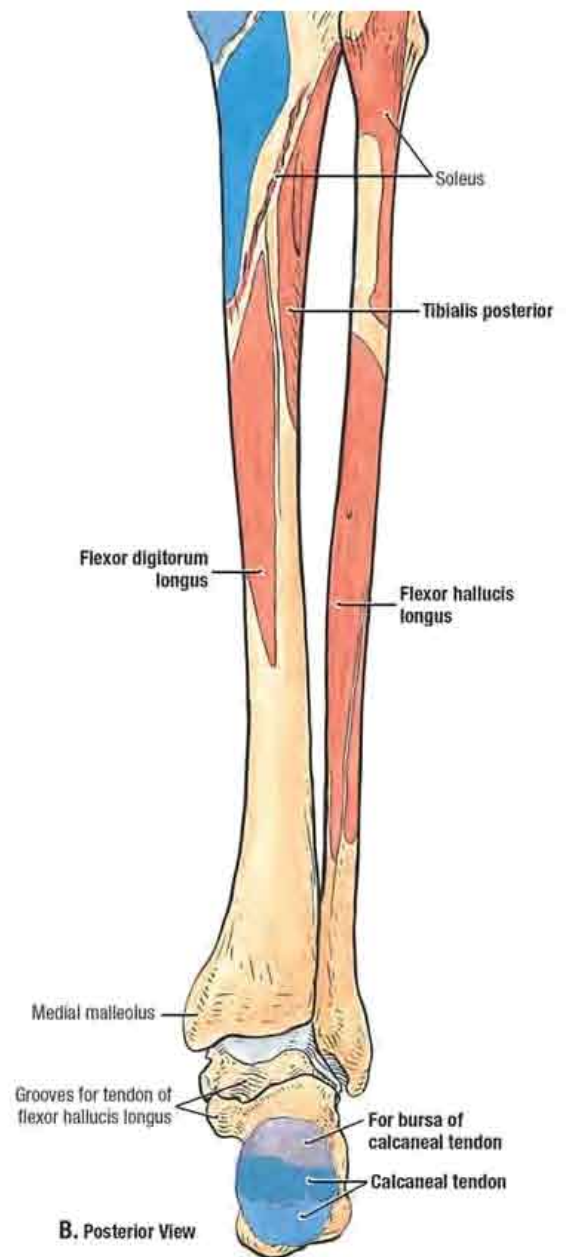
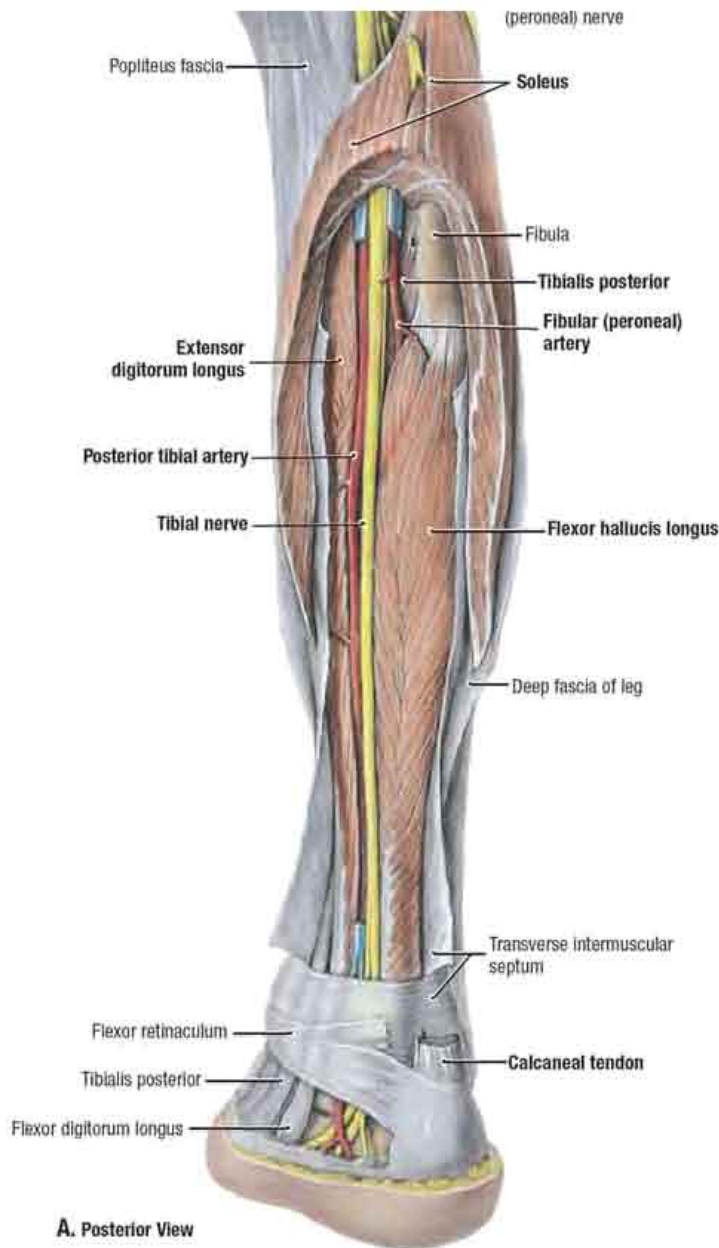
Calcaneal bursitis results from inflammation of the bursa of the calcaneal tendon located between the calcaneal tendon and the superior part of the posterior surface of the calcaneus. Calcaneal bursitis causes pain posterior to the heel and occurs commonly during long-distance running, basketball, and tennis. It is caused by excessive friction on the bursa as the calcaneal tendon continuously slides over it.

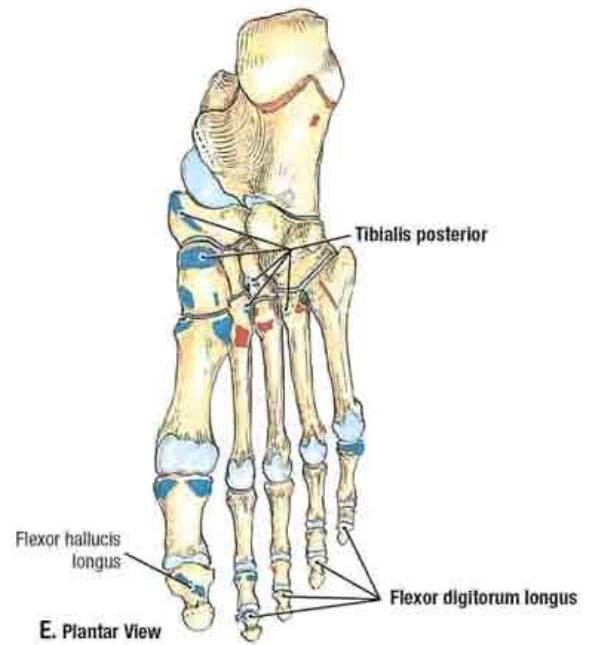
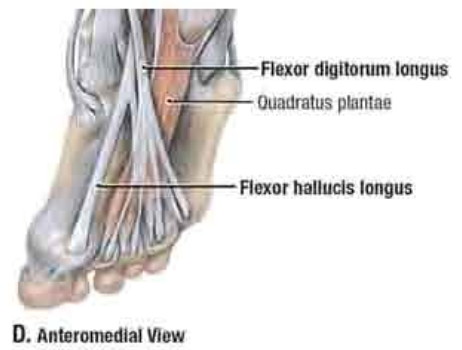
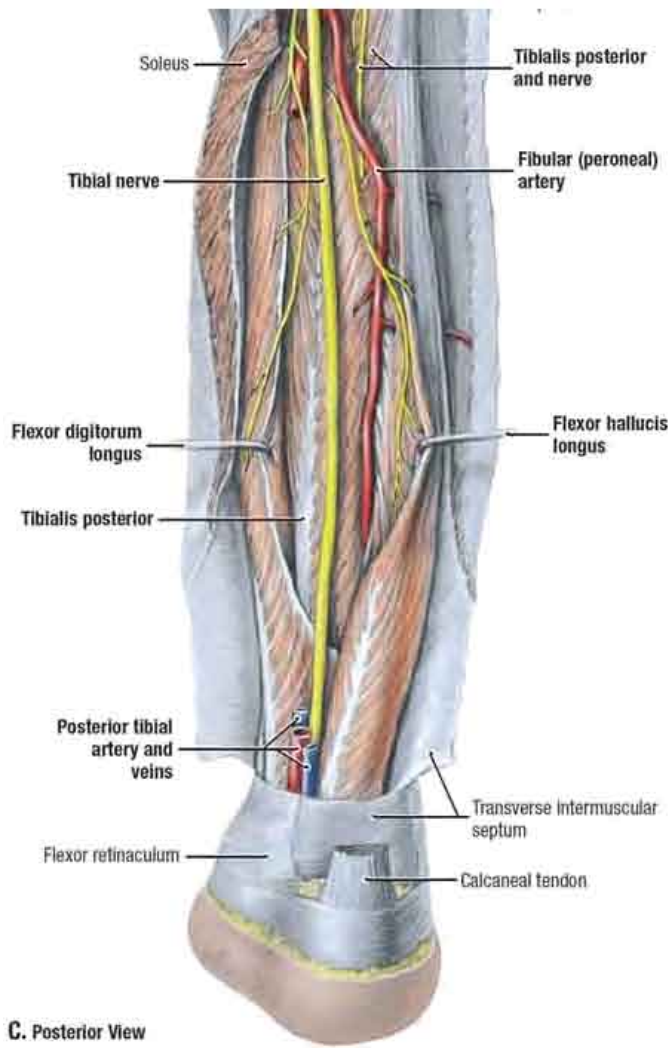
P.437

C. Deeper dissection. The flexor hallucis longus and flexor digitorum longus are pulled apart, and the posterior tibial artery is partly excised. The tibialis posterior lies deep to the two long digital flexors. D. Crossing of muscles (tendons) of the deep compartment superoposterior to the medial malleolus and into the sole of the foot. E. Bones of foot showing muscle attachments.

P.438







Authors: Agur, Anne M.R.; Dalley, Arthur F.

Title: *Grant's Atlas of Anatomy, 12th Edition*

Copyright ©2009 Lippincott Williams & Wilkins

> Table of Contents > Chapter 5 - Lower Limb > 5.62 Medial ankle region

---

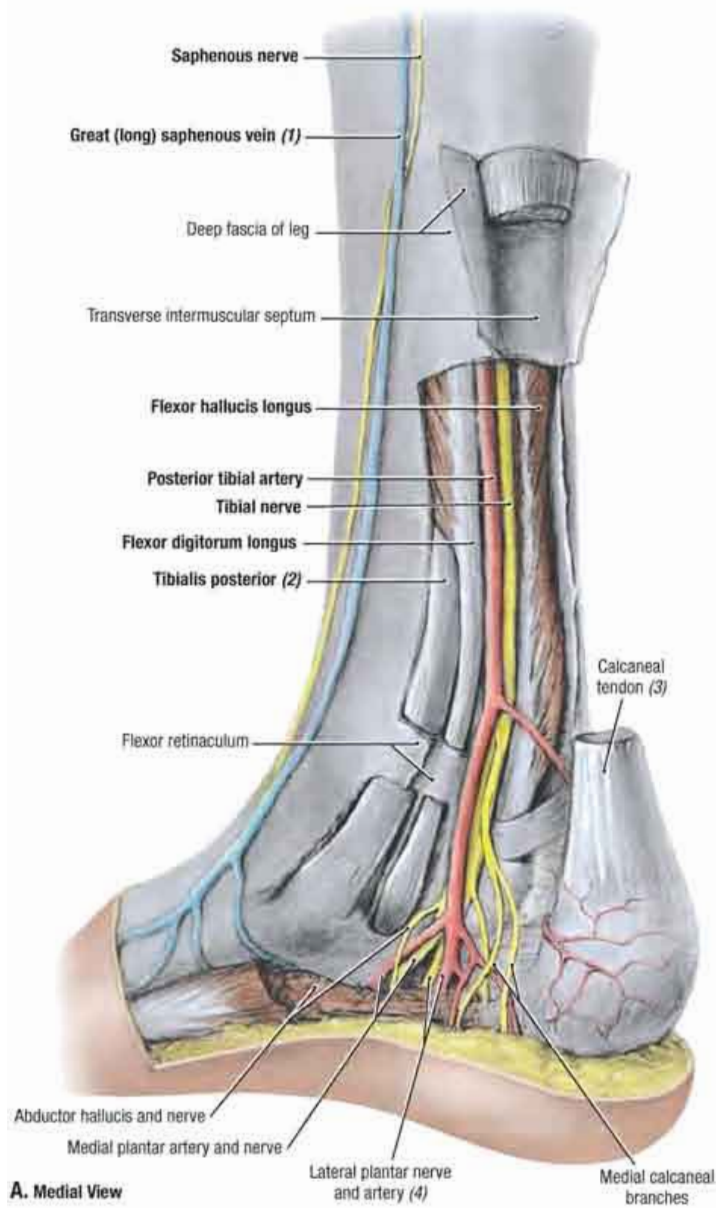
## 5.62 Medial ankle region

*Part of* "Chapter 5 - Lower Limb "

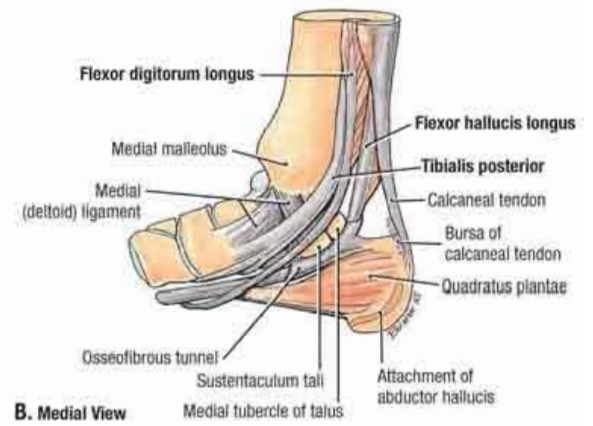
A. Dissection. The calcaneal tendon and posterior part of the abductor hallucis were excised. B. Schematic illustration of the tendons passing posterior to medial malleolus. C. Surface anatomy (*numbers* refer to structures labeled in A ).

- The posterior tibial artery and the tibial nerve lie between the flexor digitorum longus and flexor hallucis longus muscles and divide into medial and lateral plantar branches.
  - The tibialis posterior and flexor digitorum longus tendons occupy separate osseofibrous tunnels posterior to the medial malleolus.
- The posterior tibial pulse can usually be palpated between the posterior surface of the medial malleolus and the medial border of the calcaneal tendon.

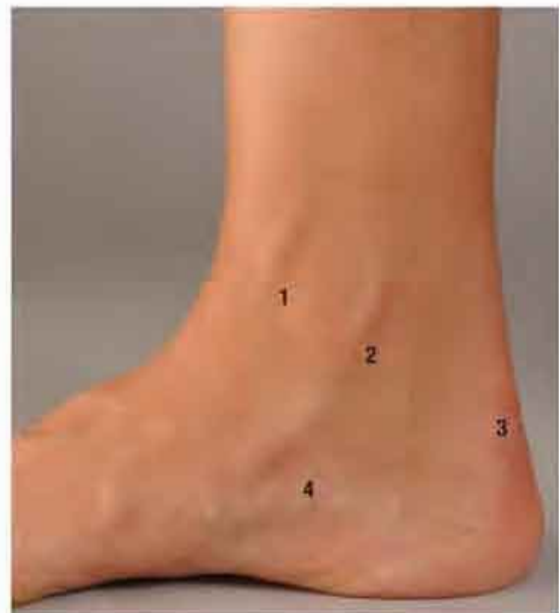



**A. Medial View**



**B. Medial View**



**C. Medial View**

Authors: Agur, Anne M.R.; Dalley, Arthur F.

Title: *Grant's Atlas of Anatomy, 12th Edition*

Copyright ©2009 Lippincott Williams & Wilkins

> Table of Contents > Chapter 5 - Lower Limb > 5.63 Medial ankle and foot

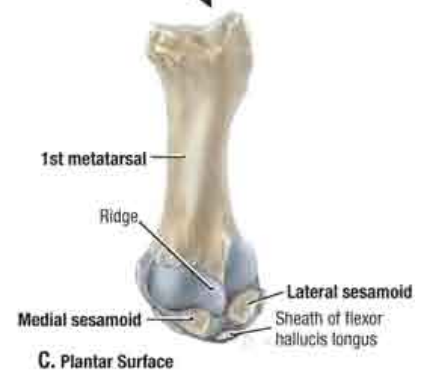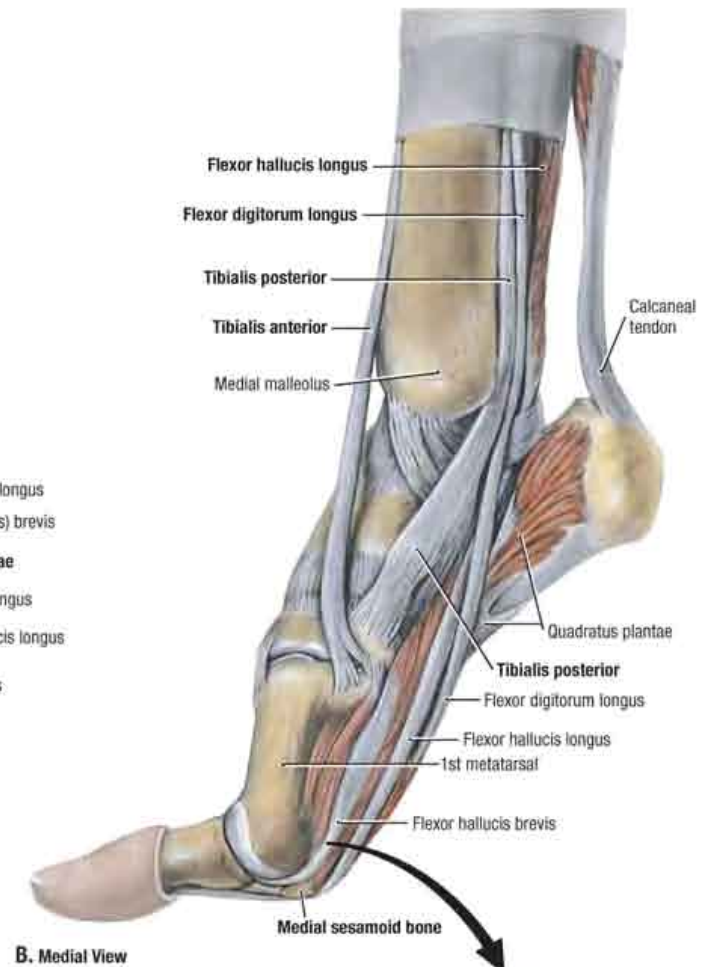
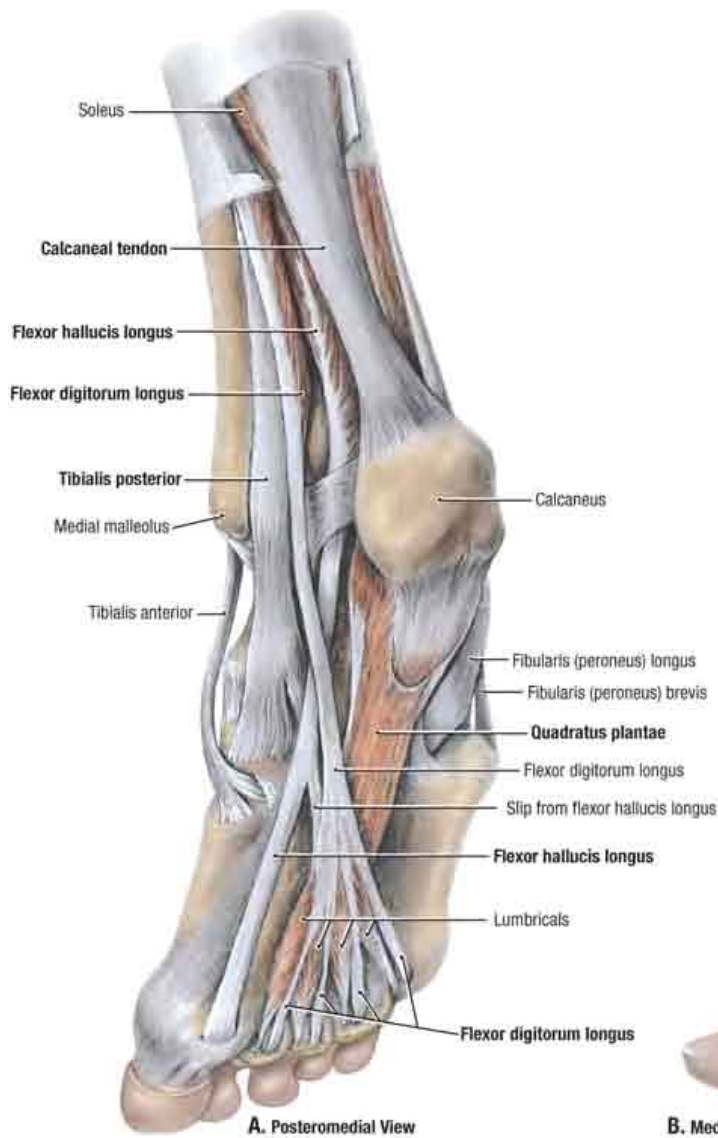
---

## 5.63 Medial ankle and foot

*Part of* "Chapter 5 - Lower Limb "

A. Tendons of deep compartment of the leg traced to their distal attachments in the sole of the foot. B. Foot raised as in walking and sesamoid bones of the great toe. The sesamoid bones of the great toe are located on each side of a bony ridge on the 1st metatarsal.

- The sesamoid bones are a "footstool" for the first metatarsal, giving it increased height.
- By inserting into the flexor digitorum longus muscle, the quadratus plantae muscle modifies the oblique pull of the flexor tendons.
- The flexor hallucis longus muscle uses three pulleys: a groove on the posterior aspect of the distal end of the tibia, a groove on the posterior aspect of the talus, and a groove inferior to the sustentaculum tali.
- The flexor digitorum longus muscle crosses superficial to the tibialis posterior, superoposterior to the medial malleolus.



Authors: Agur, Anne M.R.; Dalley, Arthur F.

Title: *Grant's Atlas of Anatomy, 12th Edition*

Copyright ©2009 Lippincott Williams & Wilkins

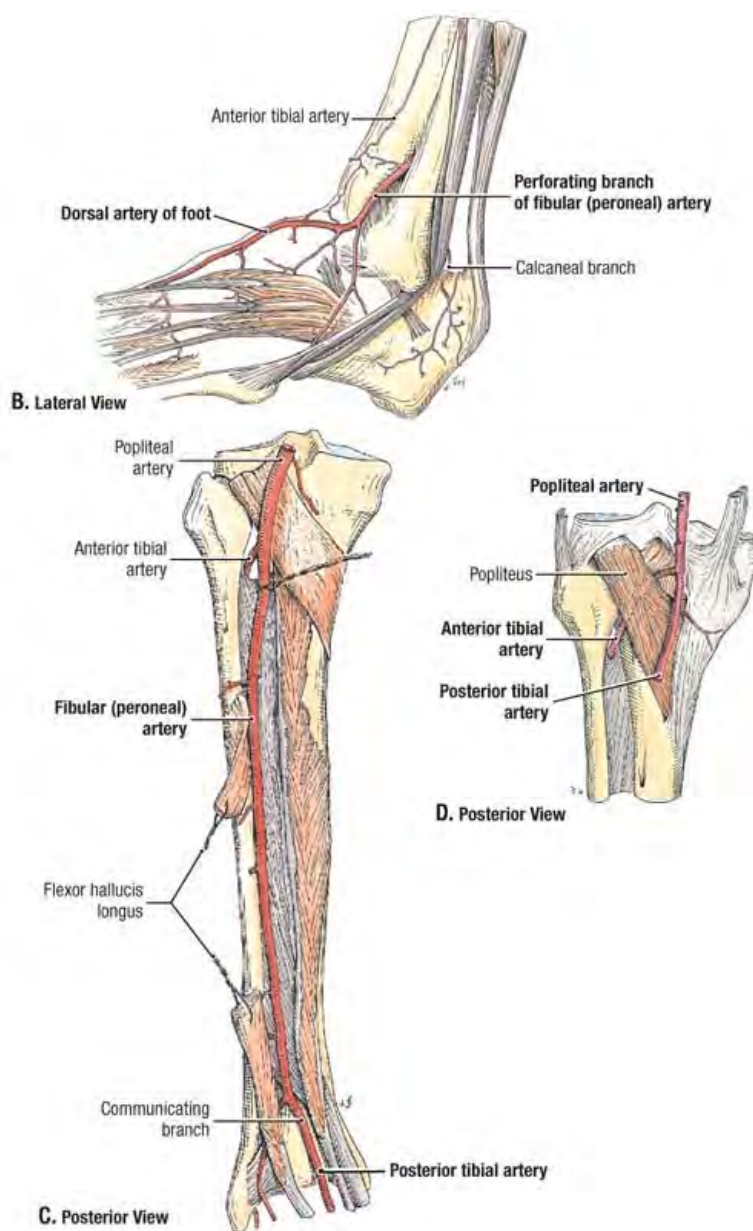
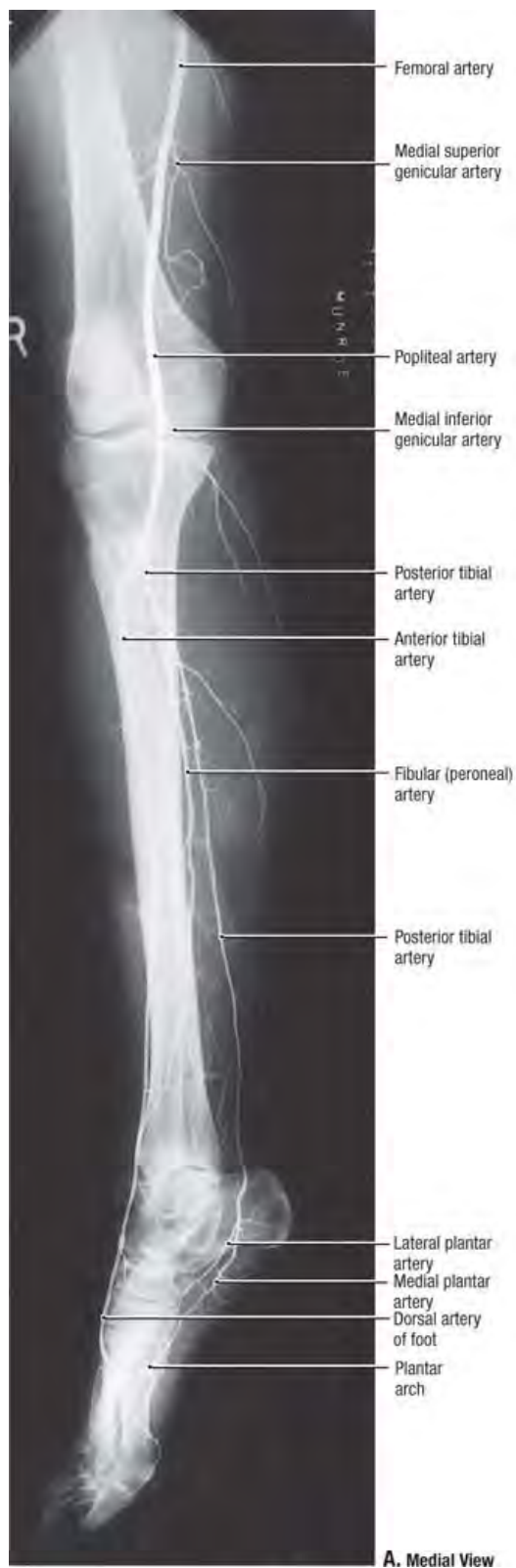
> Table of Contents > Chapter 5 - Lower Limb > 5.64 Popliteal arteriogram and arterial anomalies

---

## 5.64 Popliteal arteriogram and arterial anomalies

*Part of* "Chapter 5 - Lower Limb "

A. Popliteal arteriogram. The femoral artery becomes the popliteal artery at the adductor hiatus. The anterior tibial artery continues as the dorsalis pedis (dorsal artery of the foot). The posterior tibial artery terminates as the medial and lateral plantar arteries; its major branch is the fibular artery. B. Anomalous dorsal artery of the foot. The perforating branch of the fibular artery rarely continues as the dorsal artery of the foot, but when it does, the anterior tibial artery ends proximal to the ankle or is a slender vessel. C. Absence of posterior tibial artery. Compensatory enlargement of the fibular artery was found to occur in approximately 5% of limbs. D. High division of popliteal artery. Along with the anterior tibial artery descending anterior to the popliteus muscle; this anomaly was found to occur in approximately 2% of limbs.



Popliteal



Continuation of femoral artery at adductor hiatus

Passes through popliteal fossa to leg; divides into anterior and posterior tibial arteries at lower border of popliteus

Lateral and medial aspects of knee via genicular arteries

Anterior tibial

Popliteal

Passes between tibia and fibula into anterior compartment through gap superior to interosseous membrane; descends between tibialis anterior and extensor digitorum longus muscles

Anterior compartment

Dorsal artery of foot (dorsalis pedis)

Continuation of anterior tibial artery distal to talocrural joint

Descends to first interosseous space; divides into plantar and arcuate arteries

Muscles on dorsum of foot; pierces first dorsal interosseous muscle as deep plantar artery; joins deep plantar arch

Posterior tibial

Popliteal

Passes through posterior compartment; divides into medial and lateral plantar arteries posterior to medial malleolus

Posterior and lateral compartments, nutrient artery passes to tibia

Fibular (peroneal)

Posterior tibial

Descends in posterior compartment adjacent to posterior intermuscular septum

Posterior compartment: perforating branches supply lateral compartment

Medial plantar

In foot between abductor hallucis and flexor digitorum brevis muscles

Supplies mainly muscles of great toe and skin on medial side of sole of foot

Lateral plantar

Posterior tibial

Runs anterolaterally deep to abductor hallucis and flexor digitorum brevis, then arches medially to form deep plantar arch

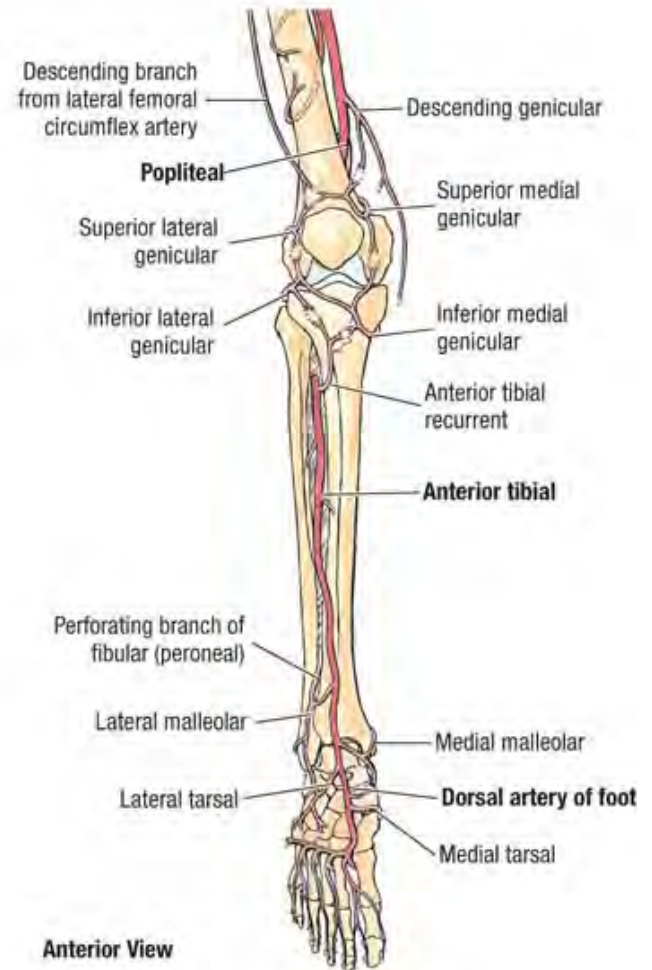
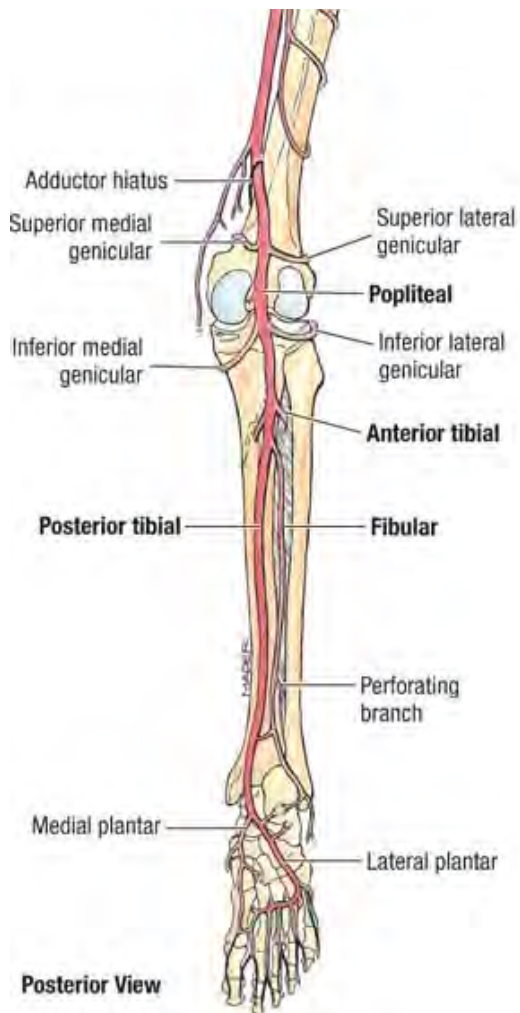
Supplies remainder (lateral aspect) of sole of foot

Artery	Origin	Course	Distribution in Leg
--------	--------	--------	---------------------

---

Table 5.14 Arterial Supply of Leg and Foot

P.442



Authors: Agur, Anne M.R.; Dalley, Arthur F.

Title: *Grant's Atlas of Anatomy, 12th Edition*

Copyright ©2009 Lippincott Williams & Wilkins

> Table of Contents > Chapter 5 - Lower Limb > 5.65 Superior tibiofibular joint and tibiofibular syndesmosis

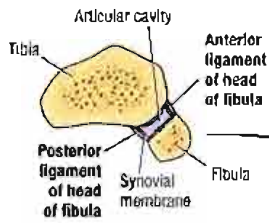
---

## 5.65 Superior tibiofibular joint and tibiofibular syndesmosis

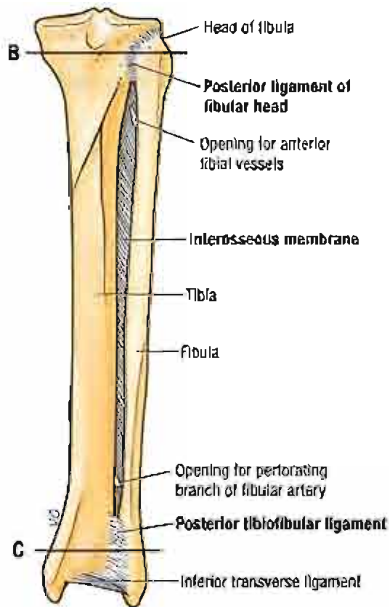
*Part of* "Chapter 5 - Lower Limb "

A. Tibiofibular joints. B. Superior tibiofibular joint. C. Tibiofibular syndesmosis. D. Tibia and fibula, disarticulated.

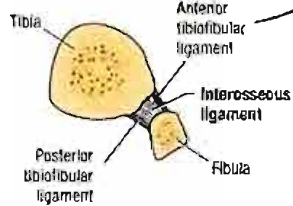
- The superior tibiofibular joint (proximal tibiofibular joint) is a plane type of synovial joint between the flat facet on the fibular head and a similar facet located posterolaterally on the lateral tibial condyle. The tense joint capsule surrounds the joint and attaches to the margins of the articular surfaces of the fibula and tibia.
- The tibiofibular syndesmosis is a compound fibrous joint. This articulation is essential for stability of the ankle joint because it keeps the lateral malleolus firmly against the lateral surface of the talus. The strong interosseous tibiofibular ligament is continuous superiorly with the interosseous membrane and forms the principal connection between the distal ends of the tibia and fibula.



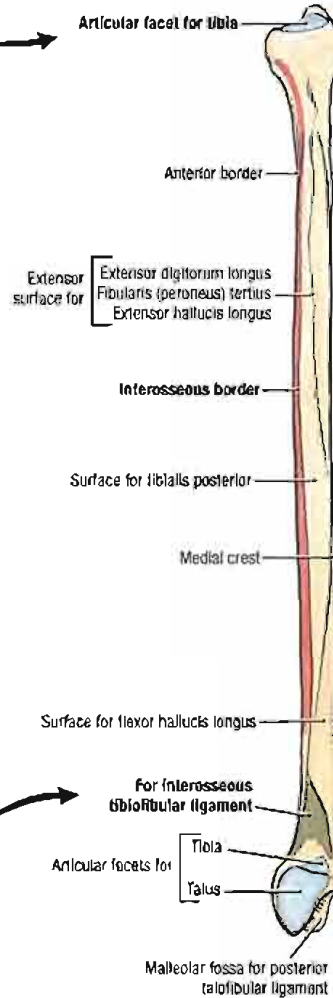
**B. Transverse Section**



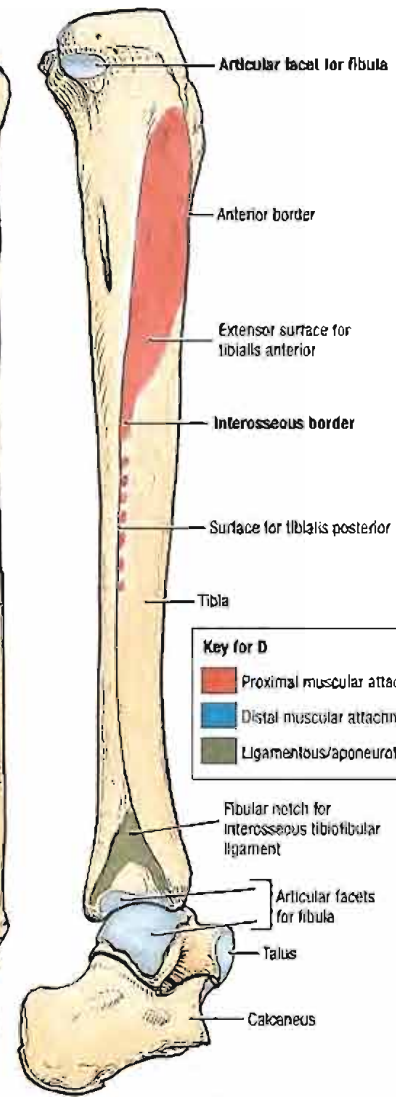
**A. Posterior View**



**C. Transverse Section**



**D. Fibula, Medial View**



**Lateral View**

Key for D	
<span style="display:inline-block; width:15px; height:15px; background-color:red; border:1px solid black;"></span>	Proximal muscular attachment
<span style="display:inline-block; width:15px; height:15px; background-color:blue; border:1px solid black;"></span>	Distal muscular attachment
<span style="display:inline-block; width:15px; height:15px; background-color:gray; border:1px solid black;"></span>	Ligamentous/aponeurotic attachment

Authors: Agur, Anne M.R.; Dalley, Arthur F.

Title: *Grant's Atlas of Anatomy, 12th Edition*

Copyright ©2009 Lippincott Williams & Wilkins

> Table of Contents > Chapter 5 - Lower Limb > 5.66 Sole of foot, superficial

---

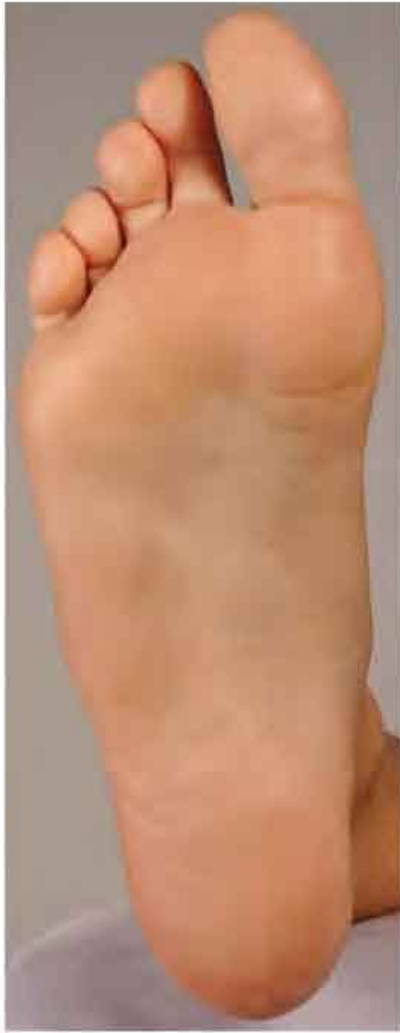## 5.66 Sole of foot, superficial

*Part of* "Chapter 5 - Lower Limb "

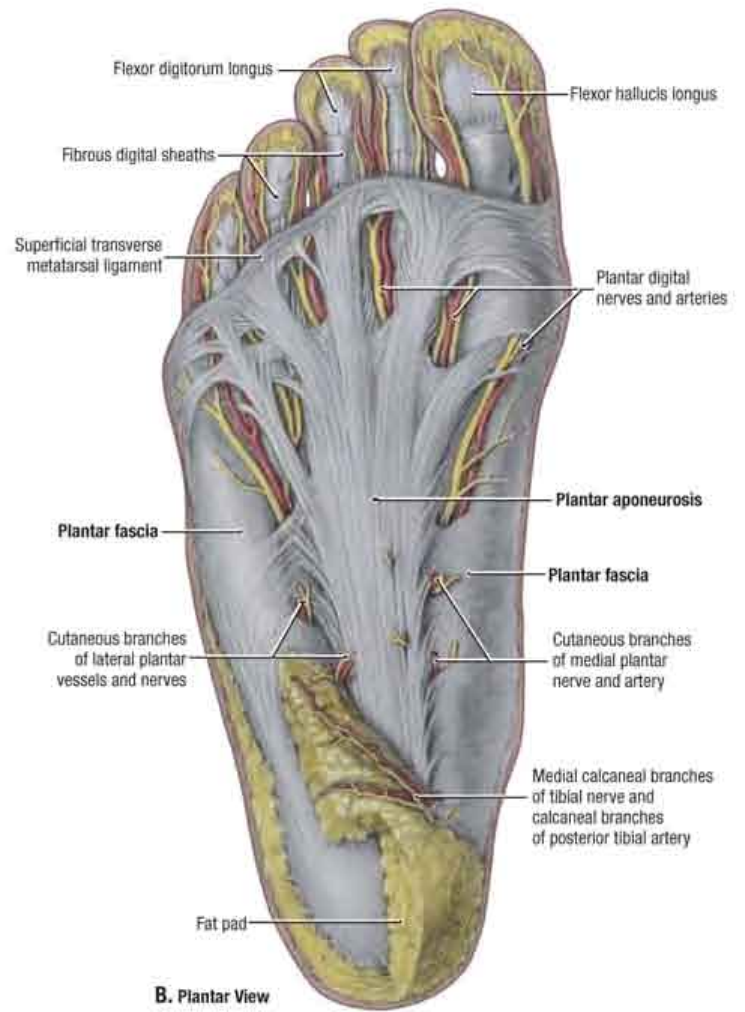
A. Surface anatomy. B. Dissection. Plantar aponeurosis and fascia, with neurovascular structures. C. Weight-bearing areas.

- The weight of the body is transmitted to the talus from the tibia and fibula. It is then transmitted to the tuberosity of the calcaneus, the heads of the second to fifth metatarsals, and the sesamoid bones of the first digit.
- Straining and inflammation of the plantar aponeurosis, a condition called plantar fasciitis, may result from running and high-impact aerobics, especially when inappropriate footwear is worn. It causes pain on the plantar surface of the heel and on the medial aspect of the foot. Point tenderness is located at the proximal attachment of the plantar aponeurosis to the medial tubercle of the calcaneus and on the medial surface of this bone. The pain increases with passive extension of the great toe and may be further exacerbated by dorsiflexion of the ankle and/or weight bearing.

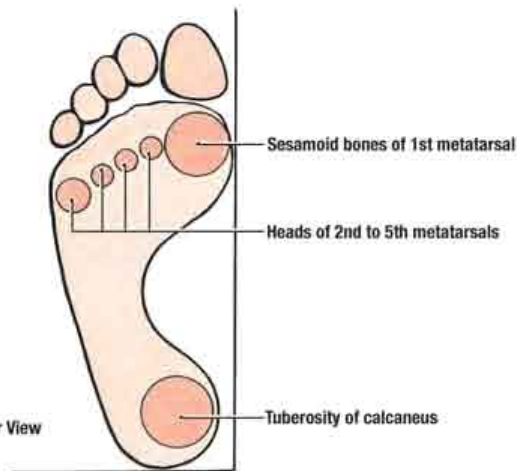




A. Plantar View



B. Plantar View



C. Plantar View

## 5.67 First layer of muscles of sole of foot

*Part of* "Chapter 5 - Lower Limb "

A. Bones. B. Dissection. Muscles and neurovascular structures.

Abductor hallucis

Medial process of tuberosity of calcaneus, flexor retinaculum, and plantar aponeurosis

Medial side of base of proximal phalanx of first digit

Medial plantar nerve (S2–S3)

Abducts and flexes

Flexor digitorum brevis

Medial process of tuberosity of calcaneus, plantar aponeurosis, and intermuscular septa

Both sides of middle phalanges of lateral four digits

Flexes lateral four digits

Abductor digiti minimi

Medial and lateral processes of tuberosity of calcaneus, plantar aponeurosis, and intermuscular septa

Lateral side of base of proximal phalanx of fifth digit

Lateral plantar nerve (S2–S3)

Abducts and flexes fifth digit

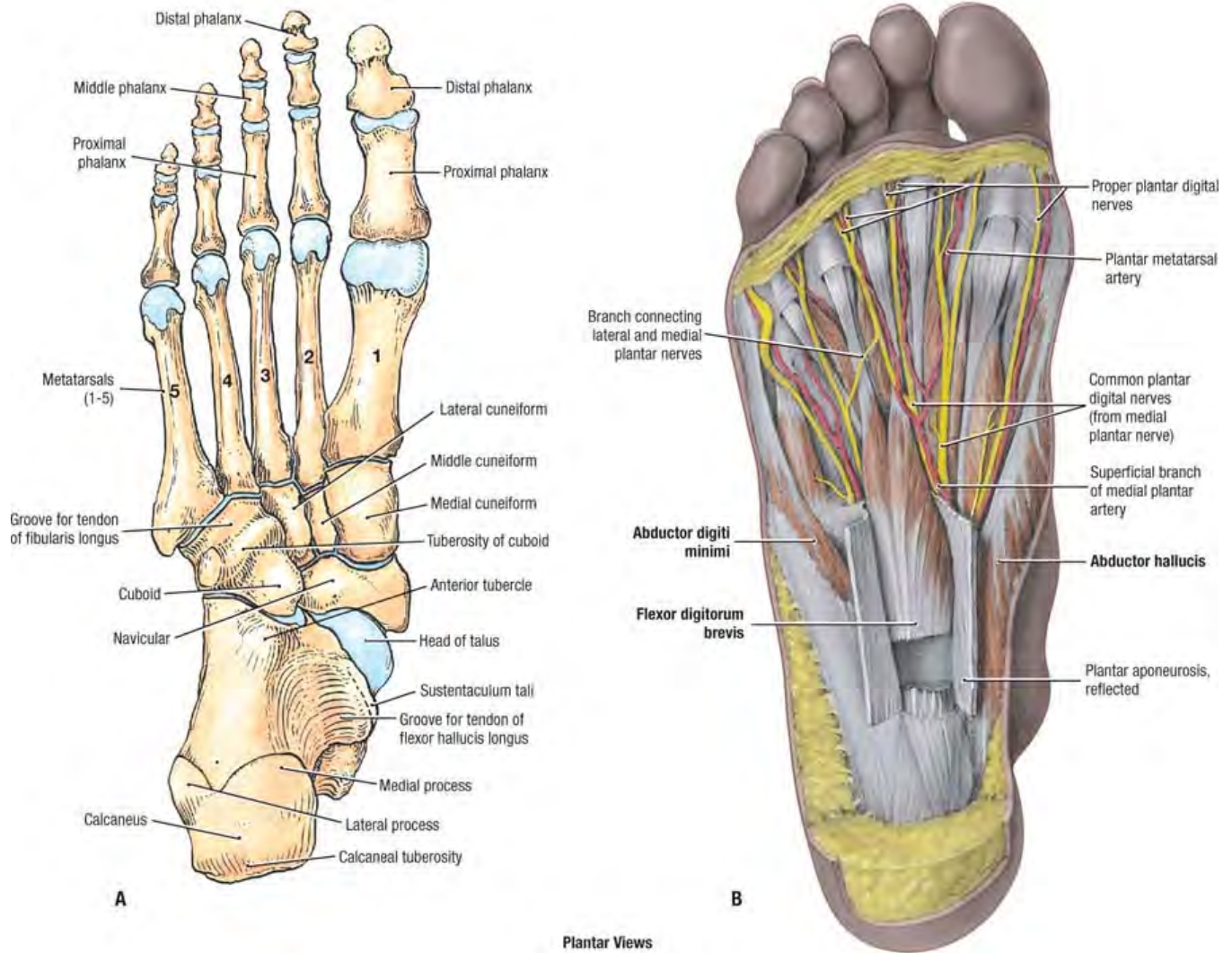
<sup>a</sup>Although individual actions are described, the primary function of the intrinsic muscles of the foot is to act collectively to resist forces that stress (attempt to flatten) the arches of the foot.

	Proximal Attachment	Distal Attachment		
Muscle	(red)	(blue)	Innervation	Actions <sup>a</sup>

---

Table 5.15 Muscles in Sole of Foot – First Layer

P.445



## 5.68 Second layer of muscles of sole of foot

Part of "Chapter 5 - Lower Limb "

A. Bony attachments. B. Dissection. Muscles.

Quadratus plantae

Medial surface and lateral margin of plantar surface of calcaneus

Posterolateral margin of tendon of flexor digitorum longus

Lateral plantar nerve (S2–S3 )

Assists flexor digitorum longus in flexing lateral four digits

Lumbricals

Tendons of flexor digitorum longus

Medial aspect of extensor expansion over lateral four digits

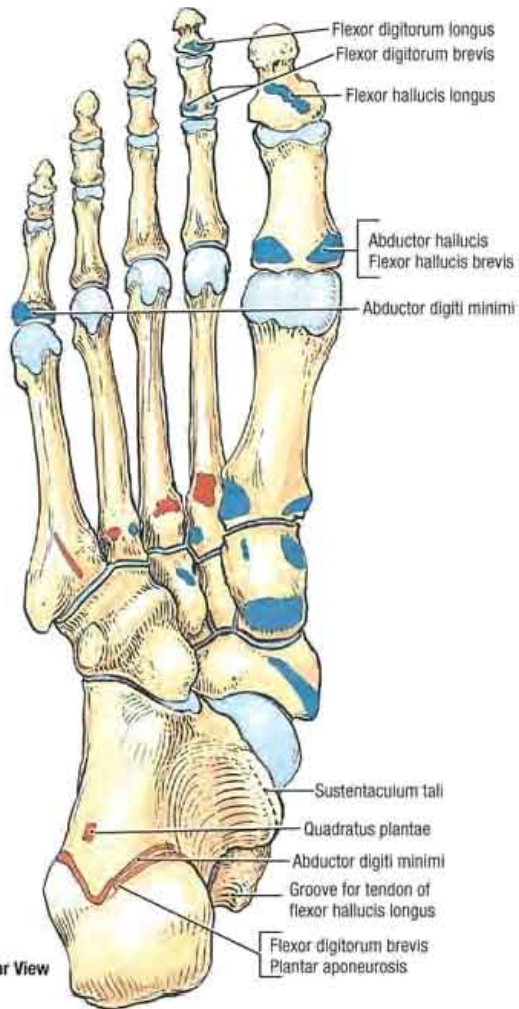
*Medial one:* medial plantar nerve (S2–S3 );

*Lateral three:* lateral plantar nerve (S2–S3 )

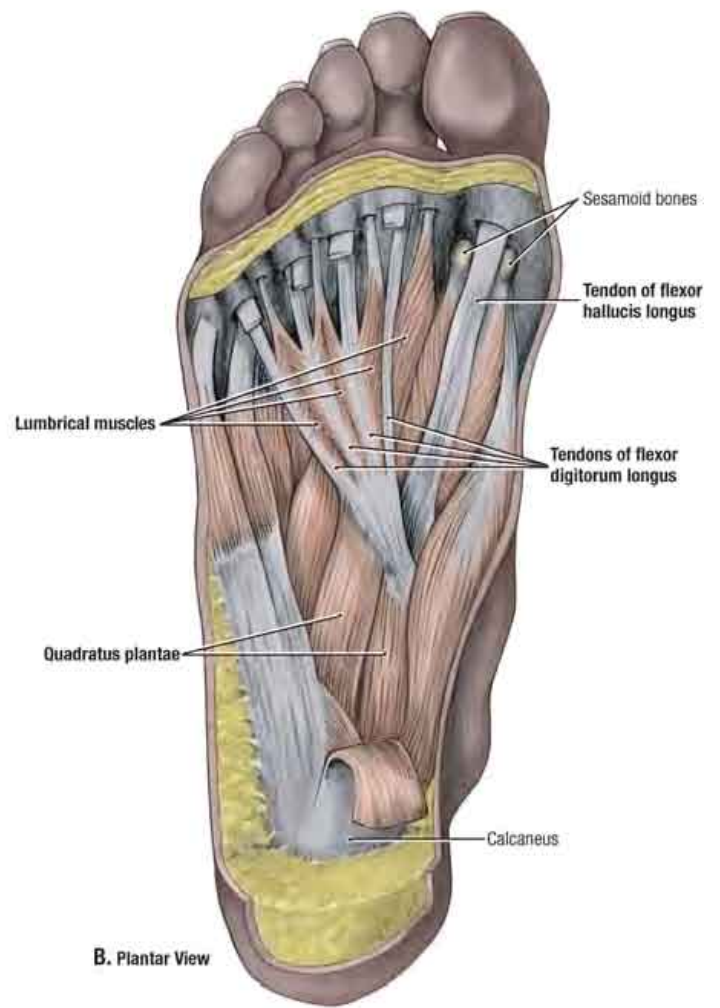
Flex proximal phalanges and extend middle and distal phalanges of lateral four digits

<sup>a</sup>Although individual actions are described, the primary function of the intrinsic muscles of the foot is to act collectively to resist forces that stress (attempt to flatten) the arches of the foot.

Muscle	Proximal Attachment (red)	Distal Attachment (blue)	Innervation	Actions <sup>a</sup>
Table 5.16 Muscles in Sole of Foot—Second Layer				



**A. Plantar View**



**B. Plantar View**



Authors: Agur, Anne M.R.; Dalley, Arthur F.

Title: *Grant's Atlas of Anatomy, 12th Edition*

Copyright ©2009 Lippincott Williams & Wilkins

> Table of Contents > Chapter 5 - Lower Limb > 5.69 Third layer of muscles and arterial supply of sole of foot

---

## 5.69 Third layer of muscles and arterial supply of sole of foot

*Part of* "Chapter 5 - Lower Limb "

A. Arterial supply. B. Dissection. Muscles and neurovascular structures.

Flexor hallucis brevis

Plantar surfaces of cuboid and lateral cuneiforms

Both sides of base of proximal phalanx of first digit

Medial plantar nerve (S2–S3 )

Flexes proximal phalanx of first digit

Adductor hallucis

*Oblique head:* bases of metatarsals 2–4;

*Transverse head:* plantar ligaments of metatarsophalangeal joints

Tendons of both heads attach to lateral side of base of proximal phalanx of first digit

Deep branch of lateral plantar nerve (S2–S3 )

Adducts first digit; assists in maintaining transverse arch of foot

Flexor digiti minimi

Base of fifth metatarsal

Base of proximal phalanx of fifth digit

Superficial branch of lateral plantar nerve (S2–S3 )

Flexes proximal phalanx of fifth digit, thereby assisting with its flexion

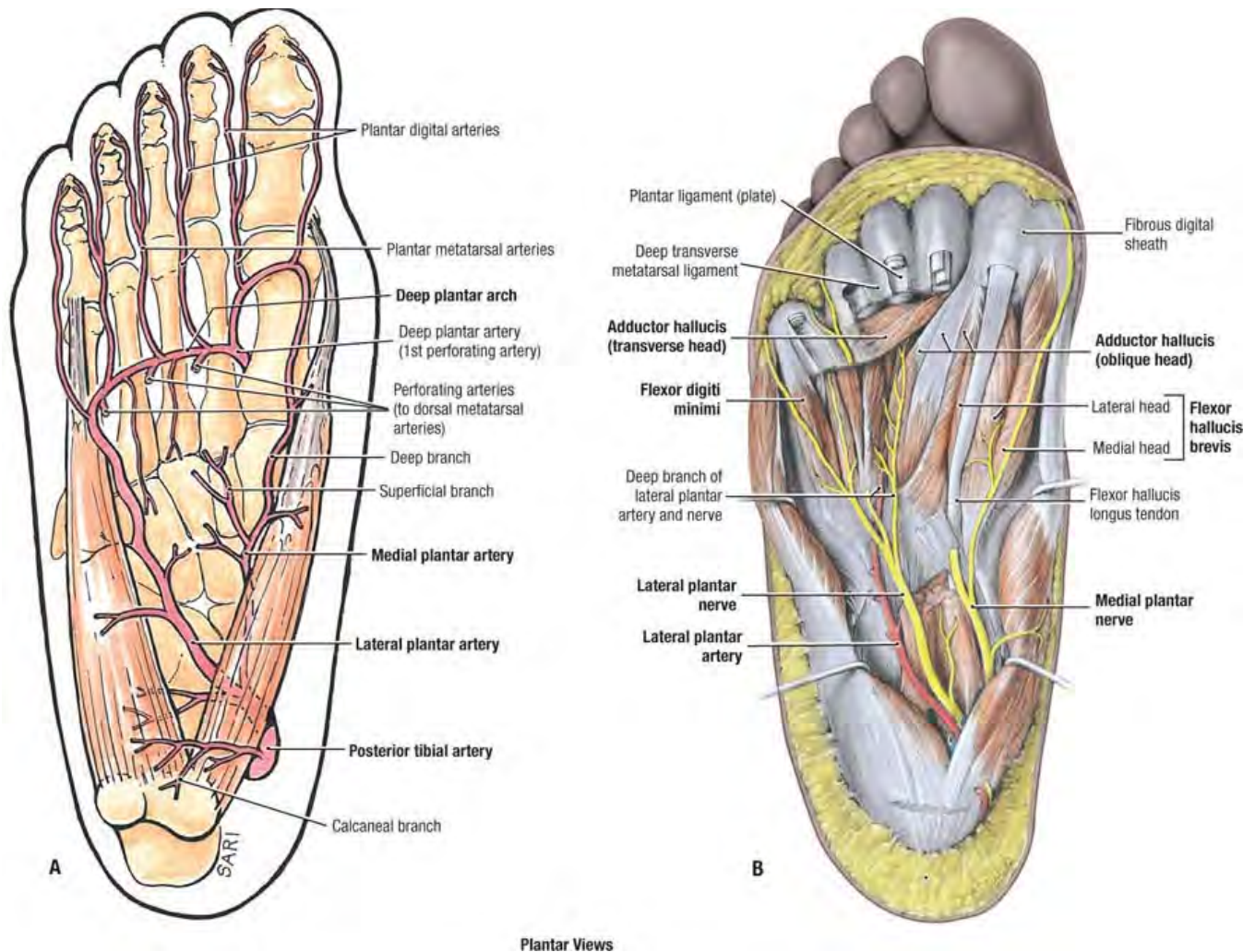
<sup>a</sup>Although individual actions are described, the primary function of the intrinsic muscles of the foot is to act collectively to resist forces that stress (attempt to flatten) the arches

of the foot.

Muscle	Proximal Attachment (red)	Distal Attachment (blue)	Innervation	Actions <sup>a</sup>
--------	------------------------------	-----------------------------	-------------	----------------------

Table 5.17 Muscles in Sole of Foot – Third Layer

P.447



## 5.70 Fourth layer of muscles of sole of foot

Part of "Chapter 5 - Lower Limb "

A. Bony attachments. B. Dissection. Muscles and ligaments.

Plantar interossei (three muscles; P1–P3)

Bases and medial sides of metatarsals 3–5

Medial sides of bases of proximal phalanges of third to fifth digits

Lateral plantar nerve (S2–S3)

Adduct digits (3–5) and flex metatarsophalangeal joints

Dorsal interossei (four muscles; D1–D4)

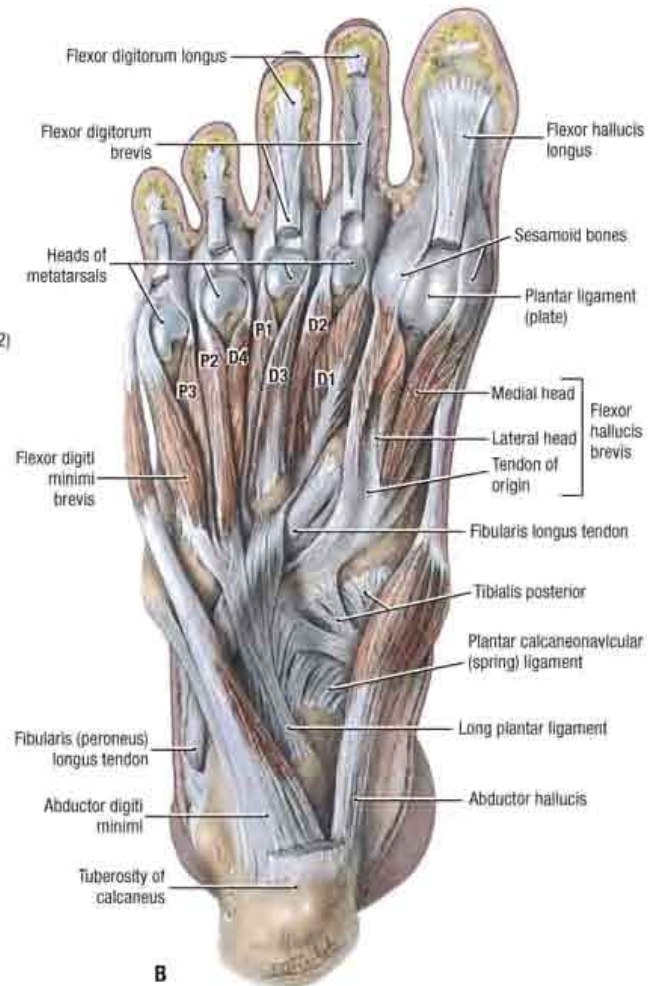
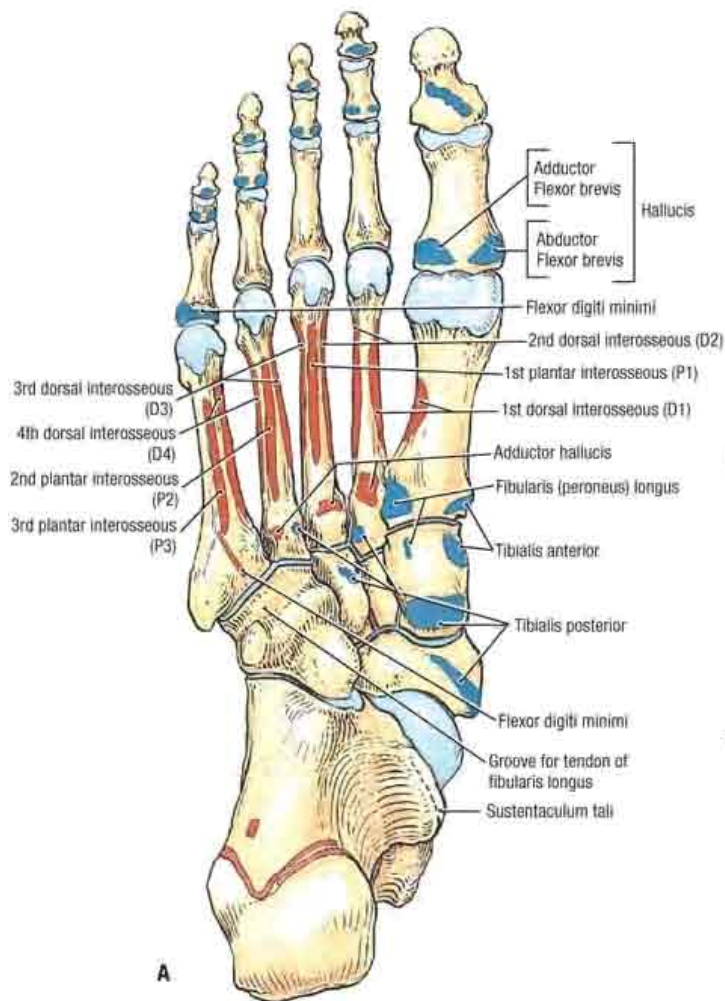
Adjacent sides of metatarsals 1–5

First: medial side of proximal phalanx of second digit  
 Second to fourth: lateral sides of second to fourth digits

Abduct digits (2–4) and flex metatarsophalangeal joints

<sup>a</sup>Although individual actions are described, the primary function of the intrinsic muscles of the foot is to act collectively to resist forces that stress (attempt to flatten) the arches of the foot.

Muscle	Proximal Attachment (red)	Distal Attachment (blue)	Innervation	Actions <sup>a</sup>
Table 5.18 Muscles in Sole of Foot–Fourth Layer				



Plantar Views

Authors: Agur, Anne M.R.; Dalley, Arthur F.

Title: *Grant's Atlas of Anatomy, 12th Edition*

Copyright ©2009 Lippincott Williams & Wilkins

> Table of Contents > Chapter 5 - Lower Limb > 5.71 Joint cavity of ankle joint

---

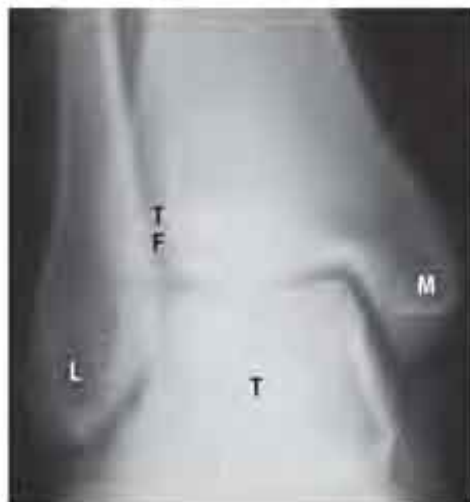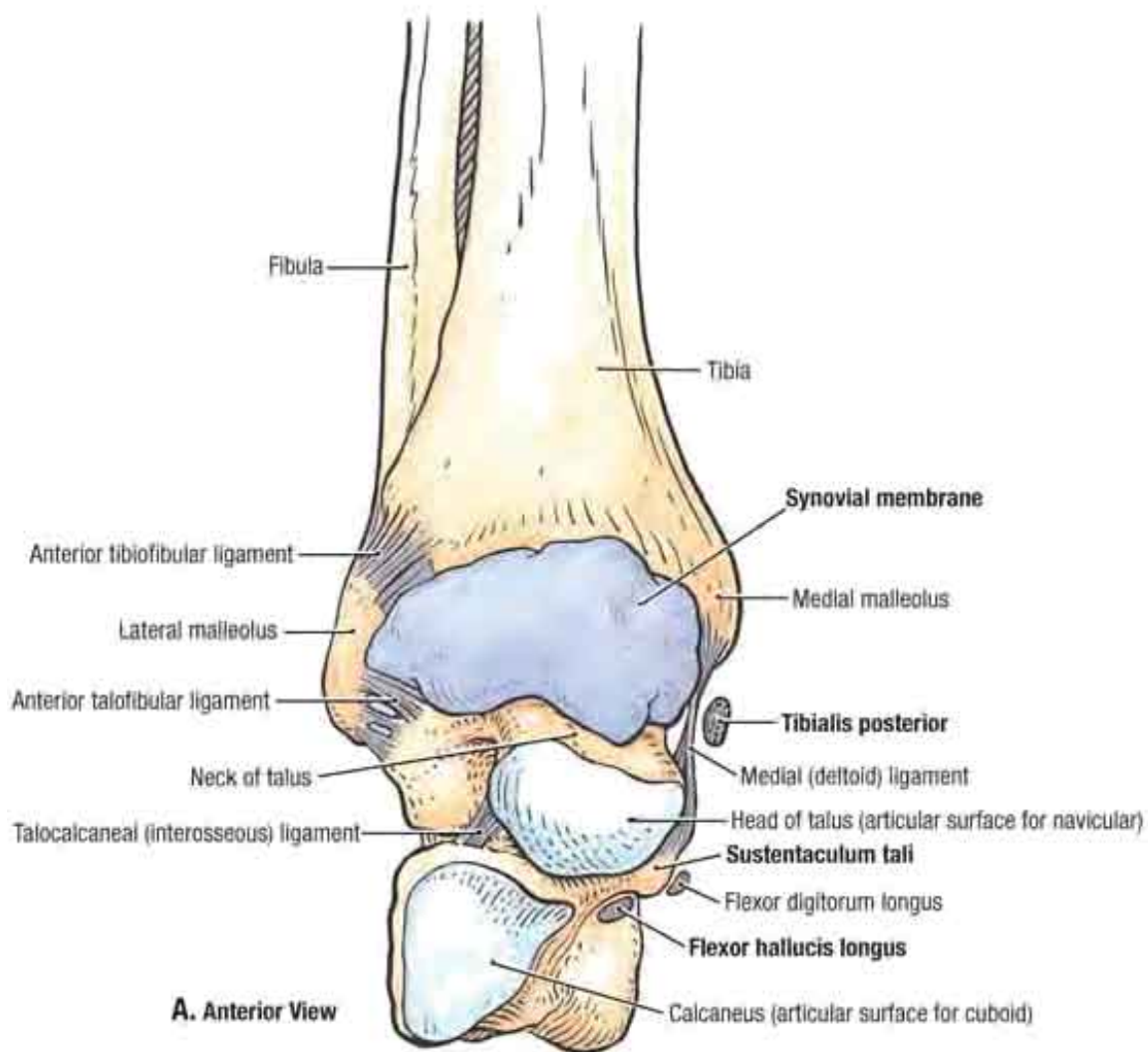
## 5.71 Joint cavity of ankle joint

*Part of* "Chapter 5 - Lower Limb"

A. Ankle joint with joint cavity distended with injected latex. B. Radiograph of joints of ankle region. *L*, lateral malleolus; *M*, medial malleolus; *T*, talus; *TF*, tibiofibular syndesmosis.

- The anterior articular surfaces of the calcaneus and head of the talus are each convex from side to side; thus the foot can be inverted and everted at the transverse tarsal joint.
- Note the relations of the tendons to the sustentaculum tali: the flexor hallucis longus inferior to it, flexor digitorum longus along its medial aspect, and tibialis posterior superior to it and in contact with the medial (deltoid) ligament.





**B. Anteroposterior View**



Authors: Agur, Anne M.R.; Dalley, Arthur F.

Title: *Grant's Atlas of Anatomy, 12th Edition*

Copyright ©2009 Lippincott Williams & Wilkins

> Table of Contents > Chapter 5 - Lower Limb > 5.72 Ankle joint and ligaments of dorsum of foot

---

## 5.72 Ankle joint and ligaments of dorsum of foot

*Part of* "Chapter 5 - Lower Limb"

Dissection. The ankle joint is plantarflexed, and its anterior capsular fibers are removed.

- All muscles attached to the fibula except the biceps femoris pull inferiorly on the bone during contraction. The oblique fibers of the interosseous membrane and ligaments uniting the fibula to the tibia resist this inferior pull but allow the fibula to be forced superiorly during full dorsiflexion of the ankle.

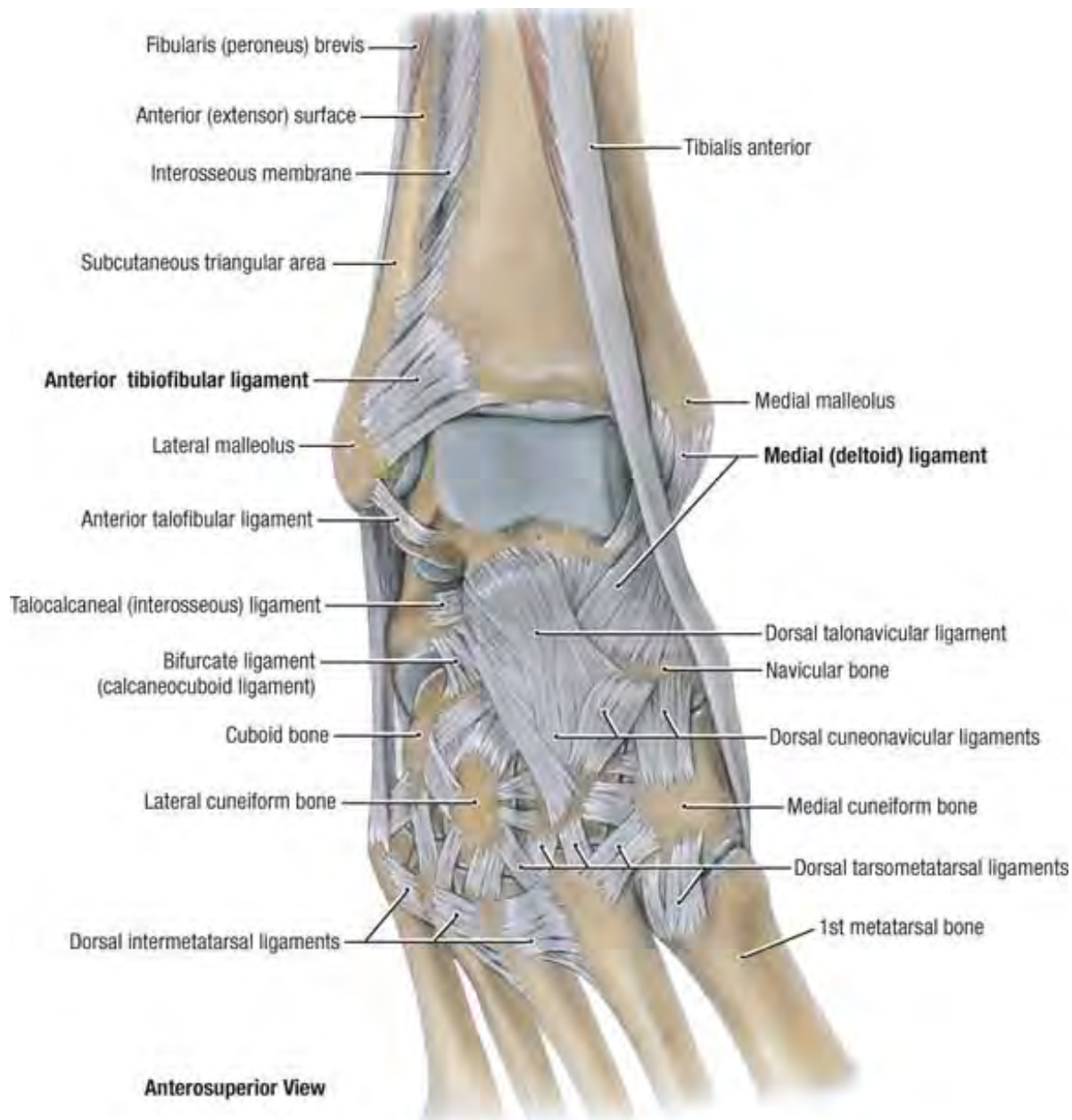
- The anterior talofibular ligament (part of the lateral ligament of the ankle) is a weak band that is easily torn (see the legend for Fig. 5.77).

- The bifurcate ligament, a Y-shaped ligament consisting of calcaneocuboid and calcaneonavicular ligaments, and the talonavicular ligament are the primary dorsal ligaments of the transverse tarsal joint (Fig. 5.83).

- A Pott fracture-dislocation of the ankle occurs when the foot is

forcibly everted. This action pulls on the extremely strong medial (deltoid) ligament, often avulsing the medial malleolus and compressing the lateral malleolus against the talus, shearing off the malleolus or, more often, fracturing the fibula superior to the tibiofibular syndesmosis.

P.450



Authors: Agur, Anne M.R.; Dalley, Arthur F.

Title: *Grant's Atlas of Anatomy, 12th Edition*

Copyright ©2009 Lippincott Williams & Wilkins

> Table of Contents > Chapter 5 - Lower Limb > 5.73 Posterior aspect of ankle joint

---

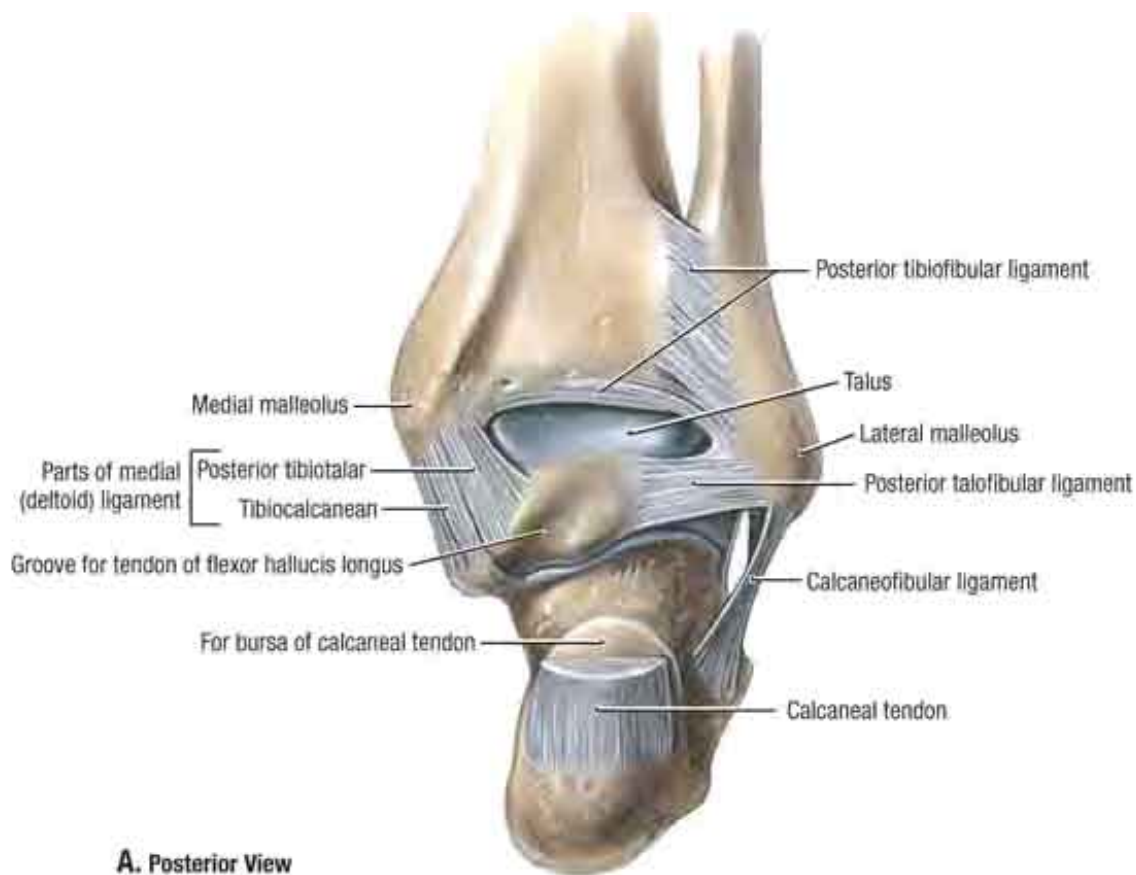## 5.73 Posterior aspect of ankle joint

*Part of* "Chapter 5 - Lower Limb "

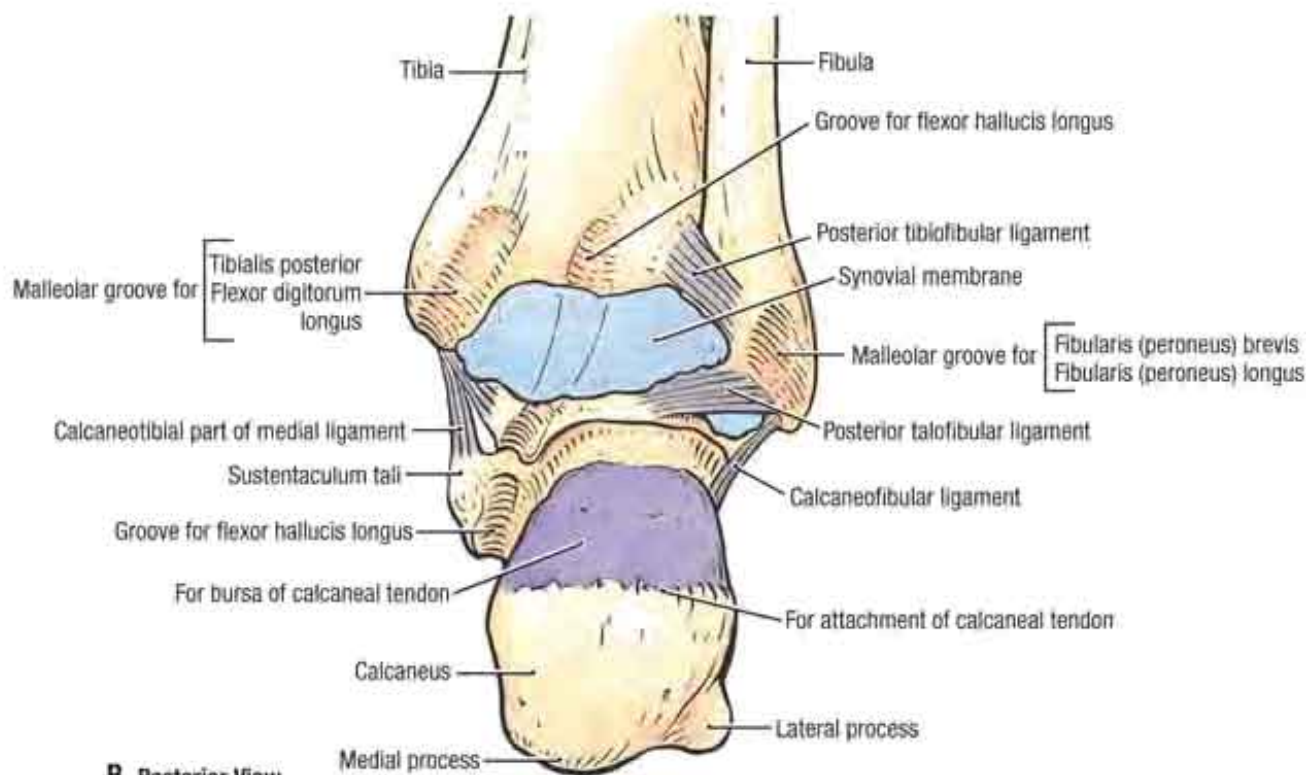
A. Dissection. B. Ankle joint with joint cavity distended with latex. Observe the grooves for the flexor hallucis longus muscle, which crosses the middle of the ankle joint posteriorly, the two tendons posterior to the medial malleolus, and the two tendons posterior to the lateral malleolus.

- The posterior aspect of the ankle joint is strengthened by the transversely oriented posterior tibiofibular and posterior talofibular ligaments.
- The calcaneofibular ligament stabilizes the joint laterally, and the posterior tibiotalar and tibiocalcaneal parts of the medial (deltoid) ligament stabilize it medially.
- The groove for the flexor hallucis tendon is between the medial and lateral tubercles of the talus and continues inferior to the sustentaculum tali.





**A. Posterior View**



**B. Posterior View**



Authors: Agur, Anne M.R.; Dalley, Arthur F.

Title: *Grant's Atlas of Anatomy, 12th Edition*

Copyright ©2009 Lippincott Williams & Wilkins

> Table of Contents > Chapter 5 - Lower Limb > 5.74 Posteromedial ankle

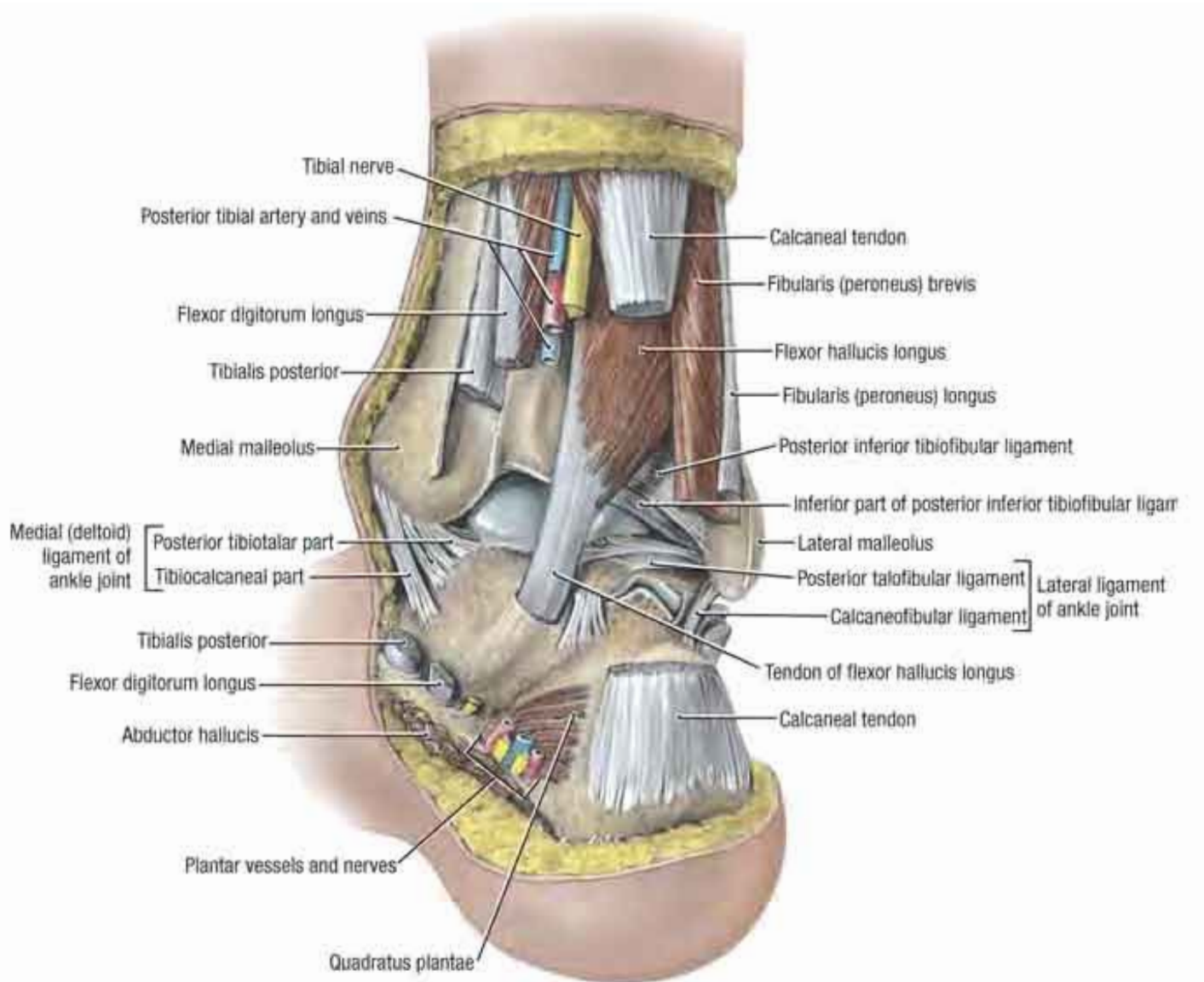
---

## 5.74 Posteromedial ankle

*Part of* "Chapter 5 - Lower Limb "

- The flexor hallucis longus muscle is midway between the medial and lateral malleoli; the tendons of the flexor digitorum and tibialis posterior are medial to it, and the tendons of the fibularis longus and brevis are lateral to it.
- The posterior tibial artery and the tibial nerve lie medial to the flexor hallucis longus muscle proximally and distally, after bifurcating posterolateral to it.
- The strongest parts of the ligaments of the ankle are those that prevent anterior displacement of the leg bones, namely, the posterior part of the medial ligament (posterior tibiotalar), the posterior talofibular, the tibiocalcaneal, and the calcaneofibular.

- Entrapment and compression of the tibial nerve (tarsal tunnel syndrome) occurs when there is edema and tightness in the ankle involving the synovial sheaths of the tendons of muscles in the posterior compartment of the leg. The area involved is from the medial malleolus to the calcaneus. The heel pain results from compression of the tibial nerve by the flexor retinaculum.



**Posteromedial View**

Authors: Agur, Anne M.R.; Dalley, Arthur F.

Title: *Grant's Atlas of Anatomy, 12th Edition*

Copyright ©2009 Lippincott Williams & Wilkins

> Table of Contents > Chapter 5 - Lower Limb > 5.75 Medial ligaments of ankle region

---

## 5.75 Medial ligaments of ankle region

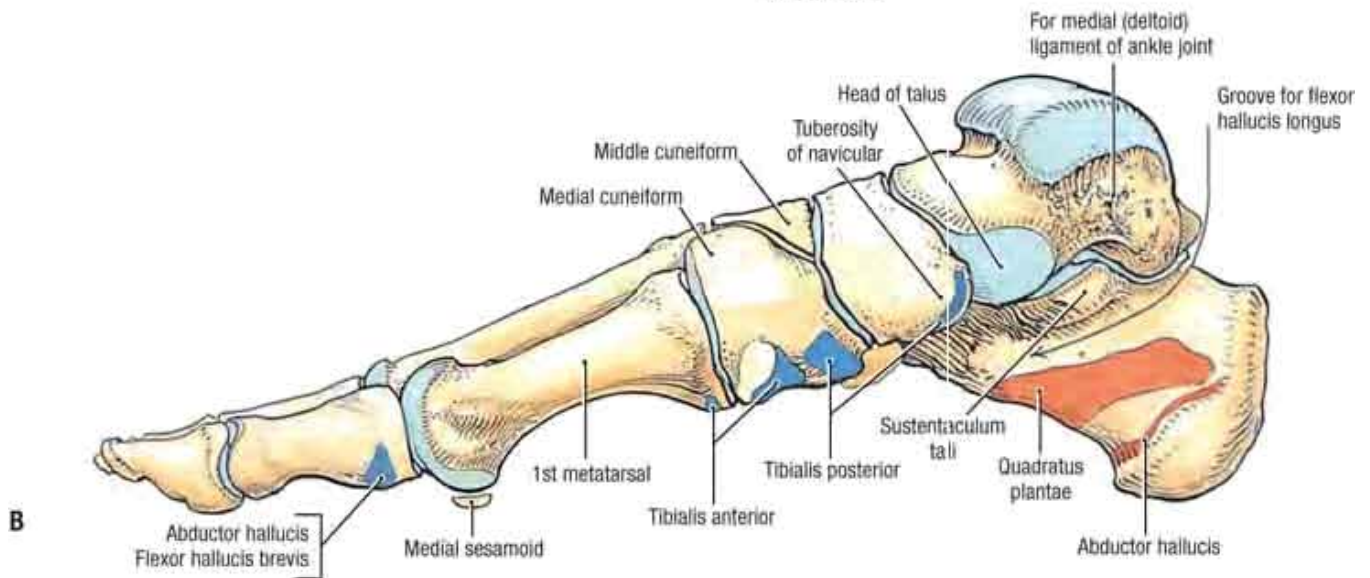
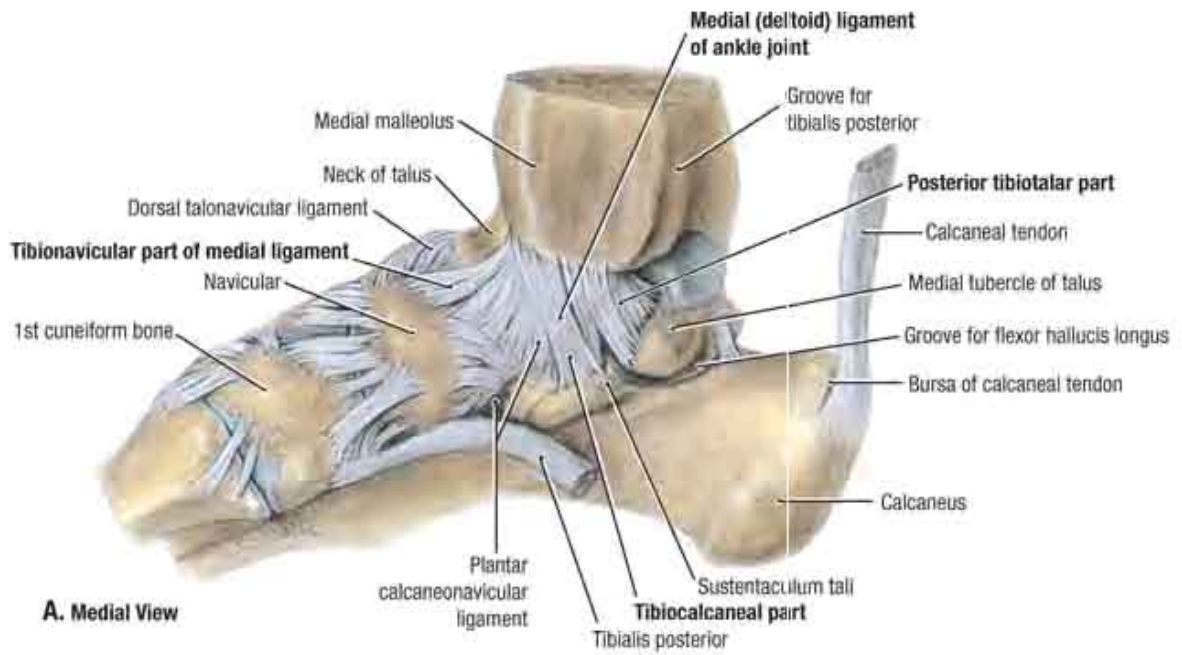
*Part of* "Chapter 5 - Lower Limb "

A. Dissection. B. Bones. The joint capsule of the ankle joint is reinforced medially by the large, strong medial ligament of the ankle (deltoid ligament) that attaches proximally to the medial malleolus and fans out from it to attach distally to the talus, calcaneus, and navicular via four adjacent and continuous parts: the tibionavicular part, the tibiocalcaneal part, and the anterior and posterior tibiotalar parts. The medial ligament stabilizes the ankle joint during eversion of the foot and prevents subluxation (partial dislocation) of the ankle joint.

---

P.453





Authors: Agur, Anne M.R.; Dalley, Arthur F.

Title: *Grant's Atlas of Anatomy, 12th Edition*

Copyright ©2009 Lippincott Williams & Wilkins

> Table of Contents > Chapter 5 - Lower Limb > 5.76 Radiographs of ankle and foot

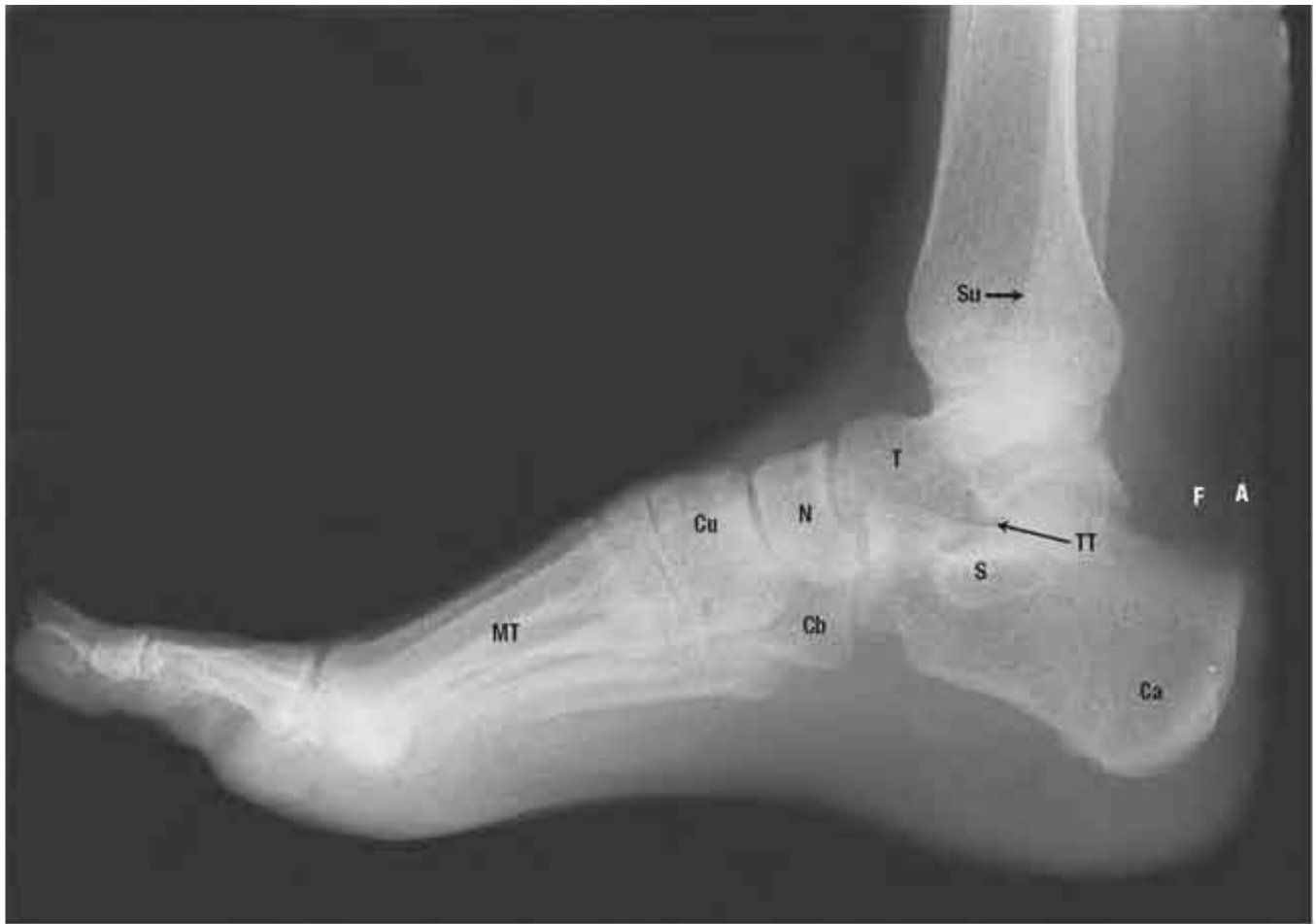---

## 5.76 Radiographs of ankle and foot

*Part of* "Chapter 5 - Lower Limb "

---

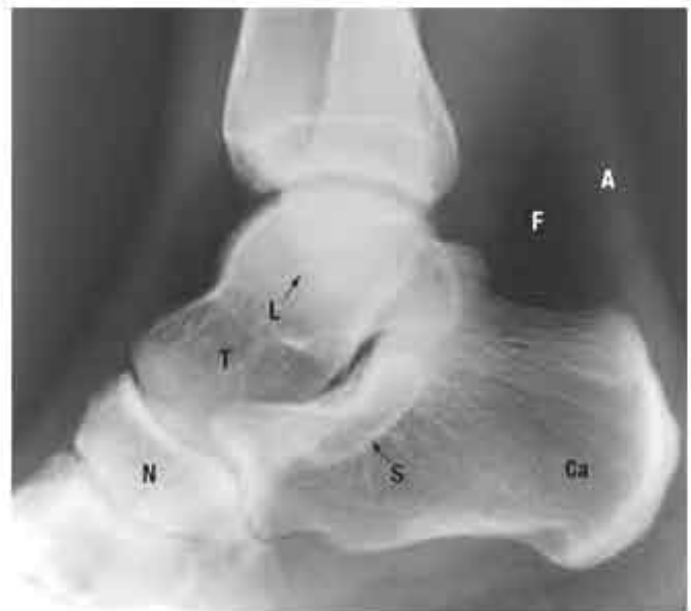
P.454



A.

Medial Views

A	Calcaneal (Achilles) tendon
Ca	Calcaneus
Cb	Cuboid
Cu	Cuneiforms
F	Fat
L	Lateral malleolus
MT	Metatarsal
N	Navicular
S	Sustentaculum tali
Su	Superimposed tibia and fibula
T	Talus
TT	Tarsal sinus



B.



Authors: Agur, Anne M.R.; Dalley, Arthur F.

Title: *Grant's Atlas of Anatomy, 12th Edition*

Copyright ©2009 Lippincott Williams & Wilkins

> Table of Contents > Chapter 5 - Lower Limb > 5.77 Lateral ligaments of ankle region

---

## 5.77 Lateral ligaments of ankle region

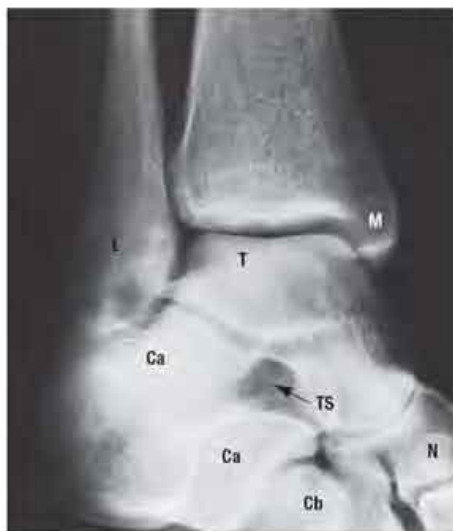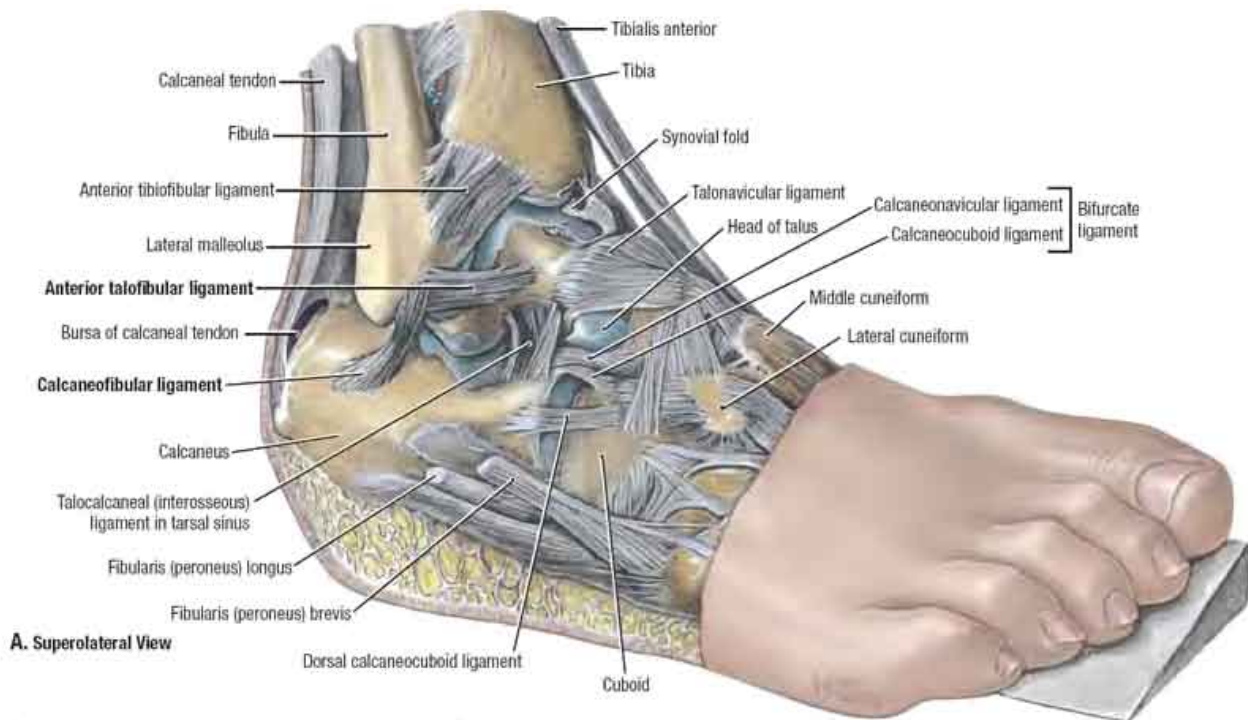
*Part of "Chapter 5 - Lower Limb "*

A. Dissection with foot inverted by underlying wedge. B. Lateral radiograph. C. Dissection. (Abbreviations following some labels refer to structures identified in B. )

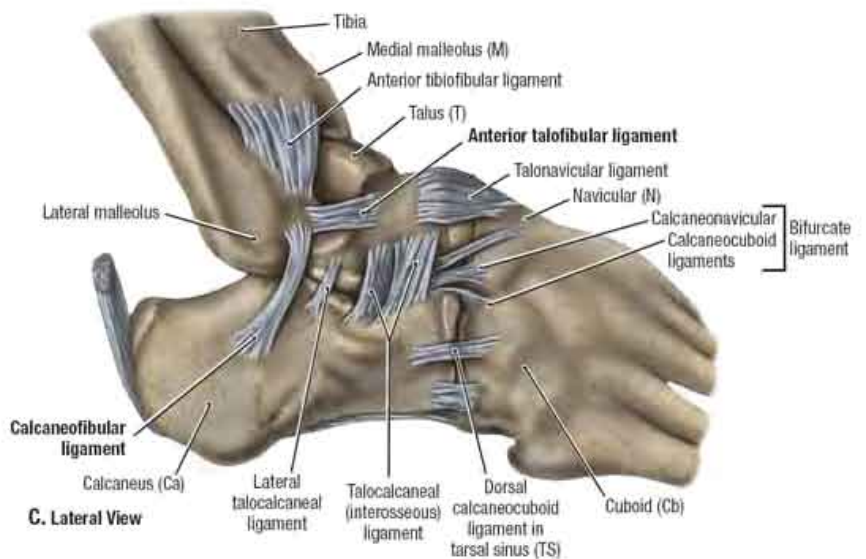
The ankle joint is reinforced laterally by the lateral ligament of the ankle, which consists of three separate ligaments: (1) anterior talofibular ligament, a flat, weak band; (2) calcaneofibular ligament, a round cord directed posteroinferiorly; and (3) posterior talofibular ligament, a strong, medially-directed horizontal ligament (see Fig. 5.74 ).

Ankle sprains (partial or fully torn ligaments) are common injuries. Ankle sprains nearly always result from forceful inversion of the weight-bearing plantarflexed foot. The anterior talofibular ligament is most commonly injured, resulting in instability of the ankle. The calcaneofibular is also often torn.





**B. Lateral View**



Authors: Agur, Anne M.R.; Dalley, Arthur F.

Title: *Grant's Atlas of Anatomy, 12th Edition*

Copyright ©2009 Lippincott Williams & Wilkins

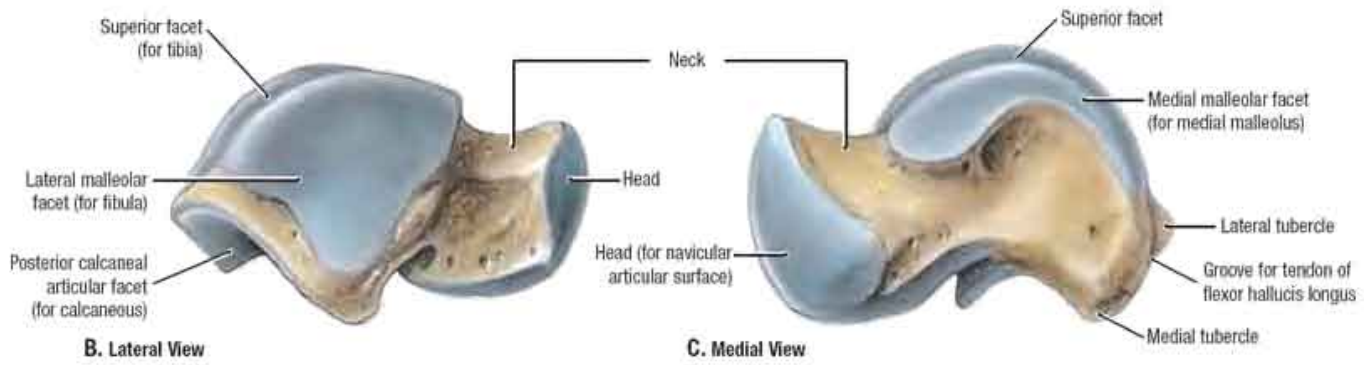
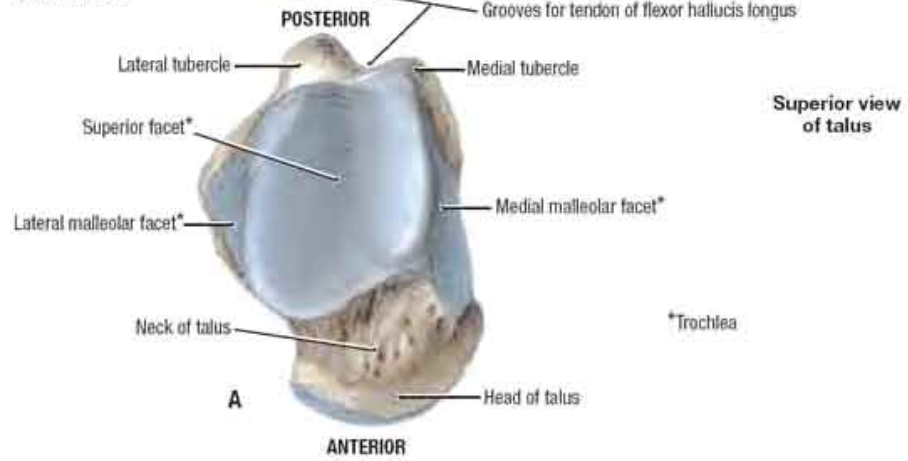
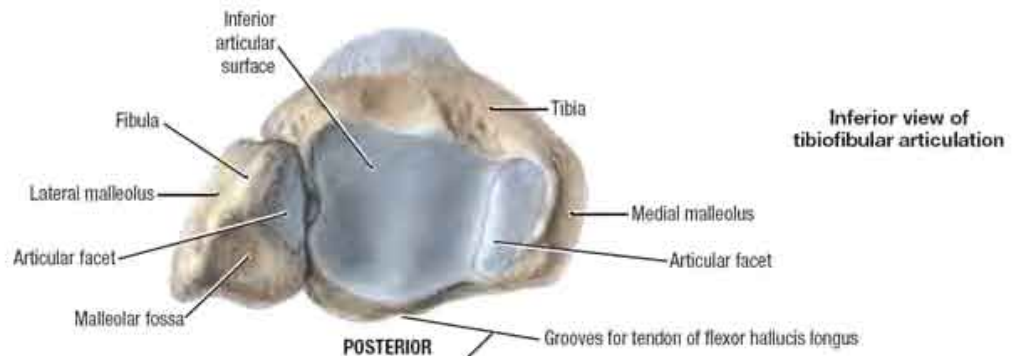
> Table of Contents > Chapter 5 - Lower Limb > 5.78 Articular surfaces of ankle joint

---

## 5.78 Articular surfaces of ankle joint

*Part of* "Chapter 5 - Lower Limb "

A. Superior aspect of talus separated from distal ends of tibia and fibula. The superior articular surface of the talus is broader anteriorly than posteriorly; hence the medial and lateral malleoli, which grasp the sides of the talus, tend to be forced apart in dorsiflexion. The fully dorsiflexed position is stable compared with the fully plantar flexed position. In plantar flexion, when the tibia and fibula articulate with the narrower posterior part of the superior articular surface of the talus, some side-to-side movement of the joint is allowed, accounting for the instability of the joint in this position. B. Lateral aspect of talus. The lateral, triangular articular area is for articulation with the lateral malleolus. C. Medial aspect of talus. The comma-shaped articular area is for articulation with the medial malleolus.



Authors: Agur, Anne M.R.; Dalley, Arthur F.

Title: *Grant's Atlas of Anatomy, 12th Edition*

Copyright ©2009 Lippincott Williams & Wilkins

> Table of Contents > Chapter 5 - Lower Limb > 5.79 Coronal section and MRI through ankle

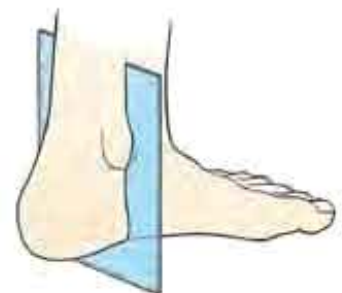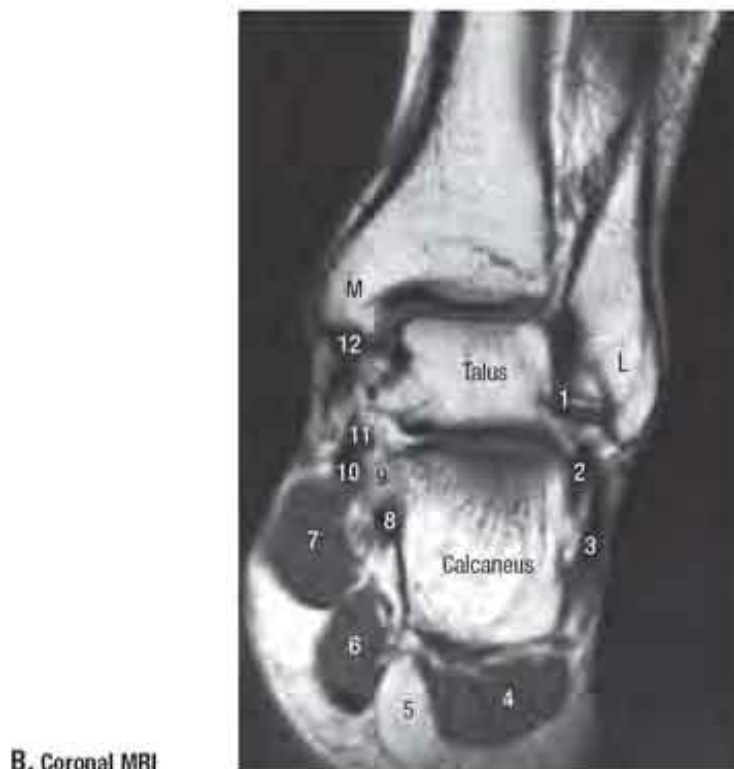
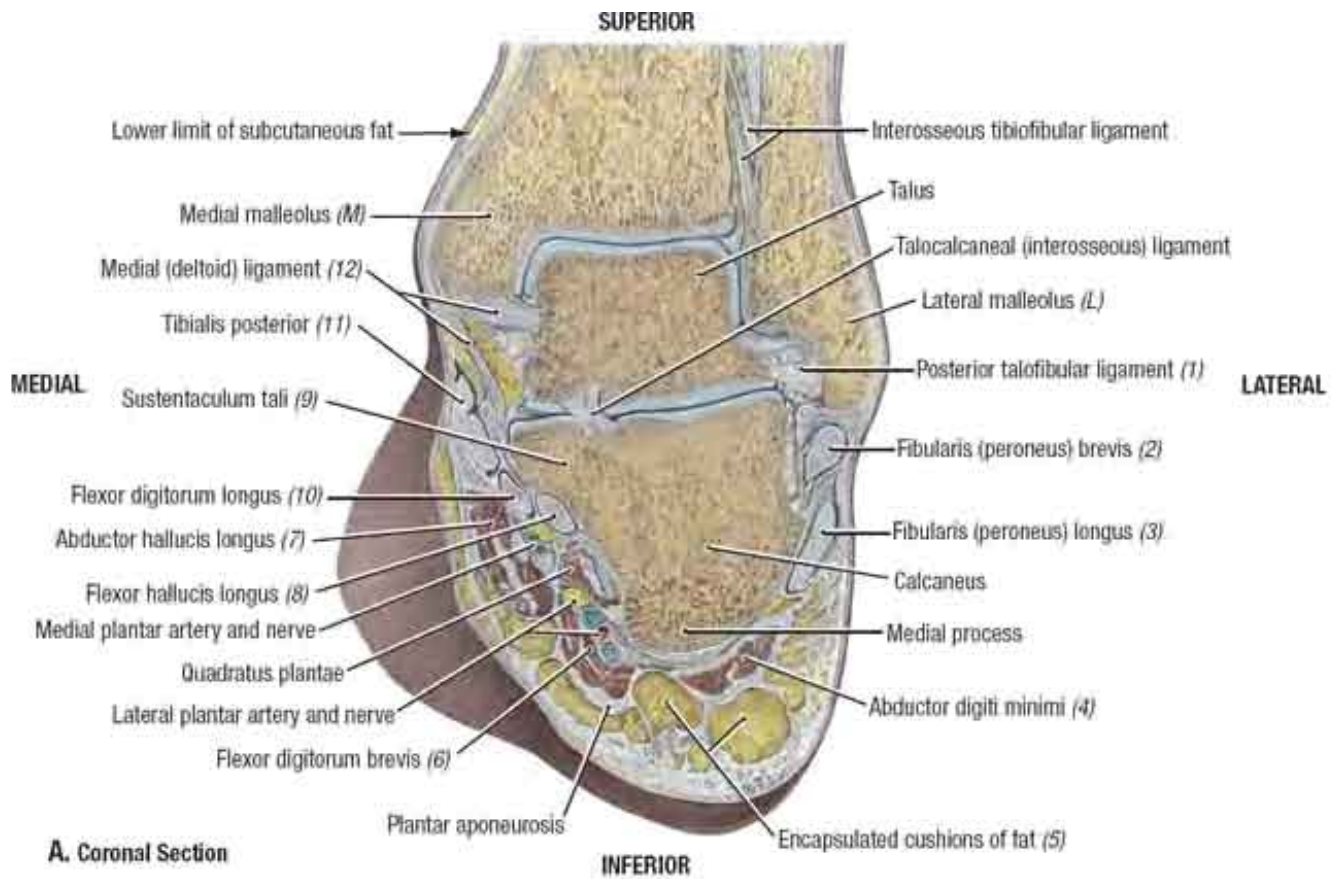
---

## 5.79 Coronal section and MRI through ankle

*Part of* "Chapter 5 - Lower Limb "

A. Coronal section. B. Coronal MRI (*numbers* in B refer to structures labeled in A ).

- The tibia rests on the talus, and the talus rests on the calcaneus; between the calcaneus and the skin are several encapsulated cushions of fat.
- The lateral malleolus descends farther inferiorly than the medial malleolus.
- The talocalcaneal (interosseous) ligament between the talus and calcaneus separates the subtalar, or posterior, talocalcaneal joint from the talocalcaneonavicular joint.
- The sustentaculum tali acts as a pulley for the flexor hallucis longus muscle and gives attachment to the calcaneotibial part of the medial (deltoid) ligament.





Authors: Agur, Anne M.R.; Dalley, Arthur F.

Title: *Grant's Atlas of Anatomy, 12th Edition*

Copyright ©2009 Lippincott Williams & Wilkins

> Table of Contents > Chapter 5 - Lower Limb > 5.80 Transverse section and MRI through ankle

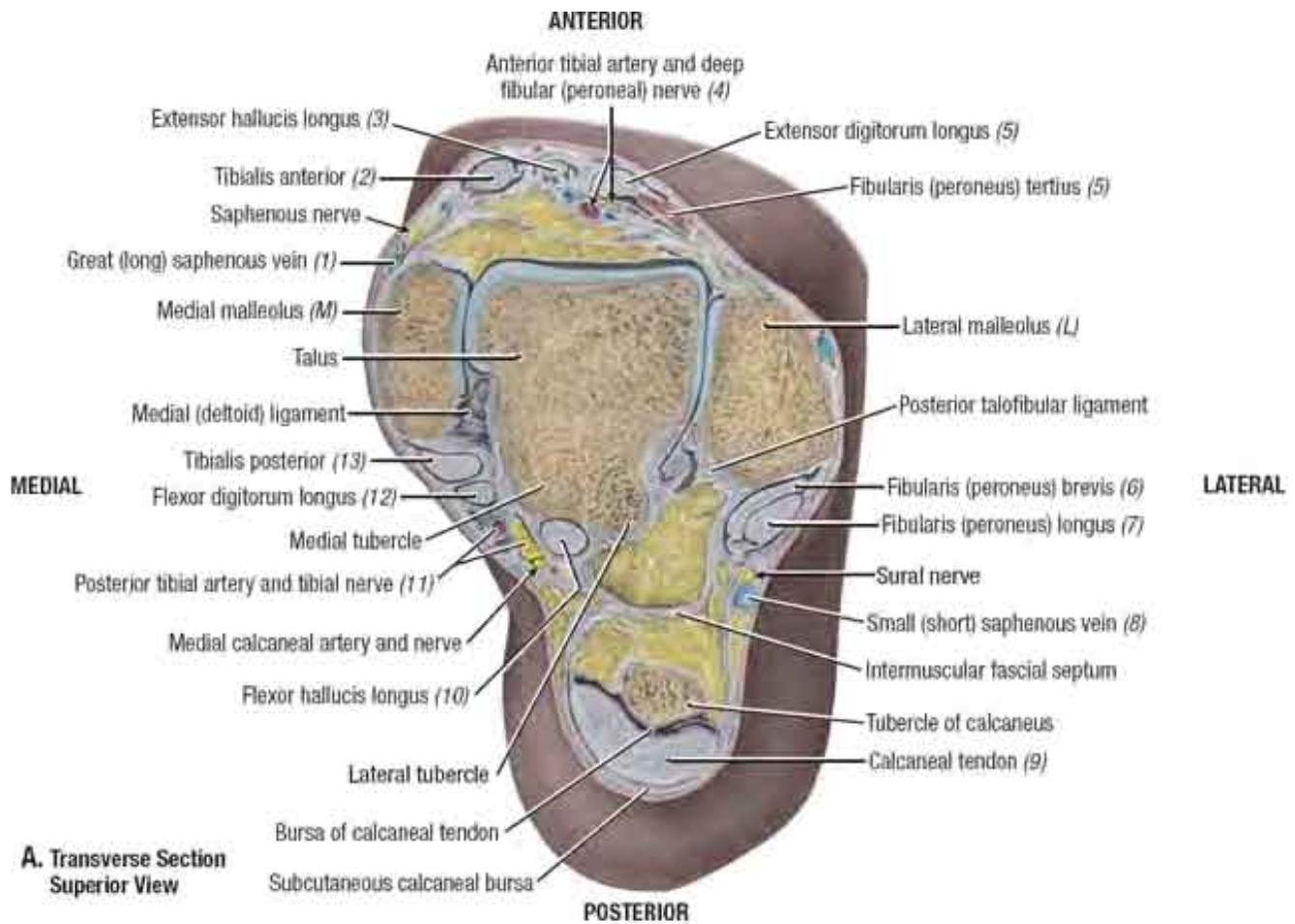
---

## 5.80 Transverse section and MRI through ankle

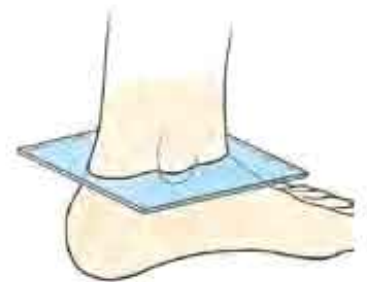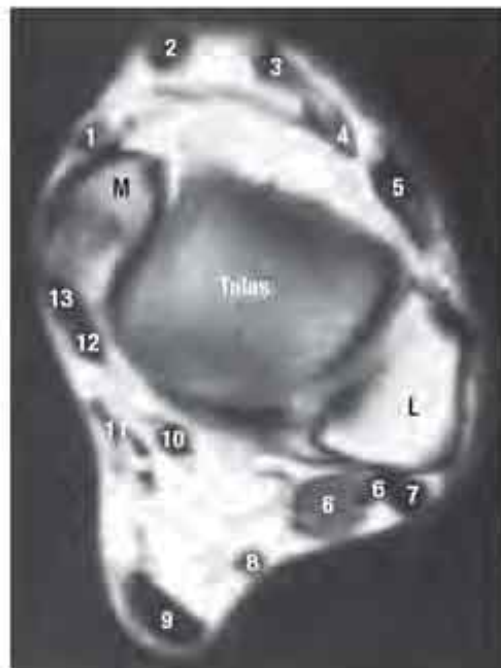*Part of* "Chapter 5 - Lower Limb "

A. Transverse section. B. Transverse MRI (*numbers* in B refer to structures labeled in A ).

- The body of the talus is wedge shaped and positioned between the malleoli, which are bound to it by the medial (deltoid) and posterior talofibular ligaments.
- The flexor hallucis longus muscle lies within its osseofibrous sheath between the medial and lateral tubercles of the talus.
- There is a small, inconstant subcutaneous bursa superficial to the calcaneal tendon ; a large, constant bursa of calcaneal tendon deep to it.



**B. Transverse MRI**



Authors: Agur, Anne M.R.; Dalley, Arthur F.

Title: *Grant's Atlas of Anatomy, 12th Edition*

Copyright ©2009 Lippincott Williams & Wilkins

> Table of Contents > Chapter 5 - Lower Limb > 5.81 Joints of inversion and eversion

---

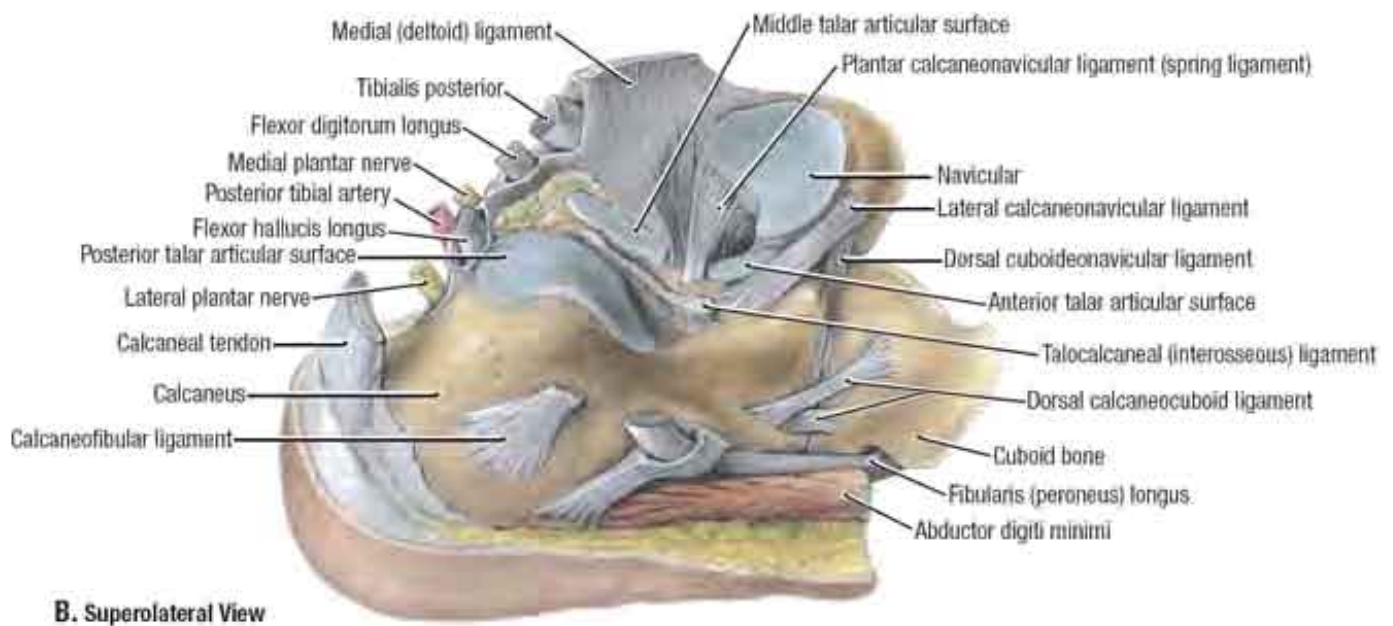
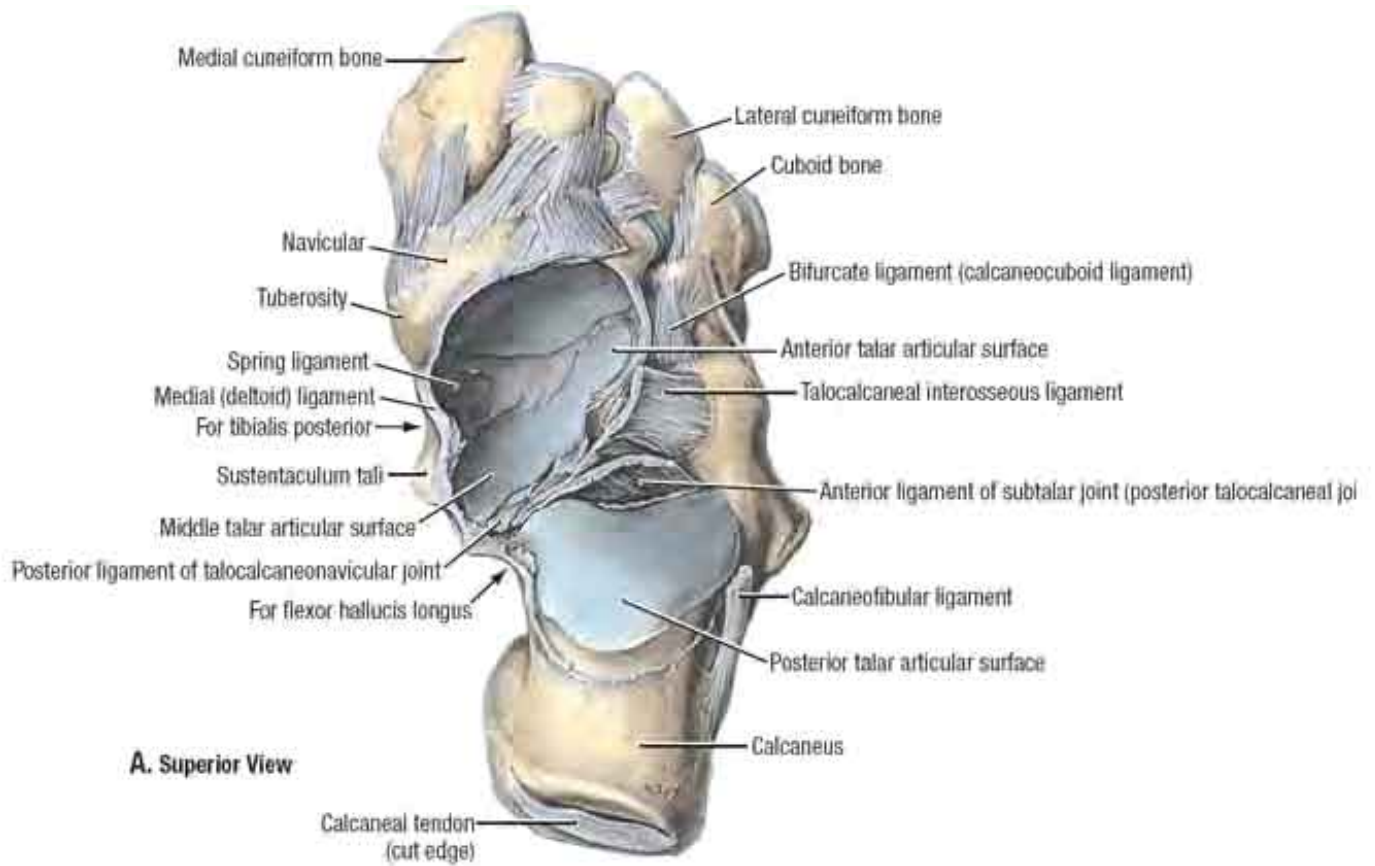
## 5.81 Joints of inversion and eversion

*Part of* "Chapter 5 - Lower Limb "

The joints of inversion and eversion are the subtalar (posterior talocalcaneal) joint, talocalcaneonavicular joint, and transverse tarsal (combined calcaneocuboid and talonavicular) joint. A. Posterior and middle parts of foot with talus removed. B. Posterior part of foot with talus removed. The convex posterior talar facet is separated from the concave middle, and anterior facets by the talocalcaneal (interosseous) ligament within the tarsal sinus.

---

P.459



Authors: Agur, Anne M.R.; Dalley, Arthur F.

Title: *Grant's Atlas of Anatomy, 12th Edition*

Copyright ©2009 Lippincott Williams & Wilkins

> Table of Contents > Chapter 5 - Lower Limb > 5.82 Talocalcaneal joint

---

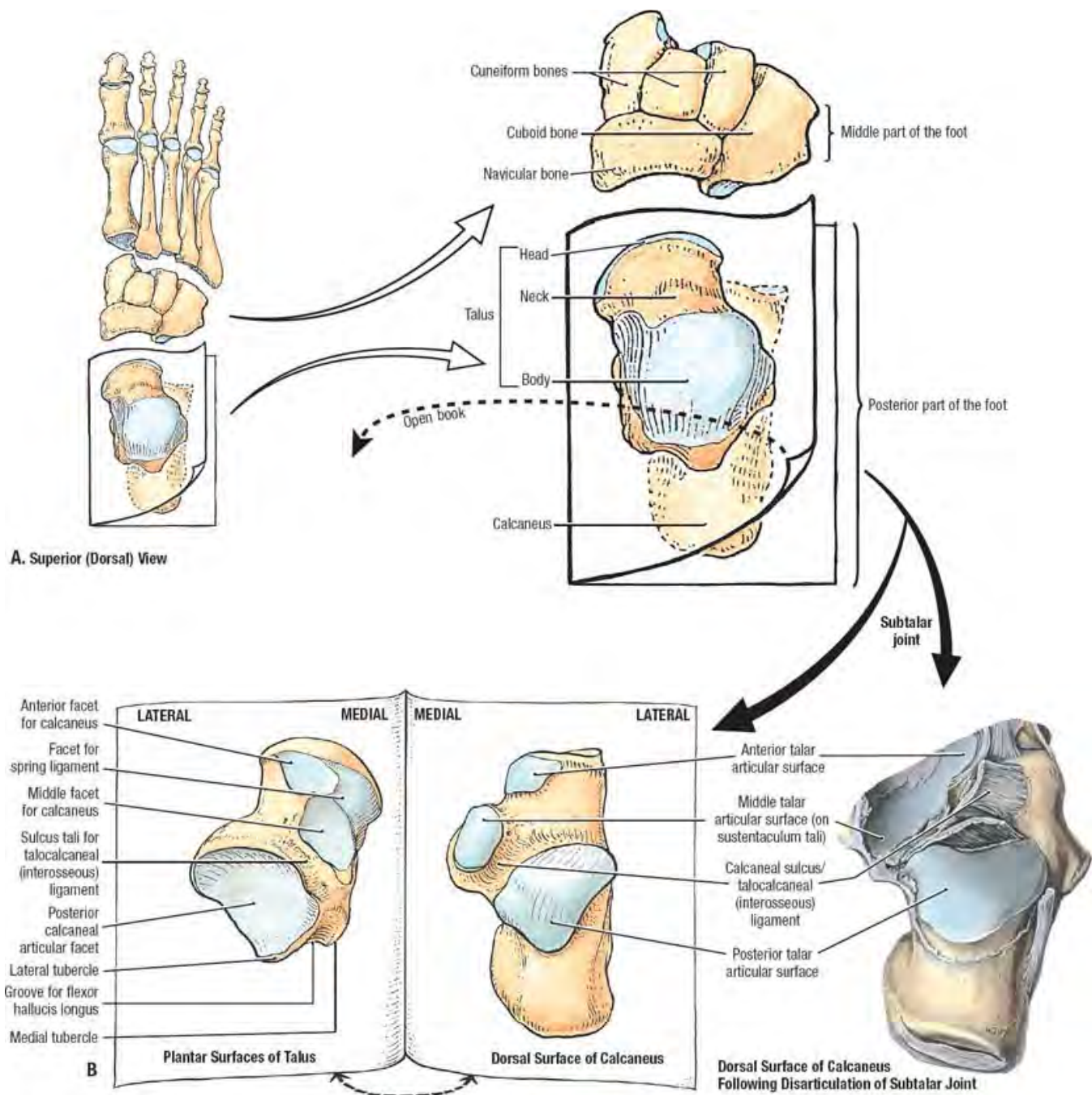
## 5.82 Talocalcaneal joint

*Part of* "Chapter 5 - Lower Limb "

A. Bones of foot, dorsal view. B. Bony surfaces of talocalcaneal joints. The plantar surface of the talus and dorsal surface of the calcaneus are displayed as pages in a book.

- The joints of inversion and eversion are the subtalar (posterior talocalcaneal) joint, talocalcaneonavicular joint, and transverse tarsal (combined calcaneocuboid and talonavicular) joint.
- The talus is part of the ankle joint, of the posterior and anterior talocalcaneal joints, and of the talonavicular joint.
- The posterior and anterior talocalcaneal joints are separated from each other by the sulcus tarsi and calcaneal sulcus, which, when the talus and calcaneus are in articulation, become the tarsal sinus.





## Subtalar

Synovial (plane) joint

Inferior surface of body of talus articulates with superior surface of calcaneus

Attached to margins of articular surfaces

Medial, lateral, and posterior talocalcaneal ligaments support capsule; talocalcaneal (interosseous) ligament binds bones together

Inversion and eversion of foot

Talocalcaneo-navicular

Synovial joint; talonavicular part is ball-and-socket type

Head of talus articulates with calcaneus and navicular bones

Incompletely encloses joint

Plantar calcaneonavicular (â€œspringâ€•) ligament supports head of talus

Gliding and rotary movements

Calcaneocuboid

Synovial (plane) joint

Anterior end of calcaneus articulates with posterior surface of cuboid

Encloses joint

Dorsal calcaneocuboid ligament, plantar calcaneocuboid ligament, and long plantar ligament support fibrous capsule

Inversion and eversion of foot

Cuneonavicular

Synovial (plane) joint

Anterior navicular articulates with posterior surface of cuneiforms

Common joint capsule

Dorsal and plantar ligaments

Little movement

Tarsometatarsal

Synovial (plane) joint

Anterior tarsal bones articulate with bases of metatarsal bones

Encloses joint

Dorsal, plantar, and interosseous ligaments

Gliding or sliding

Intermetatarsal

Synovial (plane) joint

Bases of metatarsal bones articulate with each other

Encloses each joint

Dorsal, plantar, and interosseous ligaments bind bones together

Little individual movement

Metatarsophalangeal

Synovial (condyloid) joint

Heads of metatarsal bones articulate with bases of abduc-proximal phalanges  
Encloses each joint

ligament supports

Collateral ligaments support capsule on each side; plantar and circum- duction plantar part of capsule

Flexion, extension, and some abduction, adduction,

Interphalangeal

Synovial (hinge) joint

Head of proximal or middle phalanx articulates with base of phalanx distal to it

Encloses each joint

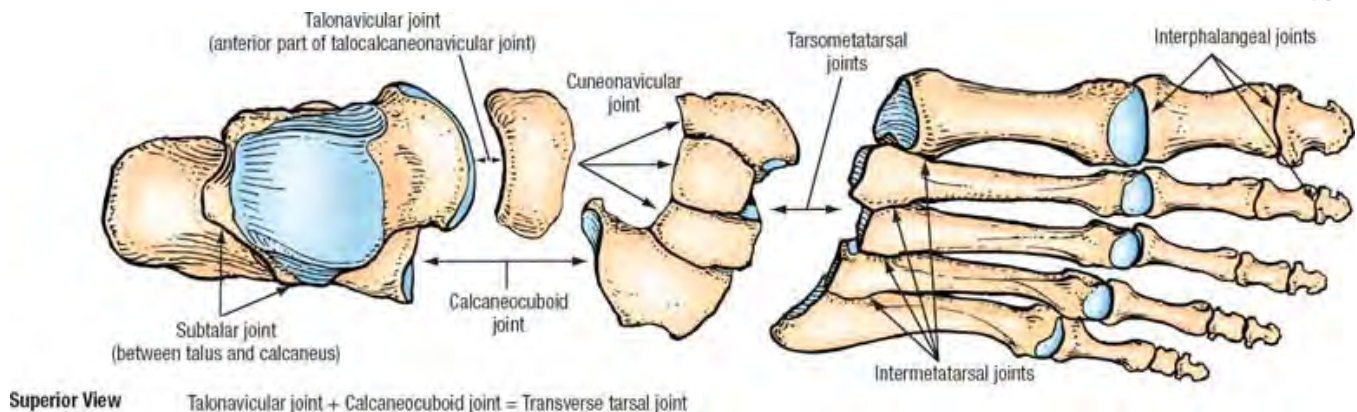
Collateral and plantar ligaments support joints

Flexion and extension

Joint	Type	Articular Surface	Joint Capsule	Ligaments	Movements
-------	------	-------------------	---------------	-----------	-----------

Table 5.19 Joints of Foot

P.461



Authors: Agur, Anne M.R.; Dalley, Arthur F.

Title: *Grant's Atlas of Anatomy, 12th Edition*

Copyright ©2009 Lippincott Williams & Wilkins

> Table of Contents > Chapter 5 - Lower Limb > 5.83 Transverse tarsal joint

---

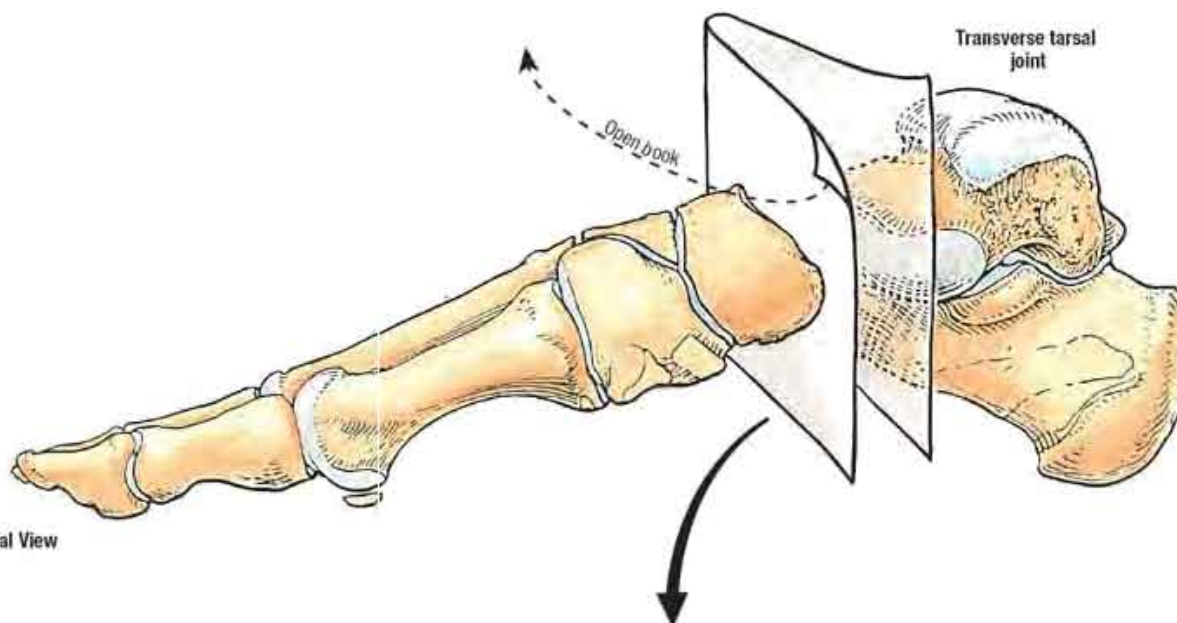
## 5.83 Transverse tarsal joint

*Part of* "Chapter 5 - Lower Limb "

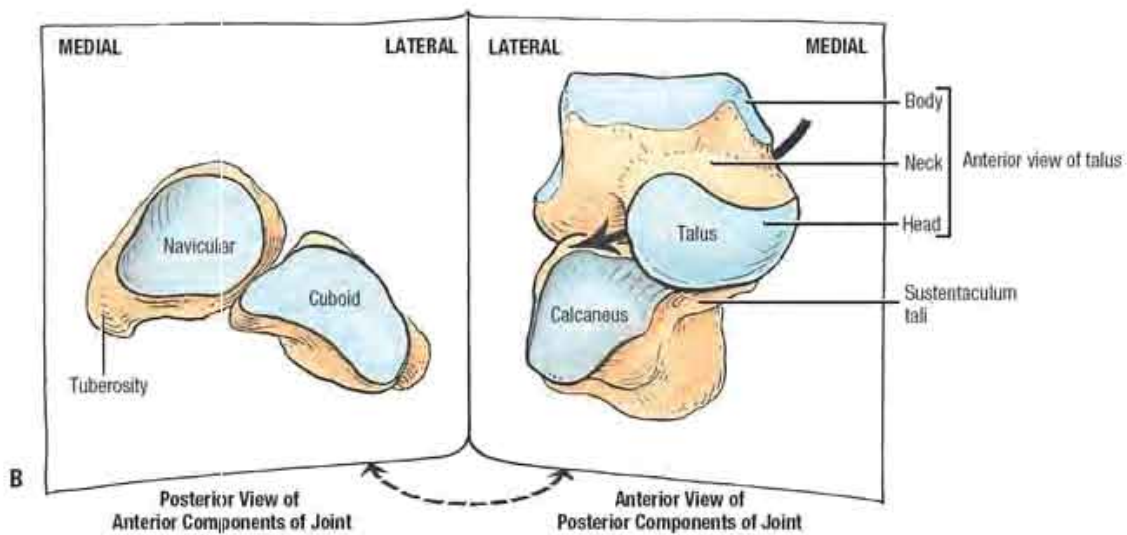
A. Bones of foot, medial view. B. Articular surfaces of transverse tarsal joint. This compound joint includes the talonavicular and calcaneocuboid articulations. The posterior surfaces of the navicular and cuboid bones and the anterior surfaces of the talus and calcaneus are displayed as pages in a book. The *black arrow* traverses the tarsal sinus, in which the talocalcaneal (interosseous) ligament is located.

---

P.462



A. Medial View



B



Authors: Agur, Anne M.R.; Dalley, Arthur F.

Title: *Grant's Atlas of Anatomy, 12th Edition*

Copyright ©2009 Lippincott Williams & Wilkins

> Table of Contents > Chapter 5 - Lower Limb > 5.84 Cuneonavicular, cubonavicular, and tarsometatarsal joints

---

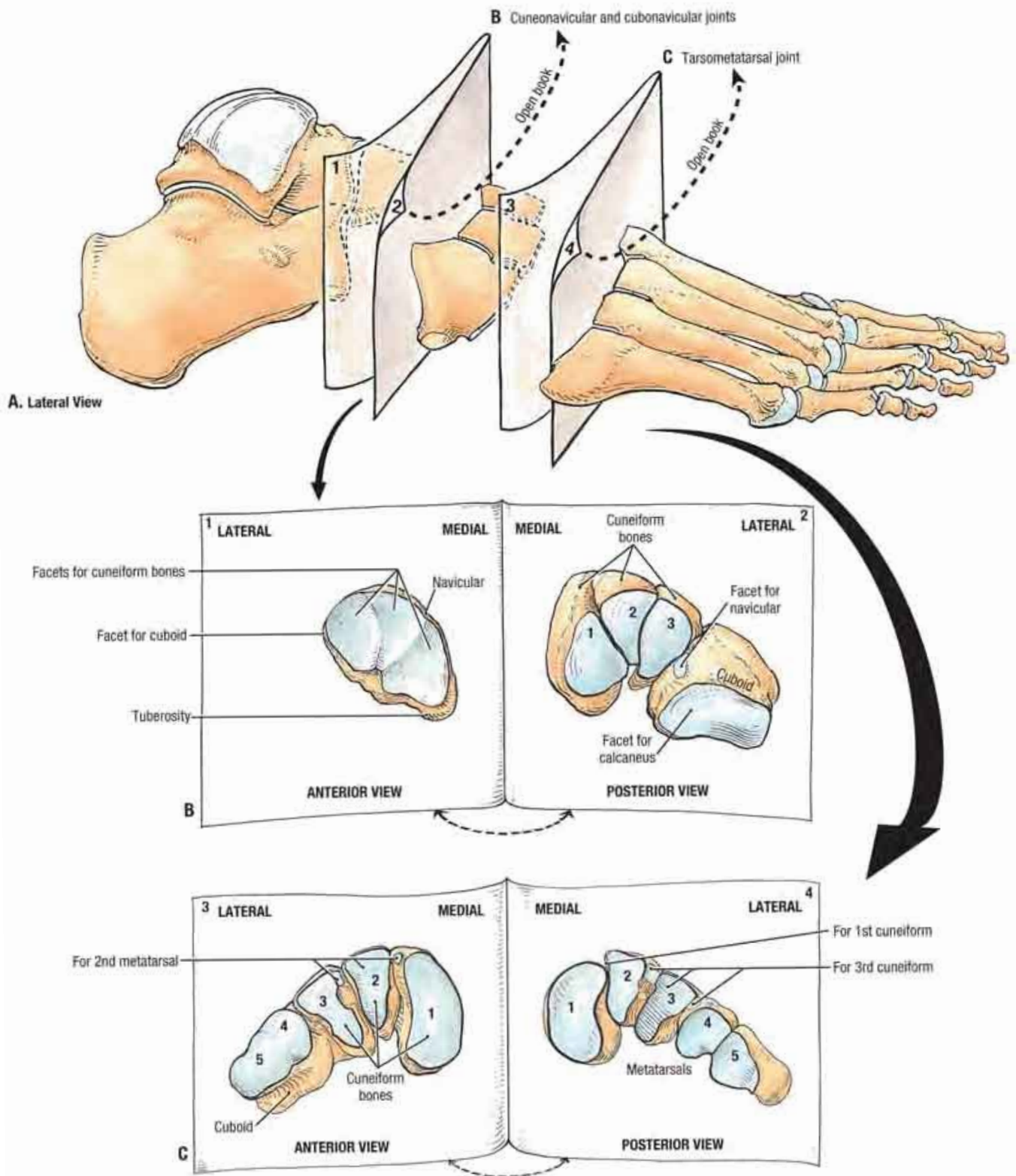
## 5.84 Cuneonavicular, cubonavicular, and tarsometatarsal joints

*Part of* "Chapter 5 - Lower Limb "

A. Bones of foot, lateral view. B. Bony surfaces of the cuneonavicular and cubonavicular joints. C. Bony surfaces of the tarsometatarsal joints.

---

P.463



Authors: Agur, Anne M.R.; Dalley, Arthur F.

Title: *Grant's Atlas of Anatomy, 12th Edition*

Copyright ©2009 Lippincott Williams & Wilkins

> Table of Contents > Chapter 5 - Lower Limb > 5.85 Metatarsophalangeal joint of great toe

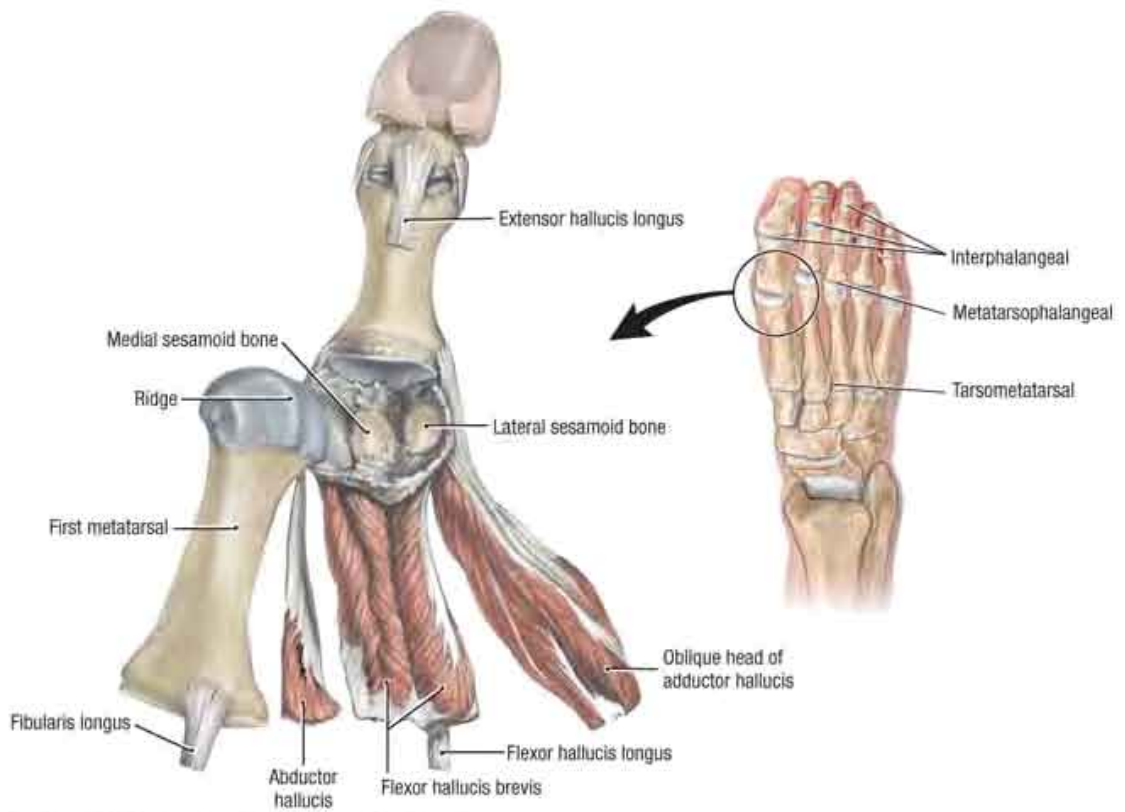
---

## 5.85 Metatarsophalangeal joint of great toe

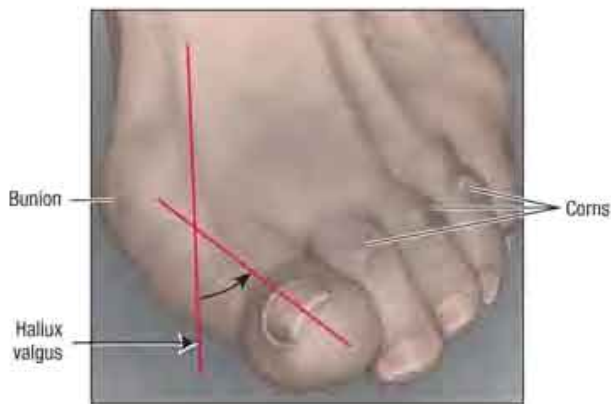
*Part of* "Chapter 5 - Lower Limb "

A. First metatarsal and sesamoid bones of the right great toe. The sesamoid bones of the great toe (hallux) are bound together and located on each side of a bony ridge on the first metatarsal.

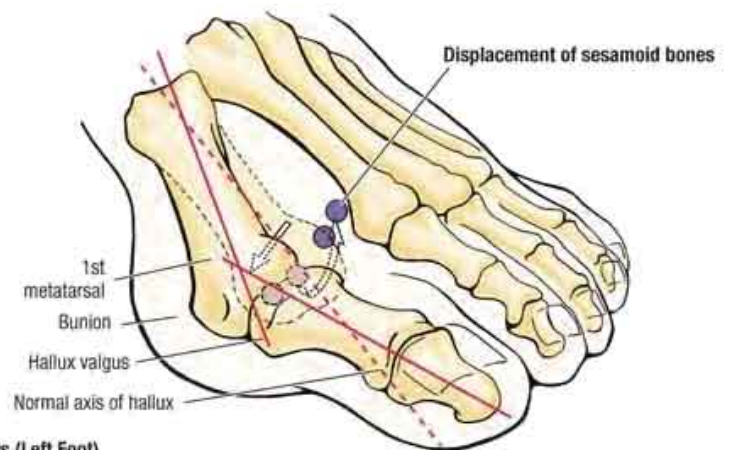
B. Hallux valgus. Hallux valgus is a foot deformity caused by pressure from footwear and degenerative joint disease; it is characterized by lateral deviation of the great toe (L. *hallux*). In some people, the deviation is so great that the 1st toe overlaps the 2nd toe. These individuals are unable to move their 1st digit away from their 2nd digit because the sesamoid bones under the head of the 1st metatarsal are displaced and lie in the space between the heads of the 1st and 2nd metatarsals. In addition, a subcutaneous bursa may form owing to pressure and friction against the shoe. When tender and inflamed, the bursa is called a bunion.



**A. Superior View of Right Great Toe, Medial View of First Metatarsal**



**B. Hallux valgus, bunion and corns**



**Superior Views (Left Foot)**

Authors: Agur, Anne M.R.; Dalley, Arthur F.

Title: *Grant's Atlas of Anatomy, 12th Edition*

Copyright ©2009 Lippincott Williams & Wilkins

> Table of Contents > Chapter 5 - Lower Limb > 5.86 Ligaments of sole of foot

---

## 5.86 Ligaments of sole of foot

*Part of* "Chapter 5 - Lower Limb "

A. Dissection of superficial ligaments. B. Bones lying deep to ligaments of A .

In A :

- The head of the talus is exposed between the sustentaculum tali of the calcaneus and the navicular.
- Note the insertions of three long tendons: fibularis (peroneus) longus, tibialis anterior, and tibialis posterior.
- The tendon of the fibularis (peroneus) longus muscle crosses the sole of the foot in the groove anterior to the ridge of the cuboid, is bridged by some fibers of the long plantar ligament, and inserts into the base of the first metatarsal.
- Observe the slips of the tibialis posterior tendon extending to the bones anterior to the transverse tarsal joint.

---

P.465

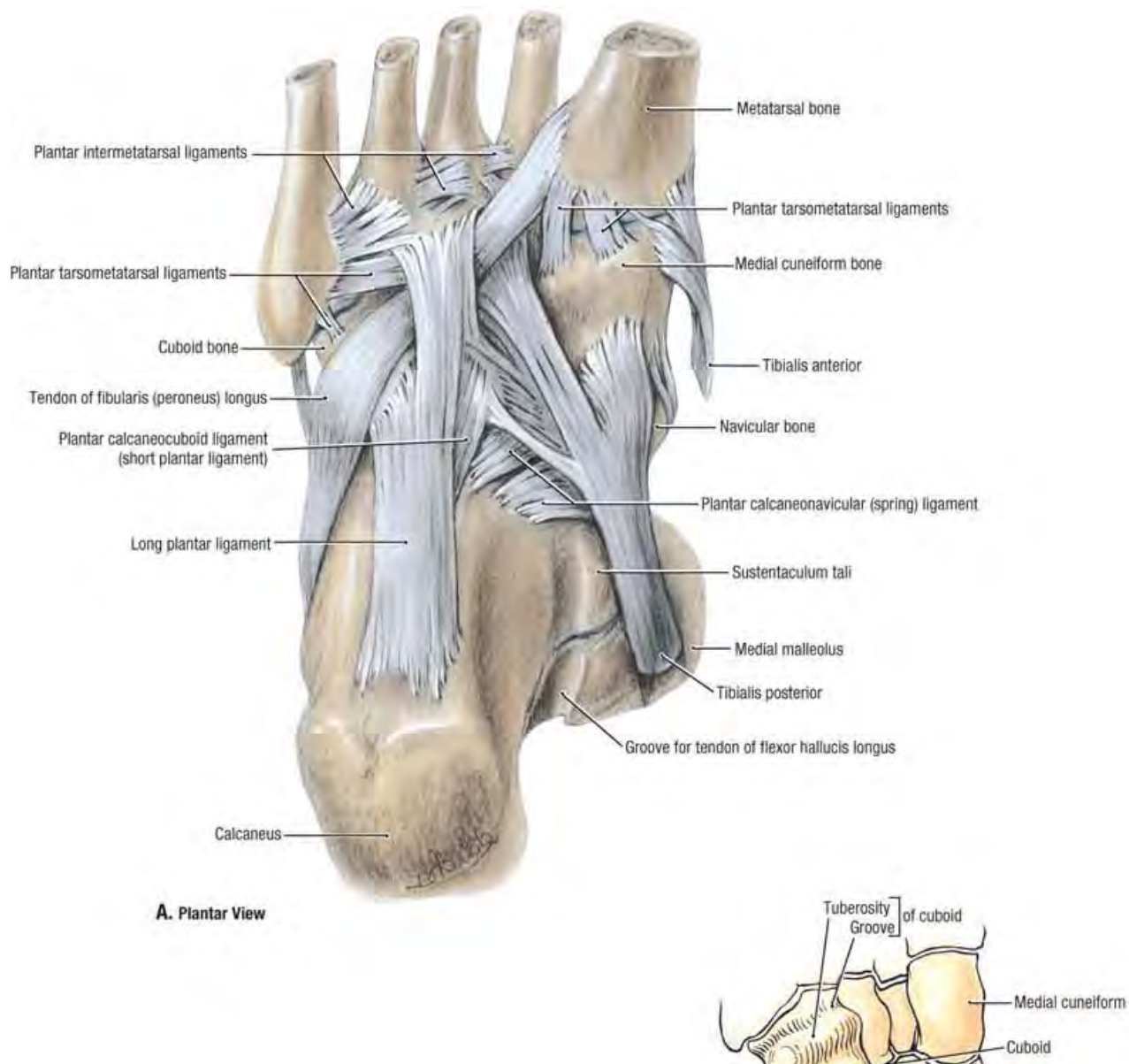
C. Dissection of the deep ligaments. D. Support for head of talus. The head of the talus is supported by the plantar calcaneonavicular ligament (spring ligament) and the tendon of the tibialis posterior.

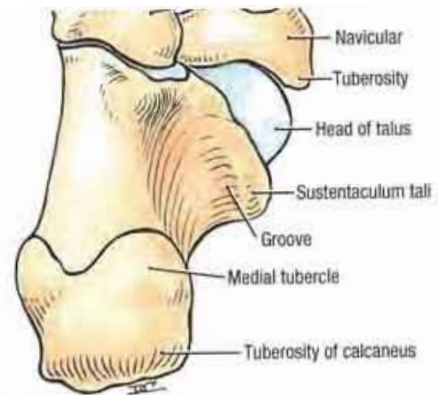
- The plantar calcaneocuboid (short plantar) and plantar calcaneonavicular (spring) ligaments are the primary plantar ligaments of the transverse tarsal joint.



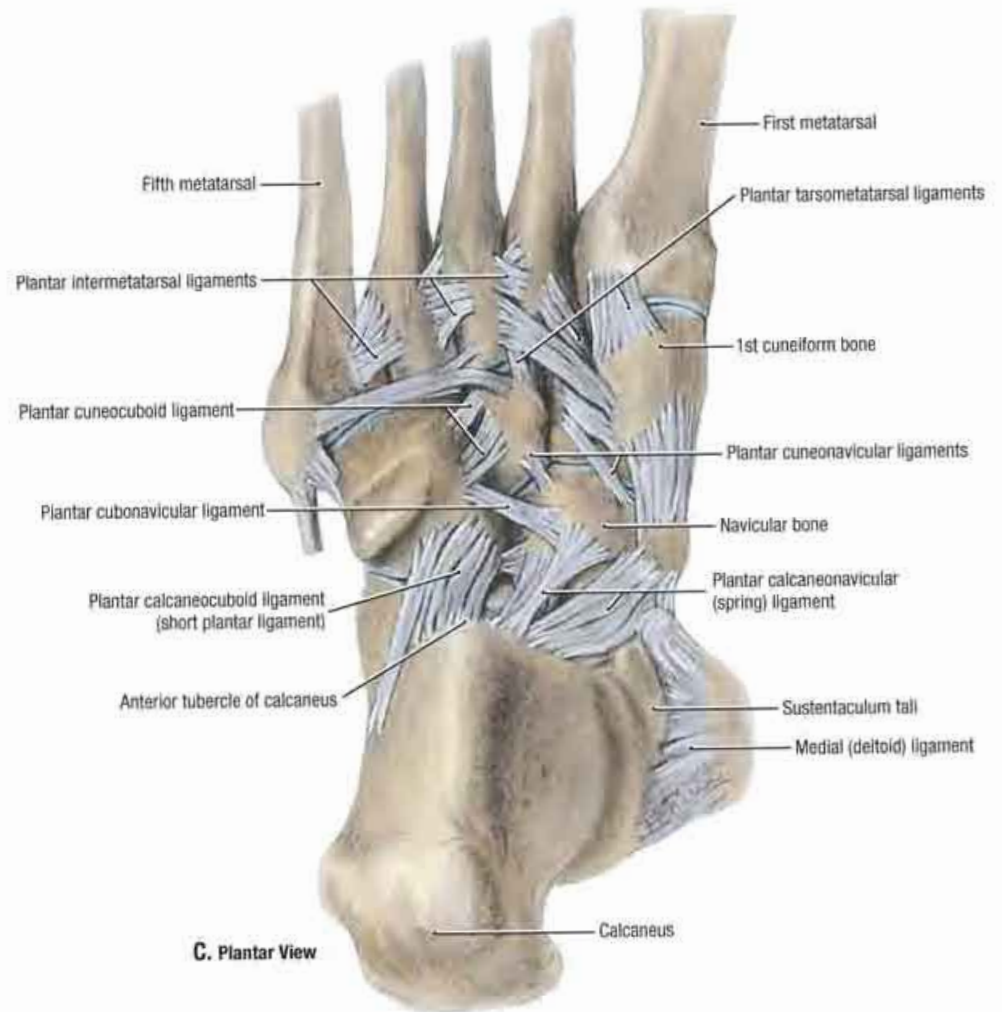
- The ligaments of the anterior foot diverge laterally and posteriorly from each side of the long axis of the third metatarsal and third cuneiform; hence a posterior thrust received by the first metatarsal, as when rising on the big toe while in walking, is transmitted directly to the navicular and talus by the first cuneiform and indirectly by the second metatarsal, second cuneiform, third metatarsal, and third cuneiform.
- A posterior thrust received by the fourth and fifth metatarsals is transmitted directly to the cuboid and calcaneus.

P.466

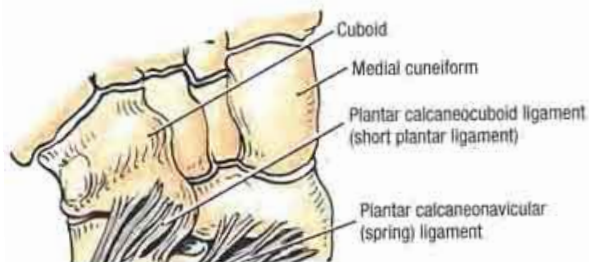


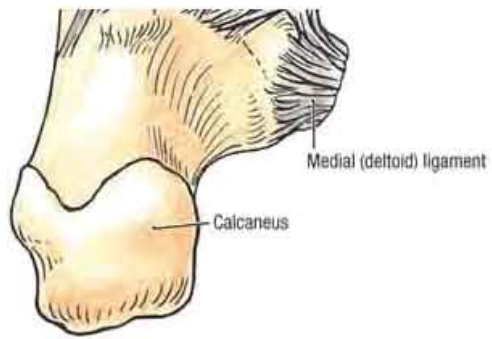


**B. Plantar View**



**C. Plantar View**





**D. Plantar View**

Authors: Agur, Anne M.R.; Dalley, Arthur F.

Title: *Grant's Atlas of Anatomy, 12th Edition*

Copyright ©2009 Lippincott Williams & Wilkins

> Table of Contents > Chapter 5 - Lower Limb > 5.87 Arches of foot

---

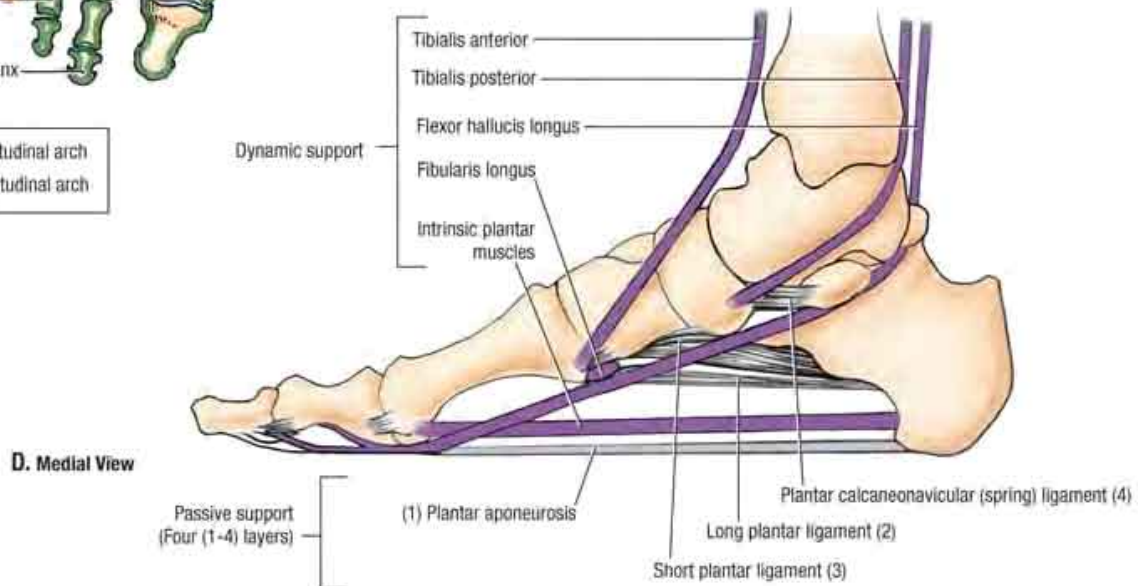
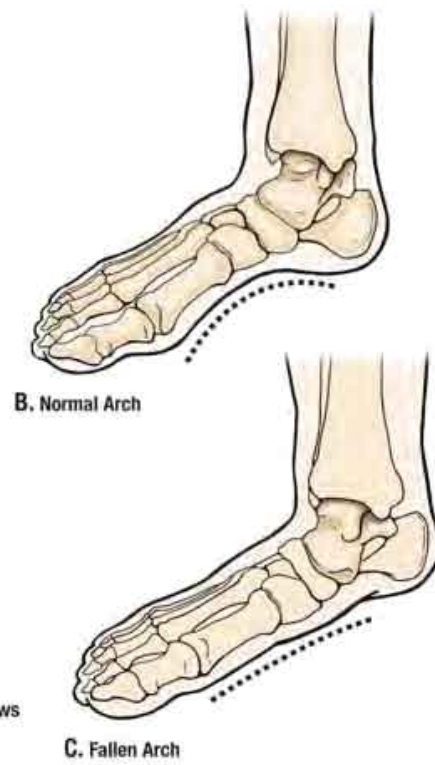
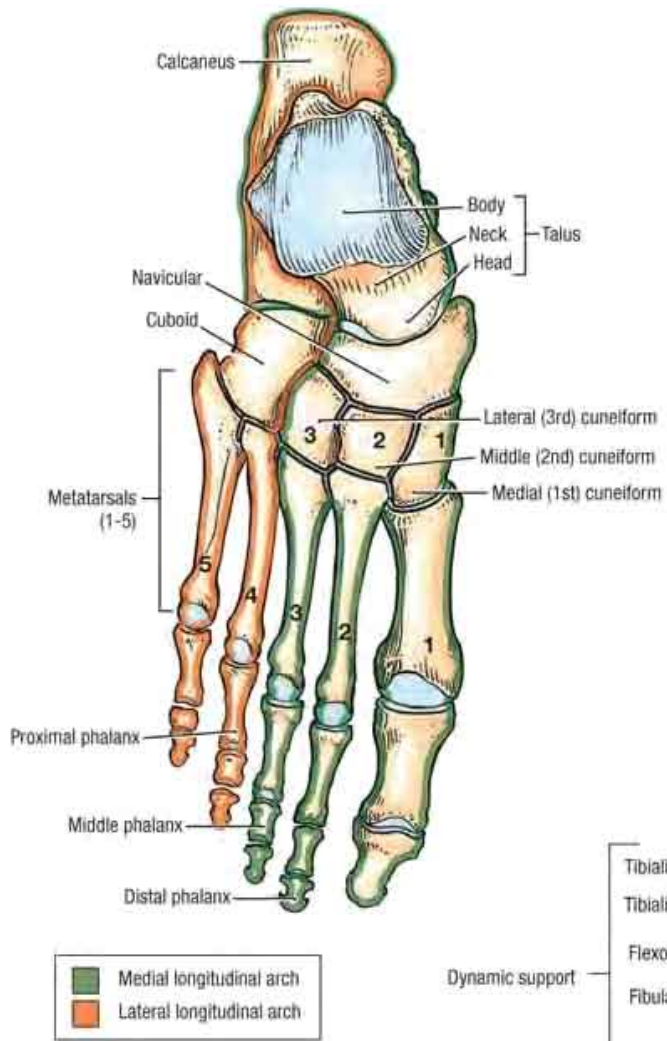
## 5.87 Arches of foot

*Part of* "Chapter 5 - Lower Limb "

A. Medial and lateral longitudinal arches. B. Normal arch. C. Fallen arch. D. Supports of the longitudinal arches.

---

P.467





Authors: Agur, Anne M.R.; Dalley, Arthur F.

Title: *Grant's Atlas of Anatomy, 12th Edition*

Copyright ©2009 Lippincott Williams & Wilkins

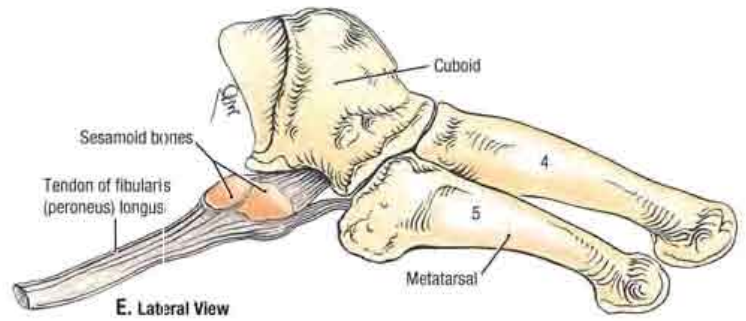
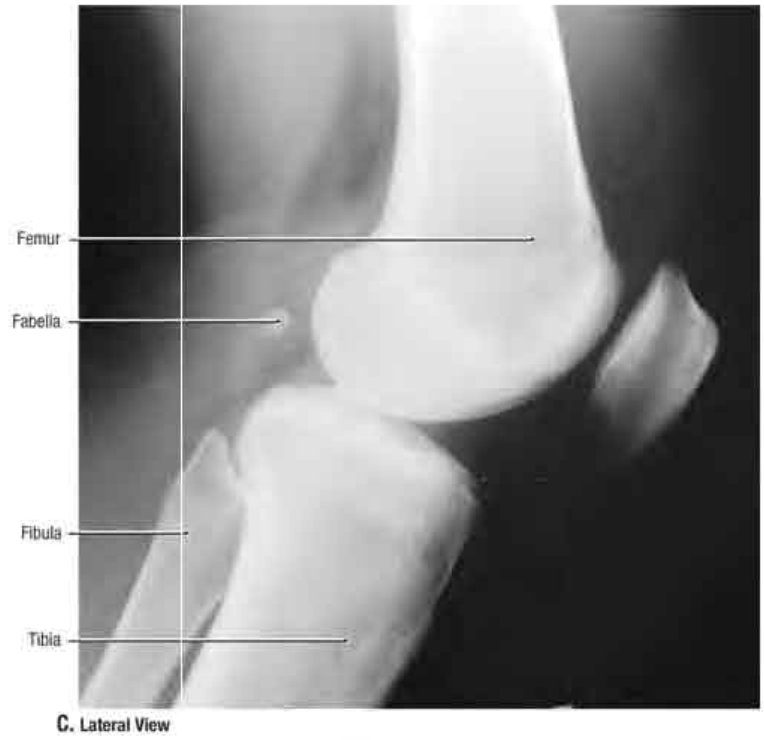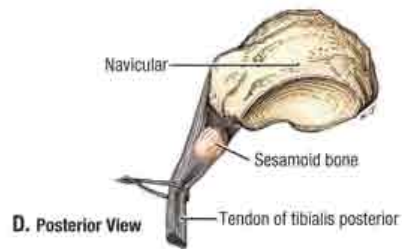
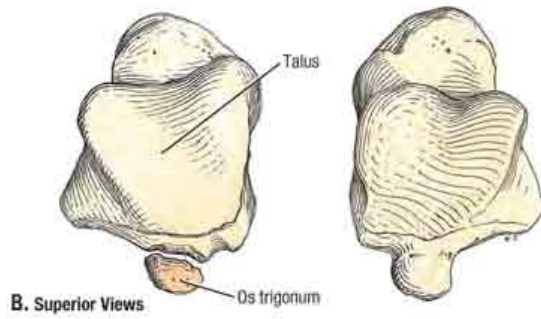
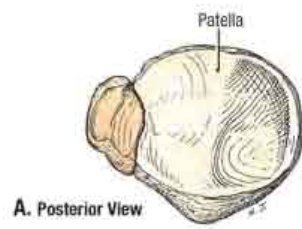
> Table of Contents > Chapter 5 - Lower Limb > 5.88 Bony anomalies

---

## 5.88 Bony anomalies

*Part of "Chapter 5 - Lower Limb "*

A. Bipartite patella. Occasionally, the superolateral angle of the patella ossifies independently and remains discrete. B. Os trigonum. The lateral (posterior) tubercle of the talus has a separate center of ossification that appears from the ages of 7 to 13 years; when this fails to fuse with the body of the talus, as in the left bone of this pair, it is called an *os trigonum*. It was found in 7.7% of 558 adult feet; 22 were paired, and 21 were unpaired. C. Fabella. A sesamoid bone in the lateral head of the gastrocnemius muscle was present in 21.6% of 116 limbs. D. Sesamoid bone in the tendon of tibialis posterior. A sesamoid bone was found in 23% of 348 adults. E. Sesamoid bone in the tendon of fibularis (peroneus) longus. A sesamoid bone was found in 26% of 92 feet. In this specimen, it is bipartite, and the fibularis (peroneus) longus muscle has an additional attachment to the 5th metatarsal bone.



Authors: Agur, Anne M.R.; Dalley, Arthur F.

Title: *Grant's Atlas of Anatomy, 12th Edition*

Copyright ©2009 Lippincott Williams & Wilkins

> Table of Contents > Chapter 5 - Lower Limb > 5.89 Postnatal lower limb development

---

## 5.89 Postnatal lower limb development

*Part of* "Chapter 5 - Lower Limb "

A. Bones of lower limb at birth. The hip bone can be divided into three primary parts: ilium, ischium, and pubis. The diaphyses (bodies) of the long bones are well ossified. Some epiphyses (growth plates) and tarsal bones have begun to ossify, including the distal epiphysis of the femur, proximal epiphysis of the tibia, calcaneus, talus, and cuboid. B and D. Anteroposterior radiographs of postmortem specimens of newborns show the bony (*white*) and cartilaginous (*gray*) components of the femur and hip bone. C. Epiphyses at proximal end of femur. The epiphysis of the head of the femur begins to ossify during the 1st year, that of the greater trochanter before the 5th year, and that of the lesser trochanter before the 14th year. These usually fuse completely with the body (shaft) before the end of the 18th year.

---

P.469

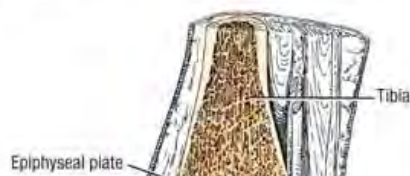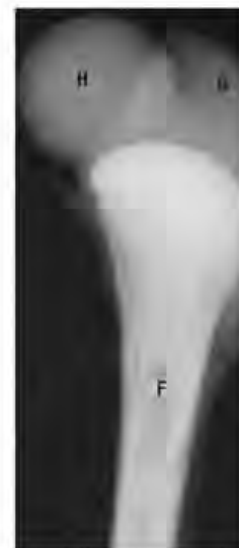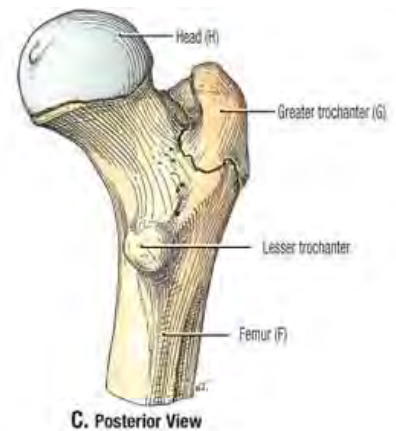
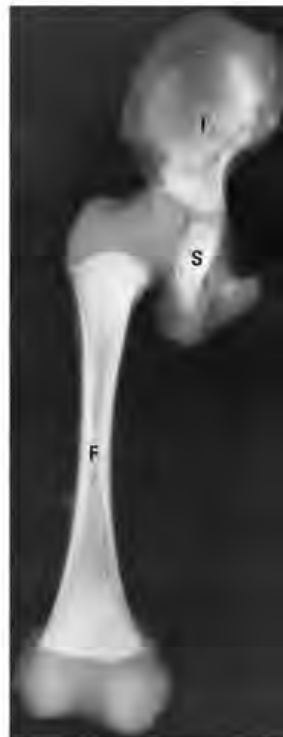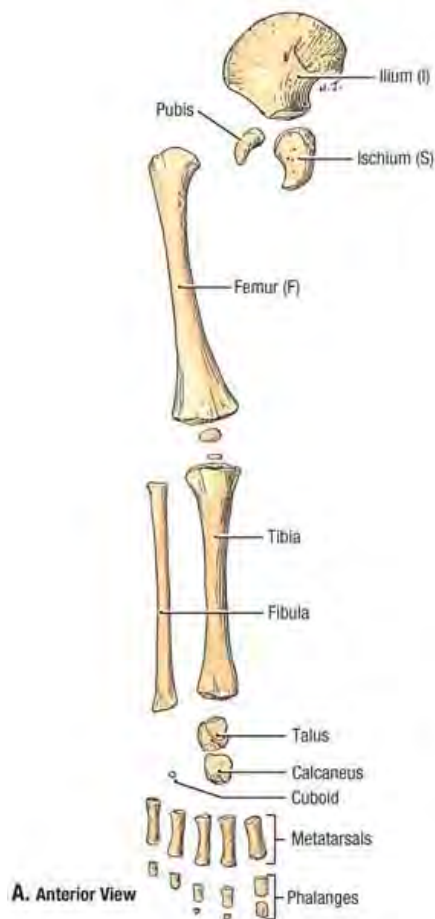
E. Foot of child age 4. F. Foot of child age 10.

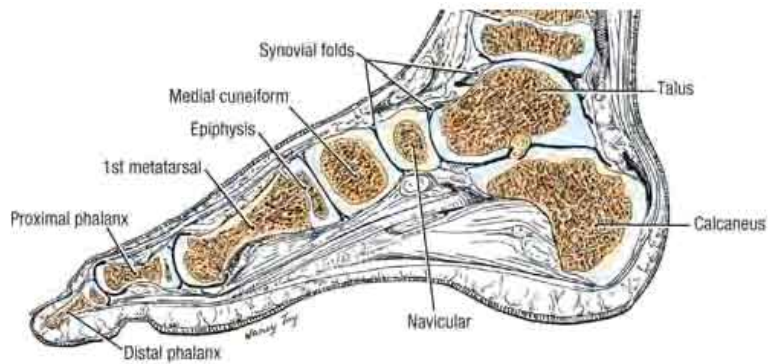
- In the foot of the younger child (E) , epiphyses of long bones (tibia, metatarsals, and phalanges) ossify like short bones, with the ossification centers being enveloped in cartilage. Ossification has already extended to the surface of the larger tarsal bones.
- In the foot of the older child (F) , ossification has spread to the dorsal and plantar surfaces of all tarsal bones in view, and cartilage persists on the articular surfaces only.
- The traction epiphysis of the calcaneus for the calcaneal tendon and plantar

aponeurosis begins to ossify from the ages of 6 to 10 years.

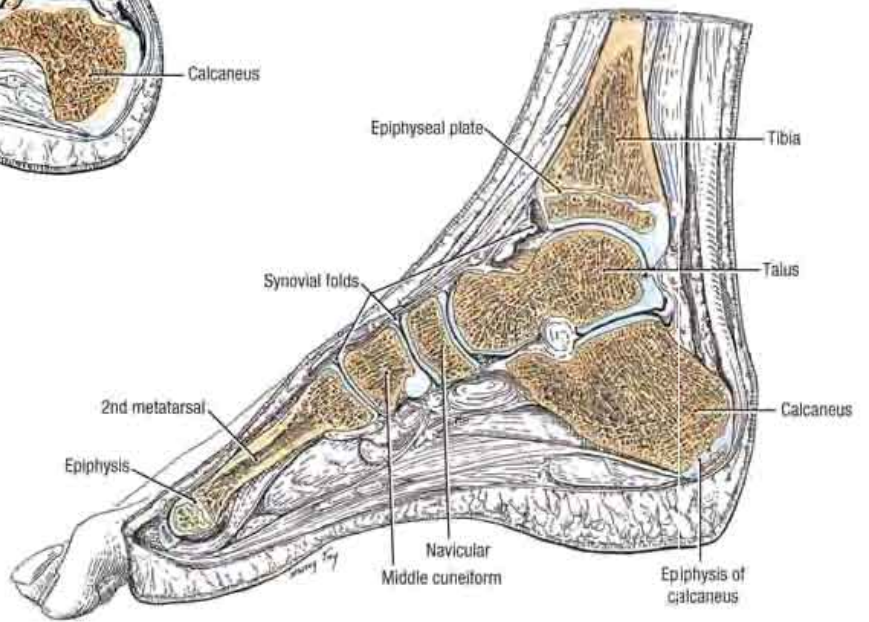
- The first metatarsal bone is similar to a phalanx in that its epiphysis is at the base instead of the head, as in the second and other metatarsal bones.
- The tuberosity of the calcaneus and the sesamoid bones of the first and the heads of the second to fifth metatarsals (here the second) support the longitudinal arch of the foot; the medial part of the longitudinal arch is higher and more mobile than the lateral.

P.470





**E. Sagittal Section**



**F. Sagittal Section**



## 5.90 Transverse sections and MRIs of thigh

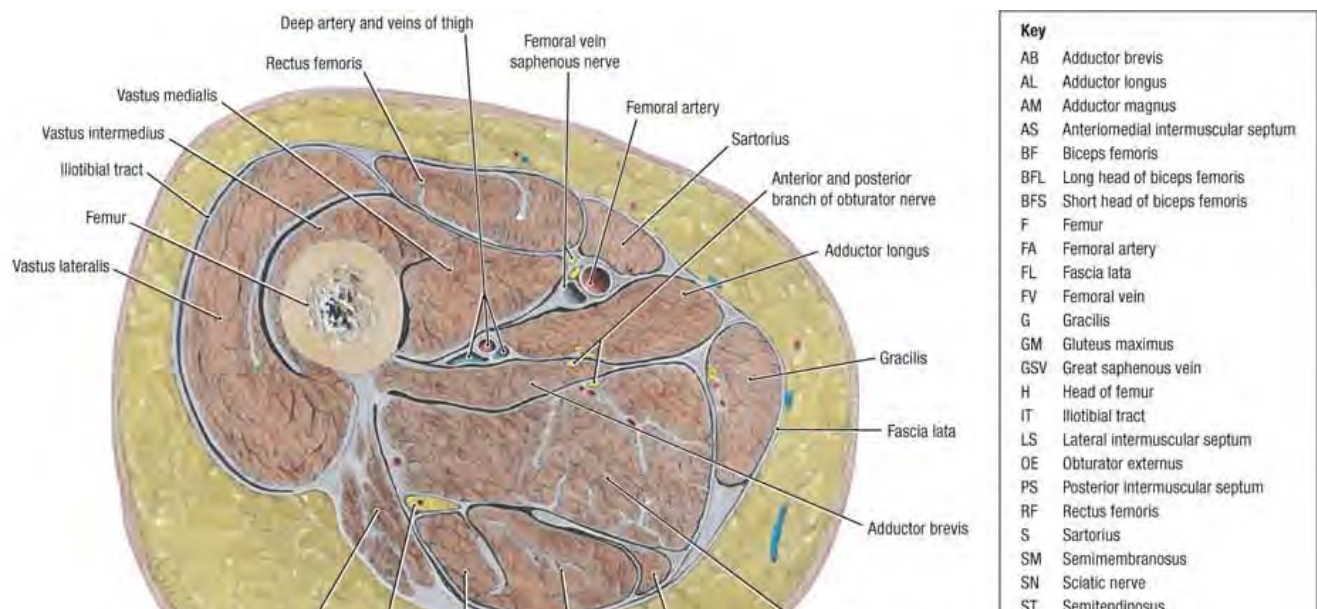
Part of "Chapter 5 - Lower Limb "

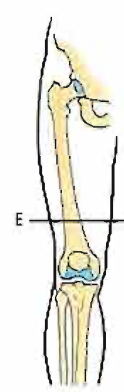
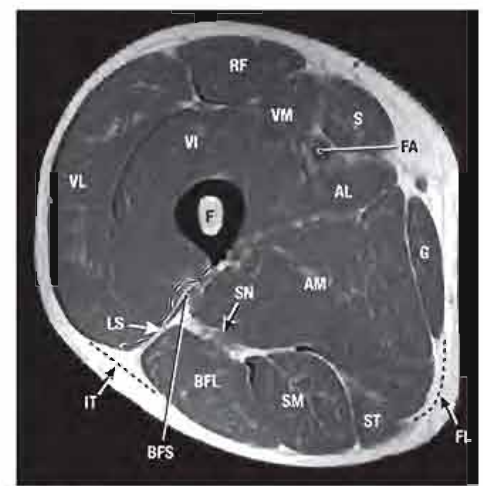
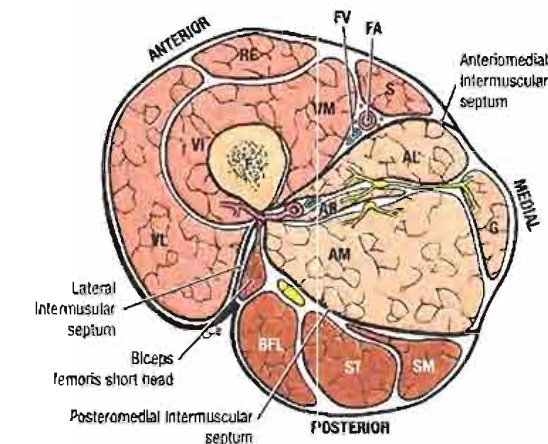
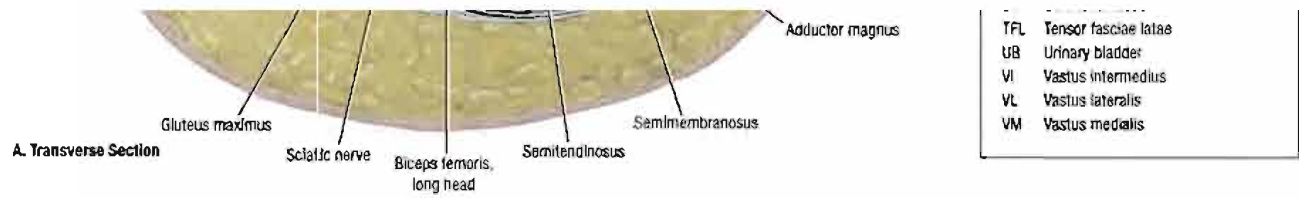
A. Anatomical section. B. Compartments of thigh. C. T1 transverse (axial) MRIs. The thigh has three compartments, each with its own nerve supply and primary function: anterior group extends the knee and is supplied by the femoral nerve; medial group adducts the hip and is supplied by the obturator nerve; posterior group flexes the knee and is supplied by the sciatic nerve.

P.471

D and E. T1 transverse MRIs. F. T1 coronal MRI. G. Transverse sections of femur. Note the differences in thickness of the compact and spongy bone and in the width of the medullary (marrow) cavity.

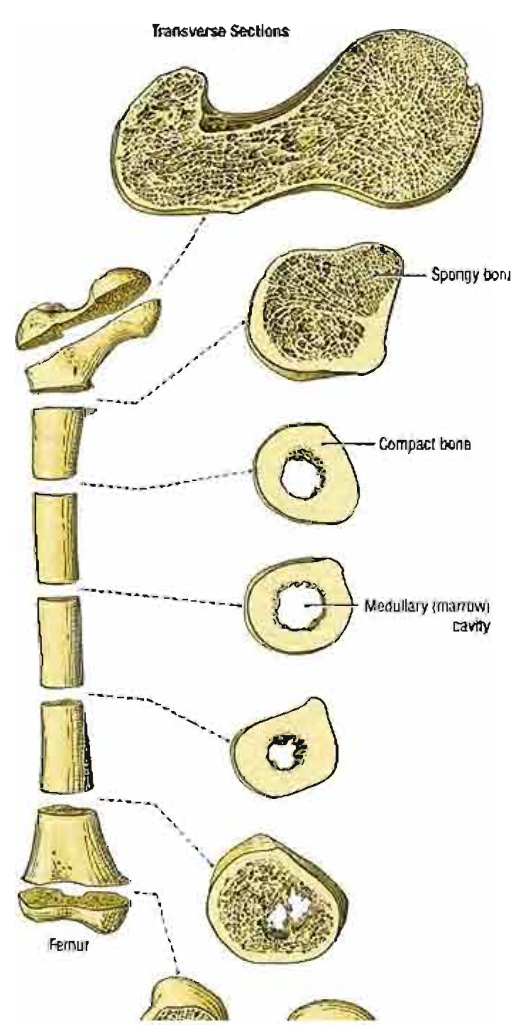
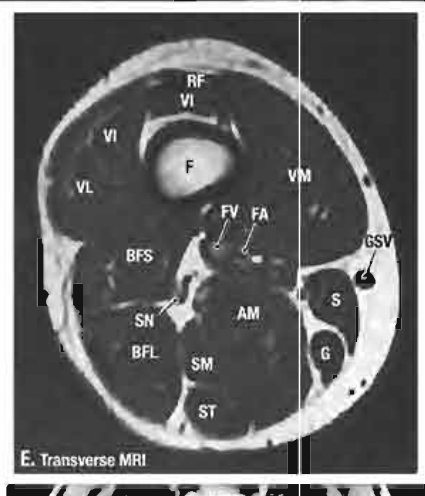
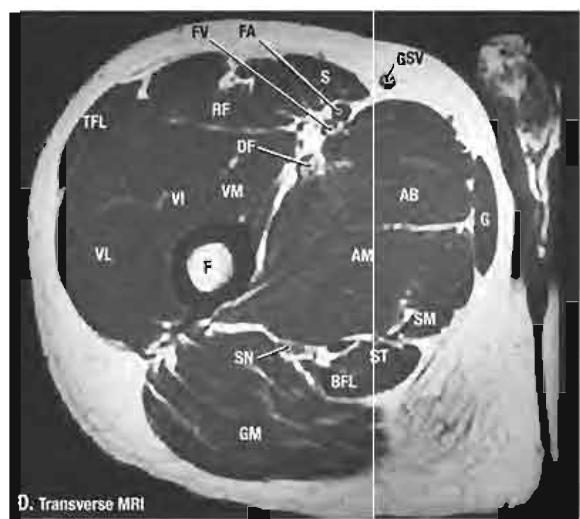
P.472

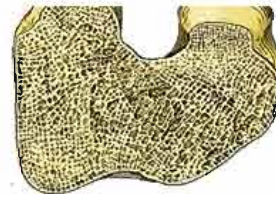
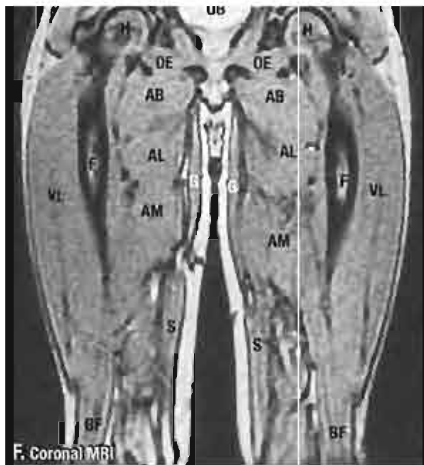




**B. Transverse Section**

**C. Transverse MRI**





G. Anterior View

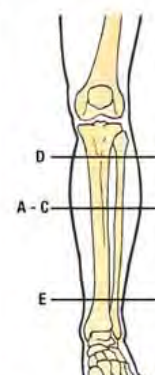
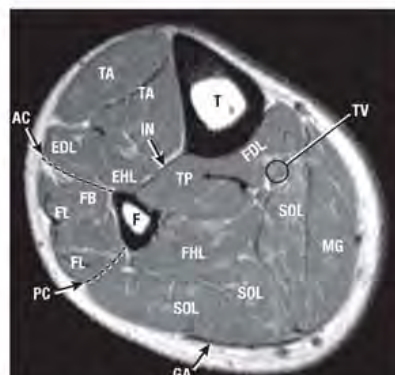
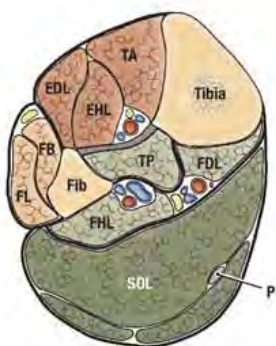
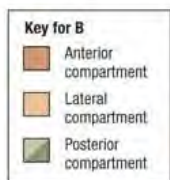
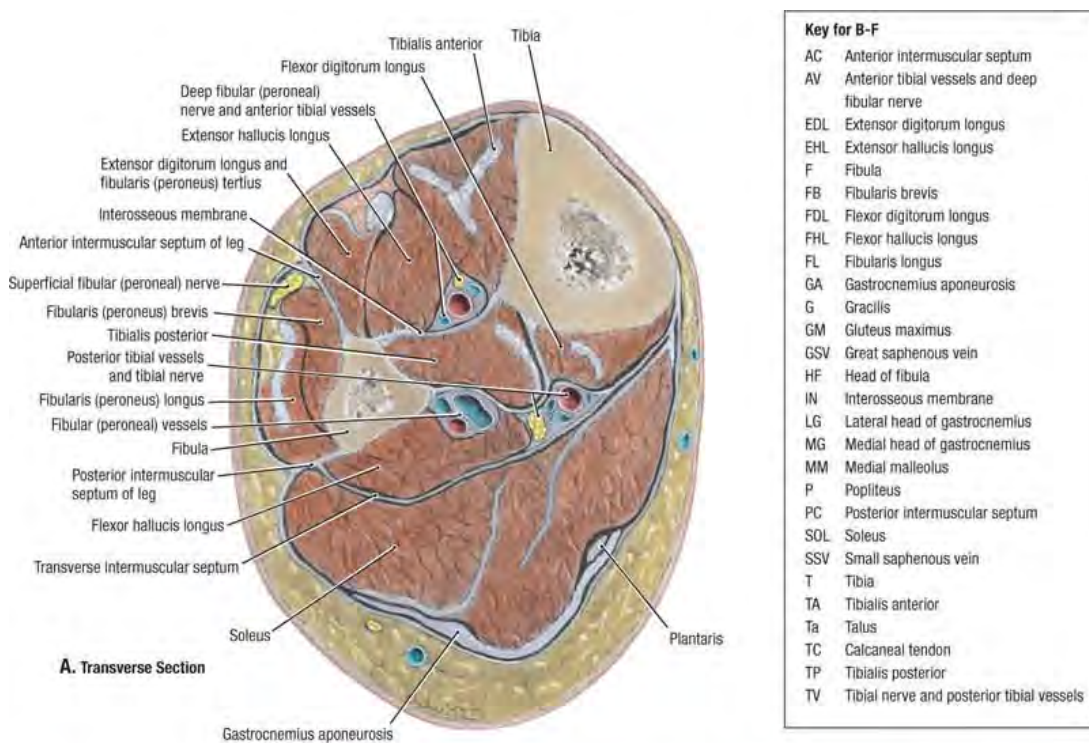


Authors: Agur, Anne M.R.; Dalley, Arthur F.  
 Title: *Grant's Atlas of Anatomy, 12th Edition*  
 Copyright ©2009 Lippincott Williams & Wilkins

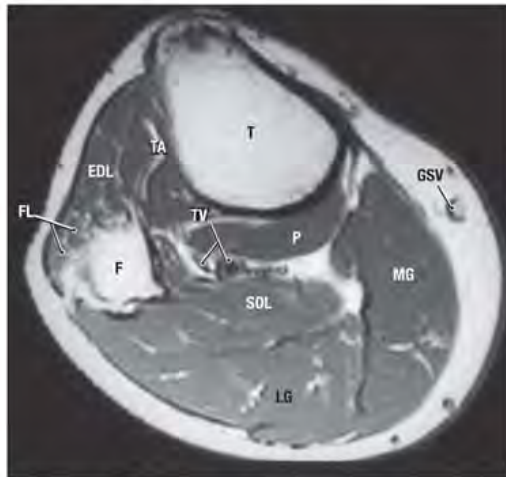> Table of Contents > Chapter 5 - Lower Limb > 5.91 Transverse sections and MRI of leg

## 5.91 Transverse sections and MRI of leg

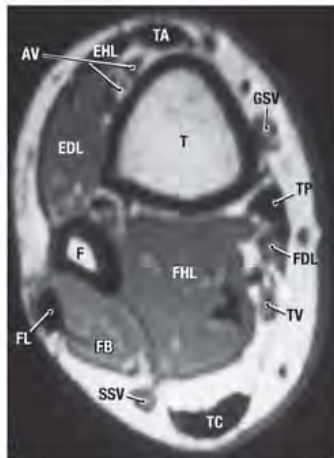Part of "Chapter 5 - Lower Limb "



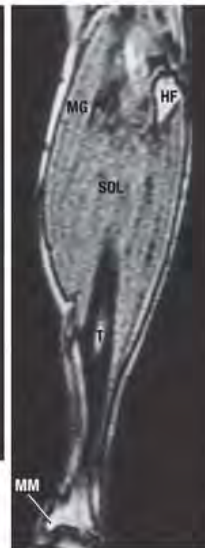B. Transverse Section



D. Transverse MRI

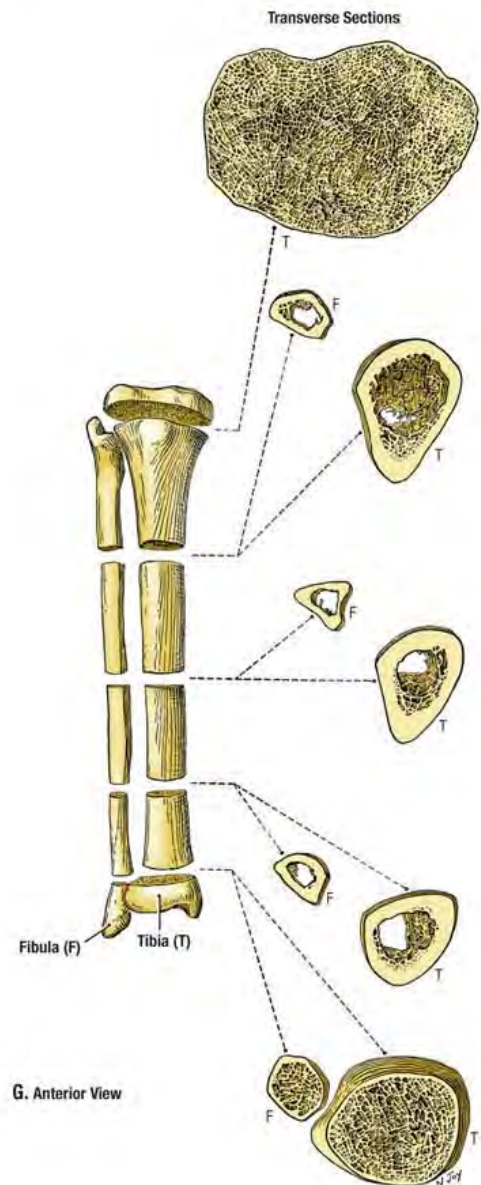


E. Transverse MRI



F. Coronal MRI

C. Transverse Section



G. Anterior View

A. Anatomical section. B. Compartments of leg. C. T1 transverse (axial) MRI. The anterior compartment is bounded by the tibia, interosseous membrane, fibula, anterior intermuscular septum, and crural fascia. The lateral compartment is bounded by the fibula, anterior and posterior intermuscular septa, and the crural fascia.

The posterior compartment is bounded by the tibia, interosseous membrane, fibula, posterior intermuscular septum, and crural fascia. This compartment is subdivided by the transverse intermuscular septum into superficial and deep subcompartments.



D and E. T1 transverse (axial) MRIs. F. T1 coronal MRI. G. Transverse sections of tibia and fibula.

Authors: Agur, Anne M.R.; Dalley, Arthur F.

Title: *Grant's Atlas of Anatomy, 12th Edition*

Copyright ©2009 Lippincott Williams & Wilkins

> Table of Contents > Chapter 6 - Upper Limb > Chapter 6 - Upper Limb

---

## Chapter 6

# Upper Limb

- 6.1 Regions, bones, and major joints of upper limb
- 6.2 Features of bones of upper limb
- 6.3 Overview of motor innervation of upper limb
- 6.4 Myotomes and myotatic (deep tendon stretch) reflexes
- 6.5 Dermatomes of upper limb
- 6.6 Cutaneous nerves of upper limb
- 6.7 Arteries and arterial anastomoses of upper limb
- 6.8 Overview of the deep veins of the upper limb
- 6.9 Superficial venous and lymphatic drainage of upper limb
- 6.10 Superficial venous drainage of upper limb
- 6.11 Deep fascia of upper limb—axillary and clavipectoral fascia
- 6.12 Deep fascia of upper limb—brachial and antebrachial fascia
- 6.13 Superficial dissection, male pectoral region
- 6.14 Surface anatomy, male pectoral region
- 6.15 Superficial dissection of trunk
- 6.16 Surface anatomy of anterolateral aspect of the trunk

- 6.17 Pectoralis major and minor and serratus anterior
- 6.18 Anterior wall of axilla and clavipectoral fascia
- 6.19 Veins of axilla
- 6.20 Walls and contents of the axilla
- 6.21 Transverse sections through the shoulder joint and axilla
- 6.22 Arteries of the proximal upper limb
- 6.23 Brachial plexus
- 6.24 Structures of axilla: Deep dissection I
- 6.25 Posterior and medial walls of axilla: Deep dissection II
- 6.26 Posterior wall of axilla, musculocutaneous nerve, and posterior cord: Deep dissection III
- 6.27 Serratus anterior and subscapularis
- 6.28 Surface anatomy of superficial back
- 6.29 Cutaneous nerves of superficial back and posterior axioappendicular muscles
- 6.30 Rotator cuff
- 6.31 Bones of proximal upper limb
- 6.32 Anterior and posterior compartments of arm
- 6.33 Muscles of anterior aspect of arm – I
- 6.33 Muscles of anterior aspect of arm – II
- 6.34 Lateral aspect of arm
- 6.35 Medial aspect of arm
- 6.36 Surface anatomy of the scapular region and posterior aspect of arm
- 6.37 Triceps brachii and related nerves
- 6.38 Dorsal scapular and subdeltoid regions

- 6.39 Suprascapular region
- 6.40 Pectoral girdle
- 6.41 Lateral aspect of subacromial bursa and acromioclavicular joint
- 6.42 Ligaments and articular capsule of glenohumeral (shoulder) joint
- 6.43 Interior of the glenohumeral (shoulder) joint and relationship of rotator cuff
- 6.44 Imaging of glenohumeral (shoulder) joint
- 6.45 Cubital fossa: Surface anatomy and superficial dissection
- 6.45 Cubital fossa: Deep dissection I
- 6.45 Cubital fossa: Deep dissection II
- 6.46 Anomalies
- 6.47 Posterior aspect of elbow – I
- 6.48 Posterior aspect of elbow – II
- 6.49 Bones and imaging of elbow region
- 6.50 Supination and pronation at superior, middle, and inferior radio-ulnar joints
- 6.51 Medial aspect of bones and ligaments of elbow region
- 6.52 Lateral aspect of bones and ligaments of elbow region
- 6.53 Synovial capsule of elbow joint and anular ligament
- 6.54 Articular surfaces of elbow joint
- 6.55 Arteries of forearm and ligaments of radioulnar joints
- 6.56 Bones and muscle attachments of forearm and hand
- 6.57 Superficial muscles of the forearm and palmar aponeurosis
- 6.58 Flexor digitorum superficialis and related structures
- 6.59 Deep flexors of the digits and related structures

- 6.60 Deep flexors of the digits and supinator
- 6.61 Structures of anterior aspect of wrist
- 6.62 Surface anatomy of skeleton of hand and wrist
- 6.63 Palmar (deep) fascia: palmar aponeurosis, thenar and hypothenar fascia
- 6.64 Compartments, spaces, and fascia of the palm
- 6.65 Attachments of palmar aponeurosis, digital vessels, and nerves
- 6.66 Muscular layers of palm
- 6.67 Superficial dissection of palm, ulnar, and median nerves
- 6.68 Synovial sheaths of palm of hand
- 6.69 Digital tendons, vessels, and nerves
- 6.70 Deep dissection of palm
- 6.71 Deep dissection of palm and digits with deep branch of ulnar nerve
- 6.72 Arterial supply of hand
- Table 6.13 Muscles on posterior surface of forearm
- 6.73 Superficial muscles of extensor region of forearm
- 6.74 Deep structures on extensor aspect of forearm
- 6.75 Cutaneous innervation of hand
- 6.76 Dorsum of hand
- 6.77 Extensor (dorsal) expansion of 3rd digit
- 6.78 Lateral aspect of wrist and hand
- 6.79 Medial aspect of wrist and hand
- 6.80 Bones of hand
- 6.81 Imaging of bones of wrist and hand
- 6.82 Coronal section of wrist



- 6.83 Ligaments of distal radio-ulnar, radiocarpal, and intercarpal joints
- 6.84 Radiocarpal (wrist) joint
- 6.85 Articular surfaces of midcarpal (transverse carpal) joint, opened anteriorly
- 6.86 Carpal bones and bases of metacarpals
- 6.87 Collateral ligaments of metacarpophalangeal and interphalangeal joints of third digit
- 6.88 Grasp, pinch, and movements of the thumb
- 6.89 Ossification and sites of epiphyses of bones of upper limb
- 6.90 Transverse section and transverse (axial) MRIs of the arm
- 6.91 Transverse sections and transverse (axial) MRIs of forearm
- 6.92 Transverse (axial) section and MRIs through carpal tunnel
- 6.93 Transverse section and MRI through palm (metacarpals) at level of adductor pollicis

Authors: Agur, Anne M.R.; Dalley, Arthur F.

Title: *Grant's Atlas of Anatomy, 12th Edition*

Copyright ©2009 Lippincott Williams & Wilkins

> Table of Contents > Chapter 6 - Upper Limb > 6.1 Regions, bones, and major joints of upper limb

---

## 6.1 Regions, bones, and major joints of upper limb

*Part of* "Chapter 6 - Upper Limb "

The joints divide the upper limb into four main regions: the shoulder, arm, forearm, and hand.

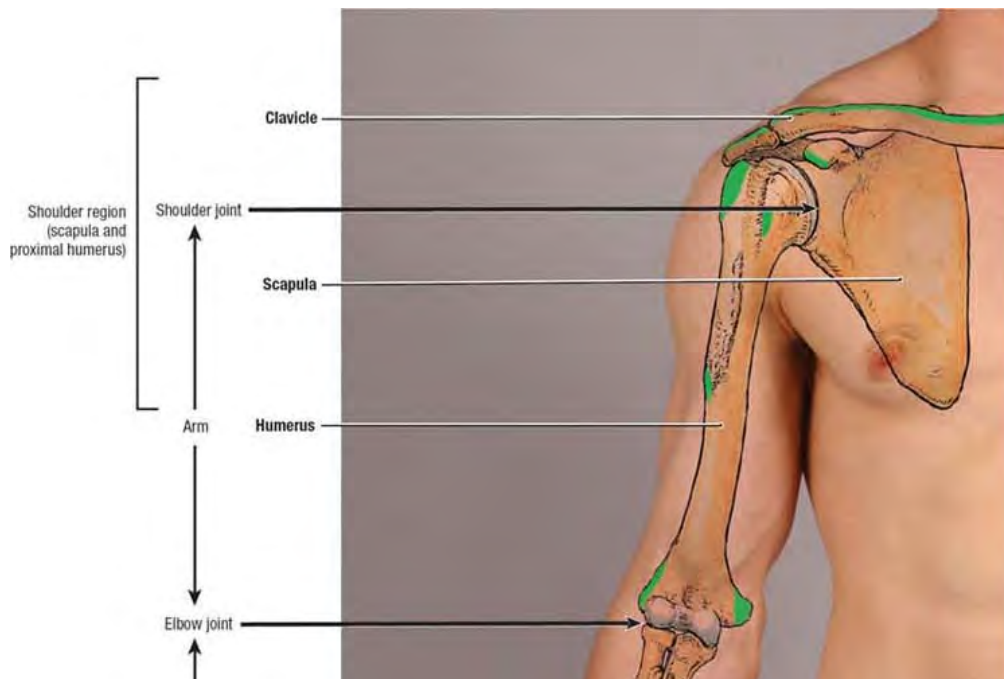
---

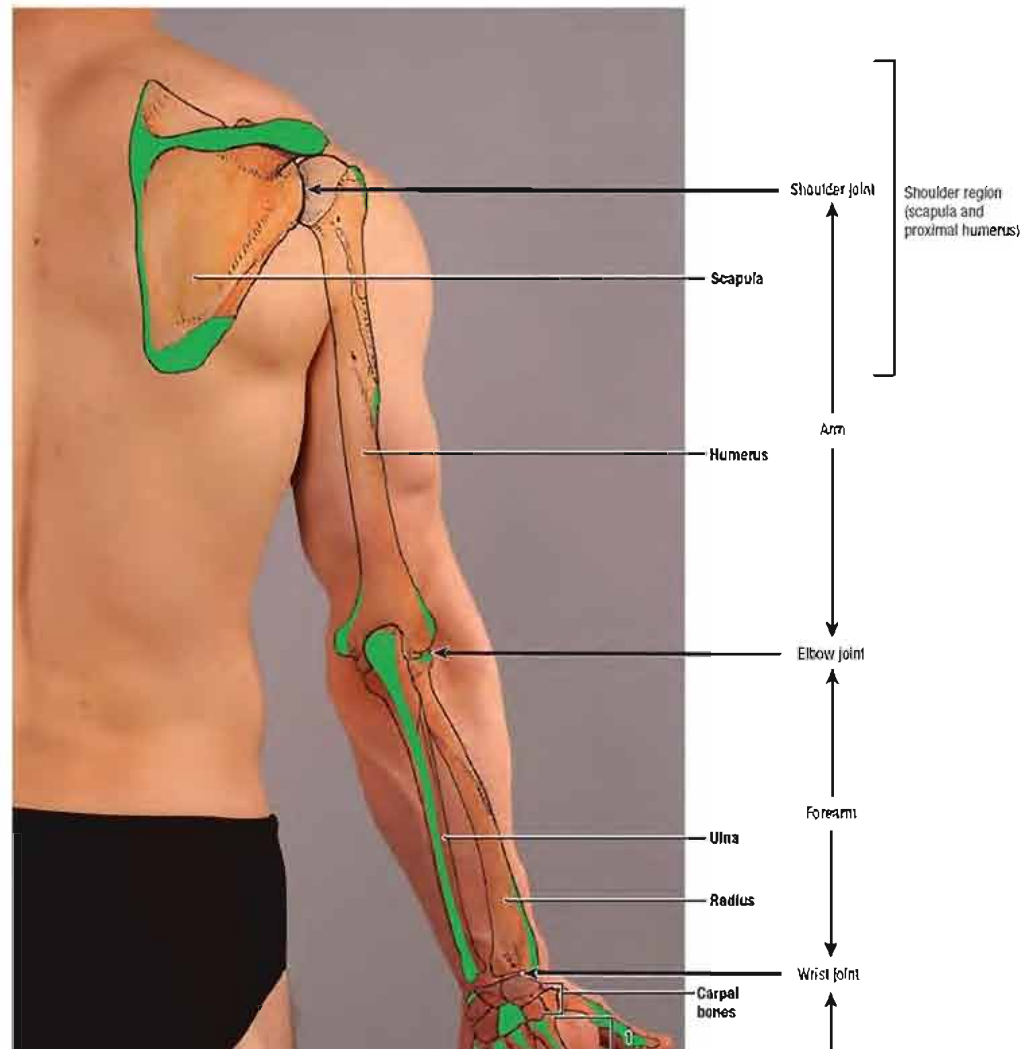
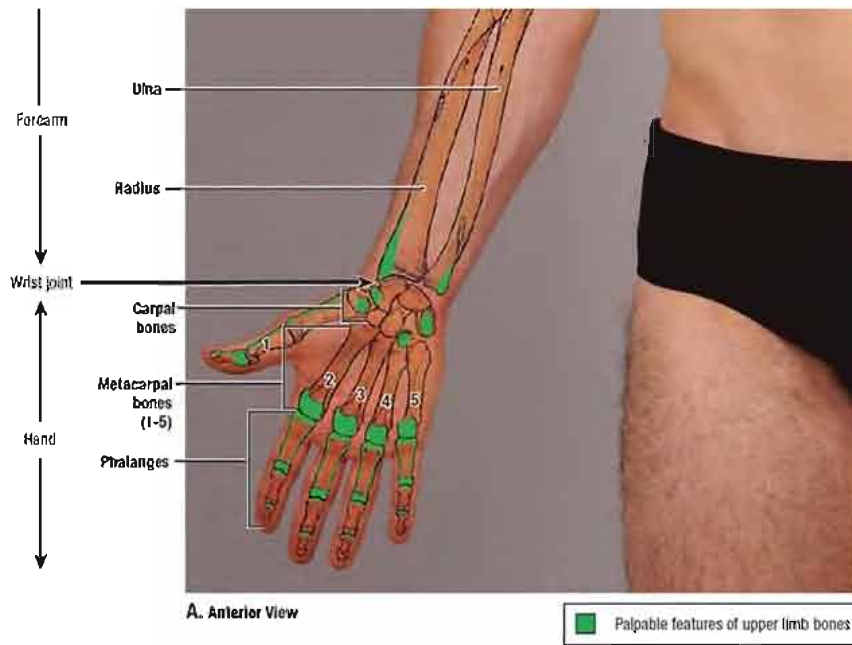
P.477


The pectoral (shoulder) girdle is an incomplete ring of bones formed by the right and left scapulae and clavicles and is joined medially to the manubrium of the sternum.

---

P.478







Authors: Agur, Anne M.R.; Dalley, Arthur F.  
 Title: *Grant's Atlas of Anatomy, 12th Edition*  
 Copyright ©2009 Lippincott Williams & Wilkins

> Table of Contents > Chapter 6 - Upper Limb > 6.2 Features of bones of upper limb

## 6.2 Features of bones of upper limb

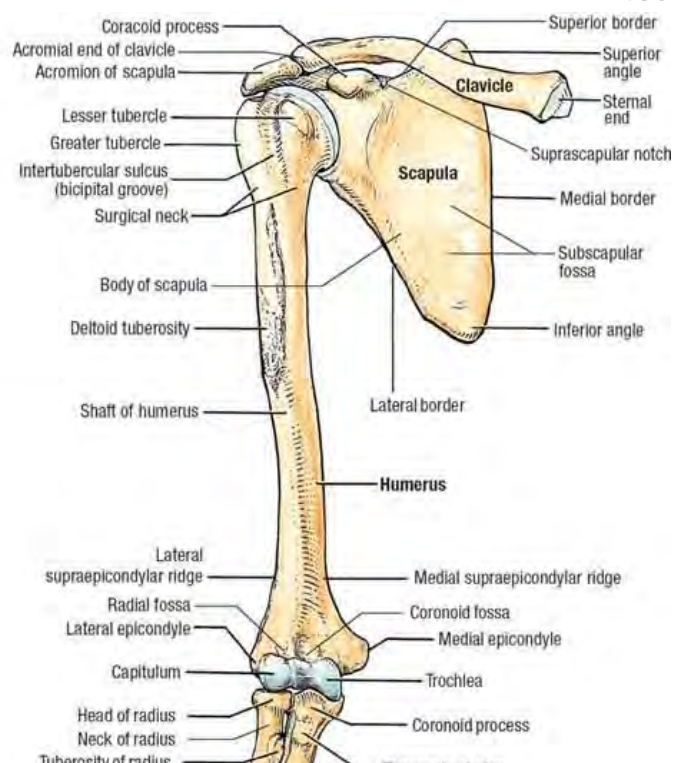
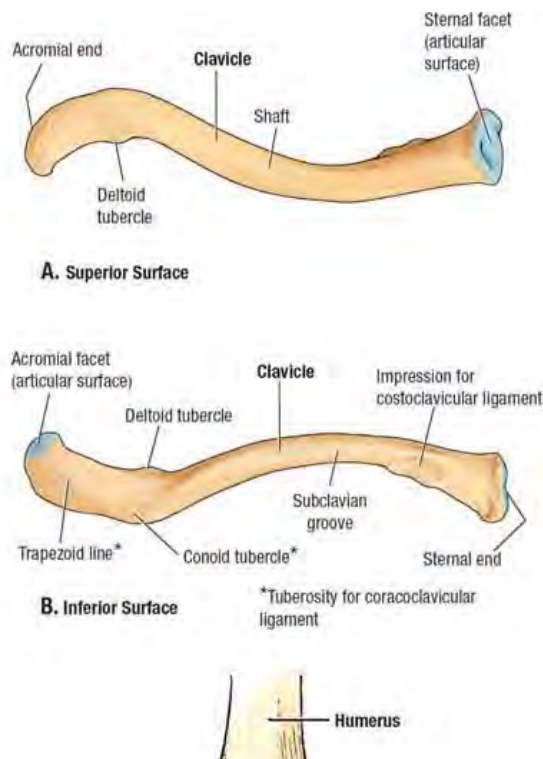
Part of "Chapter 6 - Upper Limb "

A and B. Clavicle. C. Anterior aspect of disarticulated distal end of humerus and proximal end of radius and ulna. D. Anterior aspect of articulated upper limb.

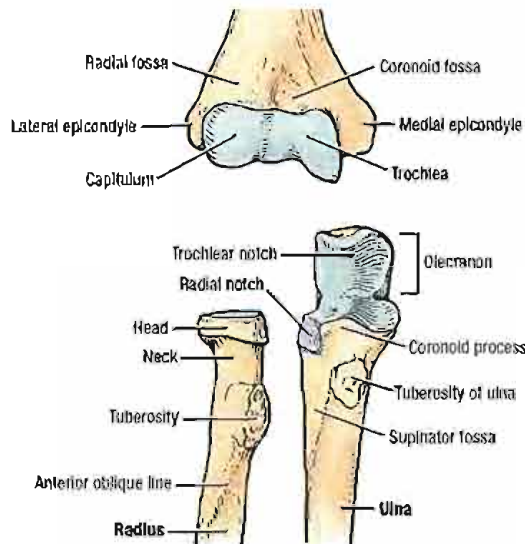
P.479

E. Posterior aspect of articulated upper limb bones. F. Lateral aspect of scapula. G. Posterior aspect of disarticulated distal end of humerus and proximal ends of radius and ulna.

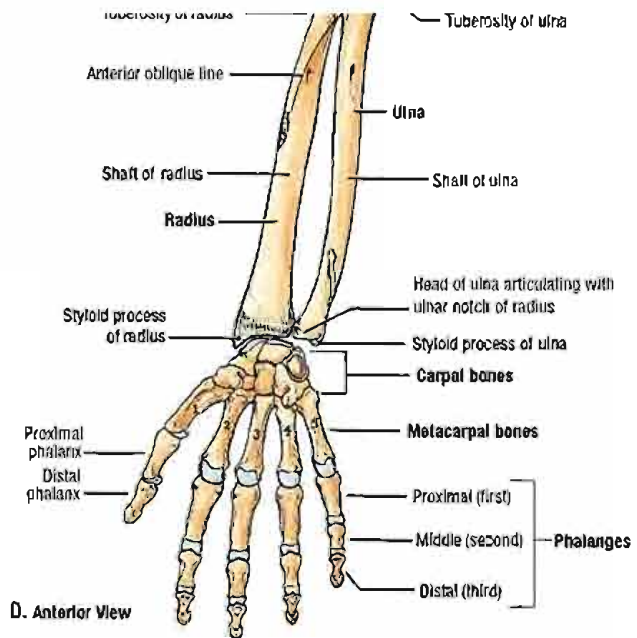
P.480



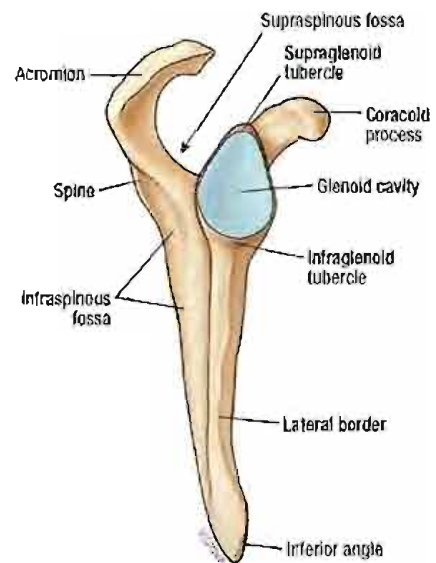
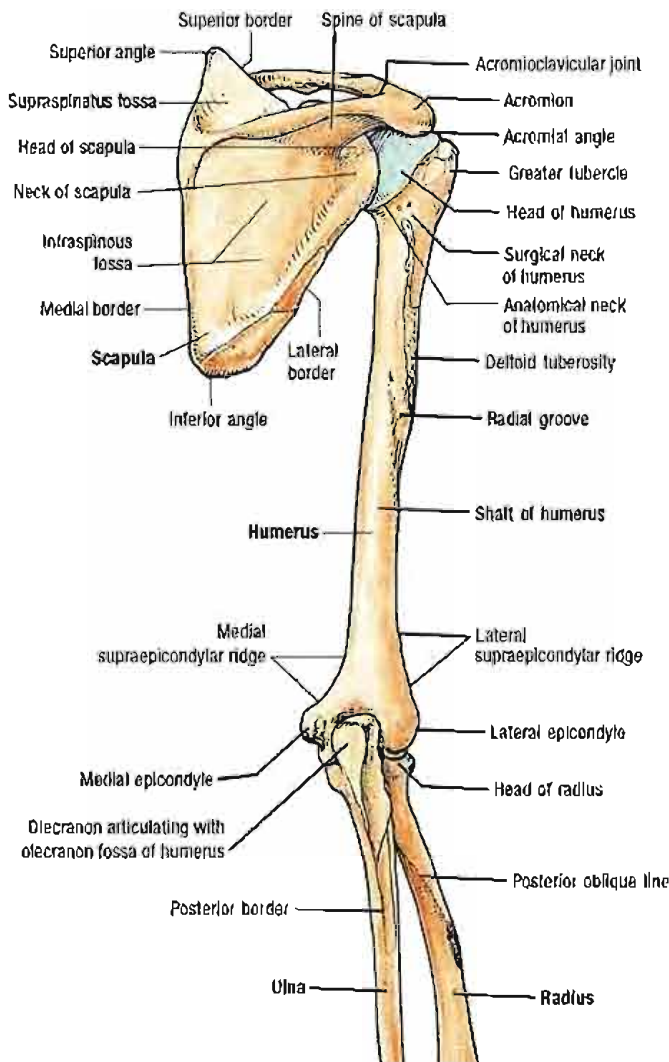




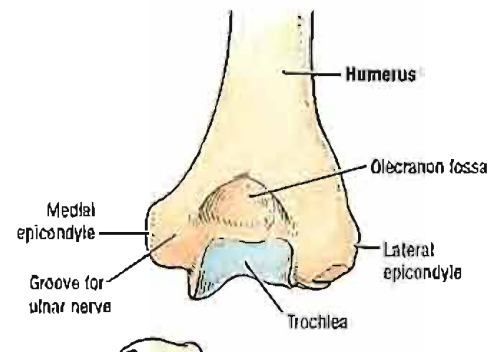C. Anterior View

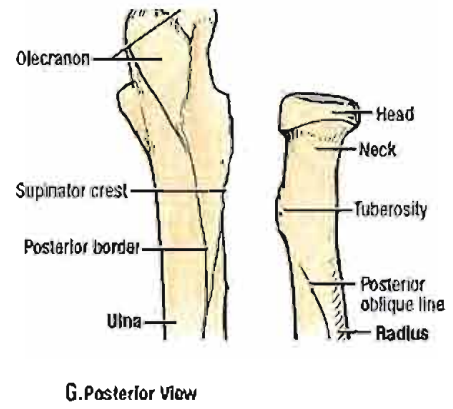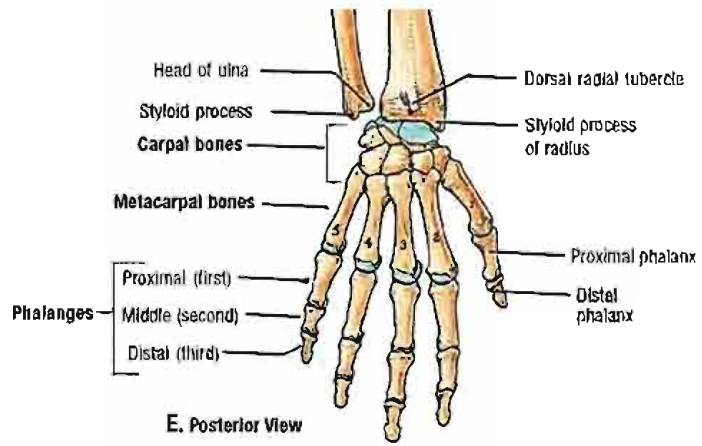


D. Anterior View



F. Lateral View





Authors: Agur, Anne M.R.; Dalley, Arthur F.

Title: *Grant's Atlas of Anatomy, 12th Edition*

Copyright ©2009 Lippincott Williams & Wilkins

> Table of Contents > Chapter 6 - Upper Limb > 6.3 Overview of motor innervation of upper limb

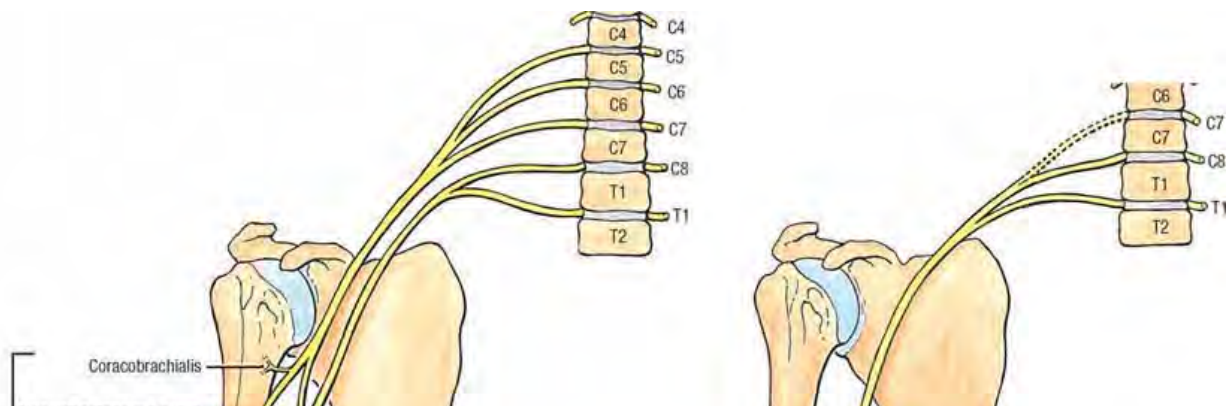
## 6.3 Overview of motor innervation of upper limb

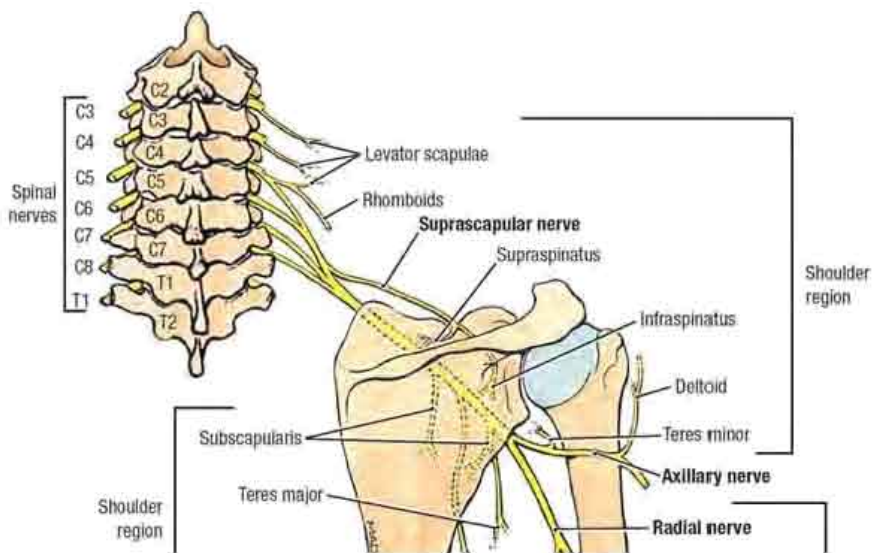
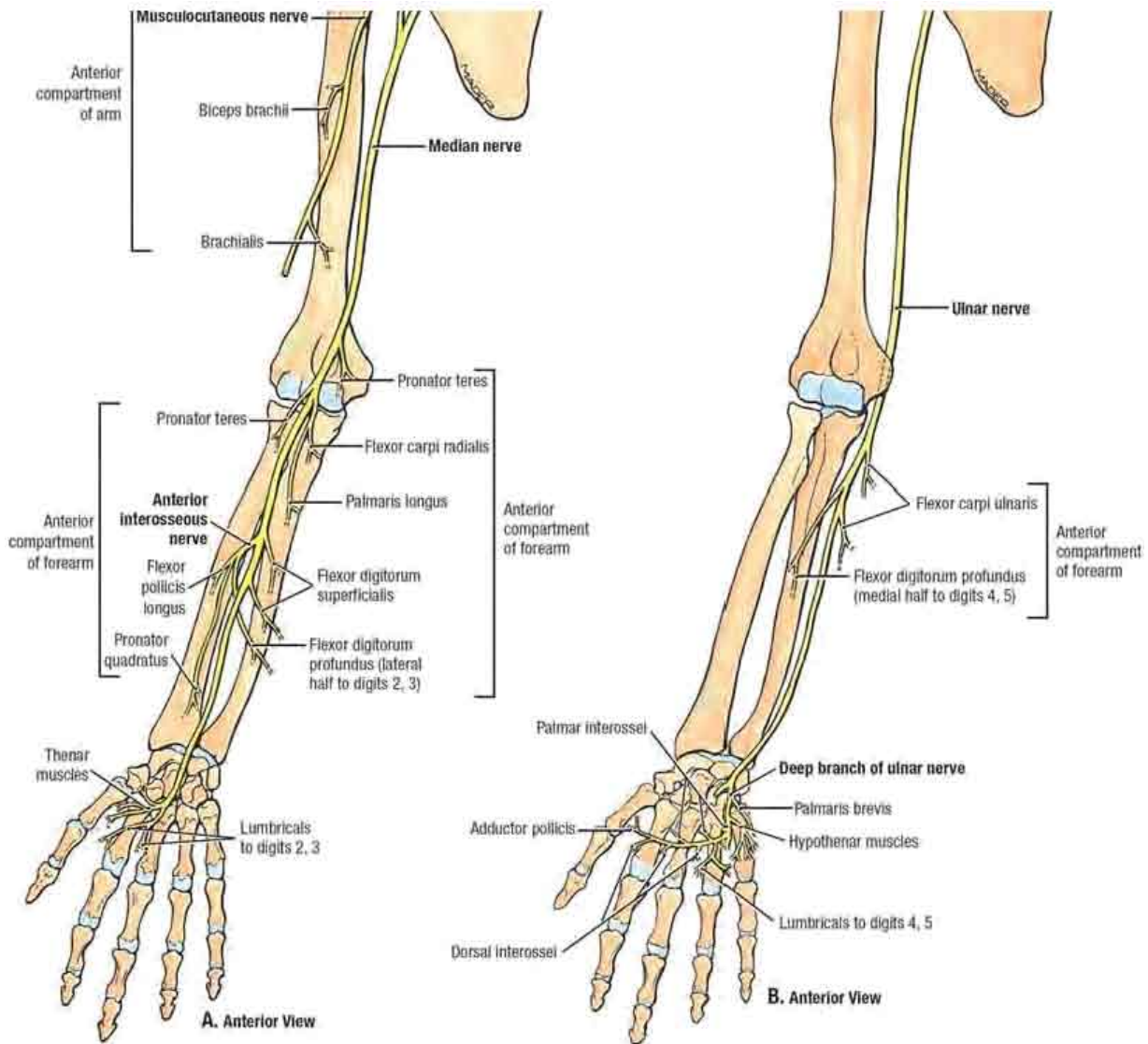
Part of "Chapter 6 - Upper Limb "

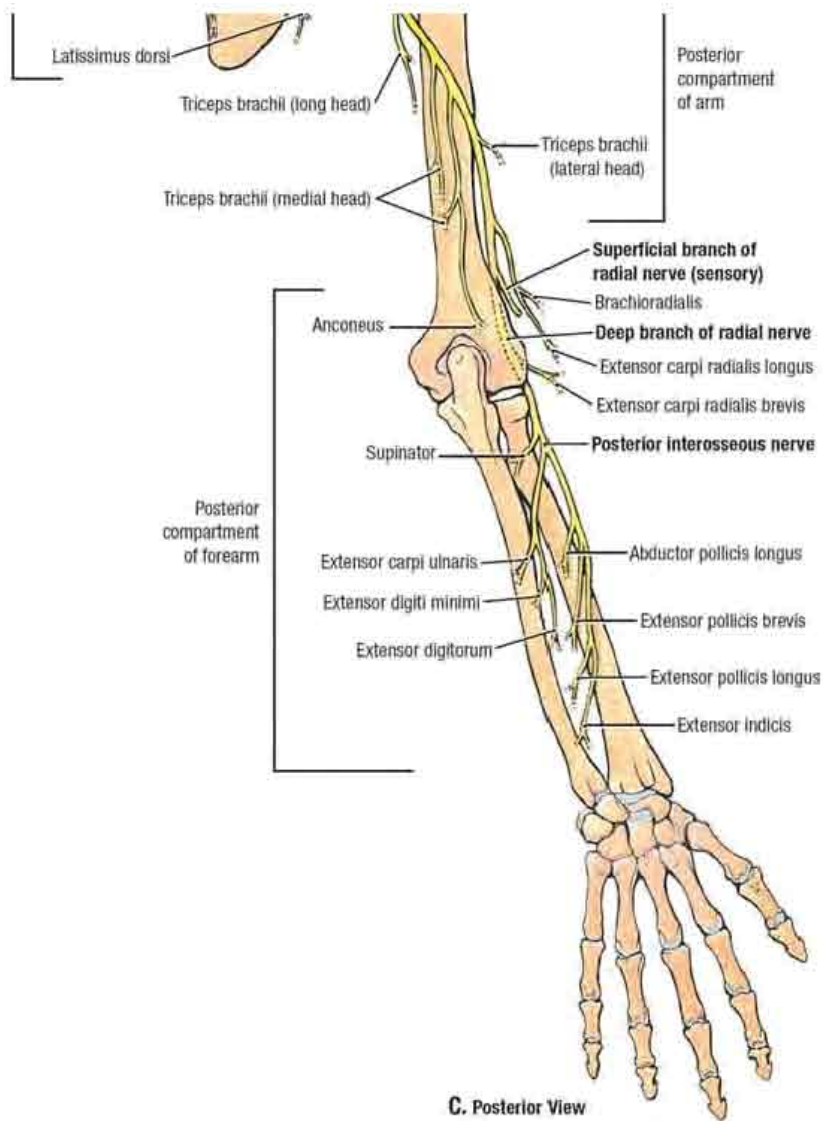
P.481

A. Musculocutaneous and median nerves. The musculocutaneous nerve innervates all the muscles of the anterior compartment of the arm. The median nerve innervates muscles of the anterior compartment of the forearm (with 11 exceptions that are innervated by the ulnar nerve), the lumbricals to digits 2 and 3, and the intrinsic muscles of the thumb (thenar muscles) with 11 exceptions that are innervated by the ulnar nerve. B. Ulnar nerve. The ulnar nerve innervates the flexor carpi ulnaris and ulnar half of the flexor digitorum profundus in the forearm, the hypothenar and interosseus muscles of the hand, the lumbricals to digits 3 and 4, and 11 exceptions thenar muscles (adductor pollicis and the deep head of the flexor pollicis brevis). C. Radial nerve. The radial nerve innervates all muscles of the posterior compartments of the arm and forearm.

P.482









Authors: Agur, Anne M.R.; Dalley, Arthur F.

Title: *Grant's Atlas of Anatomy, 12th Edition*

Copyright ©2009 Lippincott Williams & Wilkins

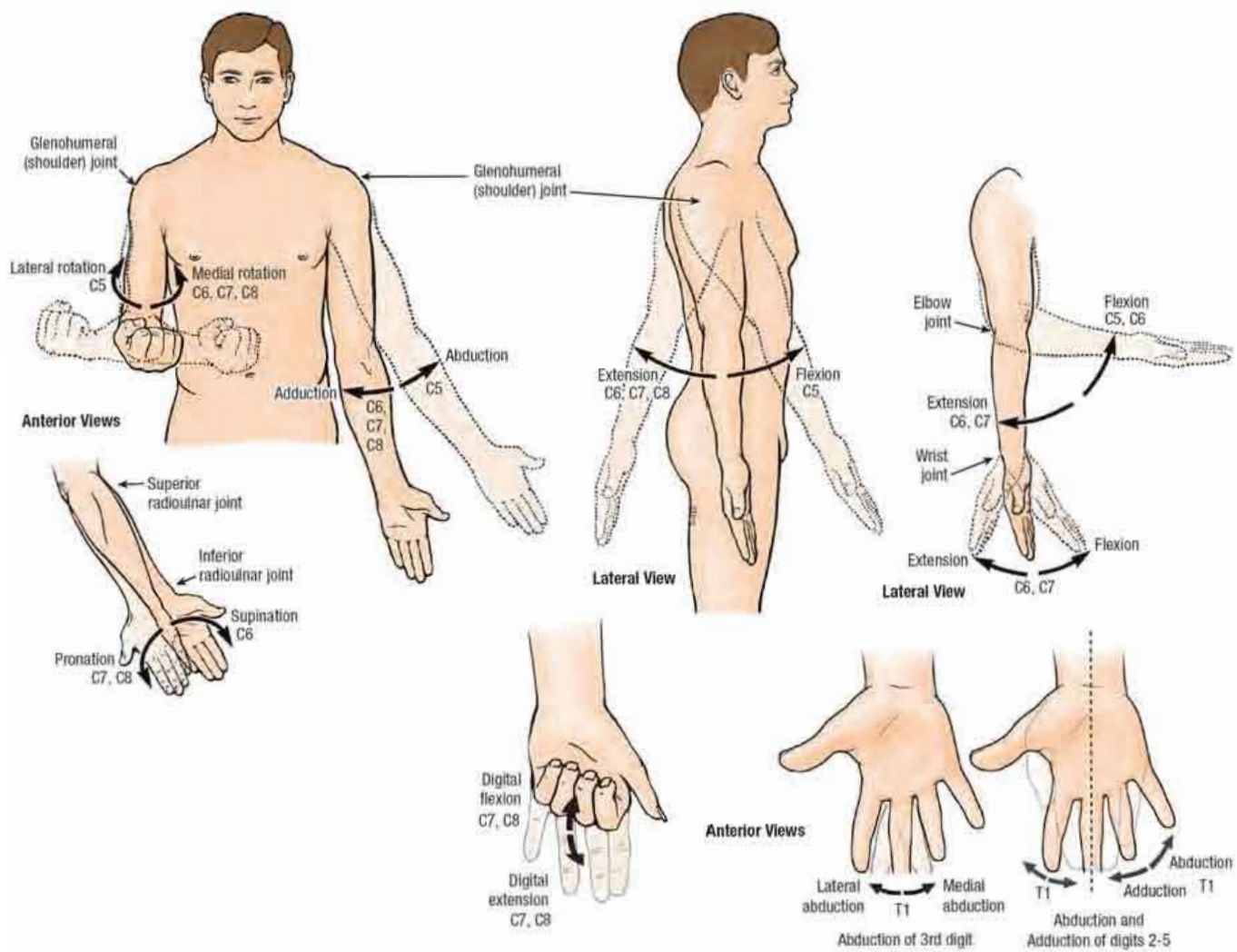
> Table of Contents > Chapter 6 - Upper Limb > 6.4 Myotomes and myotatic (deep tendon stretch) reflexes

---

## 6.4 Myotomes and myotatic (deep tendon stretch) reflexes

*Part of "Chapter 6 - Upper Limb "*

A. Myotomes. Somatic motor (general somatic efferent) fibers transmit impulses to skeletal (voluntary) muscles. The unilateral muscle mass receiving information from the somatic motor fibers conveyed by a single spinal nerve is a myotome. The intrinsic muscles of the hand constitute a single myotome—myotome T1. B. Myotatic reflexes. A myotatic reflex (deep tendon or stretch reflex) is an involuntary contraction of a muscle in response to sudden stretching. Myotatic reflexes are monosynaptic stretch reflexes that are elicited by briskly tapping the tendon with a reflex hammer. Each tendon reflex is mediated by specific spinal nerves. Stretch reflexes control muscle tone.



Myotatic (deep tendon) reflex	Spinal cord segments
Biceps	C5/C6
Brachioradialis	C5/C6
Triceps	C6/C7

Authors: Agur, Anne M.R.; Dalley, Arthur F.

Title: *Grant's Atlas of Anatomy, 12th Edition*

Copyright ©2009 Lippincott Williams & Wilkins

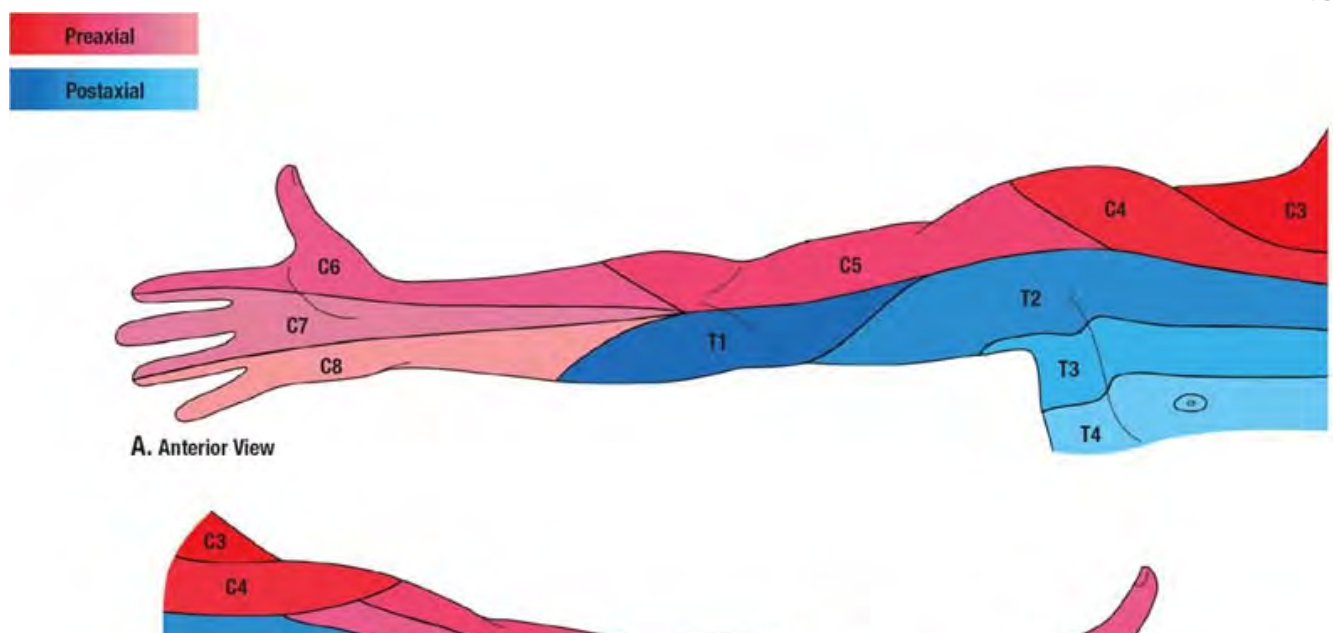
> Table of Contents > Chapter 6 - Upper Limb > 6.5 Dermatomes of upper limb

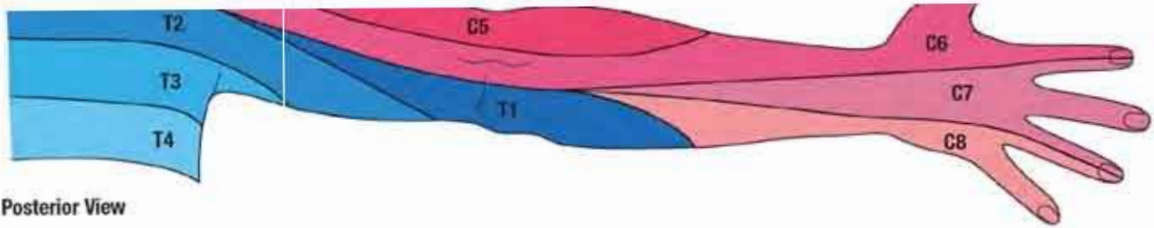
## 6.5 Dermatomes of upper limb

*Part of "Chapter 6 - Upper Limb"*

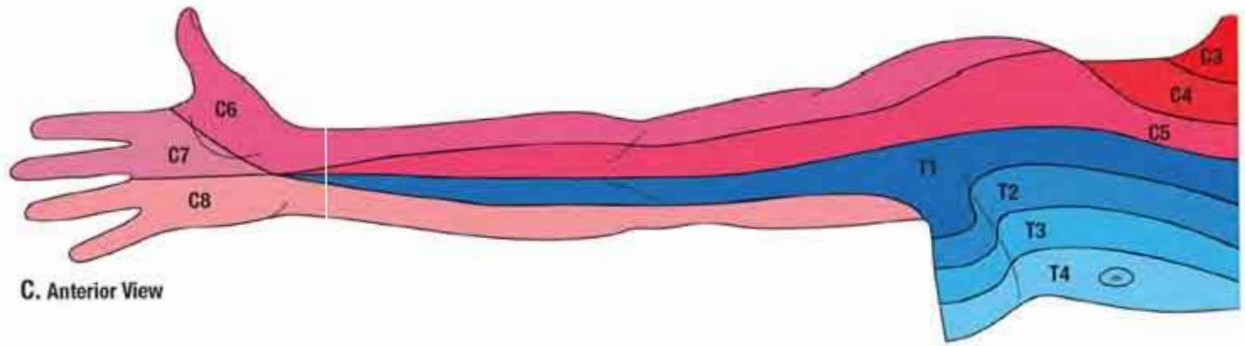
The dermatomal or segmental pattern of distribution of sensory nerve fibers persists despite the merging of spinal nerves in plexus formation during development. Two different dermatome maps are commonly used. A and B. The dermatome pattern of the upper limb according to Foerster (1933) is preferred by many because of its correlation with clinical findings. In the Foerster schema, dermatomes C6–T1 are displaced from the trunk to limbs. C and D. The dermatome pattern of the upper limb according to Keegan and Garrett (1948) is preferred by others for its correlation with development. Although depicted as distinct zones, adjacent dermatomes overlap considerably except along the axial line.

P.484

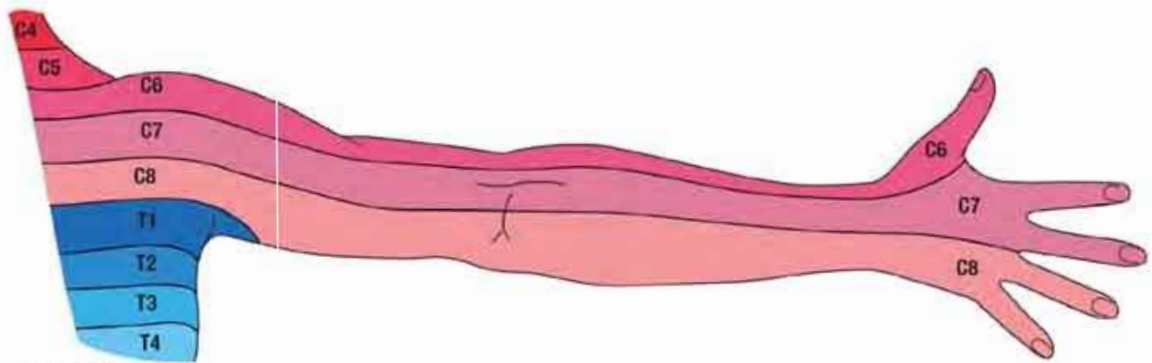




B. Posterior View



C. Anterior View



D. Posterior View

Authors: Agur, Anne M.R.; Dalley, Arthur F.

Title: *Grant's Atlas of Anatomy, 12th Edition*

Copyright ©2009 Lippincott Williams & Wilkins

> Table of Contents > Chapter 6 - Upper Limb > 6.6 Cutaneous nerves of upper limb

---

## 6.6 Cutaneous nerves of upper limb

*Part of* "Chapter 6 - Upper Limb "

---

P.485

Supraclavicular nerves

C3–C4

Cervical plexus

Pass anterior to clavicle, immediately deep to platysma, and supply the skin over the clavicle and superolateral aspect of the pectoralis major muscle

Superior lateral cutaneous nerve of arm

C5–C6

Axillary nerve (posterior cord of brachial plexus)

Emerges from posterior margin of deltoid to supply skin over lower part of this muscle and the lateral side of the midarm

Inferior lateral cutaneous nerve of arm

Radial nerve (posterior cord of brachial plexus)

Arises with the posterior cutaneous nerve of forearm; pierces lateral head of triceps brachii to supply skin over the inferolateral aspect of the arm

Posterior cutaneous nerve of arm

Arises in axilla and supplies skin on posterior surface of the arm to olecranon

Posterior cutaneous nerve of forearm

C5–C8

Arises with the inferior lateral cutaneous nerve of the arm; pierces lateral head of triceps brachii to supply skin over the posterior aspect of the arm



Superficial branch of radial nerve

C6–C7

Arises in cubital fossa; supplies lateral (radial) half of the dorsal aspect of hand and thumb, and proximal portion of the dorsal aspects of digits 2 and 3, and the lateral (radial) half of dorsal aspect of digit 4

Lateral cutaneous nerve of forearm

Musculocutaneous nerve (lateral cord of brachial plexus)

Arises between biceps brachii and brachialis muscle as continuation of musculocutaneous nerve distal to branch to brachialis; emerges in cubital fossa lateral to biceps tendon and median cubital vein; supplies skin along radial (lateral) border of forearm to base of thenar eminence

Median nerve

C6–C7 (via lateral root);

C8–T1 (via medial root)

Lateral and medial cords of brachial plexus

Courses with brachial artery in arm and deep to flexor digitorum superficialis in forearm; distal to origin of palmar cutaneous branch, traverses carpal tunnel to supply skin of palmar aspect of radial 3½ digits and adjacent palm, plus distal dorsal aspects of same, including nail beds

Ulnar nerve

(C7), C8–T1

Medial cord of brachial plexus

Courses with brachial, superior ulnar collateral, and ulnar arteries; supplies skin of palmar and dorsal aspects of medial (ulnar) 1½ digits and palm and dorsum of hand proximal to those digits

Medial cutaneous nerve of forearm

C8–T1

Pierces deep fascia with basilic vein in midarm; divides into anterior and posterior branches supplying skin over anterior and medial surfaces of forearm to wrist

Medial cutaneous nerve of arm

C8–T2

Smallest and most medial branch of brachial plexus; communicates with intercostobrachial nerve, then descends medial to brachial artery and basilic vein to innervate skin of distal medial arm

Intercostobrachial nerve

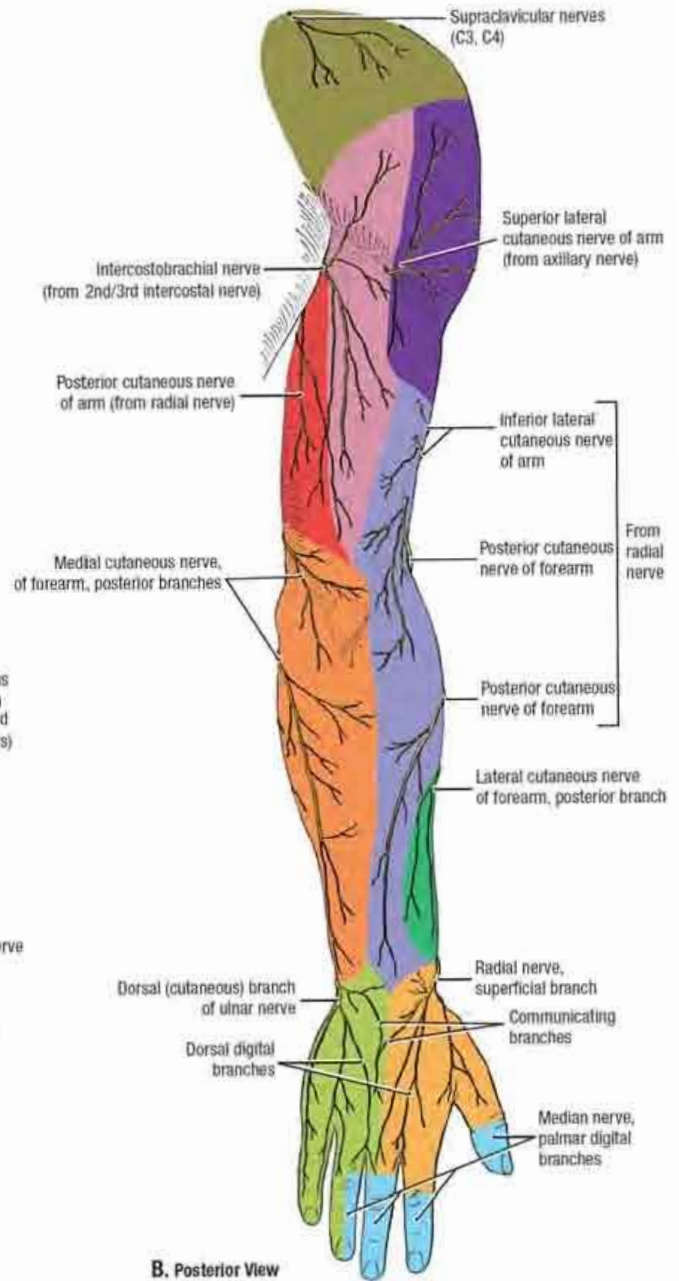
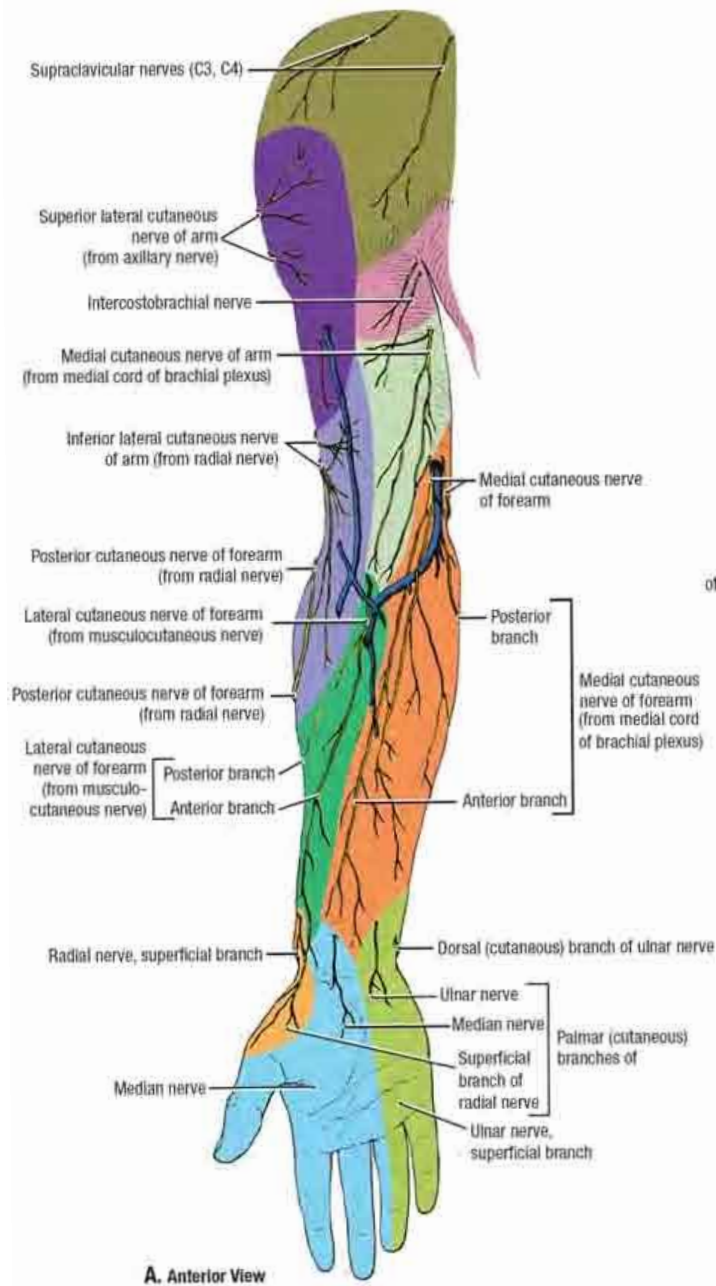
T2

Lateral cutaneous branch of 2nd intercostal nerve

Arises distal to angle of 2nd rib; supplies skin of axilla and proximal medial arm

Nerve	Spinal Nerve components	Source	Course/Distribution
-------	-------------------------	--------	---------------------

<h2>Table 6.1 Cutaneous Nerves of Upper Limb</h2>
---



Authors: Agur, Anne M.R.; Dalley, Arthur F.  
Title: *Grant's Atlas of Anatomy, 12th Edition*  
Copyright ©2009 Lippincott Williams & Wilkins

> Table of Contents > Chapter 6 - Upper Limb > 6.7 Arteries and arterial anastomoses of upper limb

## 6.7 Arteries and arterial anastomoses of upper limb

*Part of "Chapter 6 - Upper Limb"*

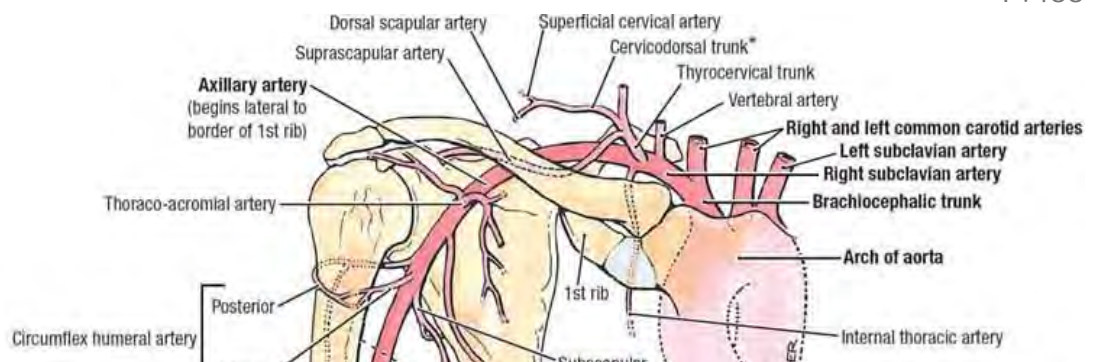
A. The arteries often anastomose or communicate to form networks to ensure blood supply distal to the joint throughout the range of movement.

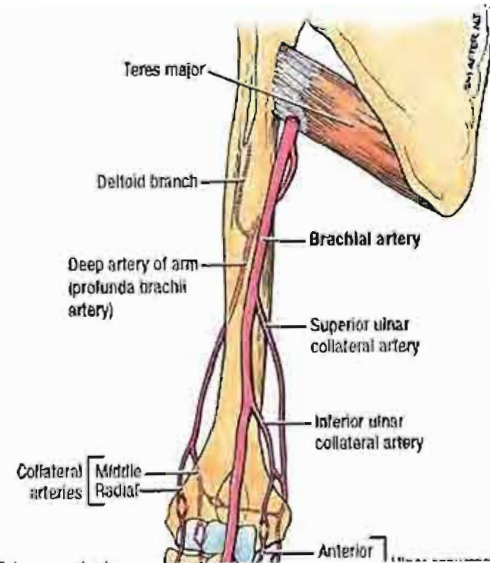
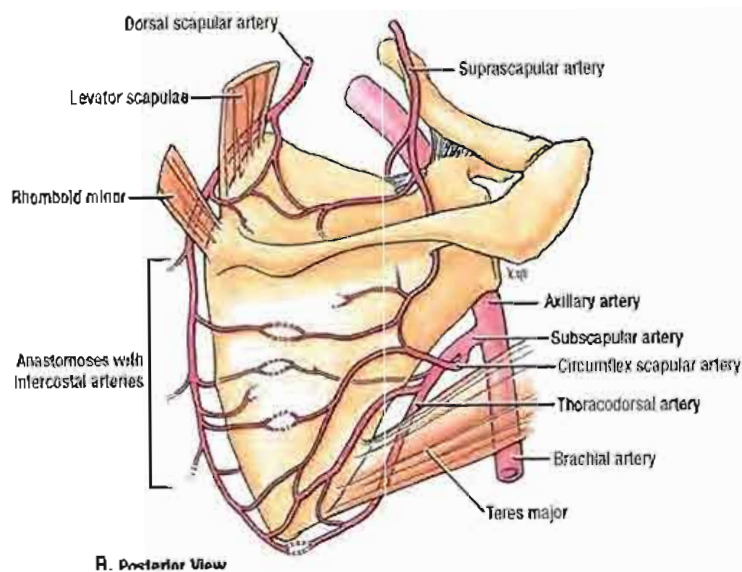
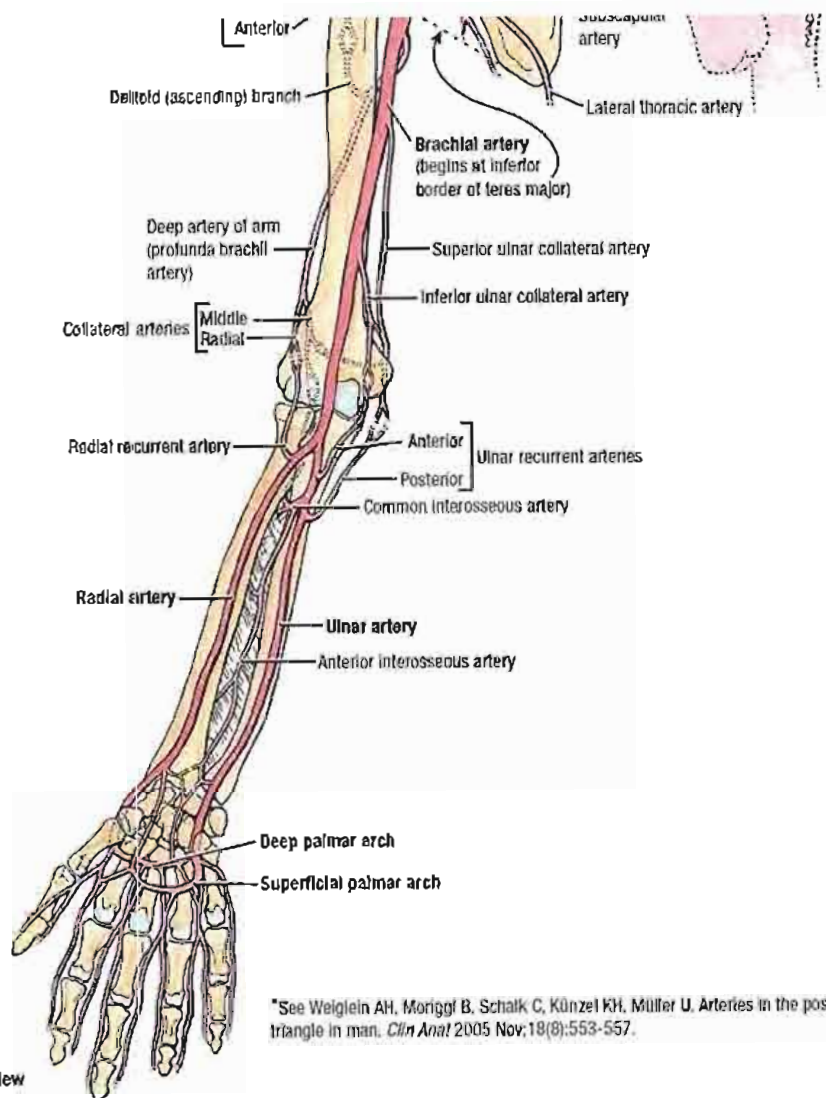
If a main channel is occluded, the smaller alternate channels can usually increase in size, providing a collateral circulation that ensures the blood supply to structures distal to the blockage. However, collateral pathways require time to develop; they are usually insufficient to compensate for sudden occlusions.

P.487

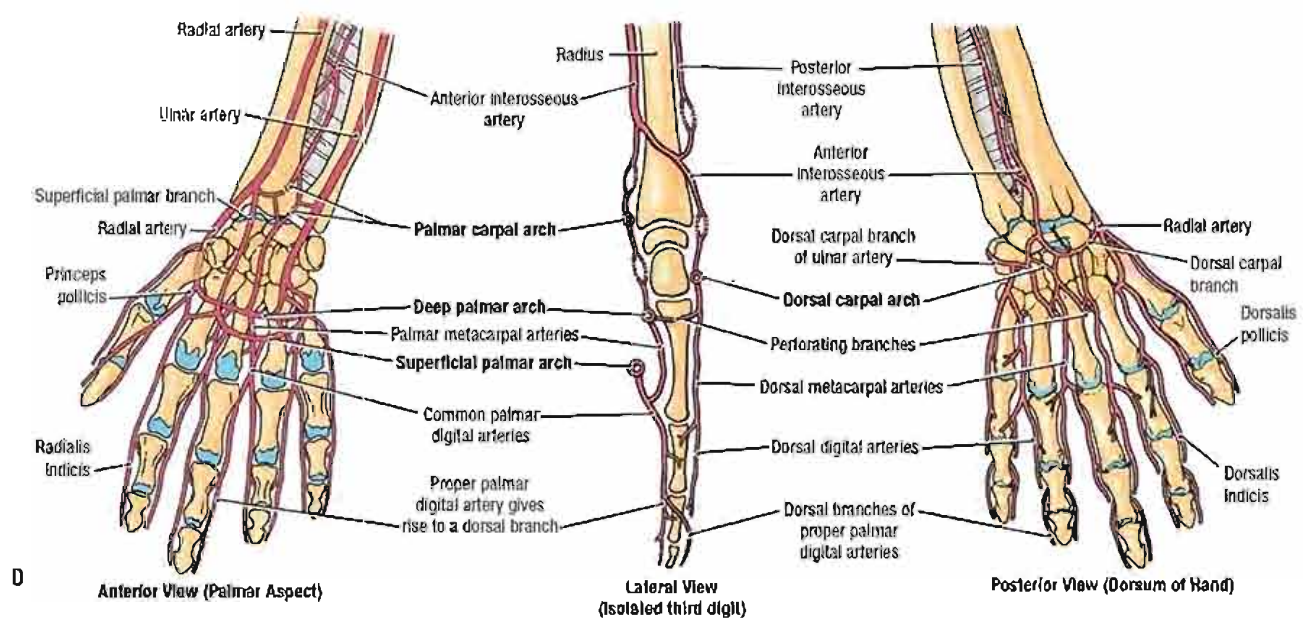
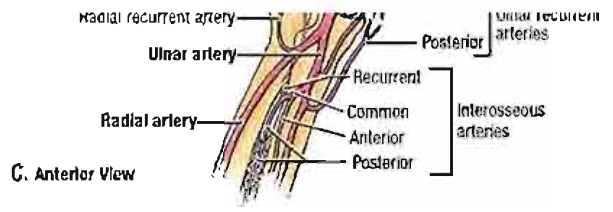
B. Scapular anastomoses. C. Anastomoses of the elbow. D. Anastomoses of the hand. Joints receive blood from articular arteries that arise from vessels around joints.

P.488









Authors: Agur, Anne M.R.; Dalley, Arthur F.

Title: *Grant's Atlas of Anatomy, 12th Edition*

Copyright ©2009 Lippincott Williams & Wilkins

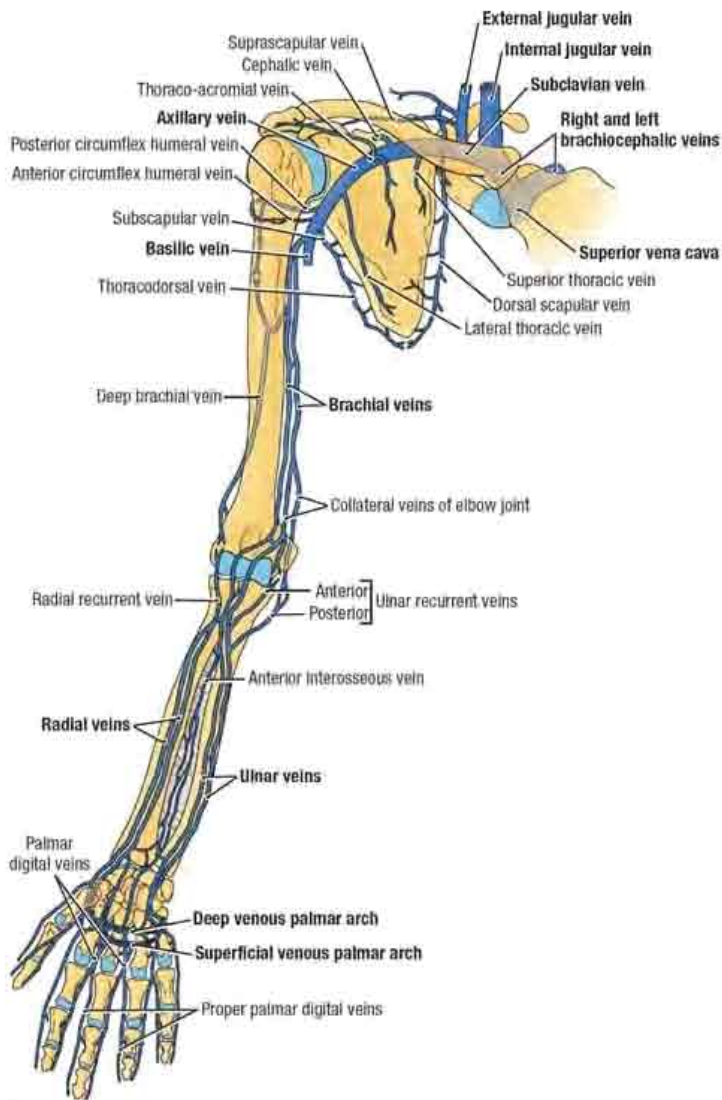
> Table of Contents > Chapter 6 - Upper Limb > 6.8 Overview of the deep veins of the upper limb

---

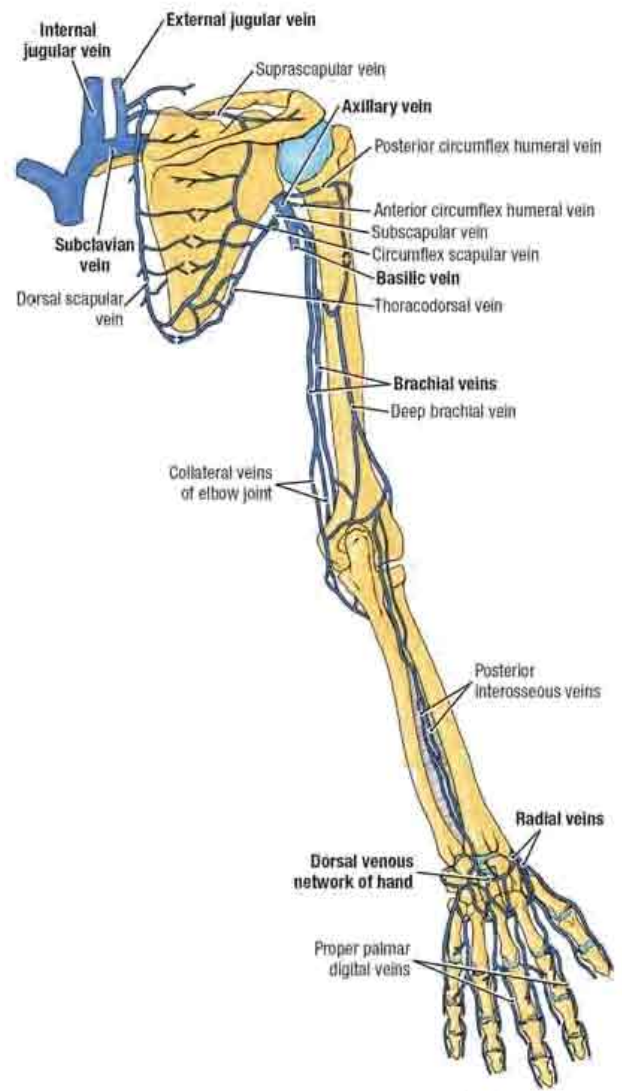
## 6.8 Overview of the deep veins of the upper limb

*Part of* "Chapter 6 - Upper Limb "

Deep veins lie internal to the deep fascia and occur as paired, continually interanastomosing "accompanying veins" (L., *venae comitantes*) surrounding and sharing the name of the artery they accompany.



**A. Anterior View**



**B. Posterior View**

Authors: Agur, Anne M.R.; Dalley, Arthur F.

Title: *Grant's Atlas of Anatomy, 12th Edition*

Copyright ©2009 Lippincott Williams & Wilkins

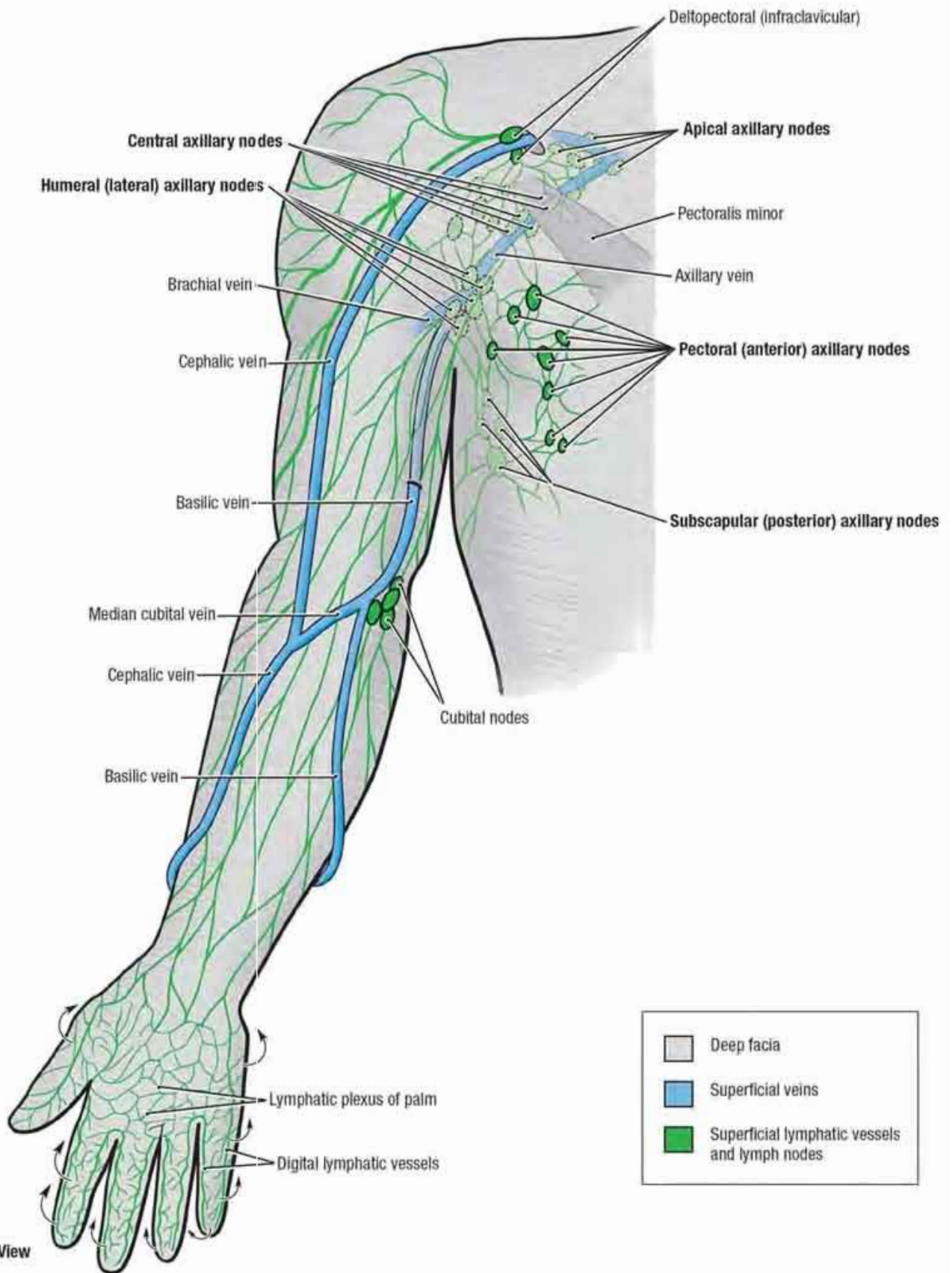
> Table of Contents > Chapter 6 - Upper Limb > 6.9 Superficial venous and lymphatic drainage of upper limb

---

## 6.9 Superficial venous and lymphatic drainage of upper limb

*Part of "Chapter 6 - Upper Limb "*

Superficial lymphatic vessels arise from lymphatic plexuses in the digits, palm, and dorsum of the hand and ascend with the superficial veins of the upper limb. The superficial lymphatic vessels ascend through the forearm and arm, converging toward the cephalic and especially to the basilic vein to reach the axillary lymph nodes. Some lymph passes through the cubital nodes at the elbow and the deltopectoral (infraclavicular) nodes at the shoulder. Deep lymphatic vessels accompany the neurovascular bundles of the upper limb and end primarily in the humeral (lateral) and central axillary lymph nodes.







Authors: Agur, Anne M.R.; Dalley, Arthur F.

Title: *Grant's Atlas of Anatomy, 12th Edition*

Copyright ©2009 Lippincott Williams & Wilkins

> Table of Contents > Chapter 6 - Upper Limb > 6.10 Superficial venous drainage of upper limb

---

## 6.10 Superficial venous drainage of upper limb

*Part of "Chapter 6 - Upper Limb "*

A. Forearm, arm, and pectoral region. B. Dorsal surface of hand. C. Palmar surface of hand. The *arrows* indicate where perforating veins penetrate the deep fascia. Blood is continuously shunted from these superficial veins in the subcutaneous tissue to deep veins via the perforating veins.

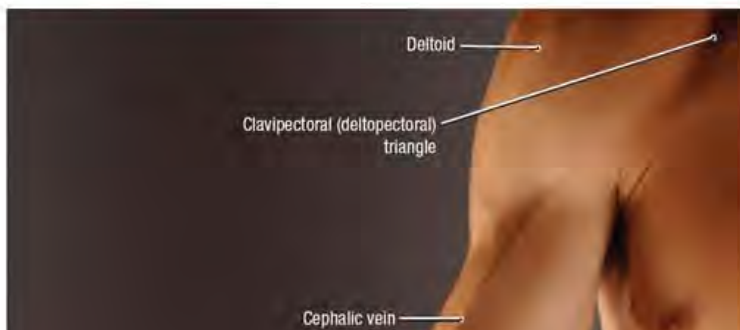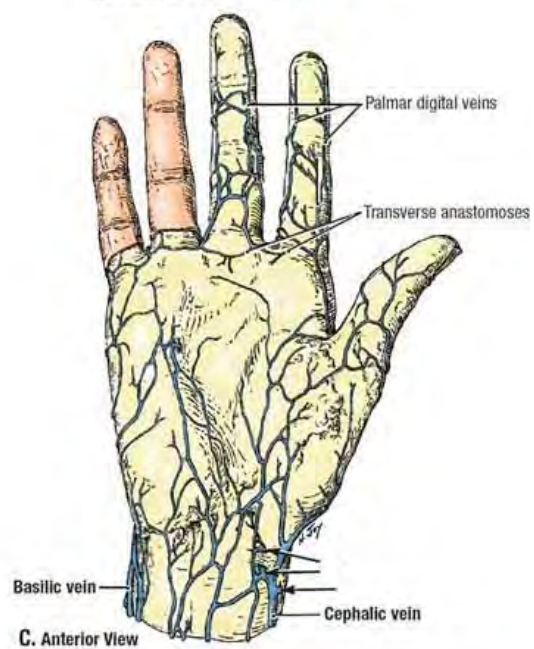
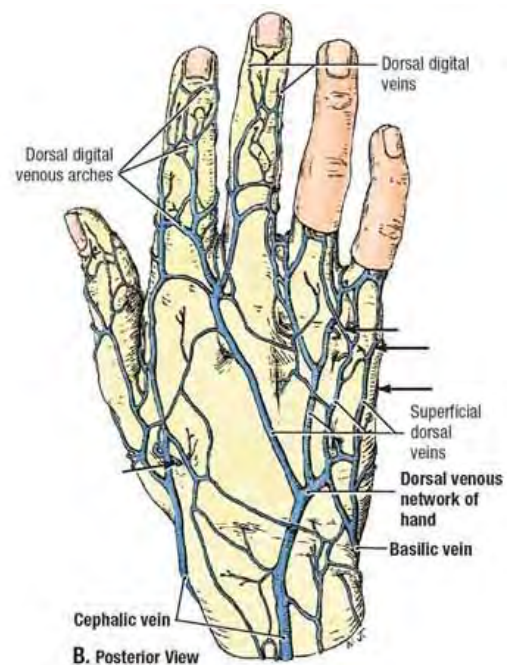
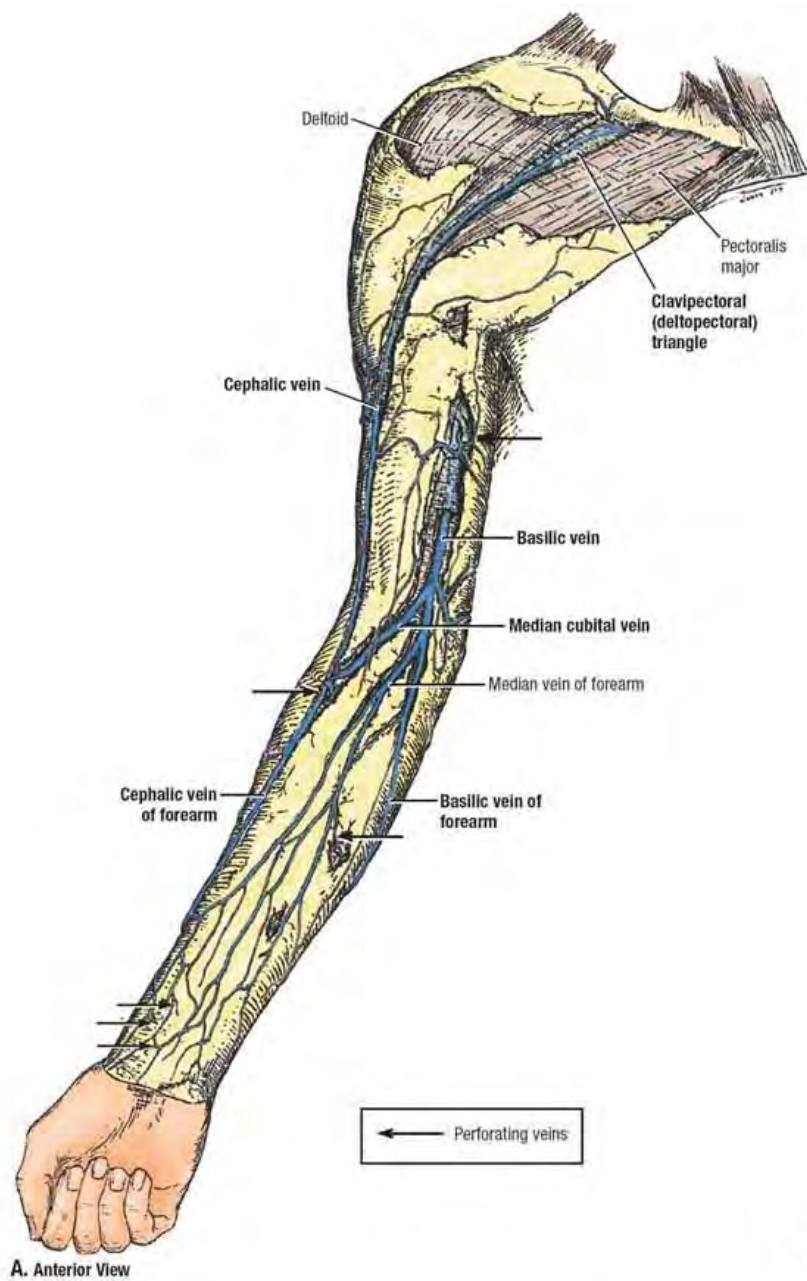
---

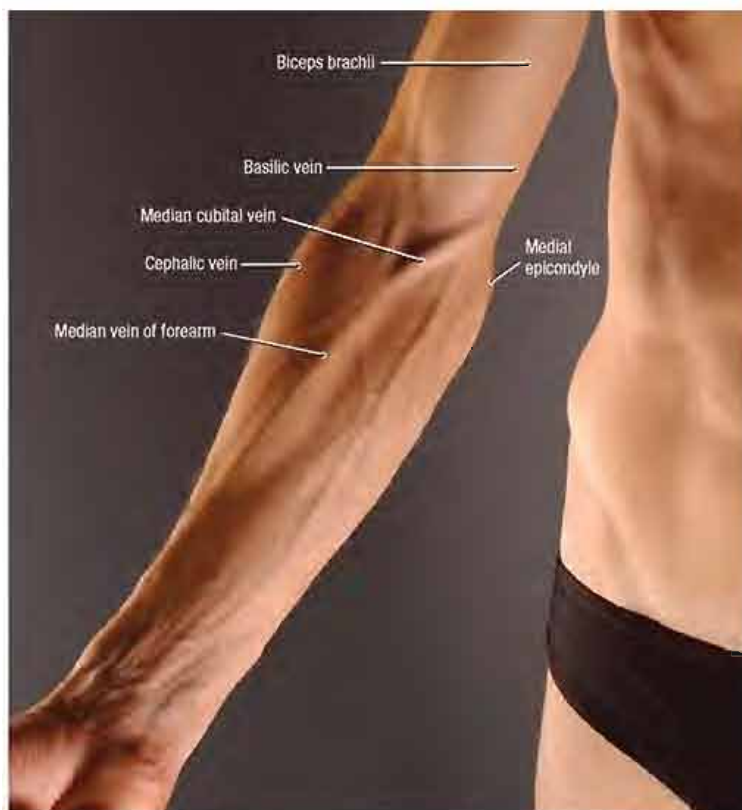P.491

D. Surface anatomy of veins of forearm and arm. E. Surface anatomy of veins of the dorsal surface of hand.

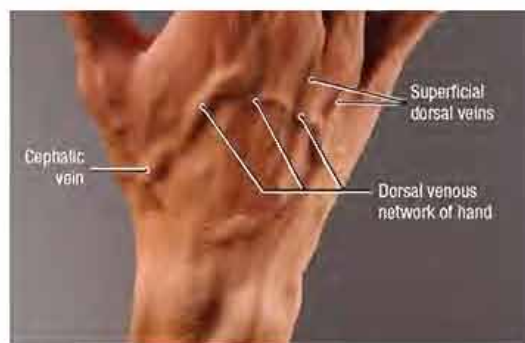
Because of the prominence and accessibility of the superficial veins, they are commonly used for venipuncture (puncture of a vein to draw blood or inject a solution). By applying a tourniquet to the arm, the venous return is occluded, and the veins distend and usually are visible and/or palpable. Once a vein is punctured, the tourniquet is removed so that when the needle is removed the vein will not bleed extensively. The median cubital vein is commonly used for venipuncture. The veins forming the dorsal venous network of the hand and the cephalic and basilic veins arising from it are commonly used for long-term introduction of fluids (intravenous feeding). The cubital veins are also a site for the introduction of cardiac catheters to secure blood samples from the great vessels and chambers of the heart.

---





**D. Anterior View**



**E. Posterior View**

Authors: Agur, Anne M.R.; Dalley, Arthur F.

Title: *Grant's Atlas of Anatomy, 12th Edition*

Copyright ©2009 Lippincott Williams & Wilkins

> Table of Contents > Chapter 6 - Upper Limb > 6.11 Deep fascia of upper limb "axillary and clavipectoral fascia

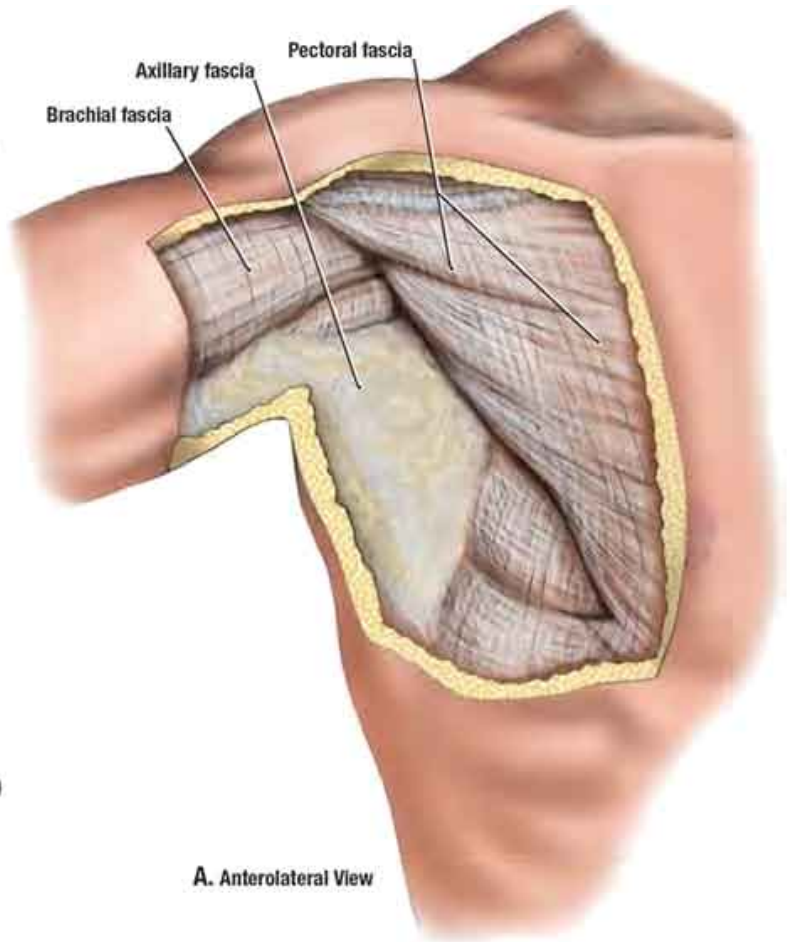
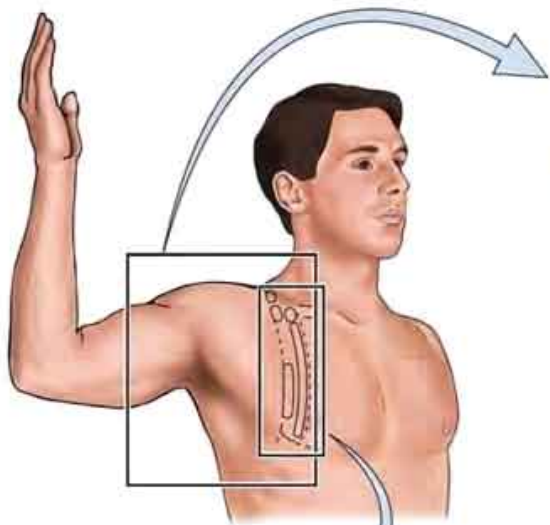
---

## 6.11 Deep fascia of upper limb "axillary and clavipectoral fascia

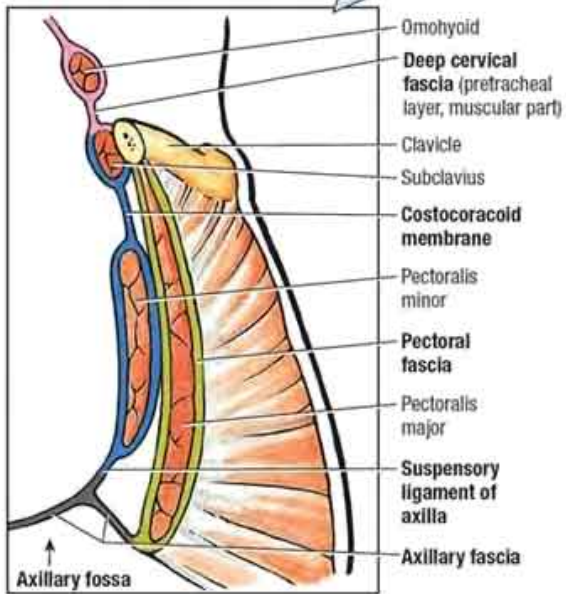
*Part of "Chapter 6 - Upper Limb "*

A. Axillary fascia. The axillary fascia forms the floor of the axillary fossa and is continuous with the pectoral fascia covering the pectoralis major muscle and the brachial fascia of the arm. B. Clavipectoral fascia. The clavipectoral fascia extends from the axillary fascia to enclose the pectoralis minor and subclavius muscles and then attaches to the clavicle. The part of the clavipectoral fascia superior to the pectoralis minor is the costocoracoid membrane and the part of the clavipectoral fascia inferior to the pectoralis minor is the suspensory ligament of the axilla. The suspensory ligament of the axilla, an extension of the axillary fascia, supports the axillary fascia and pulls the axillary fascia and the skin inferior to it superiorly when the arm is abducted, forming the axillary fossa or "arm-pit."





A. Anterolateral View



B. Sagittal Section

**Fascia in B:**

- Deep cervical
- Clavipectoral
- Pectoral
- Axillary

Authors: Agur, Anne M.R.; Dalley, Arthur F.

Title: *Grant's Atlas of Anatomy, 12th Edition*

Copyright ©2009 Lippincott Williams & Wilkins

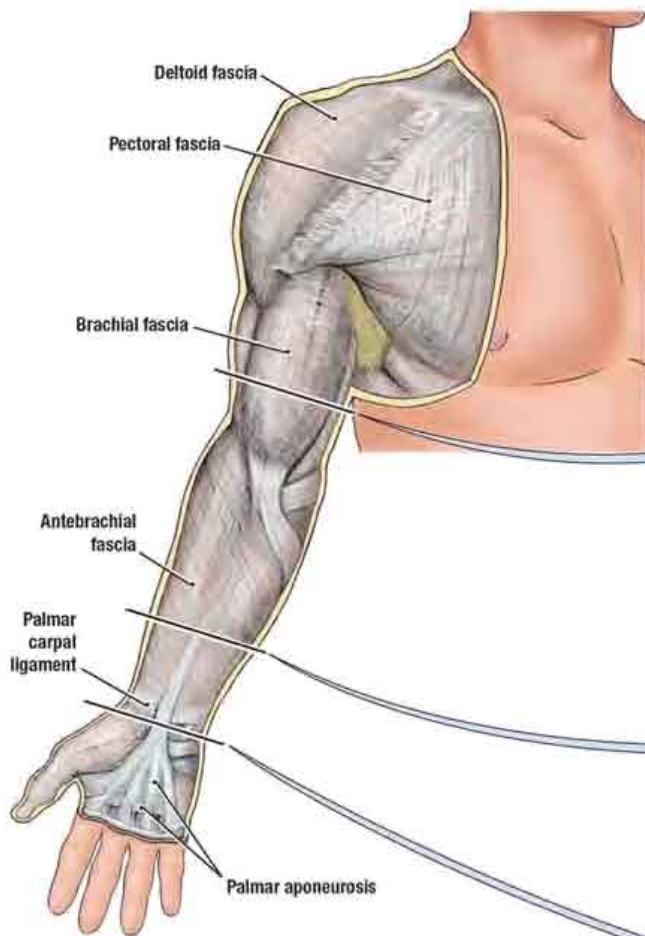
> Table of Contents > Chapter 6 - Upper Limb > 6.12 Deep fascia of upper limb "brachial and antebrachial fascia

---

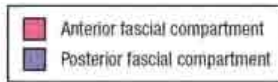
## 6.12 Deep fascia of upper limb "brachial and antebrachial fascia

*Part of "Chapter 6 - Upper Limb "*

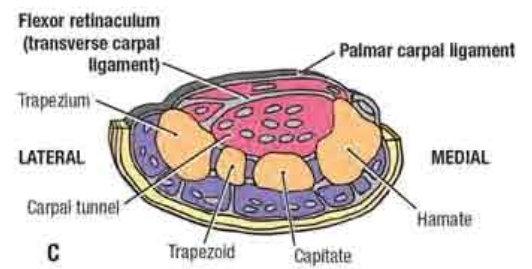
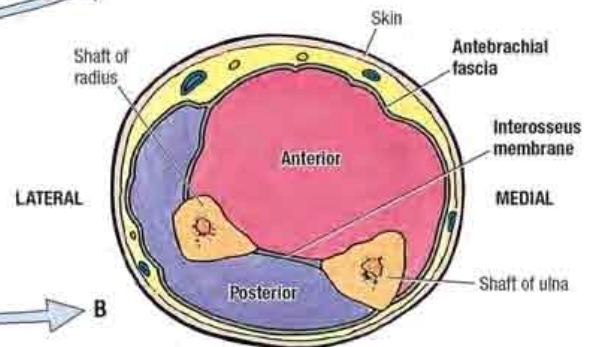
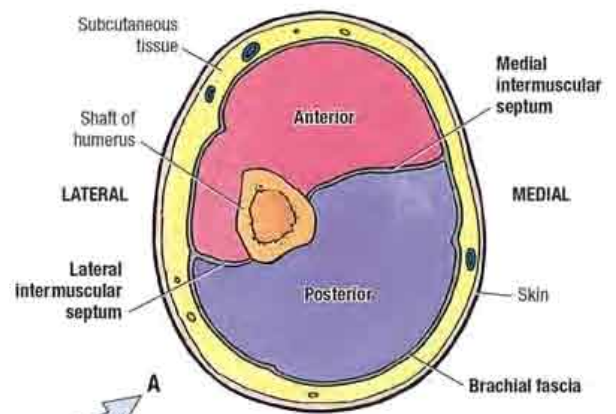
A. Brachial fascia. The brachial fascia is the deep fascia of the arm and is continuous superiorly with the pectoral and axillary layers of fascia. Medial and lateral intermuscular septa extend from the deep aspect of the brachial fascia to the humerus, dividing the arm into anterior and posterior musculofascial compartments. B. Antebrachial fascia. The antebrachial fascia surrounds the forearm and is continuous with the brachial fascia and deep fascia of the hand. The interosseous membrane separates the forearm into anterior and posterior musculofascial compartments. Distally the fascia thickens to form the palmar carpal ligament, which is continuous with the flexor retinaculum and dorsally with the extensor expansion. The deep fascia of the hand is continuous with the antebrachial fascia, and on the palmar surface of the hand it thickens to form the palmar aponeurosis. C. Flexor retinaculum (transverse carpal ligament). The flexor retinaculum extends between the medial and lateral carpal bones to form the carpal tunnel.



Right Anterior Oblique View



Transverse Sections, Inferior Views



Authors: Agur, Anne M.R.; Dalley, Arthur F.

Title: *Grant's Atlas of Anatomy, 12th Edition*

Copyright ©2009 Lippincott Williams & Wilkins

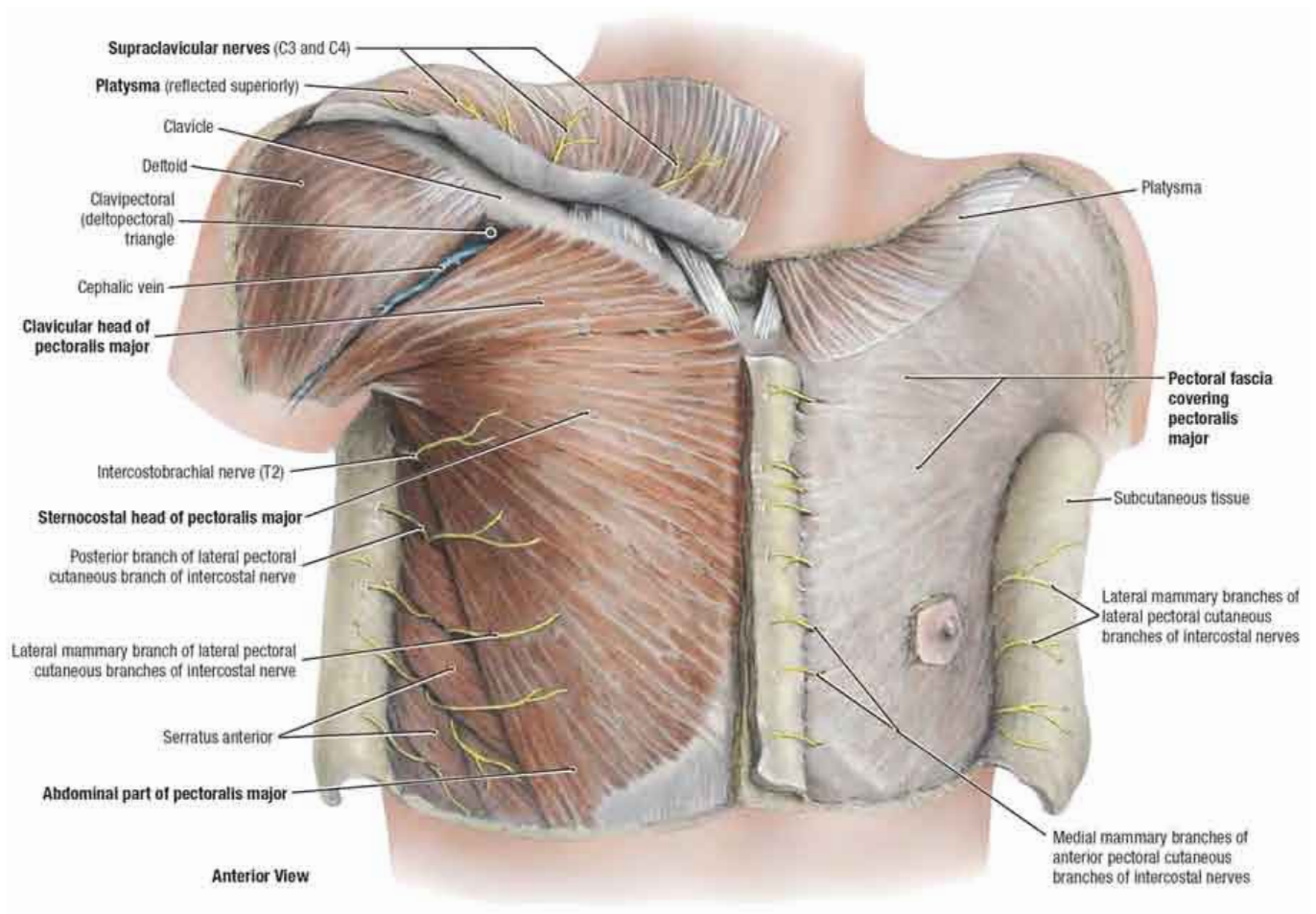
> Table of Contents > Chapter 6 - Upper Limb > 6.13 Superficial dissection, male pectoral region

---

## 6.13 Superficial dissection, male pectoral region

*Part of "Chapter 6 - Upper Limb "*

- The platysma muscle, which usually descends to the 2nd or 3rd rib, is cut short on the right side and, together with the supraclavicular nerves, is reflected on the left side.
- The exposed intermuscular bony strip of the clavicle is subcutaneous and subplatysmal.
- The cephalic vein passes deeply to join the axillary vein in the clavipectoral (deltopectoral) triangle.
- The cutaneous innervation of the pectoral region by the supraclavicular nerves (C3 and C4) and upper thoracic nerves (T2 to T6); the brachial plexus (C5–T1) does not supply cutaneous branches to the pectoral region.





Authors: Agur, Anne M.R.; Dalley, Arthur F.

Title: *Grant's Atlas of Anatomy, 12th Edition*

Copyright ©2009 Lippincott Williams & Wilkins

> Table of Contents > Chapter 6 - Upper Limb > 6.14 Surface anatomy, male pectoral region

---

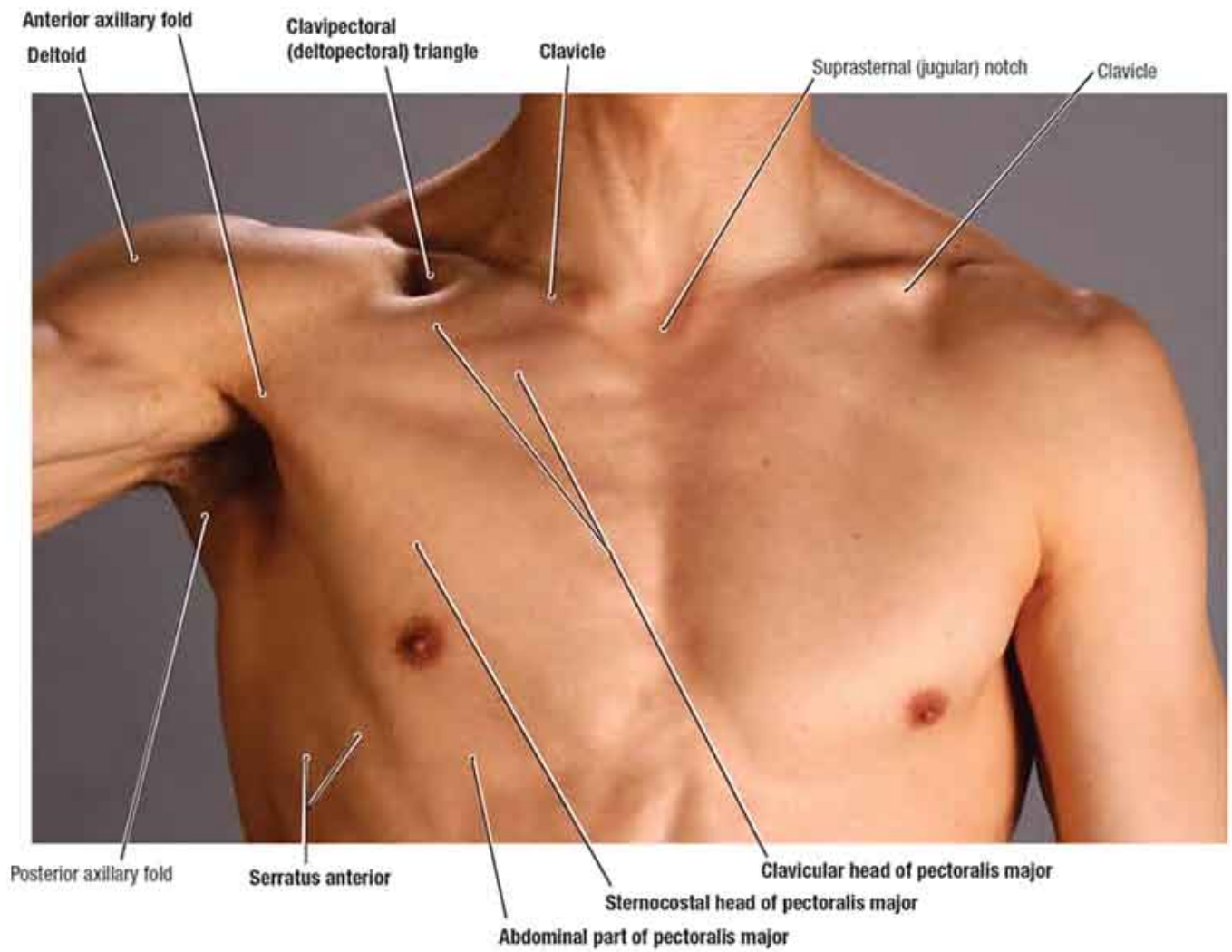
## 6.14 Surface anatomy, male pectoral region

*Part of "Chapter 6 - Upper Limb "*

The clavipectoral (deltopectoral) triangle is the depressed area just inferior to the lateral part of the clavicle. The clavipectoral triangle is bounded by the clavicle superiorly, the deltoid laterally, and the clavicular head of pectoralis major medially. When the arm is abducted and then adducted against resistance, the two heads of the pectoralis major are visible and palpable. As this muscle extends from the thoracic wall to the arm, it forms the anterior axillary fold. Digitations of the serratus anterior appear inferolateral to the pectoralis major. The coracoid process of the scapula is covered by the anterior part of deltoid; however, the tip of the process can be felt on deep palpation in the clavipectoral triangle. The deltoid forms the contour of the shoulder.

---

P.496



Authors: Agur, Anne M.R.; Dalley, Arthur F.

Title: *Grant's Atlas of Anatomy, 12th Edition*

Copyright ©2009 Lippincott Williams & Wilkins

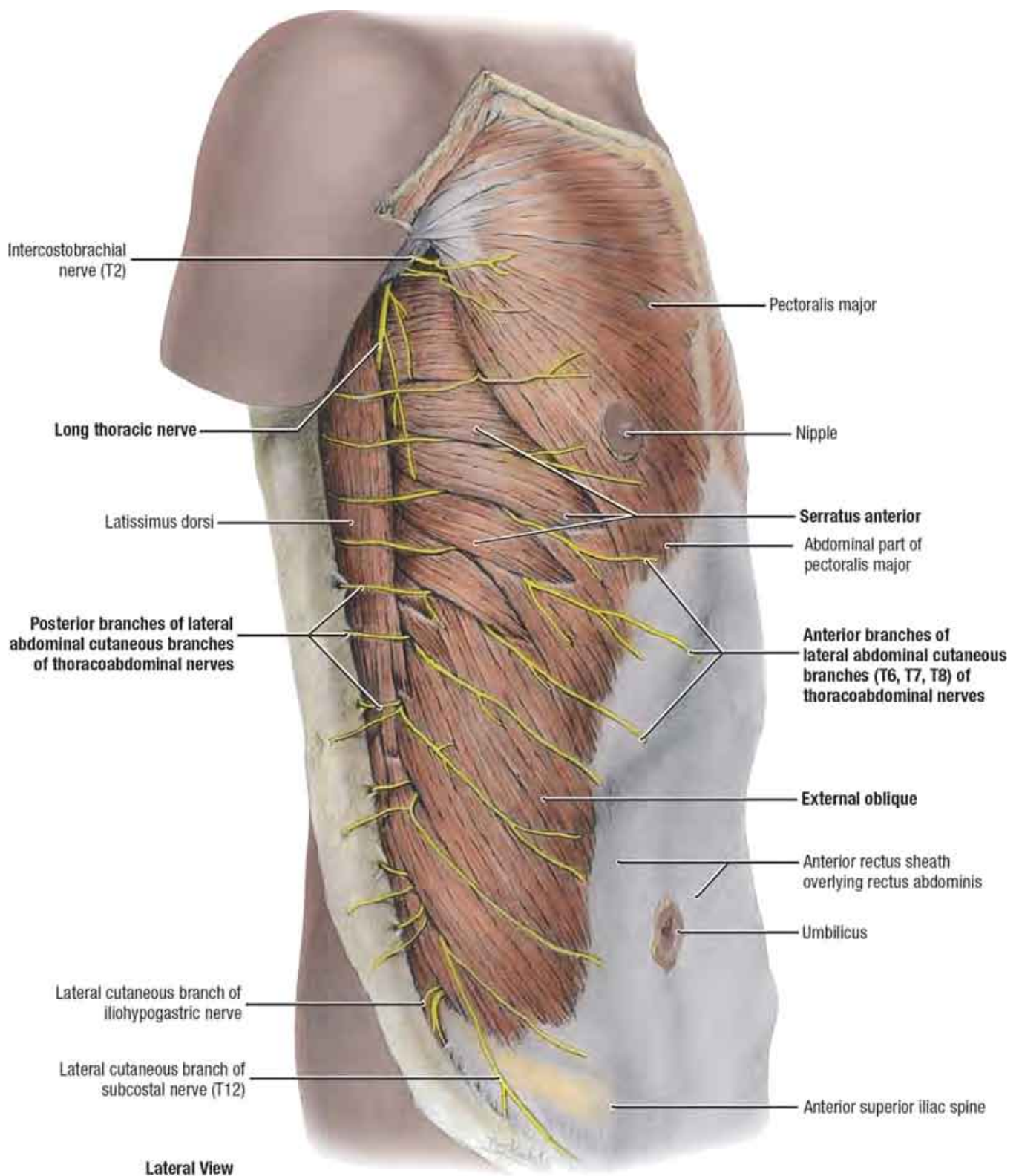
> Table of Contents > Chapter 6 - Upper Limb > 6.15 Superficial dissection of trunk

---

## 6.15 Superficial dissection of trunk

*Part of* "Chapter 6 - Upper Limb "

- The slips of the serratus anterior interdigitate with the external oblique.
- The long thoracic nerve (nerve to serratus anterior) lies on the lateral (superficial) aspect of the serratus anterior; this nerve is vulnerable to damage from stab wounds and during surgery (e.g., radical mastectomy).
- The anterior and posterior branches of the lateral thoracic and abdominal cutaneous branches of intercostal and thoracoabdominal nerves are dissected.



Authors: Agur, Anne M.R.; Dalley, Arthur F.

Title: *Grant's Atlas of Anatomy, 12th Edition*

Copyright ©2009 Lippincott Williams & Wilkins

> Table of Contents > Chapter 6 - Upper Limb > 6.16 Surface anatomy of anterolateral aspect of the trunk

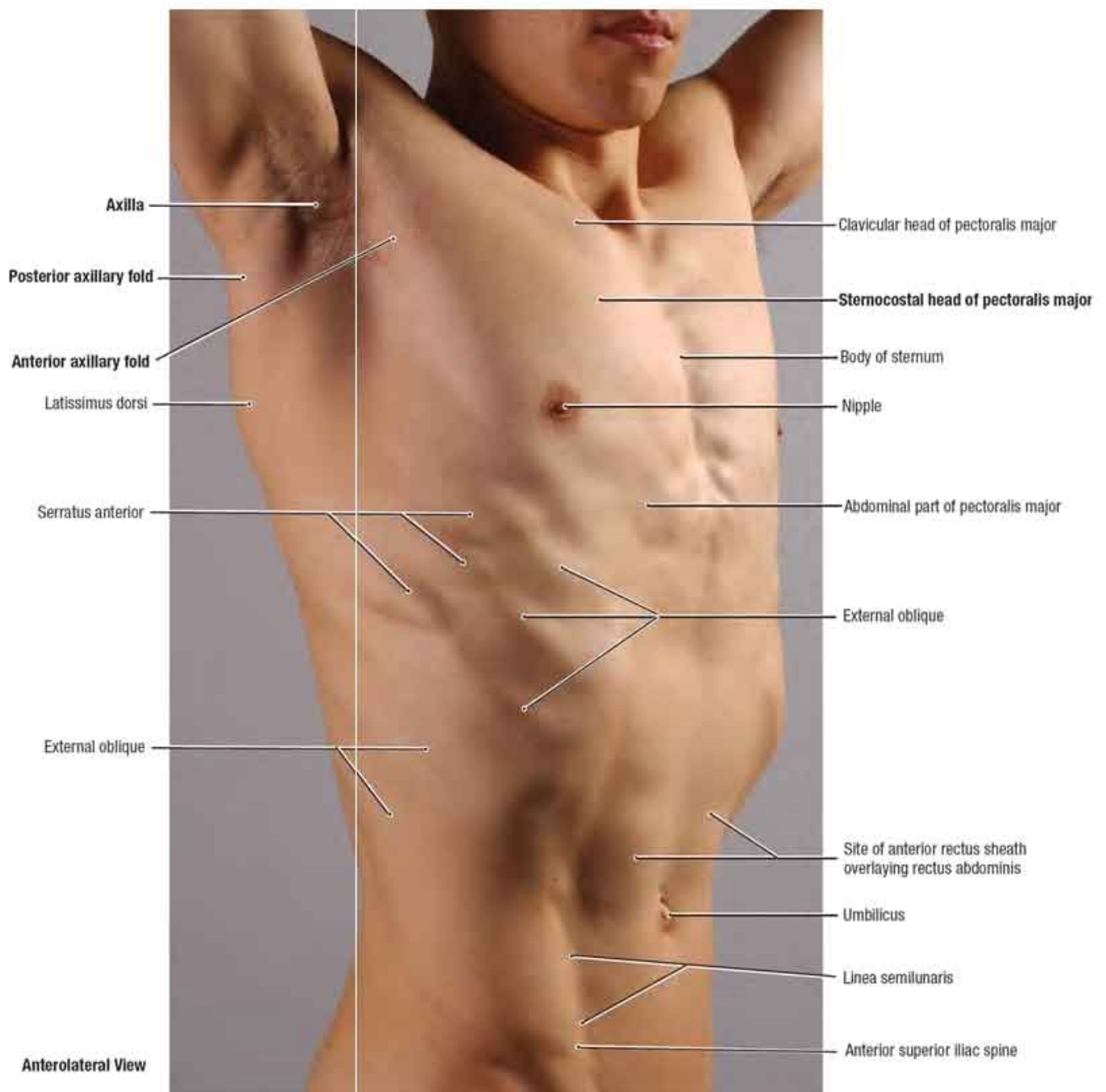
---

## 6.16 Surface anatomy of anterolateral aspect of the trunk

*Part of "Chapter 6 - Upper Limb "*

When the arm is abducted and then adducted against resistance, the sternocostal part of the pectoralis major can be seen and palpated. If the anterior axillary fold bounding the axilla is grasped between the fingers and thumb, the inferior border of the sternocostal head of the pectoralis major can be felt. Several digitations of the serratus anterior are visible inferior to the anterior axillary fold. The posterior axillary fold is composed of skin and muscular tissue (latissimus dorsi and teres major) bounding the axilla posteriorly.





Authors: Agur, Anne M.R.; Dalley, Arthur F.

Title: *Grant's Atlas of Anatomy, 12th Edition*

Copyright ©2009 Lippincott Williams & Wilkins

> Table of Contents > Chapter 6 - Upper Limb > 6.17 Pectoralis major and minor and serratus anterior

---

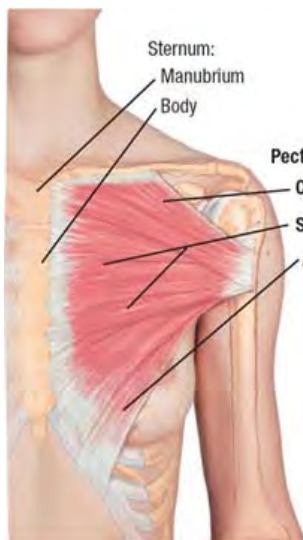## 6.17 Pectoralis major and minor and serratus anterior

*Part of* "Chapter 6 - Upper Limb "

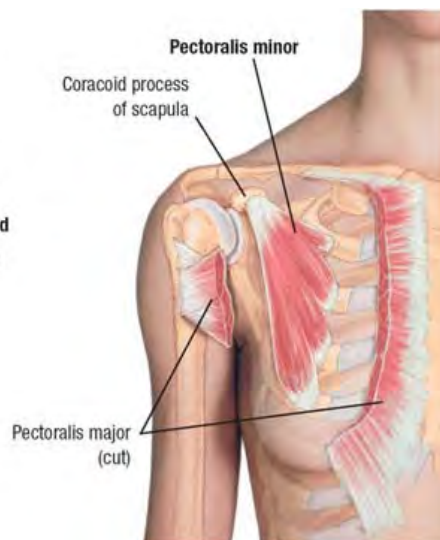
A. Pectoralis major. B. Pectoralis minor. C. Subclavius. D and E. Serratus anterior and its scapular attachment.

---

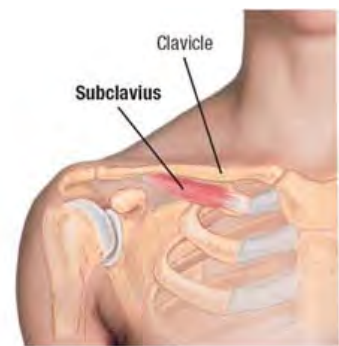
P.499



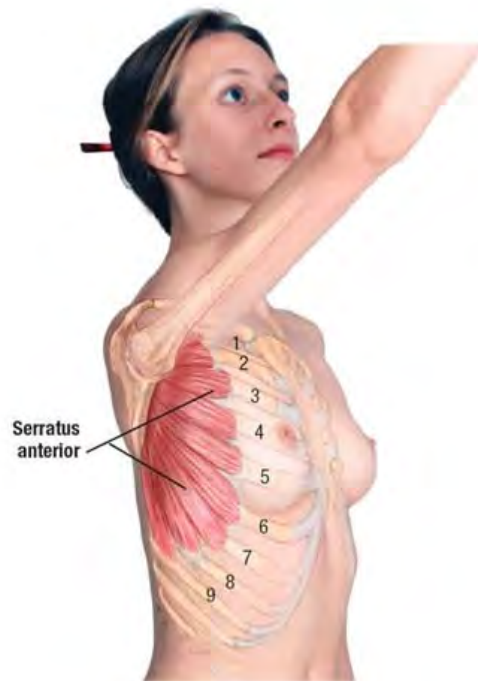
A. Anterior View



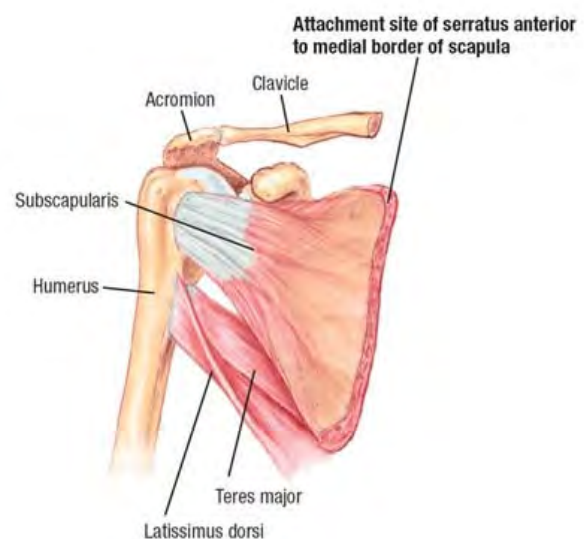
B. Anterior View



C. Anterior View



D. Lateral View



E. Anterior View

Pectoralis major

*Clavicular head:* anterior surface of medial half of clavicle

*Sternocostal head:* anterior surface of sternum, superior six costal cartilages

*Abdominal part:* aponeurosis of external oblique muscle

Crest of greater tubercle of intertubercular sulcus (lateral lip of bicipital groove)

Lateral and medial pectoral nerves; clavicular head (C5 and C6), sternocostal head (C7,

C8 , and T1)

Adducts and medially rotates humerus; draws scapula anteriorly and inferiorly

Acting alone: clavicular head flexes humerus and sternocostal head extends it from the flexed position

Pectoralis minor

3rd to 5th ribs near their costal cartilages

Medial border and superior surface of coracoid process of scapula

Medial pectoral nerve (C8 and T1)

Stabilizes scapula by drawing it inferiorly and anteriorly against thoracic wall

Subclavius

Junction of 1st rib and its costal cartilage

Inferior surface of middle third of clavicle

Nerve to subclavius (C5 and C6)

Anchors and depresses clavicle

Serratus anterior

External surfaces of lateral parts of 1st to 8th–9th ribs

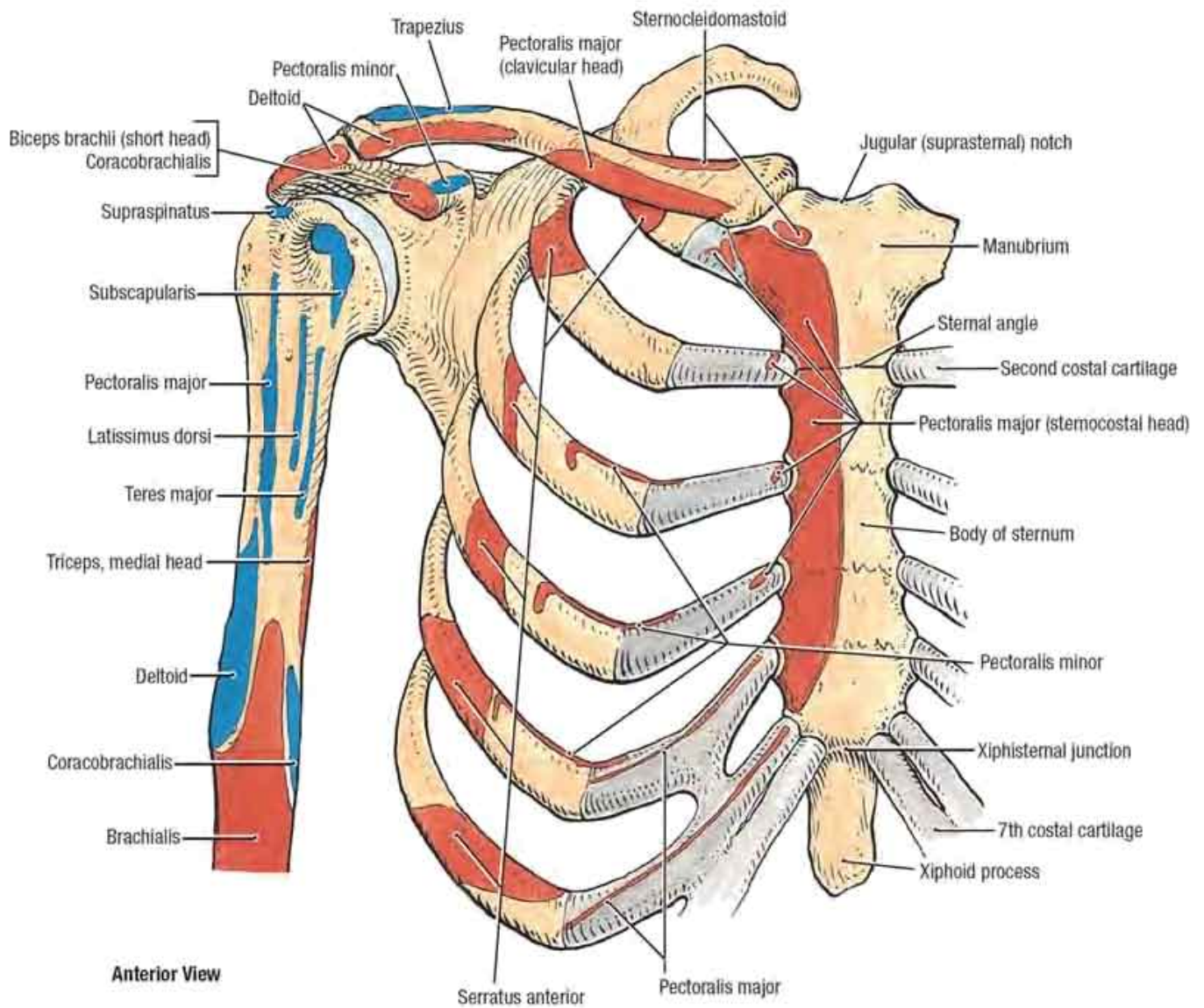
Anterior surface of medial border of scapula

Long thoracic nerve (C5, C6 , and C7)

Protracts scapula and holds it against thoracic wall; rotates scapula

<sup>a</sup>Numbers indicate spinal cord segmental innervation (e.g., C5 and C6 indicate that nerves supplying the clavicular head of pectoralis major are derived from 5th and 6th cervical segments of spinal cord). Boldface numbers indicate the main segmental innervation. Damage to these segments or to motor nerve roots arising from them results in paralysis of the muscles concerned.

Muscle	Proximal Attachment (red)	Distal Attachment (blue)	Innervation <sup>a</sup>	Main Actions
Table 6.2 Anterior Axioappendicular Muscles				





Authors: Agur, Anne M.R.; Dalley, Arthur F.

Title: *Grant's Atlas of Anatomy, 12th Edition*

Copyright ©2009 Lippincott Williams & Wilkins

> Table of Contents > Chapter 6 - Upper Limb > 6.18 Anterior wall of axilla and clavipectoral fascia

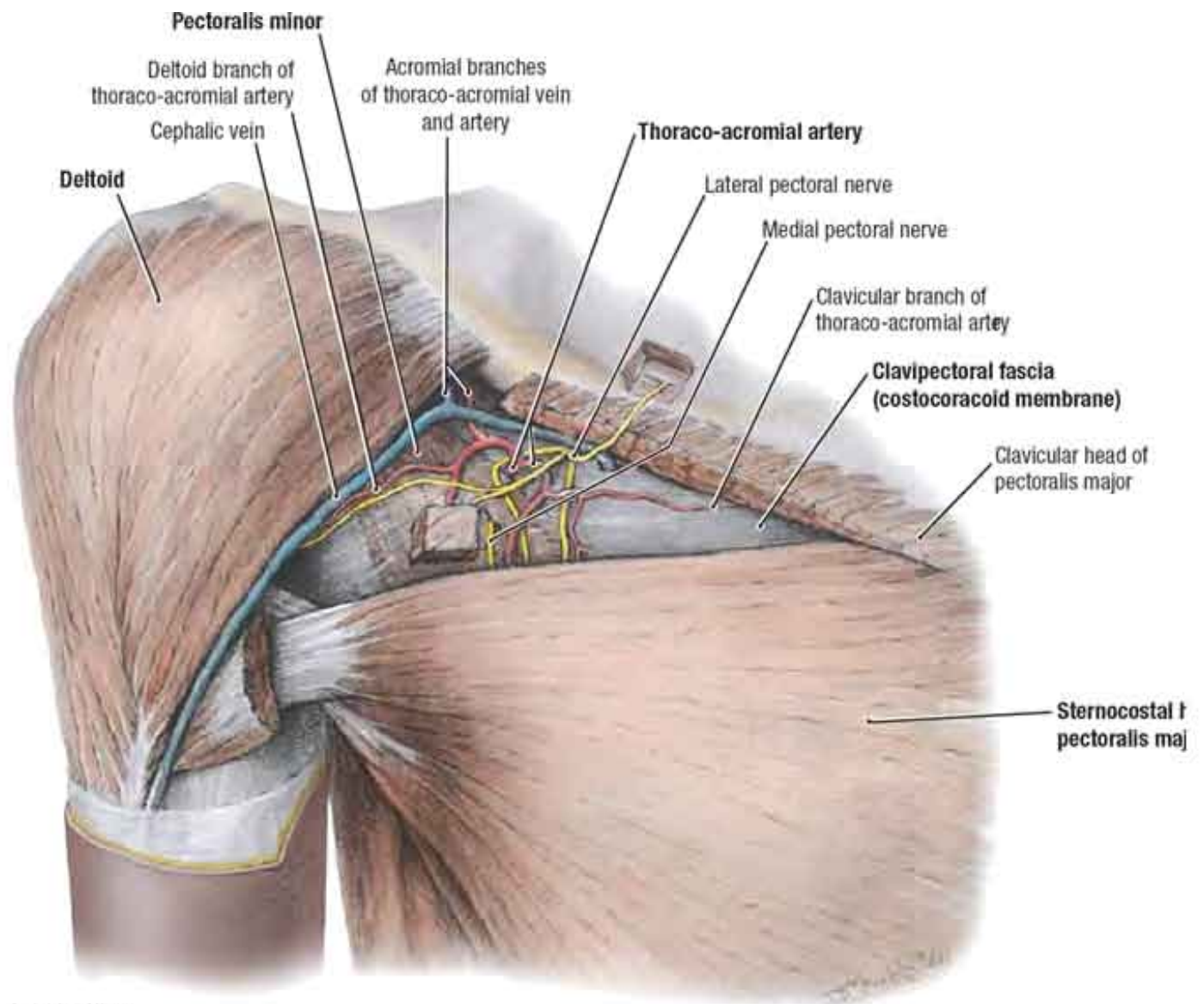
---

## 6.18 Anterior wall of axilla and clavipectoral fasc

*Part of* "Chapter 6 - Upper Limb "

A. Anterior wall of axilla. The clavicular head of the pectoralis major is excised, except for cubes of muscle that remain to identify the branches of the lateral pectoral nerve.

- The clavipectoral fascia superior to the pectoralis minor (costocoracoid membrane) pierced by the cephalic vein, the lateral pectoral nerve, and the thoraco-acromial vessels.
- The pectoralis minor and clavipectoral fascia are pierced by the medial pectoral nerve.
- Observe the trilaminar insertion of the pectoralis major from deep to superficial: inferior part of the sternocostal head, superior part of the sternocostal head, and clavicular head.



**Anterior View**

Authors: Agur, Anne M.R.; Dalley, Arthur F.

Title: *Grant's Atlas of Anatomy, 12th Edition*

Copyright ©2009 Lippincott Williams & Wilkins

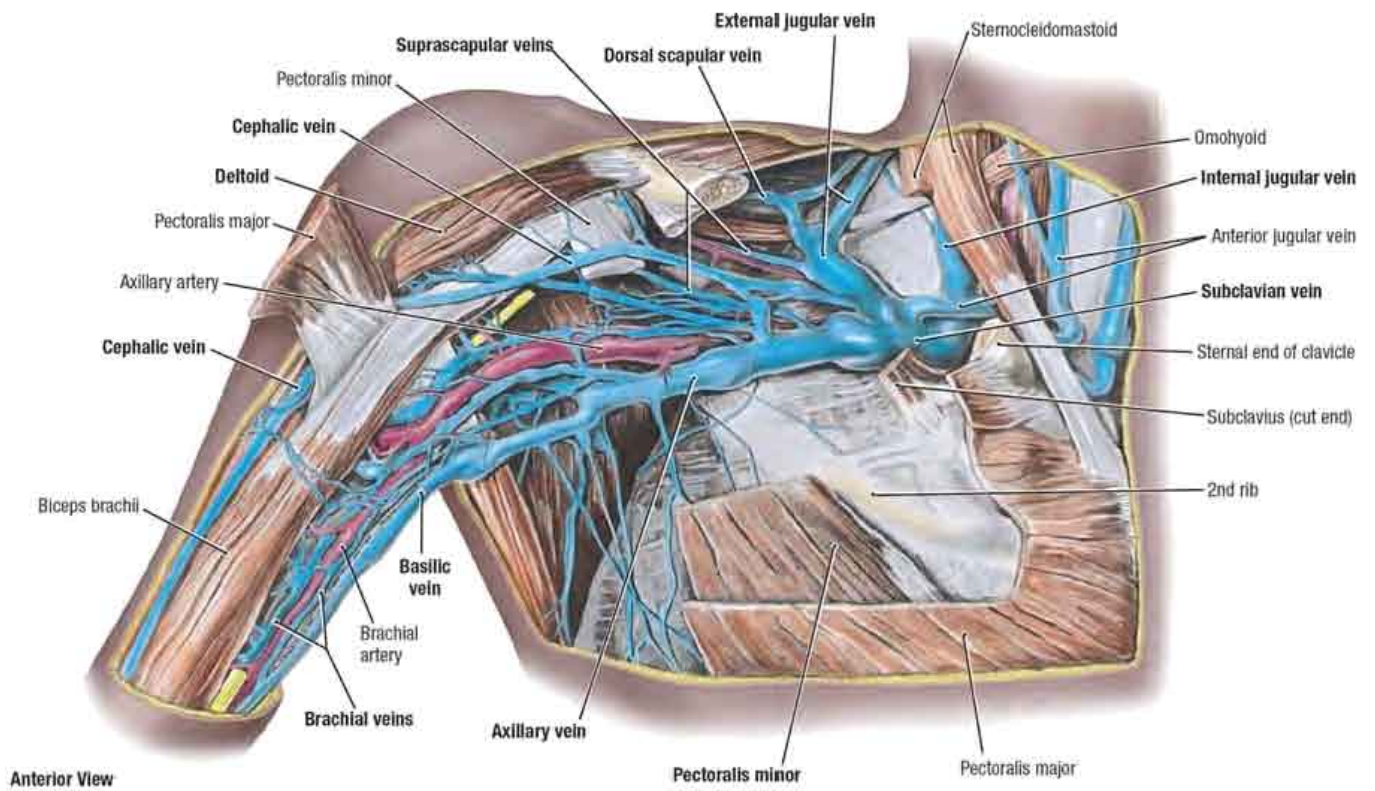
> Table of Contents > Chapter 6 - Upper Limb > 6.19 Veins of axilla

---

## 6.19 Veins of axilla

*Part of "Chapter 6 - Upper Limb "*

- The basilic vein joins the brachial veins to become the axillary vein near the inferior border of teres major, the axillary vein becomes the subclavian vein at the lateral border of the 1st rib, and the subclavian joins the internal jugular to become the brachiocephalic vein posterior to the sternal end of the clavicle.
- Numerous valves, enlargements in the vein, are shown.
- The cephalic vein in this specimen bifurcates to end in the axillary and external jugular veins.



Authors: Agur, Anne M.R.; Dalley, Arthur F.

Title: *Grant's Atlas of Anatomy, 12th Edition*

Copyright ©2009 Lippincott Williams & Wilkins

> Table of Contents > Chapter 6 - Upper Limb > 6.20 Walls and contents of the axilla

---

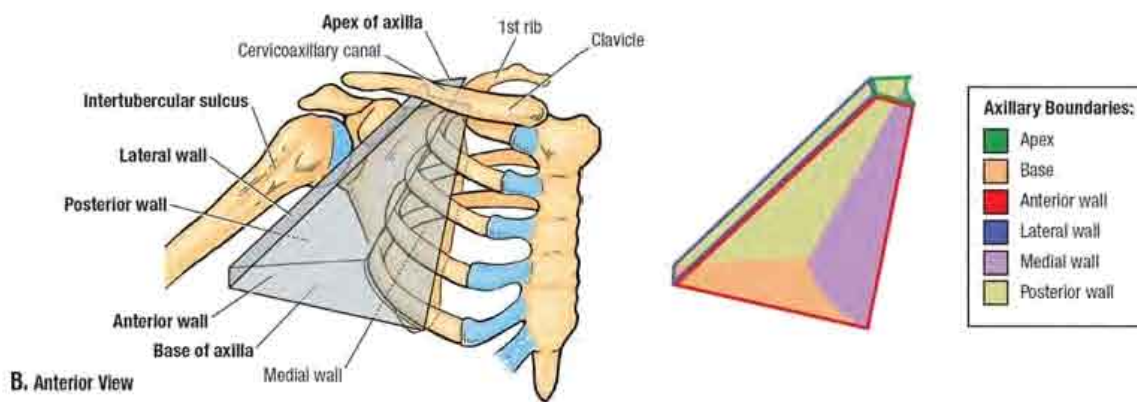
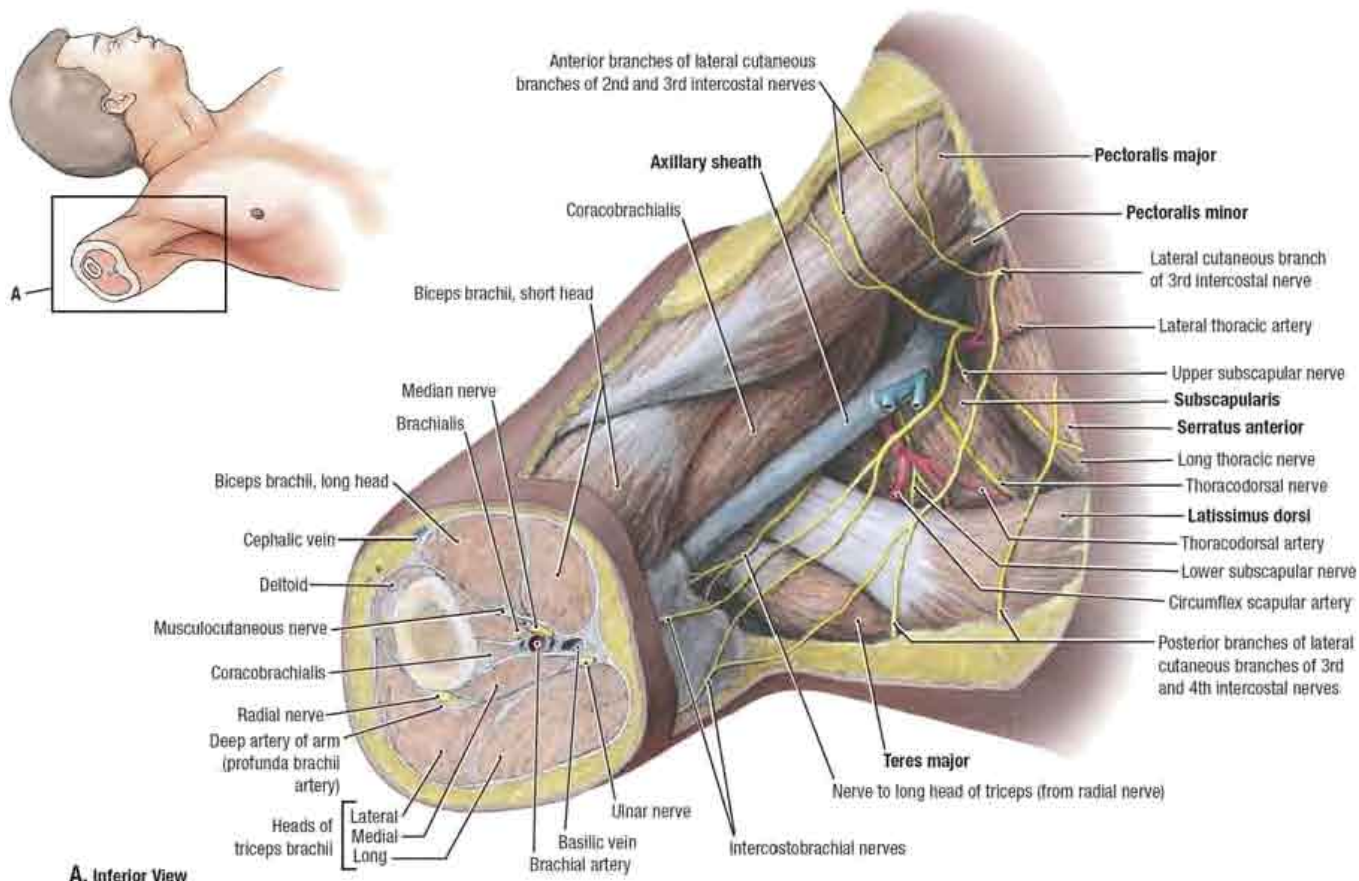
## 6.20 Walls and contents of the axilla

*Part of* "Chapter 6 - Upper Limb "

A. Dissection. B. Location and walls of axilla, schematic diagram.

- The walls of the axilla are: anterior (formed by the pectoralis major, pectoralis minor, and subclavius muscles), posterior (formed by subscapularis, latissimus dorsi, and teres major muscles), medial (formed by the serratus anterior muscle), and lateral (formed by the intertubercular sulcus [bicipital groove] of the humerus [concealed by the biceps and coracobrachialis muscles]).
- The axillary sheath surrounds the nerves and vessels (neurovascular bundle) of the upper limb.





Authors: Agur, Anne M.R.; Dalley, Arthur F.

Title: *Grant's Atlas of Anatomy, 12th Edition*

Copyright ©2009 Lippincott Williams & Wilkins

> Table of Contents > Chapter 6 - Upper Limb > 6.21 Transverse sections through the shoulder joint and axilla

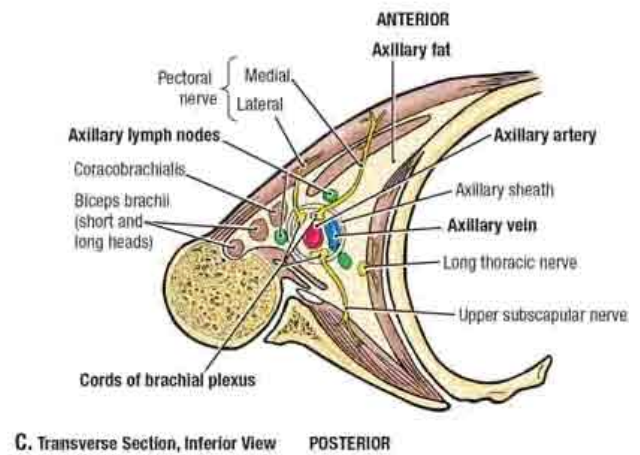
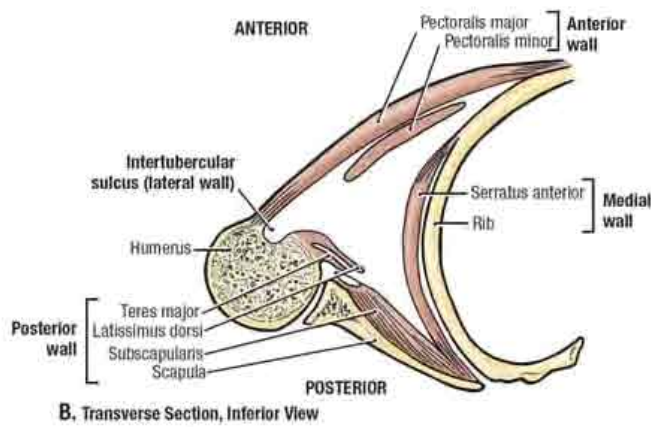
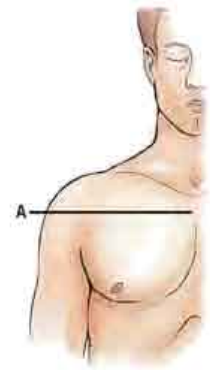
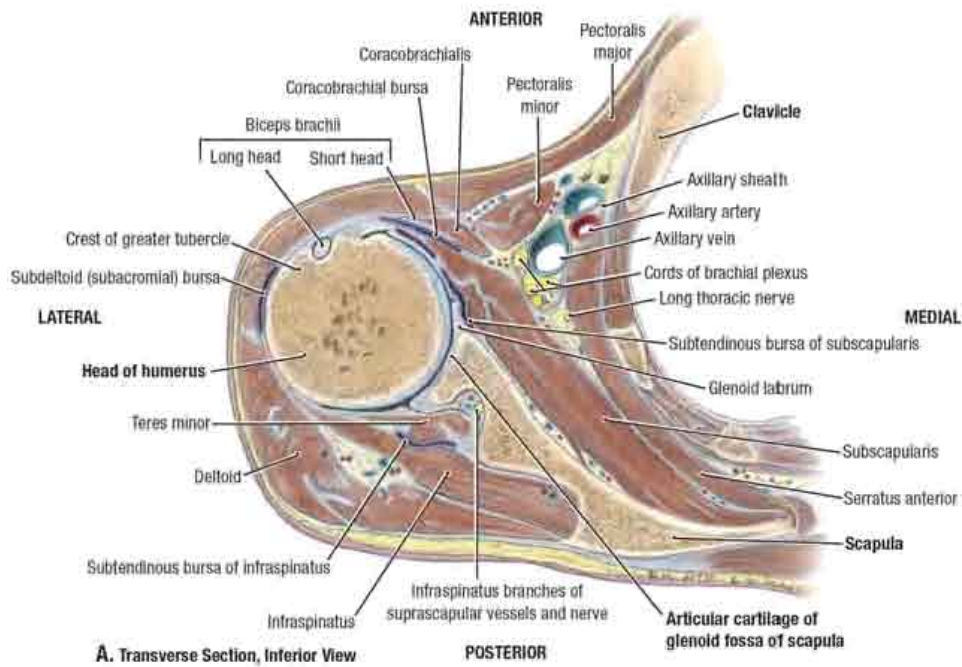
---

## 6.21 Transverse sections through the shoulder joint and axilla

*Part of* "Chapter 6 - Upper Limb "

A. Anatomical section. B. Walls of axilla, schematic illustration. C. Walls and contents of axilla, schematic illustration.

- The intertubercular sulcus (bicipital groove) containing the tendon of the long head of the biceps brachii muscle is directed anteriorly; the short head of the biceps muscle and the coracobrachialis and pectoralis minor muscles are sectioned just inferior to their attachments to the coracoid process.
- The small glenoid cavity is deepened by the glenoid labrum.
- Bursae include the subdeltoid (subacromial) bursa, between the deltoid and greater tubercle; the subtendinous bursa of subscapularis, between the subscapularis tendon and scapula; and coracobrachial bursa, between the coracobrachialis and subscapularis.
- The axillary sheath encloses the axillary artery and vein and the three cords of the brachial plexus to form a neurovascular bundle, surrounded by axillary fat.



Authors: Agur, Anne M.R.; Dalley, Arthur F.

Title: *Grant's Atlas of Anatomy, 12th Edition*

Copyright ©2009 Lippincott Williams & Wilkins

> Table of Contents > Chapter 6 - Upper Limb > 6.22 Arteries of the proximal upper limb

---

## 6.22 Arteries of the proximal upper limb

*Part of* "Chapter 6 - Upper Limb "

A and B. Schematic illustrations. C. Axillary arteriogram.

---

P.505

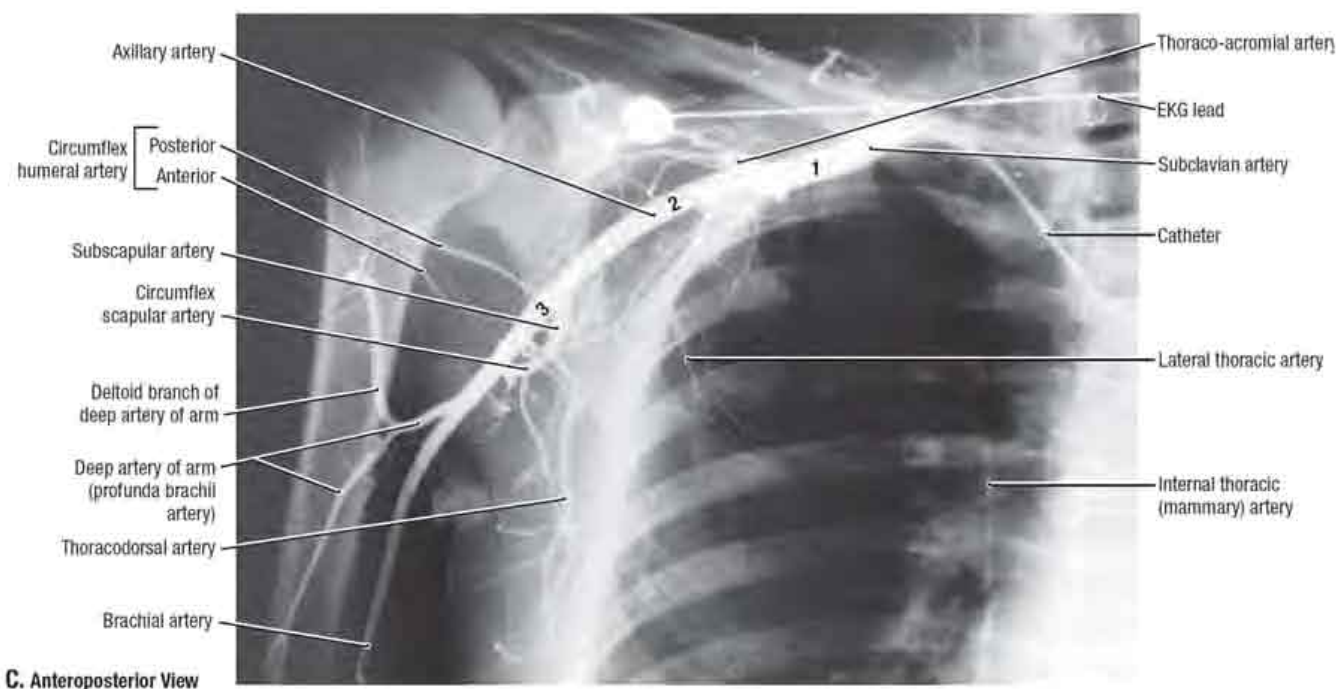
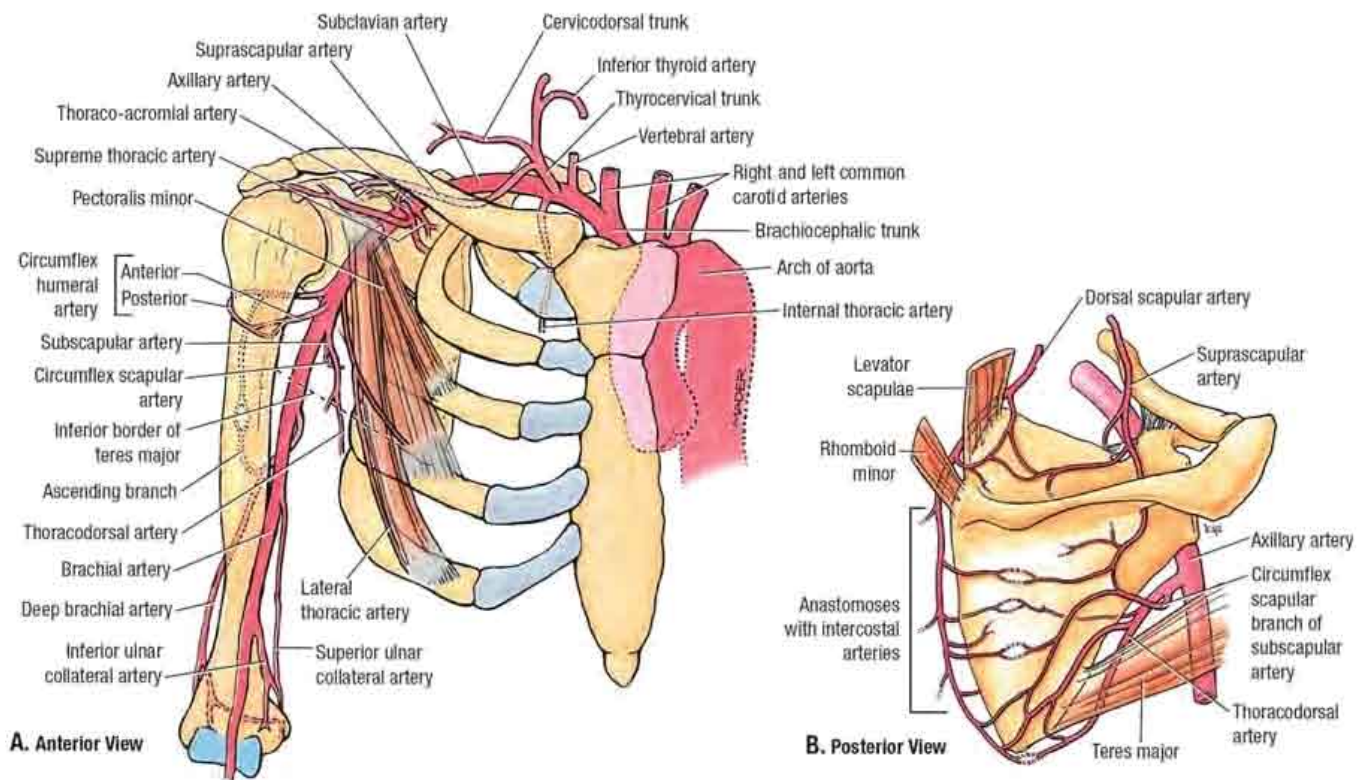


Artery	Origin	Course	
Internal thoracic	Subclavian artery	Descends, inclining anteromedially, posterior to sternal end of clavicle and first costal cartilage; enters thorax to descend in parasternal plane; gives rise to perforating branches, anterior intercostal, musculophrenic, and superior epigastric arteries	
Thyrocervical trunk		Ascends as a short, wide trunk, often giving rise to the suprascapular artery and/or cervicodorsal trunk and terminating by bifurcating into the ascending cervical and inferior thyroid arteries	
Suprascapular	Cervicodorsal trunk from thyrocervical trunk (or as direct branch of subclavian artery*)	Passes inferolaterally over anterior scalene muscle and phrenic nerve, subclavian artery and brachial plexus running laterally posterior and parallel to clavicle; next passes over transverse scapular ligament to supraspinous fossa, then lateral to scapular spine (deep to acromion) to infraspinous fossa	
Supreme thoracic	1st part (as only branch)	Axillary artery Runs anteromedially along superior border of pectoralis minor; then passes between it and pectoralis major to thoracic wall; helps supply 1st and 2nd intercostal spaces and superior part of serratus anterior	
Thoraco-acromial	2nd part (medial branch)		Curls around superomedial border of pectoralis minor, pierces costocoracoid membrane (clavipectoral fascia), and divides into four branches: pectoral, deltoid, acromial, and clavicular
Lateral thoracic	2nd part (lateral branch)		Descends along axillary border of pectoralis minor; follows it onto thoracic wall, supplying lateral aspect of breast
Circumflex humeral (anterior and posterior)	3rd part (sometimes via a common trunk)		Encircle surgical neck of humerus, anastomosing with each other laterally; larger posterior branch traverses quadrangular space
Subscapular	3rd part (largest branch)		Descends from level of inferior border of subscapularis along lateral border of scapula, dividing within 2-3 cm into terminal branches, the circumflex scapular and thoracodorsal arteries
Circumflex scapular	Subscapular artery	Brachial artery Curves around lateral border of scapula to enter infraspinous fossa, anastomosing with subscapular artery Continuation course of subscapular artery; accompanies thoracodorsal nerve to enter latissimus dorsi Accompanies radial nerve through radial groove of humerus, supplying posterior compartment of arm and participating in periarticular arterial anastomosis around elbow joint Accompanies ulnar nerve to posterior aspect of elbow; anastomoses with posterior ulnar recurrent artery Passes anterior to medial epicondyle of humerus to anastomose with anterior ulnar collateral artery around elbow joint	
Thoracodorsal	Near its origin		
Deep brachial	Near middle of arm		
Superior ulnar collateral	Superior to medial epicondyle of humerus		
Inferior ulnar collateral			

\* See Weiglein JH, Monggi B, Schalk C, et al. Arteries in the posterior cervical triangle. *Clinical Anatomy* 2005;18:533-537.

Table 6.3 Arteries of Proximal Upper Limb (Shoulder Region and Arm)





- 1: First part of the axillary artery is located between the lateral border of the 1st rib and the medial border of pectoralis minor.
- 2: Second part of the axillary artery lies posterior to pectoralis minor.
- 3: Third part of the axillary artery extends from the lateral border of pectoralis minor to the inferior border of teres major, where it becomes the brachial artery.

Authors: Agur, Anne M.R.; Dalley, Arthur F.

Title: *Grant's Atlas of Anatomy, 12th Edition*

Copyright ©2009 Lippincott Williams & Wilkins

> Table of Contents > Chapter 6 - Upper Limb > 6.23 Brachial plexus

---

## 6.23 Brachial plexus

*Part of* "Chapter 6 - Upper Limb "

A. Dissection. B. Schematic illustration.

---

P.507

Supraclavicular branches

Dorsal scapular

Anterior ramus of C5 with a frequent contribution from C4

Pierces scalenus medius, descends deep to levator scapulae, and enters deep surface of rhomboids

Rhomboids and occasionally supplies levator scapulae

Long thoracic

Anterior rami of C5–C7

Descends posterior to C8 and T1 rami and passes distally on external surface of serratus anterior

Serratus anterior

Subclavian

Superior trunk receiving fibers from C5 and C6 and often C4

Descends posterior to clavicle and anterior to brachial plexus and subclavian artery

Subclavius and sternoclavicular joint

Suprascapular

Superior trunk receiving fibers from C5 and C6 and often C4

Passes laterally across posterior triangle of neck, through suprascapular notch deep to superior transverse scapular ligament

Supraspinatus, infraspinatus, and glenohumeral (shoulder) joint

Infraclavicular branches

Lateral pectoral

Lateral cord receiving fibers from C5–C7

Pierces clavipectoral fascia to reach deep surface of pectoral muscles

Primarily pectoralis major but sends a loop to medial pectoral nerve that innervates pectoralis minor

Musculocutaneous

Lateral cord receiving fibers from C5–C7

Enters deep surface of coraco-brachialis and descends between biceps brachii and brachialis

Coracobrachialis, biceps brachii, and brachialis; continues as lateral cutaneous nerve of forearm

Median

Lateral root of median nerve is a terminal branch of lateral cord (C6, C7); medial root of median nerve is a terminal branch of medial cord (C8, T1)

Lateral and medial roots merge to form median nerve lateral to axillary artery; crosses anterior to brachial artery to lie medial to artery in cubital fossa

Flexor muscles in forearm (except flexor carpi ulnaris, ulnar half of flexor digitorum profundus, and five hand muscles) and skin of palm and 3½ digits lateral to a line bisecting 4th digit and the dorsum of the distal halves of these digits

Medial pectoral

Medial cord receiving fibers from C8, T1

Passes between axillary artery and vein and enters deep surface of pectoralis minor

Pectoralis minor and part of pectoralis major

Medial cutaneous nerve of arm

Medial cord receiving fibers from C8, T1

Runs along the medial side of axillary vein and communicates with inter-costo-brachial nerve

Skin on medial side of arm

Medial cutaneous nerve of forearm

Medial cord receiving fibers from C8, T1

Runs between axillary artery and vein

Skin over medial side of forearm

Ulnar

A terminal branch of medial cord receiving fibers from C8, T1 and often C7

Passes down medial aspect of arm and runs posterior to medial epicondyle to enter forearm

Innervates 1½ flexor muscles in forearm, most small muscles in hand, and skin of hand medial to a line bisecting 4th digit (ring finger) anteriorly and posteriorly

Upper subscapular

Branch of posterior cord receiving fibers from C5

Passes posteriorly and enters subscapularis

Superior portion of subscapularis

Thoracodorsal

Branch of posterior cord receiving fibers from C6–C8

Arises between upper and lower subscapular nerves and runs inferolaterally to latissimus dorsi

Latissimus dorsi

Lower subscapular

Branch of posterior cord receiving fibers from C6

Passes inferolaterally, deep to subscapular artery and vein, to subscapularis and teres major

Inferior portion of subscapularis and teres major

Axillary

Terminal branch of posterior cord receiving fibers from C5 and C6

Passes to posterior aspect of arm through quadrangular space in company with posterior circumflex humeral artery and then winds around surgical neck of humerus; gives rise to lateral cutaneous nerve of arm

Teres minor and deltoid, glenohumeral (shoulder) joint, and skin of superolateral part of arm

Radial

Terminal branch of posterior cord receiving fibers from C5–T1

Descends posterior to axillary artery; enters radial groove to pass between long and medial heads of triceps

Triceps brachii, anconeus, brachioradialis, and extensor muscles of forearm; supplies skin on posterior aspect of arm and forearm and dorsum of hand lateral to axial line of digit 4

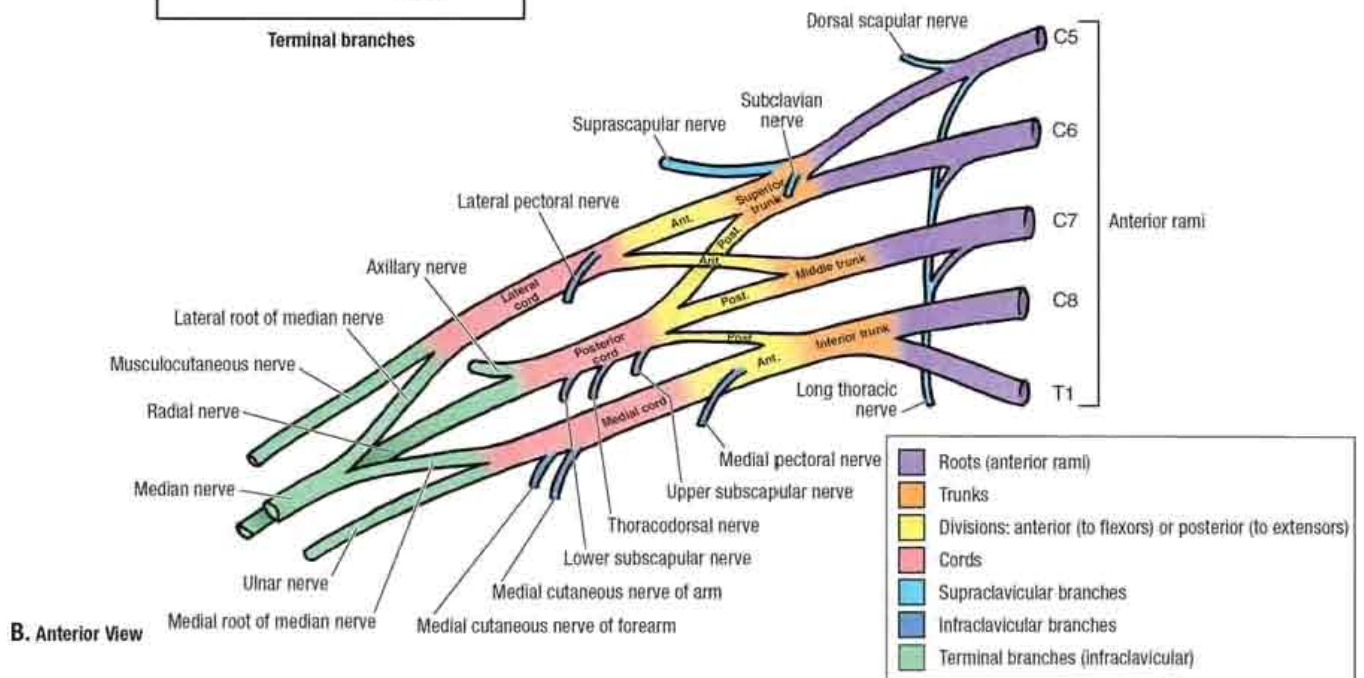
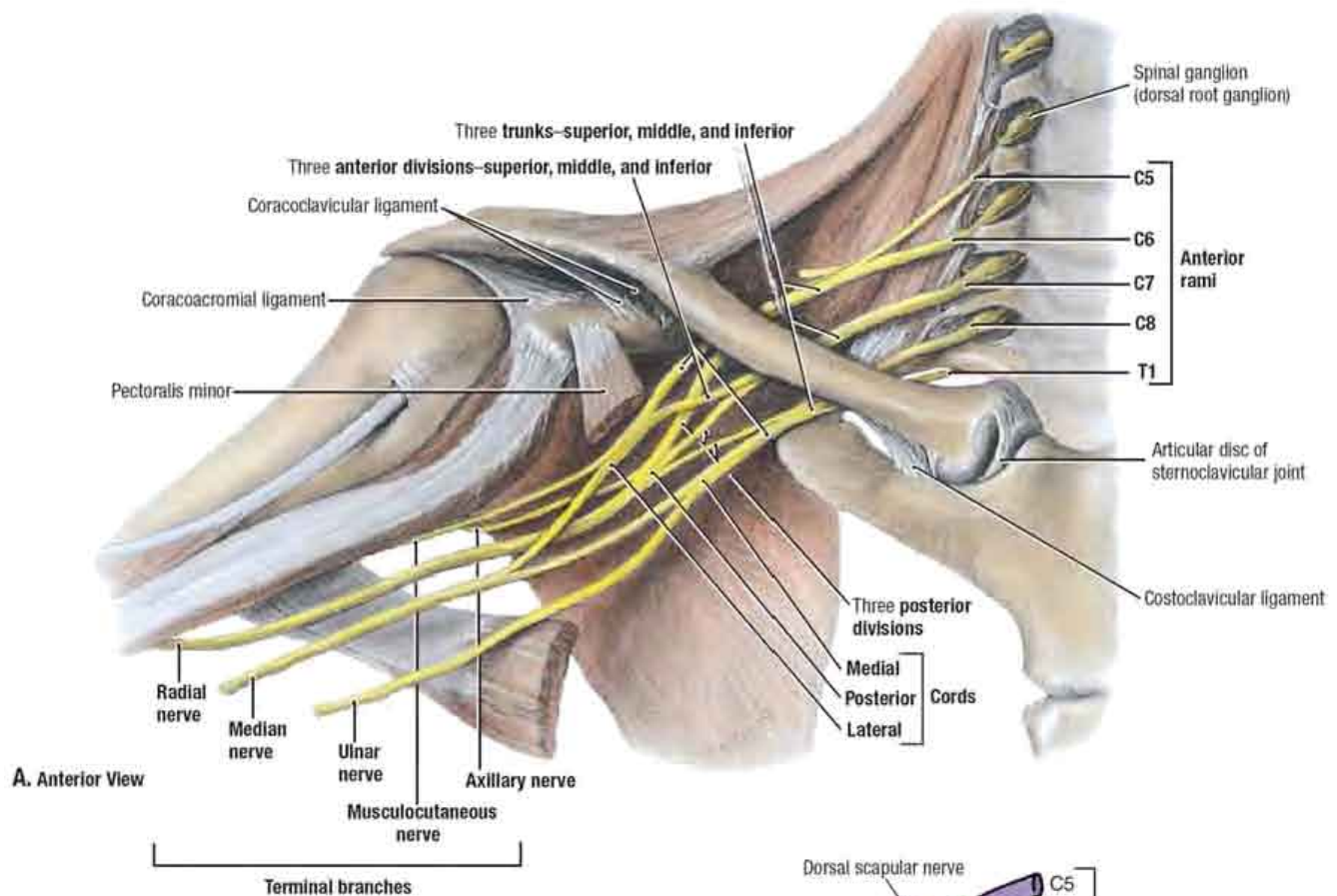
<sup>a</sup> Quadrangular space is bounded superiorly by subscapularis and teres minor, inferiorly by teres major, medially by long head of triceps, and laterally by humerus.

Nerve    Origin    Course    Distribution/Structure(s) Supplied

Table 6.4 Axilla, Axillary Vessels, and Brachial Plexus

P.508





Authors: Agur, Anne M.R.; Dalley, Arthur F.

Title: *Grant's Atlas of Anatomy, 12th Edition*

Copyright ©2009 Lippincott Williams & Wilkins

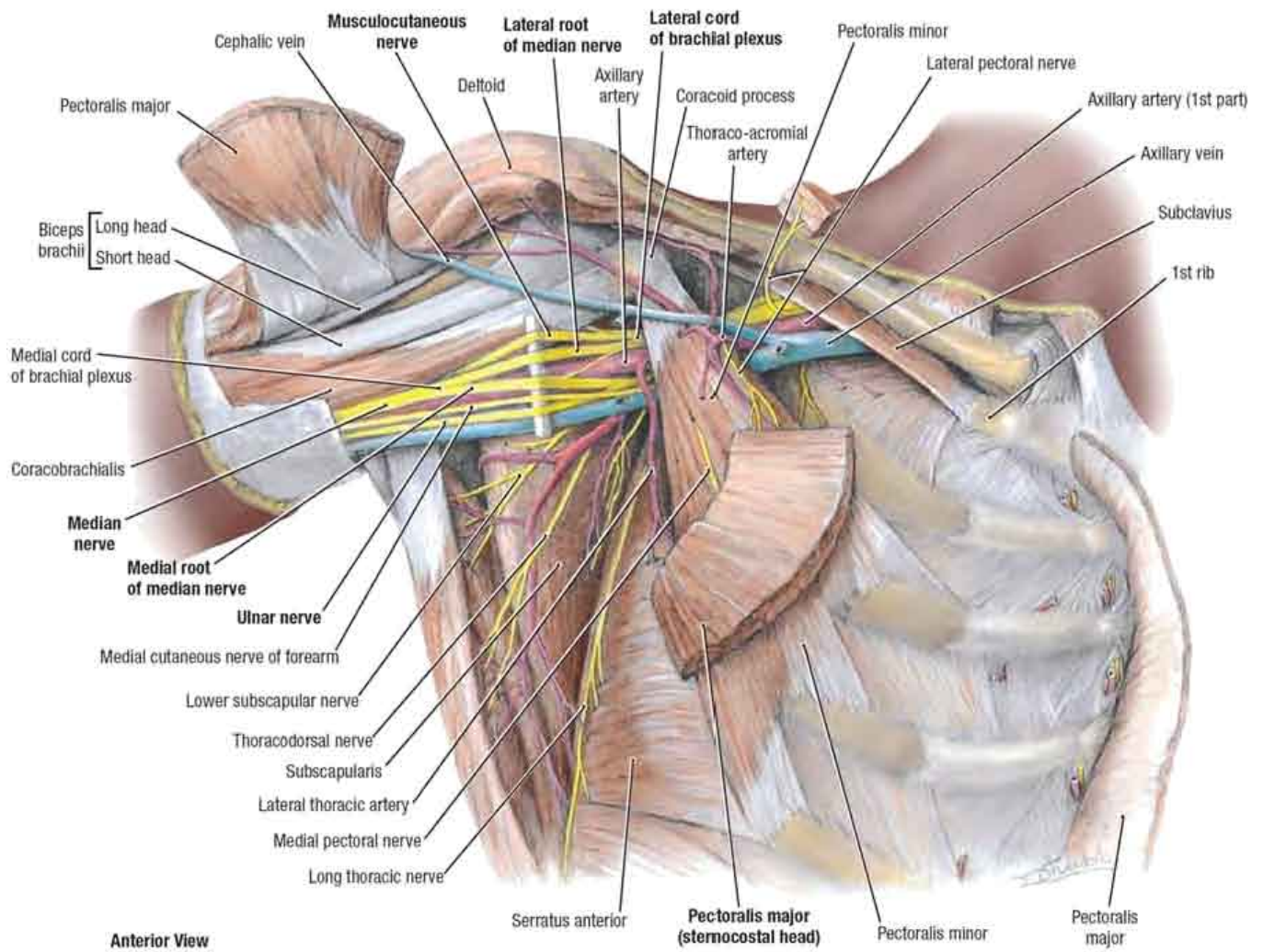
> Table of Contents > Chapter 6 - Upper Limb > 6.24 Structures of axilla: Deep dissection I

---

## 6.24 Structures of axilla: Deep dissection I

*Part of "Chapter 6 - Upper Limb "*

- The pectoralis major muscle is reflected, and the clavipectoral fascia is removed; the cube of muscle superior to the clavicle is cut from the clavicular head of the pectoralis major muscle.
- The subclavius and pectoralis minor are the two deep muscles of the anterior wall.
- The 2nd part axillary artery passes posterior to the pectoralis minor muscle, a fingerbreadth from the tip of the coracoid process; the axillary vein lies anterior and then medial to the axillary artery.
- The median nerve, followed proximally, leads by its lateral root to the lateral cord and musculocutaneous nerve and by its medial root to the medial cord and ulnar nerve. These four nerves and the medial cutaneous nerve of the forearm are derived from the anterior division of the brachial plexus and are raised on a stick. The lateral root of the median nerve may occur as several strands.
- The musculocutaneous nerve enters the flexor compartment of the arm by piercing the coracobrachialis muscle.



Authors: Agur, Anne M.R.; Dalley, Arthur F.

Title: *Grant's Atlas of Anatomy, 12th Edition*

Copyright ©2009 Lippincott Williams & Wilkins

> Table of Contents > Chapter 6 - Upper Limb > 6.25 Posterior and medial walls of axilla:

Deep dissection II

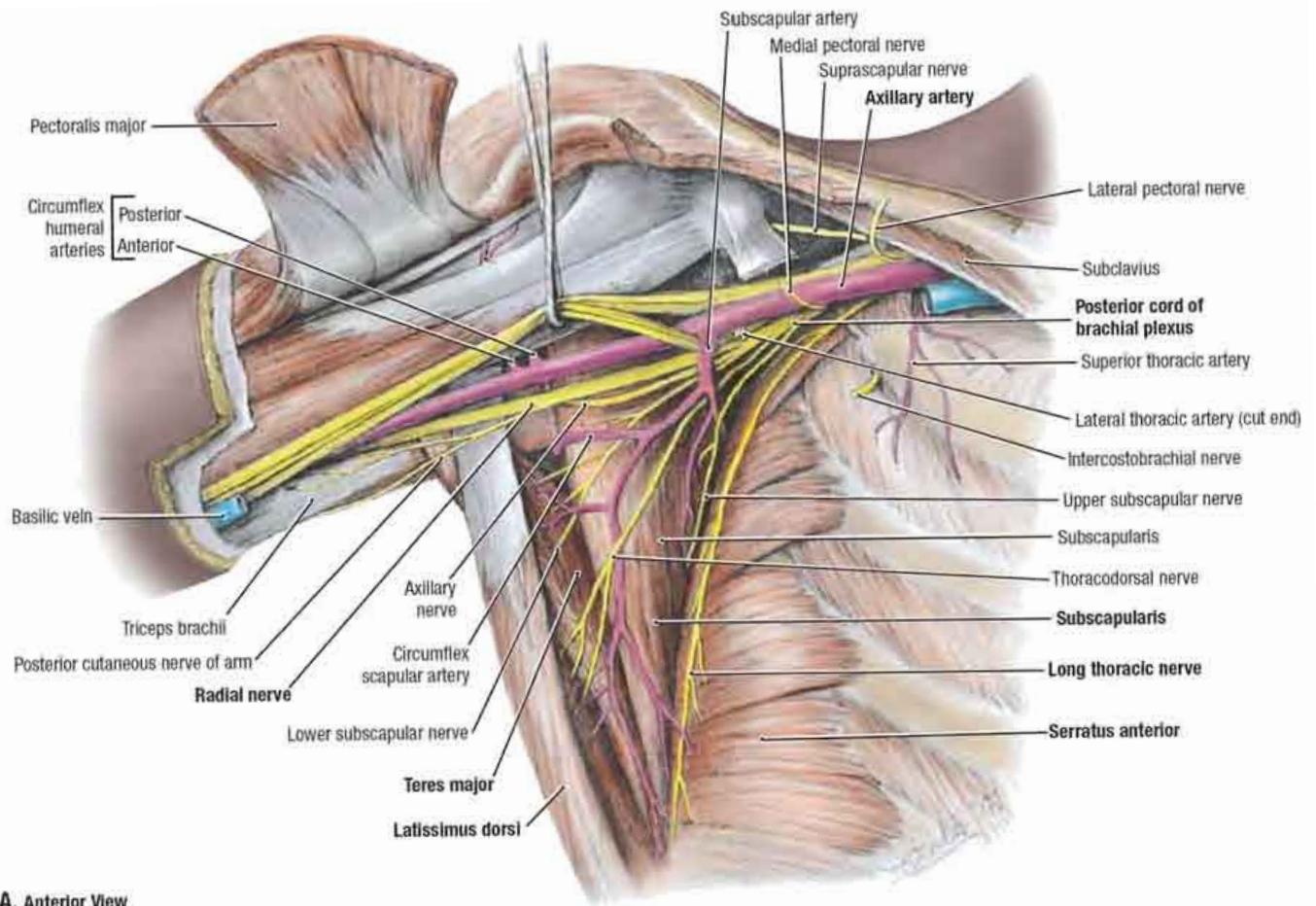
---

## 6.25 Posterior and medial walls of axilla: Deep dissection II

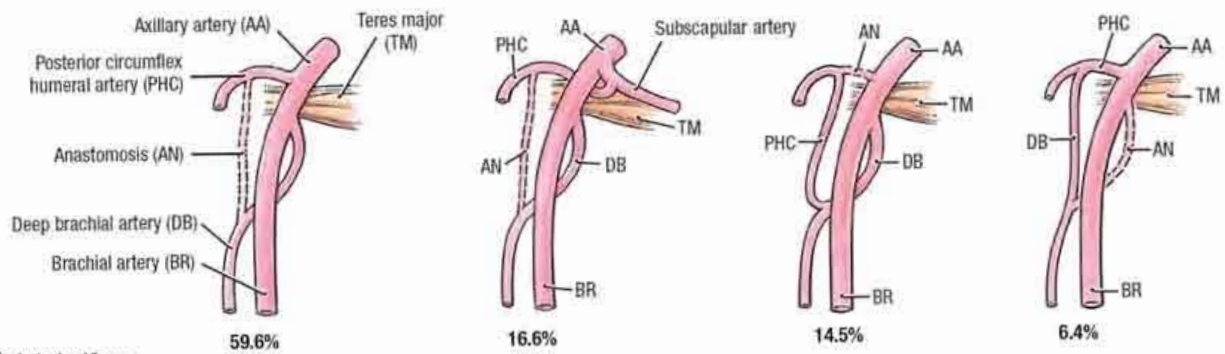
*Part of* "Chapter 6 - Upper Limb "

A. Dissection. The pectoralis minor muscle is excised, the lateral and medial cords of the brachial plexus are retracted, and the axillary vein is removed. B. Variations of the posterior circumflex humeral artery and deep artery of arm. Percentages are based on 235 specimens.





**A. Anterior View**



**B. Anterior Views**



Authors: Agur, Anne M.R.; Dalley, Arthur F.

Title: *Grant's Atlas of Anatomy, 12th Edition*

Copyright ©2009 Lippincott Williams & Wilkins

> Table of Contents > Chapter 6 - Upper Limb > 6.26 Posterior wall of axilla, musculocutaneous nerve, and posterior cord: Deep dissection III

---

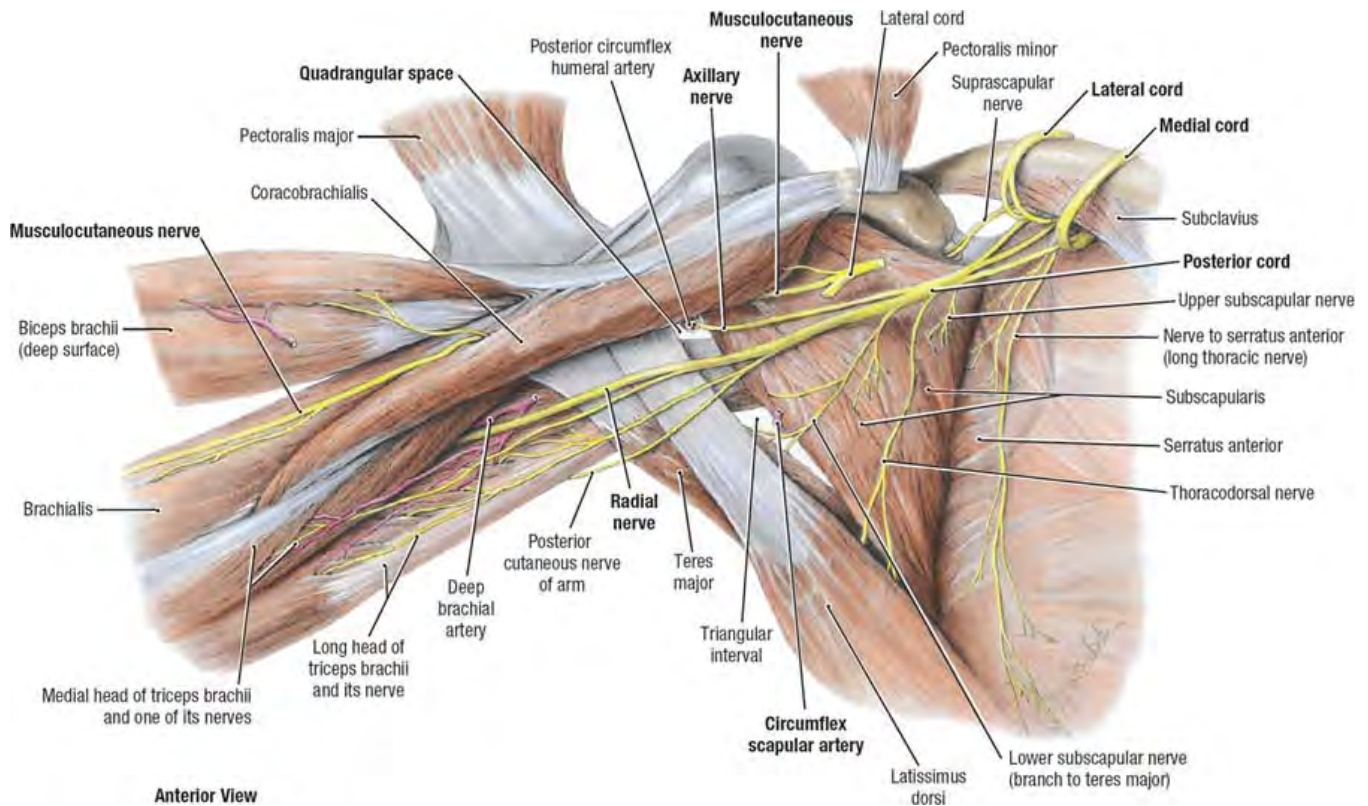
## 6.26 Posterior wall of axilla, musculocutaneous nerve, and posterior cord: Deep dissection III

*Part of "Chapter 6 - Upper Limb "*

- The pectoralis major and minor muscles are reflected laterally, the lateral and medial cords of the brachial plexus are reflected superiorly, and the arteries, veins, and median and ulnar nerves are removed.
- Coracobrachialis arises with the short head of the biceps brachii muscle from the tip of the coracoid process and attaches halfway down the medial aspect of the humerus.
- The musculocutaneous nerve pierces the coracobrachialis muscle and supplies it, the biceps, and the brachialis before becoming the lateral cutaneous nerve of the forearm.
- The posterior cord of the plexus is formed by the union of the three posterior divisions; it supplies the three muscles of the posterior wall of the axilla and then bifurcates into the radial and axillary nerves.
- In the axilla, the radial nerve gives off the nerve to the long head of the triceps brachii muscle and a cutaneous branch; in this specimen, it also gives off a branch to the medial head of the triceps. It then enters the radial groove of the humerus with the deep brachial (profunda brachii) artery.
- The axillary nerve passes through the quadrangular space along with the posterior circumflex humeral artery. The borders of the quadrangular space are superiorly,

the lateral border of the scapula; inferiorly, the teres major; laterally, the humerus (surgical neck); and medially, the long head of triceps brachii. The circumflex scapular artery traverses the triangular interval.

P.511



Authors: Agur, Anne M.R.; Dalley, Arthur F.

Title: *Grant's Atlas of Anatomy, 12th Edition*

Copyright ©2009 Lippincott Williams & Wilkins

> Table of Contents > Chapter 6 - Upper Limb > 6.27 Serratus anterior and subscapularis

---

## 6.27 Serratus anterior and subscapularis

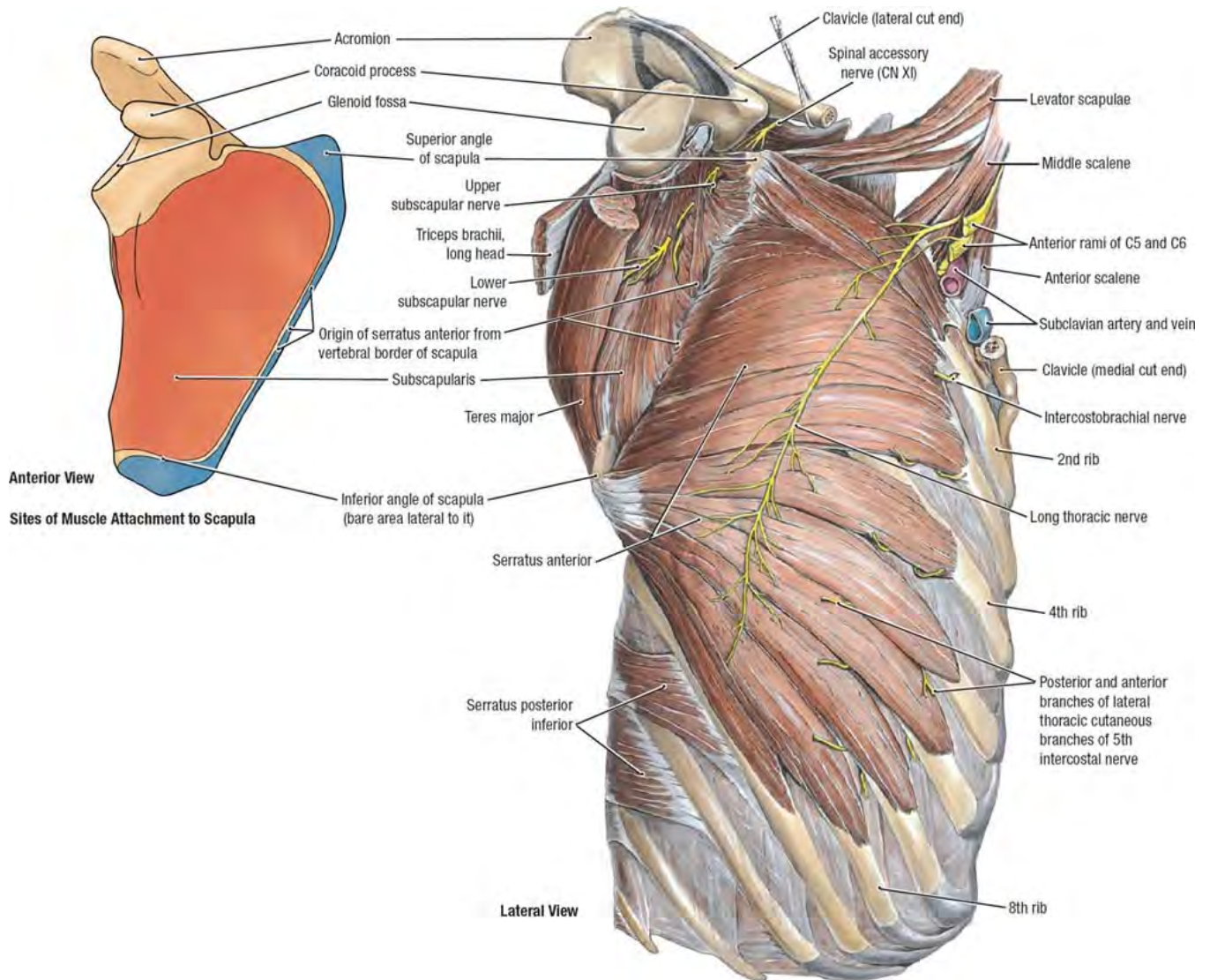
*Part of* "Chapter 6 - Upper Limb "

The serratus anterior muscle, which forms the medial wall of the axilla, has a fleshy belly extending from the superior 8 or 9 ribs in the midclavicular line (*right*) to the medial border of the scapula (*left*).

- The fibers of the serratus anterior muscle from the 1st rib and the tendinous arch between the 1st and 2nd ribs (see Table 6.2 ) converge on the superior angle of the scapula; those from the 2nd and 3rd ribs diverge to spread thinly along the medial border; and the remainder (from the 4th to 9th ribs), which form the bulk of the muscle, converge on the inferior angle via a tendinous insertion.
  - The long thoracic nerve to serratus anterior arises from spinal nerves C5, C6, and C7 and courses externally along most of the muscle's length.
- When the serratus anterior is paralyzed because of injury to the long thoracic nerve, the medial border of the scapula moves laterally and posteriorly, away from the thoracic wall. When the arm is abducted, the medial border and the inferior angle of the scapula pull away from the posterior thoracic wall, a deformation known as a winged scapula. In addition, the arm cannot be abducted above the horizontal position because the serratus anterior is unable to rotate the glenoid cavity superiorly.

- The trunks of the brachial plexus and the subclavian artery emerge between the anterior and middle scalene muscles (scalene triangle); the subclavian vein is separated from the artery by the anterior scalene muscle.

P.512



Authors: Agur, Anne M.R.; Dalley, Arthur F.

Title: *Grant's Atlas of Anatomy, 12th Edition*

Copyright ©2009 Lippincott Williams & Wilkins

> Table of Contents > Chapter 6 - Upper Limb > 6.28 Surface anatomy of superficial back

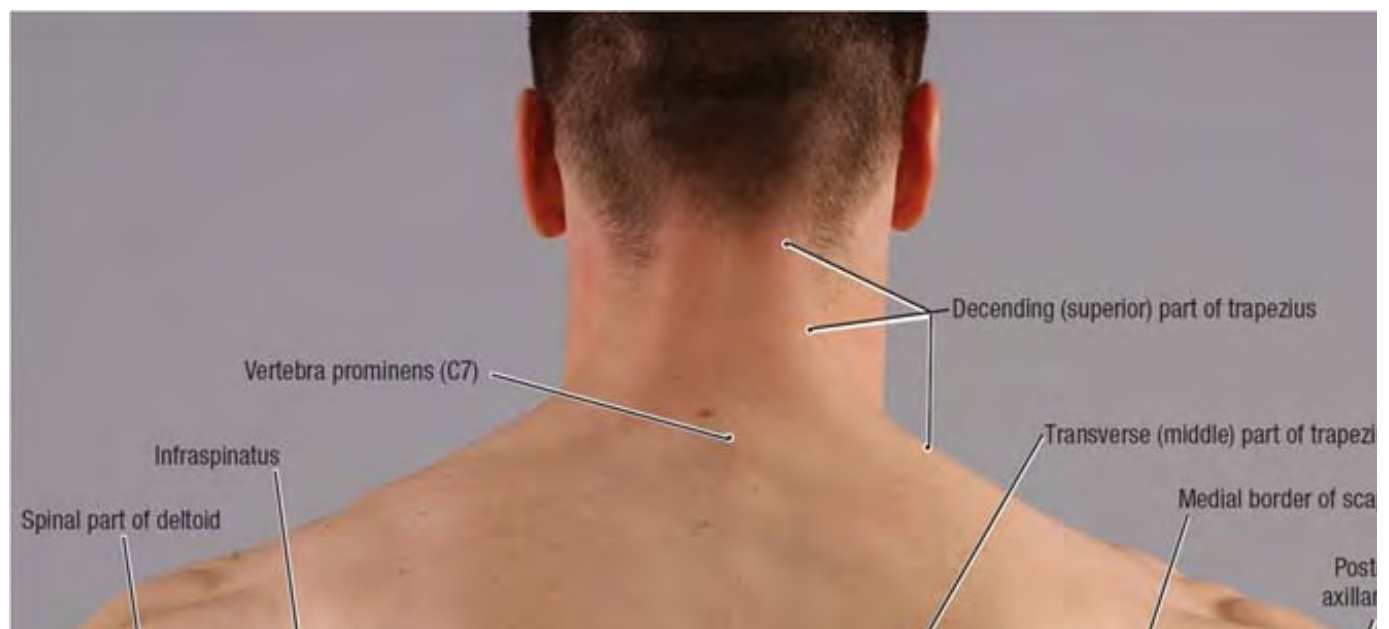
---

## 6.28 Surface anatomy of superficial back

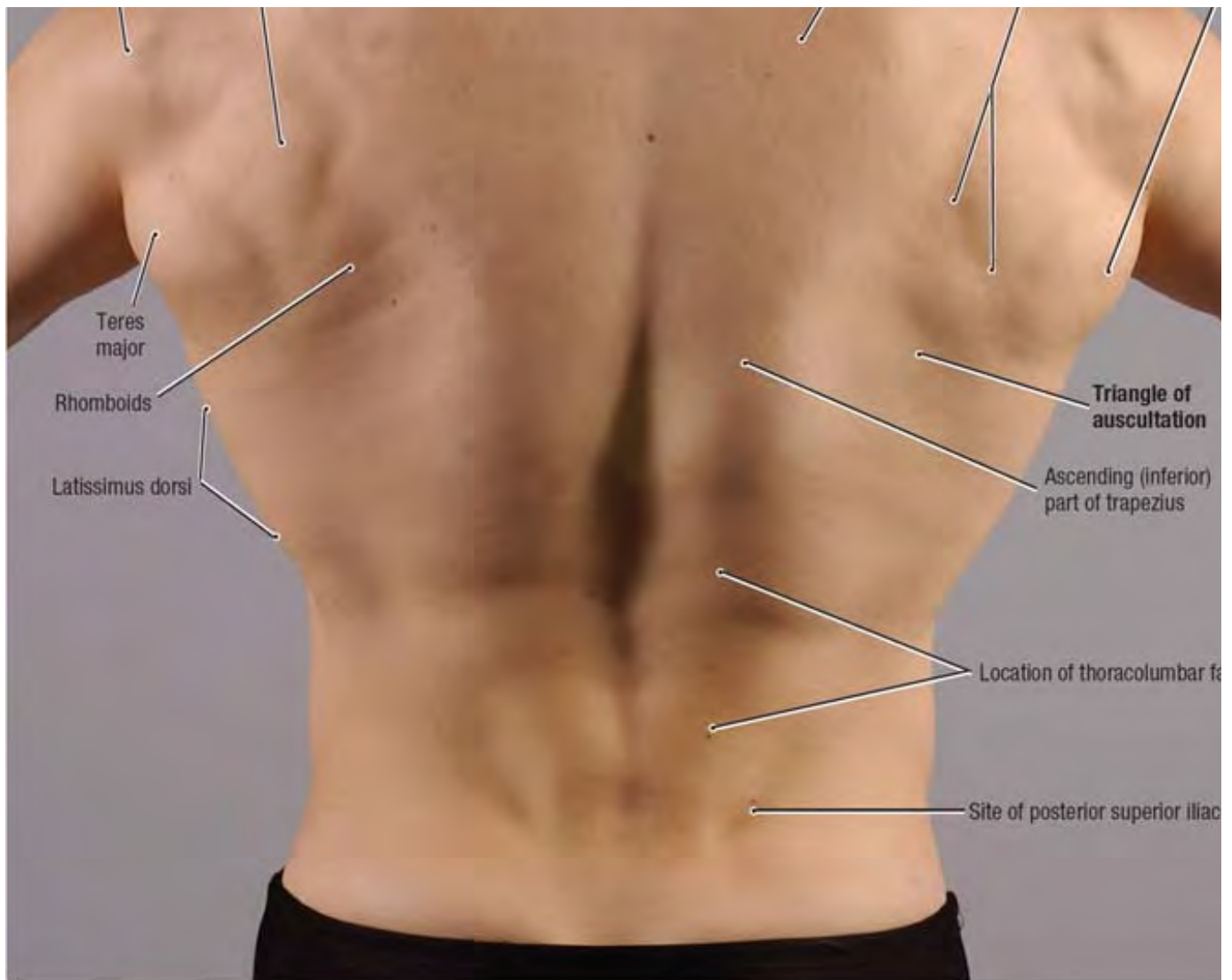*Part of "Chapter 6 - Upper Limb "*

The superior border of the latissimus dorsi and a part of the rhomboid major are overlapped by the trapezius. The area formed by the superior border of latissimus dorsi, the medial border of the scapula, and the inferolateral border of the trapezius is called the triangle of auscultation. This gap in the thick back musculature is a good place to examine posterior segments of the lungs with a stethoscope. When the scapulae are drawn anteriorly by folding the arms across the thorax and the trunk is flexed, the auscultatory triangle enlarges. The teres major forms a raised oval area on the inferolateral third of the posterior aspect of the scapula when the arm is adducted against resistance. The posterior axillary fold is formed by the teres major and the tendon of the latissimus dorsi.

P.513







**Posterior View**

## Trapezius

Medial third of superior nuchal line; external occipital protuberance, nuchal ligament, and spinous processes of T7–T12

Lateral third of clavicle, acromion, and spine of scapula

Spinal accessory nerve (CN XI) and cervical nerves (C3–C4)

Elevates, retracts, and rotates scapula; *descending part* elevates, *transverse part* retracts, *ascending part* depresses scapula; descending and ascending part act together in superior rotation of scapula

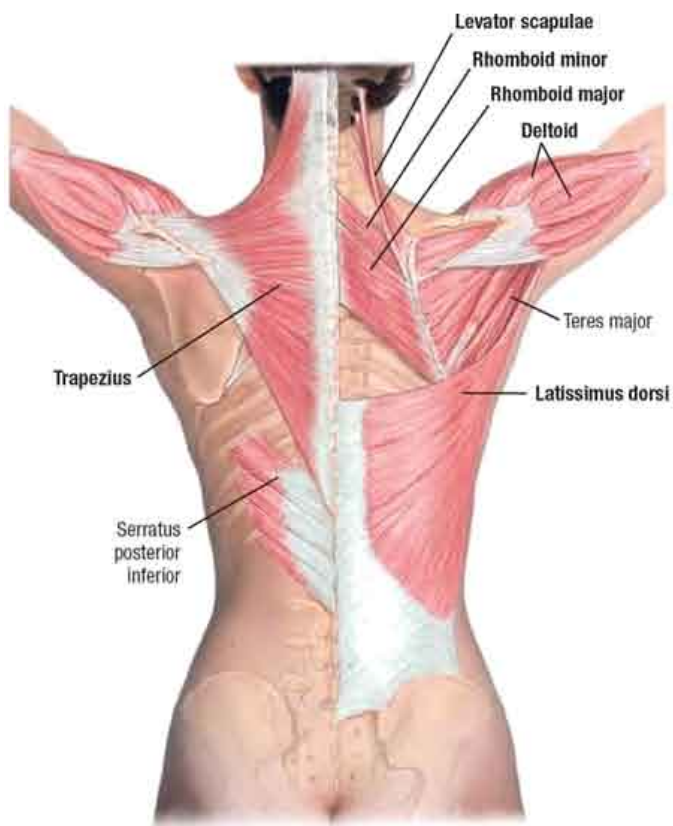
## Latissimus dorsi

Spinous processes of inferior six thoracic vertebrae, thoracolumbar fascia, iliac crest, and inferior three or four ribs

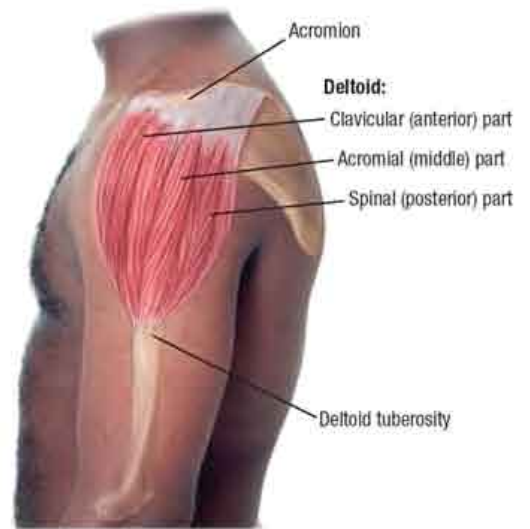
Intertubercular sulcus (bicipital groove) of humerus  
 Thoracodorsal nerve (C6–C8)  
 Extends, adducts, and medially rotates humerus; raises body toward arms during climbing  
 Levator scapulae  
 Posterior tubercles of transverse processes of C1–C4 vertebrae  
 Superior part of medial border of scapula  
 Dorsal scapular (C5) and cervical (C3–C4) nerves  
 Elevates scapula and tilts its glenoid cavity inferiorly by rotating scapula  
 Rhomboid minor and major  
*Minor:* nuchal ligament and spinous processes of C7 and T1 vertebrae  
*Major:* spinous processes of T2–T5 vertebrae  
 Medial border of scapula from level of spine to inferior angle  
 Dorsal scapular nerve (C4–C5)  
 Retracts scapula and rotates it to depress glenoid cavity; fixes scapula to thoracic wall  
 Deltoid  
 Lateral third of clavicle (*clavicular part*), acromion (*acromial part*), and spine (*spinal part*) of scapula  
 Deltoid tuberosity of humerus  
 Axillary nerve (C5–C6)  
*Clavicular (anterior) part:* flexes and medially rotates arm; *acromial (middle) part:* abducts arm; *spinal (posterior) part:* extends and laterally rotates arm

Muscle	Proximal Attachment	Distal Attachment	Innervation	Main Actions
--------	---------------------	-------------------	-------------	--------------

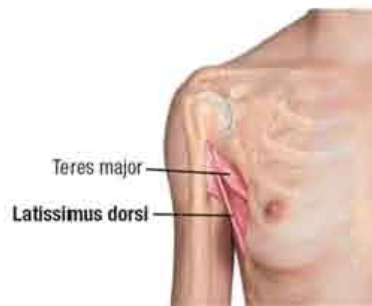
<p>Table 6.5 Superficial Back (Posterior Axioappendicular) and Deltoid Muscles</p>
--



Posterior View



Lateral View



Anterior View

Authors: Agur, Anne M.R.; Dalley, Arthur F.

Title: *Grant's Atlas of Anatomy, 12th Edition*

Copyright ©2009 Lippincott Williams & Wilkins

> Table of Contents > Chapter 6 - Upper Limb > 6.29 Cutaneous nerves of superficial back and posterior axioappendicular muscles

---

## 6.29 Cutaneous nerves of superficial back and posterior axioappendicular muscles

*Part of "Chapter 6 - Upper Limb "*

The trapezius muscle is cut and reflected on the left side. A superficial or first muscle layer consists of the trapezius and latissimus dorsi muscles, and a second layer of the levator scapulae and rhomboids. Cutaneous branches of posterior rami penetrate but do not supply the superficial muscles.

Boldface indicates prime movers. In the middle and right columns the dotted outlines represent the starting position for each movement.



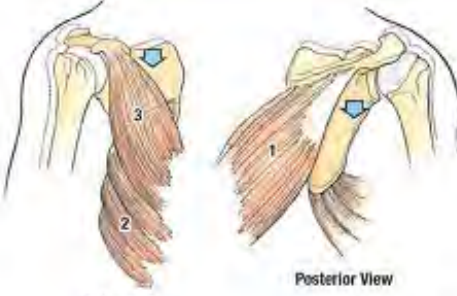
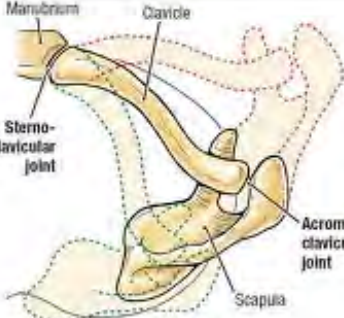



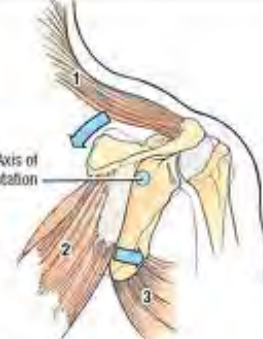
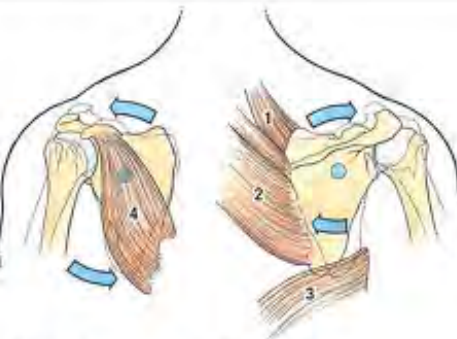
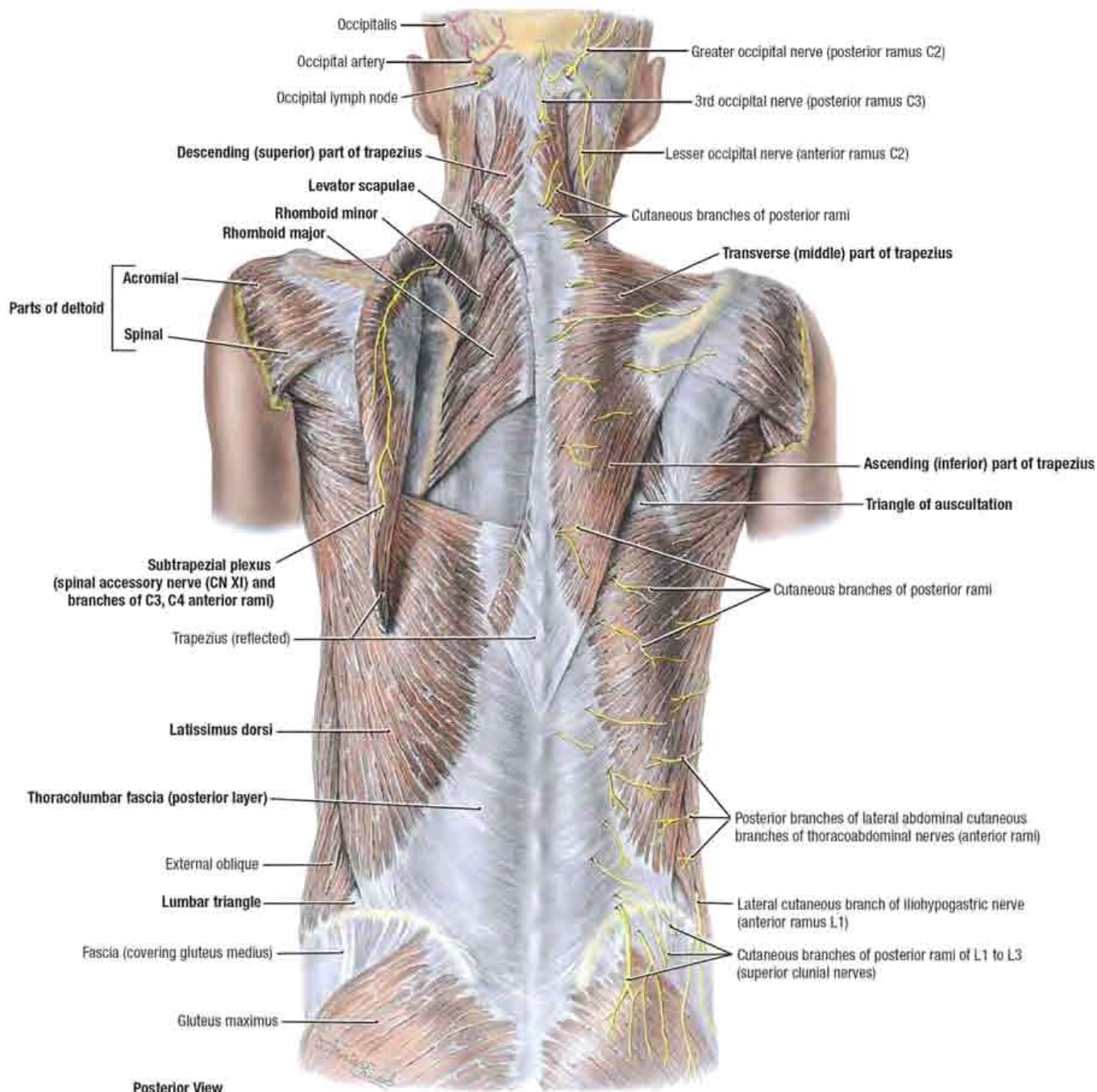
 <p><b>Posterior View</b> Elevation (red) Depression (green)</p>	 <p><b>Posterior View</b> Elevation: <b>Trapezius, superior part</b> (1) Levator scapulae (2) Rhomboids (3)</p>	 <p><b>Anterior View</b> Depression: Trapezius, inferior part (1) Serratus anterior, inferior part Pectoralis minor</p> <p><b>Posterior View</b> Also: Gravity, Latissimus dorsi, inferior sternocostal head of pectoralis major</p>
 <p><b>Superior View</b> Protraction (red) Retraction (green)</p>	 <p><b>Anterior View</b> Protraction: <b>Serratus anterior</b> (1) Pectoralis minor (2) Also: Pectoralis major</p>	 <p><b>Posterior View</b> Retraction: <b>Trapezius, middle part</b> (1) Rhomboids (2) Latissimus dorsi (3)</p>
 <p><b>Posterior View</b> Upward rotation (red)</p>	 <p><b>Posterior View</b> Upward rotation <b>Trapezius, superior part</b> (1) Trapezius, inferior part (2) <b>Serratus anterior, inferior part</b> (3)</p>	 <p><b>Anterior View</b> Downward rotation Levator scapulae (1) Rhomboids (2) <b>Latissimus dorsi</b> (3) Pectoralis minor (4)</p> <p><b>Posterior View</b> Also: Gravity, inferior sternocostal head of pectoralis major</p>

Table 6.6 Movements of Scapula





Authors: Agur, Anne M.R.; Dalley, Arthur F.

Title: *Grant's Atlas of Anatomy, 12th Edition*

Copyright ©2009 Lippincott Williams & Wilkins

> Table of Contents > Chapter 6 - Upper Limb > 6.30 Rotator cuff

---

## 6.30 Rotator cuff

*Part of "Chapter 6 - Upper Limb "*

A and B. Subscapularis. C and D. Supraspinatus, infraspinatus, and teres minor.

Four of the scapulohumeral muscles—supraspinatus, infraspinatus, teres minor, and subscapularis—are called rotator cuff muscles because they form a musculotendinous rotator cuff around the glenohumeral joint. All except the supraspinatus are rotators of the humerus.

---

P.517

E. Supraspinatus and supraspinatus tendon.

The supraspinatus, besides being part of the rotator cuff, initiates and assists the deltoid in the first 15° of abduction of the arm. The tendons of the rotator cuff muscles blend with the joint capsule of the glenohumeral joint, reinforcing it as the musculotendinous rotator cuff, which protects the joint and gives it stability.

Injury or disease may damage the rotator cuff, producing instability of the glenohumeral joint. Rupture or tear of the supraspinatus tendon is the most common injury of the rotator cuff. Degenerative tendinitis of the rotator cuff is common, especially in older people.

Supraspinatus (S)

Supraspinous fossa of scapula

Superior facet on greater tubercle of humerus

Suprascapular nerve (C4, C5, and C6)

Helps deltoid to abduct arm and acts with rotator cuff muscles<sup>a</sup>

Infraspinatus (I)

Infraspinous fossa of scapula

Middle facet on greater tubercle of humerus

Suprascapular nerve (C5 and C6)

Laterally rotates arm; helps to hold humeral head in glenoid cavity of scapula

Teres minor (T)

Superior part of lateral border of scapula

Inferior facet on greater tubercle of humerus

Axillary nerve (C5 and C6)

Subscapularis(S)

Subscapular fossa

Lesser tubercle of humerus

Upper and lower subscapular nerves (C5, C6, and C7)

Medially rotates arm and adducts it; helps to hold humeral head in glenoid cavity

Teres major <sup>b</sup>

Posterior surface of inferior angle of scapula

Crest of lesser tubercle (medial lip) of humerus

Lower subscapular nerve (C6 and C7)

Adducts and medially rotates arm

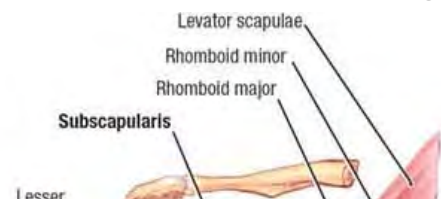
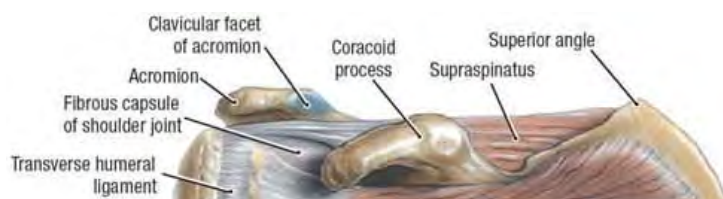
<sup>a</sup> Collectively, the supraspinatus, infraspinatus, teres minor, and subscapularis muscles are referred to as the rotator cuff muscles or “SITS” muscles. They function together during all movements of the shoulder joint to hold the head of the humerus in the glenoid cavity of scapula.

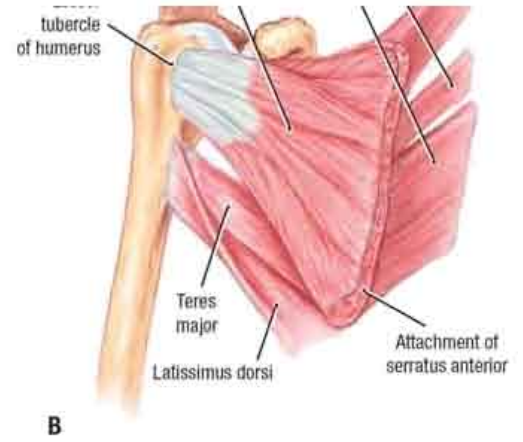
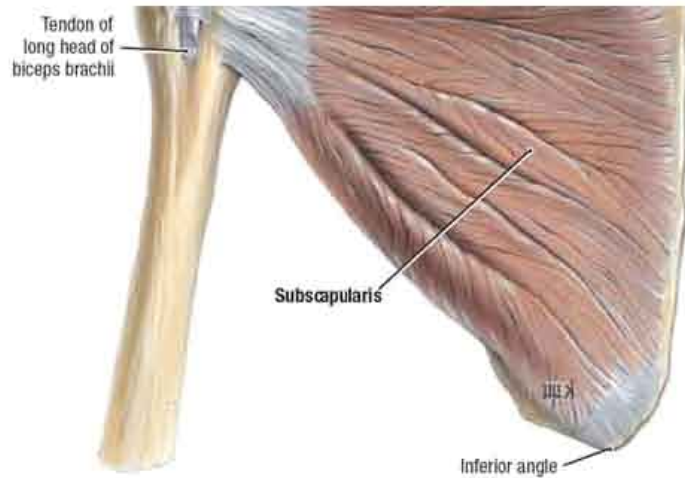
<sup>b</sup> Not a rotator cuff muscle.

Muscle	Proximal Attachment	Distal Attachment	Innervation	Main Actions
--------	---------------------	-------------------	-------------	--------------

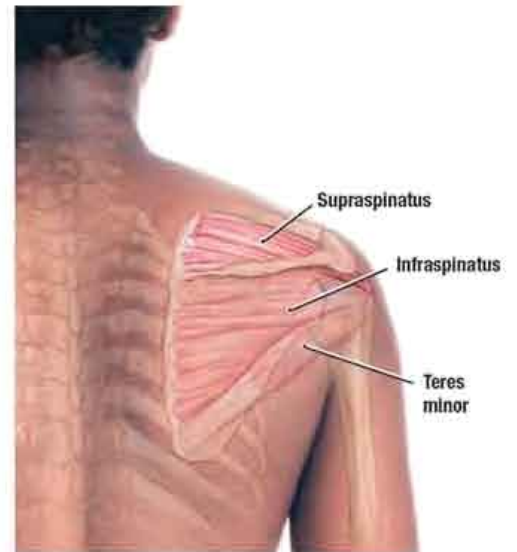
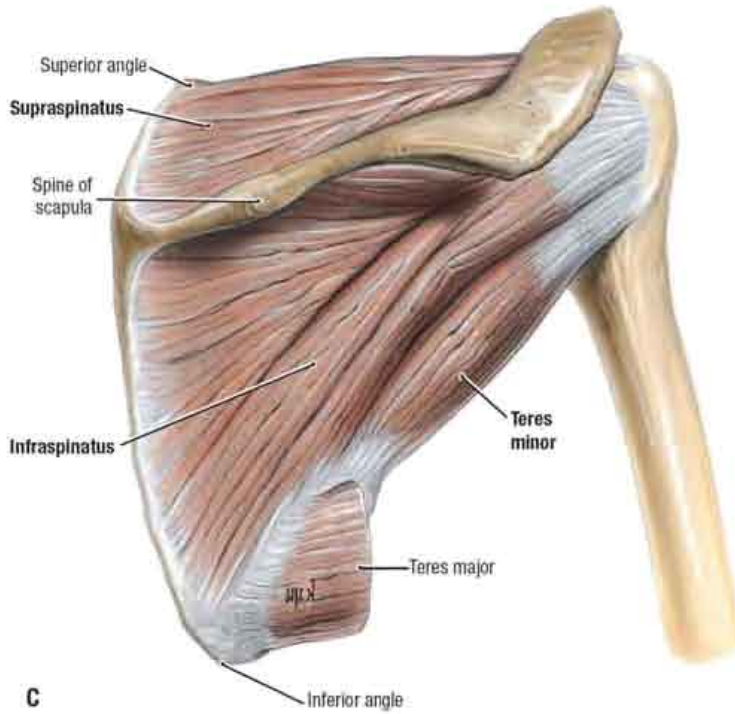
Table 6.7 Deep Scapulohumeral/Shoulder Muscles

P.518

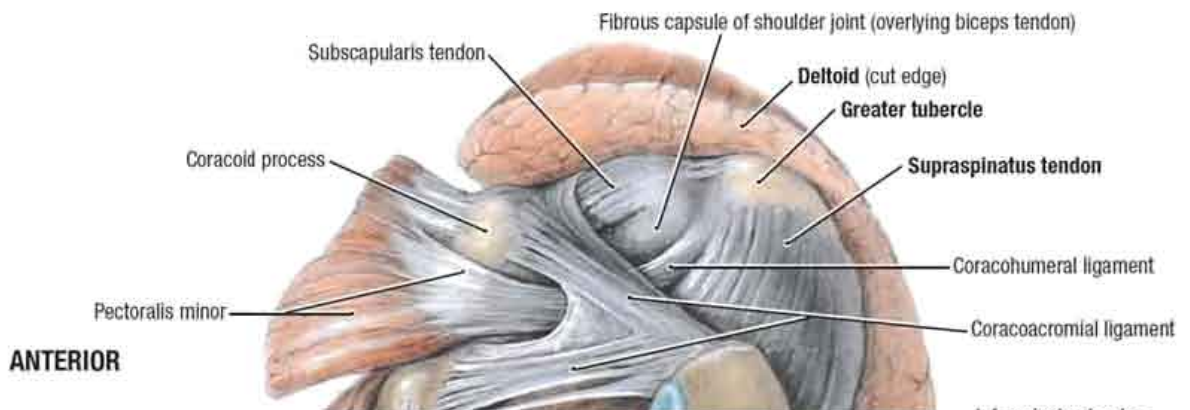




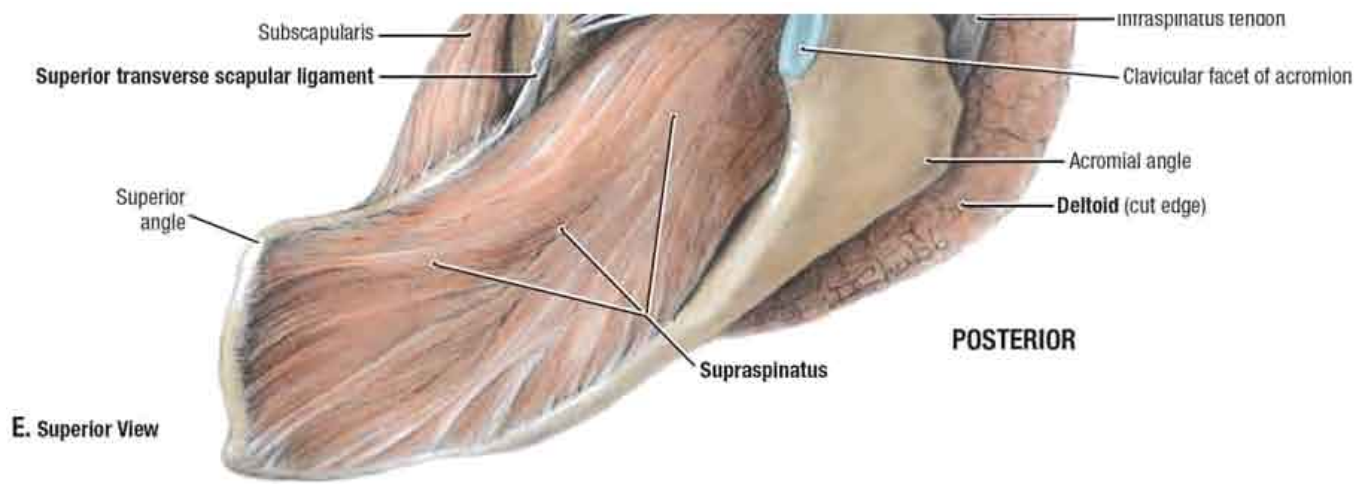
**Anterior Views**



**Posterior Views**









Authors: Agur, Anne M.R.; Dalley, Arthur F.  
Title: *Grant's Atlas of Anatomy, 12th Edition*  
Copyright ©2009 Lippincott Williams & Wilkins

> Table of Contents > Chapter 6 - Upper Limb > 6.31 Bones of proximal upper limb

## 6.31 Bones of proximal upper limb

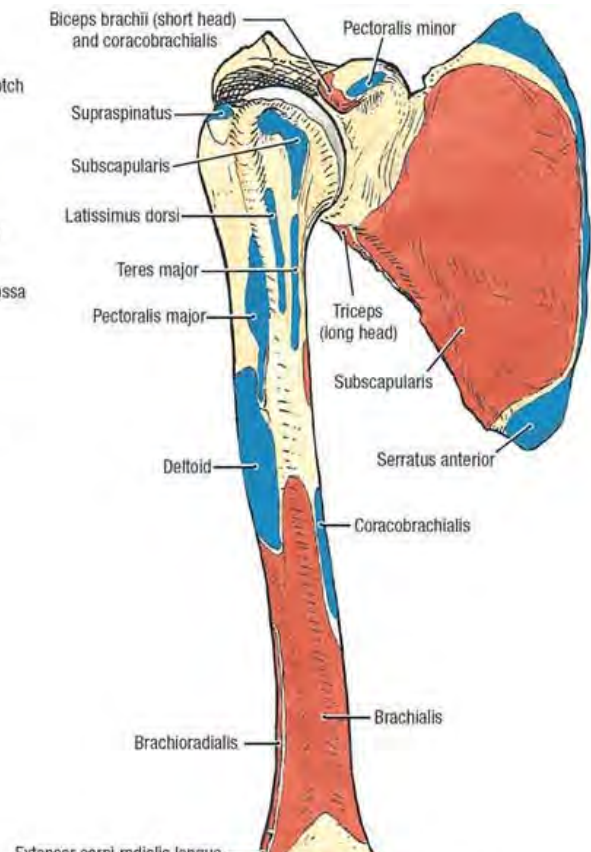
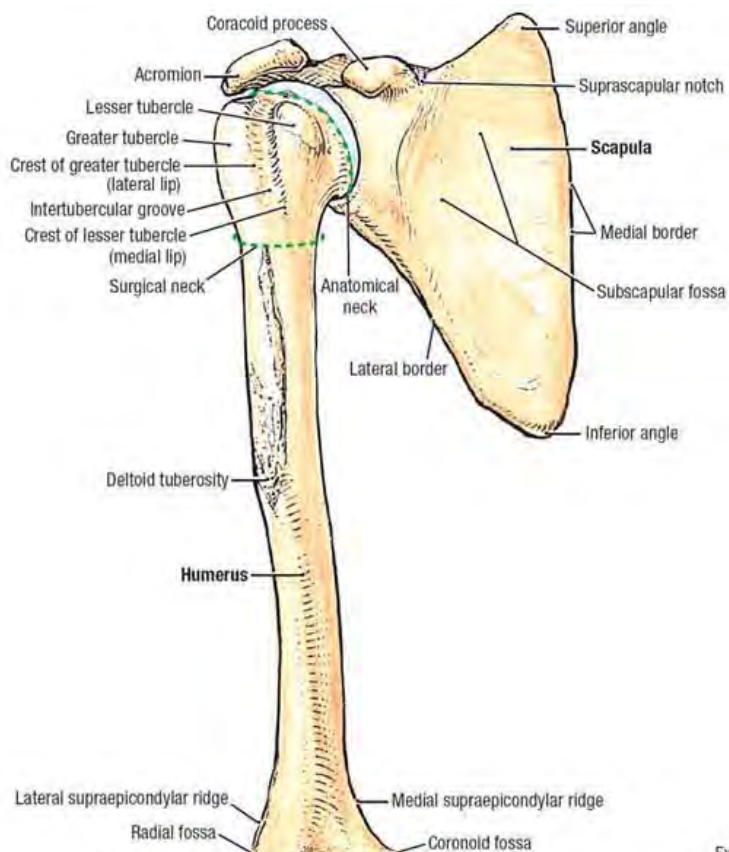
Part of "Chapter 6 - Upper Limb "

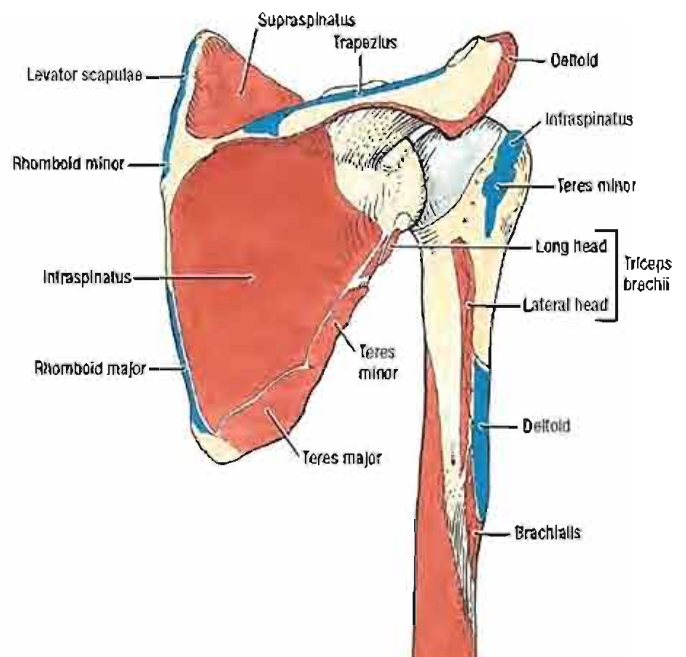
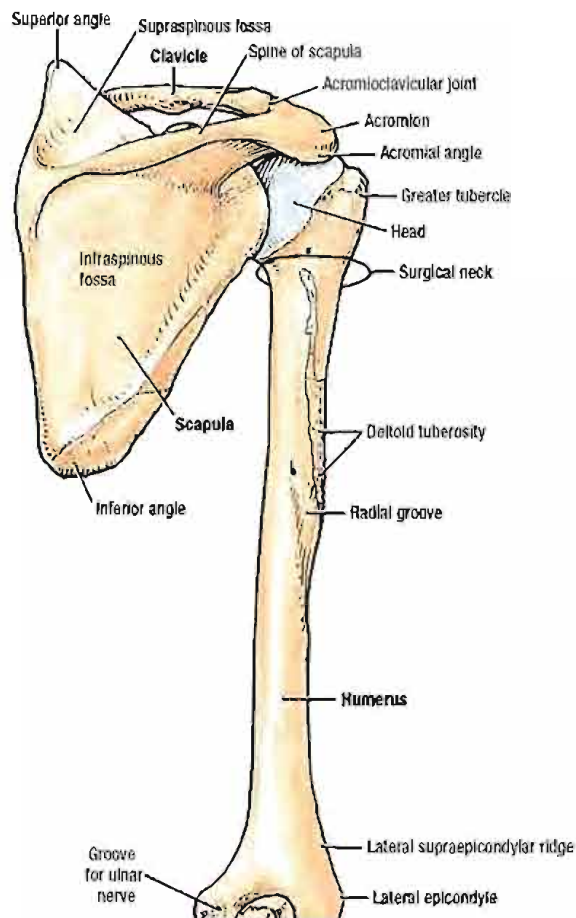
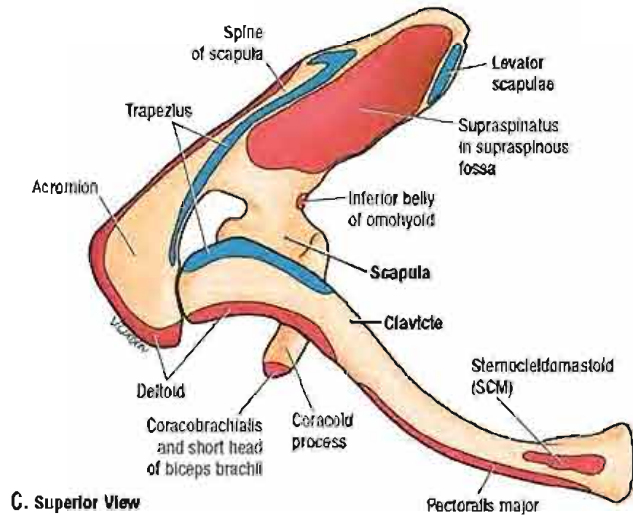
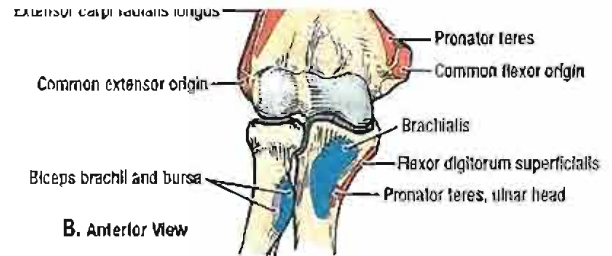
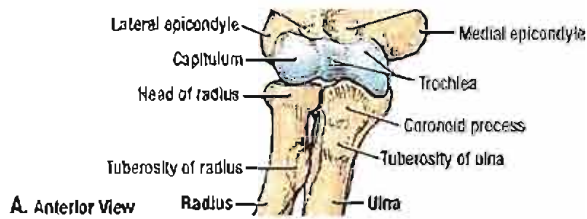
A. Bony features, anterior aspect. B. Muscle attachment sites, anterior aspect. C. Muscle attachment sites, clavicle and scapula.

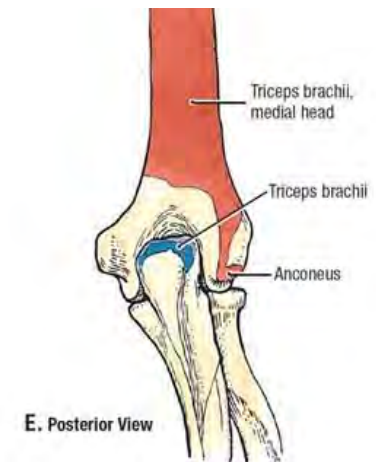
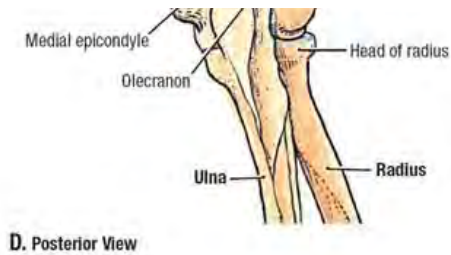
P.519

D. Bony features, posterior aspect. E. Muscle attachment sites, posterior aspect.

P.520







## Biceps brachii

*Short head:* tip of coracoid process of scapula

*Long head:* supraglenoid tubercle of scapula

Tuberosity of radius and fascia of forearm through bicipital aponeurosis

Musculocutaneous nerve (C5–C6)

Supinates forearm and, when forearm is supine, flexes forearm

## Brachialis

Distal half of anterior surface of humerus

Coronoid process and tuberosity of ulna

Flexes forearm in all positions

## Coracobrachialis

Tip of coracoid process of scapula

Middle third of medial surface of humerus

Musculocutaneous nerve (C5–C7)

Assists with flexion and adduction of arm

## Triceps brachii

*Long head:* infraglenoid tubercle of scapula

*Lateral head:* posterior surface of humerus, superior to radial groove

*Medial head:* posterior surface of humerus, inferior to radial groove

Proximal end of olecranon of ulna and fascia of forearm

Radial nerve (C6–C8)

Extends the forearm; long head steadies head of abducted humerus

## Anconeus

Lateral epicondyle of humerus

Lateral surface of olecranon and superior part of posterior surface of ulna

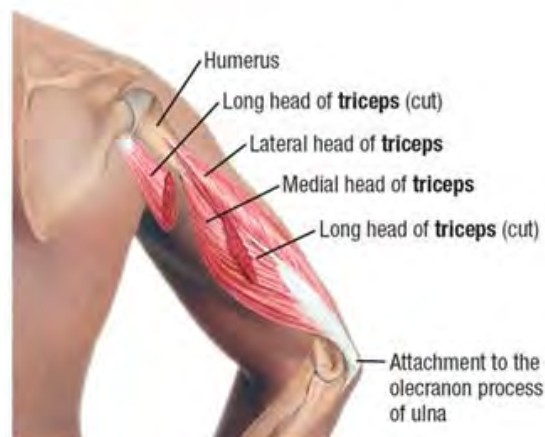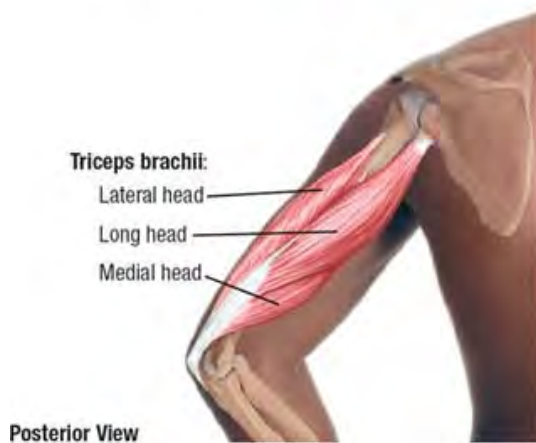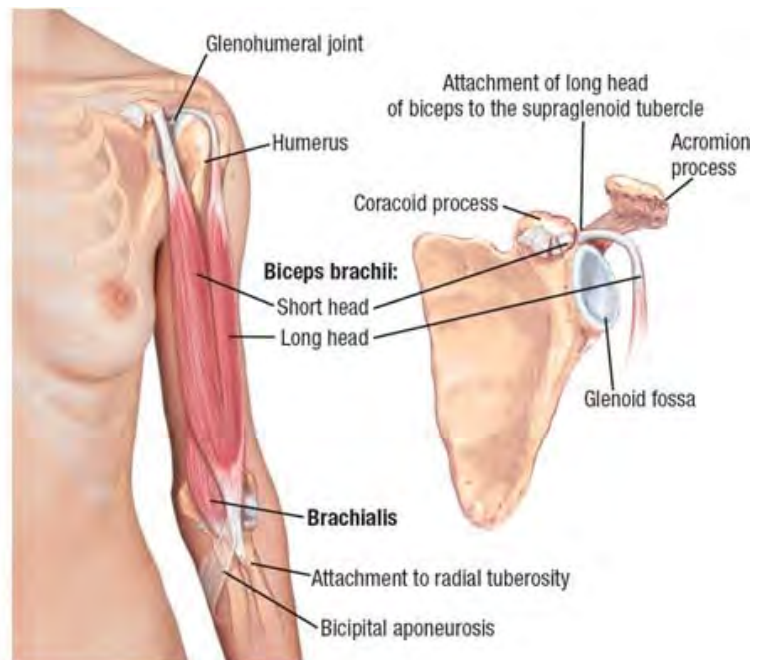
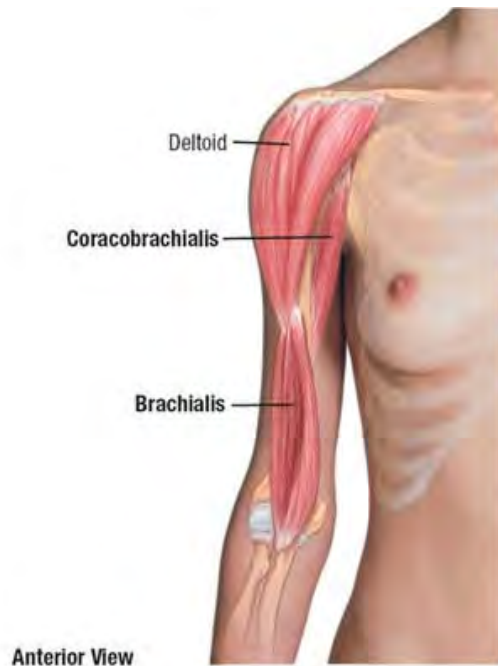Radial nerve (C7â€”T1)

Assists triceps in extending forearm; stabilizes elbow joint; abducts ulna during pronation

Muscle	Proximal Attachment	Distal Attachment	Innervation	Main Actions
--------	---------------------	-------------------	-------------	--------------

Table 6.8 Arm Muscles

P.521



Authors: Agur, Anne M.R.; Dalley, Arthur F.

Title: *Grant's Atlas of Anatomy, 12th Edition*

Copyright ©2009 Lippincott Williams & Wilkins

> Table of Contents > Chapter 6 - Upper Limb > 6.32 Anterior and posterior compartments of arm

---

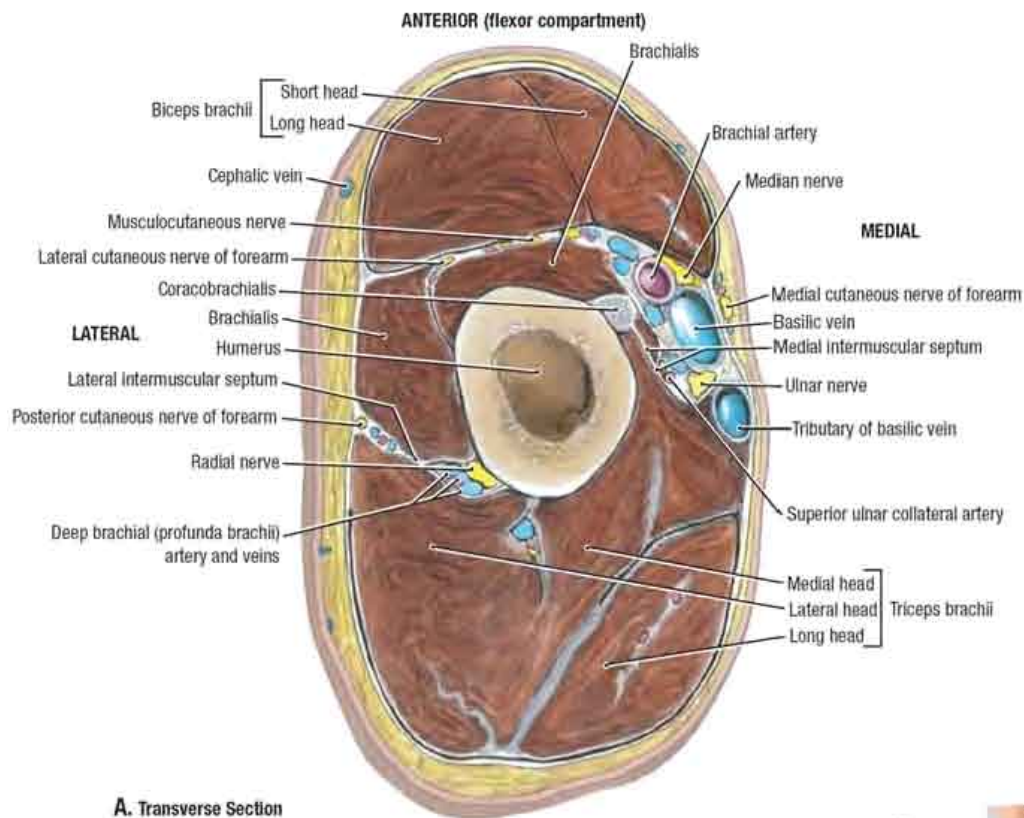
## 6.32 Anterior and posterior compartments of arm

*Part of* "Chapter 6 - Upper Limb "

A. Anatomical section. B. Surface anatomy.

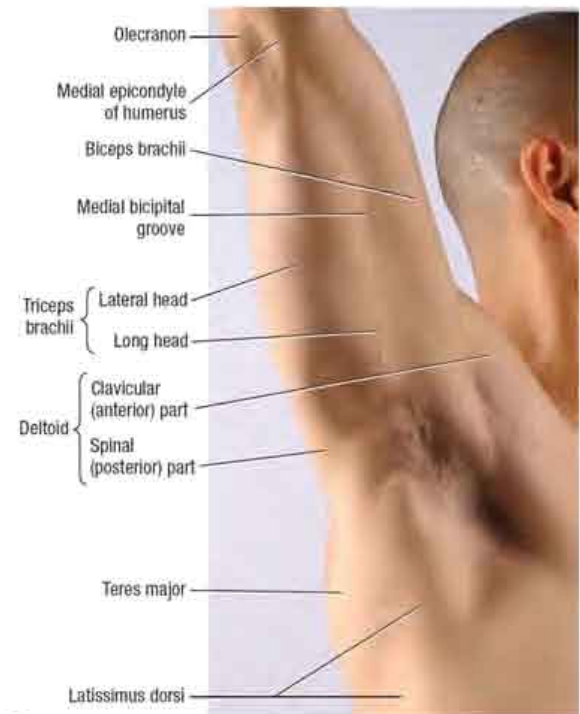
- Three muscles, the biceps, brachialis, and coracobrachialis, lie in the anterior compartment of the arm; the triceps brachii lies in the posterior compartment.
- The medial and lateral intermuscular septum separates these two muscle groups.
- The radial nerve and deep brachial artery and veins serving the posterior compartment lie in contact with the radial groove of the humerus.
- The musculocutaneous nerve serving the anterior compartment lies in the plane between the biceps and the brachialis muscles.
- The median nerve crosses to the medial side of the brachial artery.
- The ulnar nerve passes posteriorly onto the medial side of the triceps muscle.
- The basilic vein (appearing here as two vessels) has pierced the deep fascia.





**A. Transverse Section**

**POSTERIOR (extensor compartment)**



**B. Anterolateral View**

Authors: Agur, Anne M.R.; Dalley, Arthur F.

Title: *Grant's Atlas of Anatomy, 12th Edition*

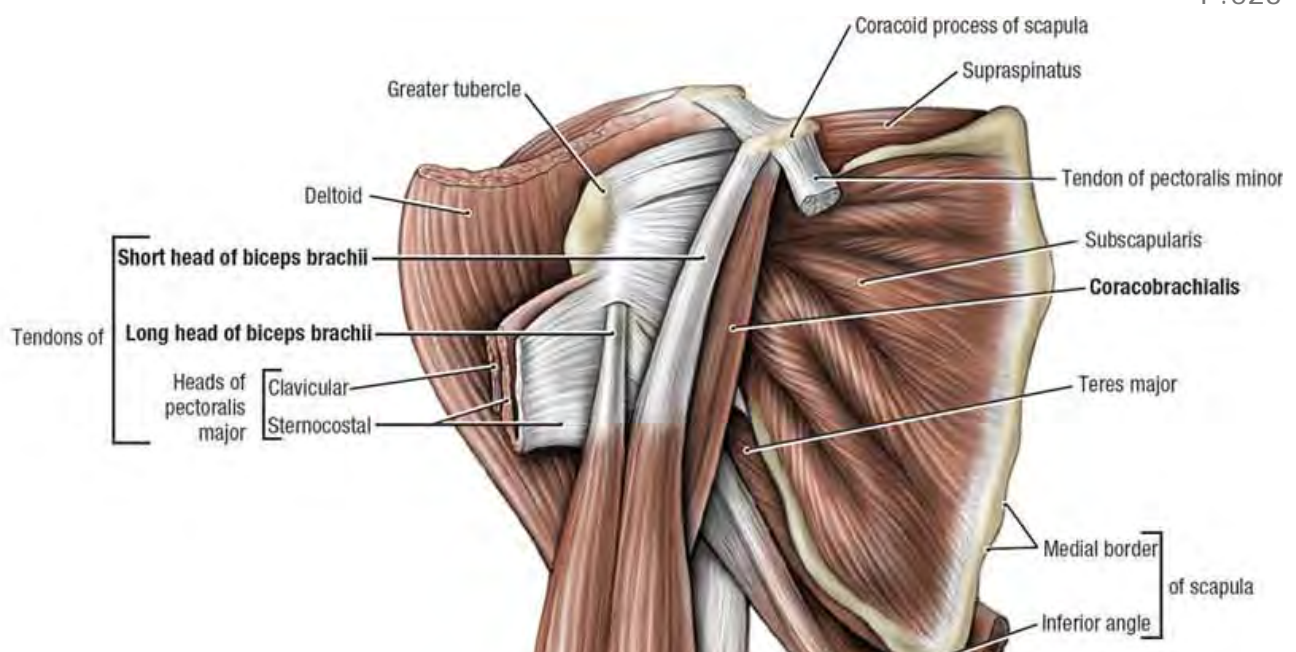
Copyright ©2009 Lippincott Williams & Wilkins

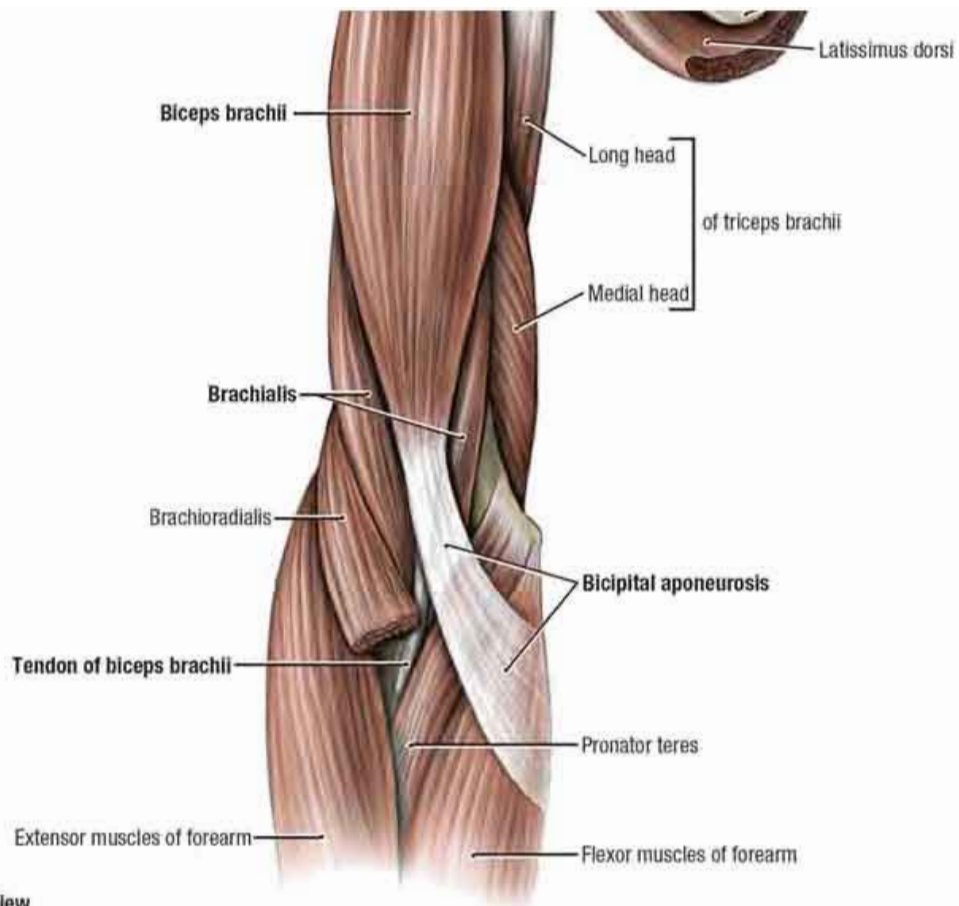
> Table of Contents > Chapter 6 - Upper Limb > 6.33 Muscles of anterior aspect of arm

## 6.33 Muscles of anterior aspect of arm

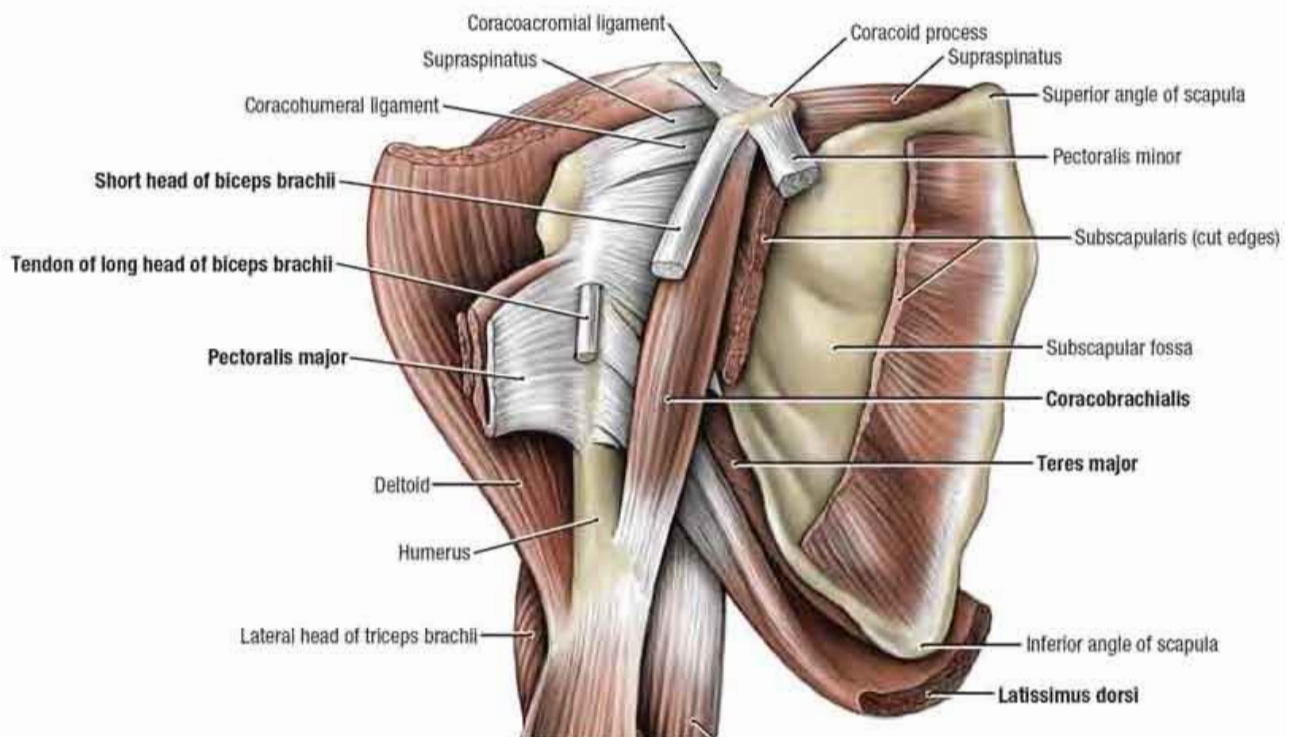
Part of "Chapter 6 - Upper Limb "

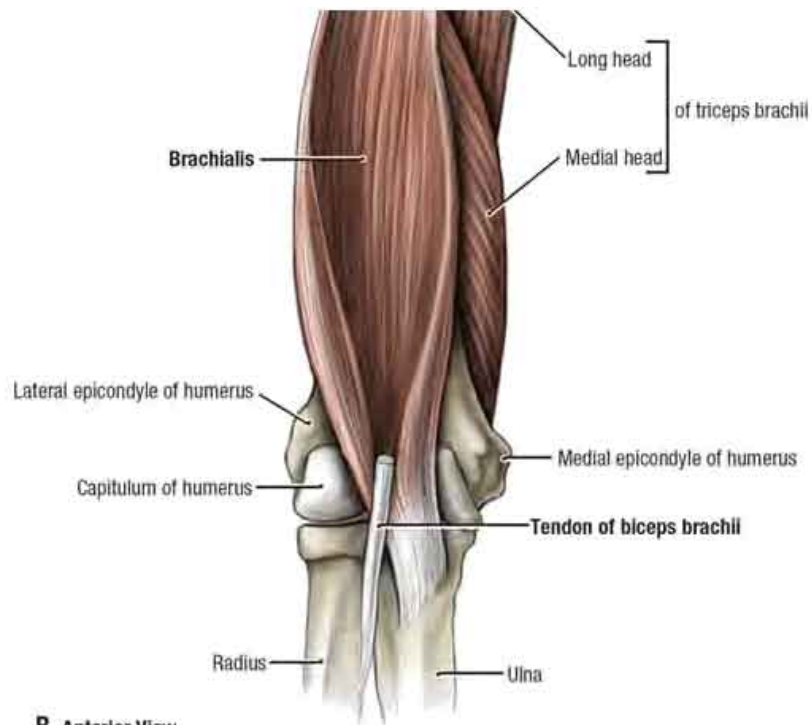
- The biceps brachii has two heads: a long head and a short head.
- However, when the elbow is flexed approximately  $90^\circ$  the biceps is a flexor from the supinated position of the forearm but a very powerful supinator from the pronated position.
- A triangular membranous band, the bicipital aponeurosis runs from the biceps tendon across the cubital fossa and merges with the antebrachial (deep) fascia covering the flexor muscles on the medial side of the forearm.





**A. Anterior View**





**B. Anterior View**

Authors: Agur, Anne M.R.; Dalley, Arthur F.

Title: *Grant's Atlas of Anatomy, 12th Edition*

Copyright ©2009 Lippincott Williams & Wilkins

> Table of Contents > Chapter 6 - Upper Limb > 6.33 Muscles of anterior aspect of arm " II

---

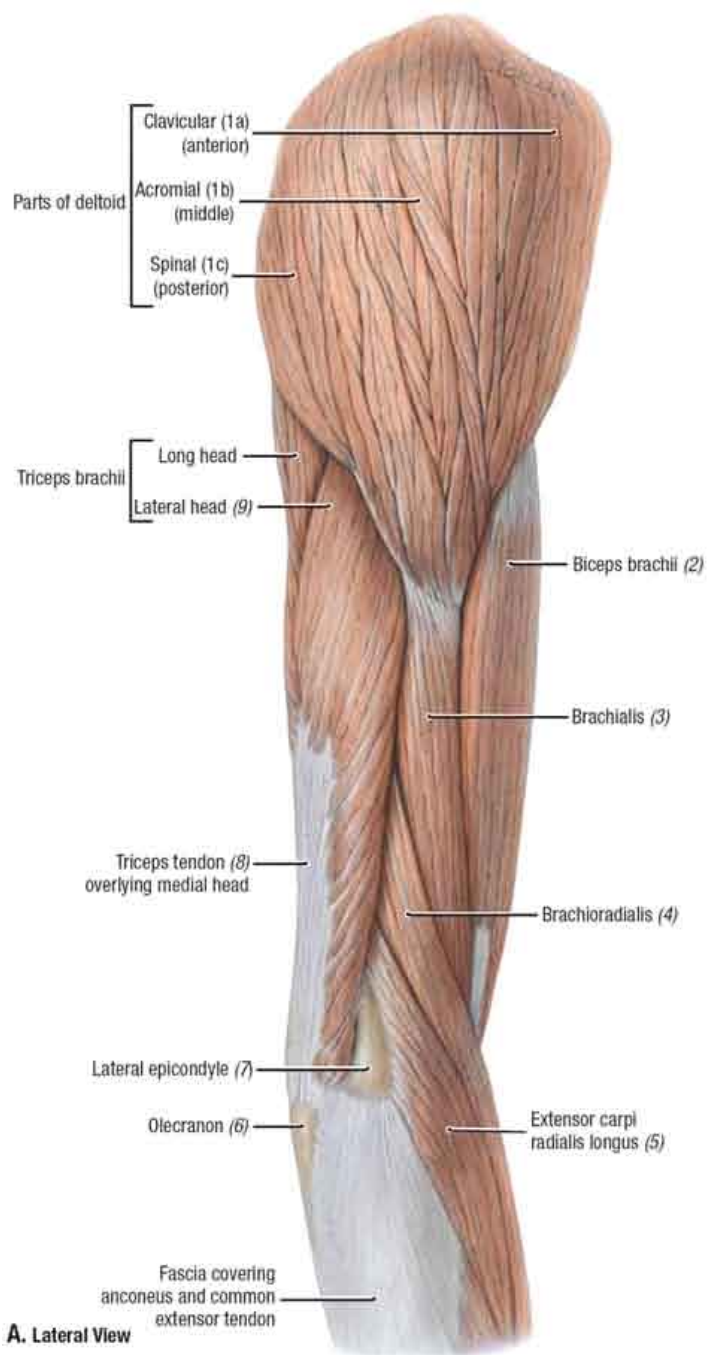
## 6.33 Muscles of anterior aspect of arm " II

*Part of "Chapter 6 - Upper Limb "*

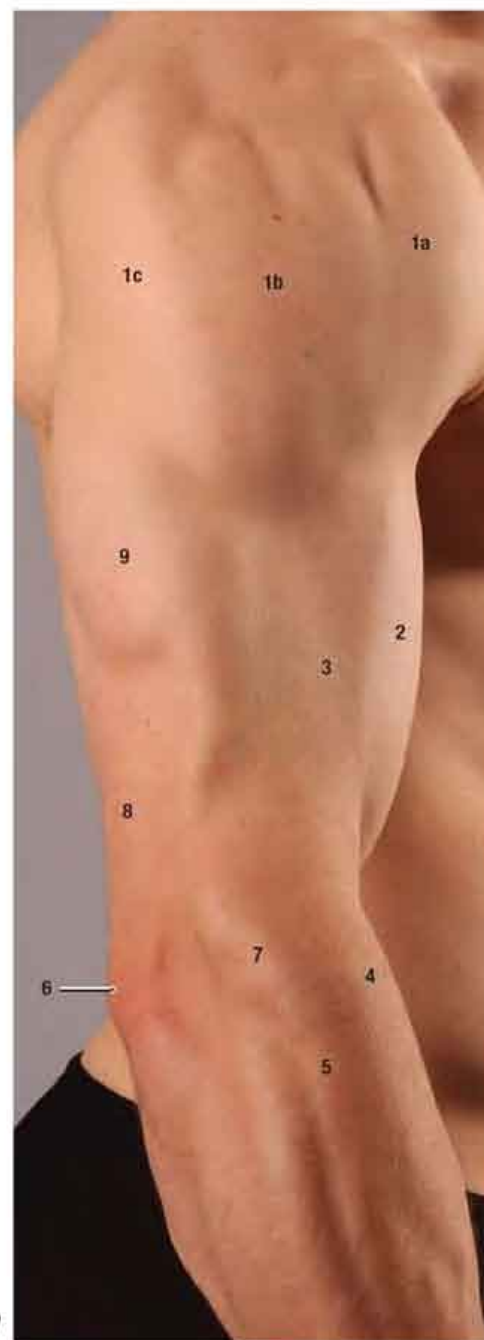
- The brachialis , a flattened fusiform muscle, lies posterior (deep) to the biceps that produce the greatest amount of flexion force.
- The coracobrachialis , an elongated muscle in the superomedial part of the arm, is pierced by the musculocutaneous nerve. It helps flex and adduct the arm.

Rupture of the tendon of the long head of the biceps usually results from wear and tear of an inflamed tendon (*biceps tendinitis*). Normally, the tendon is torn from its attachment to the supraglenoid tubercle of the scapula. The detached muscle belly forms a ball near the center of the distal part of the anterior aspect of the arm.





**B. Lateral View**



Authors: Agur, Anne M.R.; Dalley, Arthur F.

Title: *Grant's Atlas of Anatomy, 12th Edition*

Copyright ©2009 Lippincott Williams & Wilkins

> Table of Contents > Chapter 6 - Upper Limb > 6.34 Lateral aspect of arm

---

## 6.34 Lateral aspect of arm

*Part of* "Chapter 6 - Upper Limb "

A. Dissection (*numbers* in parentheses refer to structures in B ). B. Surface anatomy.

Atrophy of the deltoid occurs when the axillary nerve (C5 and C6) is severely damaged (e.g., as might occur when the surgical neck of the humerus is fractured). As the deltoid atrophies, the rounded contour of the shoulder disappears. This gives the shoulder a flattened appearance and produces a slight hollow inferior to the acromion. A loss of sensation may occur over the lateral side of the proximal part of the arm, the area supplied by the superior lateral cutaneous nerve of the arm. To test the deltoid (or the function of the axillary nerve) the arm is abducted, against resistance, starting from approximately 15°. Supraspinatus initiates abduction.



Authors: Agur, Anne M.R.; Dalley, Arthur F.

Title: *Grant's Atlas of Anatomy, 12th Edition*

Copyright ©2009 Lippincott Williams & Wilkins

> Table of Contents > Chapter 6 - Upper Limb > 6.35 Medial aspect of arm

---

## 6.35 Medial aspect of arm

*Part of "Chapter 6 - Upper Limb "*

A. Dissection. B. Surface anatomy.

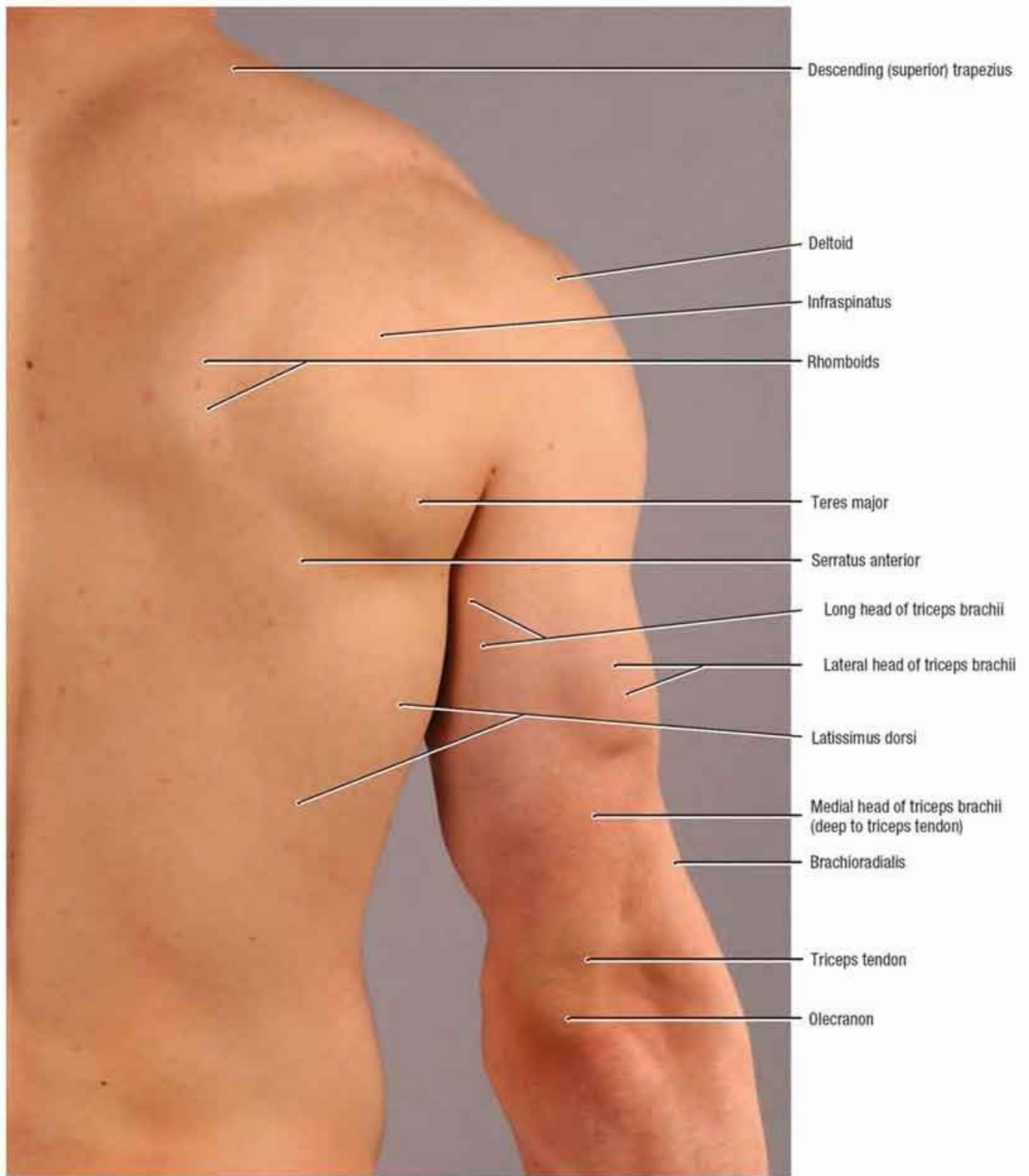
- The axillary artery passes just inferior to the tip of the coracoid process and courses posterior to the coracobrachialis. At the inferior border of the teres major, the axillary artery changes names to become the brachial artery and continues distally on the anterior aspect of the brachialis.

- Although collateral pathways confer some protection against gradual temporary and partial occlusion, sudden complete occlusion or laceration of the brachial artery creates a surgical emergency because paralysis of muscles results from ischemia within a few hours.

- The median nerve lies adjacent to the axillary and brachial arteries and then crosses the artery from lateral to medial.
- Proximally, the ulnar nerve is adjacent to the medial side of the artery, passes posterior to the medial intermuscular septum, and descends on the medial head of triceps to pass posterior to the medial epicondyle; here, the ulnar nerve is palpable.
- The superior ulnar collateral artery and ulnar collateral branch of the radial nerve

(to medial head of the triceps) accompany the ulnar nerve in the arm.





Posterior View

Authors: Agur, Anne M.R.; Dalley, Arthur F.

Title: *Grant's Atlas of Anatomy, 12th Edition*

Copyright ©2009 Lippincott Williams & Wilkins

> Table of Contents > Chapter 6 - Upper Limb > 6.36 Surface anatomy of the scapular region and posterior aspect of arm

---

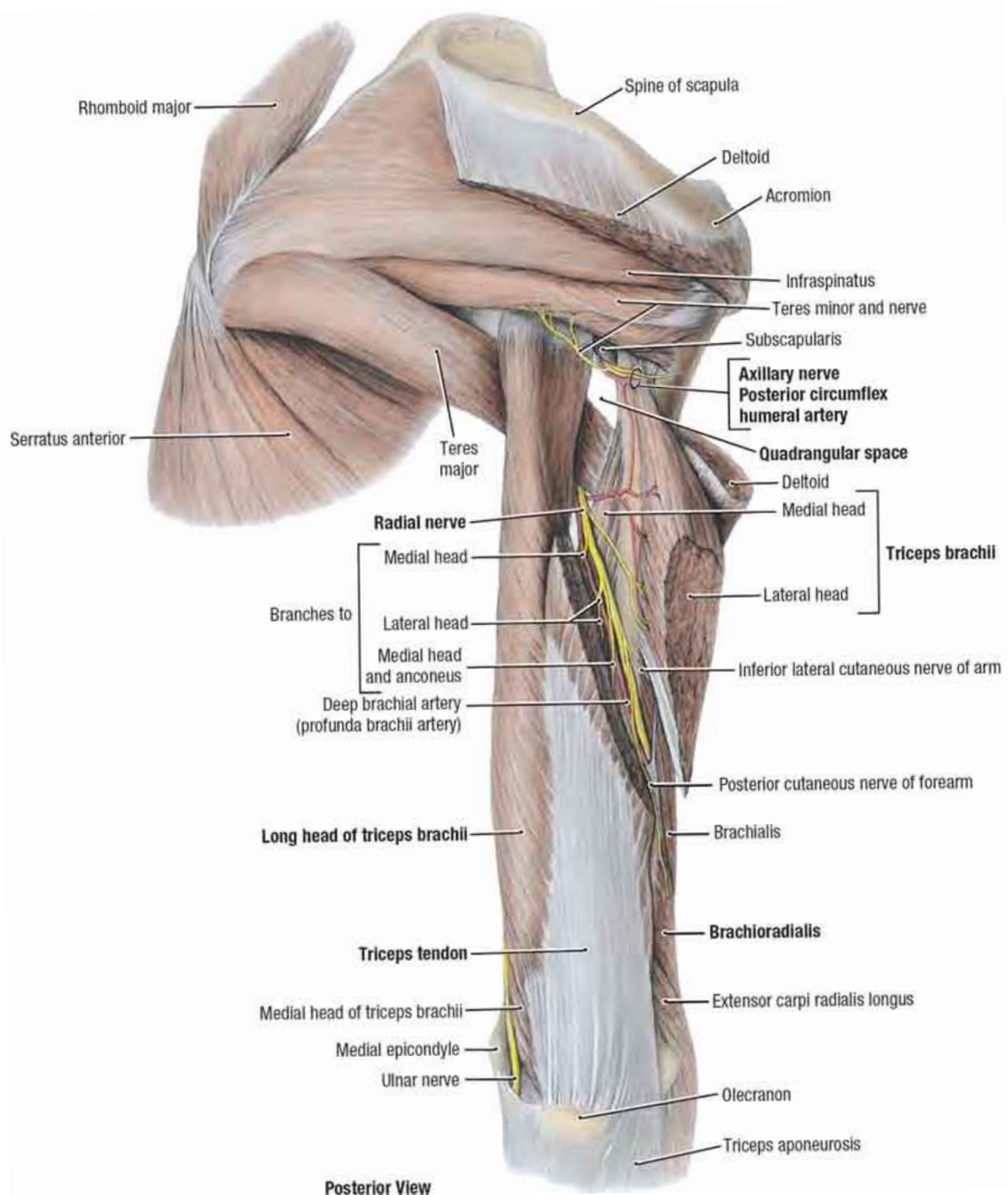
## 6.36 Surface anatomy of the scapular region and posterior aspect of arm

*Part of* "Chapter 6 - Upper Limb "

The three heads of the triceps form a bulge on the posterior aspect of the arm and are identifiable when the forearm is extended from the flexed position against resistance.

---

P.527



Authors: Agur, Anne M.R.; Dalley, Arthur F.

Title: *Grant's Atlas of Anatomy, 12th Edition*

Copyright ©2009 Lippincott Williams & Wilkins

> Table of Contents > Chapter 6 - Upper Limb > 6.37 Triceps brachii and related nerves

---

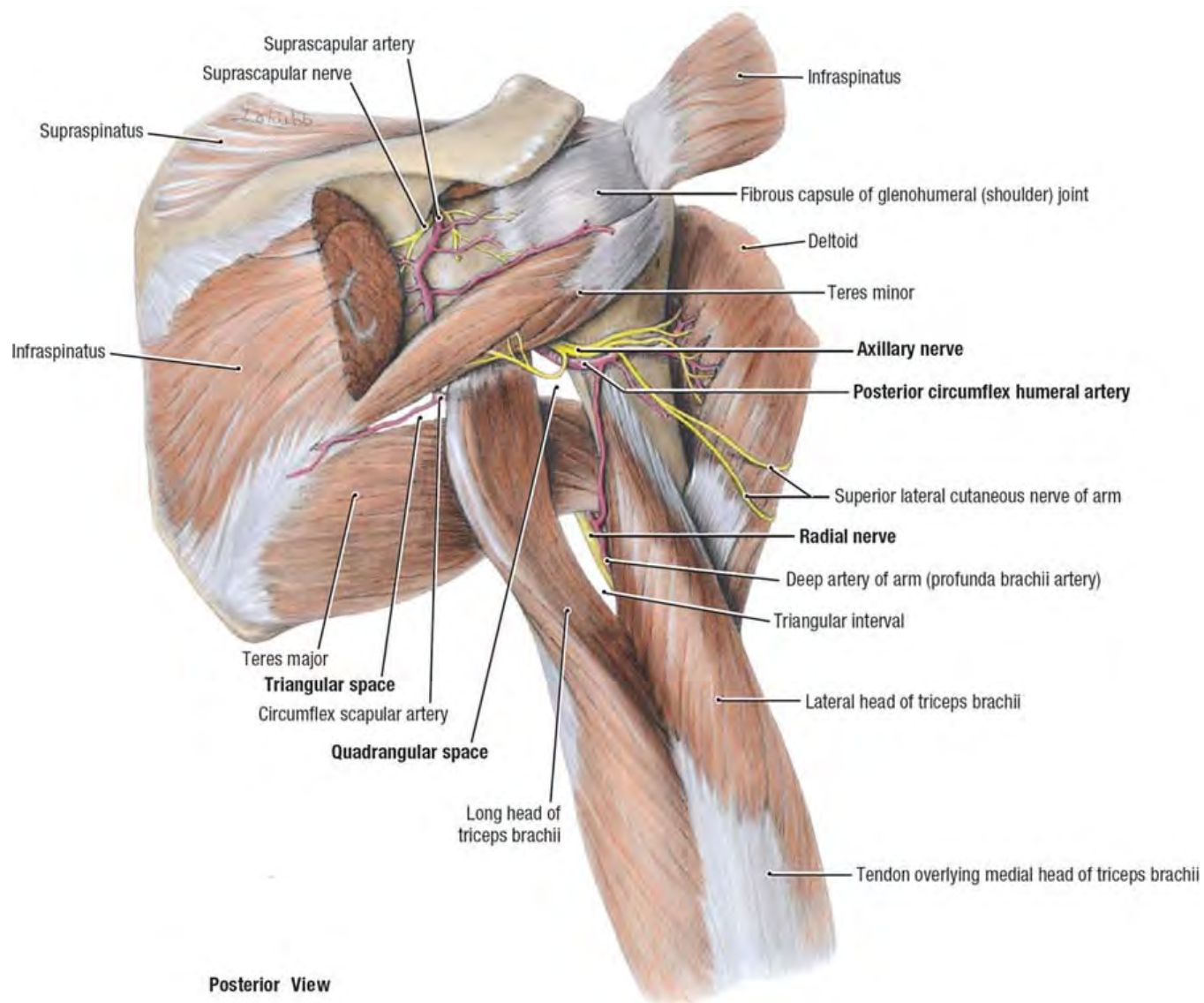
## 6.37 Triceps brachii and related nerves

*Part of* "Chapter 6 - Upper Limb "

- The lateral head is reflected laterally, and the medial head is attached to the deep surface of the triceps tendon, which attaches to the olecranon.
- The radial nerve and deep brachial artery pass between the proximal attachments of the long and medial heads of the triceps brachii in the middle third of the arm, directly contacting the radial groove of the humerus.

- The middle third of the arm is a common site for fractures of the humerus, often with associated radial nerve trauma. When the radial nerve is injured in the radial groove, the triceps brachii muscle typically is only weakened because only the medial head is affected. However, the muscles in the posterior compartment of the forearm, supplied by more distal branches of the radial nerve, are paralyzed. The characteristic clinical sign of radial nerve injury is wrist drop (inability to extend the wrist and fingers at the metacarpophalangeal joints).

- The axillary nerve passes through the quadrangular space along with the posterior humeral circumflex artery.
- The ulnar nerve follows the medial border of the triceps then passes posterior to the medial epicondyle.





Authors: Agur, Anne M.R.; Dalley, Arthur F.

Title: *Grant's Atlas of Anatomy, 12th Edition*

Copyright ©2009 Lippincott Williams & Wilkins

> Table of Contents > Chapter 6 - Upper Limb > 6.38 Dorsal scapular and subdeltoid regions

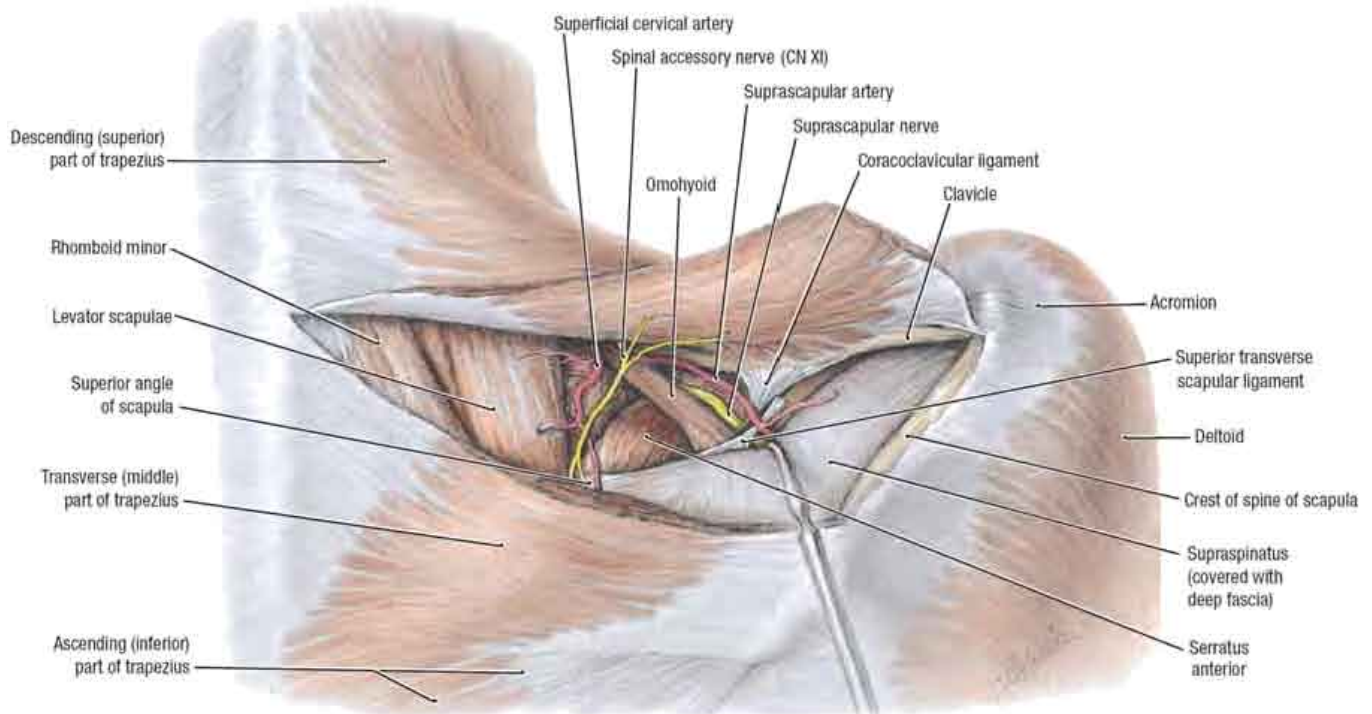
---

## 6.38 Dorsal scapular and subdeltoid regions

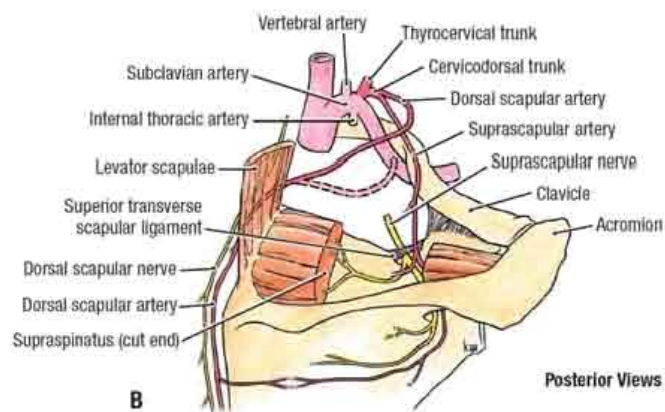
*Part of "Chapter 6 - Upper Limb "*

- The infraspinatus muscle, aided by the teres minor and spinal (posterior) fibers of the deltoid muscle, rotates the humerus laterally.
- The long head of the triceps muscle passes between the teres minor (a lateral rotator) and teres major (a medial rotator) muscles.
- The long head of the triceps muscle separates the quadrangular space from the triangular space.
- Regarding the distribution of the suprascapular and axillary nerves, each comes from C5 and C6; each supplies two muscles—the suprascapular nerve innervates the supraspinatus and infraspinatus, and the axillary nerve innervates the teres minor and deltoid muscles. Both nerves supply the shoulder joint, but only the axillary nerve has a cutaneous branch.

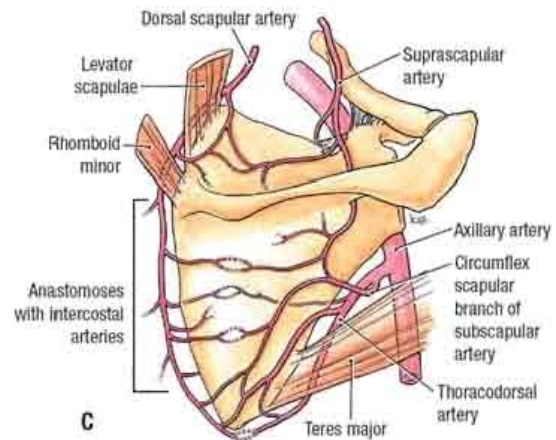
- The axillary nerve may be injured when the glenohumeral joint dislocates because of its close relation to the inferior part of the joint capsule of this joint. The subglenoid displacement of the head of the humerus into the quadrangular space damages the axillary nerve. Axillary nerve injury is indicated by paralysis of the deltoid.



**A. Posterior View**



**Posterior Views**



Authors: Agur, Anne M.R.; Dalley, Arthur F.

Title: *Grant's Atlas of Anatomy, 12th Edition*

Copyright ©2009 Lippincott Williams & Wilkins

> Table of Contents > Chapter 6 - Upper Limb > 6.39 Suprascapular region

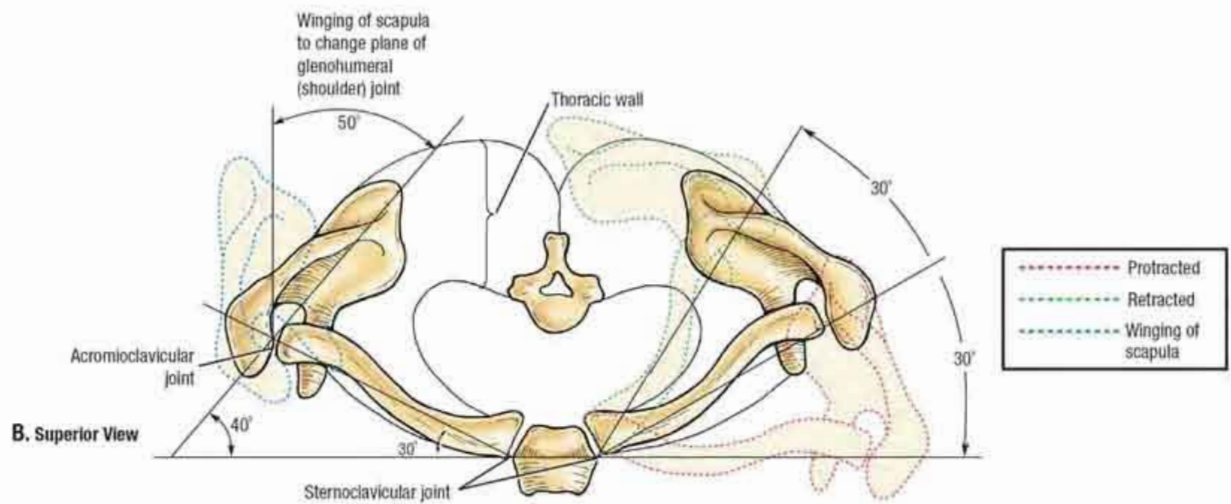
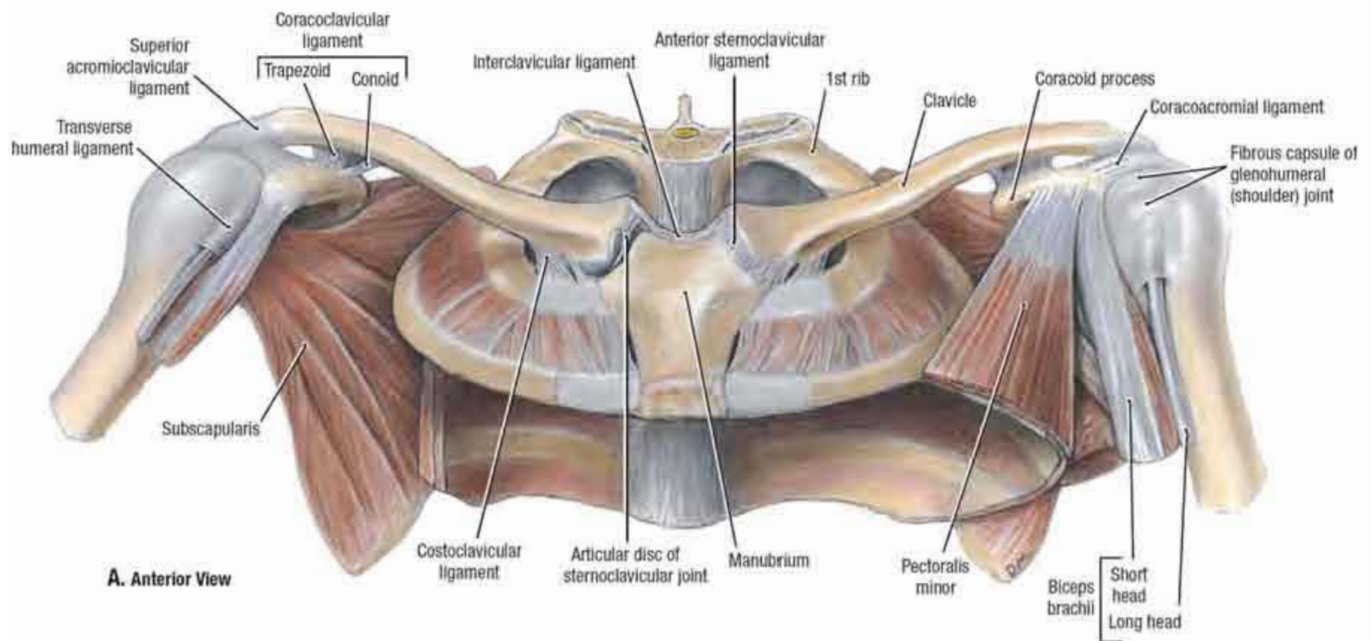
---

## 6.39 Suprascapular region

*Part of* "Chapter 6 - Upper Limb "

A. Dissection. At the level of the superior angle of the scapula, the transverse part of the trapezius muscle is reflected. B. Suprascapular and dorsal scapular arteries. C. Scapular anastomosis.

Several arteries join to form anastomoses on the anterior and posterior surfaces of the scapula. The importance of the collateral circulation made possible by these anastomoses becomes apparent when ligation of a lacerated subclavian or axillary artery is necessary or there is occlusion of these vessels. The direction of blood flow in the subscapular artery is then reversed, enabling blood to reach the third part of the axillary artery. In contrast to a sudden occlusion, slow occlusion of an artery often enables sufficient lateral circulation to develop, preventing ischemia (deficiency of blood).



Authors: Agur, Anne M.R.; Dalley, Arthur F.

Title: *Grant's Atlas of Anatomy, 12th Edition*

Copyright ©2009 Lippincott Williams & Wilkins

> Table of Contents > Chapter 6 - Upper Limb > 6.40 Pectoral girdle

---

## 6.40 Pectoral girdle

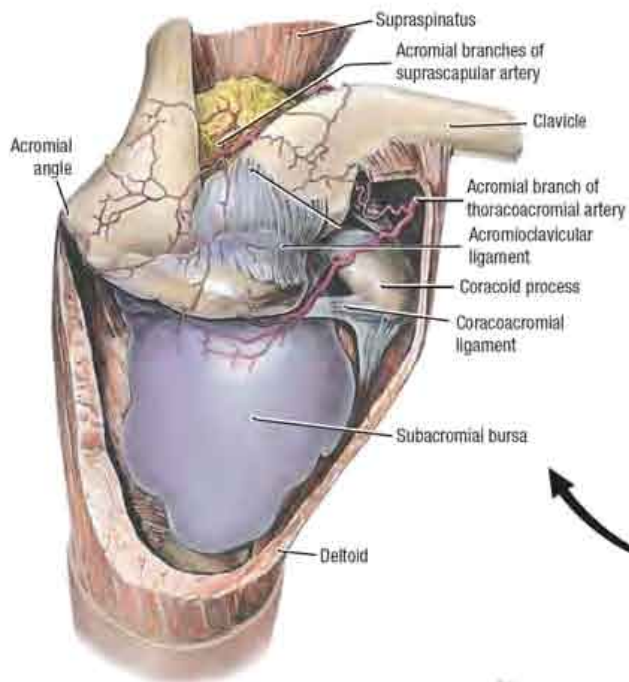
*Part of "Chapter 6 - Upper Limb "*

A. Dissection. B. Clavicular movements at the sternoclavicular and acromioclavicular joints during rotation, protraction, and retraction of the scapula on the thoracic wall (*left side*) and winging of the scapula (*right side*).

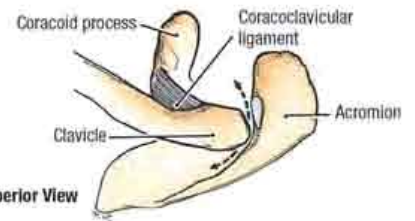
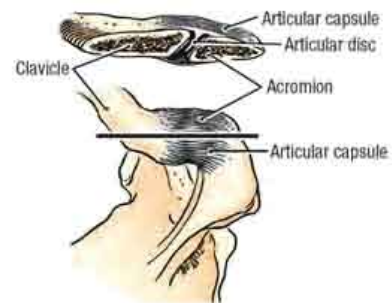- The shoulder region includes the sternoclavicular, acromioclavicular, and shoulder (glenohumeral) joints; the mobility of the clavicle is essential to the movement of the upper limb.
- The sternoclavicular joint is the only joint connecting the upper limb (appendicular skeleton) to the trunk (axial skeleton). The articular disc of the sternoclavicular joint divides the joint cavity into two parts and attaches superiorly to the clavicle and inferiorly to the first costal cartilage; the disc resists superior and medial displacement of the clavicle.

In B , note that when the serratus anterior is paralyzed because of injury to the long thoracic nerve, the medial border of the scapula moves laterally and posteriorly away from the thoracic wall, giving the scapula the appearance of a wing. The arm cannot be abducted beyond the horizontal position because the serratus anterior cannot rotate the glenoid cavity superiorly to allow complete abduction of the arm.

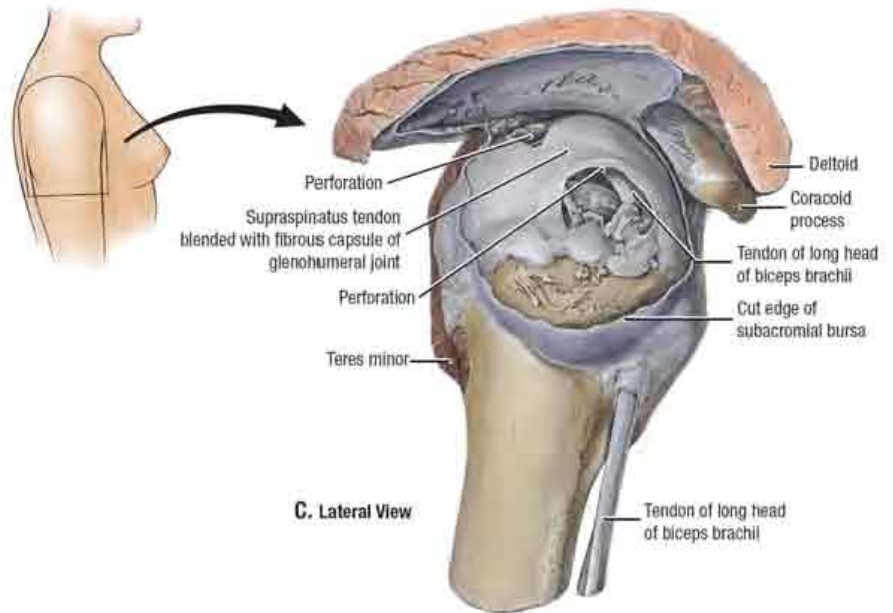




**A. Superolateral View**



**B. Superior View**



**C. Lateral View**

Authors: Agur, Anne M.R.; Dalley, Arthur F.

Title: *Grant's Atlas of Anatomy, 12th Edition*

Copyright ©2009 Lippincott Williams & Wilkins

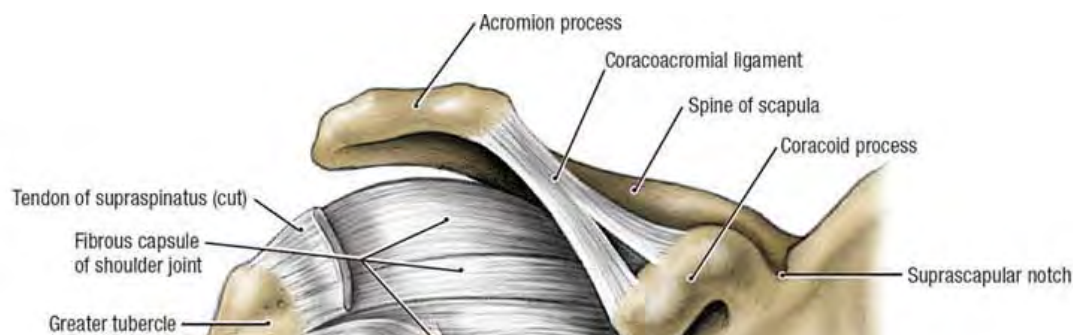
> Table of Contents > Chapter 6 - Upper Limb > 6.41 Lateral aspect of subacromial bursa and acromioclavicular joint

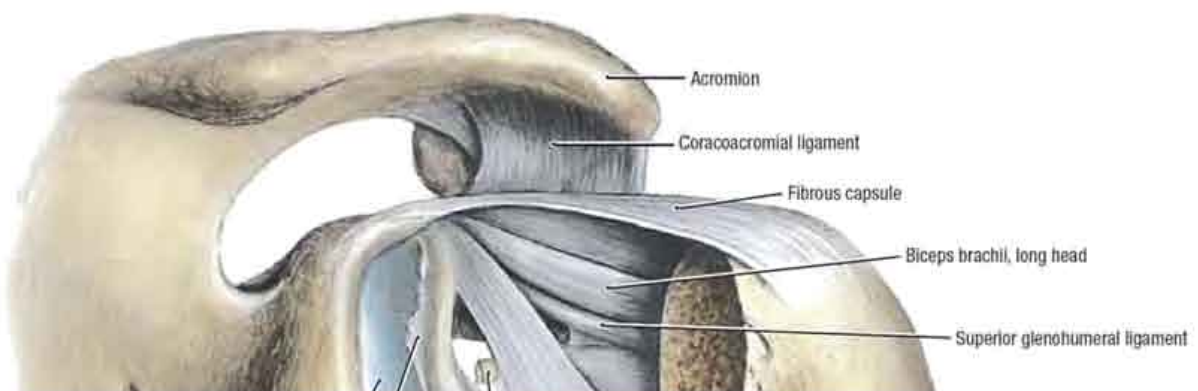
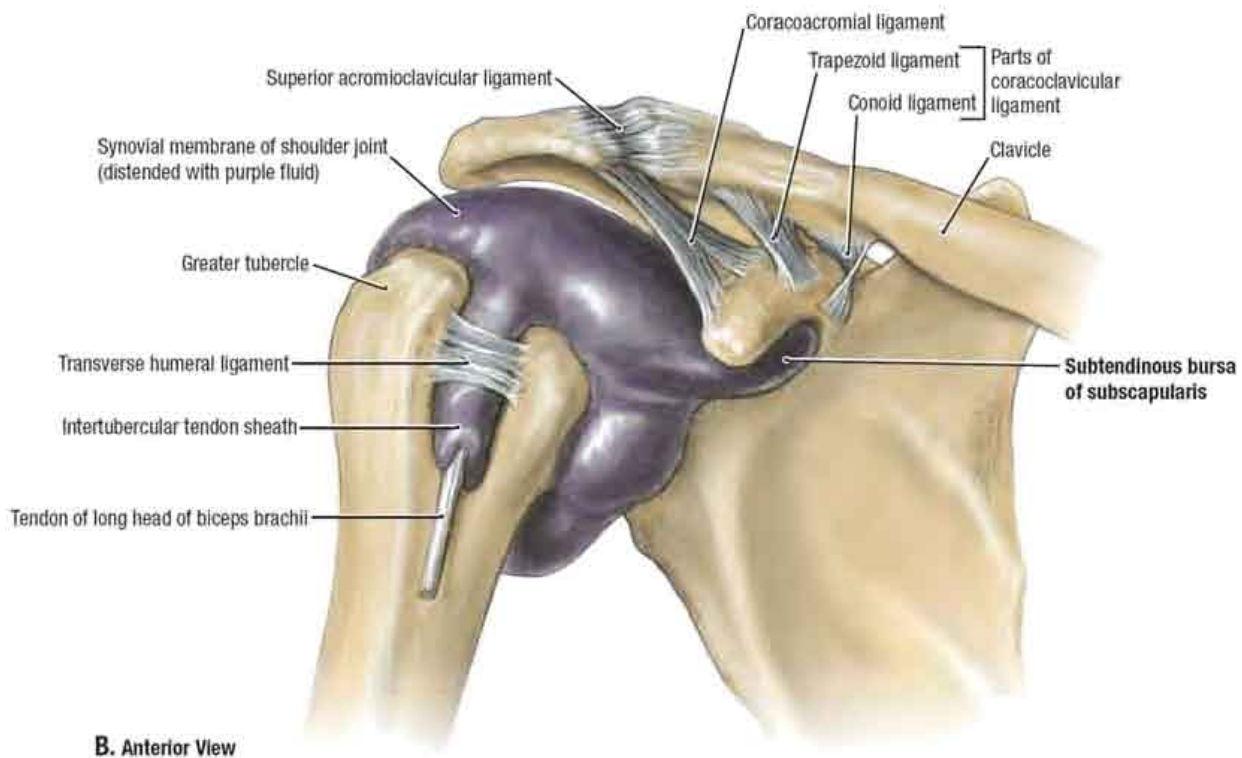
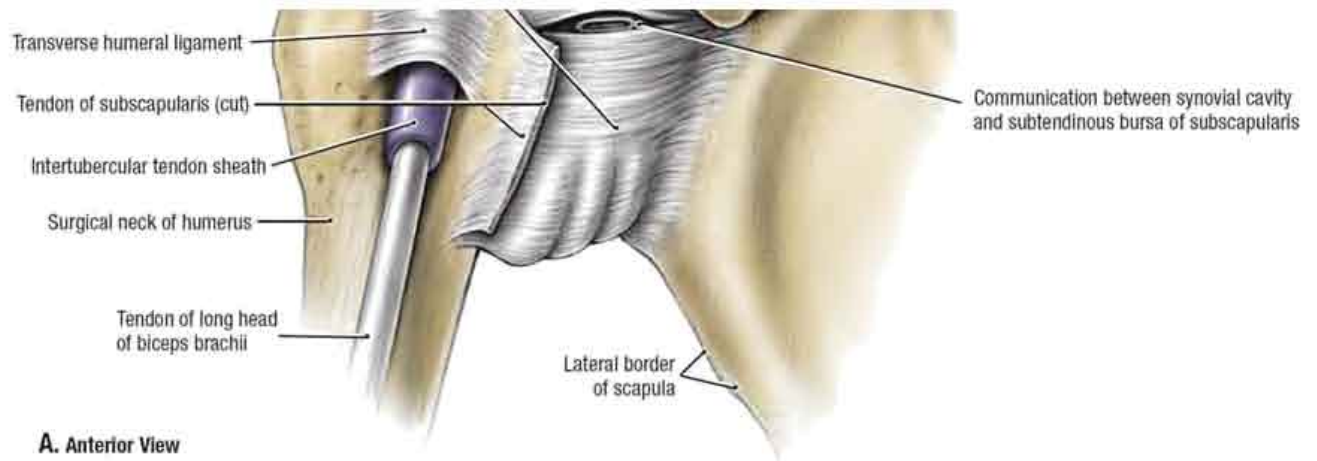
## 6.41 Lateral aspect of subacromial bursa and acromioclavicular joint

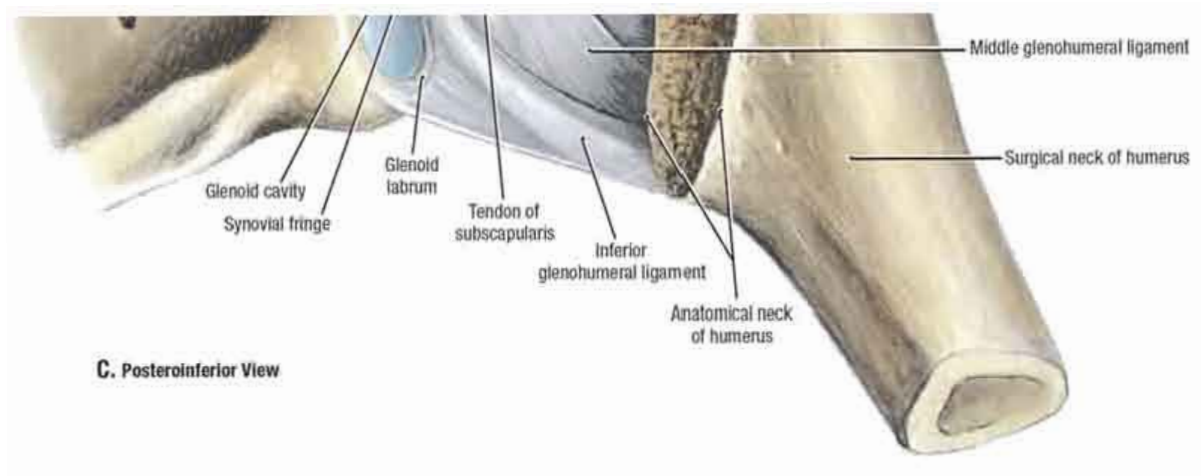
*Part of* "Chapter 6 - Upper Limb "

A. Subacromial bursa. The bursa has been injected with purple latex. B. Acromioclavicular joint.

C. Attrition of supraspinatus tendon. As a result of wearing away of the supraspinatus tendon and underlying capsule, the subacromial bursa and shoulder joint come into communication. The intracapsular part of the tendon of the long head of biceps muscle becomes frayed, leaving it adherent to the intertubercular groove. Of 95 dissecting room subjects, none of the 18 younger than 50 years of age had a perforation, but 4 of the 19 who were 50 to 60 years and 23 of the 57 older than 60 years had perforations. The perforation was bilateral in 11 subjects and unilateral in 14.







Authors: Agur, Anne M.R.; Dalley, Arthur F.

Title: *Grant's Atlas of Anatomy, 12th Edition*

Copyright ©2009 Lippincott Williams & Wilkins

> Table of Contents > Chapter 6 - Upper Limb > 6.42 Ligaments and articular capsule of glenohumeral (shoulder) joint

---

## 6.42 Ligaments and articular capsule of glenohumeral (shoulder) joint

*Part of* "Chapter 6 - Upper Limb "

### A. Fibrous capsule.

- The loose fibrous capsule is attached to the margin of the glenoid cavity and to the anatomical neck of the humerus.
- The strong coracoclavicular ligament provides stability to the acromioclavicular joint and prevents the scapula from being driven medially and the acromion from being driven inferior to the clavicle.
- The coracoacromial ligament prevents superior displacement of the head of the humerus.

---

P.533

B. Synovial membrane of joint capsule. The synovial membrane lines the fibrous capsule and has two prolongations: (1) where it forms a synovial sheath for the tendon of the long head of the biceps muscle in its osseofibrous tunnel and (2) inferior to the coracoid process, where it forms a bursa between the subscapularis tendon and margin of the glenoid cavity—the subtendinous bursa of the subscapularis. C. Glenohumeral ligaments viewed from the interior of the shoulder joint.

- The joint is exposed from the posterior aspect by cutting away the thinner

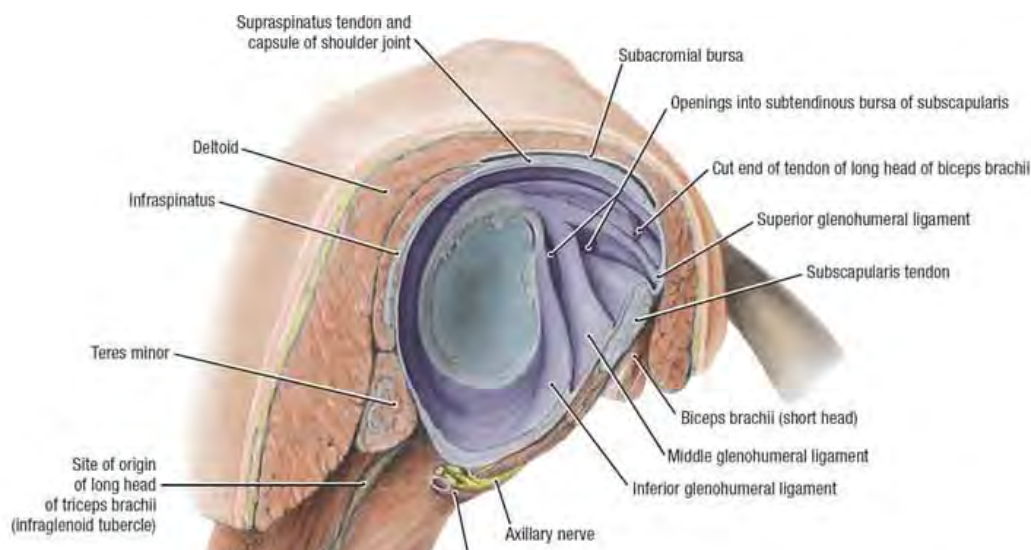


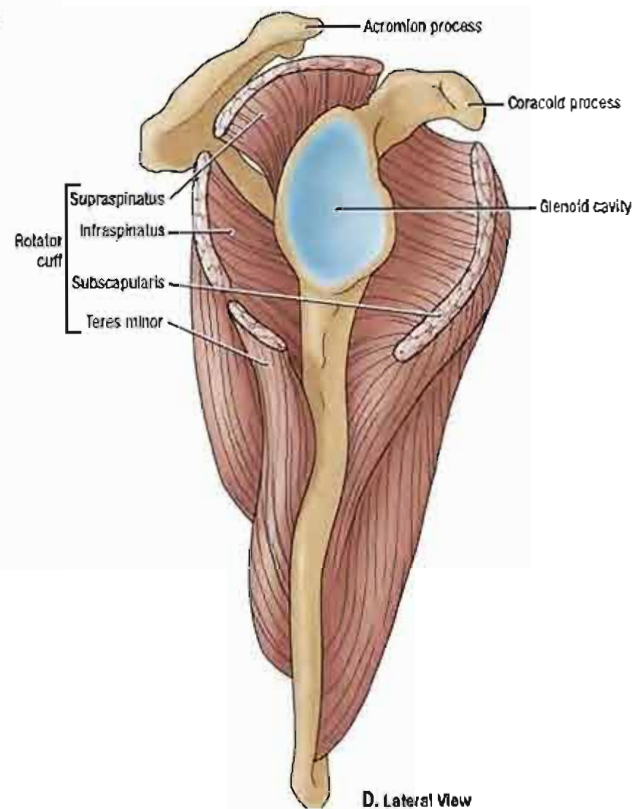
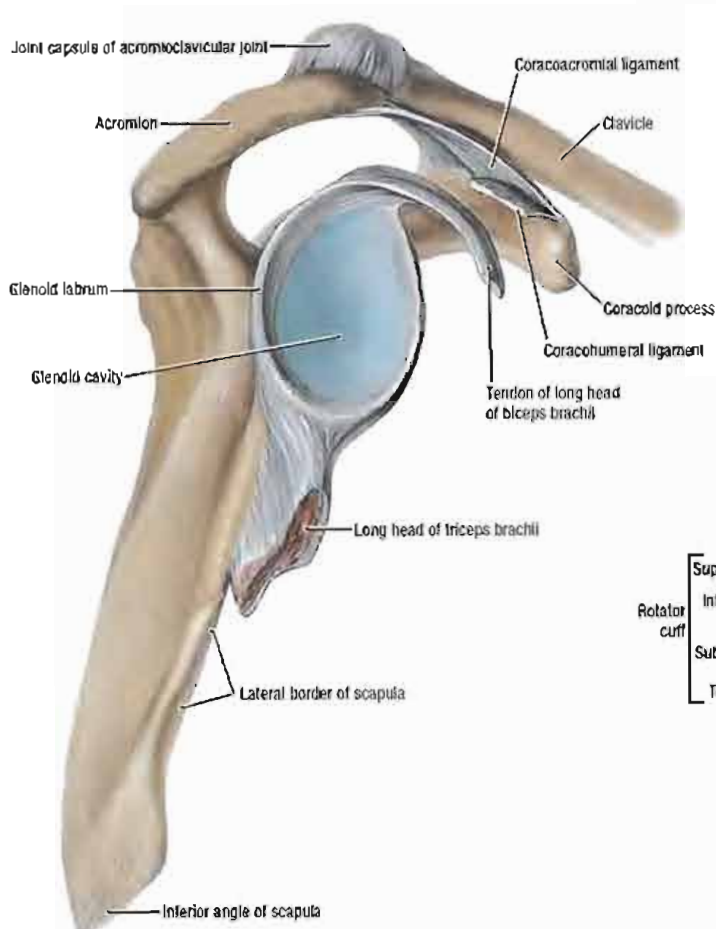
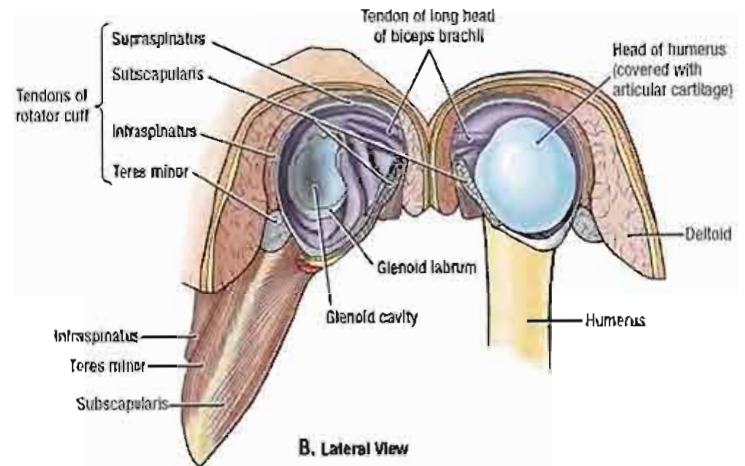
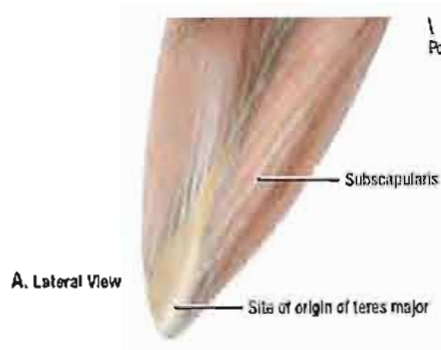
posteroinferior part of the capsule and sawing off the head of the humerus.

- The glenohumeral ligaments are visible from within the joint but are not easily seen externally.
- The glenohumeral ligaments and tendon of the long head of biceps brachii muscle converge on the supraglenoid tubercle.
- The slender superior glenohumeral ligament lies parallel to the tendon of the long head of biceps brachii. The middle ligament is free medially because the subtendinous bursa of subscapularis communicates with the joint cavity, usually there is only a single site of communication. In this individual there are openings on both sides of the ligament.

Because of its freedom of movement and instability, the glenohumeral joint is commonly dislocated by direct or indirect injury. Most dislocations of the humeral head occur in the downward (inferior) direction but are described clinically as anterior or (more rarely) posterior dislocations, indicating whether the humeral head has descended anterior or posterior to the infraglenoid tubercle and the long head of triceps. Anterior dislocation of the glenohumeral joint occurs most often in young adults, particularly athletes. It is usually caused by excessive extension and lateral rotation of the humerus.

P.534







Authors: Agur, Anne M.R.; Dalley, Arthur F.

Title: *Grant's Atlas of Anatomy, 12th Edition*

Copyright ©2009 Lippincott Williams & Wilkins

> Table of Contents > Chapter 6 - Upper Limb > 6.43 Interior of the glenohumeral (shoulder) joint and relationship of rotator cuff

---

## 6.43 Interior of the glenohumeral (shoulder) joint and relationship of rotator cuff

*Part of* "Chapter 6 - Upper Limb "

A. Dissection. B. Schematic illustration.

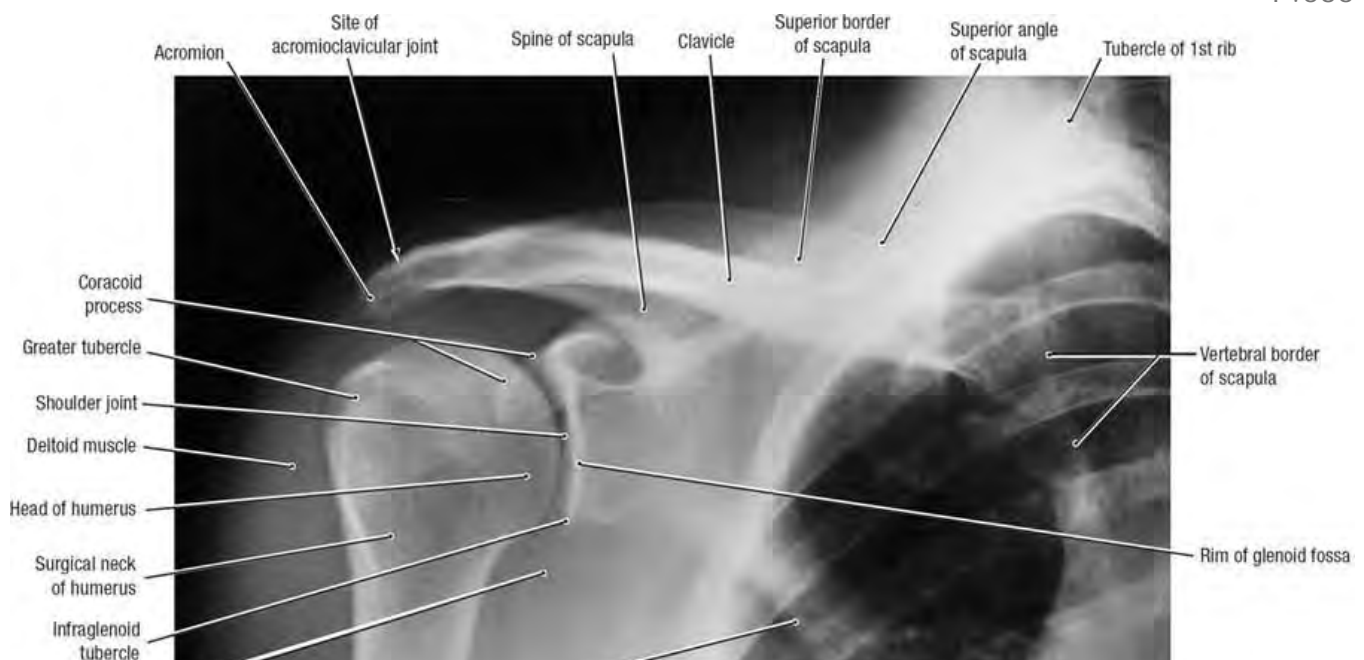
- The fibrous capsule of the joint is thickened anteriorly by the three glenohumeral ligaments.
- The subacromial bursa is between the acromion and deltoid superiorly and the tendon of supraspinatus inferiorly.
- The four short rotator cuff muscles (supraspinatus, infraspinatus, teres minor, and subscapularis) cross the joint and blend with the capsule.
- The axillary nerve and posterior circumflex humeral artery are in contact with the capsule inferiorly and may be injured when the glenohumeral joint dislocates.

- Inflammation and calcification of the subacromial bursa result in pain, tenderness, and limitation of movement of the glenohumeral joint. This condition is also known as calcific scapulohumeral bursitis. Deposition of calcium in the supraspinatus tendon may irritate the overlying subacromial bursa, producing an inflammatory reaction, subacromial bursitis.
-


C. Dissection. D. Schematic illustration of the rotator cuff muscles and their relationship to the glenoid cavity.

- The coracoacromial arch (coracoid process, coracoacromial ligament, and acromion) prevents superior displacement of the head of the humerus.
- The long head of the triceps brachii muscle arises just inferior to the glenoid cavity; the long head of biceps just superior to it.
- The main function of the musculotendinous rotator cuff is to hold the large head of the humerus in the smaller and shallow glenoid cavity of the scapula, both during the relaxed state (by tonic contraction) and during active abduction.

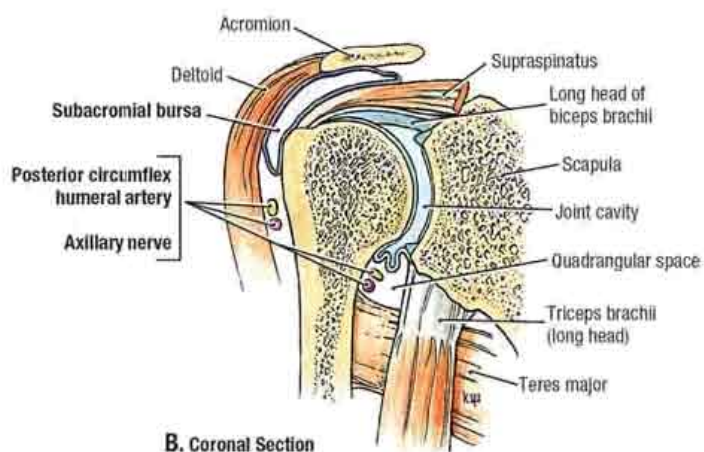
Tearing of the fibrocartilaginous glenoid labrum commonly occurs in the athletes who throw (e.g., a baseball) and in those who have shoulder instability and subluxation (partial dislocation) of the glenohumeral joint. The tear often results from sudden contraction of the biceps or forceful subluxation of the humeral head over the glenoid labrum. Usually a tear occurs in the anterosuperior part of the labrum.



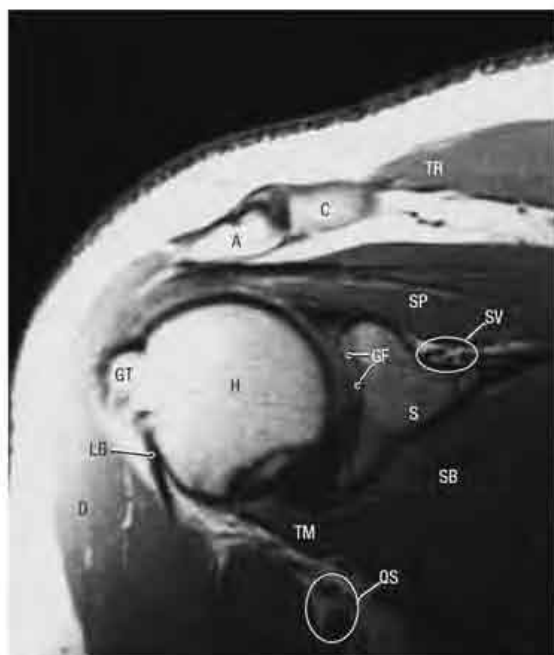



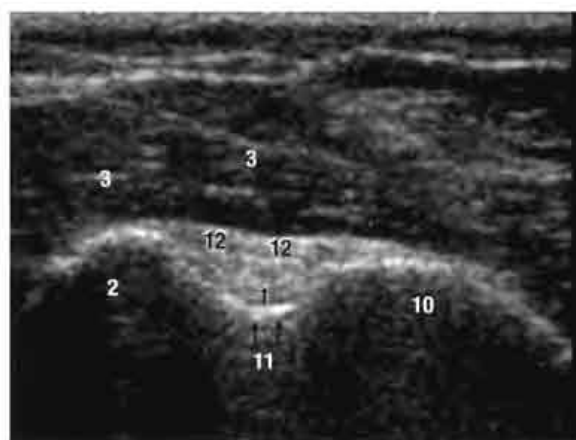
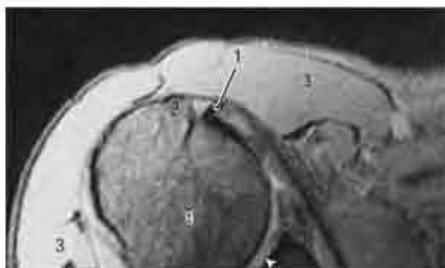**A. Anteroposterior View**



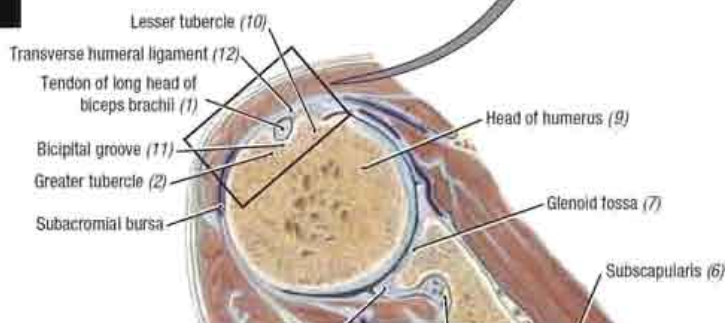
**B. Coronal Section**

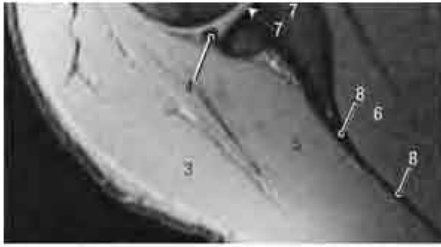

**C. Coronal MRI**

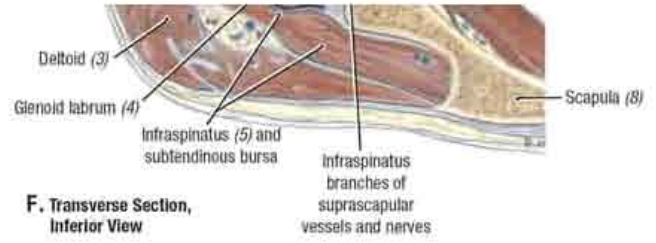


**D. Transverse Scan**

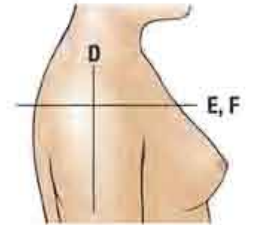




**E. Transverse MRI**



**F. Transverse Section,  
Inferior View**



## 6.44 Imaging of glenohumeral (shoulder) joint

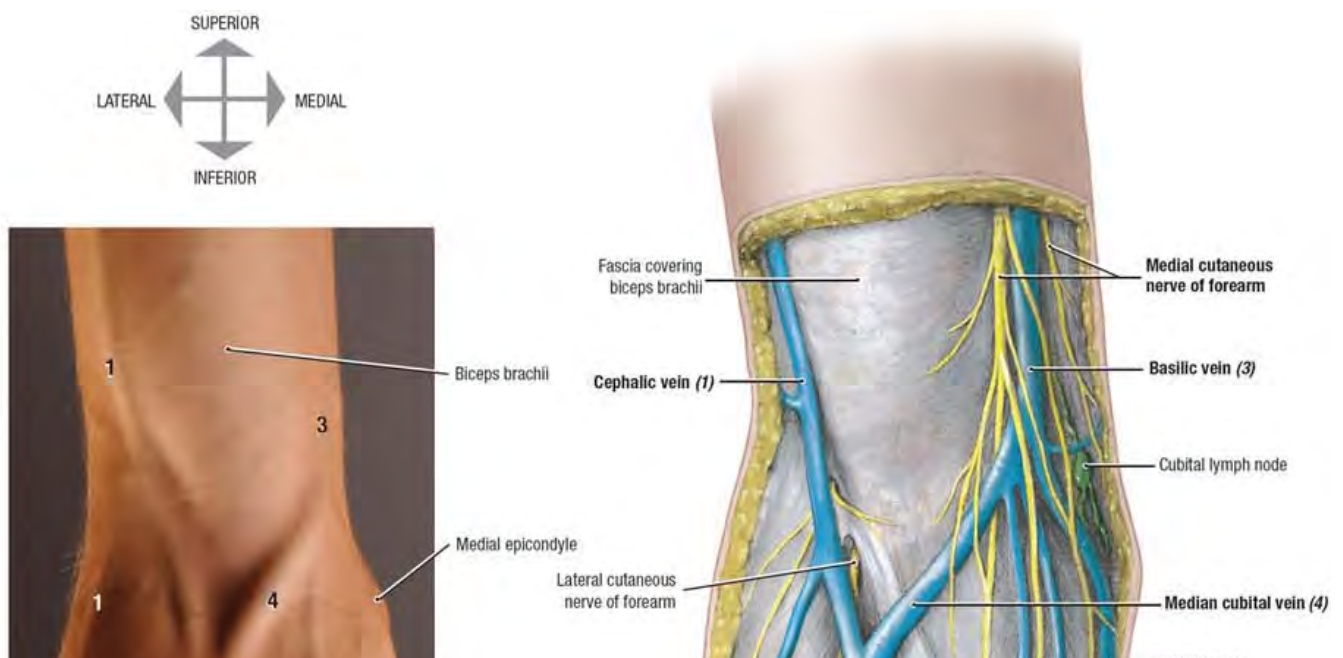
Part of "Chapter 6 - Upper Limb "

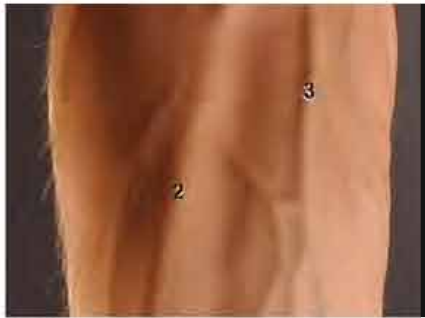A. Radiograph. B. Sectioned joint to show location of subacromial bursa and joint cavity.

P.537

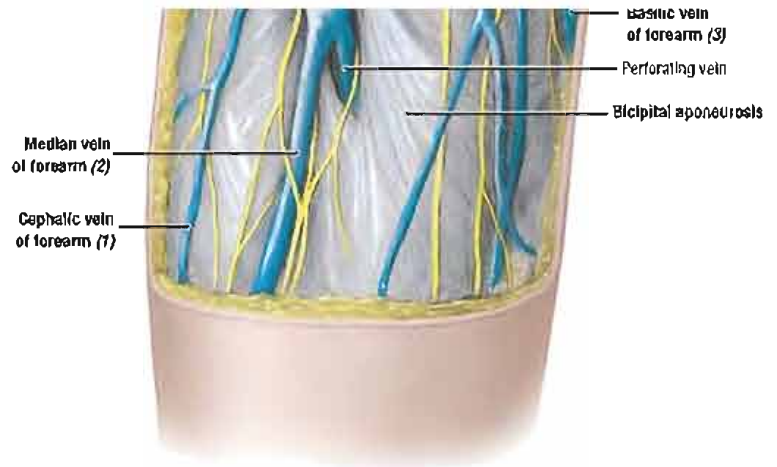
C. Coronal MRI. *A*, acromion; *C*, clavicle; *D*, deltoid; *GF*, glenoid cavity; *GT*, crest of greater tubercle; *H*, head of humerus; *LB*, long head of biceps brachii; *QS*, quadrangular space; *S*, scapula; *SB*, subscapularis; *SP*, supraspinatus; *SV*, suprascapular vessels and nerve; *TM*, teres minor; *TR*, trapezius. D. Transverse ultrasound scan of area indicated in F. E. Transverse MRI. F. Transverse section (*numbers* in F refer to structures labeled in D and E ).

P.538

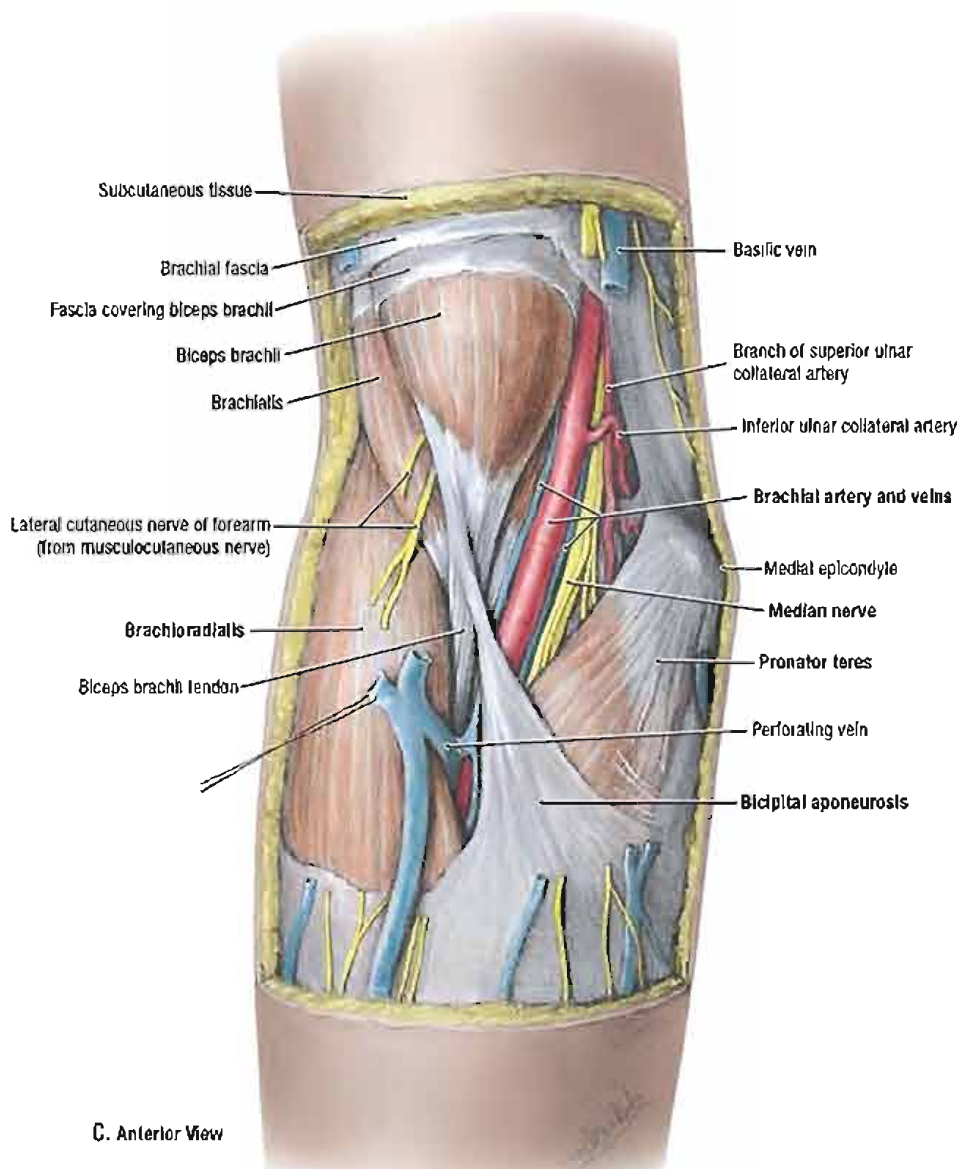




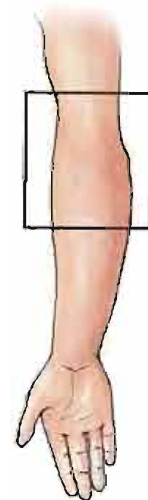
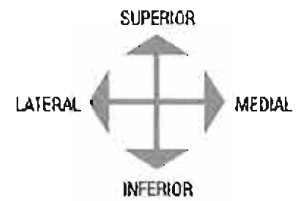
A. Anterior View

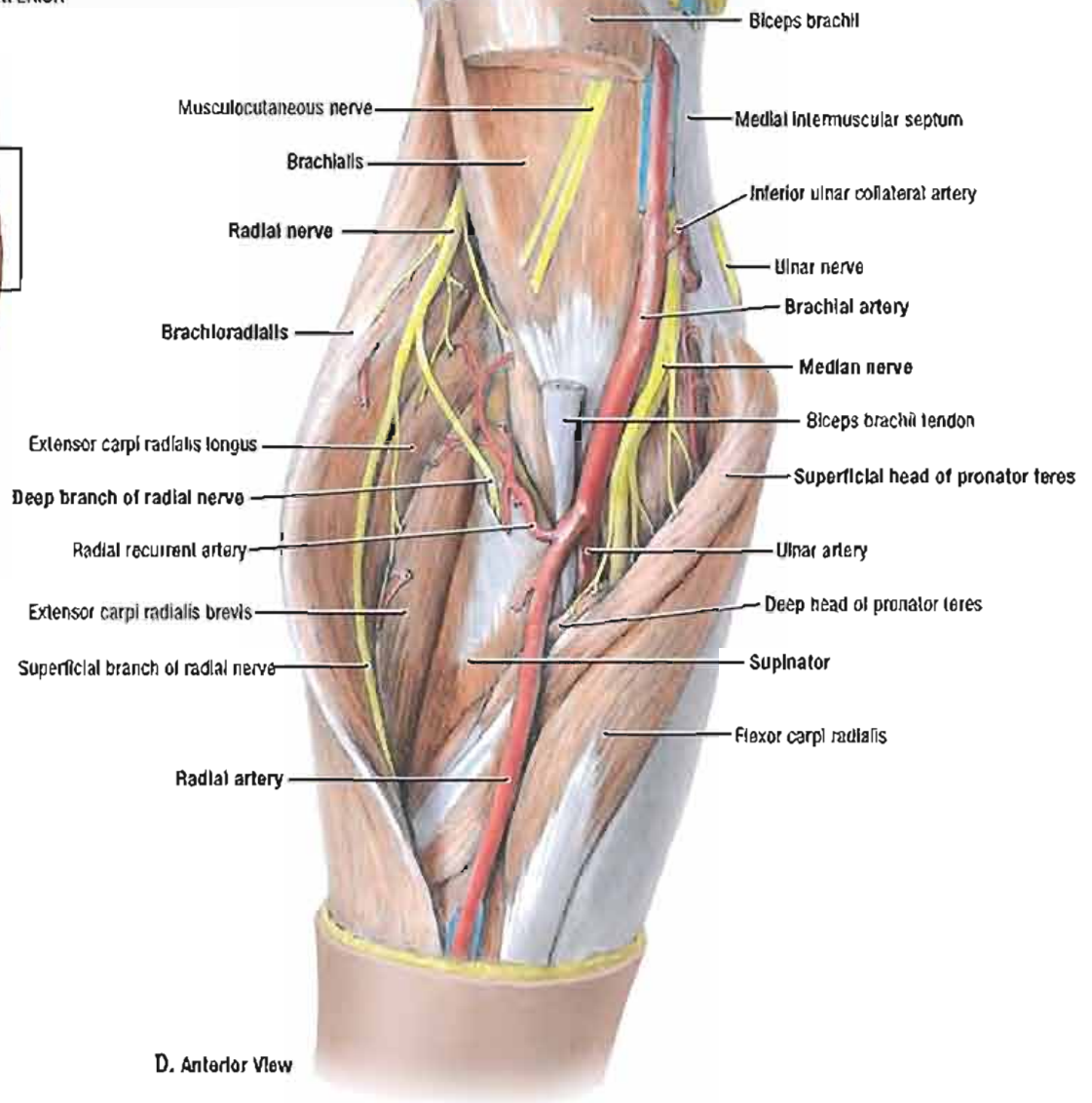
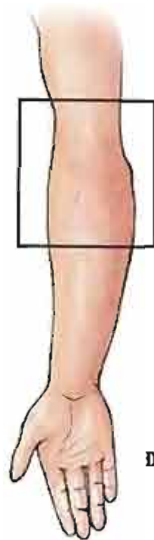
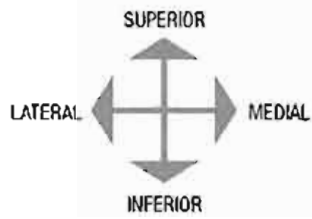


B. Anterior View



C. Anterior View







Authors: Agur, Anne M.R.; Dalley, Arthur F.

Title: *Grant's Atlas of Anatomy, 12th Edition*

Copyright ©2009 Lippincott Williams & Wilkins

> Table of Contents > Chapter 6 - Upper Limb > 6.45 Cubital fossa: Surface anatomy and superficial dissection

---

## 6.45 Cubital fossa: Surface anatomy and superficial dissection

*Part of* "Chapter 6 - Upper Limb"

A. Surface anatomy. B. Cutaneous nerves and superficial veins (*numbers* in parentheses refer to structures in A).

- The cubital fossa is a triangular space (compartment) inferior to the elbow crease, roofed by deep fascia.
  - In the forearm, the superficial veins (cephalic, median, basilic, and their connecting veins) make a variable, M-shaped pattern.
  - The cephalic and basilic veins occupy the bicipital grooves, one on each side of the biceps brachii. In the lateral bicipital groove, the lateral cutaneous nerve of the forearm appears just superior to the elbow crease; in the medial bicipital groove, the medial cutaneous nerve of the forearm becomes cutaneous at approximately the midpoint of the arm.
- The cubital fossa is the common site for sampling and transfusion of blood and intravenous injections because of the prominence and accessibility of veins. Usually, the median cubital vein or basilic vein is selected.

Authors: Agur, Anne M.R.; Dalley, Arthur F.

Title: *Grant's Atlas of Anatomy, 12th Edition*

Copyright ©2009 Lippincott Williams & Wilkins

> Table of Contents > Chapter 6 - Upper Limb > 6.45 Cubital fossa: Deep dissection I

---

## 6.45 Cubital fossa: Deep dissection I

Part of "Chapter 6 - Upper Limb"

---

P.539

C. Boundaries and contents of the cubital fossa.

- The cubital fossa is bound laterally by the brachioradialis and medially by the pronator teres and superiorly by a line joining the medial and lateral epicondyles.
- The three chief contents of the cubital fossa are the biceps brachii tendon, brachial artery, and median nerve.
- The biceps brachii tendon, on approaching its insertion, rotates through 90°, and the bicipital aponeurosis extends medially from the proximal part of the tendon.

- A fracture of the distal part of the humerus, near the supraepicondylar ridges, is called a *supraepicondylar fracture*. The distal bone fragment may be displaced anteriorly or posteriorly. Any of the nerves or branches of the brachial vessels related to the humerus may be injured by a displaced bone fragment.

Authors: Agur, Anne M.R.; Dalley, Arthur F.

Title: *Grant's Atlas of Anatomy, 12th Edition*

Copyright ©2009 Lippincott Williams & Wilkins

> Table of Contents > Chapter 6 - Upper Limb > 6.45 Cubital fossa: Deep dissection II

---

## 6.45 Cubital fossa: Deep dissection II

*Part of* "Chapter 6 - Upper Limb "

---

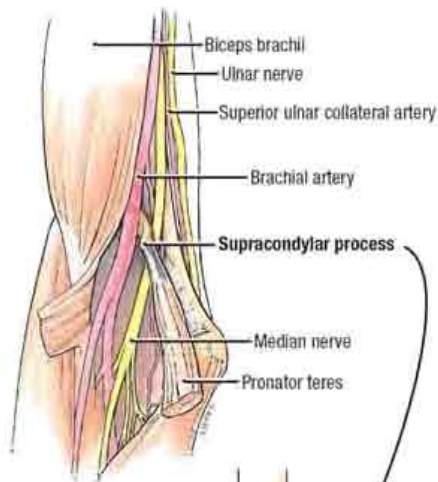
P.540

D. Floor of the cubital fossa.

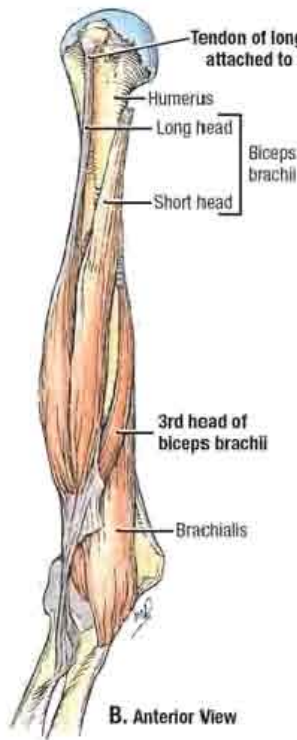
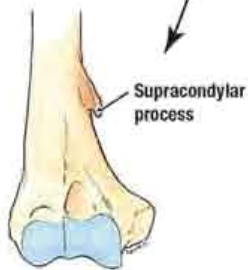- Part of the biceps brachii muscle is excised, and the cubital fossa is opened widely, exposing the brachialis and supinator muscles in the floor of the fossa.
- The deep branch of the radial nerve pierces the supinator.
- The brachial artery lies between the biceps tendon and median nerve and divides into two branches, the ulnar and radial arteries.
- The median nerve supplies the flexor muscles. With the exception of the twig to the deep head of pronator teres, its motor branches arise from its medial side.
- The radial nerve supplies the extensor muscles. With the exception of the twig to brachioradialis, its motor branches arise from its lateral side. In this specimen, the radial nerve has been displaced laterally, so here its lateral branches appear to run medially.

---

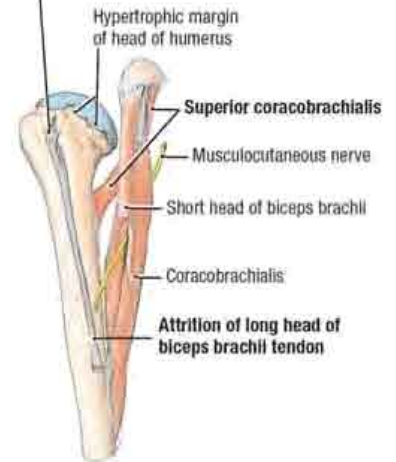
P.541



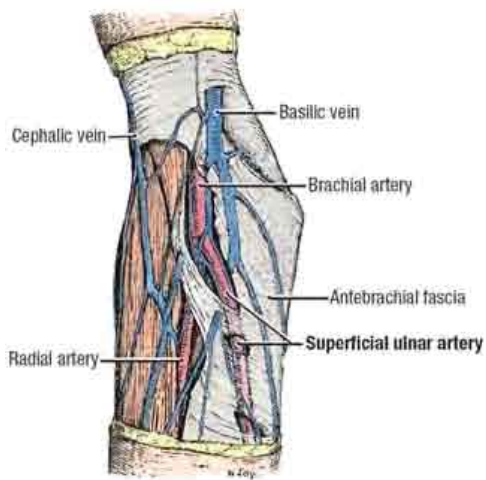
A. Anterior View



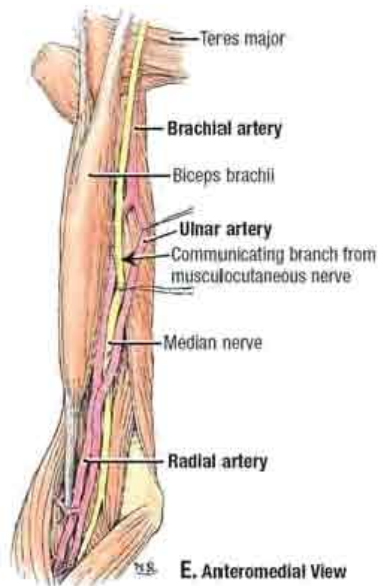
B. Anterior View



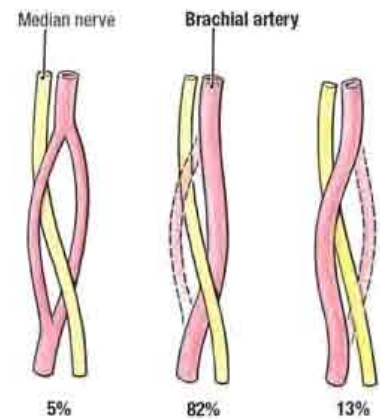
C. Anterior View



D. Anterior View



E. Anteromedial View



F. Anterior Views

Authors: Agur, Anne M.R.; Dalley, Arthur F.

Title: *Grant's Atlas of Anatomy, 12th Edition*

Copyright ©2009 Lippincott Williams & Wilkins

> Table of Contents > Chapter 6 - Upper Limb > 6.46 Anomalies

---

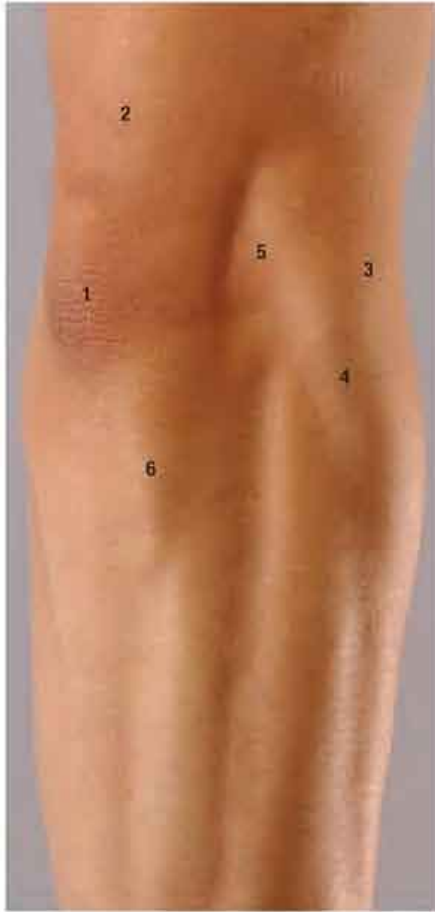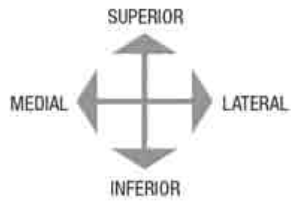
## 6.46 Anomalies

*Part of "Chapter 6 - Upper Limb "*

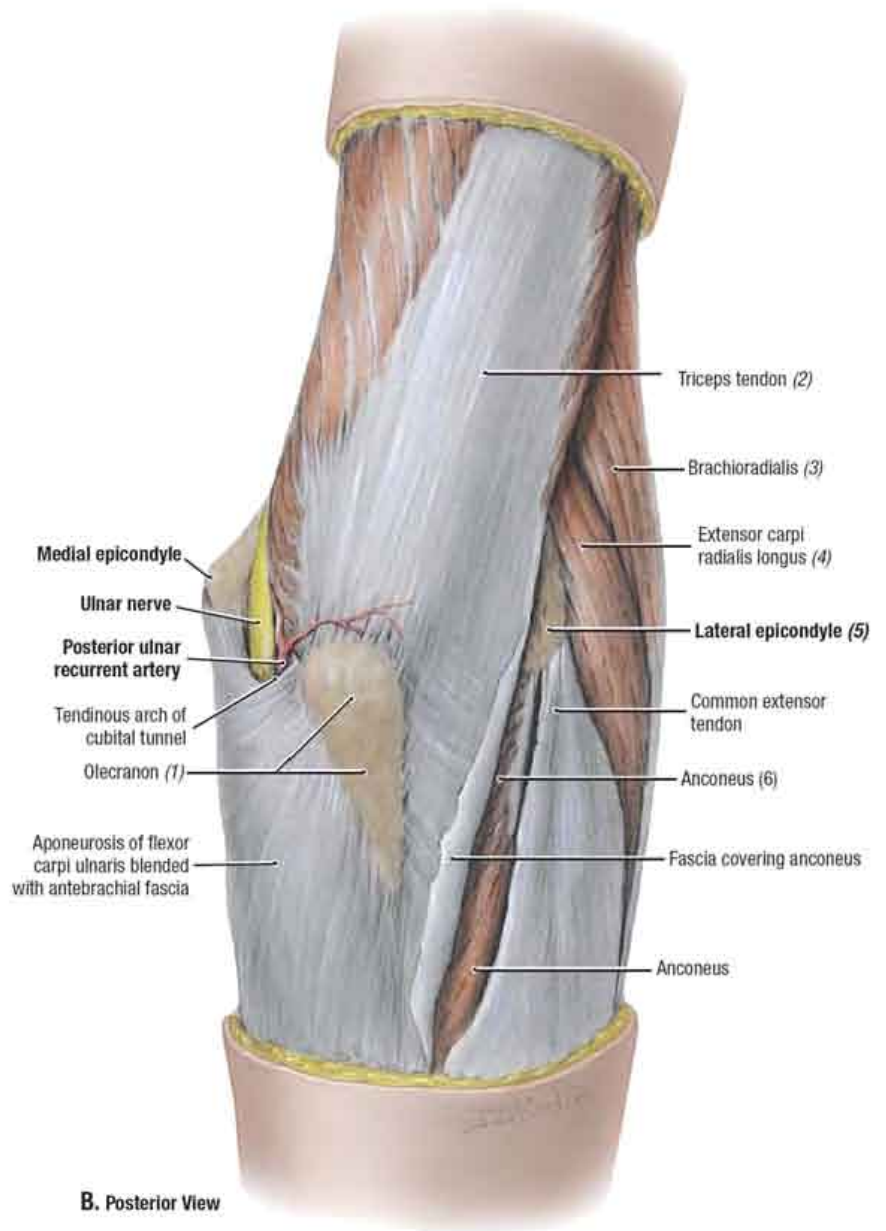
A. Supracondylar process of humerus. A fibrous band, from which the pronator teres muscle arises, joins this supraepicondylar process to the medial epicondyle. The median nerve, often accompanied by the brachial artery, passes through the foramen formed by this band. This may be a cause of nerve entrapment. B. Third head of biceps brachii. In this case, there is also attrition of the biceps tendon. C. Attrition of the tendon of the long head of biceps brachii and presence of a coracobrachialis.

D. Superficial ulnar artery. E. Anomalous division of brachial artery. In this case, the median nerve passes between the radial and ulnar arteries, which arise high in the arm. F. Relationship of median nerve and brachial artery. The variable relationship of these two structures can be explained developmentally. In a study of 307 limbs, portions of both primitive brachial arteries persisted in 5%, the posterior in 82%, and the anterior in 13%.





**A. Posterior View**



**B. Posterior View**

Authors: Agur, Anne M.R.; Dalley, Arthur F.

Title: *Grant's Atlas of Anatomy, 12th Edition*

Copyright ©2009 Lippincott Williams & Wilkins

> Table of Contents > Chapter 6 - Upper Limb > 6.47 Posterior aspect of elbow

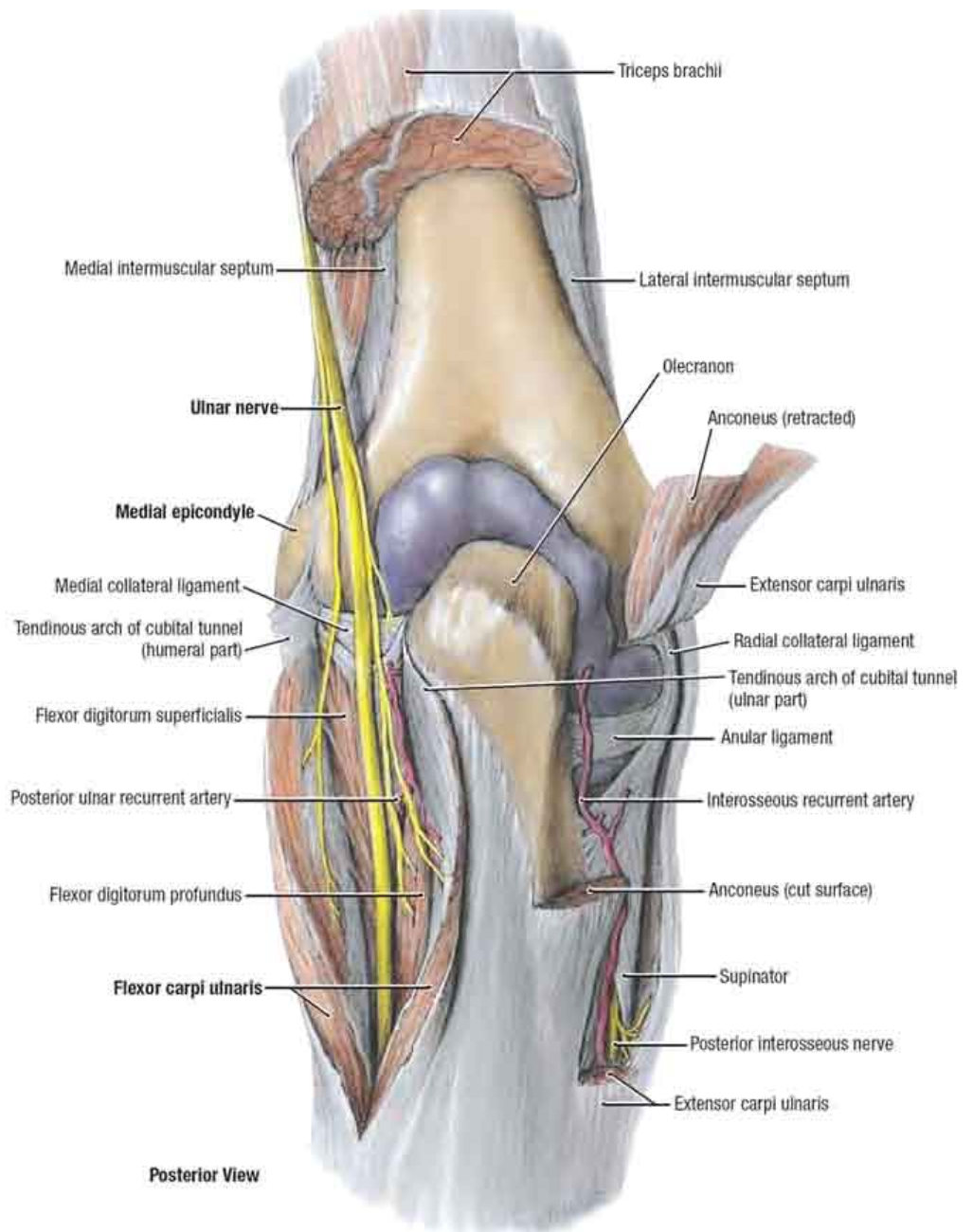
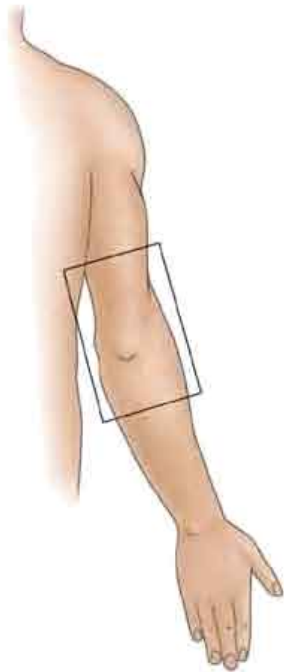
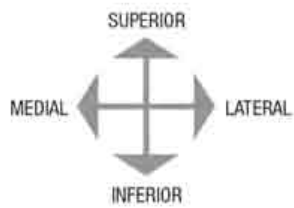
---

## 6.47 Posterior aspect of elbow

*Part of* "Chapter 6 - Upper Limb "

A. Surface anatomy. B. Superficial dissection (*numbers* in parentheses refer to structures in A ).

- The triceps brachii is attached distally to the superior surface of the olecranon and, through the deep fascia covering the anconeus, into the lateral border of olecranon.
- The posterior surfaces of the medial epicondyle, lateral epicondyle, and olecranon are subcutaneous and palpable.
- The ulnar nerve, also palpable, runs subfascially posterior to the medial epicondyle; distal to this point, it disappears deep to the two heads of the flexor carpi ulnaris.



**Posterior View**

Authors: Agur, Anne M.R.; Dalley, Arthur F.

Title: *Grant's Atlas of Anatomy, 12th Edition*

Copyright ©2009 Lippincott Williams & Wilkins

> Table of Contents > Chapter 6 - Upper Limb > 6.48 Posterior aspect of elbow "II

---

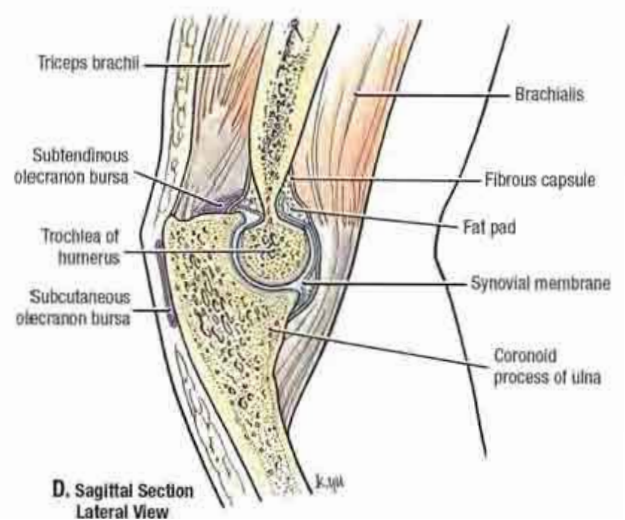
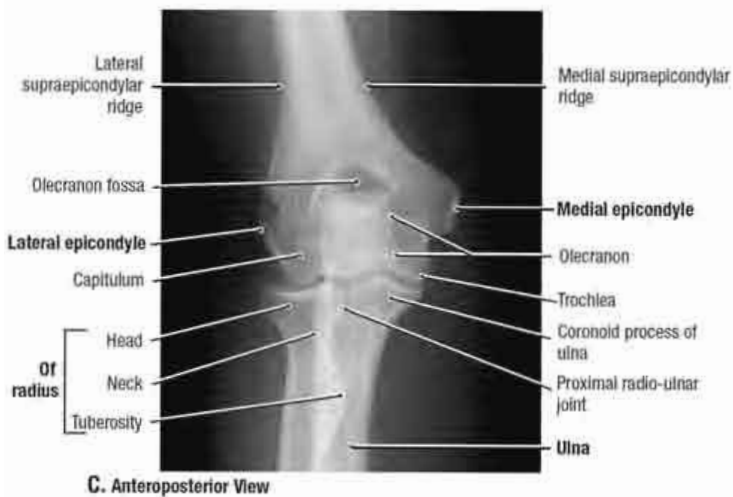
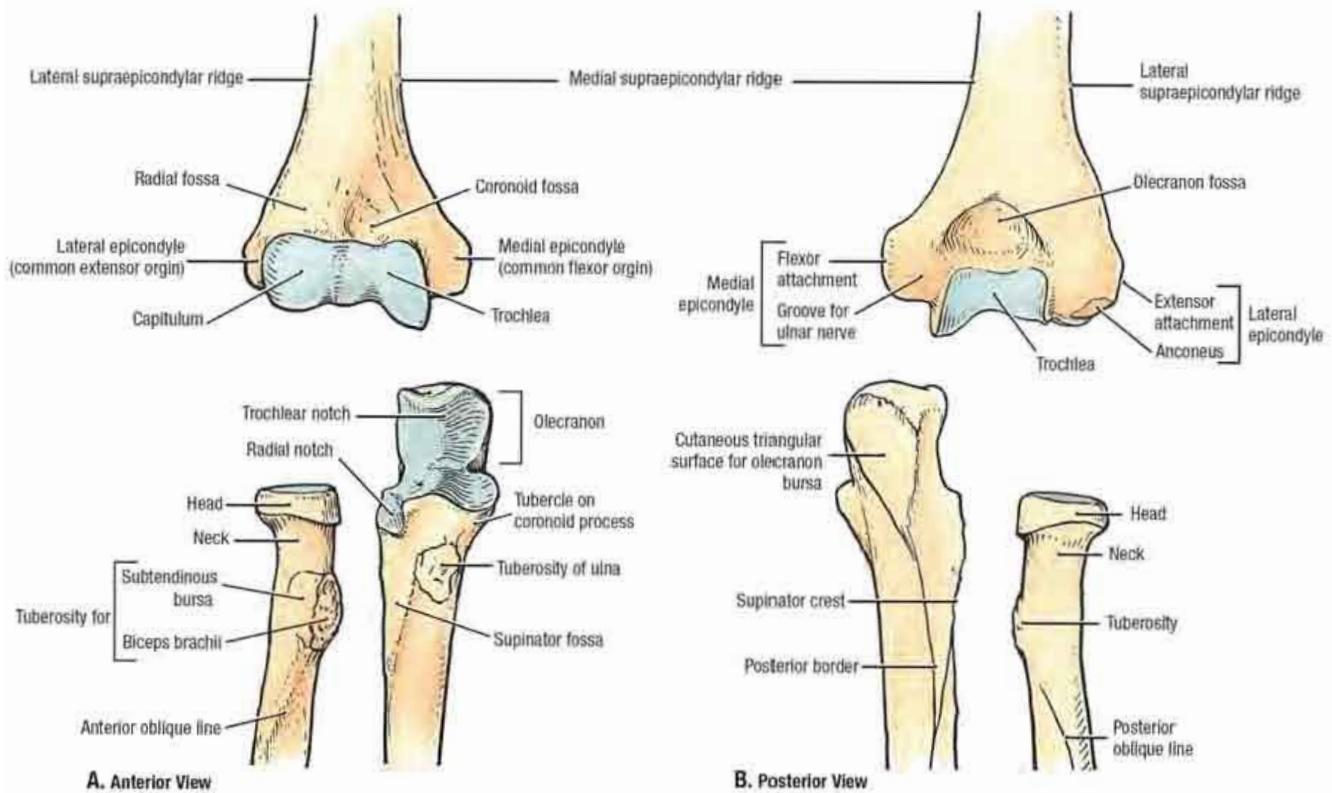
## 6.48 Posterior aspect of elbow "II

*Part of "Chapter 6 - Upper Limb "*

C. Deep dissection. The distal portion of the triceps brachii muscle was removed.

- The ulnar nerve descends subfascially within the posterior compartment of the arm, passing posterior to the medial epicondyle in the groove for the ulnar nerve. Next it passes posterior to the ulnar collateral ligament of the elbow joint and then between the flexor carpi ulnaris and flexor digitorum profundus muscles.

Ulnar nerve injury occurs most commonly where the nerve passes posterior to the medial epicondyle of the humerus. The injury results when the medial part of the elbow hits a hard surface, fracturing the medial epicondyle. The ulnar nerve may be compressed in the cubital tunnel (cubital tunnel syndrome) formed by the tendinous arch joining the humeral and ulnar heads of attachment of the flexor carpi ulnaris muscle. Ulnar nerve injury can result in extensive motor and sensory loss to the hand.





Authors: Agur, Anne M.R.; Dalley, Arthur F.

Title: *Grant's Atlas of Anatomy, 12th Edition*

Copyright ©2009 Lippincott Williams & Wilkins

> Table of Contents > Chapter 6 - Upper Limb > 6.49 Bones and imaging of elbow region

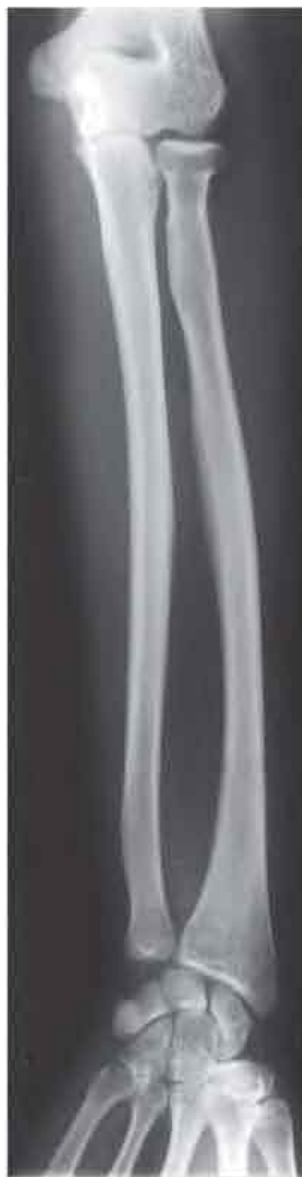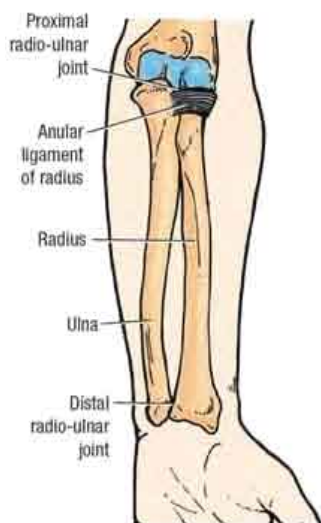
---

## 6.49 Bones and imaging of elbow region

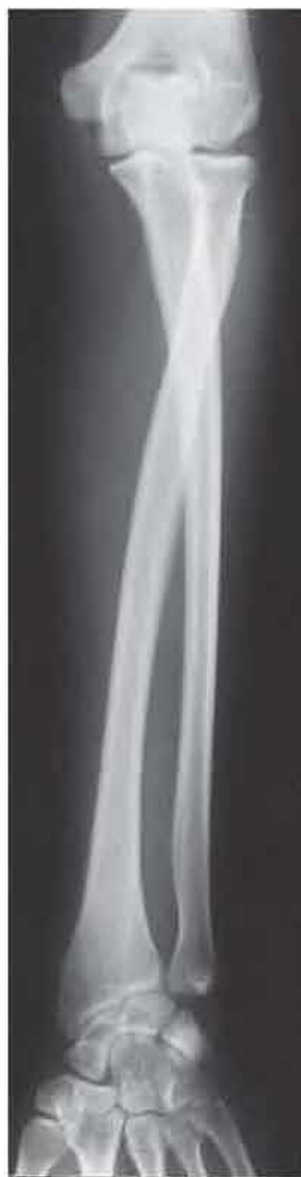*Part of "Chapter 6 - Upper Limb "*

A. Anterior bony features. B. Posterior bony features. C. Radio-graph of elbow joint. D. Section of humero-ulnar joint.

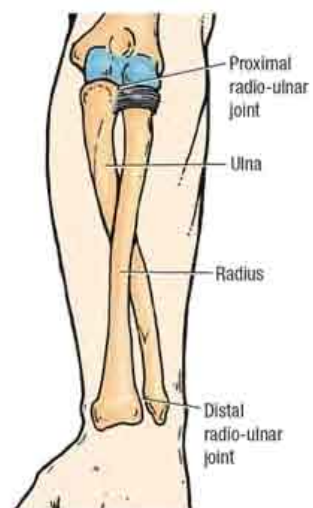
The subcutaneous olecranon bursa is exposed to injury during falls on the elbow and to infection from abrasions of the skin covering the olecranon. Repeated excessive pressure and friction produces a friction subcutaneous olecranon bursitis (e.g., "student's elbow" • ). Subtendinous olecranon bursitis results from excessive friction between the triceps tendon and the olecranon, for example, resulting from repeated flexion-extension of the forearm as occurs during certain assembly-line jobs. The pain is severe during flexion of the forearm because of pressure exerted on the inflamed subtendinous olecranon bursa by the triceps tendon.



**A. Anterior View, Supination**



**B. Anterior View, Pronation**



Authors: Agur, Anne M.R.; Dalley, Arthur F.

Title: *Grant's Atlas of Anatomy, 12th Edition*

Copyright ©2009 Lippincott Williams & Wilkins

> Table of Contents > Chapter 6 - Upper Limb > 6.50 Supination and pronation at superior, middle, and inferior radio-ulnar joints

---

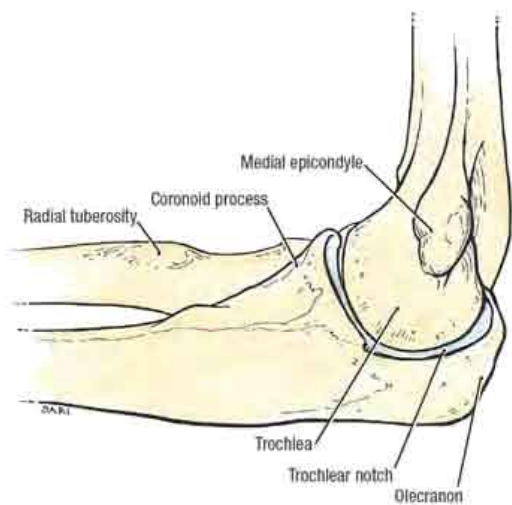
## 6.50 Supination and pronation at superior, middle, and inferior radio-ulnar joints

*Part of* "Chapter 6 - Upper Limb "

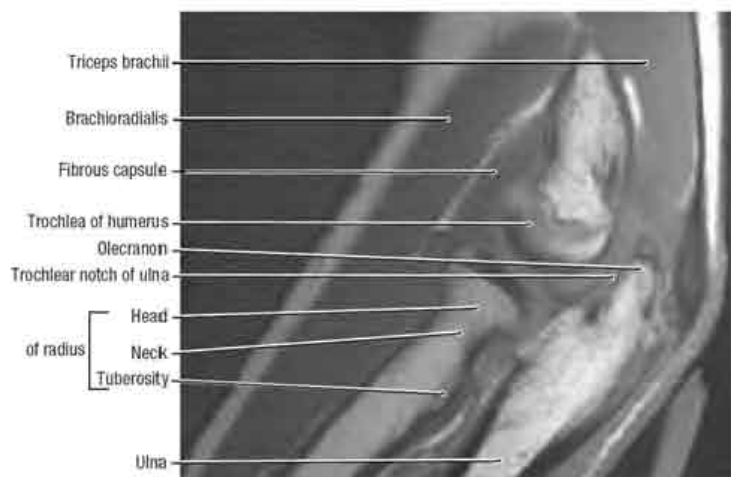
A. Radiograph of forearm in supination. B. Radiograph of forearm in pronation. The radius crosses the ulna when the forearm is pronated. The superior and inferior radio-ulnar joints are synovial joints; the middle radio-ulnar joint is a syndesmosis (fibrous joint) in which the interosseous ligament connects the forearm bones.

---

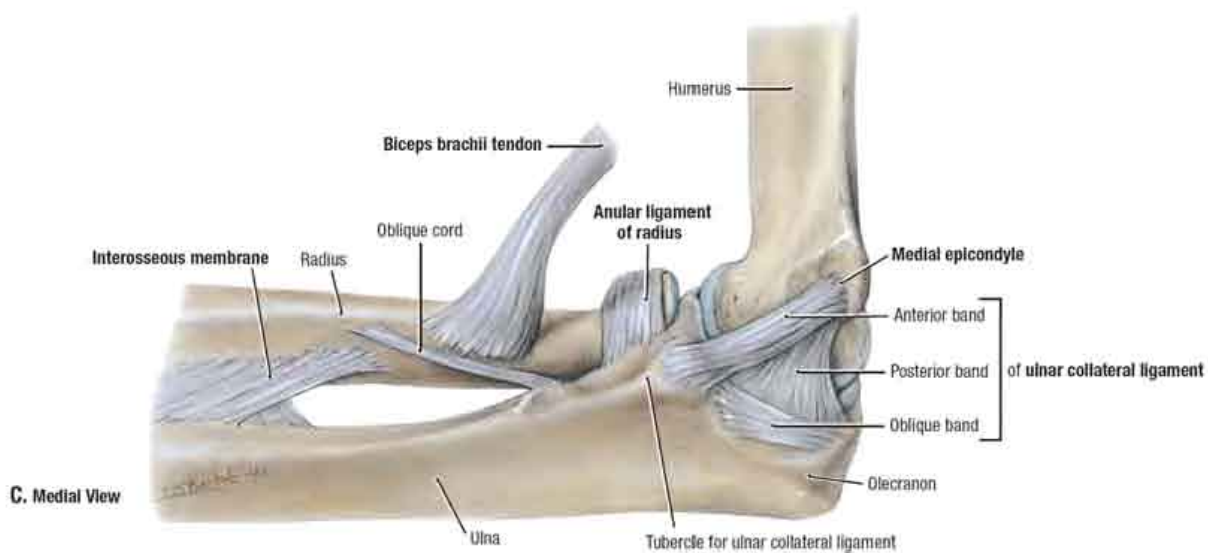
P.546



**A. Medial View**



**B. Sagittal MRI**



**C. Medial View**

Authors: Agur, Anne M.R.; Dalley, Arthur F.

Title: *Grant's Atlas of Anatomy, 12th Edition*

Copyright ©2009 Lippincott Williams & Wilkins

> Table of Contents > Chapter 6 - Upper Limb > 6.51 Medial aspect of bones and ligaments of elbow region

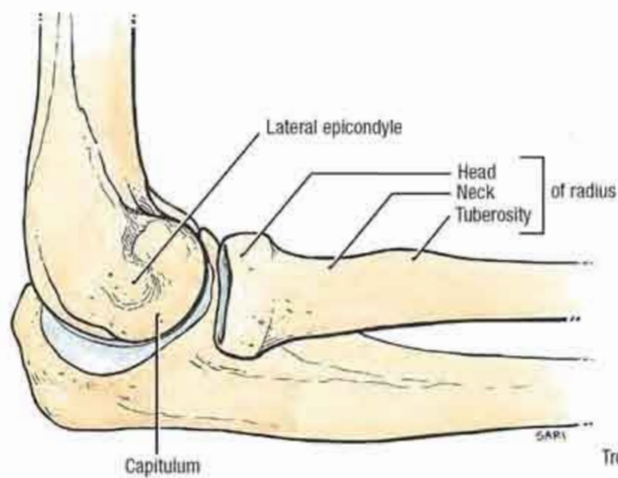
---

## 6.51 Medial aspect of bones and ligaments of elbow region

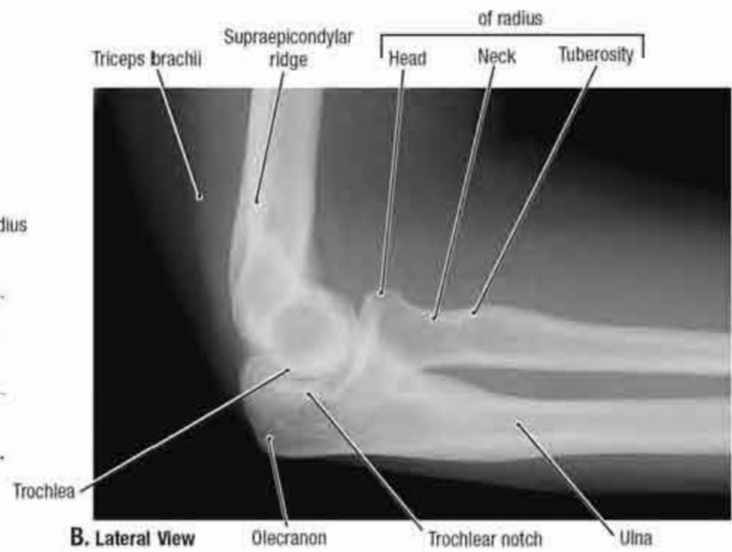
*Part of "Chapter 6 - Upper Limb "*

A. Bony features. B. MRI of elbow joint. C. Ligaments. The anterior band of the ulnar (medial) collateral ligament is a strong, round cord that is taut when the elbow joint is extended. The posterior band is a weak fan that is taut in flexion of the joint. The oblique fibers deepen the socket for the trochlea of the humerus.

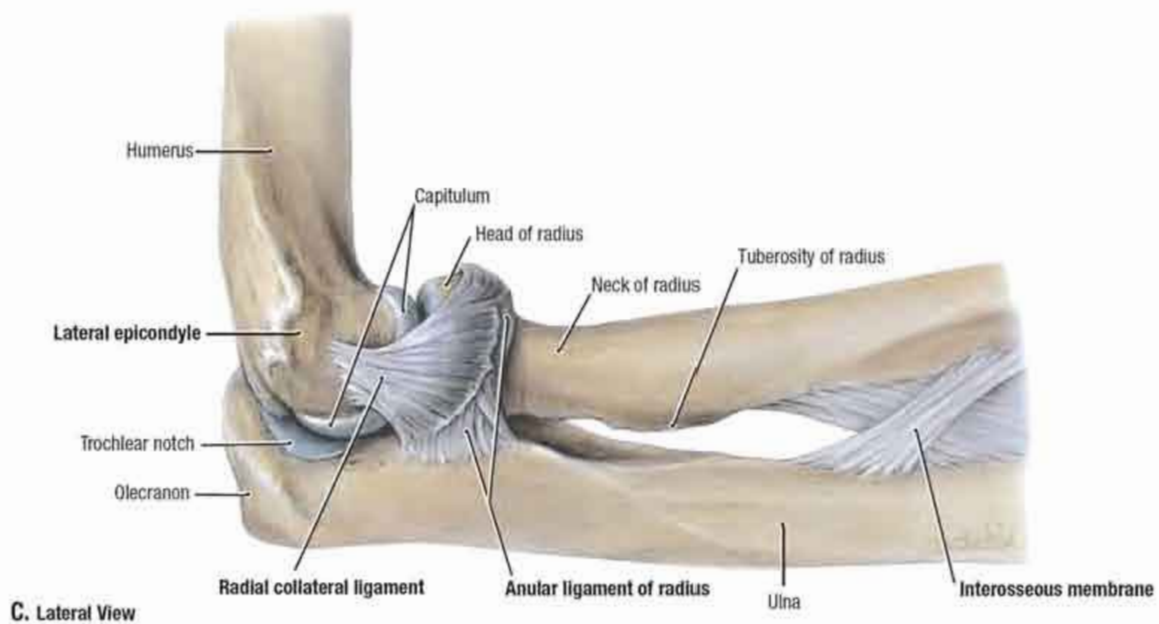




**A. Lateral View**



**B. Lateral View**



**C. Lateral View**

Authors: Agur, Anne M.R.; Dalley, Arthur F.

Title: *Grant's Atlas of Anatomy, 12th Edition*

Copyright ©2009 Lippincott Williams & Wilkins

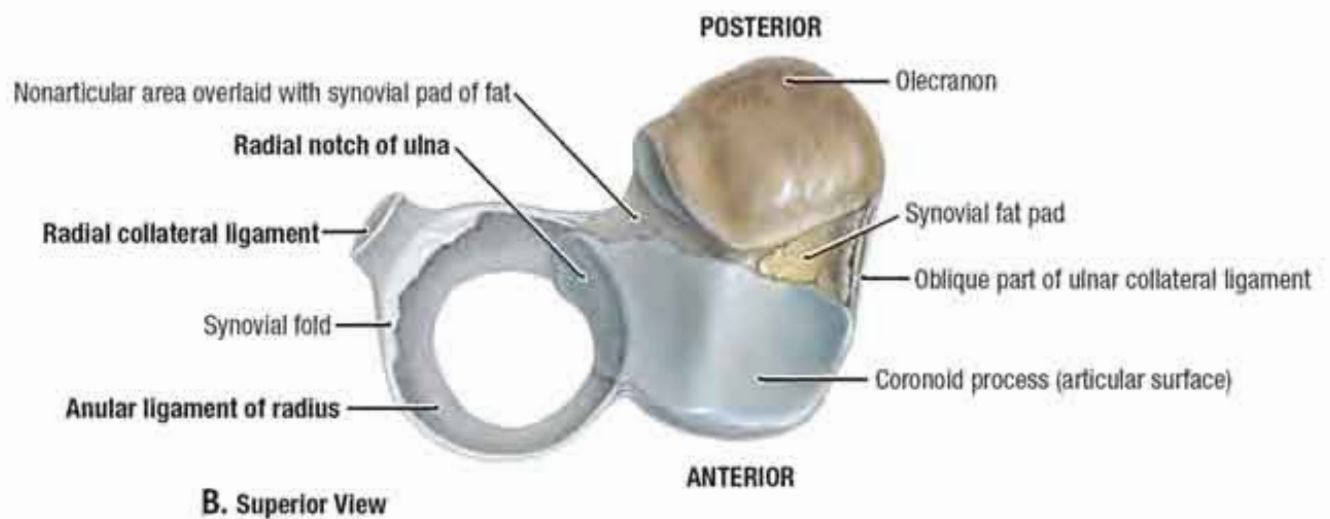
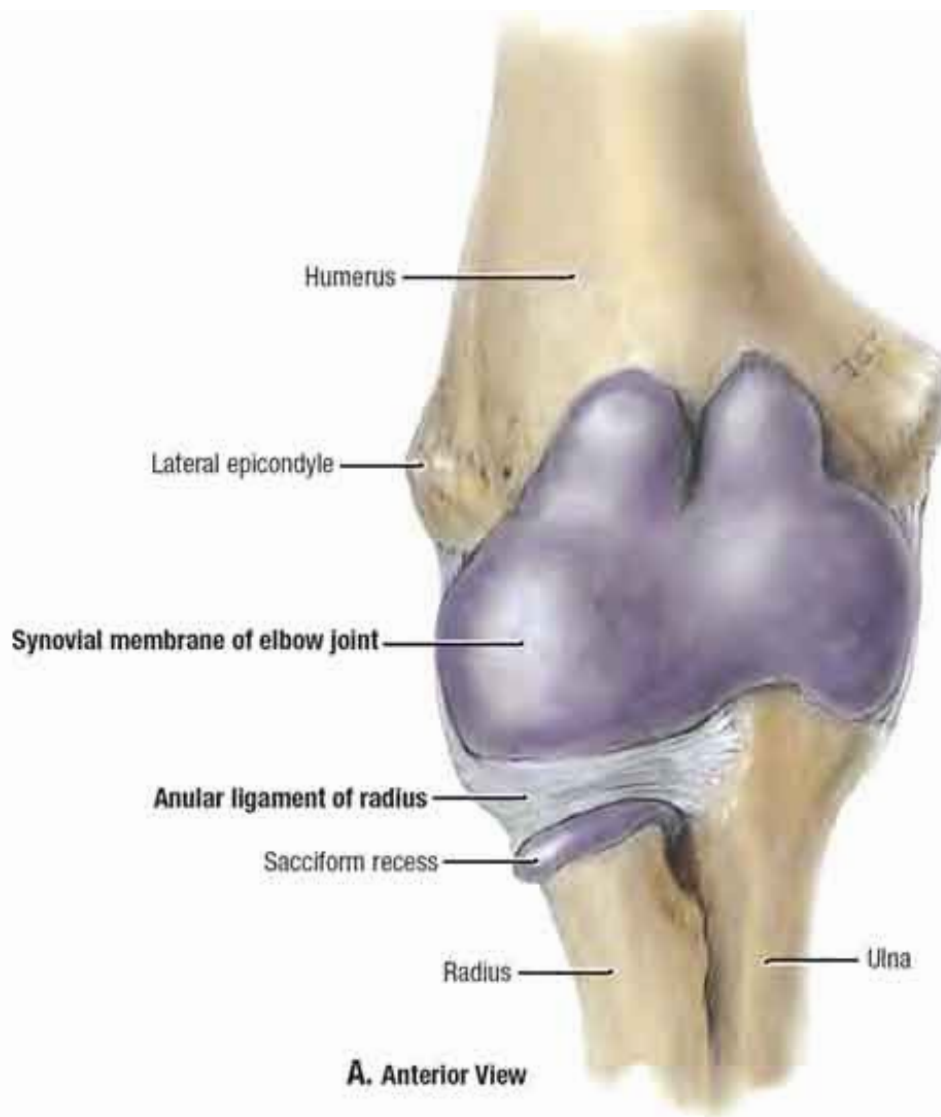
> Table of Contents > Chapter 6 - Upper Limb > 6.52 Lateral aspect of bones and ligaments of elbow region

---

## 6.52 Lateral aspect of bones and ligaments of elbow region

*Part of "Chapter 6 - Upper Limb "*

A. Bony features. B. Lateral radiograph. C. Ligaments. The fan-shaped radial (lateral) collateral ligament is primarily attached to the anular ligament of the radius; superficial fibers of the lateral ligament blend with the fibrous capsule and continue onto the radius.





Authors: Agur, Anne M.R.; Dalley, Arthur F.

Title: *Grant's Atlas of Anatomy, 12th Edition*

Copyright ©2009 Lippincott Williams & Wilkins

> Table of Contents > Chapter 6 - Upper Limb > 6.53 Synovial capsule of elbow joint and anular ligament

---

## 6.53 Synovial capsule of elbow joint and anular ligament

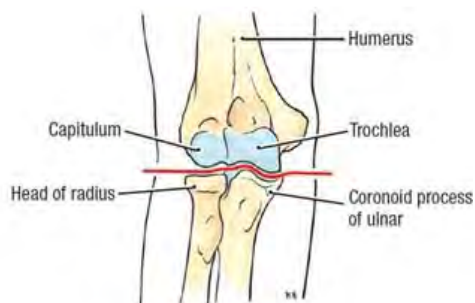
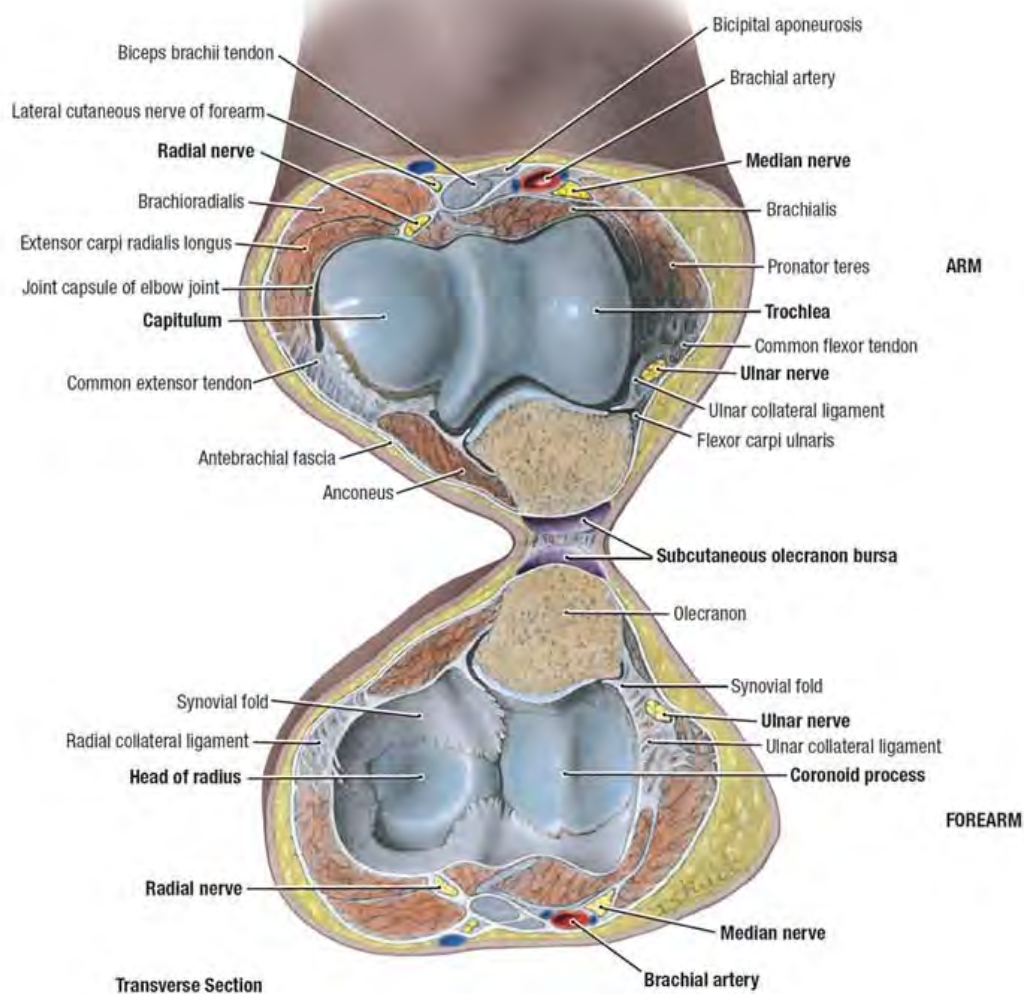
*Part of* "Chapter 6 - Upper Limb "

A. Synovial capsule of elbow and proximal radio-ulnar joints. The cavity of the elbow was injected with purple fluid (wax). The fibrous capsule was removed, and the synovial membrane remains. B. Anular ligament.

- The anular ligament secures the head of the radius to the radial notch of the ulna and with it forms a tapering columnar socket (i.e., wide superiorly, narrow inferiorly).
- The anular ligament is bound to the humerus by the radial collateral ligament of the elbow.

A common childhood injury is subluxation and dislocation of the head of the radius after traction on a pronated forearm (e.g., when lifting a child onto a bus). The sudden pulling of the upper limb tears or stretches the distal attachment of the less tapering anular ligament of a child. The radial head then moves distally, partially out of the anular ligament. The proximal part of the torn ligament may become trapped between the head of the radius and the capitulum of the humerus. The source of pain is the pinched anular ligament.





Authors: Agur, Anne M.R.; Dalley, Arthur F.

Title: *Grant's Atlas of Anatomy, 12th Edition*

Copyright ©2009 Lippincott Williams & Wilkins

> Table of Contents > Chapter 6 - Upper Limb > 6.54 Articular surfaces of elbow joint

---

## 6.54 Articular surfaces of elbow joint

*Part of "Chapter 6 - Upper Limb "*

The tissue surrounding the condyles of the humerus has been sectioned in a transverse plane, followed by disarticulation of the elbow joint, revealing the articular surfaces. Compare the forearm (inferior) component with Fig. 6.53B .

- Synovial folds containing fat overlie the periphery of the head of the radius and the nonarticular indentations on the trochlear notch of the ulna.
- The radial nerve is in contact with the joint capsule, the ulnar nerve is in contact with the ulnar collateral ligament, and the median nerve is separated from the joint capsule by the brachialis muscle.

---

P.550

Radial artery

Origin:

In cubital fossa, as smaller terminal division of brachial artery

Course/Distribution:

Runs distally under brachioradialis, lateral to flexor carpi radialis, defining boundary between the flexor and extensor compartments and supplying the radial aspect of both. Gives rise to a superficial palmar branch near the radiocarpal joint; it then transverses the anatomical snuff box to pass between the heads of the 1st dorsal interosseous muscle joining the deep branch of the ulnar artery to form the deep palmar arch

Ulnar artery

Origin:

In cubital fossa, as larger terminal division of brachial artery

Course/Distribution:

Passes distally between 2nd and 3rd layers of forearm flexor muscles, supplying ulnar aspect of flexor compartment; passes superficial to flexor retinaculum at wrist, continuing as the superficial palmar arch (with superficial branch of radial) after its deep palmar branch joins the deep palmar arch

Radial recurrent artery

Origin:

In cubital fossa, as 1st (lateral) branch of radial artery

Course/Distribution:

Courses proximally, superficial to supinator, passing between brachioradialis and brachialis to anastomose with radial collateral artery

Anterior and posterior ulnar recurrent arteries

Origin:

In and immediately distal to cubital fossa, as 1st and 2nd medial branches of ulnar artery

Course/Distribution:

Course proximally to anastomose with the inferior and superior ulnar collateral arteries, respectively, forming collateral pathways anterior and posterior to the medial epicondyle of the humerus

Common interosseous artery

Origin:

Immediately distal to the cubital fossa, as 1st lateral branch of ulnar artery

Course/Distribution:

Terminates almost immediately, dividing into anterior and posterior interosseous arteries

Anterior and posterior interosseous arteries

Origin:

Distal to radial tubercle, as terminal branches of common interosseous

Course/Distribution:

Pass to opposite sides of interosseous membrane; anterior artery runs on interosseous membrane; posterior artery runs between superficial and deep layers of extensor muscles as primary artery of compartment

Interosseous recurrent artery

Origin:

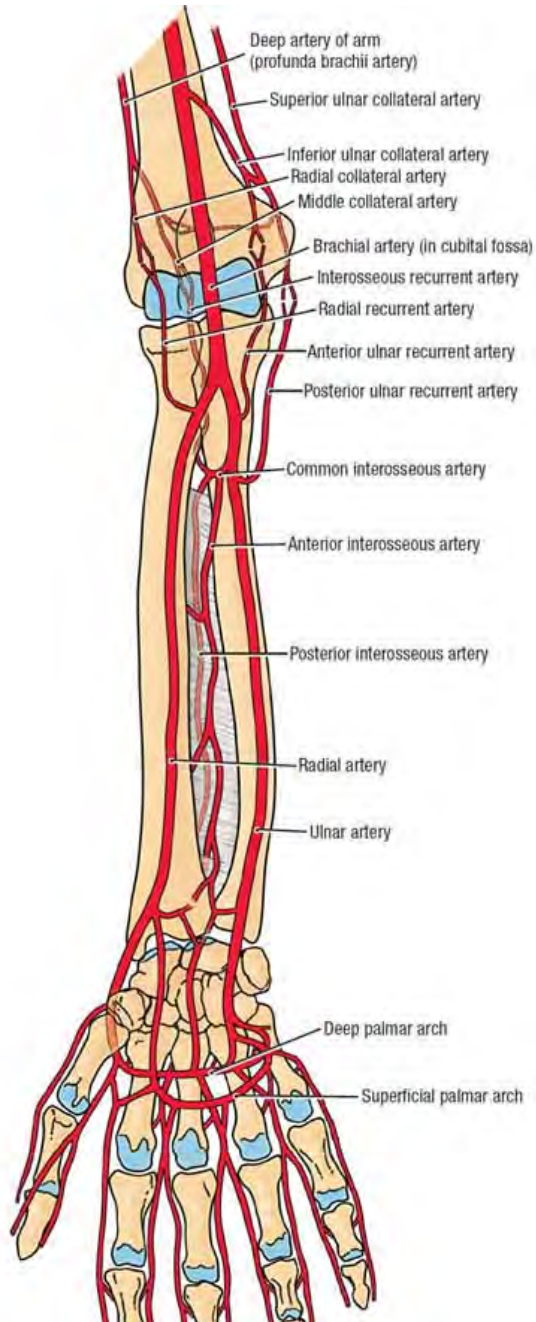
Initial part of posterior interosseous artery

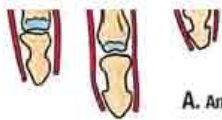
Course/Distribution:

Courses proximally between lateral epicondyle and olecranon, deep to anconeus, to anastomose with middle collateral artery

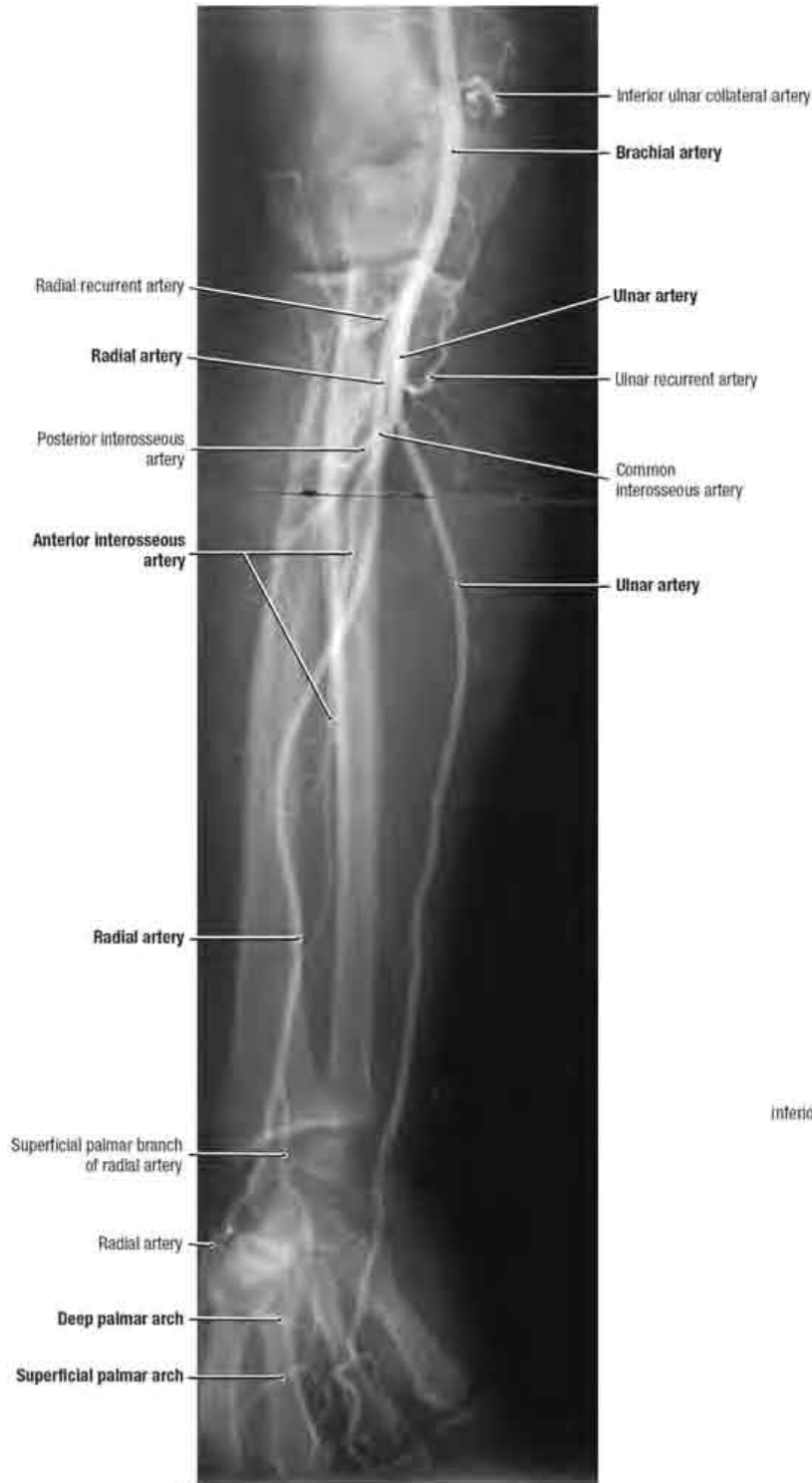
## Table 6.9 Arteries of Forearm

P.551

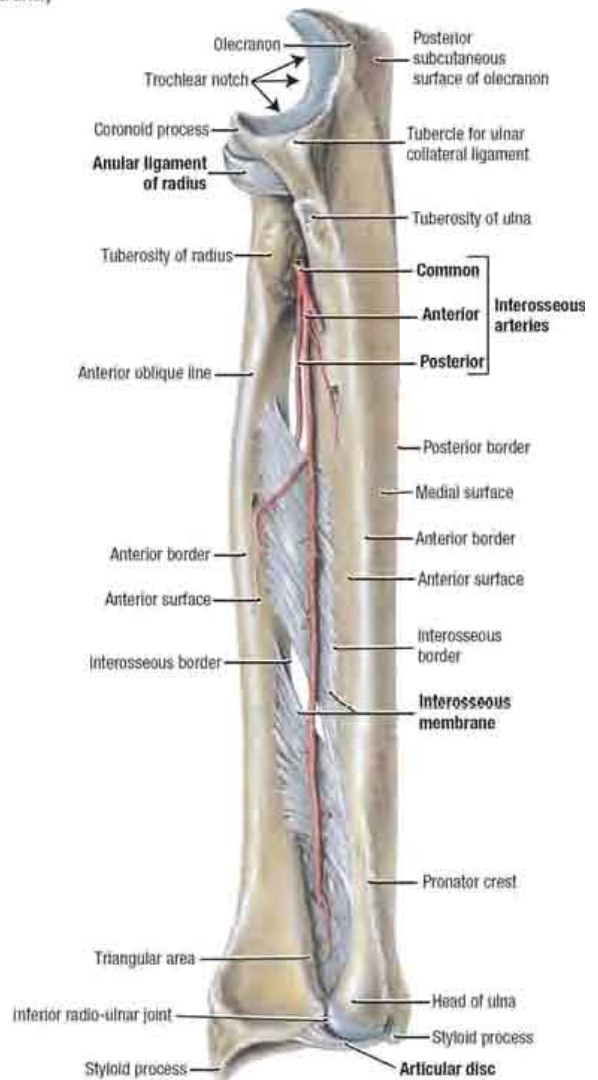




**A. Anterior View**



**B. Anteroposterior View**



**C. Anterior View**





Authors: Agur, Anne M.R.; Dalley, Arthur F.

Title: *Grant's Atlas of Anatomy, 12th Edition*

Copyright ©2009 Lippincott Williams & Wilkins

> Table of Contents > Chapter 6 - Upper Limb > 6.55 Arteries of forearm and ligaments of radioulnar joints

---

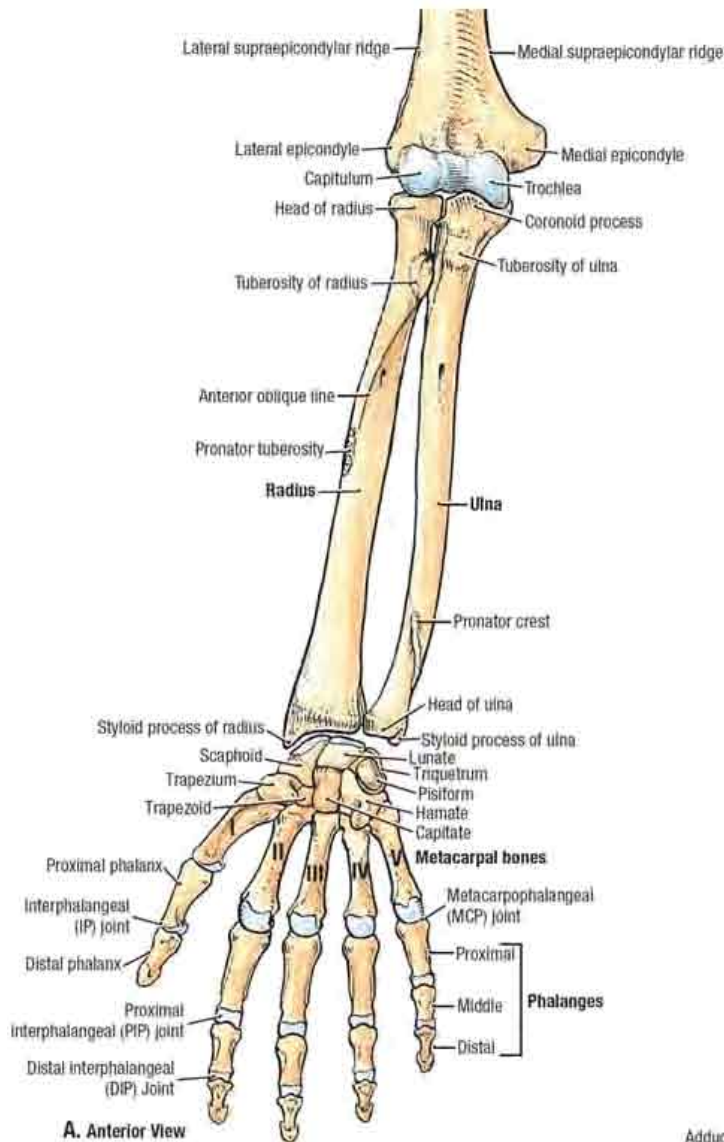
## 6.55 Arteries of forearm and ligaments of radioulnar joints

*Part of* "Chapter 6 - Upper Limb "

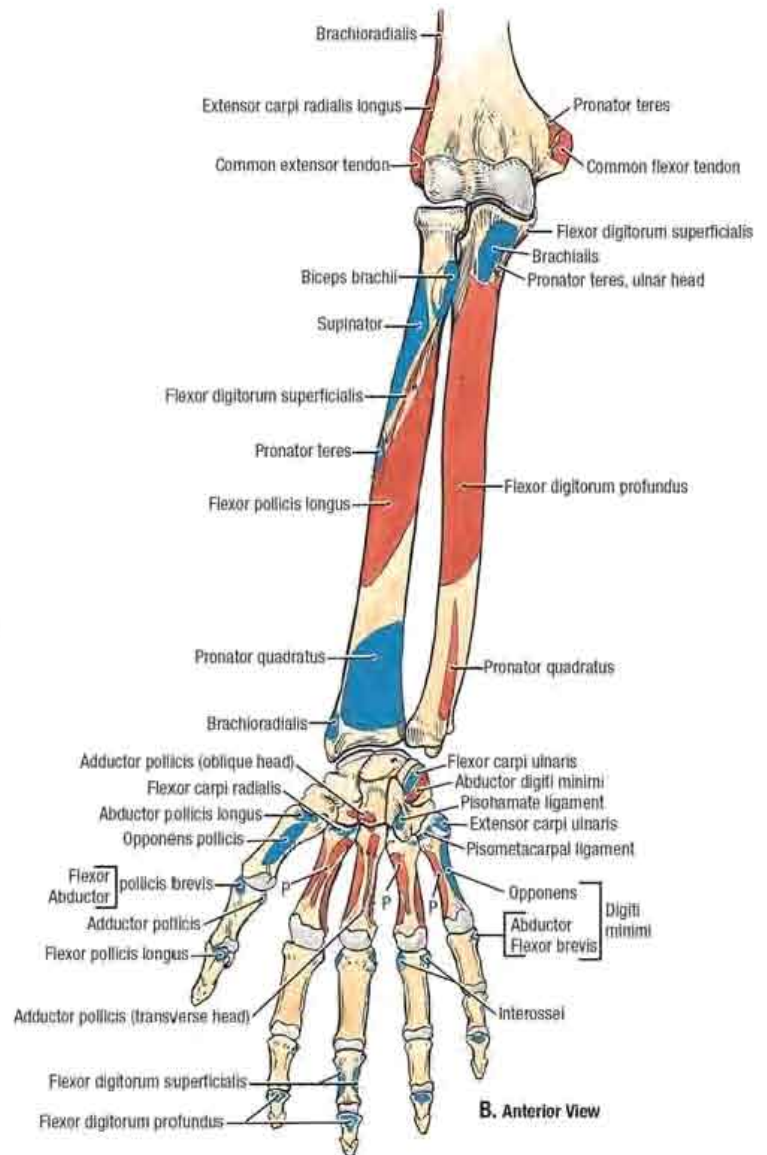
A. Anterior view B. Brachial arteriogram. C. Radio-ulnar ligaments and interosseous arteries. The ligament maintaining the proximal radio-ulnar joint is the anular ligament, that for the distal joint is the articular disc, and that for the middle joint is the interosseous membrane. The interosseous membrane is attached to the interosseous borders of the radius and ulna, but it also spreads onto their surfaces.

---

P.552



**A. Anterior View**



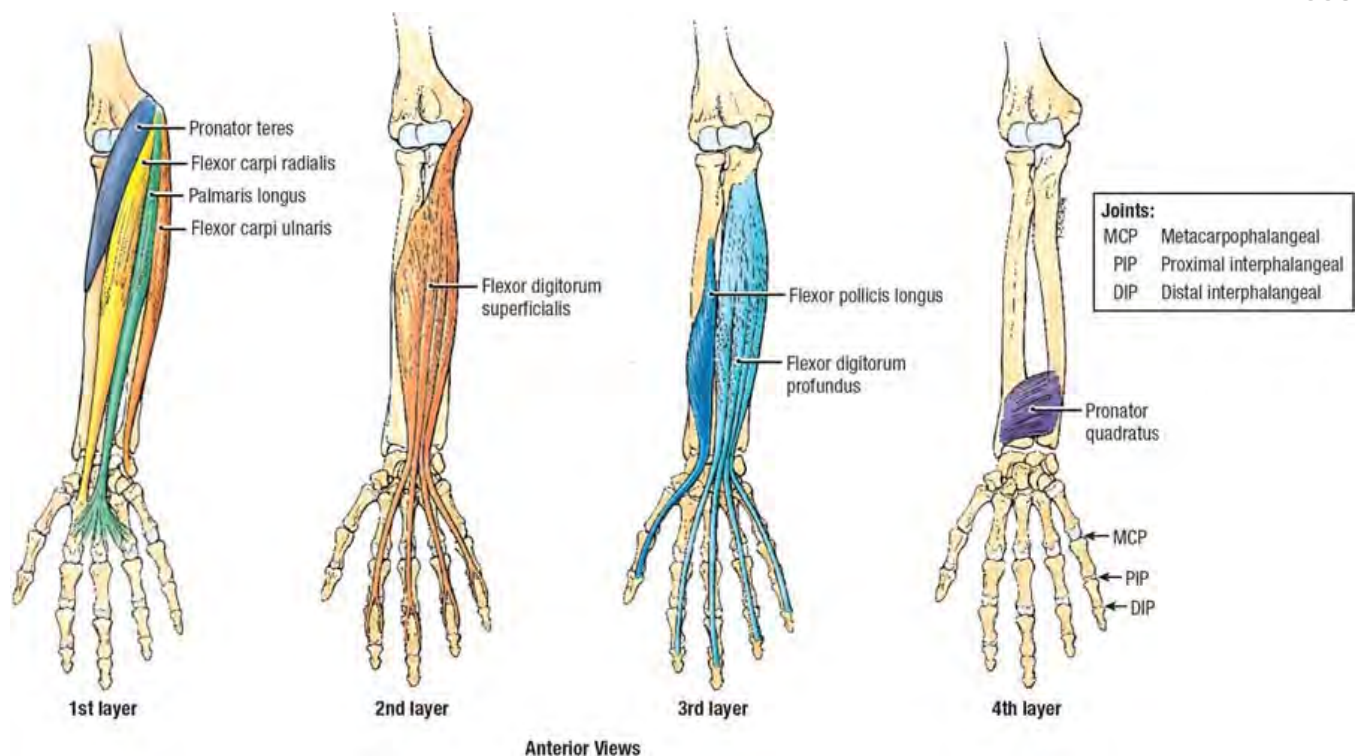
**B. Anterior View**

## 6.56 Bones and muscle attachments of forearm and hand

Part of "Chapter 6 - Upper Limb "

A. Bony features. B. Sites of muscle attachments. The proximal attachments of the three palmar interossei are indicated by the letter *P*; those of the four dorsal interossei are indicated by color only.

P.553



Pronator teres

Medial epicondyle of humerus and coronoid process of ulna

Middle of lateral surface of radius (pronator tuberosity)

Median nerve (C6–C7)

Pronates forearm and flexes elbow

Flexor carpi radialis

Medial epicondyle of humerus

Base of 2nd metacarpal

Flexes wrist and abducts hand

Palmaris longus

Distal half of flexor retinaculum and palmar aponeurosis

Median nerve (C7–C8)

Flexes wrist and tightens palmar aponeurosis

Flexor carpi ulnaris

*Humeral head:* medial epicondyle of humerus; *Ulnar head:* olecranon and posterior border of ulna

Pisiform, hook of hamate, and 5th metacarpal

Ulnar nerve (C7–C8)

Flexes wrist and adducts hand

Flexor digitorum superficialis

*Humero-ulnar head:* medial epicondyle of humerus, ulnar collateral ligament, and coronoid process of ulna *Radial head:* superior half of anterior border of radius

Bodies of middle phalanges of medial four digits

Median nerve (C7, C8, and T1)

Flexes PIPs of medial four digits; acting more strongly, it flexes MCPs and hand

Flexor digitorum profundus

Proximal three quarters of medial and anterior surfaces of ulna and interosseous membrane

Bases of distal phalanges of medial four digits

*Medial part:* ulnar nerve (C8–T1)

*Lateral part:* median nerve (C8–T1)

Flexes DIPs of medial four digits; assists with flexion of wrist

Flexor pollicis longus

Anterior surface of radius and adjacent interosseous membrane

Base of distal phalanx of thumb

Anterior interosseous nerve from median (C8 & T1)

Flexes phalanges of 1st digit (thumb)

Pronator quadratus

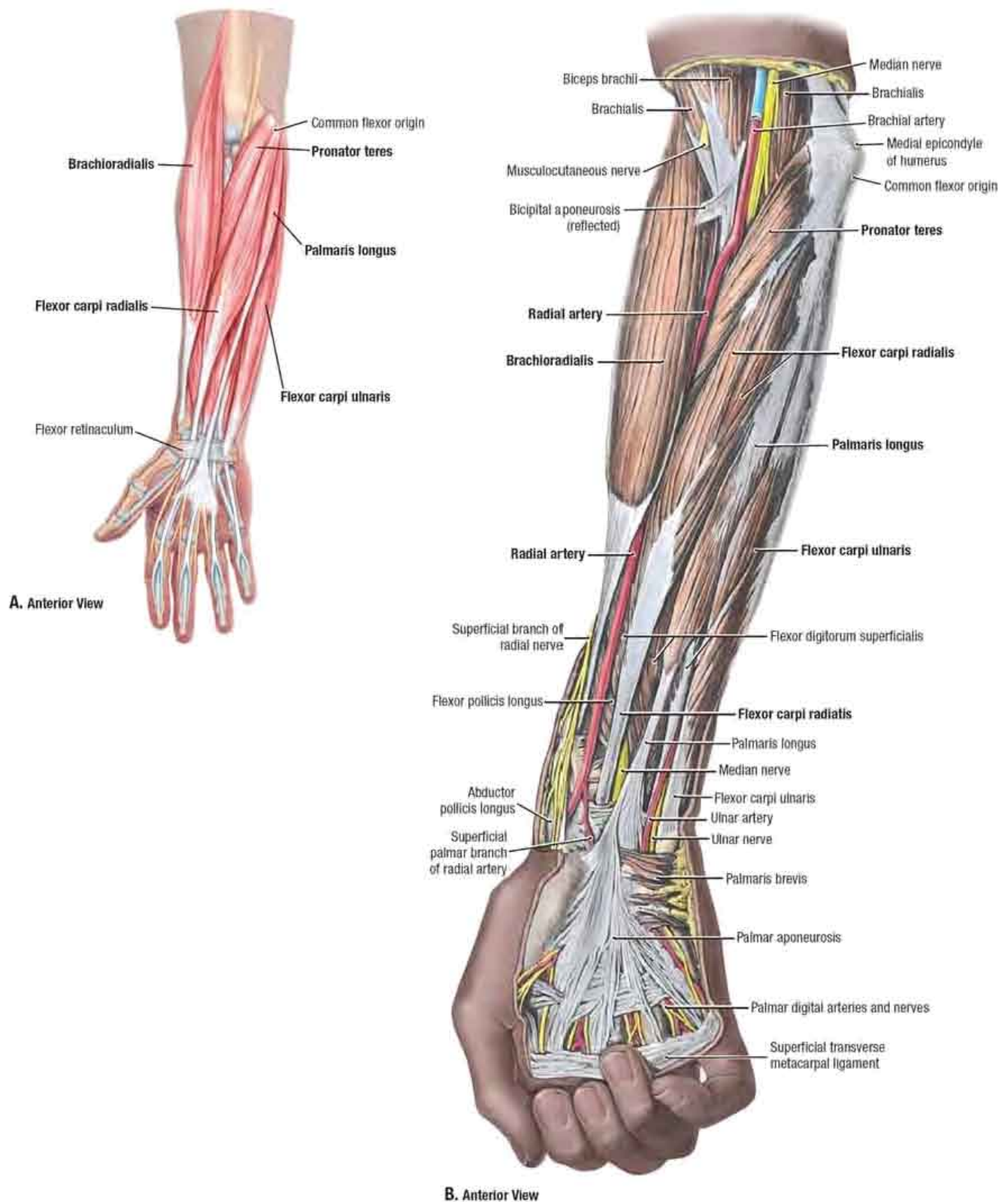
Distal fourth of anterior surface of ulna

Distal fourth of anterior surface of radius

Pronates forearm; deep fibers bind radius and ulna together

Muscle	Proximal Attachment	Distal Attachment	Innervation	Main Actions
--------	---------------------	-------------------	-------------	--------------

Table 6.10 Muscles of Anterior Surface of Forearm
---





Authors: Agur, Anne M.R.; Dalley, Arthur F.

Title: *Grant's Atlas of Anatomy, 12th Edition*

Copyright ©2009 Lippincott Williams & Wilkins

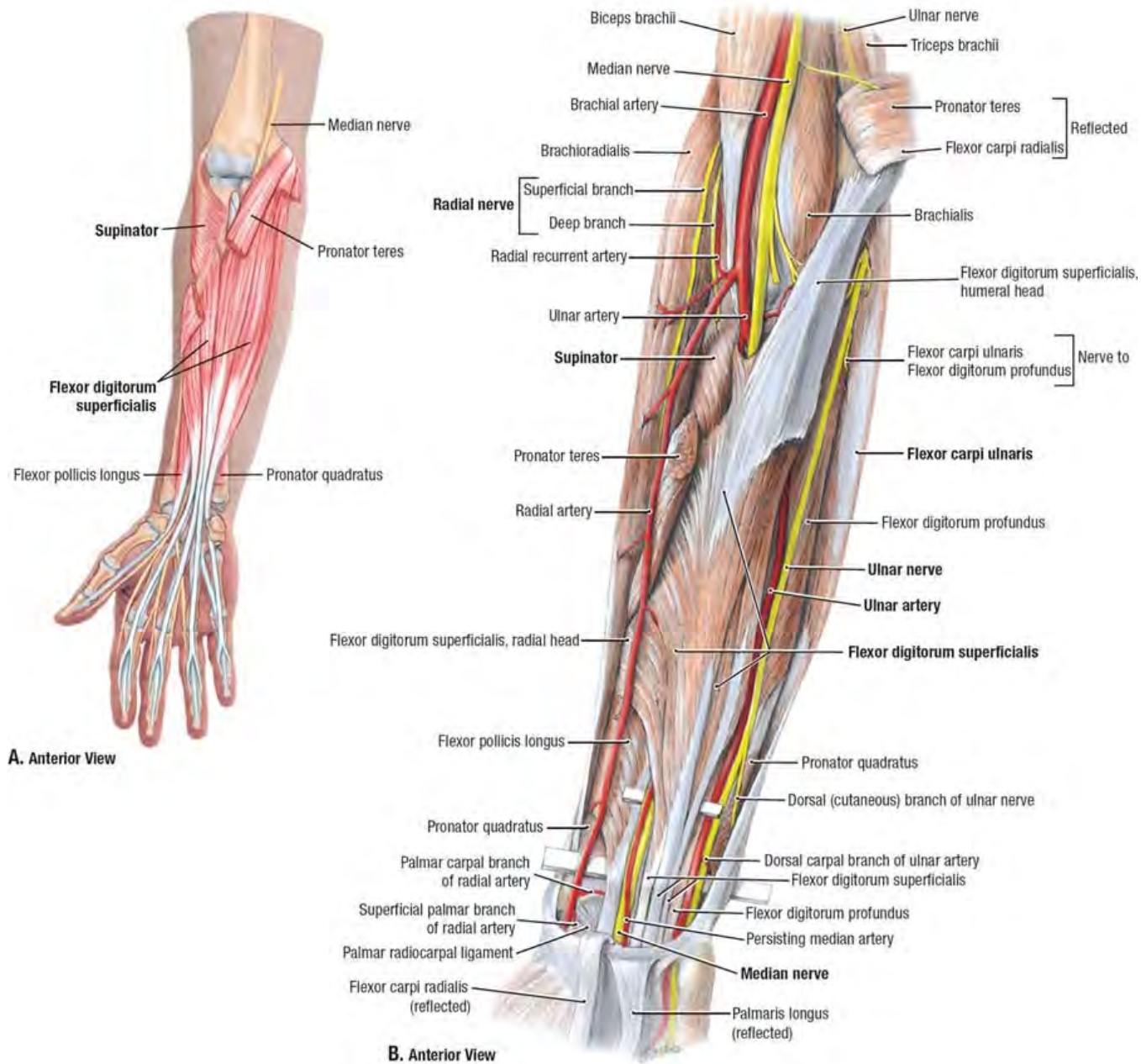
> Table of Contents > Chapter 6 - Upper Limb > 6.57 Superficial muscles of the forearm and palmar aponeurosis

---

## 6.57 Superficial muscles of the forearm and palmar aponeurosis

*Part of "Chapter 6 - Upper Limb "*

- At the elbow, the brachial artery lies between the biceps tendon and median nerve. It then bifurcates into the radial and ulnar arteries.
  - At the wrist, the radial artery is lateral to the flexor carpi radialis tendon, and the ulnar artery is lateral to flexor carpi ulnaris tendon.
  - In the forearm, the radial artery lies between the flexor and extensor compartments. The muscles lateral to the artery are supplied by the radial nerve, and those medial to it by the median and ulnar nerves; thus, no motor nerve crosses the radial artery.
  - The brachioradialis muscle slightly overlaps the radial artery, which is otherwise superficial.
  - The four superficial muscles (pronator teres, flexor carpi radialis, palmaris longus, and flexor carpi ulnaris) all attach proximally to the medial epicondyle of the humerus (common flexor origin).
  - The palmaris longus muscle, in this specimen, has an anomalous distal belly; this muscle usually has a small belly at the common flexor origin and a long tendon that is continued into the palm as the palmar aponeurosis. The palmaris longus is absent in approximately 14% of limbs.
-



Authors: Agur, Anne M.R.; Dalley, Arthur F.

Title: *Grant's Atlas of Anatomy, 12th Edition*

Copyright ©2009 Lippincott Williams & Wilkins

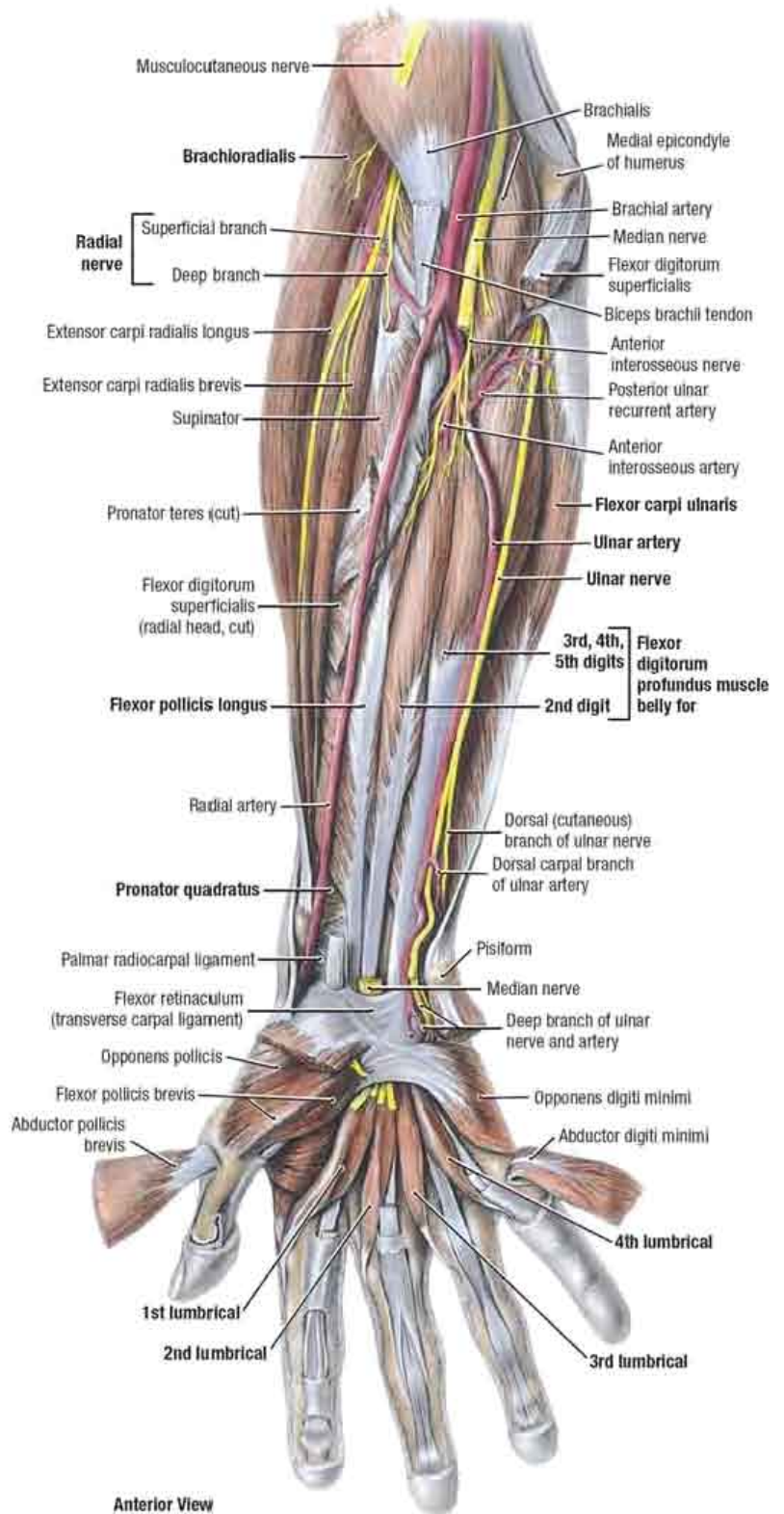
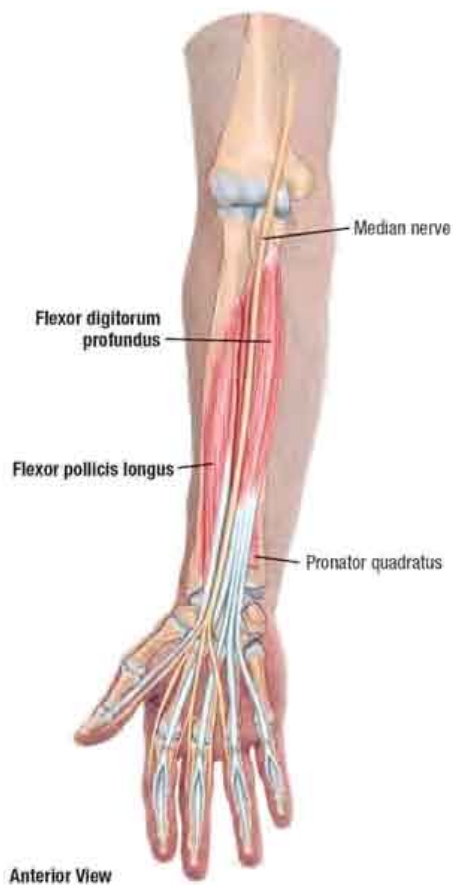
> Table of Contents > Chapter 6 - Upper Limb > 6.58 Flexor digitorum superficialis and related structures

---

## 6.58 Flexor digitorum superficialis and related structures

*Part of "Chapter 6 - Upper Limb "*

- The flexor digitorum superficialis muscle is attached proximally to the humerus, ulna, and radius.
- The ulnar artery passes obliquely posterior to the flexor digitorum superficialis; at the medial border of the muscle, the ulnar artery joins the ulnar nerve.
- The ulnar nerve lies between the flexor digitorum profundus and flexor carpi ulnaris.
- The median nerve descends vertically posterior to the flexor digitorum superficialis and appears distally at its lateral border.
- The median artery of this specimen is a variation resulting from persistence of an embryologic vessel that usually disappears.



Authors: Agur, Anne M.R.; Dalley, Arthur F.

Title: *Grant's Atlas of Anatomy, 12th Edition*

Copyright ©2009 Lippincott Williams & Wilkins

> Table of Contents > Chapter 6 - Upper Limb > 6.59 Deep flexors of the digits and related structures

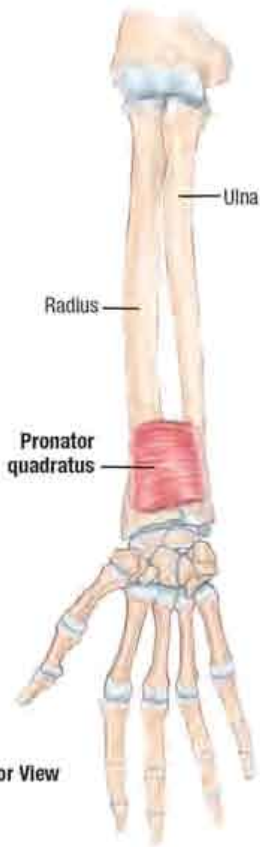---

## 6.59 Deep flexors of the digits and related structures

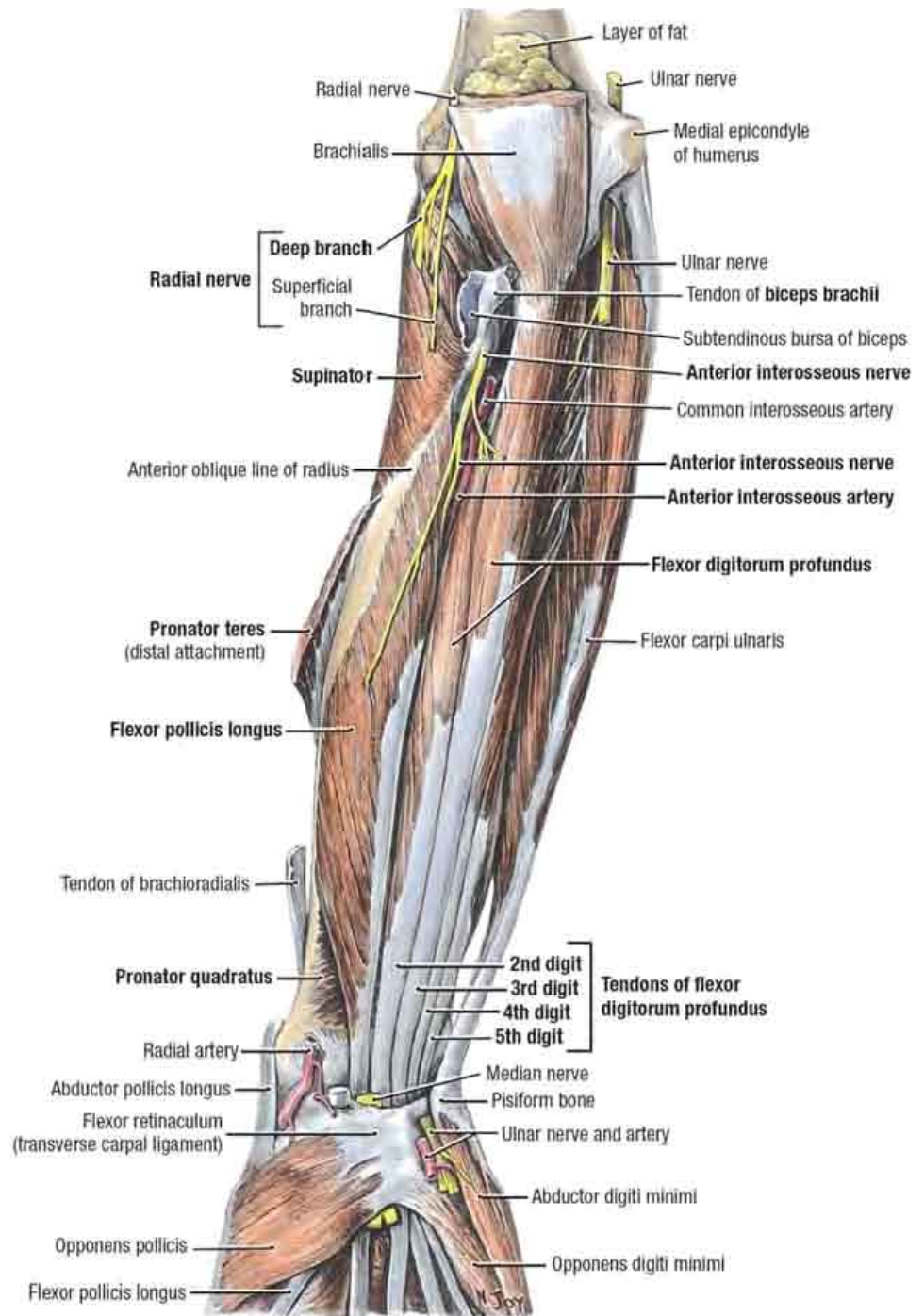
*Part of* "Chapter 6 - Upper Limb "

- The two deep digital flexor muscles, flexor pollicis longus and flexor digitorum profundus, arise from the flexor aspects of the radius, interosseous membrane, and ulna between the origin of flexor digitorum superficialis proximally and pronator quadratus distally.
- The ulnar nerve enters the forearm posterior to the medial epicondyle, then descends between the flexor digitorum profundus and flexor carpi ulnaris and is joined by the ulnar artery. At the wrist the ulnar nerve and artery pass anterior to the flexor retinaculum and lateral to the pisiform to enter the palm.
- At the elbow, the ulnar nerve supplies the flexor carpi ulnaris and the medial half of the flexor digitorum profundus muscles; superior to the wrist, it gives off the dorsal (cutaneous) branch.
- The four lumbricals arise from the flexor digitorum profundus tendons.





Anterior View



Anterior View



Authors: Agur, Anne M.R.; Dalley, Arthur F.

Title: *Grant's Atlas of Anatomy, 12th Edition*

Copyright ©2009 Lippincott Williams & Wilkins

> Table of Contents > Chapter 6 - Upper Limb > 6.60 Deep flexors of the digits and supinator

---

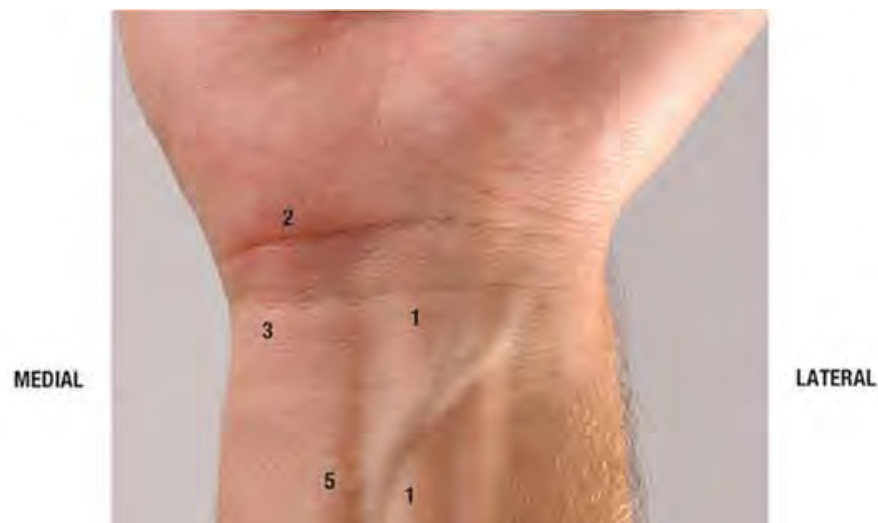## 6.60 Deep flexors of the digits and supinator

*Part of "Chapter 6 - Upper Limb "*

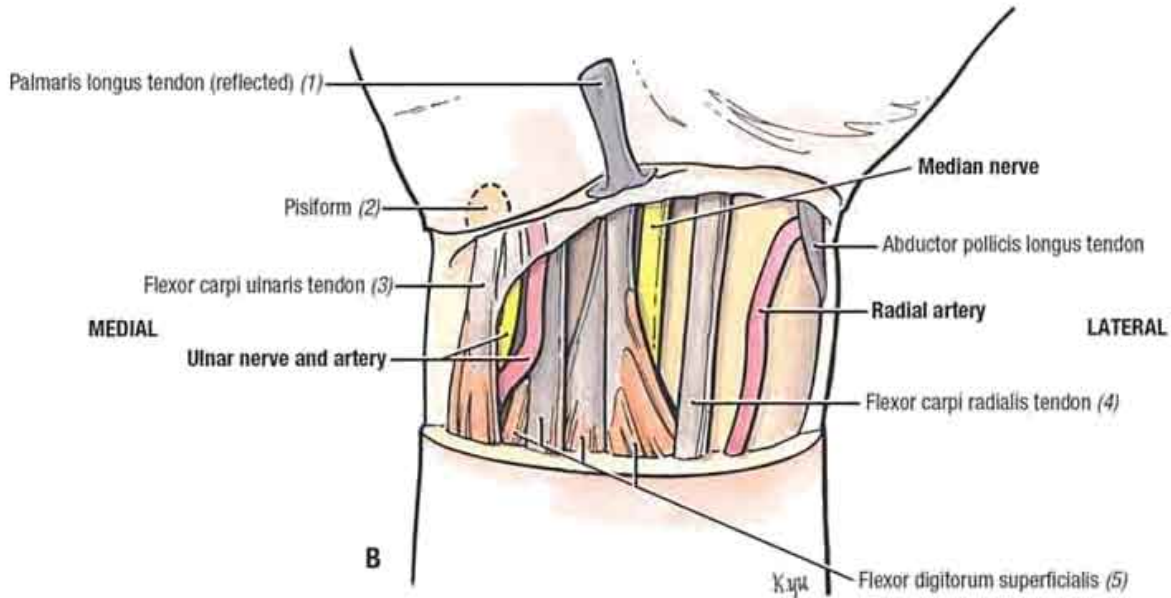
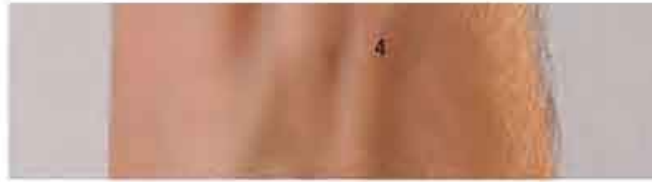- The five tendons of the deep digital flexors (flexor pollicis longus and flexor digitorum profundus) lie side by side as they enter the carpal tunnel.
- The biceps brachii muscle attaches to the medial aspect of the radius; hence, it can supinate the forearm, whereas the pronator teres muscle, by attaching to the lateral surface, can pronate the forearm.
- The deep branch of the radial nerve pierces and innervates the supinator muscle.
- The anterior interosseous nerve and artery disappear between the flexor pollicis longus and flexor digitorum profundus muscles to lie on the interosseous membrane.

---

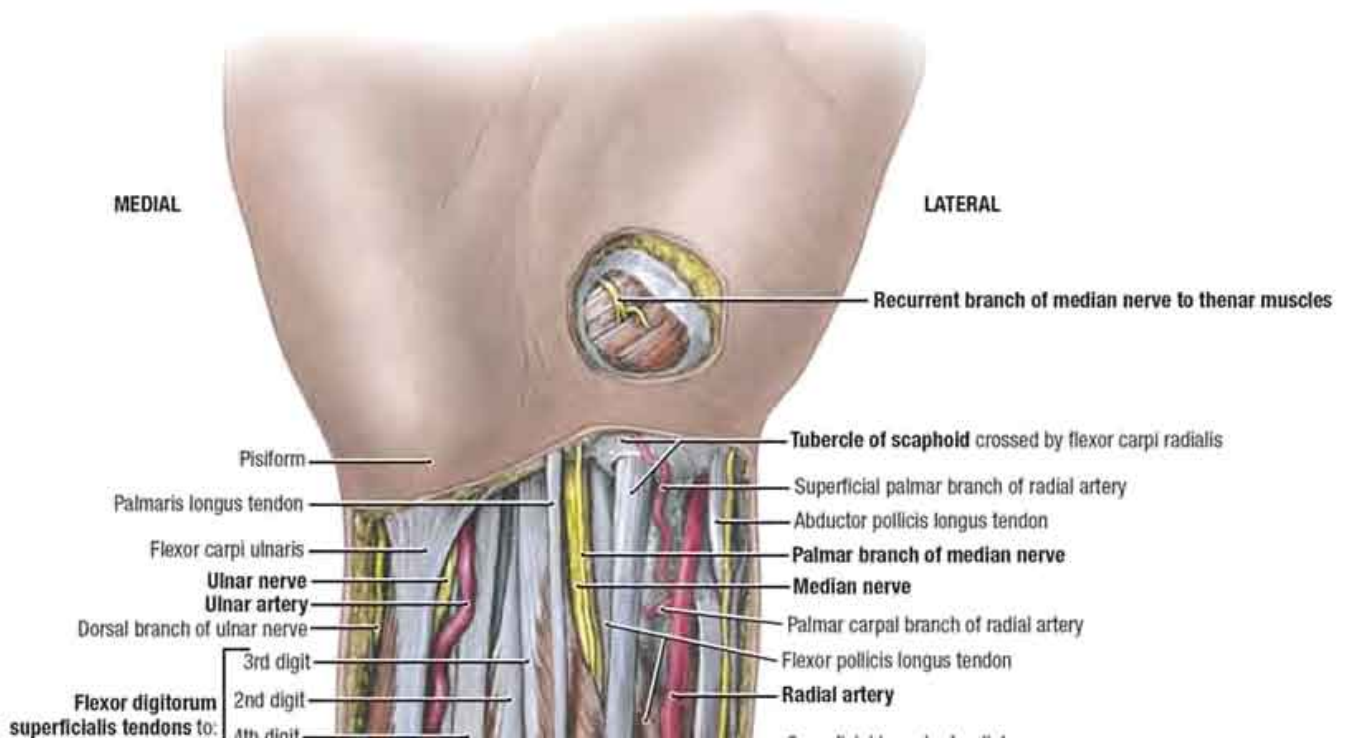
P.558



A



Anterior Views of Right Hand and Wrist





Authors: Agur, Anne M.R.; Dalley, Arthur F.

Title: *Grant's Atlas of Anatomy, 12th Edition*

Copyright ©2009 Lippincott Williams & Wilkins

> Table of Contents > Chapter 6 - Upper Limb > 6.61 Structures of anterior aspect of wrist

---

## 6.61 Structures of anterior aspect of wrist

*Part of* "Chapter 6 - Upper Limb "

A. Surface anatomy. B. Schematic illustration. C. Dissection.

- The distal skin incision follows the transverse skin crease at the wrist. The incision crosses the pisiform, to which the flexor carpi ulnaris muscle attaches, and the tubercle of the scaphoid, to which the tendon of flexor carpi radialis muscle is a guide.
- The palmaris longus tendon bisects the transverse skin crease; deep to its lateral margin is the median nerve.
- The radial artery passes deep to the tendon of the abductor pollicis longus muscle.
- The flexor digitorum superficialis tendons to the 3rd and 4th digits become anterior to those of the 2nd and 5th digits.
- The recurrent branch of the median nerve to the thenar muscles lies within a circle whose center is 2.5 to 4 cm distal to the tubercle of the scaphoid.

---

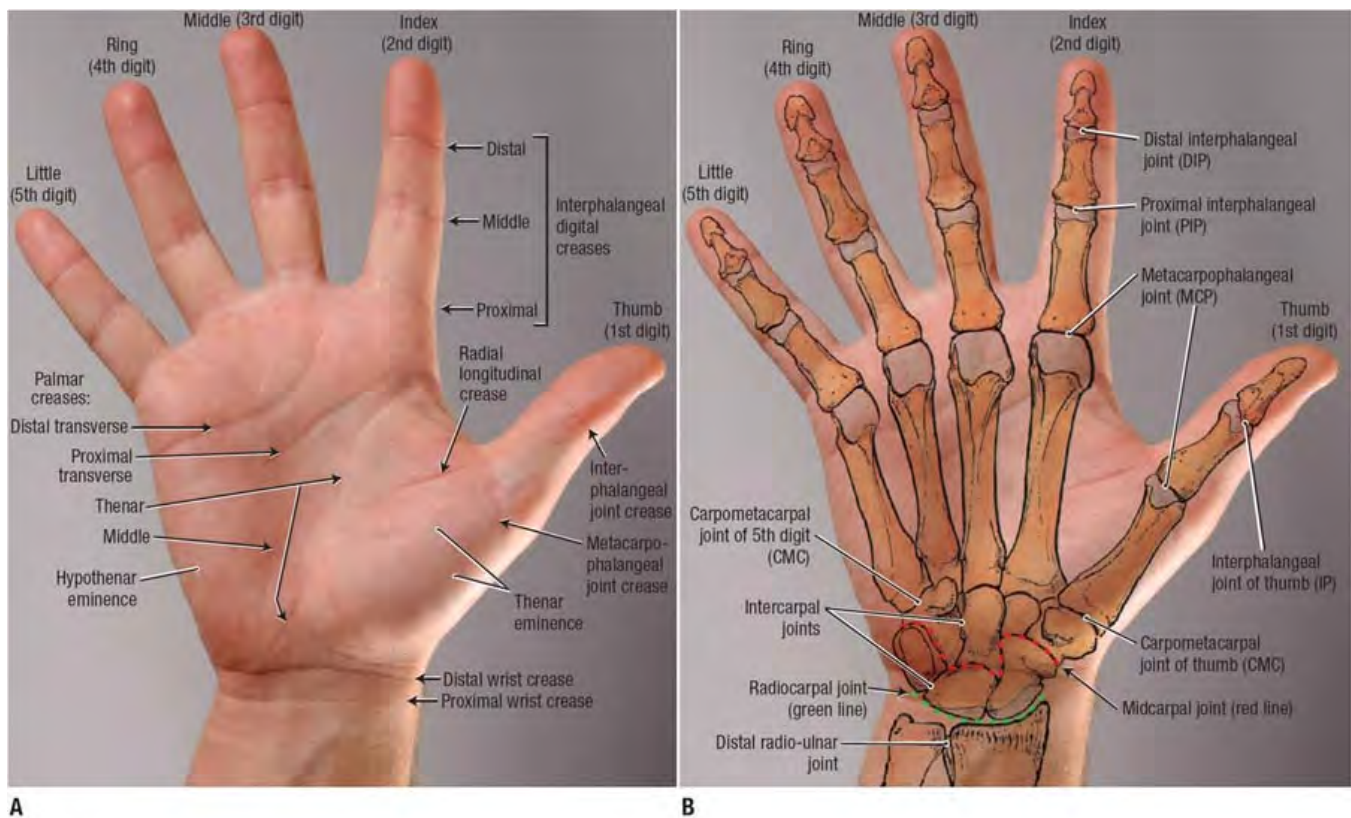
P.559

Lesions of the median nerve usually occur in two places: the forearm and wrist. The most common site is where the nerve passes through the carpal tunnel. Lacerations of the wrist often cause median nerve injury because this nerve is relatively close to the surface. This results in paralysis of the

thenar muscles and the first two lumbricals. Hence opposition of the thumb is not possible and fine control movements of the 2nd and 3rd digits are impaired. Sensation is also lost over the thumb and adjacent two and a half fingers.

Median nerve injury resulting from a perforating wound in the elbow region results in loss of flexion of the proximal and distal interphalangeal joints of the 2nd and 3rd digits. The ability to flex the metacarpophalangeal joints of these digits is also affected because digital branches of the median nerve supply the 1st and 2nd lumbricals. The palmar cutaneous branch of the median nerve does not traverse the carpal tunnel. It supplies the skin of the central palm, which remains sensitive in carpal tunnel syndrome.

P.560



A

B

Anterior Views

Authors: Agur, Anne M.R.; Dalley, Arthur F.

Title: *Grant's Atlas of Anatomy, 12th Edition*

Copyright ©2009 Lippincott Williams & Wilkins

> Table of Contents > Chapter 6 - Upper Limb > 6.62 Surface anatomy of skeleton of hand and wrist

---

## 6.62 Surface anatomy of skeleton of hand and wrist

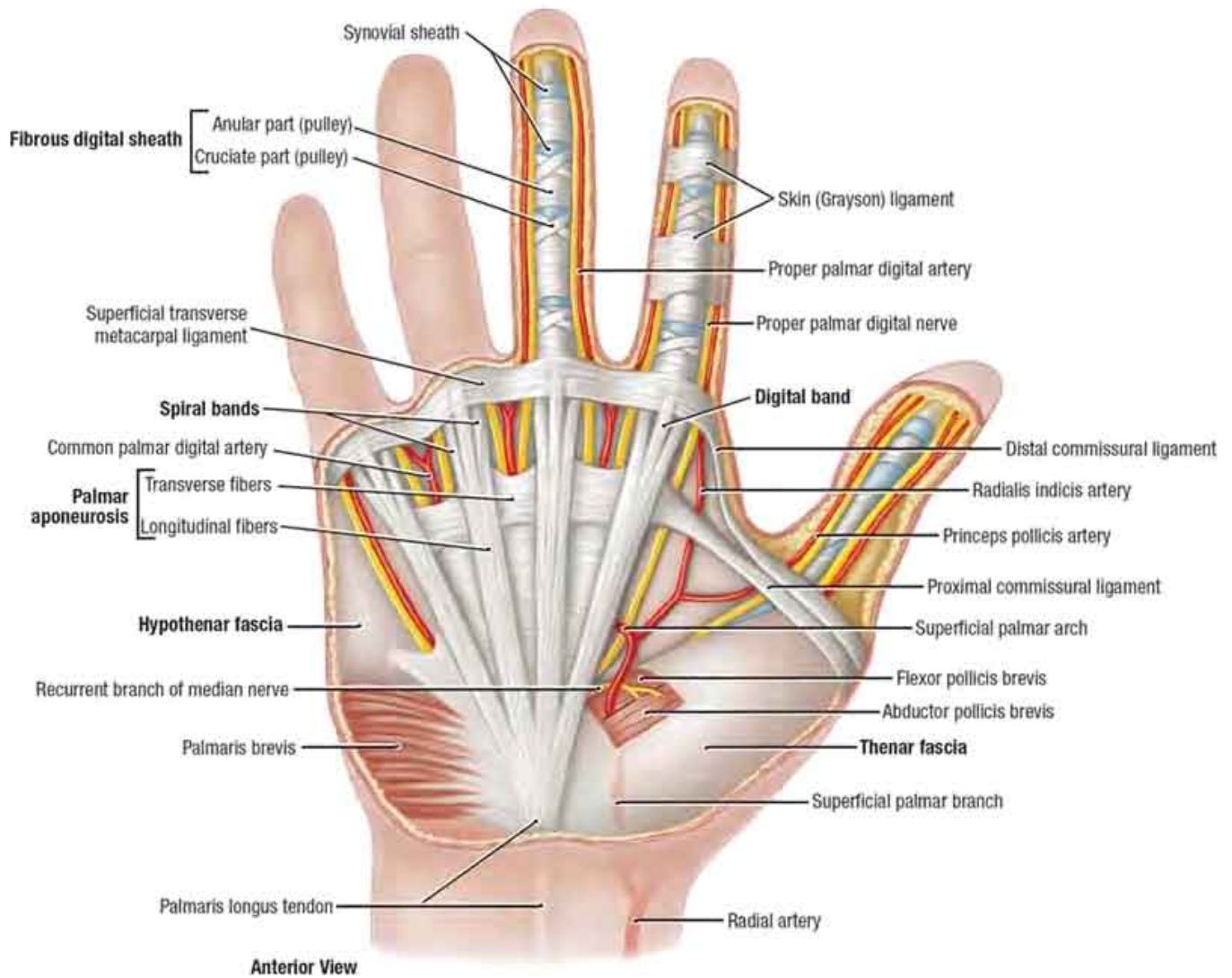
*Part of* "Chapter 6 - Upper Limb "

A. Skin creases of wrist and hand. B. Surface projection of joints of wrist and hand. Note relationship of bones and joints to features of the hand.

---

P.561





Authors: Agur, Anne M.R.; Dalley, Arthur F.

Title: *Grant's Atlas of Anatomy, 12th Edition*

Copyright ©2009 Lippincott Williams & Wilkins

> Table of Contents > Chapter 6 - Upper Limb > 6.63 Palmar (deep) fascia: palmar aponeurosis, thenar and hypothenar fascia

---

## 6.63 Palmar (deep) fascia: palmar aponeurosis, thenar and hypothenar fascia

*Part of* "Chapter 6 - Upper Limb"

- The palmar fascia is thin over the thenar and hypothenar eminences, but thick centrally, where it forms the palmar aponeurosis, and in the digits, where it forms the fibrous digital sheaths.
  - At the distal end (base) of the palmar aponeurosis, four bundles of digital and spiral bands continue to the bases and fibrous digital sheaths of digits 2–5.
- Dupuytren contracture is a disease of the palmar fascia resulting in progressive shortening, thickening, and fibrosis of the palmar fascia and palmar aponeurosis. The fibrous degeneration of the longitudinal digital bands of the aponeurosis on the medial side of the hand pulls the 4th and 5th fingers into partial flexion at the metacarpophalangeal and proximal interphalangeal joints. The contracture is frequently bilateral. Treatment of Dupuytren contracture usually involves surgical excision of all fibrotic parts of the palmar fascia to free the fingers.



Dupuytren contracture

P.562



Authors: Agur, Anne M.R.; Dalley, Arthur F.

Title: *Grant's Atlas of Anatomy, 12th Edition*

Copyright ©2009 Lippincott Williams & Wilkins

> Table of Contents > Chapter 6 - Upper Limb > 6.64 Compartments, spaces, and fascia of the palm

---

## 6.64 Compartments, spaces, and fascia of the palm

*Part of* "Chapter 6 - Upper Limb "

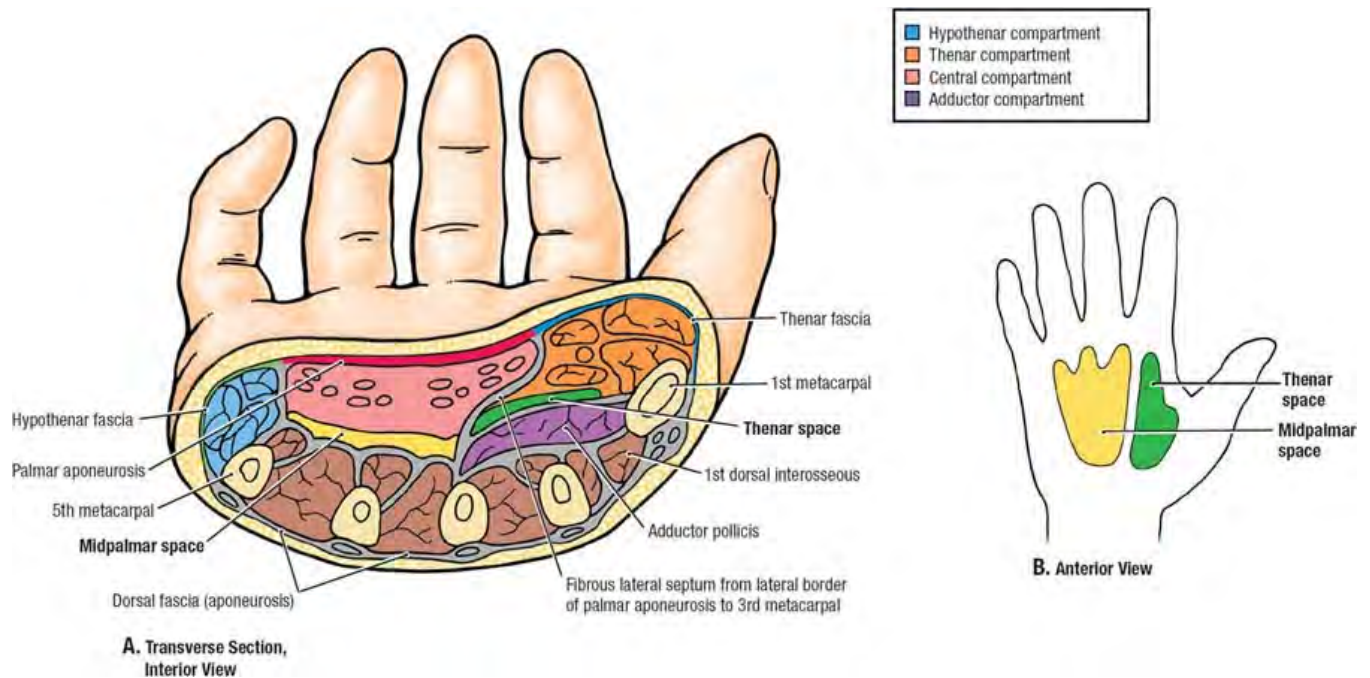
A. Transverse section through the middle of the palm showing the fascial compartments for the musculotendinous structures of the hand. B. Potential fascial spaces of palm.

- The potential midpalmar space lies posterior to the central compartment, is bounded medially by the hypothenar compartment, and is related distally to the synovial sheath of the 3rd, 4th, and 5th digits.
- The potential thenar space lies posterior to the thenar compartment and is related distally to the synovial sheath of the index finger.
- The potential midpalmar and thenar spaces are separated by a septum that passes from the palmar aponeurosis to the third metacarpal.

Because the palmar fascia is thick and strong, swellings resulting from hand infections usually appear on the dorsum of the hand where the fascia is thinner. The potential fascial spaces of the palm are important because they may become infected. The fascial spaces determine the extent and direction of the spread of pus formed in the infected areas. Depending on the site of infection, pus will accumulate in the thenar, hypothenar, or adductor compartments. Antibiotic therapy has made infections that spread

beyond one of these fascial compartments rare, but an untreated infection can spread proximally through the carpal tunnel into the forearm anterior to the pronator quadratus and its fascia.

P.563



Authors: Agur, Anne M.R.; Dalley, Arthur F.

Title: *Grant's Atlas of Anatomy, 12th Edition*

Copyright ©2009 Lippincott Williams & Wilkins

> Table of Contents > Chapter 6 - Upper Limb > 6.65 Attachments of palmar aponeurosis, digital vessels, and nerves

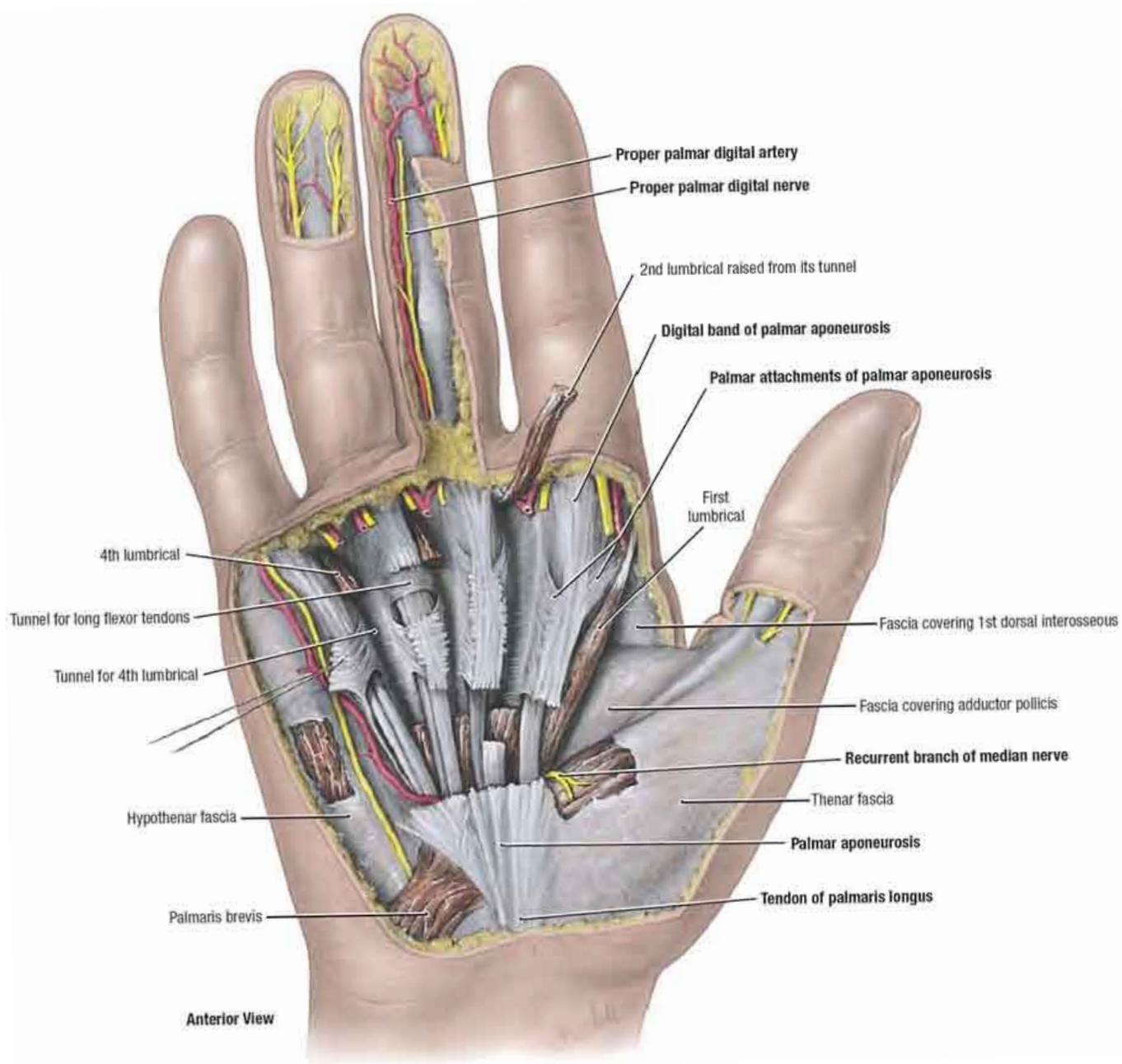
---

## 6.65 Attachments of palmar aponeurosis, digital vessels, and nerves

*Part of "Chapter 6 - Upper Limb "*

- From the palmar aponeurosis, four longitudinal digital bands enter the fingers; the other fibers form extensive fibroareolar septa that pass posteriorly to the palmar ligaments (see Fig. 6.71 ) and, more proximally, to the fascia covering the interossei. Thus, two sets of tunnels exist in the distal half of the palm: (1) tunnels for long flexor tendons and (2) tunnels for lumbricals, digital vessels, and digital nerves.
- In the dissected middle finger, note the absence of fat deep to the skin creases of the fingers.





Authors: Agur, Anne M.R.; Dalley, Arthur F.

Title: *Grant's Atlas of Anatomy, 12th Edition*

Copyright ©2009 Lippincott Williams & Wilkins

> Table of Contents > Chapter 6 - Upper Limb > 6.66 Muscular layers of palm

---

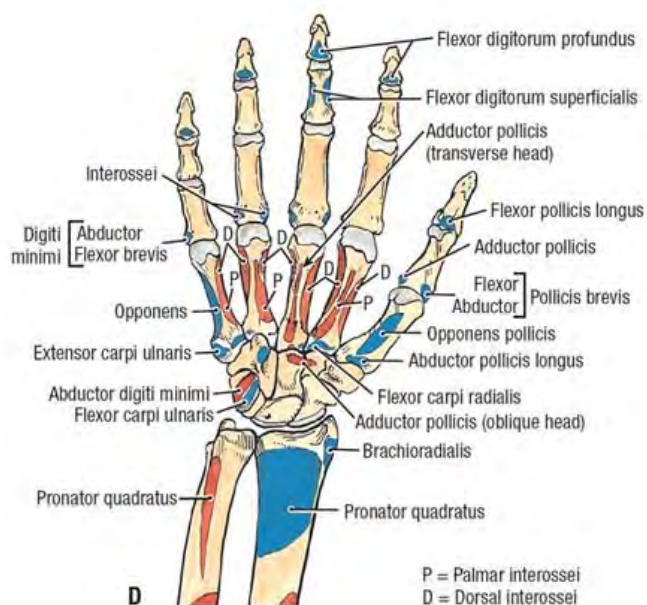
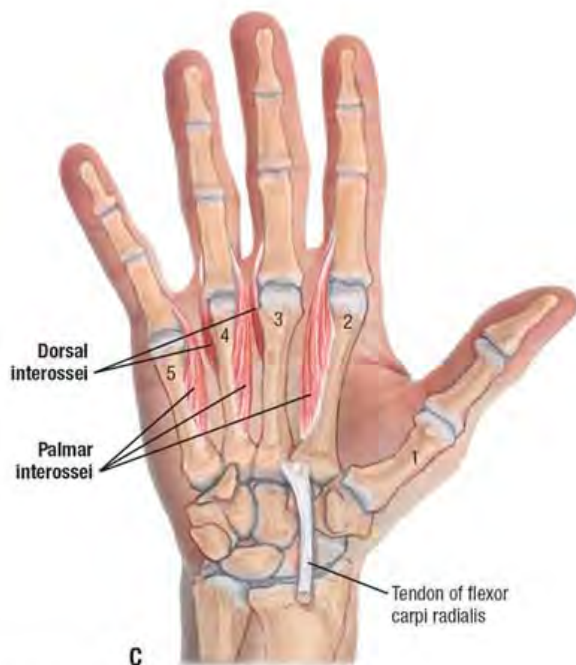
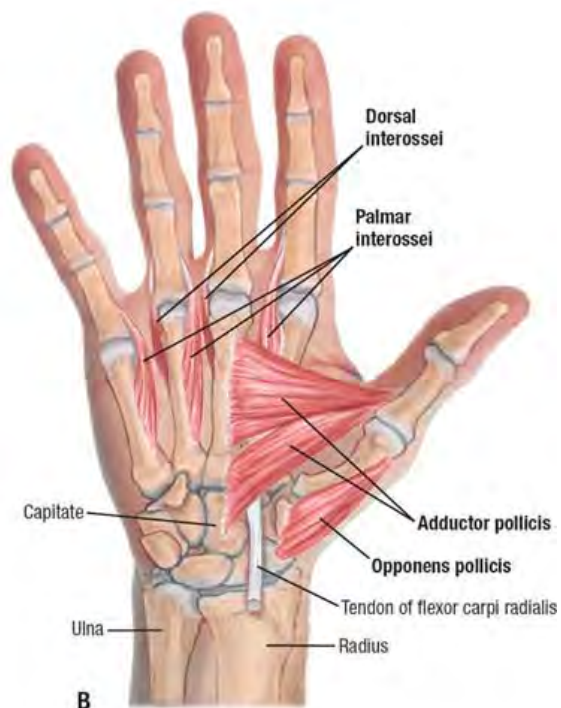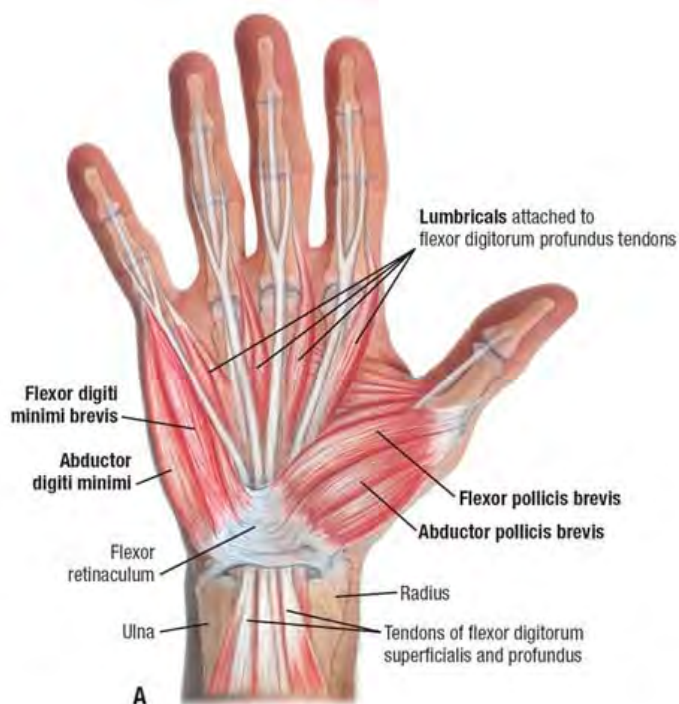## 6.66 Muscular layers of palm

*Part of* "Chapter 6 - Upper Limb "

A. Lumbricals. B. Adductor pollicis. C. Dorsal and palmar interossei. D. Bony attachments.

---

P.565



Anterior Views

Abductor pollicis brevis

Flexor retinaculum and tubercles of scaphoid and trapezium

Lateral side of base of proximal phalanx of thumb

Recurrent branch of median nerve (C8 and T1)

Abducts thumb and helps oppose it

Flexor pollicis brevis

Flexor retinaculum (transverse carpal ligament) and tubercle of trapezium

Flexes thumb

Opponens pollicis

Lateral side of first metacarpal

Opposes thumb toward center of palm and rotates it medially

Adductor pollicis

*Oblique head:* bases of second and third metacarpals, capitate, and adjacent carpal

bones *Transverse head:* anterior surface of body of third metacarpal

Medial side of base of proximal phalanx of thumb

Deep branch of ulnar nerve (C8 and T1 )

Adducts thumb toward middle digit

Abductor digiti minimi

Pisiform

Medial side of base of proximal phalanx of digit 5

Deep branch of ulnar nerve (C8 and T1)

Abducts digit 5

Flexor digiti minimi brevis

Hook of hamate and flexor retinaculum (transverse carpal ligament)

Medial border of fifth metacarpal

Flexes proximal phalanx of digit 5

Opponens digiti minimi

Draws fifth metacarpal anteriorly and rotates it, bringing digit 5 into opposition with thumb

Lumbricals 1 and 2

Lateral two tendons of flexor digitorum profundus

Lateral sides of extensor expansions of digits 2–5

Median nerve (C8 and T1 )

Flex digits at metacarpophalangeal joints and extend interphalangeal joints

Lumbricals 3 and 4

Medial three tendons of flexor digitorum profundus

Dorsal interossei 1–4

Adjacent sides of two metacarpals

Extensor expansions and bases of proximal phalanges of digits 2–4

Deep branch of ulnar nerve (C8 and T1 )

Abduct digits 2–5 and assist lumbricals

Palmar interossei 1–3

Palmar surfaces of second, fourth, and fifth metacarpals

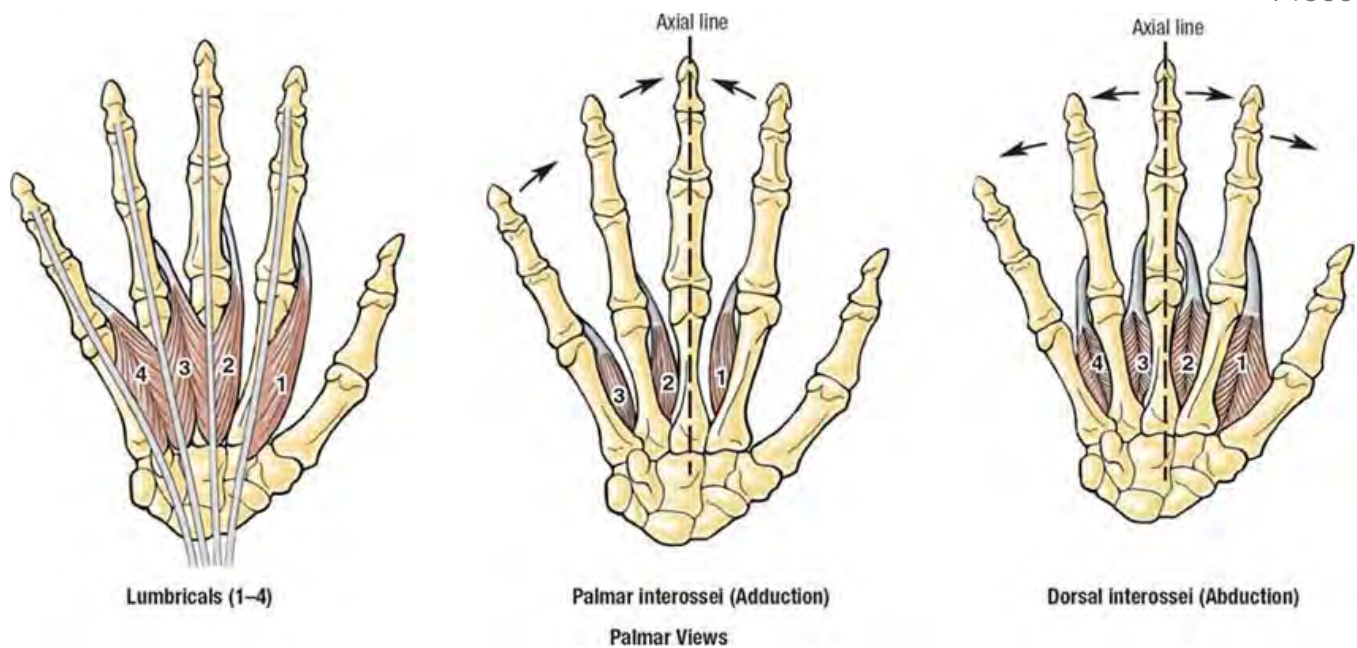
Extensor expansions of digits and bases of proximal phalanges of digits 2, 4, and 5

Adduct digits 2, 4, and 5 and assist lumbricals

Muscle	Proximal Attachment	Distal Attachment	Innervation	Main Actions
--------	---------------------	-------------------	-------------	--------------

Table 6.11 Muscles of Hand

P.566





Authors: Agur, Anne M.R.; Dalley, Arthur F.

Title: *Grant's Atlas of Anatomy, 12th Edition*

Copyright ©2009 Lippincott Williams & Wilkins

> Table of Contents > Chapter 6 - Upper Limb > 6.67 Superficial dissection of palm, ulnar, and median nerves

---

## 6.67 Superficial dissection of palm, ulnar, and median nerves

*Part of* "Chapter 6 - Upper Limb "

### A. Superficial palmar arch and digital nerves and vessels.

- The skin, superficial fascia, palmar aponeurosis, and thenar and hypothenar fasciae have been removed.
- The superficial palmar arch is formed by the ulnar artery and completed by the superficial palmar branch of the radial artery.

Bleeding is usually profuse when the palmar (arterial) arches are lacerated. It may not be sufficient to ligate (tie off) only one forearm artery when the arches are lacerated, because these vessels usually have numerous communications in the forearm and hand and thus bleed from both ends.

---

P.567

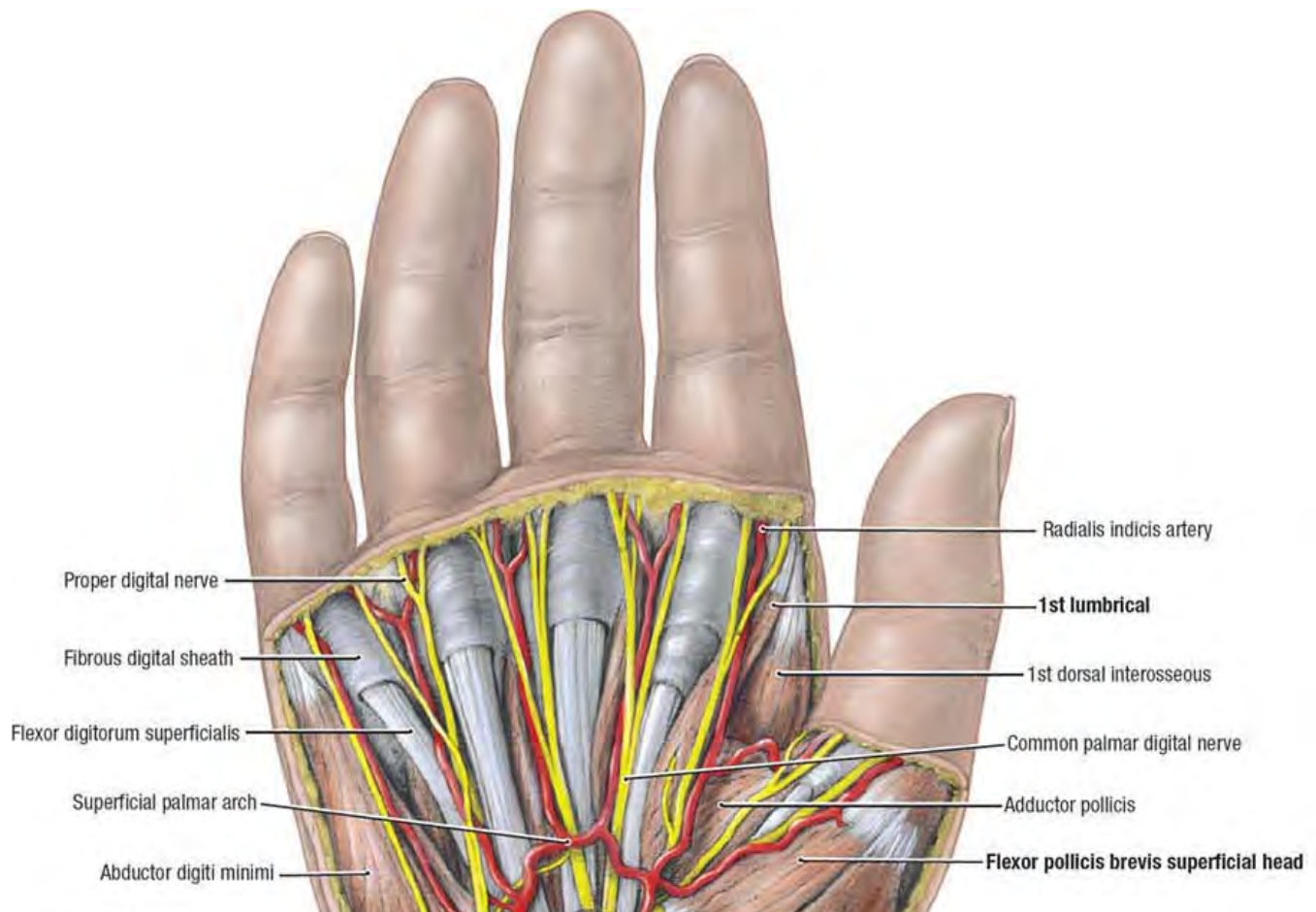
### B. Ulnar and median nerves.

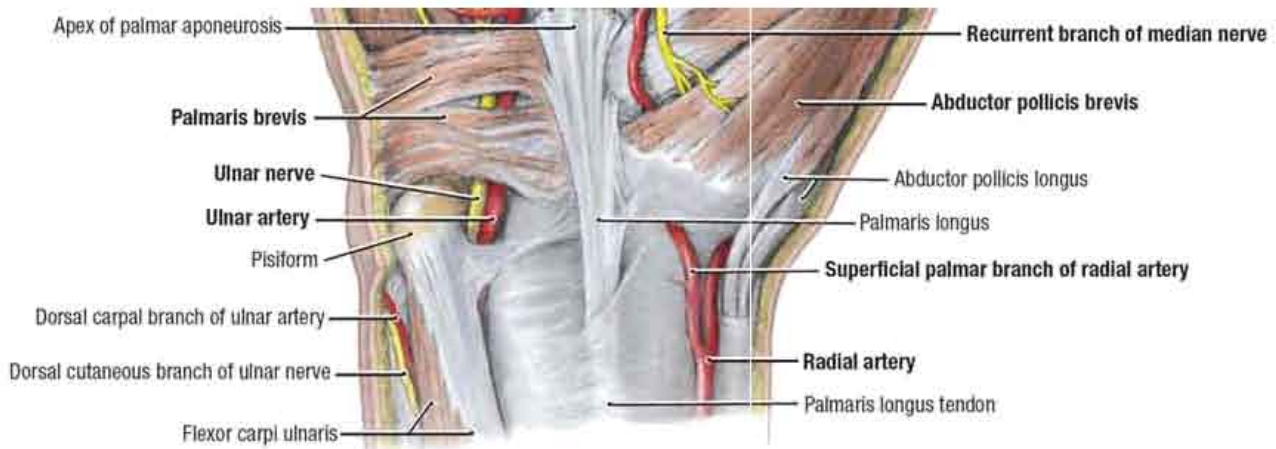
Carpal tunnel syndrome results from any lesion that significantly reduces the size of the carpal tunnel or, more commonly, increases the size of some of the structures (or their coverings) that pass through it (e.g., inflammation of the synovial sheaths). The median nerve is the most sensitive structure



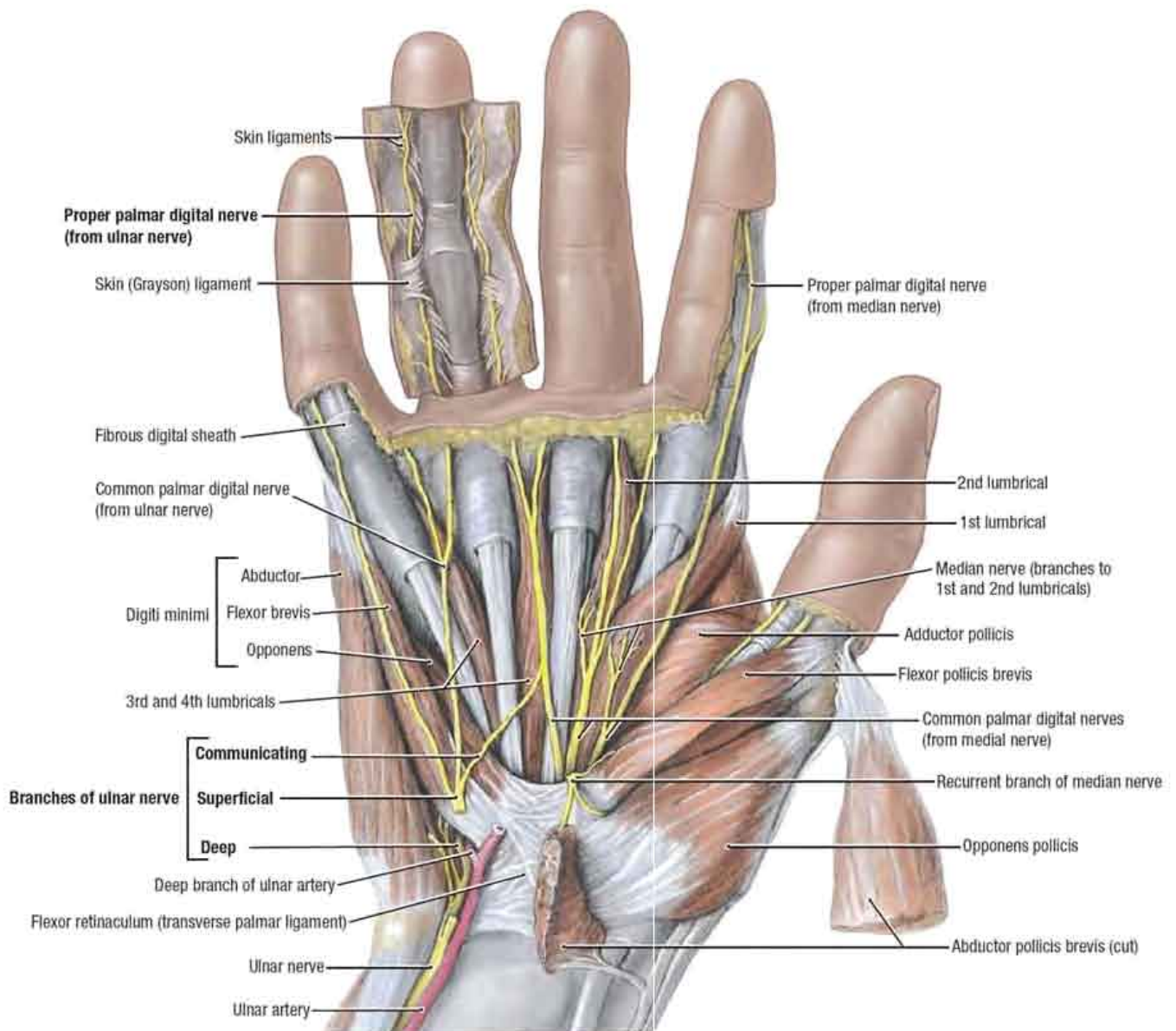
in the carpal tunnel. The median nerve has two terminal sensory branches that supply the skin of the hand; hence paresthesia (tingling), hypoesthesia (diminished sensation), or anesthesia (absence of tactile sensation) may occur in the lateral three and a half digits. Recall, however, that the palmar cutaneous branch of the median nerve arises proximal to and does not pass through the carpal tunnel; thus sensation in the central palm remains unaffected. This nerve also has one terminal motor branch, the recurrent branch, which innervates the three thenar muscles. Wasting of the thenar eminence and progressive loss of coordination and strength in the thumb may occur. To relieve the compression and resulting symptoms, partial or complete surgical division of the flexor retinaculum, a procedure called carpal tunnel release, may be necessary. The incision for carpal tunnel release is made toward the medial side of the wrist and flexor retinaculum to avoid possible injury to the recurrent branch of the median nerve.

P.568





**A. Anterior View**



**B. Anterior View**



Authors: Agur, Anne M.R.; Dalley, Arthur F.

Title: *Grant's Atlas of Anatomy, 12th Edition*

Copyright ©2009 Lippincott Williams & Wilkins

> Table of Contents > Chapter 6 - Upper Limb > 6.68 Synovial sheaths of palm of hand

---

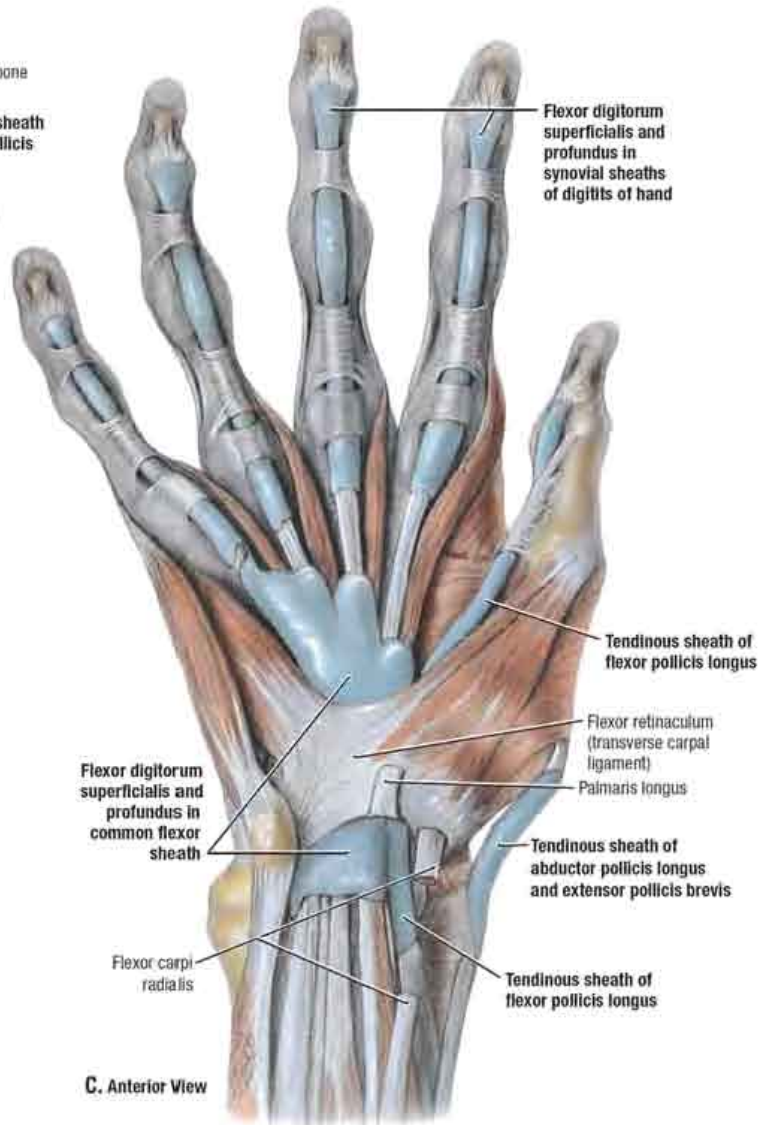
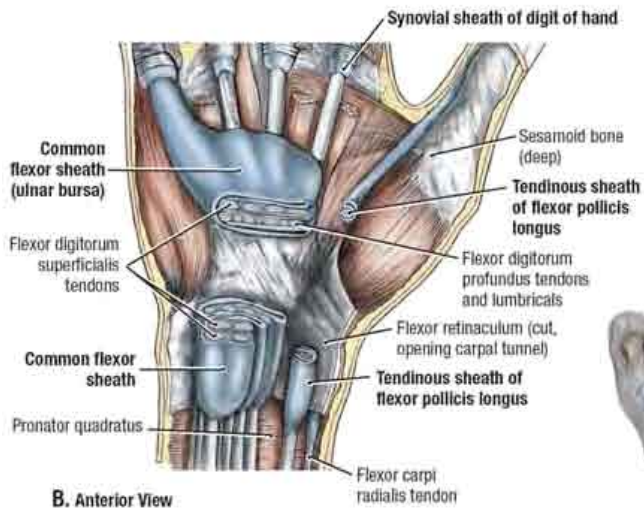
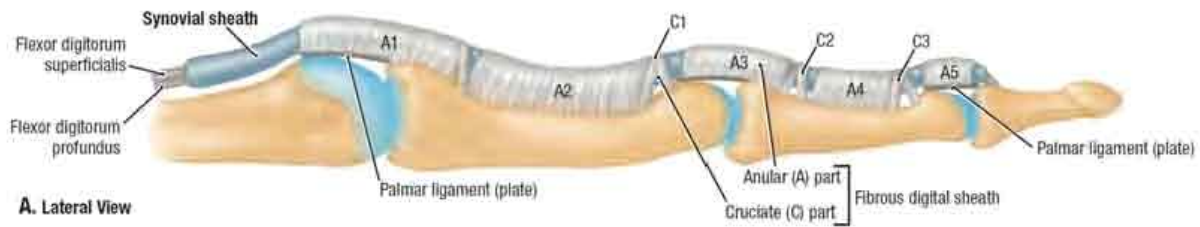
## 6.68 Synovial sheaths of palm of hand

*Part of "Chapter 6 - Upper Limb "*

A. Anular and cruciate parts (pulleys) of the fibrous digital sheath. B. Common flexor sheath. C. Tendinous (synovial) sheaths of long flexor tendons of the digits.

Injuries such as puncture of a finger by a rusty nail can cause infection of the digital synovial sheaths. When inflammation of the tendon and synovial sheath (tenosynovitis) occurs, the digit swells and movement becomes painful. Because the tendons of the 2nd–4th digits nearly always have separate synovial sheaths, the infection usually is confined to the infected digits. If the infection is untreated, however, the proximal ends of these sheaths may rupture, allowing the infection to spread to the midpalmar space. Because the synovial sheath of the little finger is usually continuous with the common flexor sheath, tenosynovitis in this finger may spread to the common flexor sheath and thus through the palm and carpal tunnel to the anterior forearm. Likewise, tenosynovitis in the thumb may spread through the continuous tendinous sheath of flexor pollicis longus.





Authors: Agur, Anne M.R.; Dalley, Arthur F.

Title: *Grant's Atlas of Anatomy, 12th Edition*

Copyright ©2009 Lippincott Williams & Wilkins

> Table of Contents > Chapter 6 - Upper Limb > 6.69 Digital tendons, vessels, and nerves

---

## 6.69 Digital tendons, vessels, and nerves

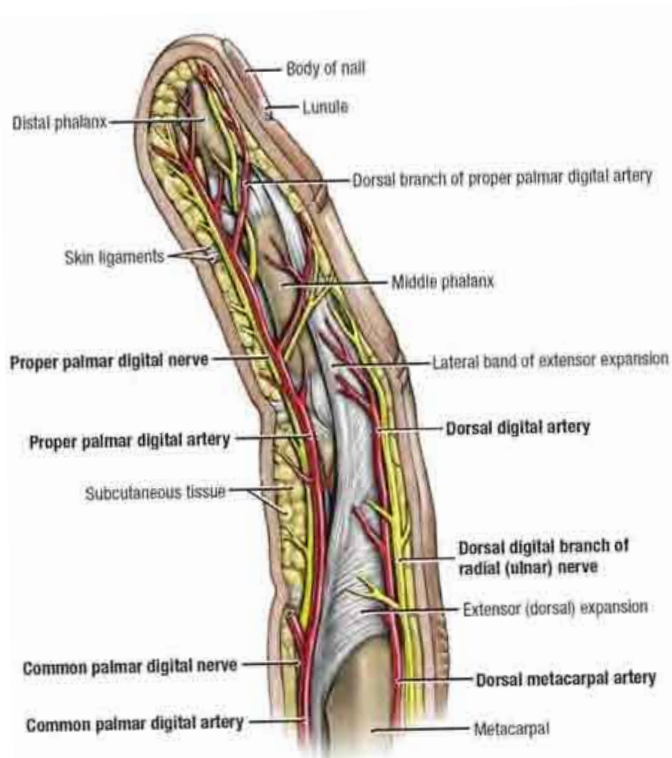
*Part of* "Chapter 6 - Upper Limb "

A. Digital vessels and nerves. B. Extensor expansion of the 3rd (middle) digit. C. Transverse section through the proximal phalanx. D. Osseofibrous tunnel and tendinous (synovial) sheath.

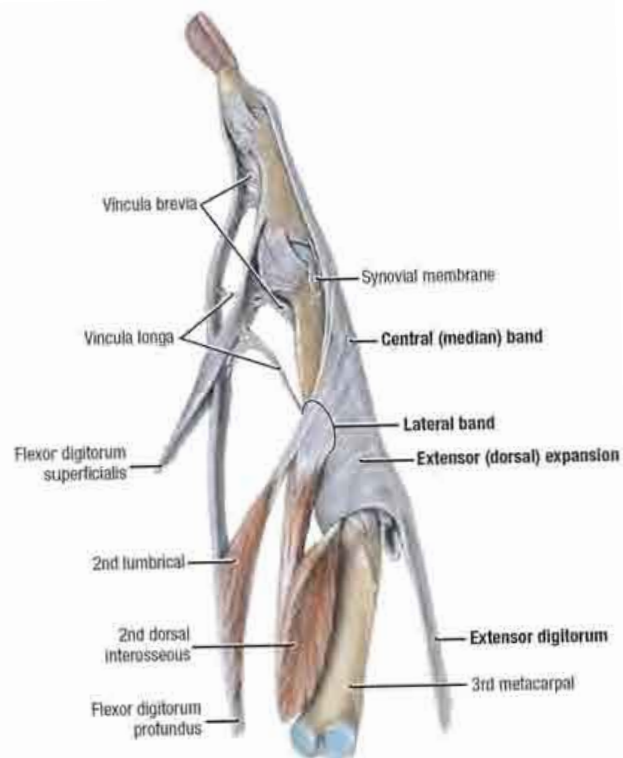
---

P.570

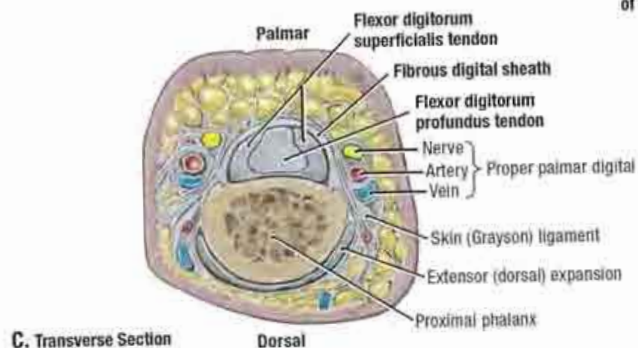




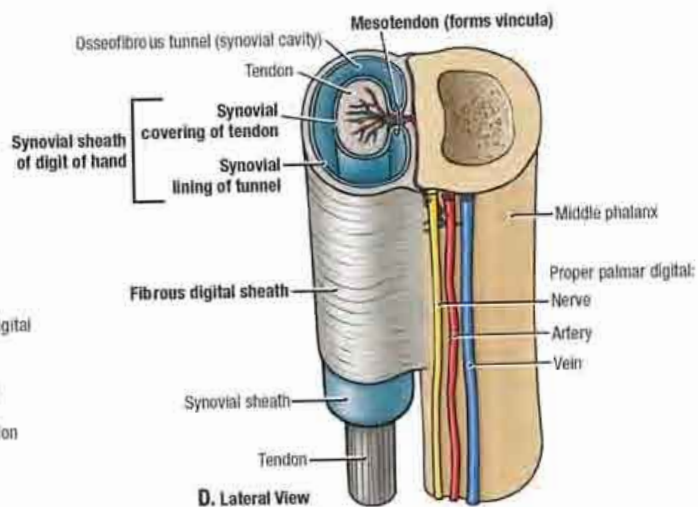
**A. Lateral View (right 3rd digit)**



**B. Lateral View (right 3rd digit)**



**C. Transverse Section**



**D. Lateral View**

Authors: Agur, Anne M.R.; Dalley, Arthur F.

Title: *Grant's Atlas of Anatomy, 12th Edition*

Copyright ©2009 Lippincott Williams & Wilkins

> Table of Contents > Chapter 6 - Upper Limb > 6.70 Deep dissection of palm

---

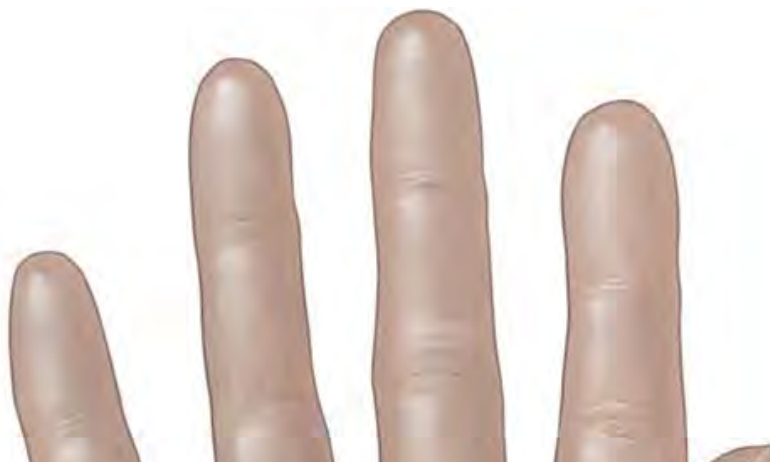## 6.70 Deep dissection of palm

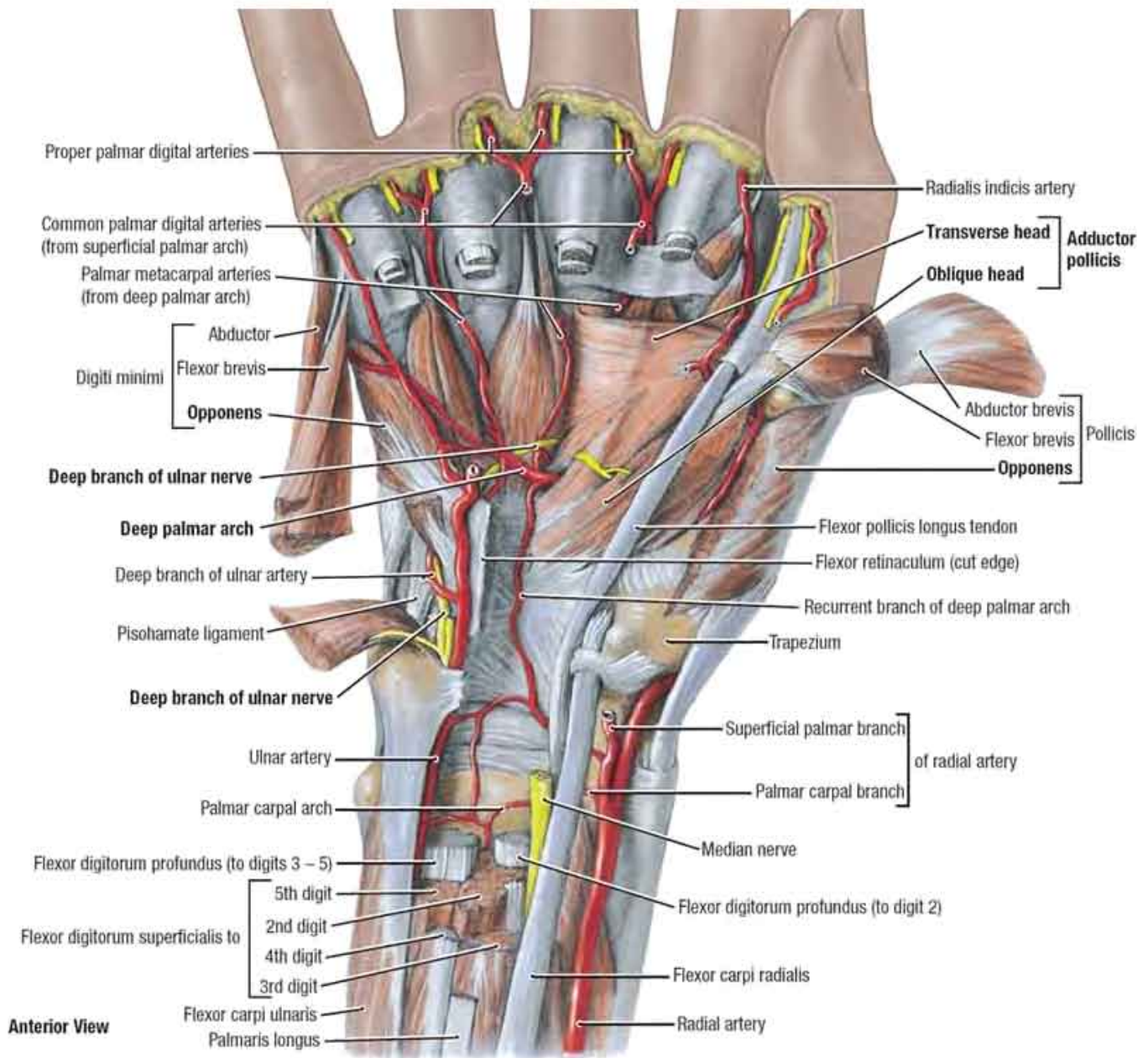
*Part of "Chapter 6 - Upper Limb"*

- The deep branch of the ulnar artery joins the radial artery to form the deep palmar arch.

Compression of the ulnar nerve may occur at the wrist where it passes between the pisiform and the hook of hamate. The depression between these bones is converted by the pisohamate ligament into an osseofibrous ulnar canal (Guyon canal). Ulnar canal syndrome is manifest by hypoesthesia in the medial one and one half fingers and weakness of the intrinsic hand muscles. Clawing of the 4th and 5th fingers may occur, but in contrast to proximal nerve injury, their ability to flex is unaffected and there is no radical deviation of the hand.

P.571





Authors: Agur, Anne M.R.; Dalley, Arthur F.

Title: *Grant's Atlas of Anatomy, 12th Edition*

Copyright ©2009 Lippincott Williams & Wilkins

> Table of Contents > Chapter 6 - Upper Limb > 6.71 Deep dissection of palm and digits with deep branch of ulnar nerve

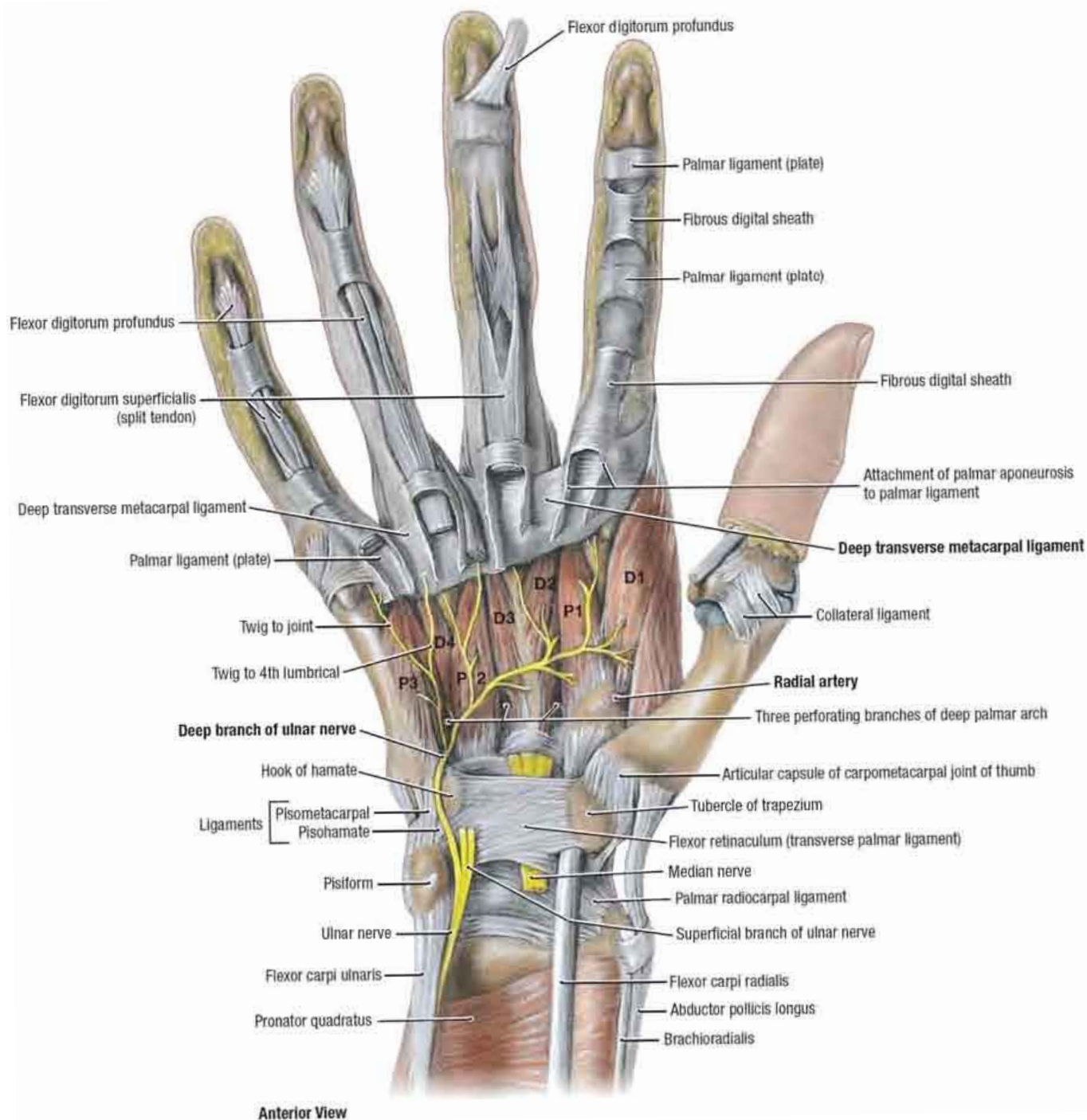
---

## 6.71 Deep dissection of palm and digits with deep branch of ulnar nerve

*Part of "Chapter 6 - Upper Limb "*

- Three unipennate palmar (*P1*) and four bipennate dorsal (*D1*) interosseous muscles are illustrated; the palmar interossei adduct the fingers, and the dorsal interossei abduct the fingers in relation to the axial line, an imaginary line drawn through the long axis of the 3rd digit (see Table 6.11 ).
- The deep transverse metacarpal ligaments unite the palmar ligaments; the lumbricals pass anterior to the deep transverse metacarpal ligament, and the interossei pass posterior to the ligament.
- Note the ulnar (Guyon) canal through which the ulnar vessels and nerve pass medial to the pisiform.





Authors: Agur, Anne M.R.; Dalley, Arthur F.

Title: *Grant's Atlas of Anatomy, 12th Edition*

Copyright ©2009 Lippincott Williams & Wilkins

> Table of Contents > Chapter 6 - Upper Limb > 6.72 Arterial supply of hand

---

## 6.72 Arterial supply of hand

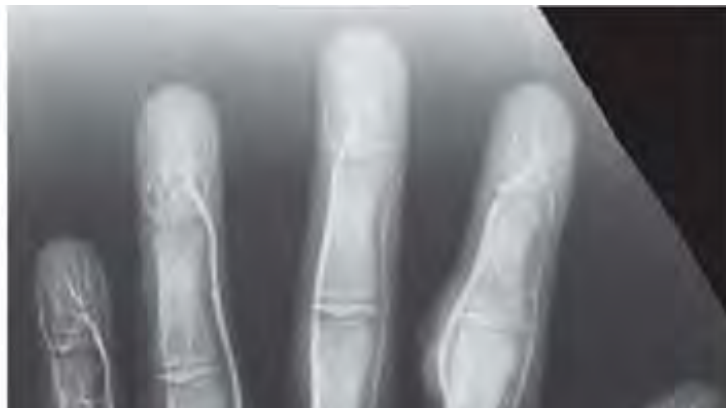*Part of "Chapter 6 - Upper Limb "*

A. Arteriogram of the hand. B. Dissection of palmar arterial arches.

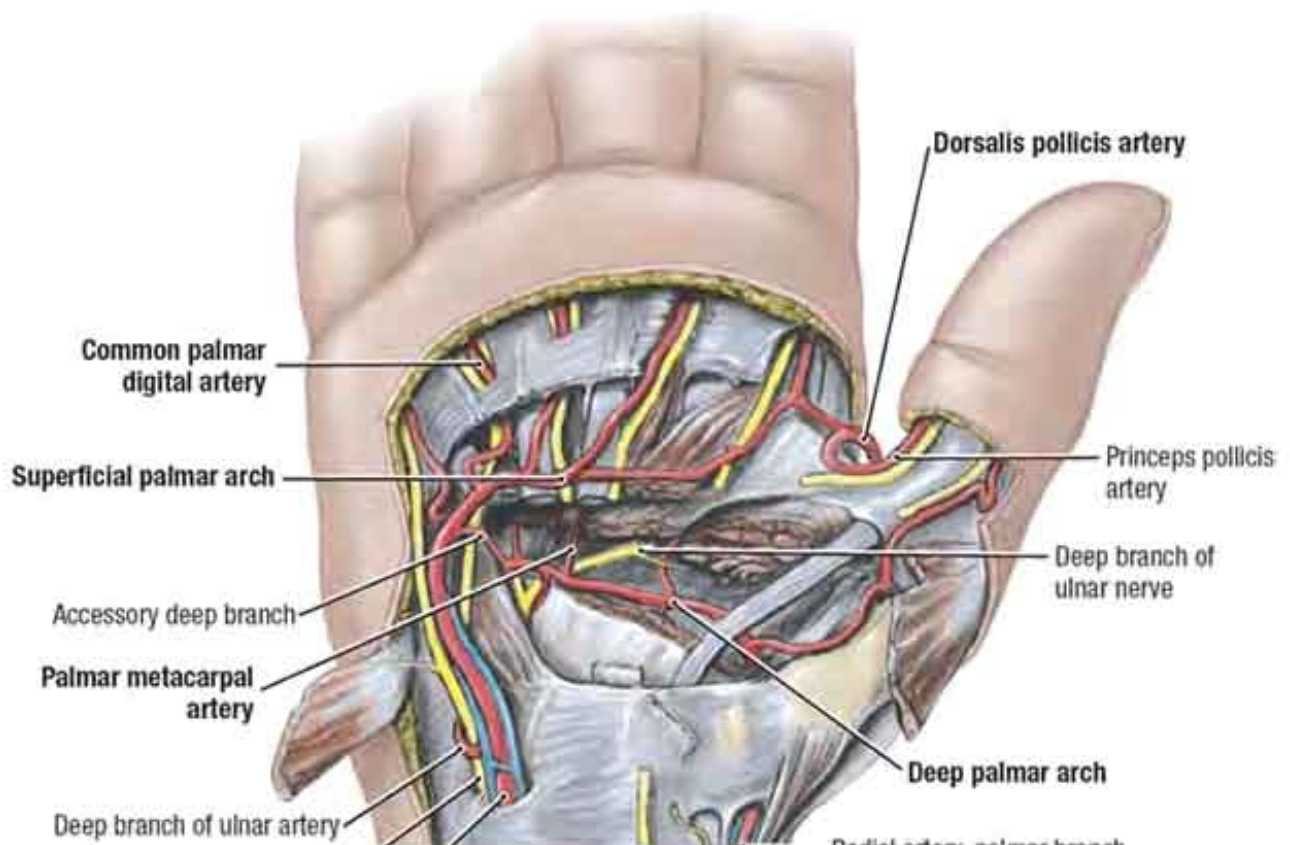
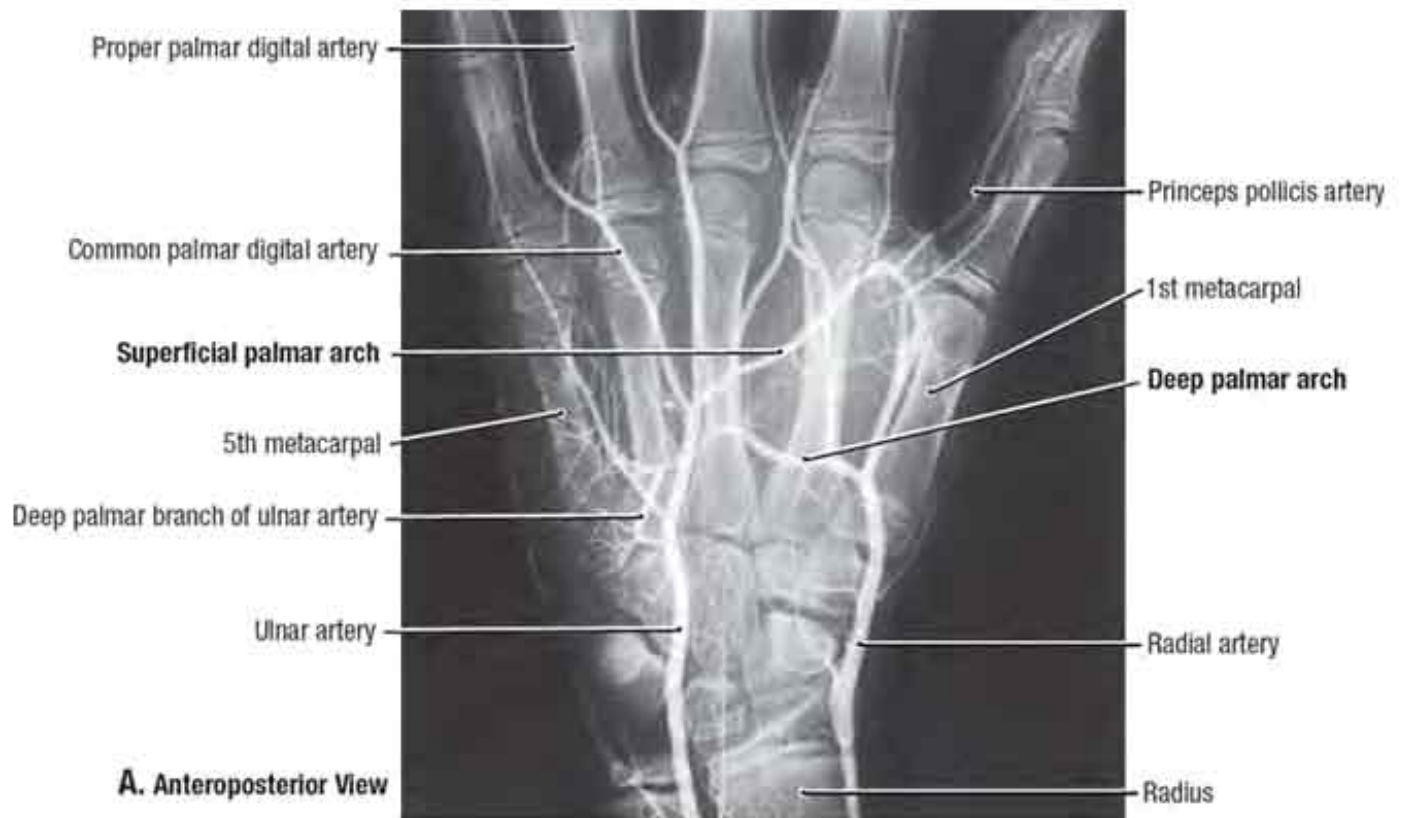- The superficial palmar arch is usually completed by the superficial palmar branch of the radial artery, but in this specimen the dorsalis pollicis artery completes the arch.

The superficial and deep palmar (arterial) arches are not palpable, but their surface markings are visible. The superficial palmar arch occurs at the level of the distal border of the fully extended thumb. The deep palmar arch lies approximately 1 cm proximal to the superficial palmar arch. The location of these arches should be borne in mind in wounds of the palm and when palmar incisions are made.

P.573









### Superficial palmar arch

Direct continuation of ulnar artery; arch is completed on lateral side by superficial branch of radial artery or another of its branches

Curves laterally deep to palmar aponeurosis and superficial to long flexor tendons; curve of arch lies across palm at level of distal border of extended thumb

### Deep palmar arch

Direct continuation of radial artery; arch is completed on medial side by deep branch of ulnar artery

Curves medially, deep to long flexor tendons and is in contact with bases of metacarpals

### Common palmar digitals

#### Superficial palmar arch

Pass directly on lumbricals to webbings of digits

#### Proper palmar digitals

#### Common palmar digital arteries

Run along sides of digits 2–5

#### Princeps pollicis

Radial artery as it turns into palm

Descends on palmar aspect of first metacarpal and divides at the base of proximal phalanx into two branches that run along sides of thumb

#### Radialis indicis

Radial artery, but may arise from princeps pollicis artery

Passes along lateral side of index finger to its distal end

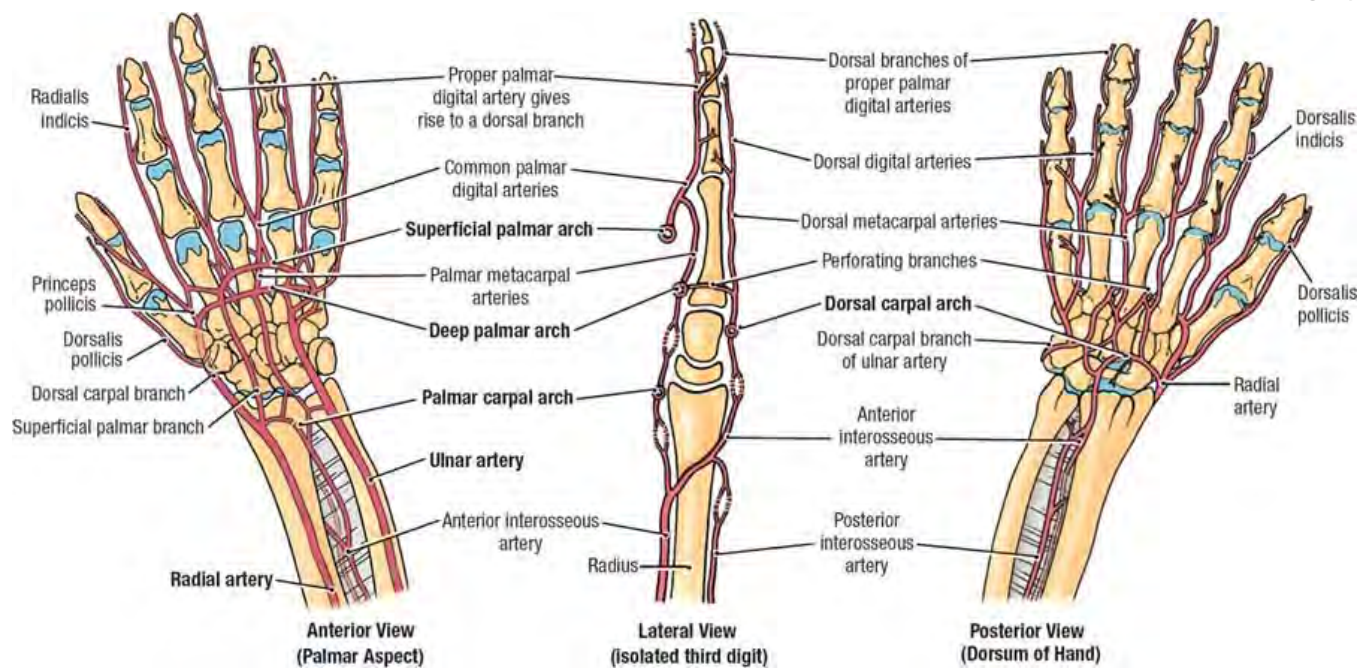
### Dorsal carpal arch

Radial and ulnar arteries

Arches within fascia on dorsum of hand

Artery    Origin    Course

**Table 6.12 Arteries of Hand**



Authors: Agur, Anne M.R.; Dalley, Arthur F.

Title: *Grant's Atlas of Anatomy, 12th Edition*

Copyright ©2009 Lippincott Williams & Wilkins

> Table of Contents > Chapter 6 - Upper Limb > 6.73 Superficial muscles of extensor region of forearm

---

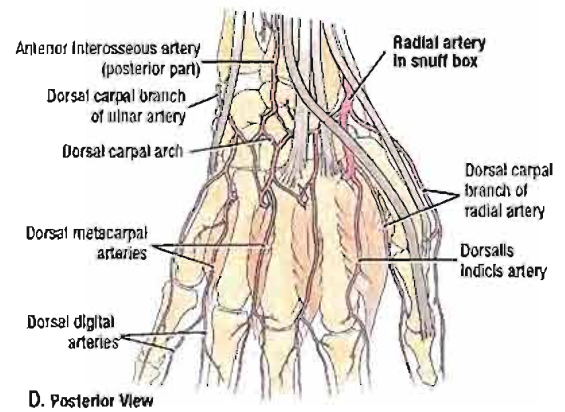
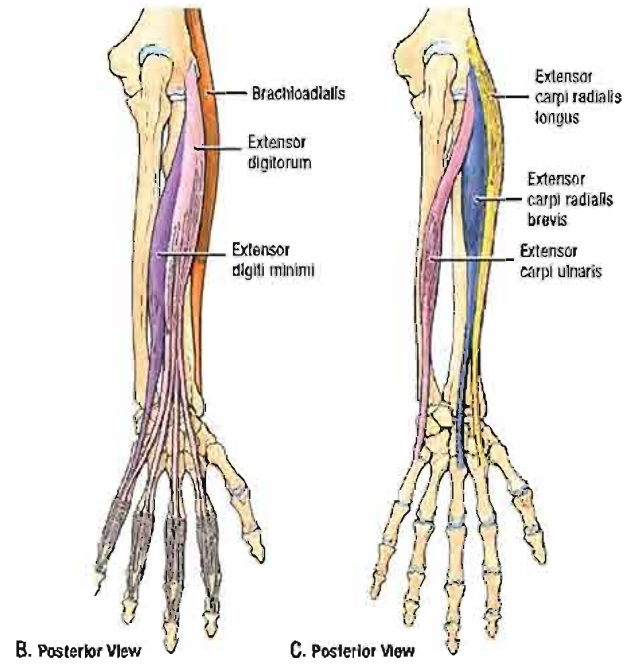
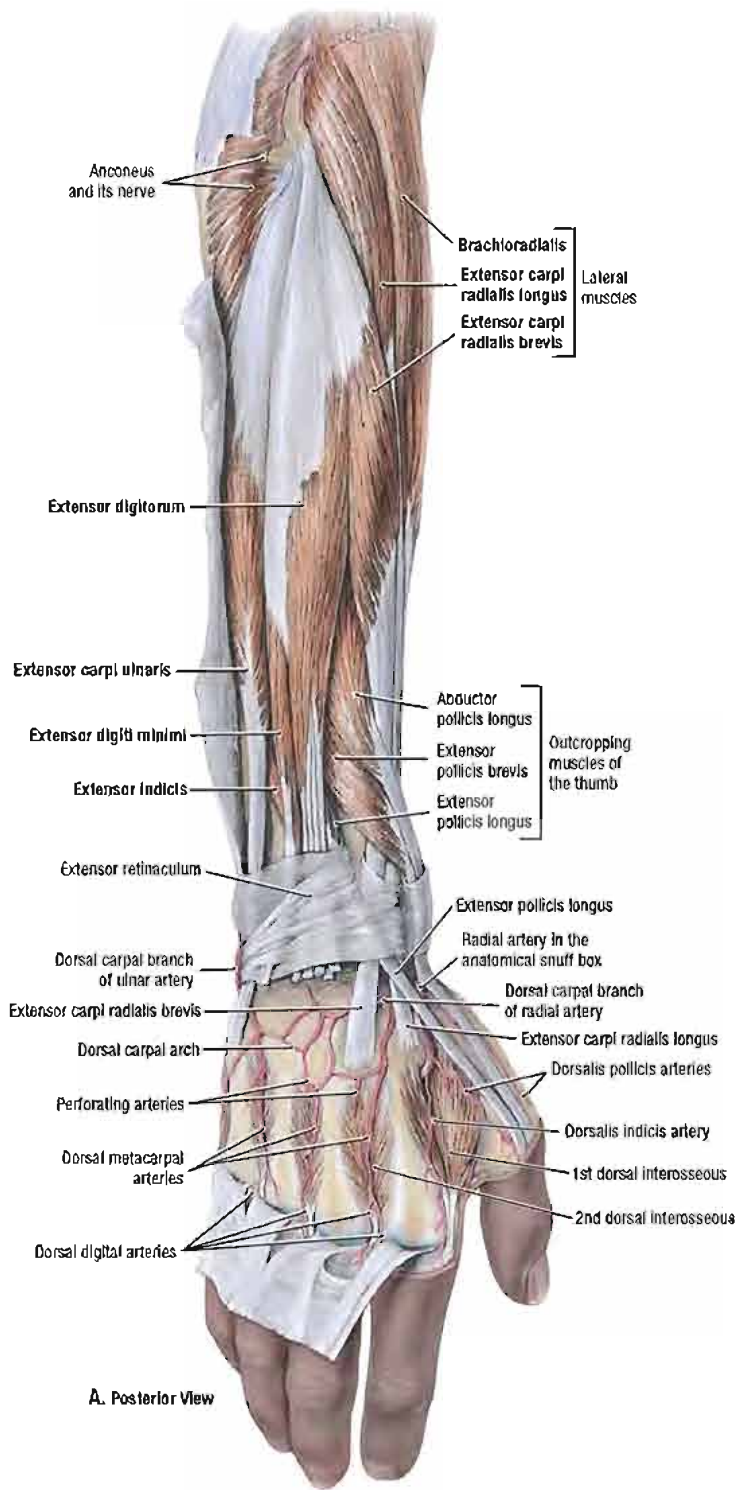
## 6.73 Superficial muscles of extensor region of forearm

*Part of "Chapter 6 - Upper Limb "*

A. Dissection. The digital extensor tendons have been reflected without disturbing the arteries because they lie on the skeletal plane. B and C. Schematic illustrations of extensor muscles. D. Arteries on dorsum of hand.

---

P.577





Authors: Agur, Anne M.R.; Dalley, Arthur F.

Title: *Grant's Atlas of Anatomy, 12th Edition*

Copyright ©2009 Lippincott Williams & Wilkins

> Table of Contents > Chapter 6 - Upper Limb > 6.74 Deep structures on extensor aspect of forearm

---

## 6.74 Deep structures on extensor aspect of forearm

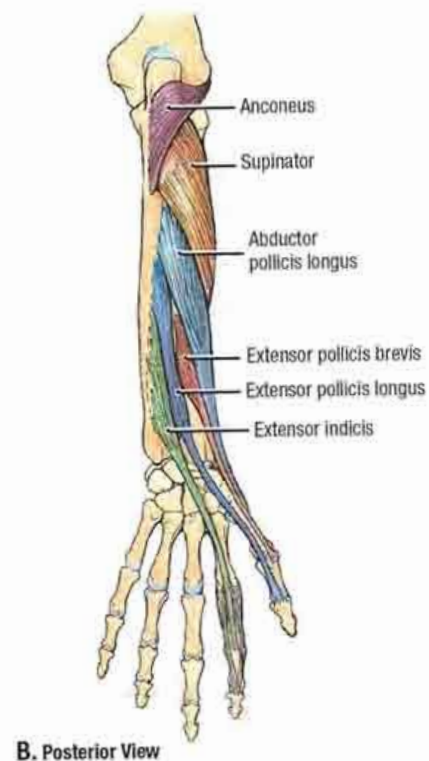
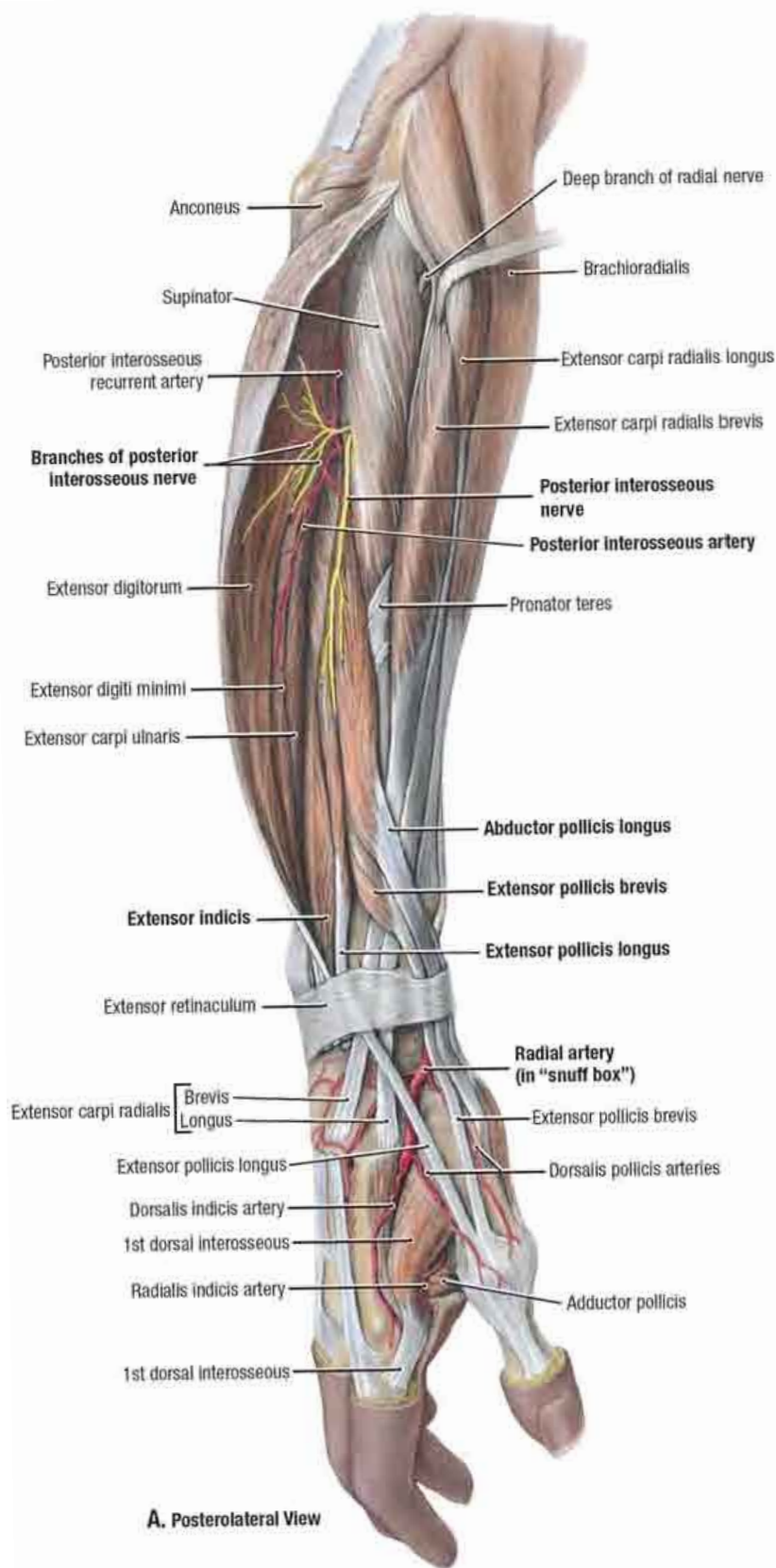
*Part of* "Chapter 6 - Upper Limb "

A. Dissection. B. Schematic illustration.

- Three “outcropping” muscles of the thumb (abductor pollicis longus, extensor pollicis brevis, and extensor pollicis longus) emerge between the extensor carpi radialis brevis and the extensor digitorum.
- The laterally retracted brachioradialis and extensor carpi radialis longus and brevis muscles and supinator muscles are innervated by the deep branch of the radial nerve; the other extensor muscles are supplied by the posterior interosseous nerve, which is a continuation of the deep branch of the radial nerve that pierced the supinator.

Severance of the deep branch of the radial nerve results in an inability to extend the thumb and the metacarpophalangeal joints of the other digits. Loss of sensation does not occur because the deep branch is entirely muscular and articular in distribution.





Authors: Agur, Anne M.R.; Dalley, Arthur F.  
Title: *Grant's Atlas of Anatomy, 12th Edition*  
Copyright ©2009 Lippincott Williams & Wilkins

> Table of Contents > Chapter 6 - Upper Limb > 6.75 Cutaneous innervation of hand

---

## 6.75 Cutaneous innervation of hand

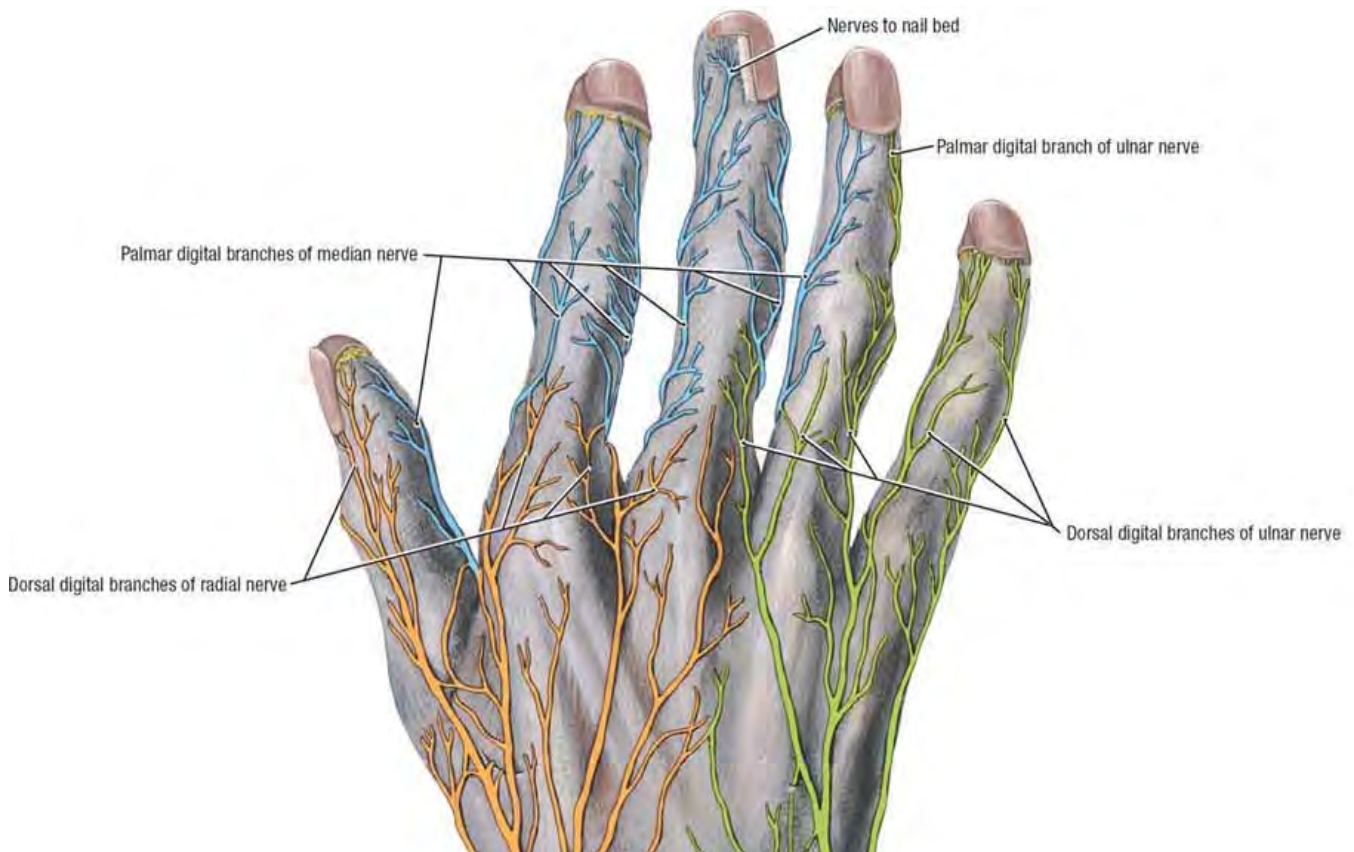
Part of "Chapter 6 - Upper Limb "

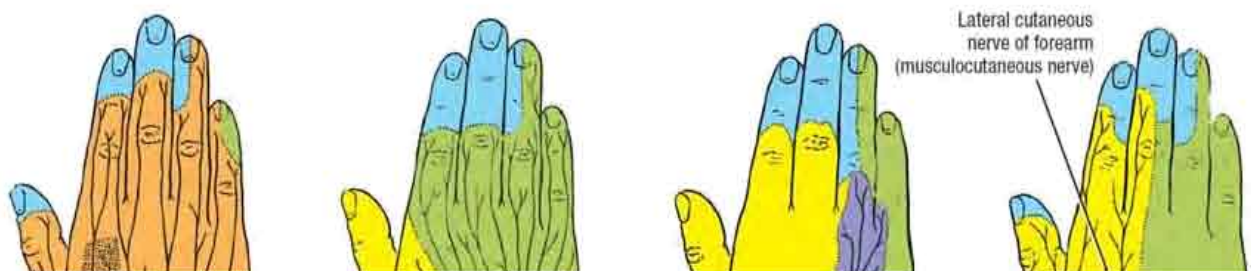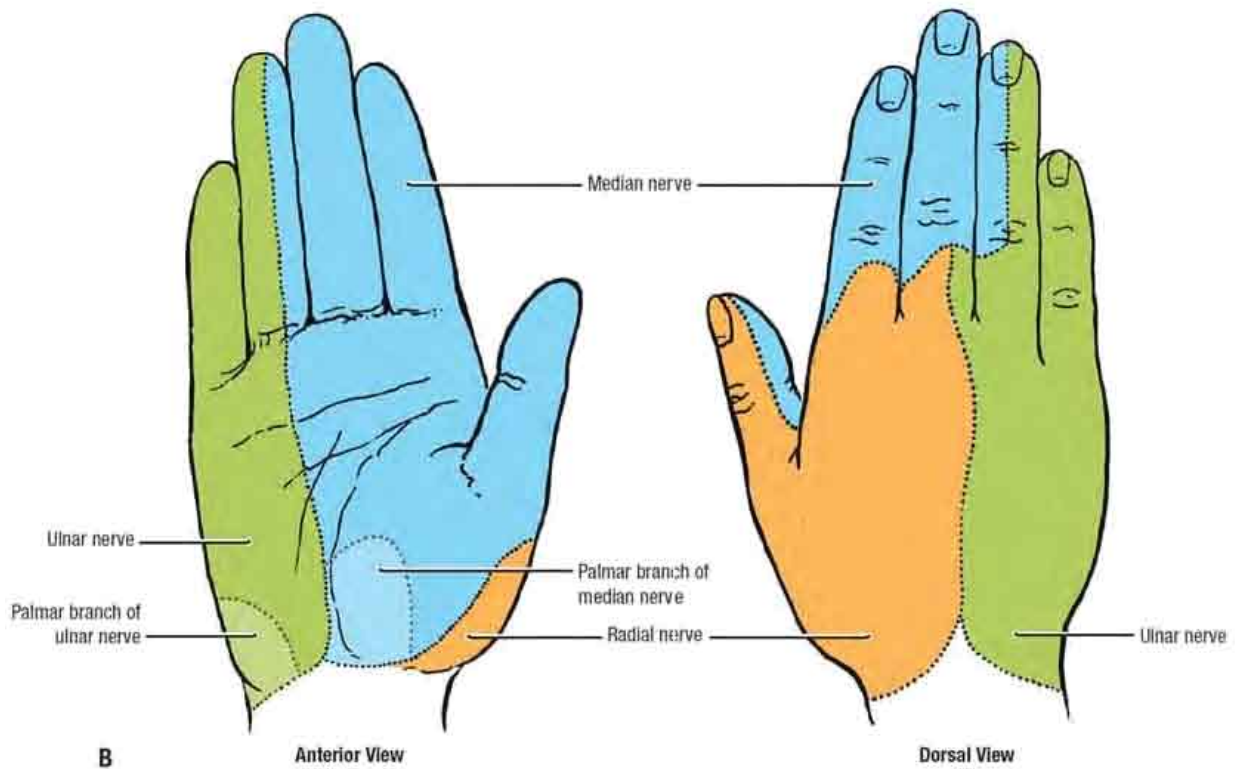
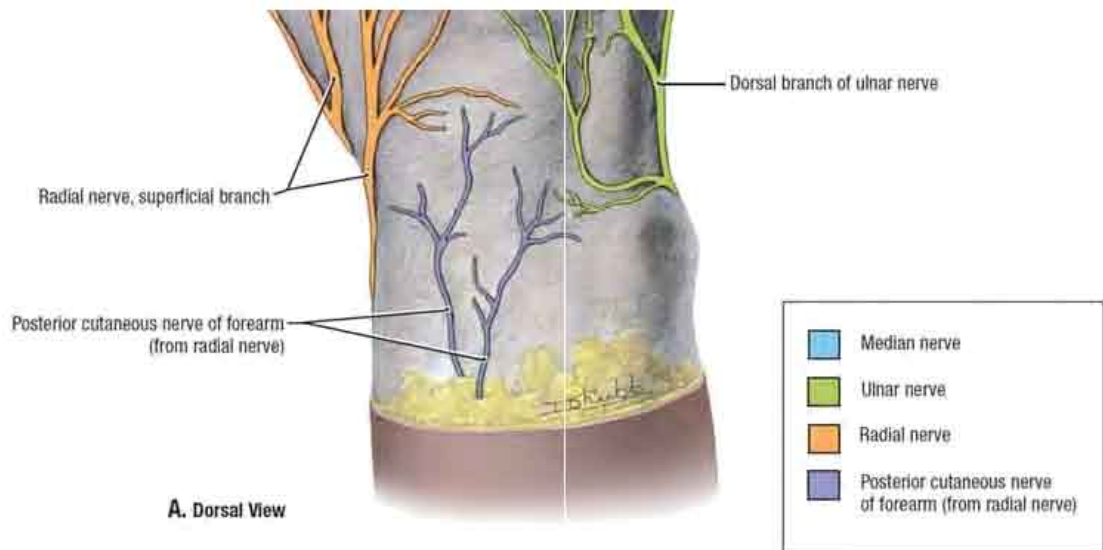
A. Dissection of nerves of dorsum of hand.

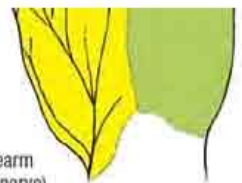
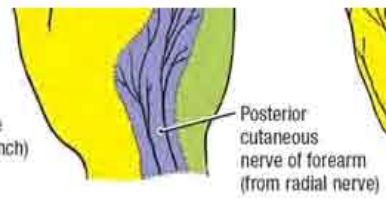
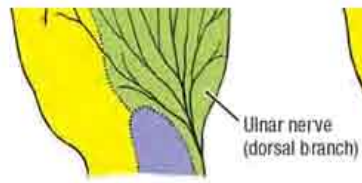
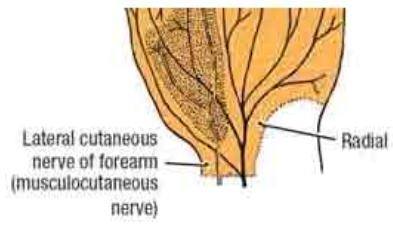
P.579

B. Distribution of the cutaneous nerves to the palm and dorsum of the hand, schematic illustration. C. Variations in pattern of cutaneous nerves in dorsum of hand.

P.580







### C. Dorsal Views

Authors: Agur, Anne M.R.; Dalley, Arthur F.

Title: *Grant's Atlas of Anatomy, 12th Edition*

Copyright ©2009 Lippincott Williams & Wilkins

> Table of Contents > Chapter 6 - Upper Limb > 6.76 Dorsum of hand

---

## 6.76 Dorsum of hand

*Part of "Chapter 6 - Upper Limb "*

A. Surface anatomy. The interphalangeal joints are flexed, and the metacarpophalangeal joints are hyperextended to demonstrate the extensor digitorum tendons. B. Tendinous (synovial) sheaths distended with blue fluid. C. Transverse section of distal forearm (*numbers* refer to structures labeled in B). D. Sites of bony attachments.

- Six tendinous sheaths occupy the six osseofibrous tunnels deep to the extensor retinaculum. They contain nine tendons: tendons for the thumb in sheaths 1 and 3, tendons for the extensors of the wrist in sheaths 2 and 6, and tendons for the extensors of the wrist and fingers in sheaths 4 and 5.
- The tendon of the extensor pollicis longus hooks around the dorsal tubercle of radius to pass obliquely across the tendons of the extensor carpi radialis longus and brevis to the thumb.

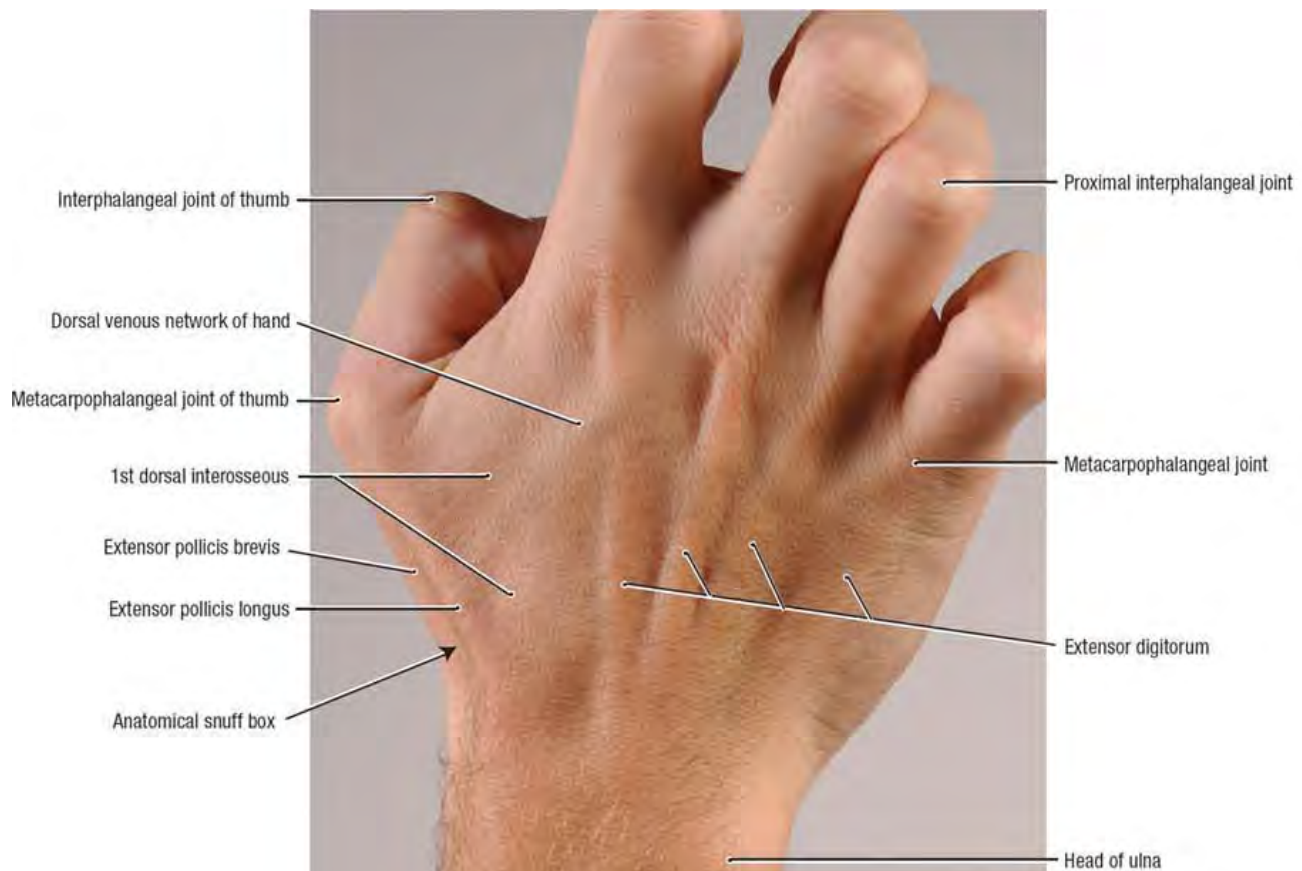
The tendons of the abductor pollicis longus and extensor pollicis brevis are in the same tendinous sheath on the dorsum of the wrist. Excessive friction of these tendons results in fibrous thickening of the sheath and stenosis of the osseofibrous tunnel, Quervain tenovaginitis stenosans. This condition causes pain in the wrist that radiates proximally to the forearm and distally to the thumb.



### E. Tendons on dorsum of hand and extensor retinaculum.

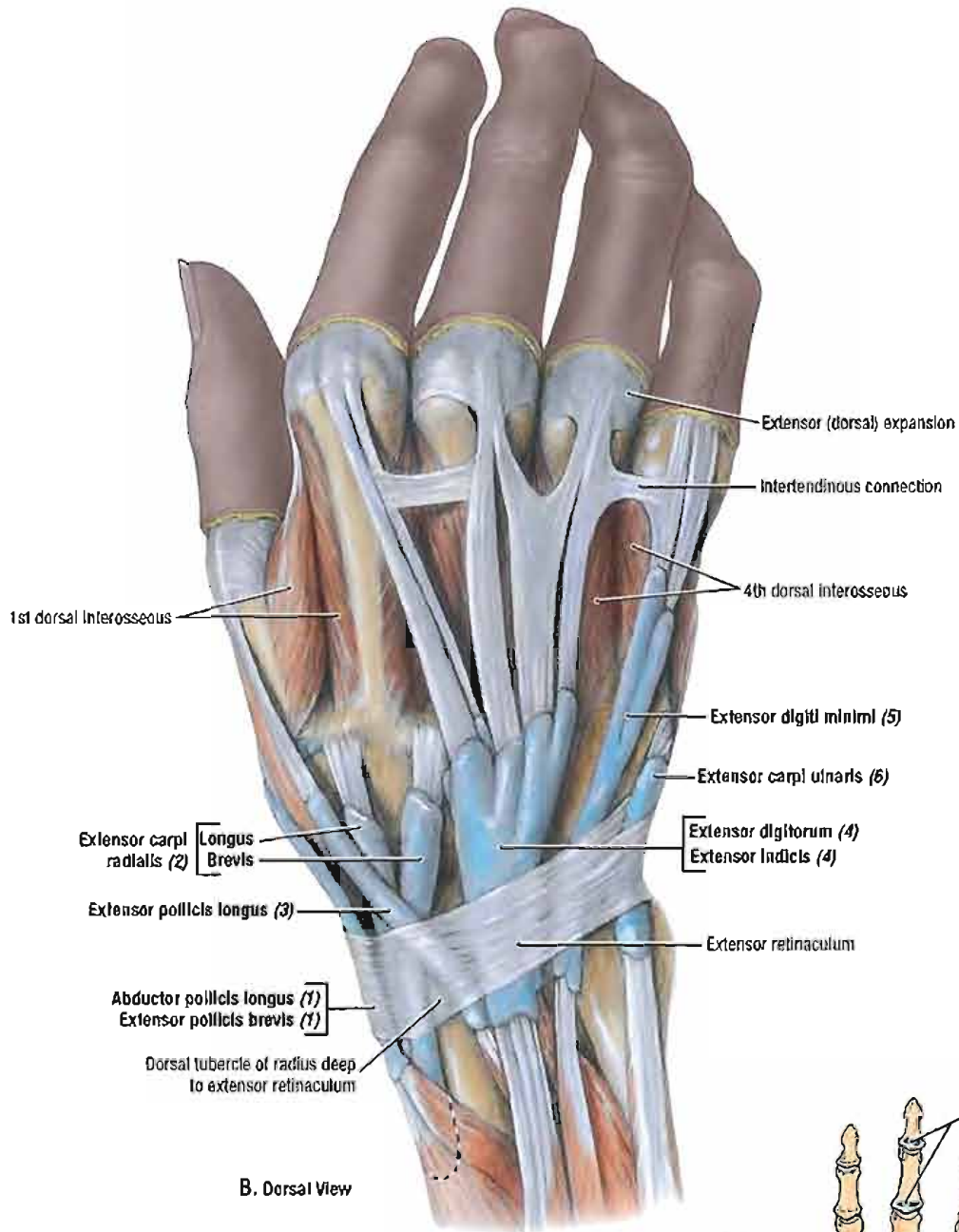
- The deep fascia is thickened to form the extensor retinaculum.
- Proximal to the knuckles, intertendinous connections extend between the tendons of the digital extensors and, thereby, restrict the independent action of the fingers.

Sometimes a nontender cystic swelling appears on the hand, most commonly on the dorsum of the wrist. The thin-walled cyst contains clear mucinous fluid. Clinically, this type of swelling is called a "ganglion" (G. swelling or knot). These synovial cysts are close to and often communicate with the synovial sheaths. The distal attachment of the extensor carpi radialis brevis tendon is a common site for such a cyst.

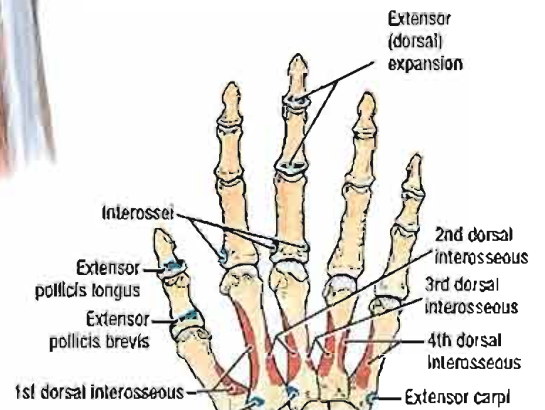
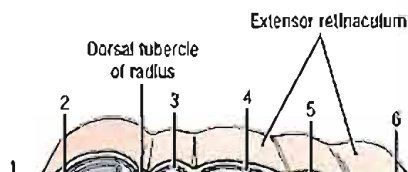


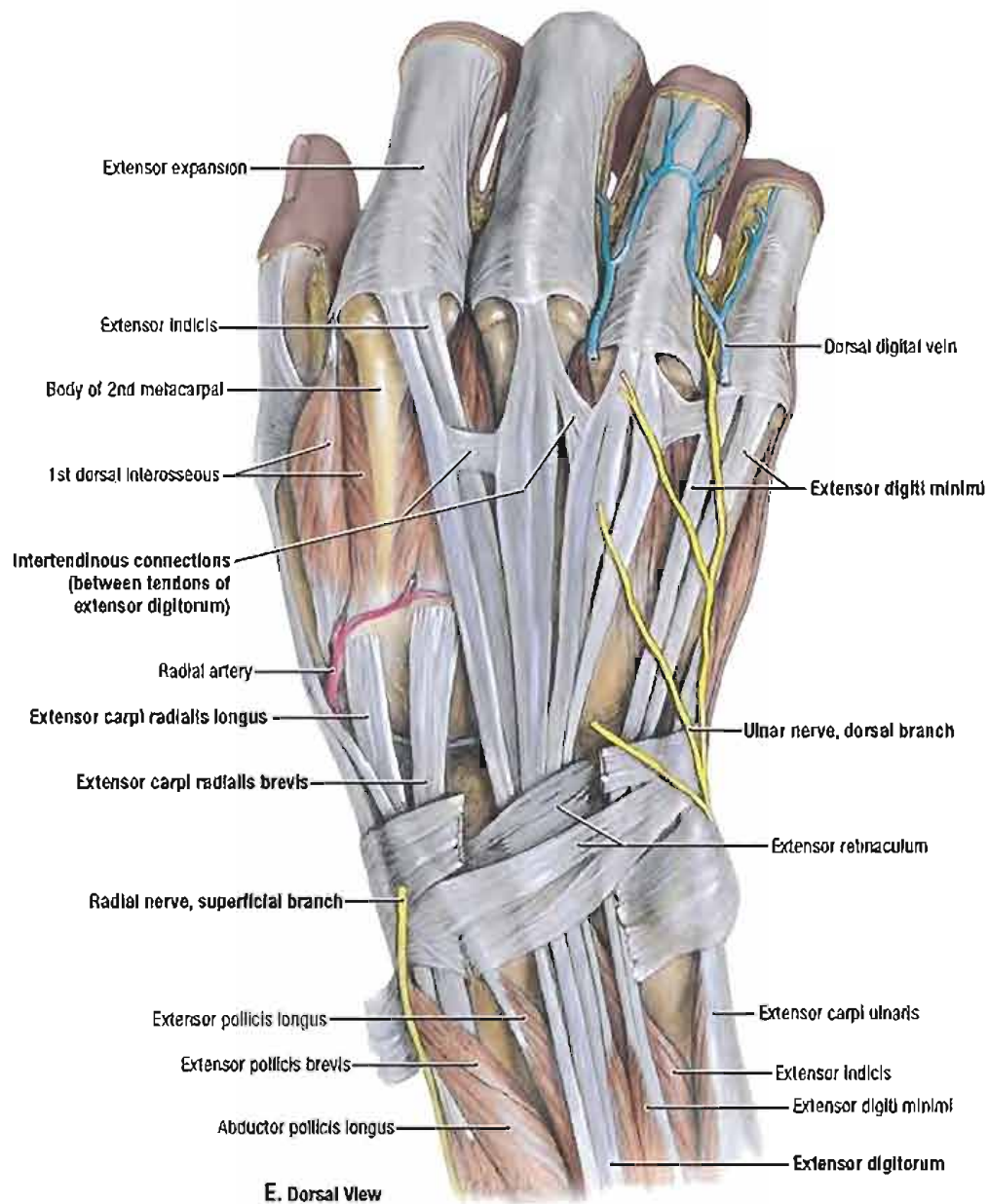
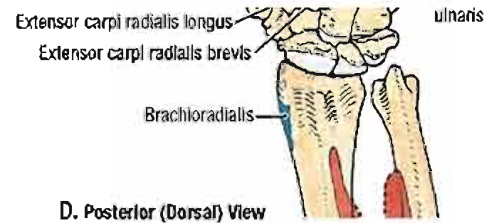
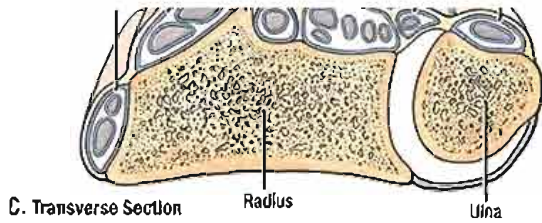


A. Dorsal View



B. Dorsal View





Authors: Agur, Anne M.R.; Dalley, Arthur F.

Title: *Grant's Atlas of Anatomy, 12th Edition*

Copyright ©2009 Lippincott Williams & Wilkins

> Table of Contents > Chapter 6 - Upper Limb > 6.77 Extensor (dorsal) expansion of 3rd digit

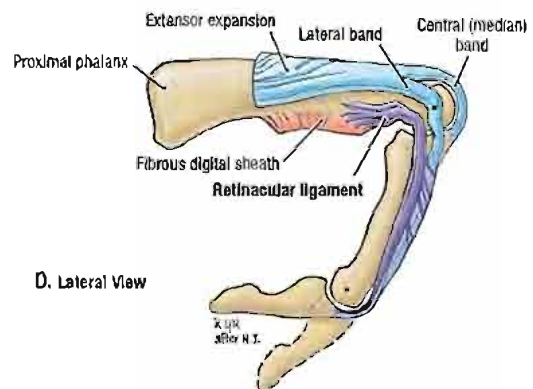
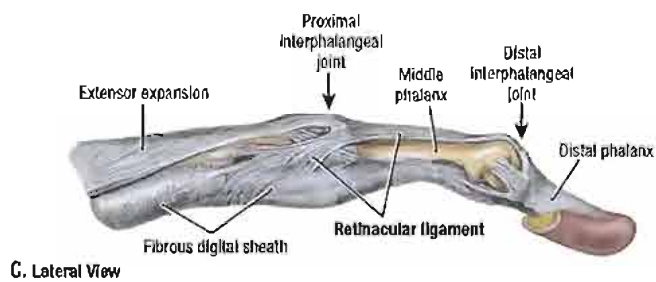
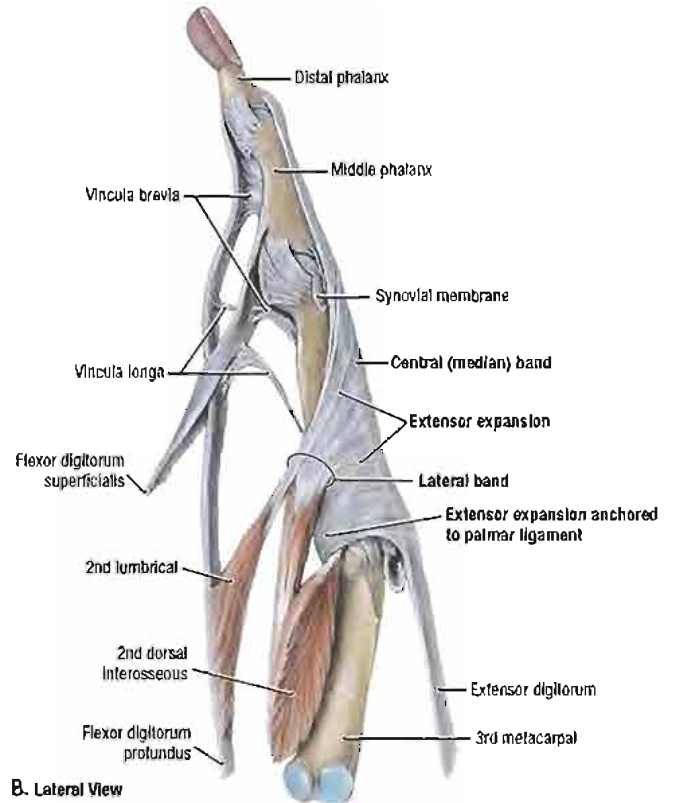
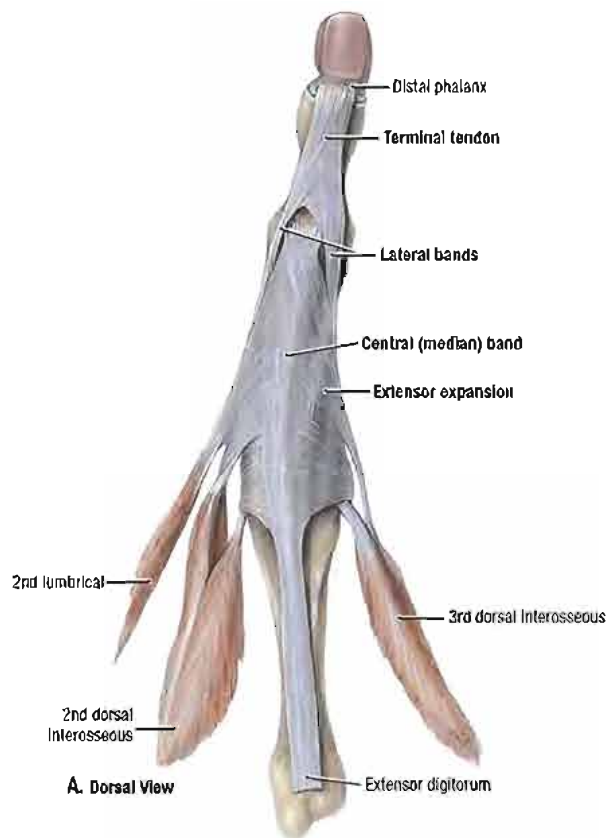
---

## 6.77 Extensor (dorsal) expansion of 3rd digit

*Part of* "Chapter 6 - Upper Limb "

A. Dorsal aspect. B. Lateral aspect. C. Retinacular ligaments of extended digit. D. Retinacular ligaments of flexed digit.

- The hood covering the head of the metacarpal is attached to the palmar ligament.
- Contraction of the muscles attaching to the lateral band will produce flexion of the metacarpophalangeal joint and extension of the interphalangeal joints.
- The retinacular ligament is a fibrous band that runs from the proximal phalanx and fibrous digital sheath obliquely across the middle phalanx and two interphalangeal joints to join the extensor (dorsal) expansion, and then to the distal phalanx.
- On flexion of the distal interphalangeal joint, the retinacular ligament becomes taut and pulls the proximal joint into flexion; on extension of the proximal joint, the distal joint is pulled by the ligament into nearly complete extension.



Authors: Agur, Anne M.R.; Dalley, Arthur F.

Title: *Grant's Atlas of Anatomy, 12th Edition*

Copyright ©2009 Lippincott Williams & Wilkins

> Table of Contents > Chapter 6 - Upper Limb > 6.78 Lateral aspect of wrist and hand

---

## 6.78 Lateral aspect of wrist and hand

*Part of "Chapter 6 - Upper Limb "*

A. Anatomical snuff box I. B. Anatomical snuff box II.

In A :

- The depression at the base of the thumb, the "anatomical snuff box," retains its name from an archaic habit.
- Note the superficial veins, including the cephalic vein of forearm and/or its tributaries, and cutaneous nerves crossing the snuff box.

In B :

- Three long tendons of the thumb form the boundaries of the snuff box; the extensor pollicis longus forms the medial boundary and the abductor pollicis longus and extensor pollicis brevis the lateral boundary.
- The radial artery crosses the floor of the snuff box and travels between the two heads of the 1st dorsal interosseous.
- The adductor pollicis and 1st dorsal interosseous are supplied by the ulnar nerve.

---

P.585

C. Anatomical snuff box III. D. Surface anatomy.

In C : Note the scaphoid bone, the wrist joint proximal to the scaphoid, and the



midcarpal joint distal to it.

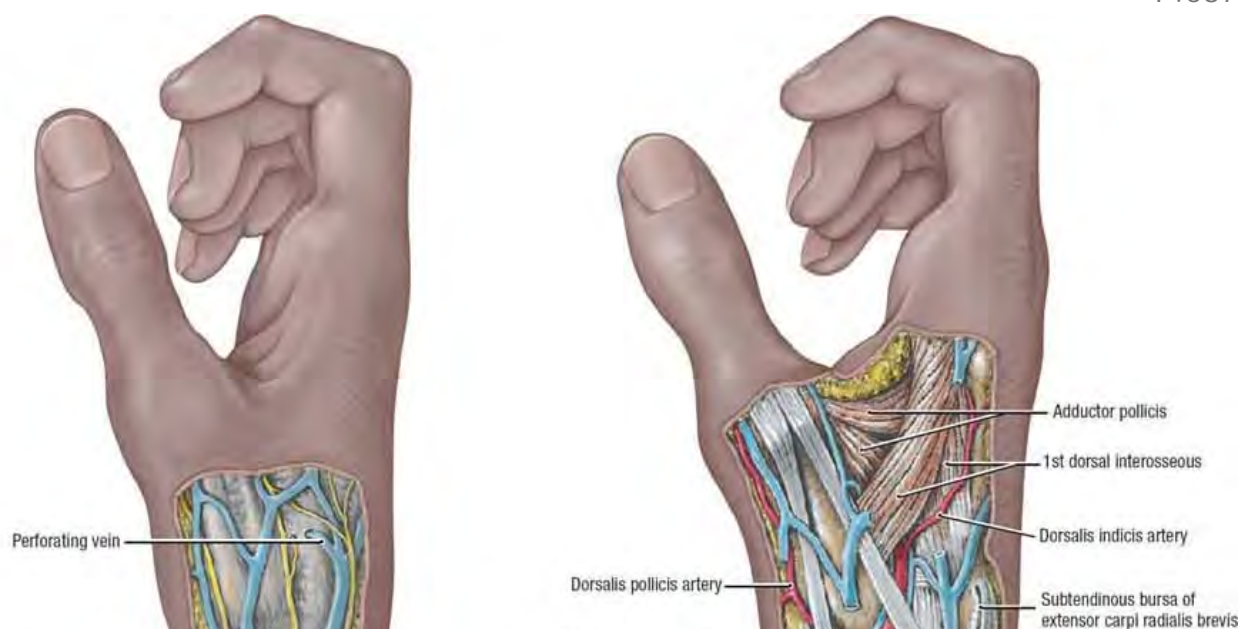
Fracture of the scaphoid often results from a fall on the palm with the hand abducted. The fracture occurs across the narrow part (â€œwaistâ€•) of the scaphoid. Pain occurs primarily on the lateral side of the wrist, especially during dorsiflexion and abduction of the hand. Initial radiographs of the wrist may not reveal a fracture, but radiographs taken 10â€“14 days later reveal a fracture because bone resorption has occurred. Owing to the poor blood supply to the proximal part of the scaphoid, union of the fractured parts may take several months. Avascular necrosis of the proximal fragment of the scaphoid (pathological death of bone resulting from poor blood supply) may occur and produce degenerative joint disease of the wrist.

P.586

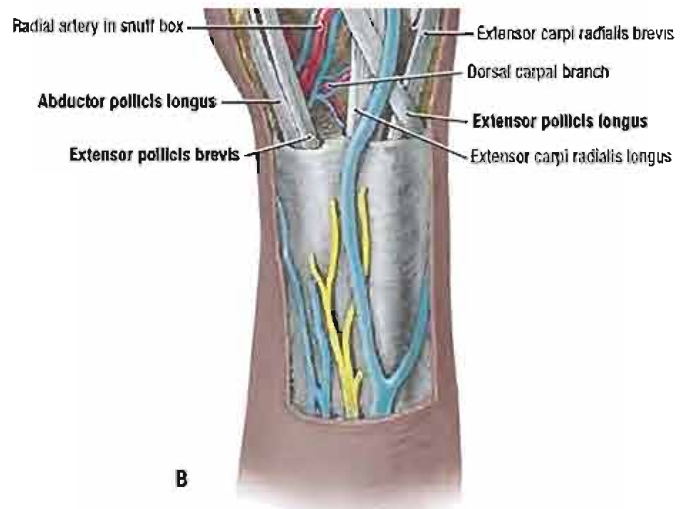
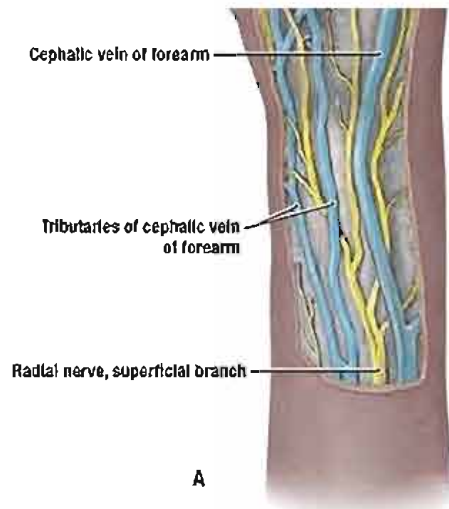
E. Bony hand showing muscle attachments. F. Radiograph.

- The anatomical snuff box is limited proximally by the styloid process of the radius and distally by the base of the 1st metacarpal; aspects of the two lateral bones of the carpus (scaphoid and trapezium) form the floor of the snuff box.

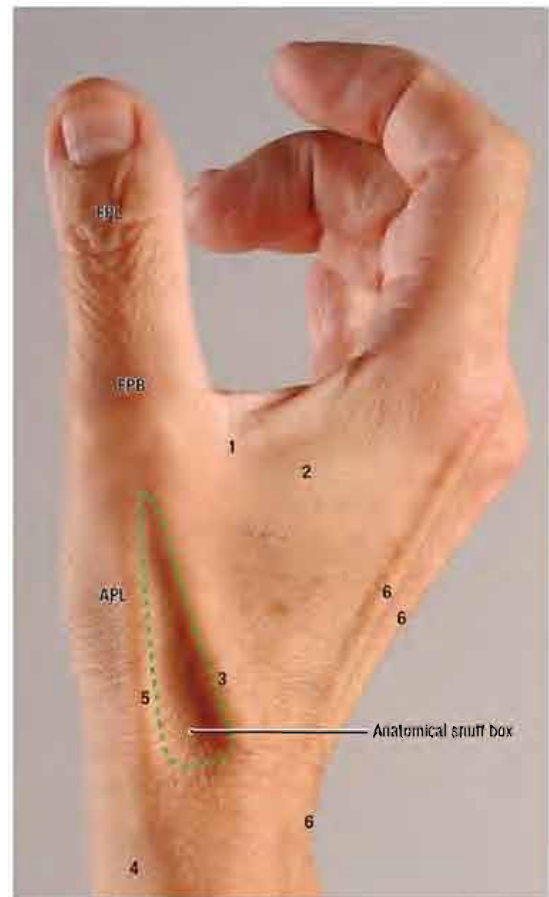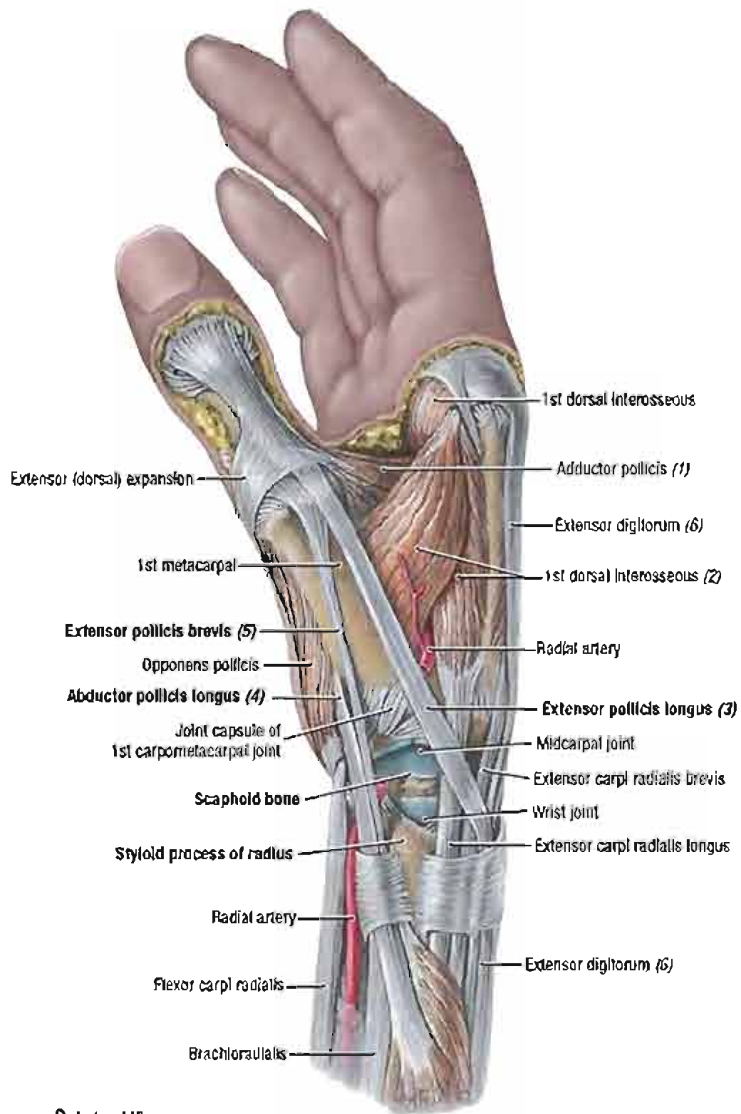
P.587







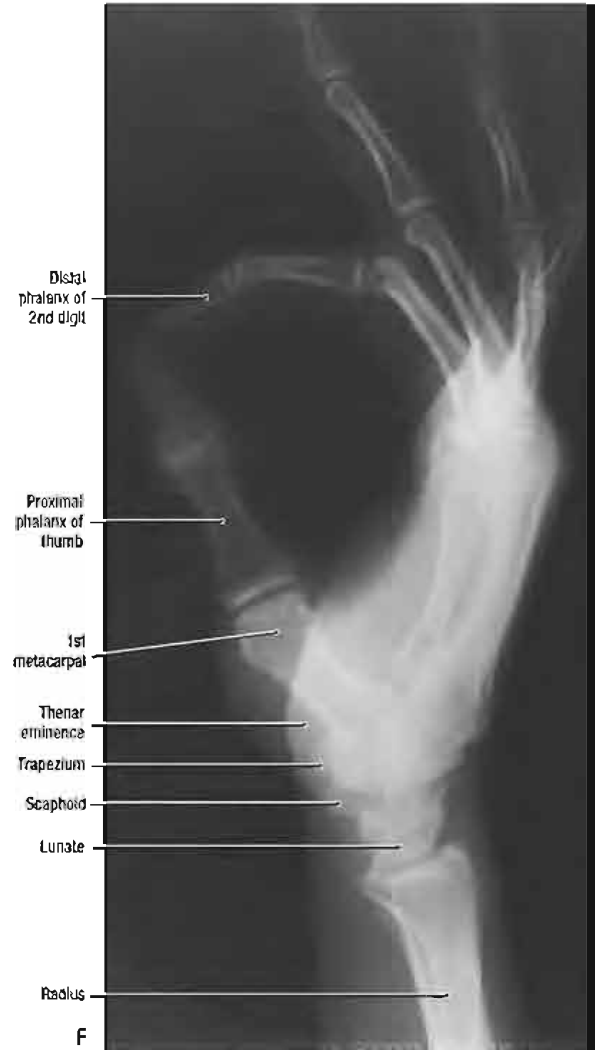
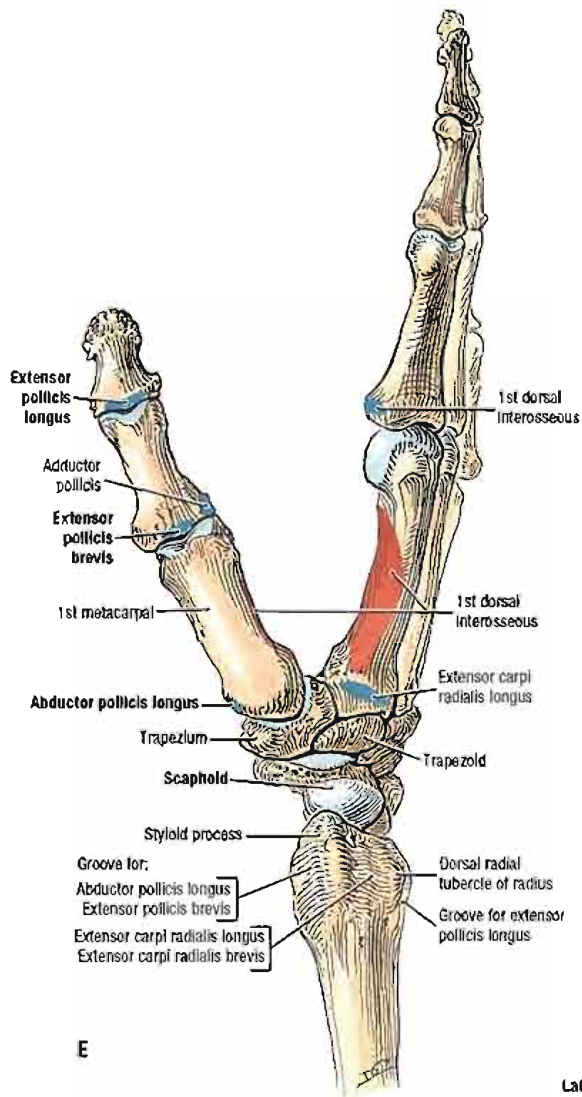
#### Lateral Views



**D. Lateral View**

#### Distal Extents of:

EPL	Extensor pollicis longus
EPB	Extensor pollicis brevis
APL	Abductor pollicis longus



Lateral Views, Right Hand

Authors: Agur, Anne M.R.; Dalley, Arthur F.

Title: *Grant's Atlas of Anatomy, 12th Edition*

Copyright ©2009 Lippincott Williams & Wilkins

> Table of Contents > Chapter 6 - Upper Limb > 6.79 Medial aspect of wrist and hand

---

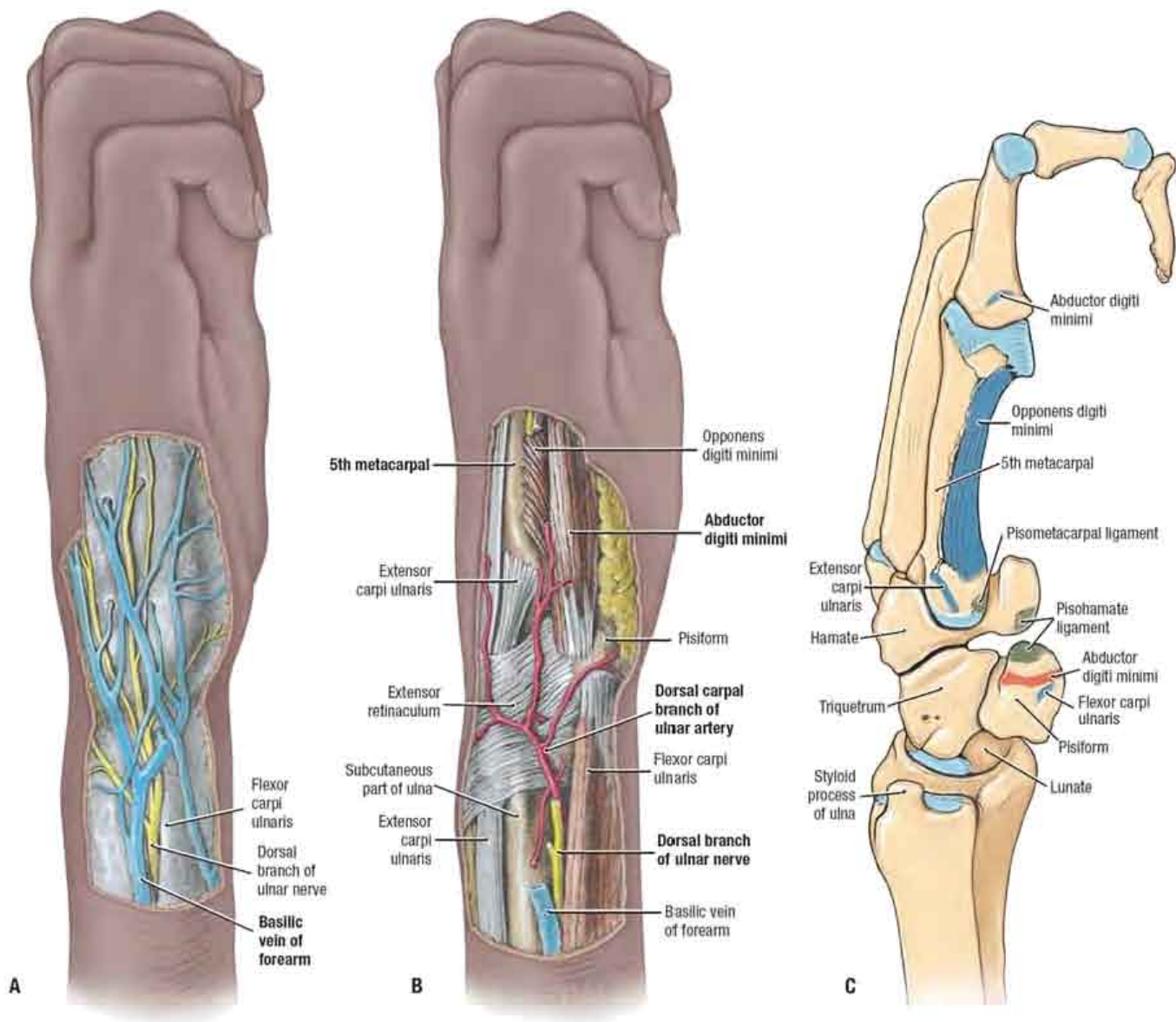
## 6.79 Medial aspect of wrist and hand

*Part of* "Chapter 6 - Upper Limb "

A. Superficial dissection. B. Deep dissection. C. Bony hand showing sites of muscular and ligamentous attachments. The extensor carpi ulnaris is inserted directly into the base of the fifth metacarpal, but the flexor carpi ulnaris inserts indirectly to the base of the fifth metacarpal and the hook of the hamate through the pisiform and pisohamate and pisometacarpal ligaments.

---

P.588



Medial Views

Authors: Agur, Anne M.R.; Dalley, Arthur F.

Title: *Grant's Atlas of Anatomy, 12th Edition*

Copyright ©2009 Lippincott Williams & Wilkins

> Table of Contents > Chapter 6 - Upper Limb > 6.80 Bones of hand

---

## 6.80 Bones of hand

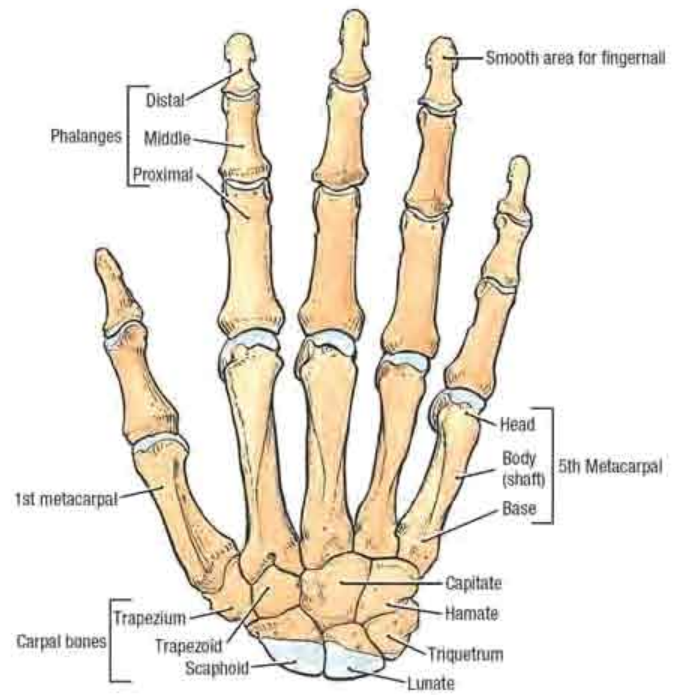
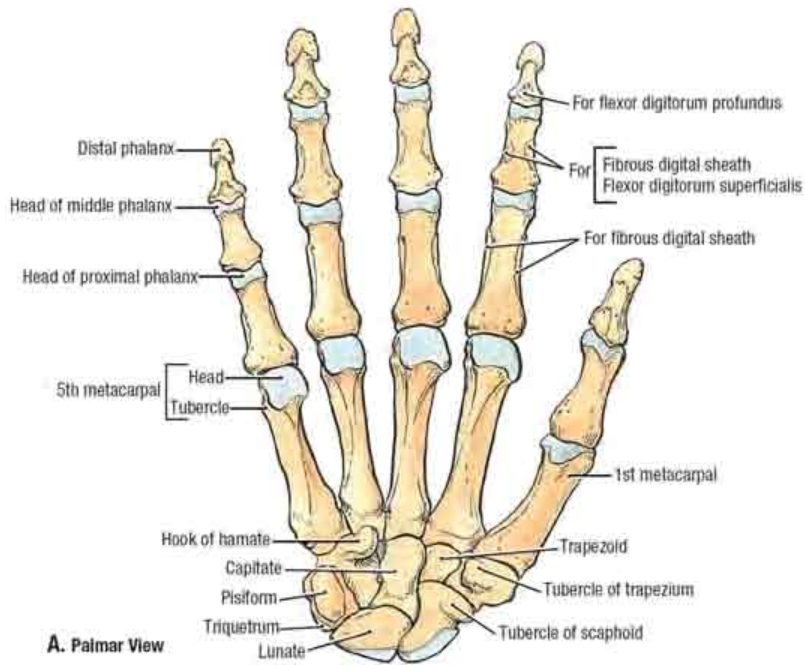
*Part of "Chapter 6 - Upper Limb "*

A. Palmar view. B. Dorsal view.

The eight carpal bones form two rows: in the distal row, the hamate, capitate, trapezoid, and trapezium; the trapezium forming a saddle-shaped joint with the 1st metacarpal; in the proximal row, the scaphoid, lunate, and pisiform; the pisiform is superimposed on the triquetrum.

Severe crushing injuries of the hand may produce multiple metacarpal fractures, resulting in instability of the hand. Similar injuries of the distal phalanges are common (e.g., when a finger is caught in a car door).

A fracture of a distal phalanx is usually comminuted, and a painful hematoma (collection of blood) develops. Fractures of the proximal and middle phalanges are usually the result of crushing or hypertension injuries.





Authors: Agur, Anne M.R.; Dalley, Arthur F.

Title: *Grant's Atlas of Anatomy, 12th Edition*

Copyright ©2009 Lippincott Williams & Wilkins

> Table of Contents > Chapter 6 - Upper Limb > 6.81 Imaging of bones of wrist and hand

---

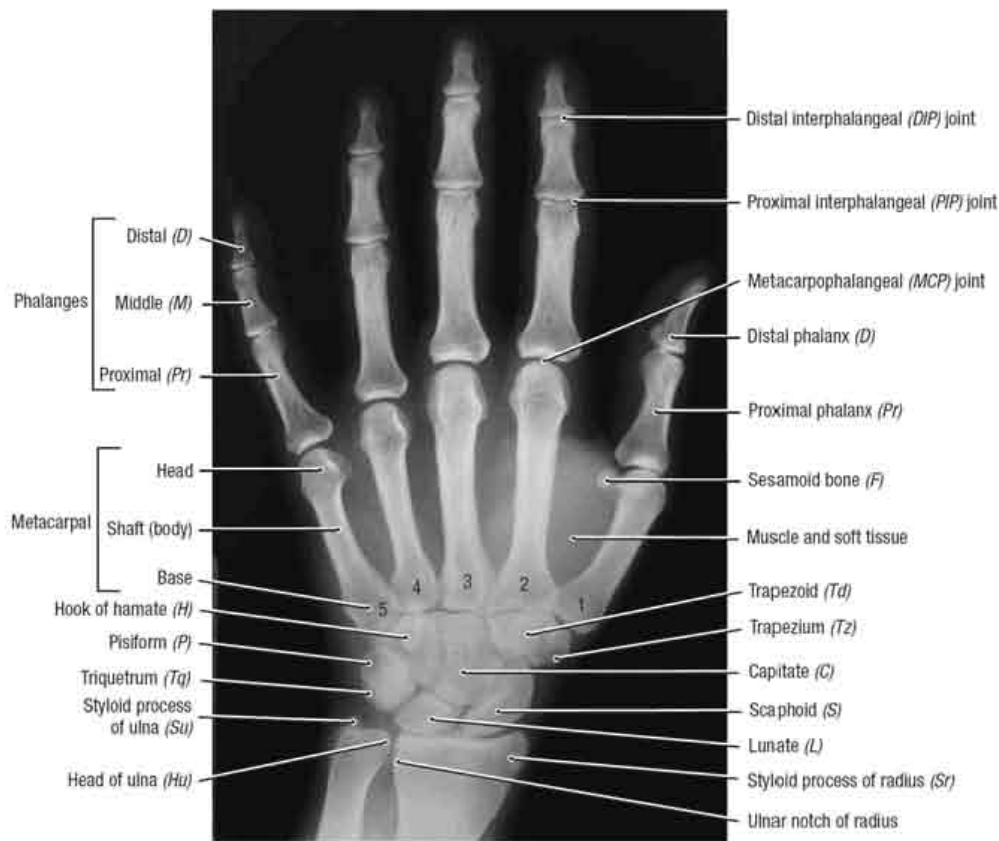
## 6.81 Imaging of bones of wrist and hand

*Part of* "Chapter 6 - Upper Limb "

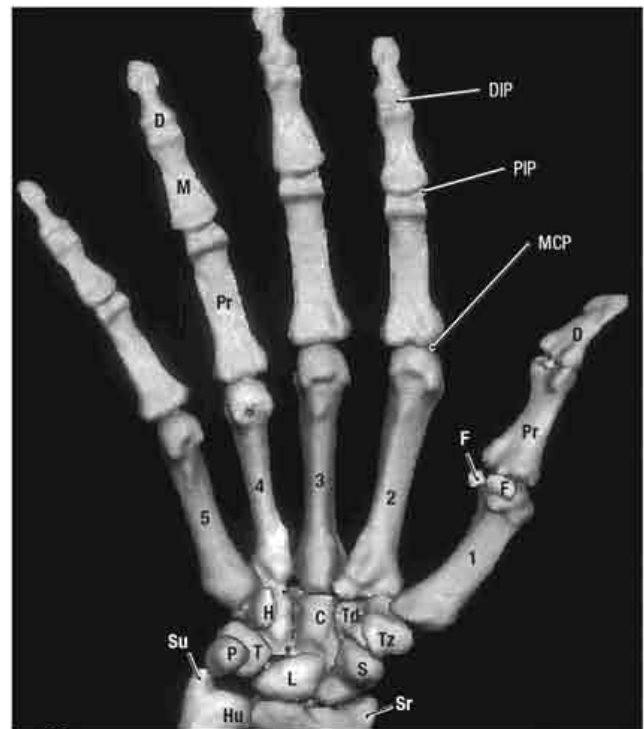
A. Radiograph. B. Three-dimensional computer-generated image of wrist and hand (letters correspond to structures labeled in A ).

---

P.590



A. Anterior View



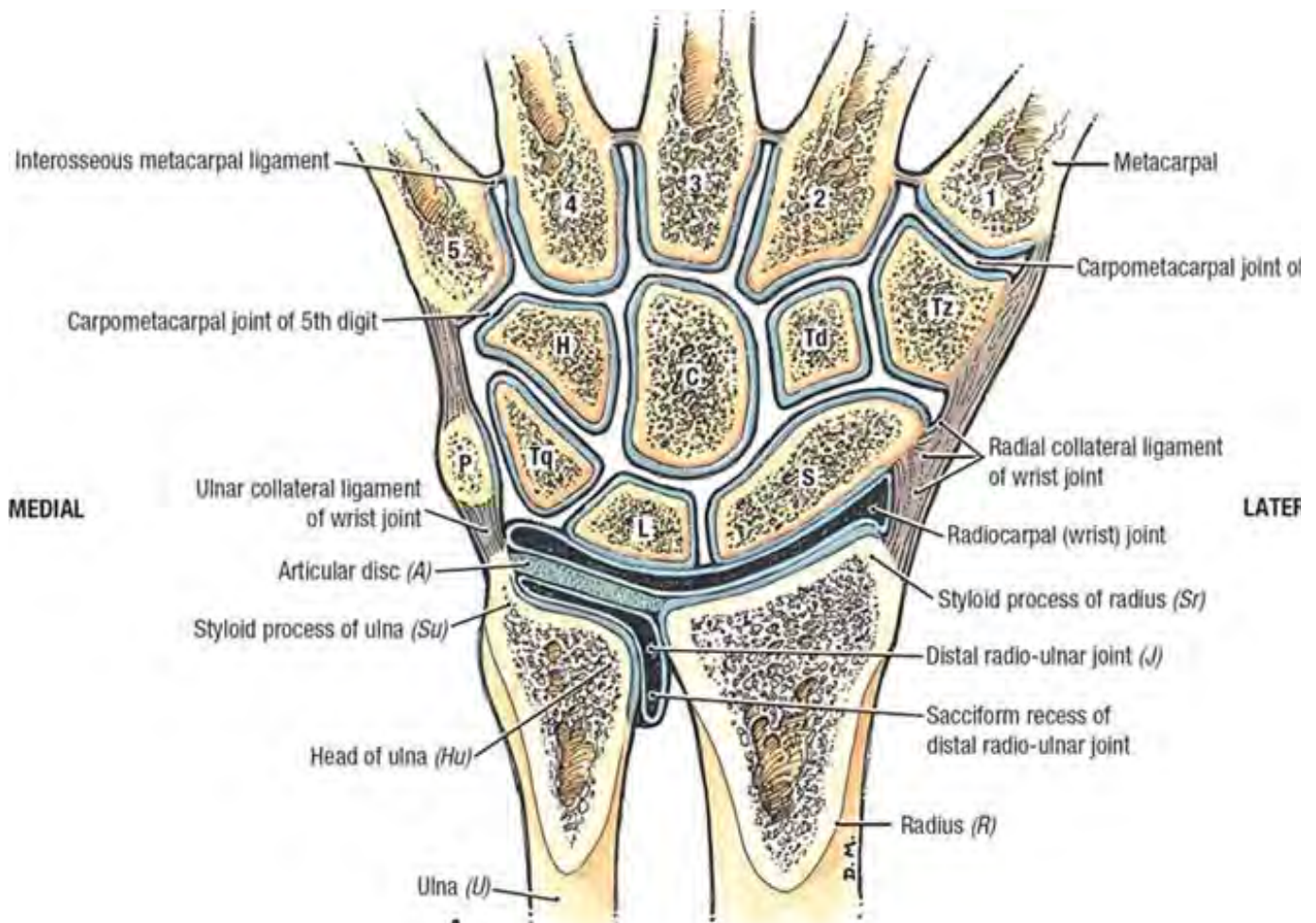
B. Anterior View

## 6.82 Coronal section of wrist

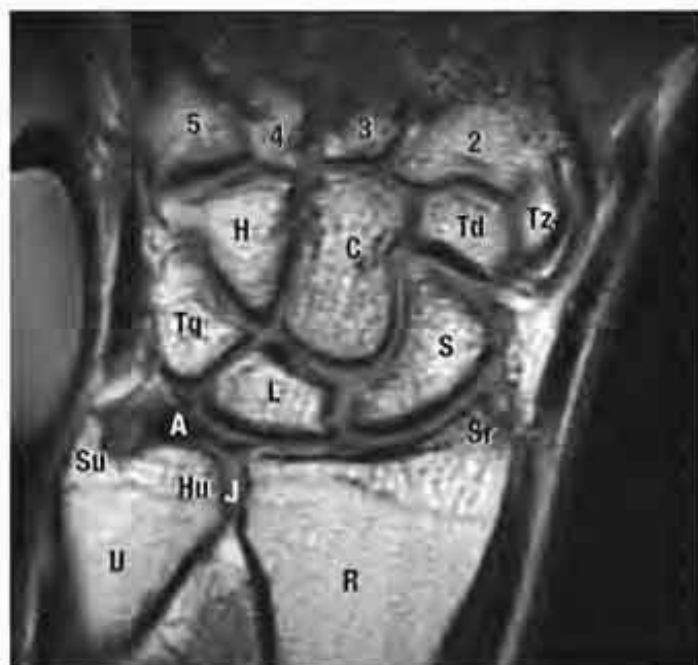
Part of "Chapter 6 - Upper Limb "

A. Schematic illustration. B. Coronal MRI. *A*, articular disc; *J*, distal radio-ulnar joint (letters correspond to structures labeled in A and Figure 6.81A ).

P.591



A



B

Authors: Agur, Anne M.R.; Dalley, Arthur F.

Title: *Grant's Atlas of Anatomy, 12th Edition*

Copyright ©2009 Lippincott Williams & Wilkins

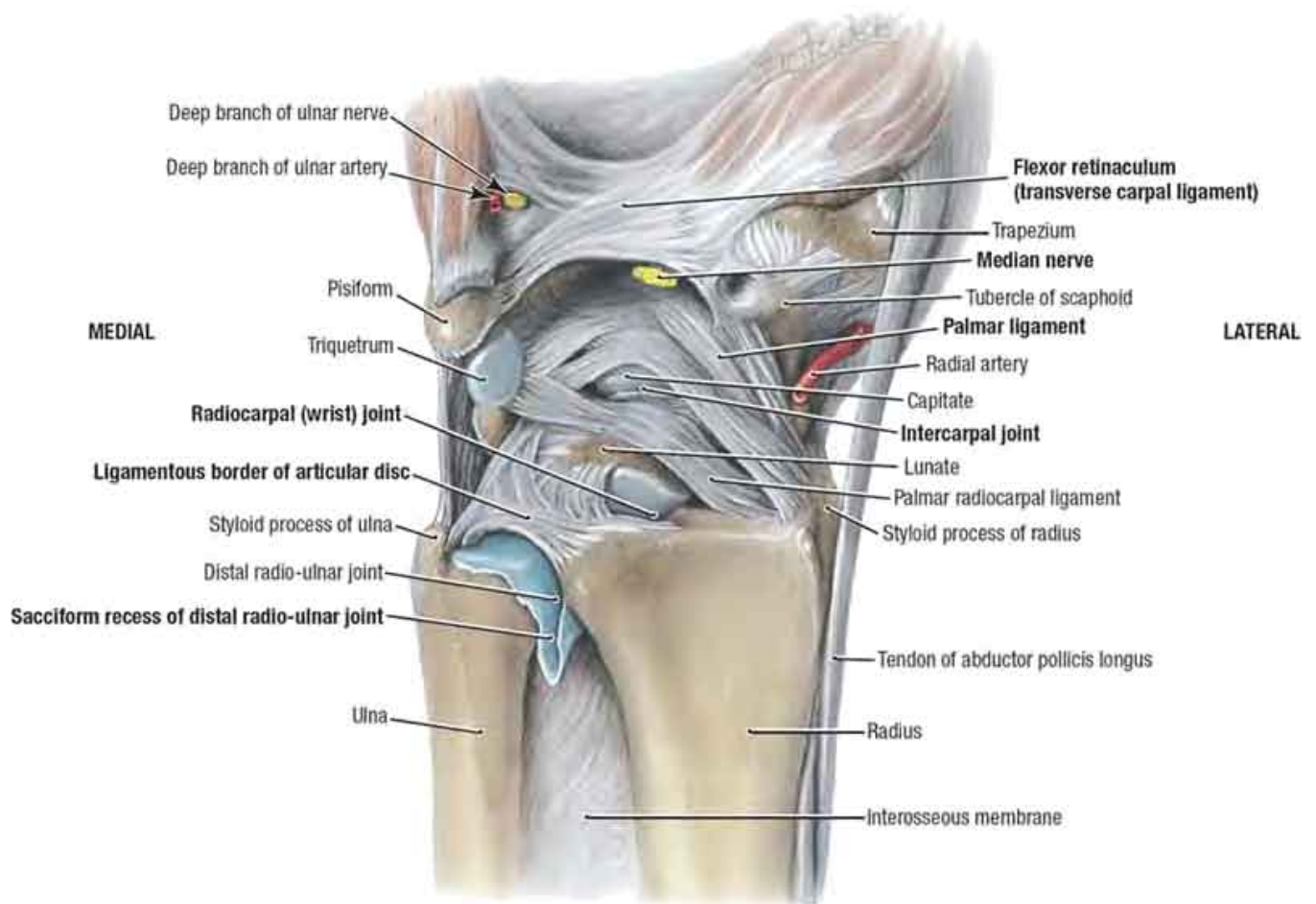
> Table of Contents > Chapter 6 - Upper Limb > 6.83 Ligaments of distal radio-ulnar, radiocarpal, and intercarpal joints

---

## 6.83 Ligaments of distal radio-ulnar, radiocarpal, and intercarpal joints

*Part of* "Chapter 6 - Upper Limb "

The hand is forcibly extended. Observe the palmar radiocarpal ligament passing from the radius to the two rows of carpal bones; they are strong and directed, so that the hand moves with the radius during supination.



**Anterior View**



Authors: Agur, Anne M.R.; Dalley, Arthur F.

Title: *Grant's Atlas of Anatomy, 12th Edition*

Copyright ©2009 Lippincott Williams & Wilkins

> Table of Contents > Chapter 6 - Upper Limb > 6.84 Radiocarpal (wrist) joint

---

## 6.84 Radiocarpal (wrist) joint

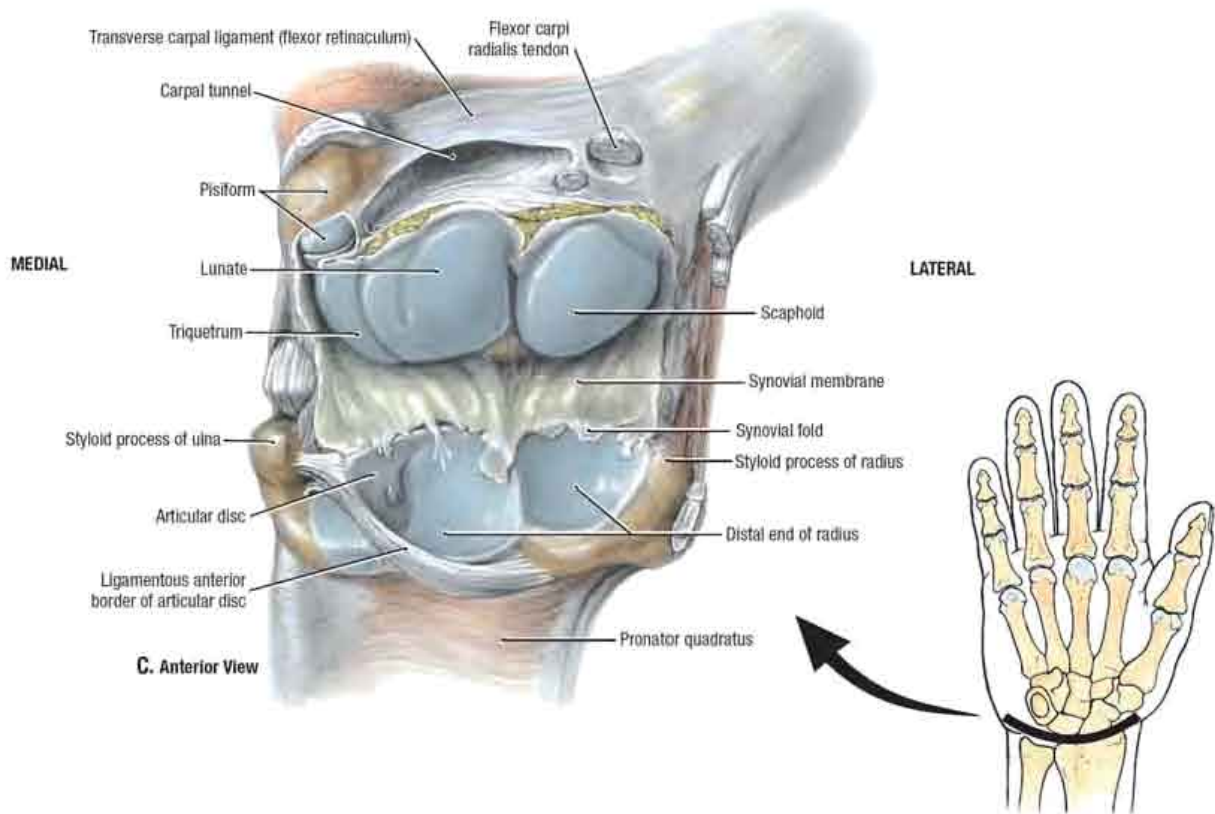
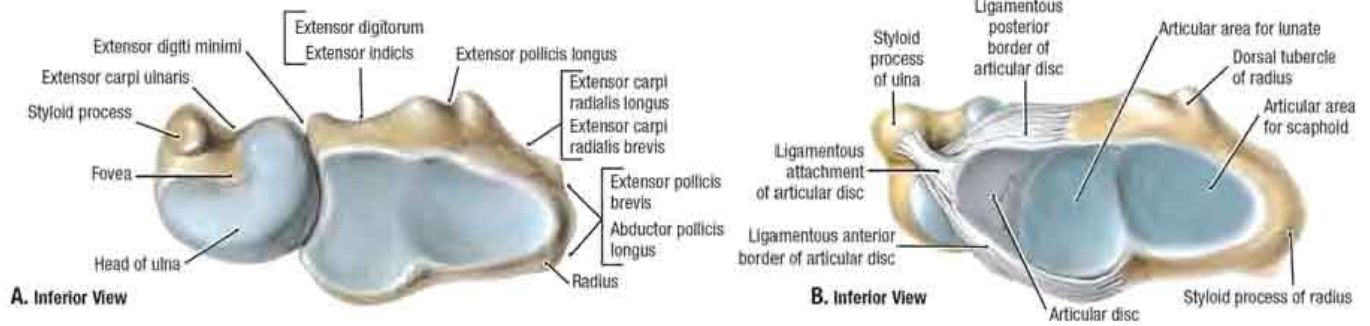
*Part of "Chapter 6 - Upper Limb "*

A. Distal ends of radius and ulna showing grooves for tendons on the posterior aspects. B. Articular disc. The articular disc unites the distal ends of the radius and ulna; it is fibrocartilaginous at the triangular area between the head of the ulna and the lunate bone, but ligamentous and pliable elsewhere.

The cartilaginous part commonly has a fissure or perforation, as shown here.

C. Articular surface of the radiocarpal joint, which is opened anteriorly. The lunate articulates with the radius and articular disc; only during adduction of the wrist does the triquetrum come into articulation with the disc.

The perforation in the disc and the associated roughened surface of the lunate are a common occurrence.



Authors: Agur, Anne M.R.; Dalley, Arthur F.

Title: *Grant's Atlas of Anatomy, 12th Edition*

Copyright ©2009 Lippincott Williams & Wilkins

> Table of Contents > Chapter 6 - Upper Limb > 6.85 Articular surfaces of midcarpal (transverse carpal) joint, opened anteriorly

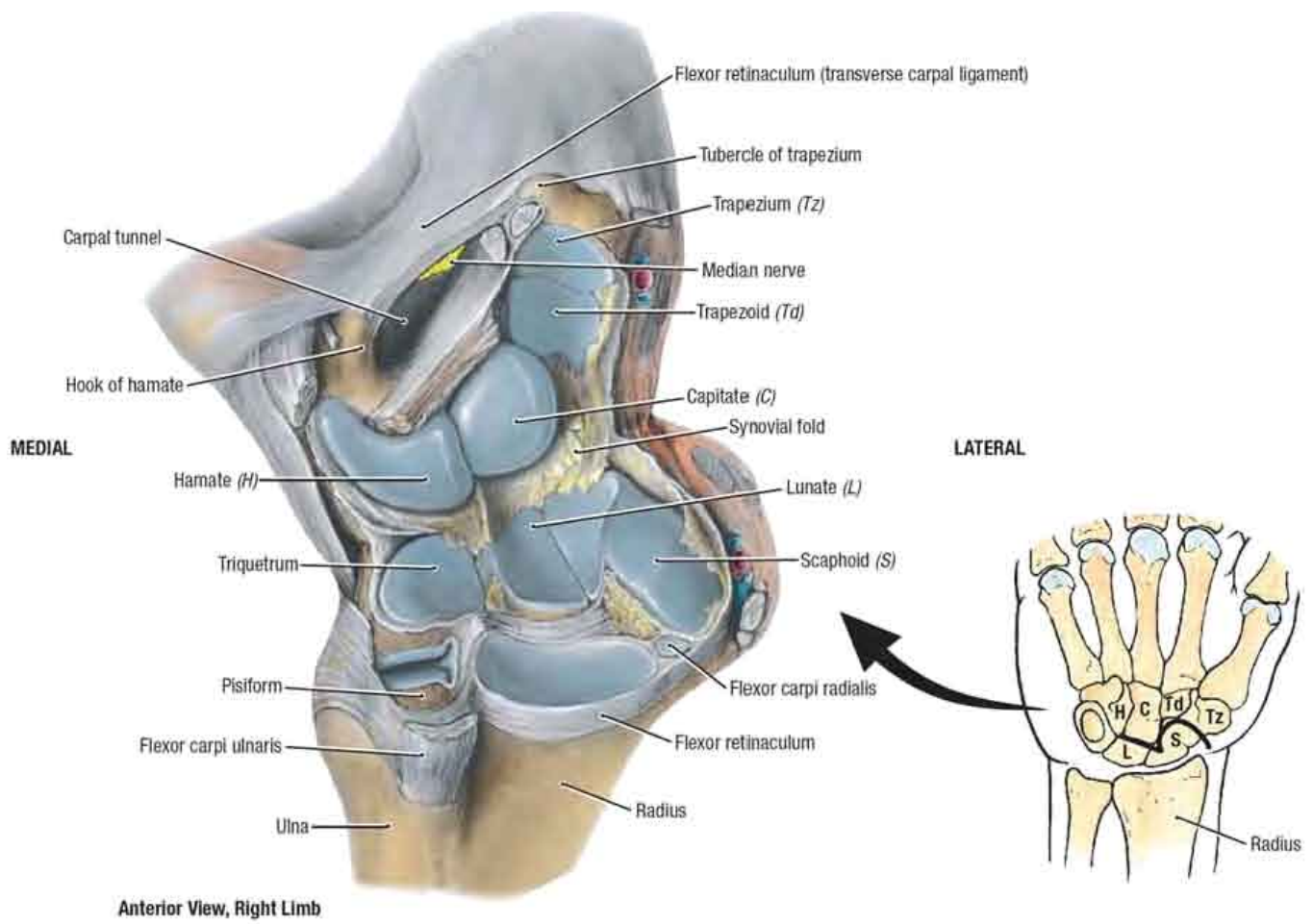
---

## 6.85 Articular surfaces of midcarpal (transverse carpal) joint, opened anteriorly

*Part of "Chapter 6 - Upper Limb "*

- The flexor retinaculum (transverse carpal ligament) is cut; the proximal part of the ligament, which spans from the pisiform to the scaphoid, is relatively weak; the distal part, which passes from the hook of the hamate to the tubercle of the trapezium, is strong.
- Observe the sinuous surfaces of the opposed bones: the trapezium and trapezoid together form a concave, oval surface for the scaphoid, and the capitate and hamate together form a convex surface for the scaphoid, lunate, and triquetrum.

Anterior dislocation of the lunate is a serious injury that usually results from a fall on the dorsiflexed wrist. The lunate is pushed to the palmar surface of the wrist and may compress the median nerve and lead to carpal tunnel syndrome. Because of poor blood supply, avascular necrosis of the lunate may occur.



Authors: Agur, Anne M.R.; Dalley, Arthur F.

Title: *Grant's Atlas of Anatomy, 12th Edition*

Copyright ©2009 Lippincott Williams & Wilkins

> Table of Contents > Chapter 6 - Upper Limb > 6.86 Carpal bones and bases of metacarpals

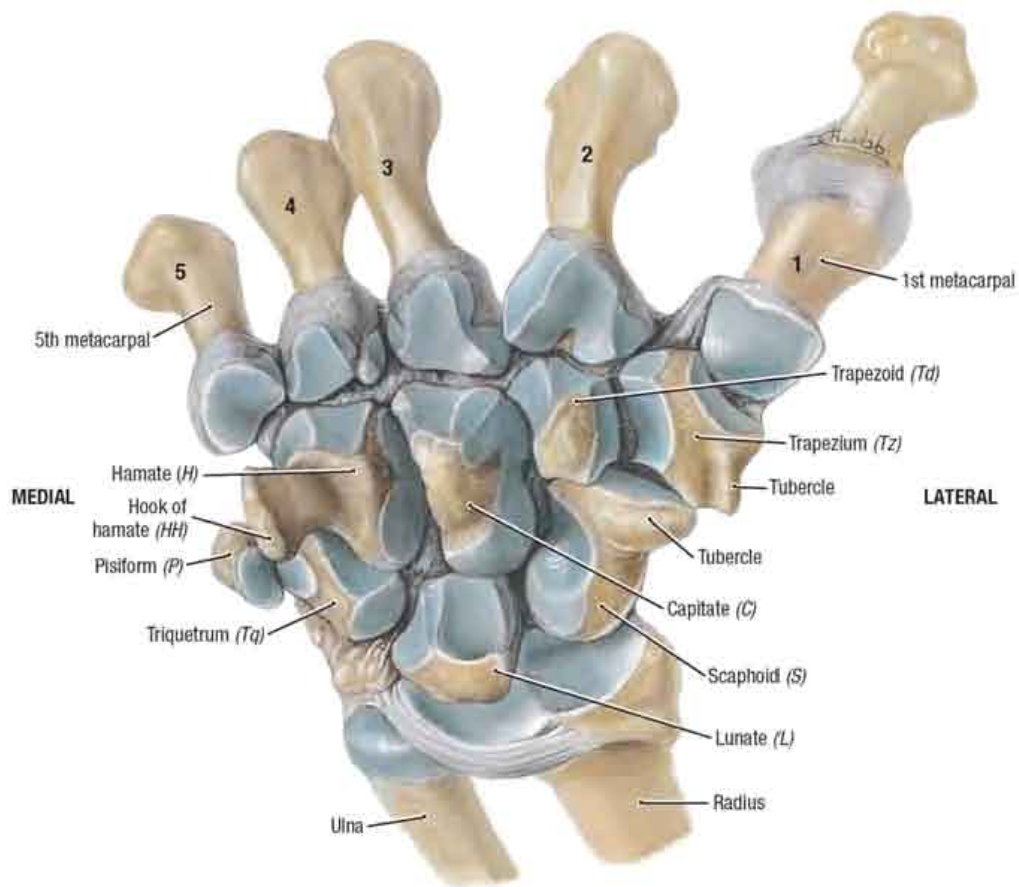
---

## 6.86 Carpal bones and bases of metacarpals

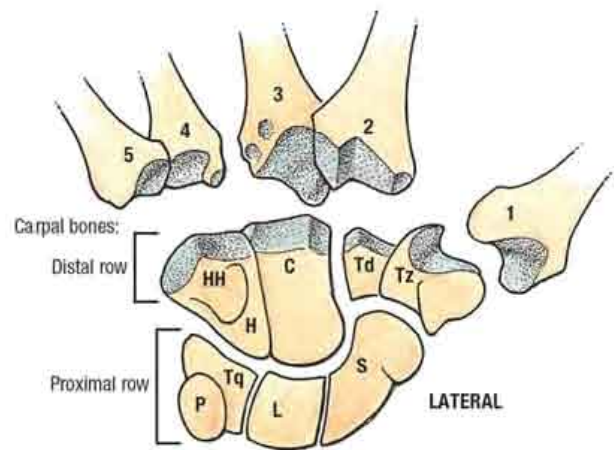
*Part of* "Chapter 6 - Upper Limb "

A. Open intercarpal and carpometacarpal joints. The dorsal ligaments remain intact, and all the joints have been hyperextended, permitting study of articular facets. B. Diagram of the articular surfaces of the carpometacarpal joints (*letters* refer to structures labeled in A ).

- The capitate articulates with three metacarpals (2nd, 3rd, and 4th).
- The 2nd metacarpal articulates with three carpals (trapezium, trapezoid, and capitate).
- The 2nd and 3rd carpometacarpal joints are practically immobile; the 1st is saddle-shaped, and the 4th and 5th are hinge-shaped synovial joints.



**A. Anterior View, Right Limb**



**B. Anterior View**



Authors: Agur, Anne M.R.; Dalley, Arthur F.

Title: *Grant's Atlas of Anatomy, 12th Edition*

Copyright ©2009 Lippincott Williams & Wilkins

> Table of Contents > Chapter 6 - Upper Limb > 6.87 Collateral ligaments of metacarpophalangeal and interphalangeal joints of third digit

---

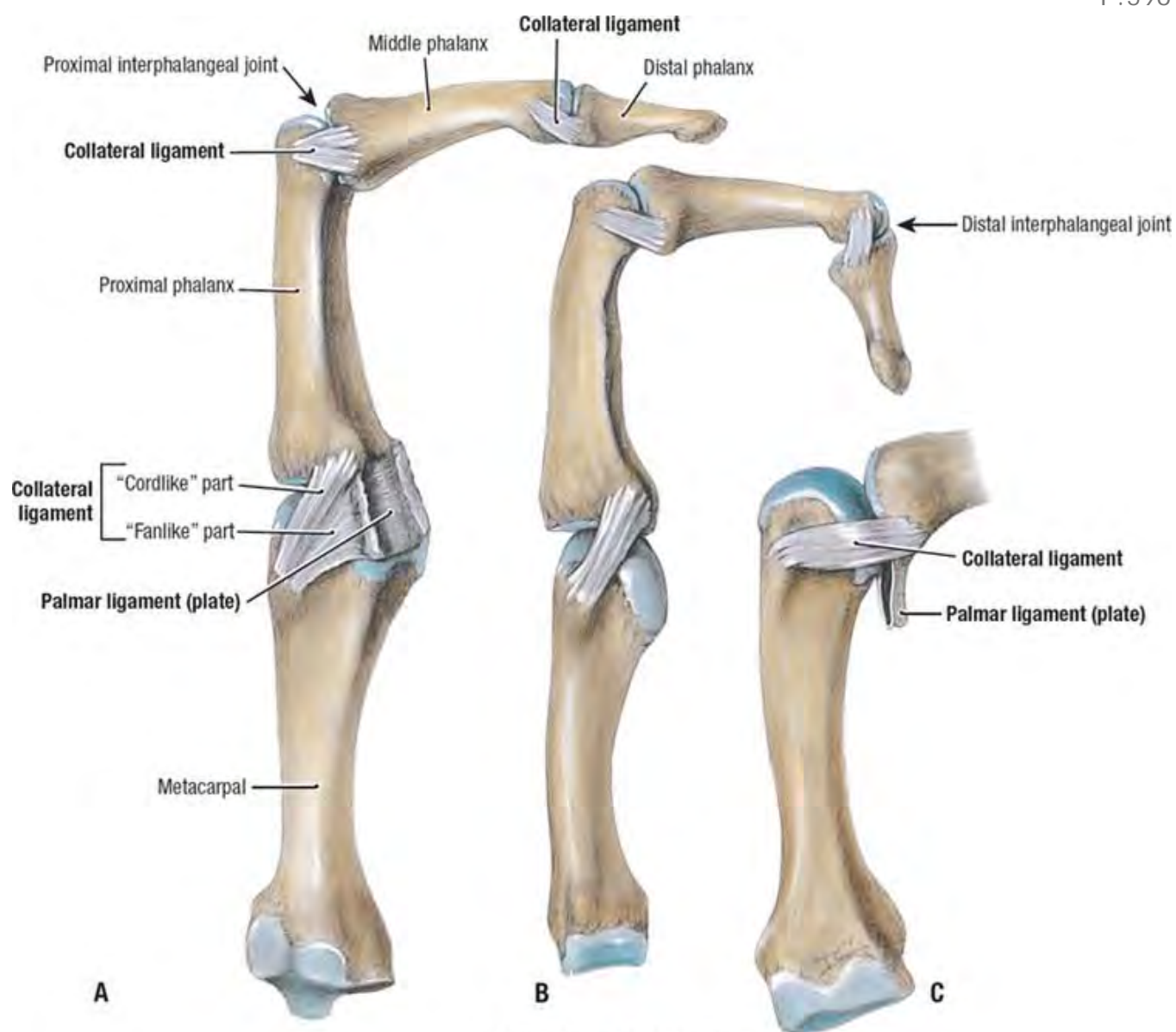
## 6.87 Collateral ligaments of metacarpophalangeal and interphalangeal joints of third digit

*Part of* "Chapter 6 - Upper Limb "

A. Extended metacarpophalangeal and distal interphalangeal joints. B. Flexed interphalangeal joints. C. Flexed metacarpophalangeal joint.

- A fibrocartilaginous plate, the palmar ligament, hangs from the base of the proximal phalanx; is fixed to the head of the metacarpal by the weaker, fanlike part of the collateral ligament (A ); and moves like a visor across the metacarpal head (C ).
- The extremely strong, cordlike parts of the collateral ligaments of this joint (A and B ) are eccentrically attached to the metacarpal heads; they are slack during extension and taut during flexion (C ), so the fingers cannot be spread (abducted) unless the hand is open; the interphalangeal joints have similar ligaments.

Skier's thumb refers to the rupture or chronic laxity of the collateral ligament of the 1st metacarpophalangeal joint. The injury results from hyperextension of the joint, which occurs when the thumb is held by the ski pole while the rest of the hand hits the ground or enters the snow.



Lateral Views of Right 3rd Digit

## 6.88 Grasp, pinch, and movements of the thumb

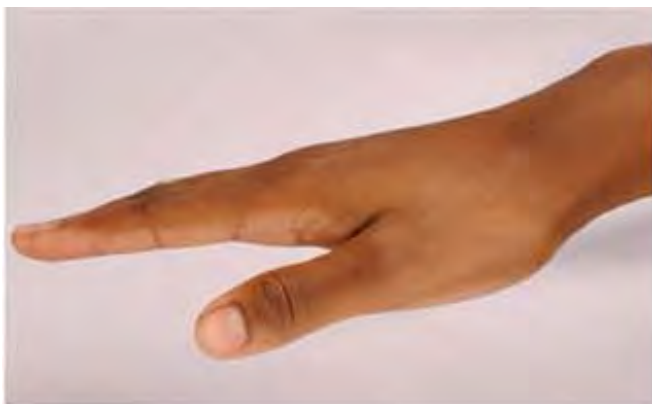*Part of "Chapter 6 - Upper Limb "*

A. The extended hand. B. Cylindrical (power) grasp. When grasping an object, the metacarpophalangeal and interphalangeal joints are flexed, but the radiocarpal joints are extended. Without wrist extension the grip is weak and insecure. C. Loose cylindrical grasp. Firm cylindrical (power) grasp. The heads of the 4th and 5th metacarpals have moved in a palmar direction. E. Centralized (power) grasp. F. Disc (power) grasp.

P.597

G. Hook grasp. This grasp involves primarily the long flexors of the fingers, which are flexed varying degree depending on the size of the object. H. Fingertip pinch. I. Tripod (three-jaw chuck) pinch. J. Positions of the thumb.

P.598



A



B





C



D



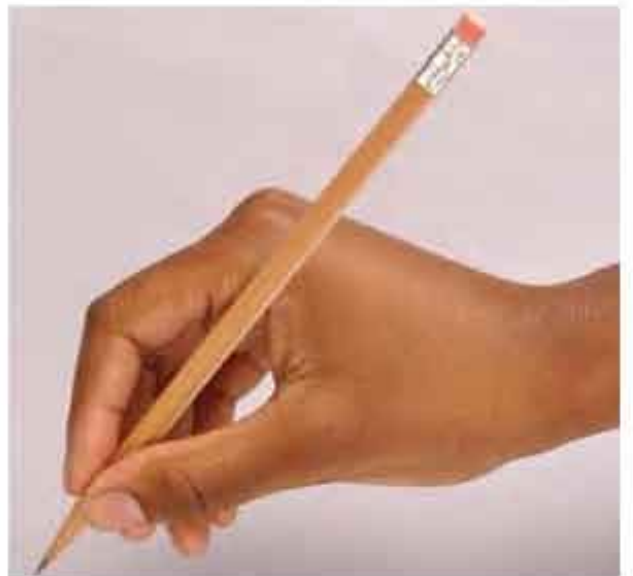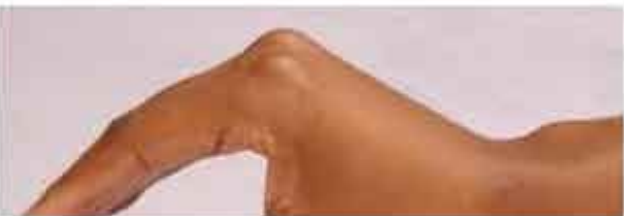E

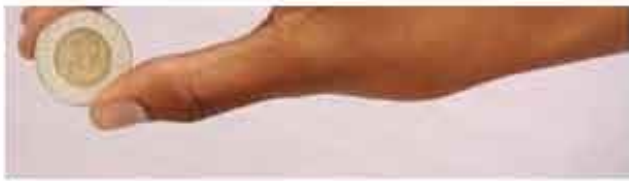

F



G

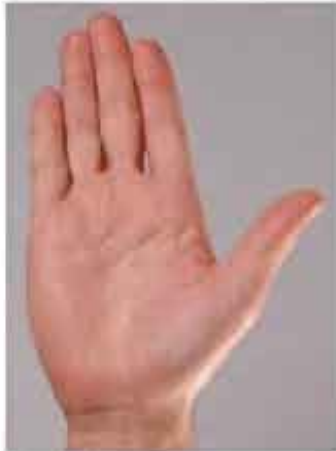



H



I



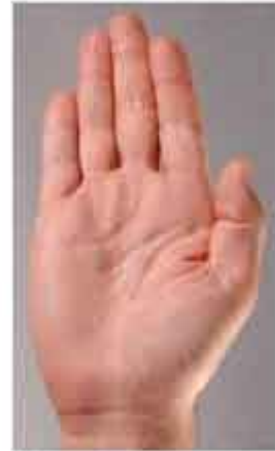Extended



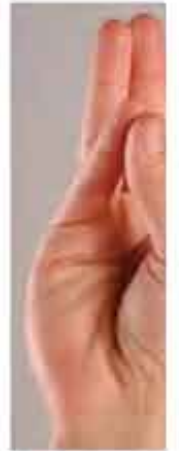Flexed



Abducted



Adducted



Opposed to little f

J

Authors: Agur, Anne M.R.; Dalley, Arthur F.

Title: *Grant's Atlas of Anatomy, 12th Edition*

Copyright ©2009 Lippincott Williams & Wilkins

> Table of Contents > Chapter 6 - Upper Limb > 6.89 Ossification and sites of epiphyses of bones of upper limb

---

## 6.89 Ossification and sites of epiphyses of bones of upper limb

*Part of* "Chapter 6 - Upper Limb "

A. Upper limb bones at birth. Only the diaphyses of the long bones and scapula are ossified. The epiphyses, carpal bones, coracoid process, medial border of the scapula, and acromion are still cartilaginous. I. Sites of epiphyses (*darker orange regions*).

- The ends of the long bones are ossified by the formation of one or more secondary centers of ossification; these epiphyses develop from birth to approximately 20 years of age in the clavicle, humerus, radius, ulna, metacarpals, and phalanges.

Without knowledge of bone growth and the appearance of bones in radiographic and other diagnostic images at various ages, a displaced epiphysial plate could be mistaken for a fracture, and separation of an epiphysis could be interpreted as a displaced piece of fractured bone. Knowledge of the patient's age and the location of epiphyses can prevent these errors.

---

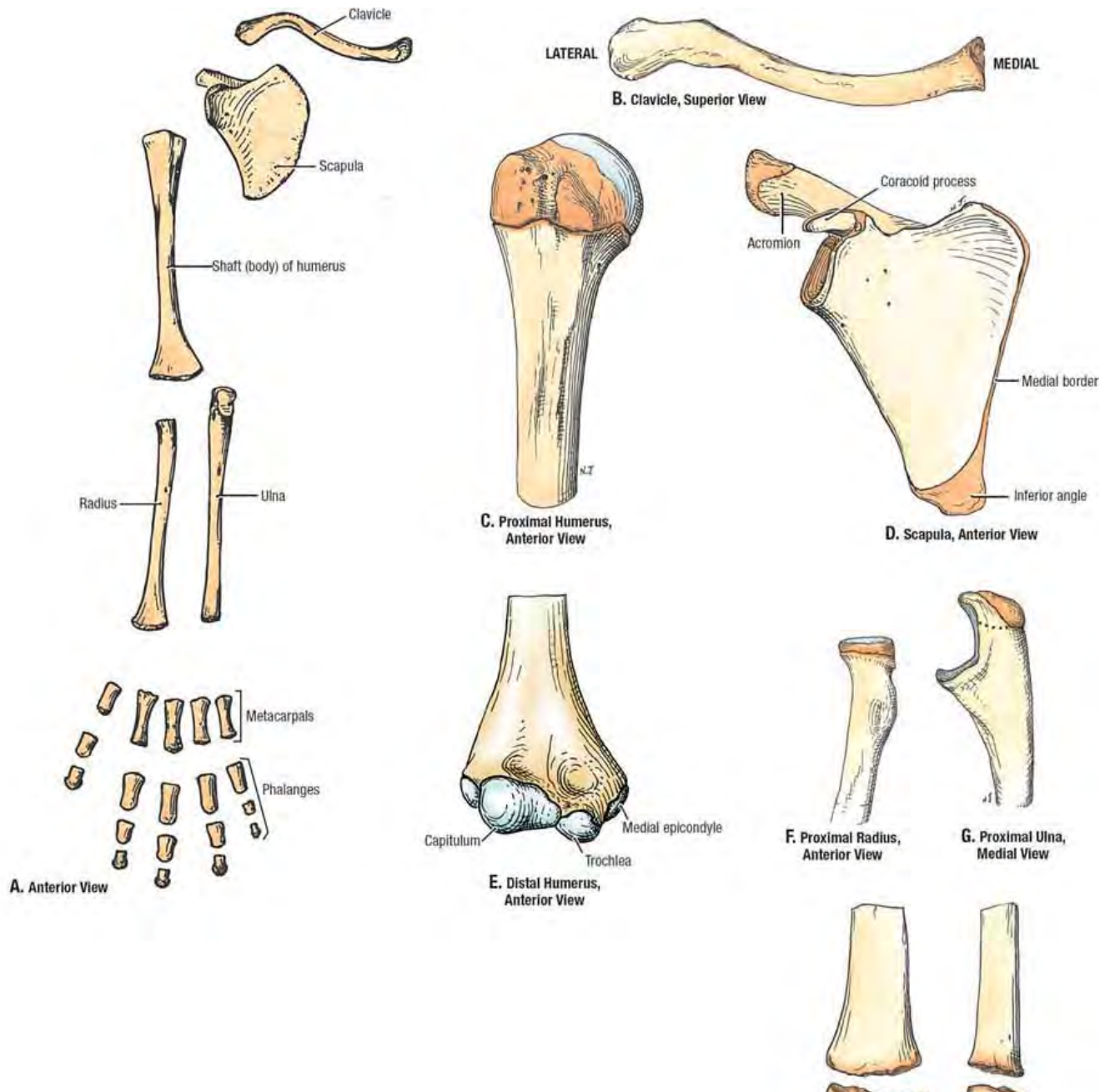
P.599

J. Sequence of ossification of carpal bones. K. Ossification of bones of hand. Note the phalanges have a single proximal epiphysis and metacarpals 2, 3, 4, and 5 have single distal epiphyses. The 1st metacarpal behaves as a phalanx by having proximal epiphysis.



Short-lived epiphyses may appear at the other ends of metacarpals 1 and/or 2. There are individual and gender differences in sequence and timing of ossification. *L.* Radiographs of stages of ossification of wrist and hand. *Top*, a 21-month-old child; the lunate is ossifying, and the distal radial epiphysis (*R*) is present (*C*, capitate; *H*, hamate; *Tq*, triquetrum; *L*, lunate). *Bottom*, an 11-year-old child. All carpal bones are ossified (*S*, scaphoid; *Td*, trapezoid; *Tz*, trapezium; *arrowhead*, pisiform), and the distal epiphysis of the ulna (*U*) has ossified.

P.600

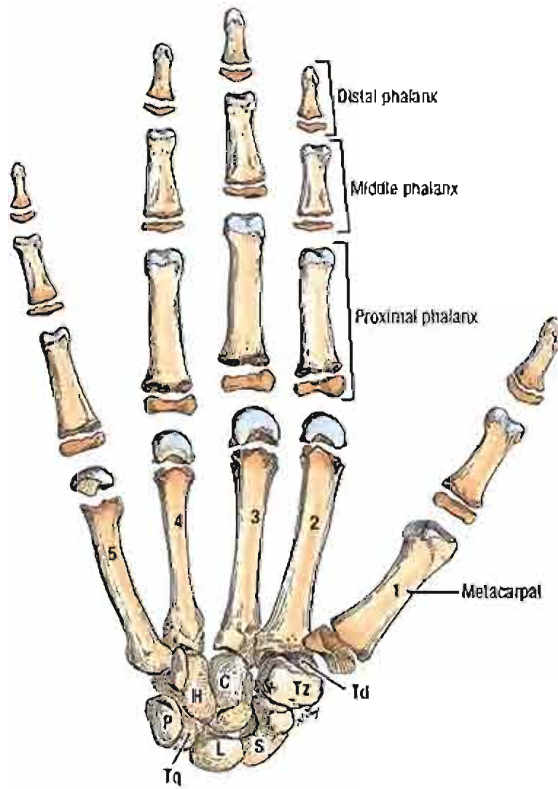




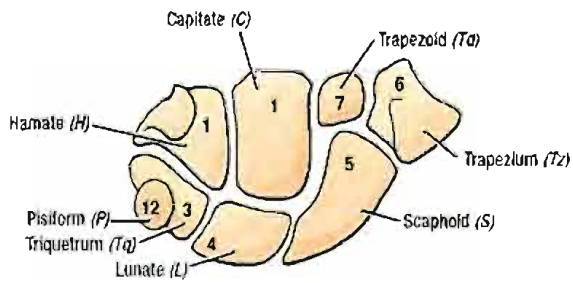
H. Distal Radius,  
Anterior View



I. Distal Ulna,  
Anterior View

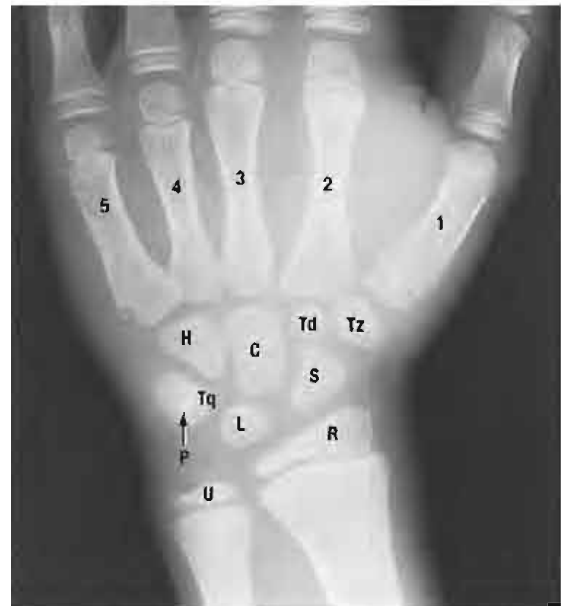
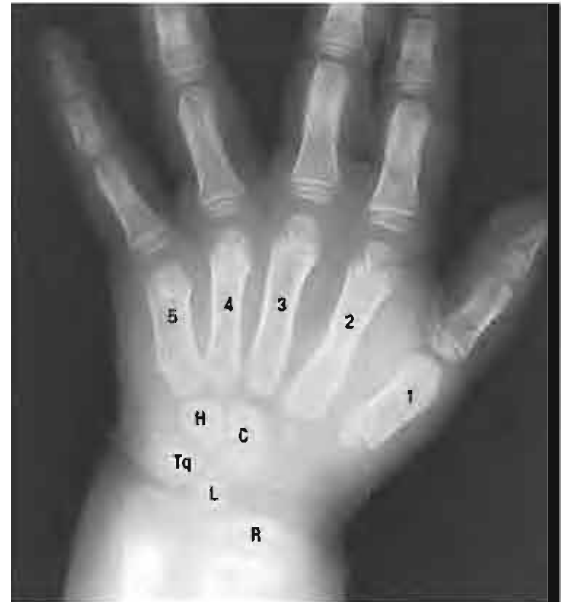
J. Anterior View (Right Hand)



Numbers: approximate age of ossification of carpal bones in years

K. Anterior View



L. Anteroposterior View, Right Hand

Epiphyses in radiographs appear as radiolucent lines

Authors: Agur, Anne M.R.; Dalley, Arthur F.

Title: *Grant's Atlas of Anatomy, 12th Edition*

Copyright ©2009 Lippincott Williams & Wilkins

> Table of Contents > Chapter 6 - Upper Limb > 6.90 Transverse section and transverse (axial)  
MRIs of the arm

---

## 6.90 Transverse section and transverse (axial) MRIs of the arm

*Part of* "Chapter 6 - Upper Limb "

A. Transverse section through arm.

- The body (shaft) of the humerus is nearly circular, and its cortex is thickest at this level.
- Three heads (lateral, medial, and long) of the triceps muscle occupy the posterior compartment of the arm.
- The radial nerve and deep artery and veins of arm lie in contact with the radial groove of the humerus.
- The musculocutaneous nerve lies in the plane between the biceps and brachialis muscles.
- The median nerve crosses to the medial side of the brachial artery and veins, the ulnar nerve passes posteriorly onto the medial side of the triceps muscle, and the basilic vein (appearing here as two vessels) has pierced the deep fascia.

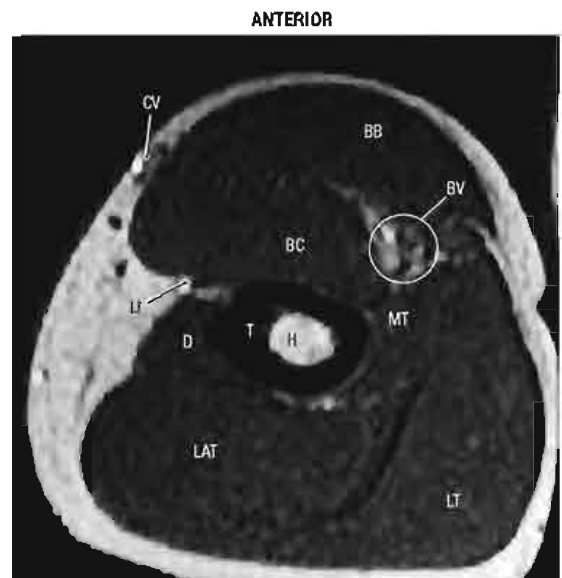
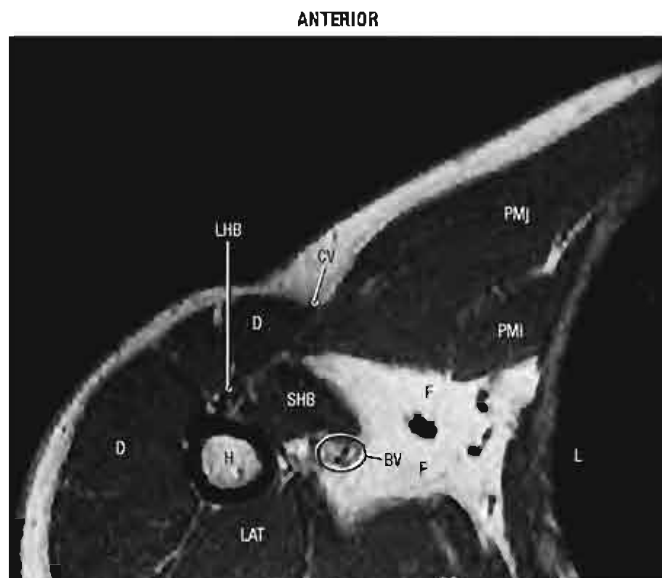
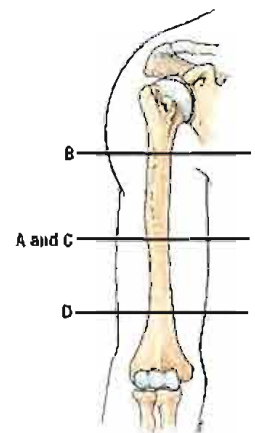
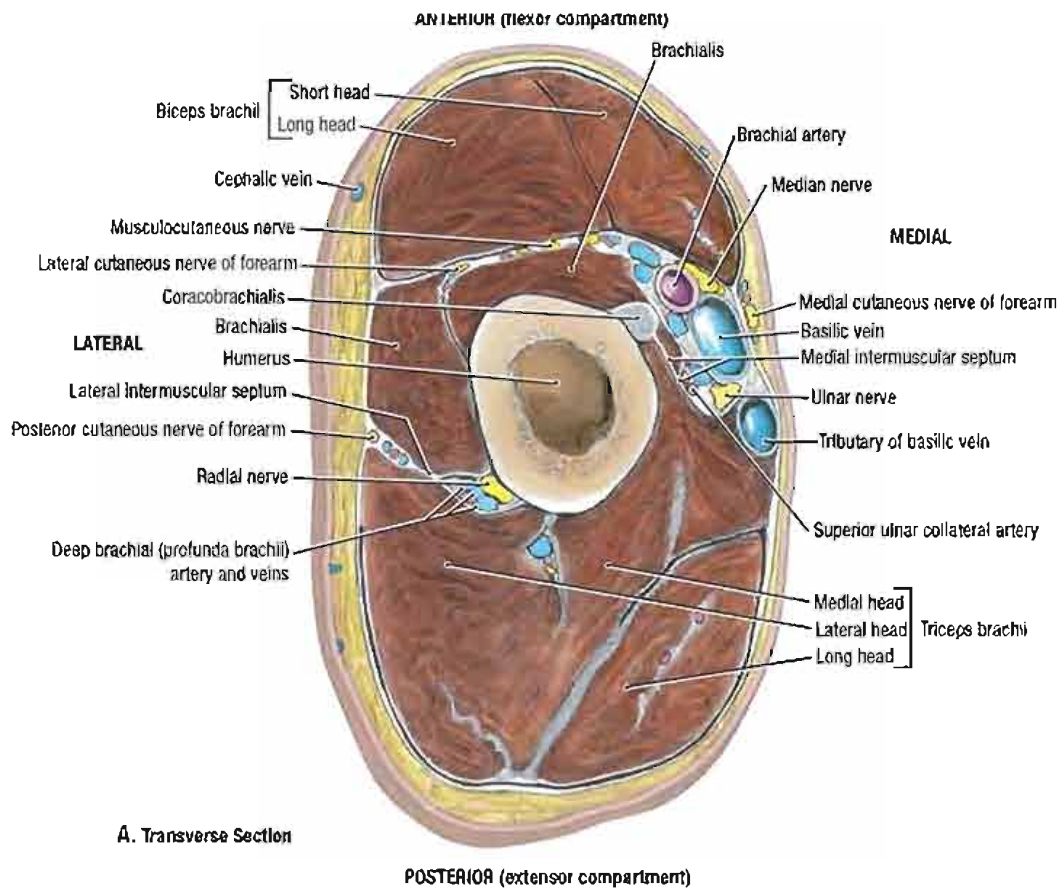
---

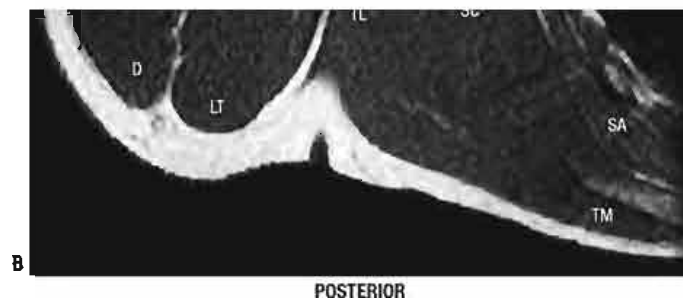P.601

B. Transverse MRI through the proximal arm. C. Transverse MRI through the middle of the arm. D. Transverse MRI through the distal arm.

---

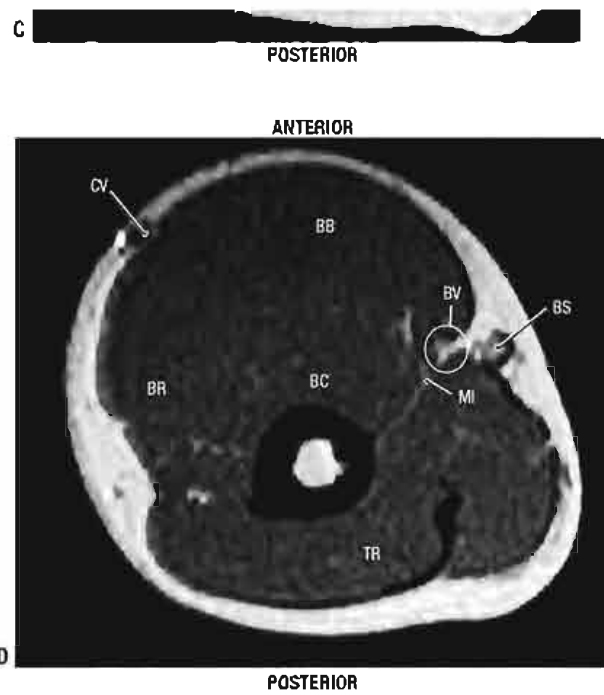
P.602





**Key for B, E, and D:**

BB	Biceps brachii	LI	Long head of triceps brachii
BC	Brachialis	MI	Medial intermuscular septum
BR	Brachioradialis	MT	Medial head of triceps brachii
BS	Basilic vein	PMI	Pectoralis minor
BV	Brachial vessels and nerves	PMJ	Pectoralis major
CV	Cephalic vein	SA	Serratus anterior
D	Deltoid	SC	Subscapularis
F	Fat in axilla	SHB	Short head of biceps brachii
H	Humerus	T	Deltoid tuberosity
L	Lung	TL	Teres major and latissimus dorsi
LAT	Lateral head of triceps brachii	TM	Teres minor
LHB	Long head of biceps brachii	TR	Triceps brachii
LI	Lateral intermuscular septum		





## 6.91 Transverse sections and transverse (axial) MRIs of forearm

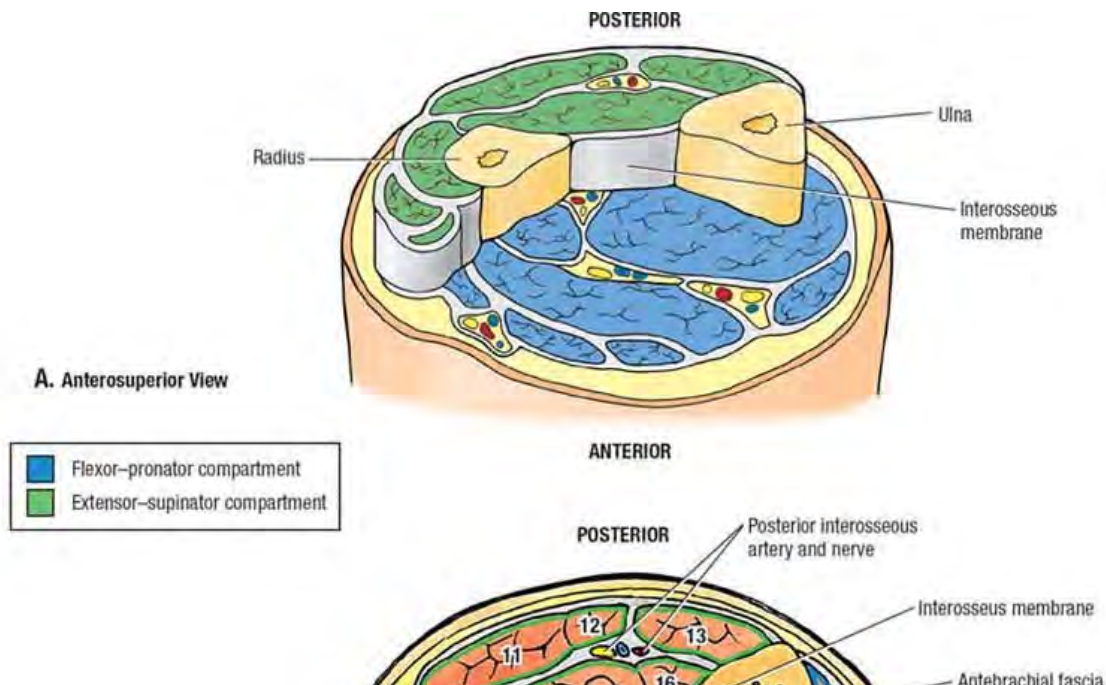
Part of "Chapter 6 - Upper Limb "

A. Stepped transverse sections of the anterior and posterior compartments. B. Contents of the anterior and posterior compartments.

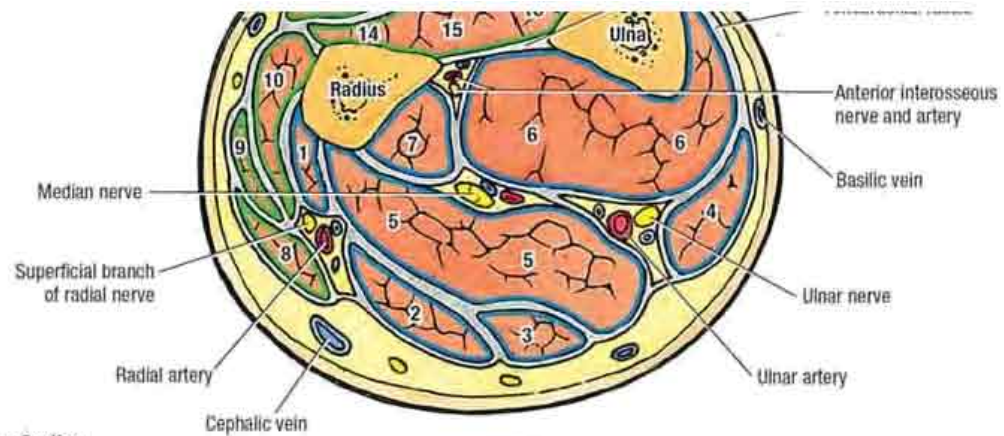
P.603

C. Transverse MRI through the proximal forearm. D. Transverse MRI through the middle forearm. E. Transverse MRI through the distal forearm.

P.604

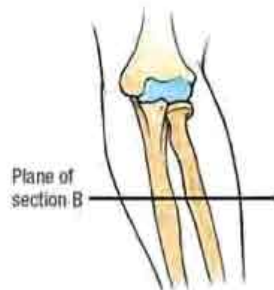






**B. Transverse Section**

ANTERIOR

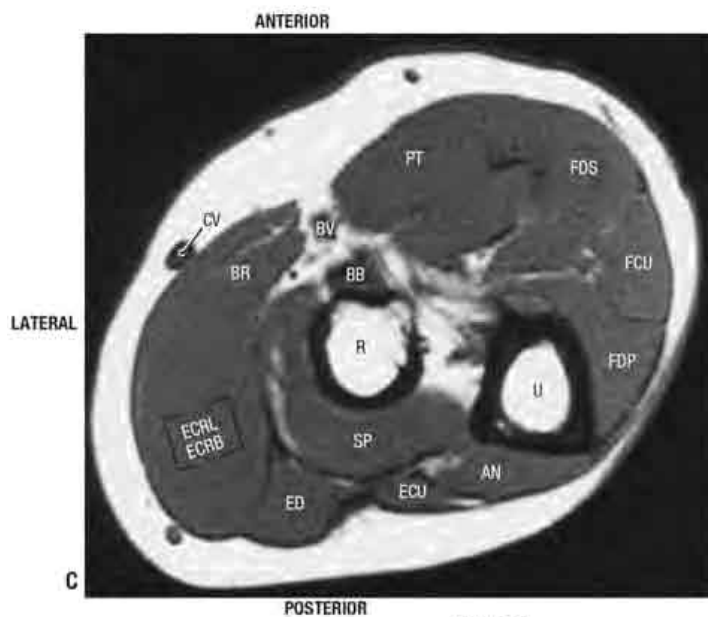


**Flexors:**

- 1 Pronator teres
- 2 Flexor carpi radialis
- 3 Palmaris longus
- 4 Flexor carpi ulnaris
- 5 Flexor digitorum superficialis
- 6 Flexor digitorum profundus
- 7 Flexor pollicis longus

**Extensors:**

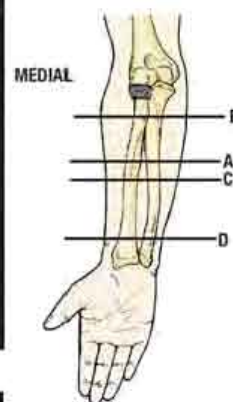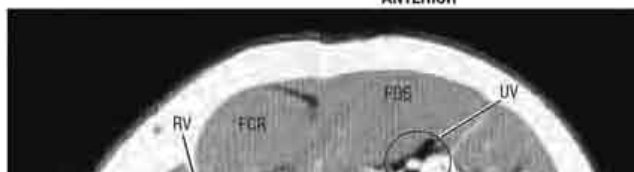- 8 Brachioradialis
- 9 Extensor carpi radialis longus
- 10 Extensor carpi radialis brevis
- 11 Extensor digitorum
- 12 Extensor digiti minimi
- 13 Extensor carpi ulnaris
- 14 Abductor pollicis longus
- 15 Extensor pollicis brevis
- 16 Extensor pollicis longus and extensor indicis



C

POSTERIOR

ANTERIOR



MEDIAL

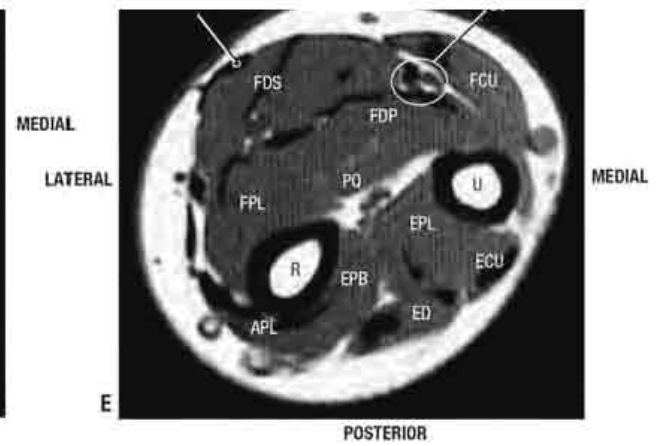
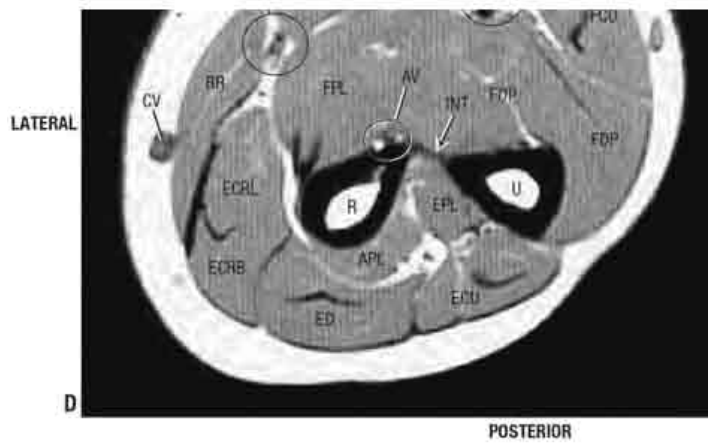
**Key for C, D, and E:**

- |      |   |
|------|---|
| AN   | Anconeus                                |
| APL  | Abductor pollicis longus                |
| AV   | Anterior interosseous vessels and nerve |
| BB   | Biceps brachii                          |
| BR   | Brachioradialis                         |
| BV   | Brachial vessels                        |
| CV   | Cephalic vein                           |
| ECRB | Extensor carpi radialis brevis          |
| ECRL | Extensor carpi radialis longus          |
| ECU  | Extensor carpi ulnaris                  |
| ED   | Extensor digitorum                      |
| EPB  | Extensor pollicis brevis                |
| EPL  | Extensor pollicis longus                |
| FCR  | Flexor carpi radialis                   |
| FCU  | Flexor carpi ulnaris                    |
| FDP  | Flexor digitorum profundus              |
| FDS  | Flexor digitorum superficialis          |
| FPL  | Flexor pollicis longus                  |
| INT  | Interosseous membrane                   |
| PQ   | Pronator quadratus                      |
| PT   | Pronator teres                          |
| R    | Radius                                  |
| RV   | Radial vessels                          |
| SP   | Supinator                               |
| U    | Ulna                                    |
| UN   | Ulnar vessels and nerve                 |

ANTERIOR

FCR

UV



## 6.92 Transverse (axial) section and MRIs through carpal tunnel

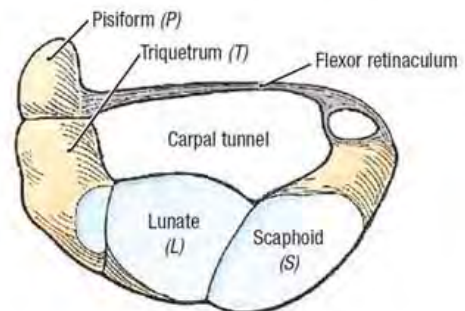
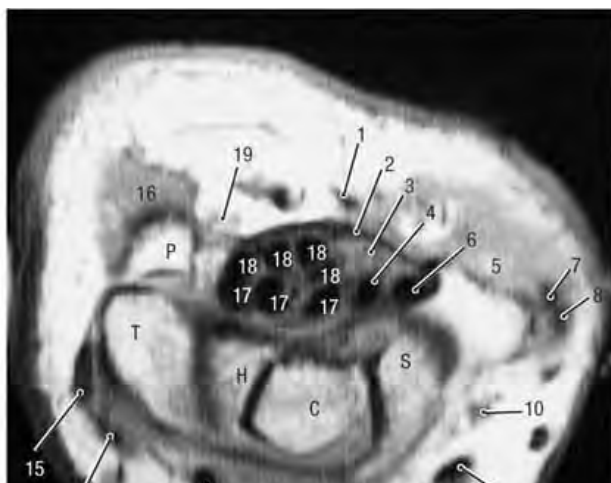
Part of "Chapter 6 - Upper Limb "

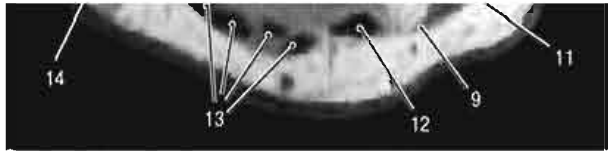
A. Transverse MRI through the proximal carpal tunnel (*numbers and letters in MRIs refer to structures in D*). B. Coronal MRI of wrist and hand showing the course of the long flexor tendons in the carpal tunnel (*numbers and letters in MRIs refer to structures in D*). *FT*, long flexor tendons in carpal tunnel; *TH*, thenar muscles; *P*, pisiform; *H*, hook of hamate; *Tm*, trapezium; *I*, interossei, *A&E*, proximal phalanges.

P.605

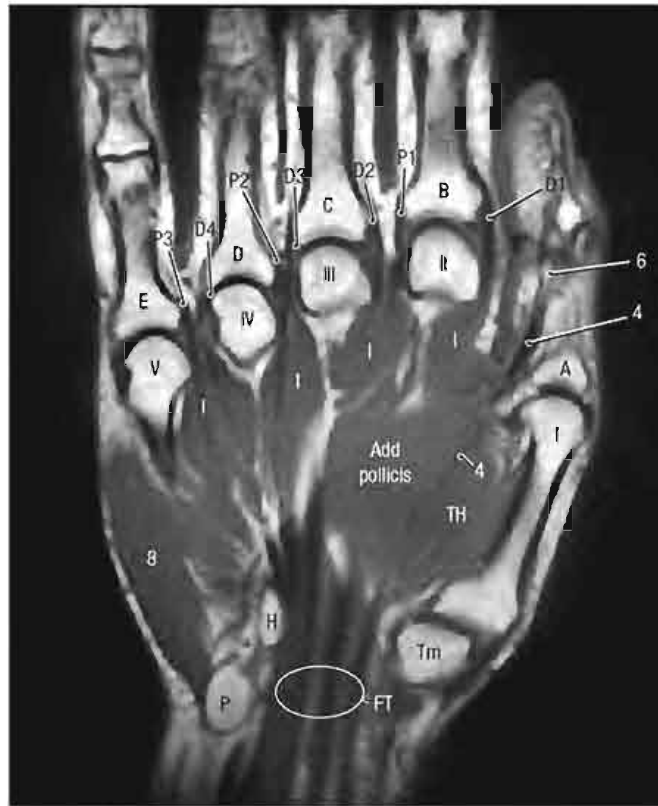C. Transverse MRI through the distal carpal tunnel (*numbers and letters in MRIs refer to structures in D*). D. Transverse section of carpal tunnel through the distal row of carpal bones.

P.606

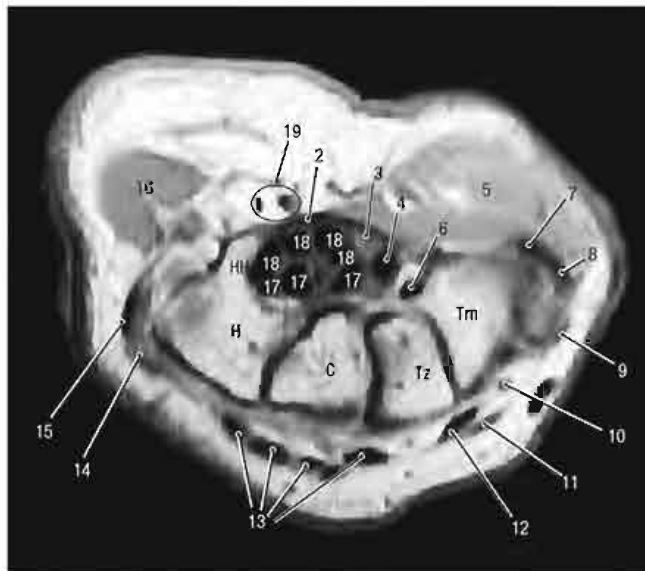
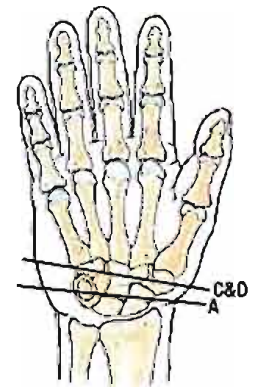




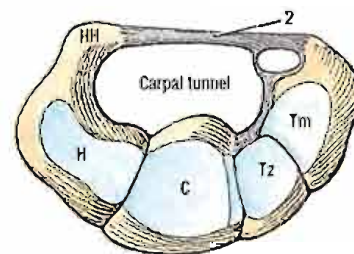
A. Transverse MRI

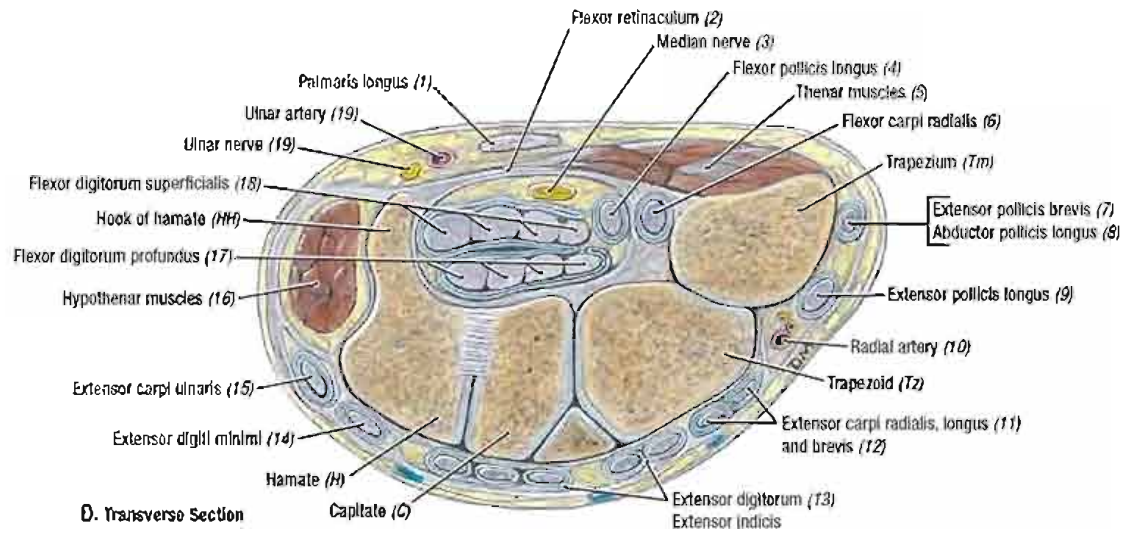


B. Coronal MRI



C. Transverse MRI





Authors: Agur, Anne M.R.; Dalley, Arthur F.

Title: *Grant's Atlas of Anatomy, 12th Edition*

Copyright ©2009 Lippincott Williams & Wilkins

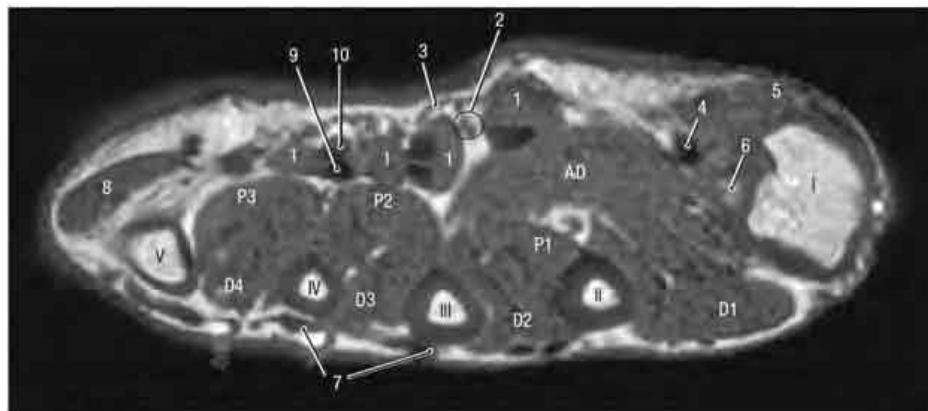
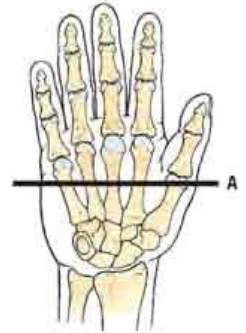
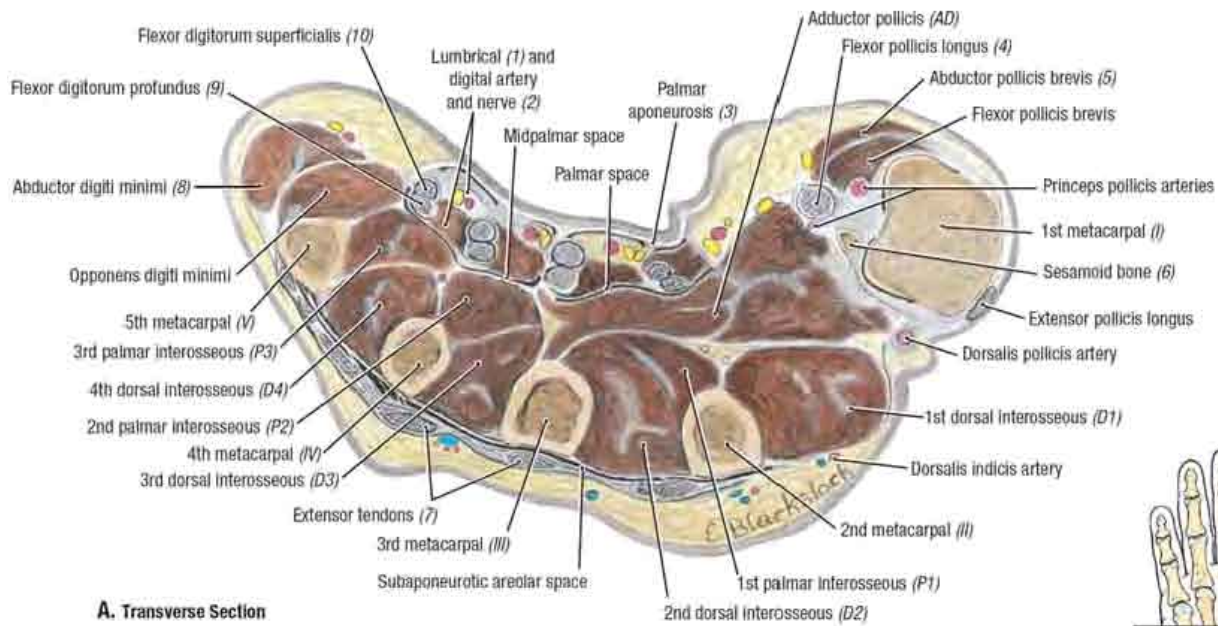
> Table of Contents > Chapter 6 - Upper Limb > 6.93 Transverse section and MRI through palm (metacarpals) at level of adductor pollicis

---

## 6.93 Transverse section and MRI through palm (metacarpals) at level of adductor pollicis

*Part of "Chapter 6 - Upper Limb "*





**B. Transverse MRI**

Authors: Agur, Anne M.R.; Dalley, Arthur F.

Title: *Grant's Atlas of Anatomy, 12th Edition*

Copyright ©2009 Lippincott Williams & Wilkins

> Table of Contents > Chapter 7 - Head > Chapter 7 - Head

---

# Chapter 7

## Head

---

P.608

- 7.1 Cranium at birth and in early childhood
- 7.2 Cranium, facial (frontal) aspect
- 7.3 Cranium, lateral aspect
- 7.4 Cranium, occipital aspect, calvaria, and anterior part of posterior cranial fossa
- 7.5 Cranium, inferior aspect
- 7.6 Interior of the cranial base
- 7.7 Radiographs of the cranium
- 7.8 Superficial bones of facial skeleton
- 7.9 Deep bones of facial skeleton
- 7.10 Sphenoid bone
- 7.11 Temporal bone
- 7.12 Muscles of facial expression and arteries of the face
- 7.13 Relationships of the branches of the facial nerve and vessels to the parotid gland and duct
- 7.14 Muscles of facial expression

- 7.15 Cutaneous branches of trigeminal nerve, muscles of facial expression, and eyelid
- 7.16 Branches of facial nerve, muscles of facial expression, and scalp
- 7.17 Middle meningeal artery and pterion
- 7.18 Layers of the scalp and meninges
- 7.19 Dura mater and arachnoid granulations
- 7.20 Dura mater
- 7.21 Venous sinuses of the dura mater
- 7.22 Nerves and vessels of the interior of the base of the cranium
- 7.23 Base of brain and superficial origins of cranial nerves
- 7.24 Posterior exposures of cranial nerves
- 7.25 Tentorial notch
- 7.26 Nerves and vessels of middle cranial fossaâ€”I
- 7.27 Nerves and vessels of middle cranial fossaâ€”II
- 7.28 Base of brain and cerebral arterial circle
- 7.29 Arteriograms
- 7.30 Blood supply of head and neck
- 7.31 Orbital cavity and surface anatomy of the eye
- 7.32 Eye and lacrimal apparatus
- 7.33 Orbital cavity, superior approach
- 7.34 Lateral aspect of the orbit and structure of the eyelid
- 7.35 Lateral aspect of the orbit and structure of the eyelid
- 7.36 Nerves and veins of the orbit
- 7.37 Illustration of a dissected eyeball
- 7.38 Ocular fundus and blood supply to the eyeball

- 7.39 Parotid region
- 7.40 Temporal and infratemporal fossa and mandible
- 7.41 Temporalis and masseter
- 7.42 Infratemporal region
- 7.43 Branches of maxillary artery
- 7.44 Branches of maxillary and mandibular nerves
- 7.45 Temporomandibular joint
- 7.46 Sectional anatomy of temporomandibular joint (TMJ)
- 7.47 Tongue
- 7.48 Sections through mouth
- 7.49 Tongue and floor of mouth
- 7.50 Arteries and nerves of the tongue
- 7.51 Muscles, glands, and vessels of floor of mouth and medial aspect of mandible
- 7.52 Palate
- 7.53 Permanent teethâ€”I
- 7.54 Permanent teethâ€”II
- 7.55 Innervation of teeth
- 7.56 Primary teeth
- 7.57 Surface anatomy, cartilages, and bones of nose
- 7.58 Bones of the lateral wall and septum of the nose
- 7.59 Innervation of lateral wall and septum of the nose
- 7.60 Arteries of lateral wall and septum of the nose
- 7.61 Right half of hemisected head demonstrating upper respiratory tract
- 7.62 Communications through the lateral wall of the nasal cavity

- 7.63 Paranasal sinuses, openings, and palatine muscles in the lateral wall of the nasal cavity
- 7.64 Paranasal sinuses and nasal cavity
- 7.65 Paranasal sinuses
- 7.66 Pterygopalatine fossa, orbital approach
- 7.67 Nerves of the pterygopalatine fossa
- 7.68 Auricle
- 7.69 External, middle, and internal ear – I: overviews
- 7.70 External, middle, and internal ear – II: coronally sectioned
- 7.71 Tympanic membrane
- 7.72 Ossicles of the middle ear
- 7.73 Structures of the tympanic cavity
- 7.74 Middle and inner ear in situ
- 7.75 Right tympanic cavity and pharyngotympanic tube
- 7.76 Right tympanic cavity and pharyngotympanic tube
- 7.77 Bony and membranous labyrinths
- 7.78 Vestibulocochlear nerve and structure of cochlea
- 7.79 Lymphatic and venous drainage of the head and neck
- 7.80 Autonomic innervation of the head
- 7.81 Coronal section and MRI imaging of nasopharynx and oral cavity
- 7.82 Transverse section and MRI imaging of nasal cavity and nasopharynx
- 7.83 MRIs of oropharynx
- 7.84 Brain
- 7.85 Ventricular system
- 7.86 Serial dissections of the lateral aspect of the cerebral hemisphere

- 7.87 Serial dissections of the medial aspect of cerebral hemisphere
- 7.88 Caudate and lentiform nuclei
- 7.89 Axial sections through the thalamus, caudate nucleus, and lentiform nucleus
- 7.90 Axial (transverse) MRIs through the cerebral hemispheres
- 7.91 Brainstem
- 7.92 Cerebellum
- 7.93 Serial dissections of the cerebellum
- 7.94 Axial (transverse) MRIs through the brainstem, inferior views
- 7.95 Coronal MRIs (T2 weighted) and sections of brain
- 7.96 Sagittal MRIs (T1 weighted) and median section of brain



Authors: Agur, Anne M.R.; Dalley, Arthur F.

Title: *Grant's Atlas of Anatomy, 12th Edition*

Copyright ©2009 Lippincott Williams & Wilkins

> Table of Contents > Chapter 7 - Head > 7.1 Cranium at birth and in early childhood

---

## 7.1 Cranium at birth and in early childhood

*Part of "Chapter 7 - Head "*

A . Cranium at birth, anterior aspect. B. Radiograph of 6<sup>1</sup>/<sub>2</sub> -month- old child. C. Cranium at birth, lateral aspect.

Compared with the adult skull (Figs. 7.2 ,7.3 and 7.4 ):

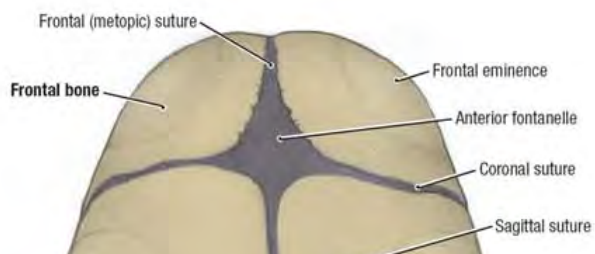
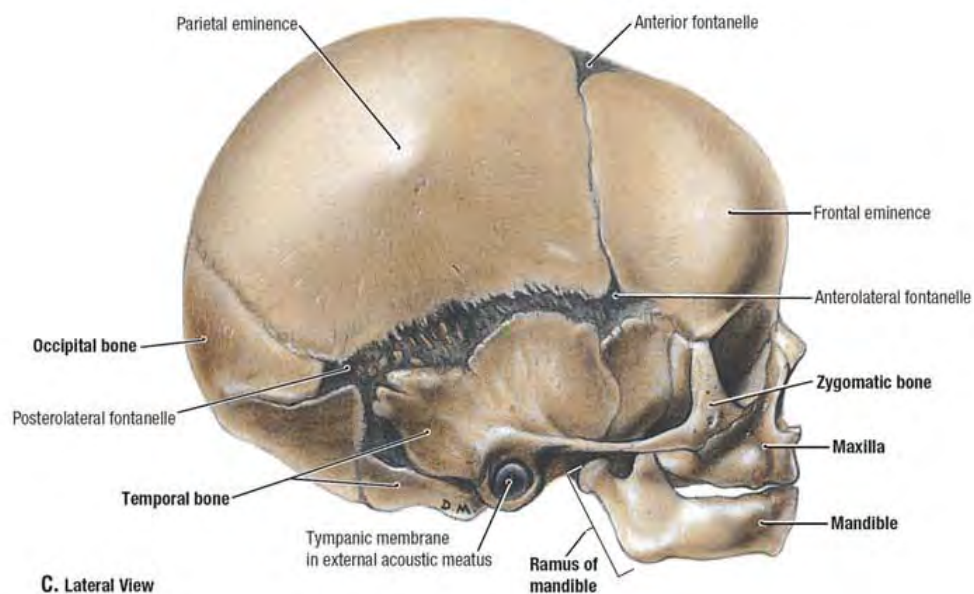
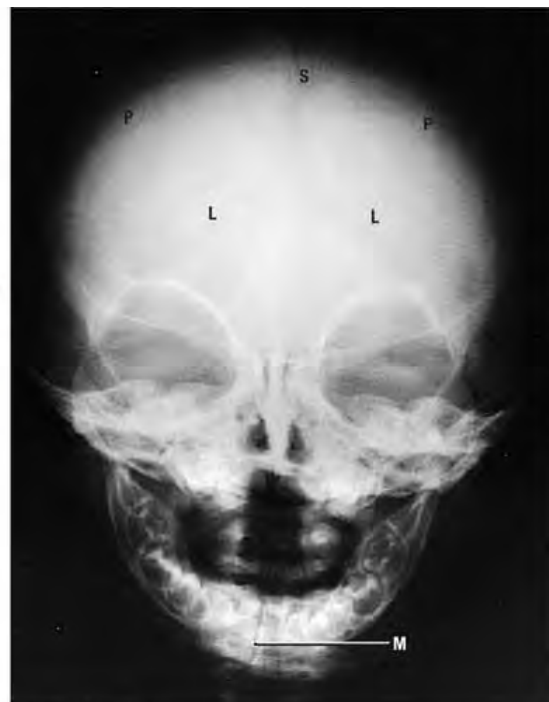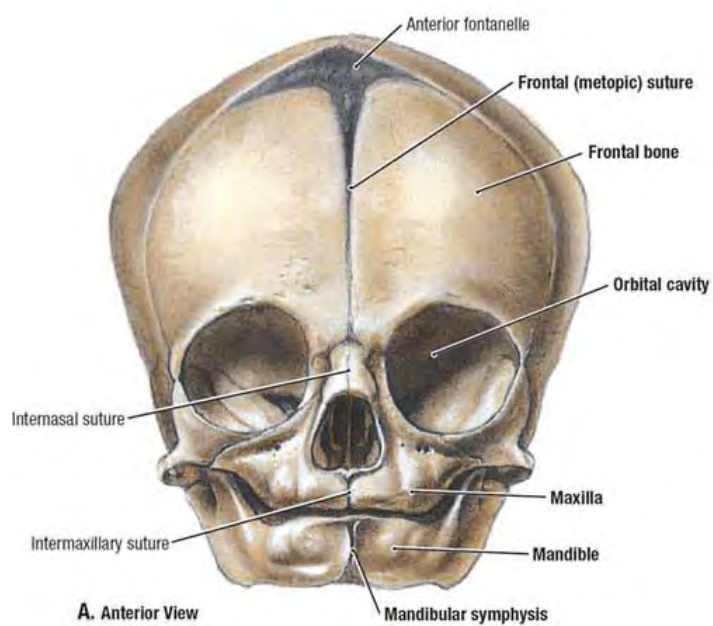
- The maxilla and mandible are proportionately small.
- The mandibular symphysis, which closes during the second year, and the frontal suture, which closes during the sixth year, are still open (unfused).
- The orbital cavities are proportionately large, but the face is small; the facial skeleton forming only one eighth of the whole cranium, while in the adult, it forms one third.

---

P.609

D. Cranium at birth, superior aspect. E. Radiograph of 6<sup>1</sup>/<sub>2</sub> -month-old child. F. Three-dimensional computer-generated images of 3-year-old child's cranium.

- The parietal eminence is a rounded cone. Ossification, which starts at the eminences, has not yet reached the ultimate four angles of the parietal bone; accordingly, these regions are membranous, and the membrane is blended with the pericranium externally and the dura mater internally to form the fontanelles. The fontanelles are usually closed by the second year; there is no mastoid process until the second year.

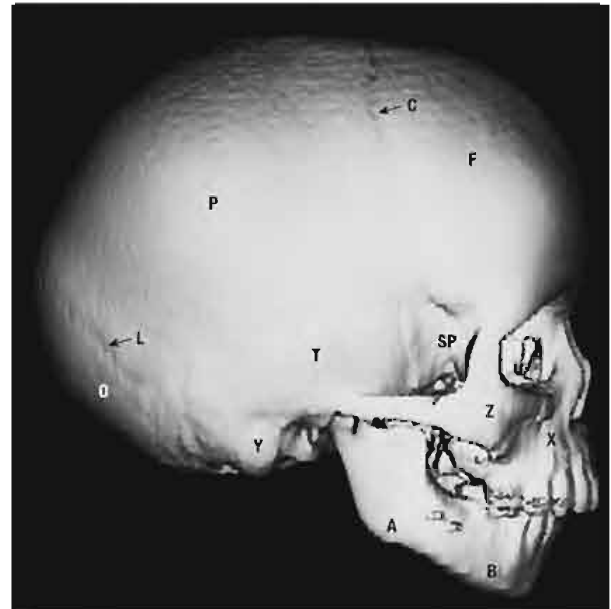
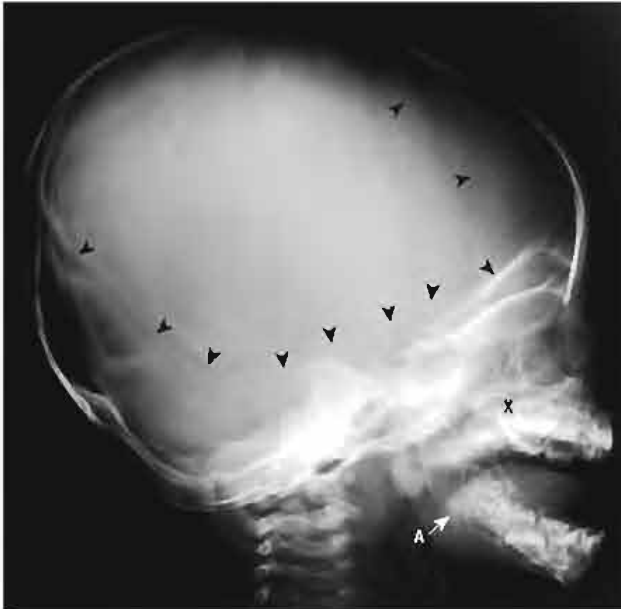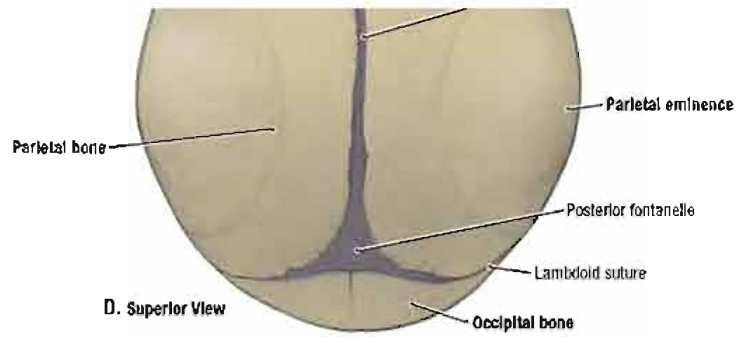


**Key for B, E and F**

- A Angle of mandible
- B Body of mandible
- C Coronal suture

F Frontal bone  
 L Lambdoid suture  
 M Mandibular symphysis  
 O Occipital bone  
 P Parietal eminence  
 S Sagittal suture  
 SP Sphenoid  
 T Temporal bone  
 X Maxilla  
 Y Mastoid process  
 Z Zygomatic bone

Arrowheads = Membranous outline of parietal bone



Authors: Agur, Anne M.R.; Dalley, Arthur F.

Title: *Grant's Atlas of Anatomy, 12th Edition*

Copyright ©2009 Lippincott Williams & Wilkins

> Table of Contents > Chapter 7 - Head > 7.2 Cranium, facial (frontal) aspect

## 7.2 Cranium, facial (frontal) aspect

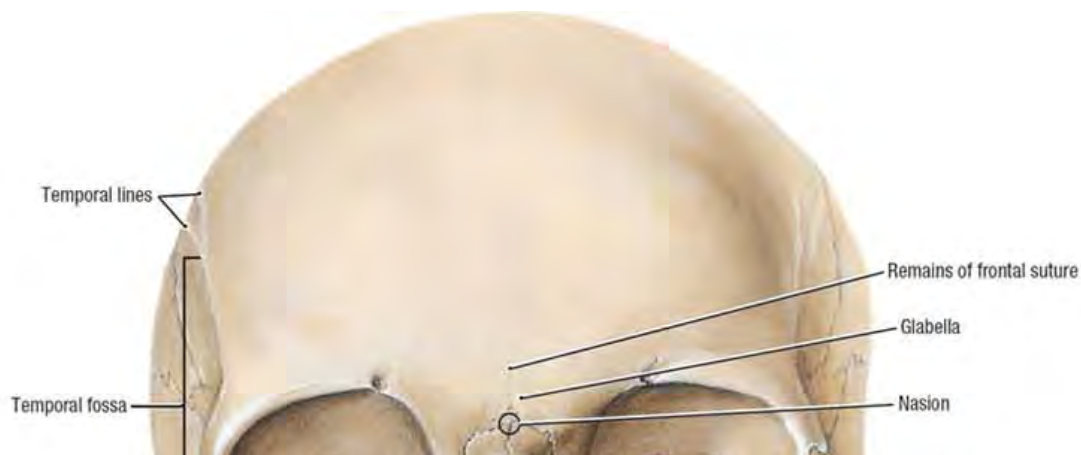Part of "Chapter 7 - Head "

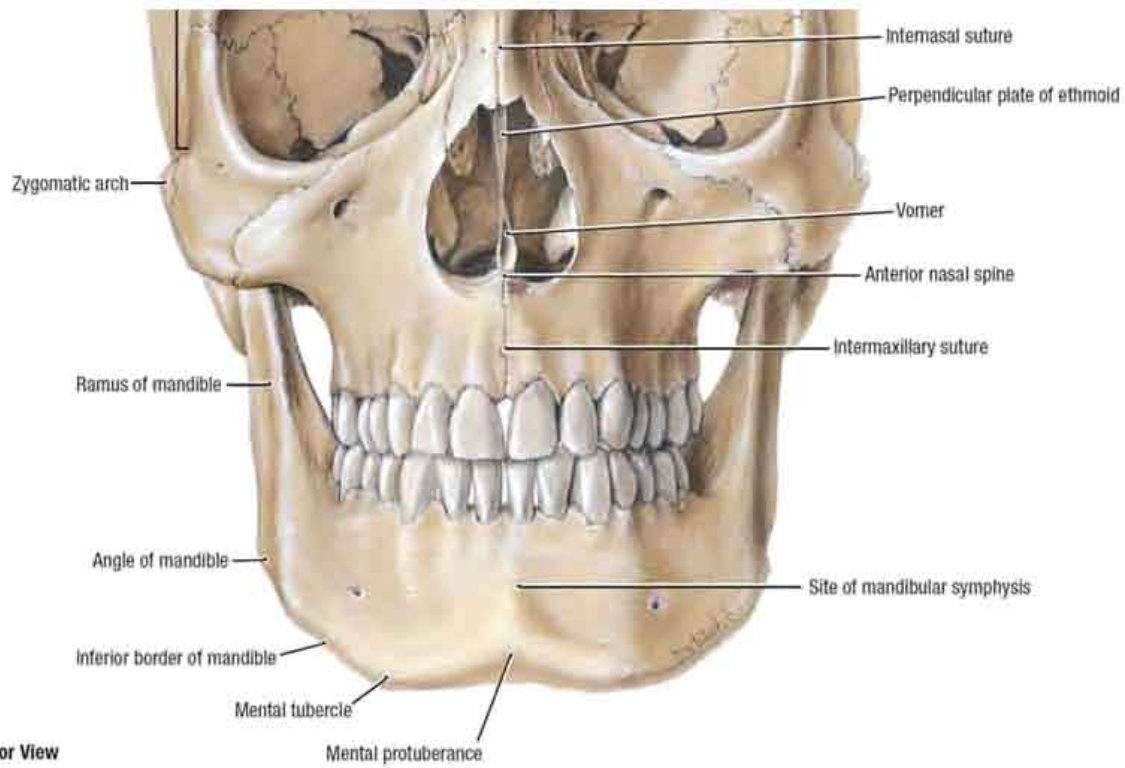
A. Formations of the bony cranium. B. Bones of cranium and their features. The individual bones forming the cranium are color coded. For the orbital cavity, see also Figure 7.31A .

P.611

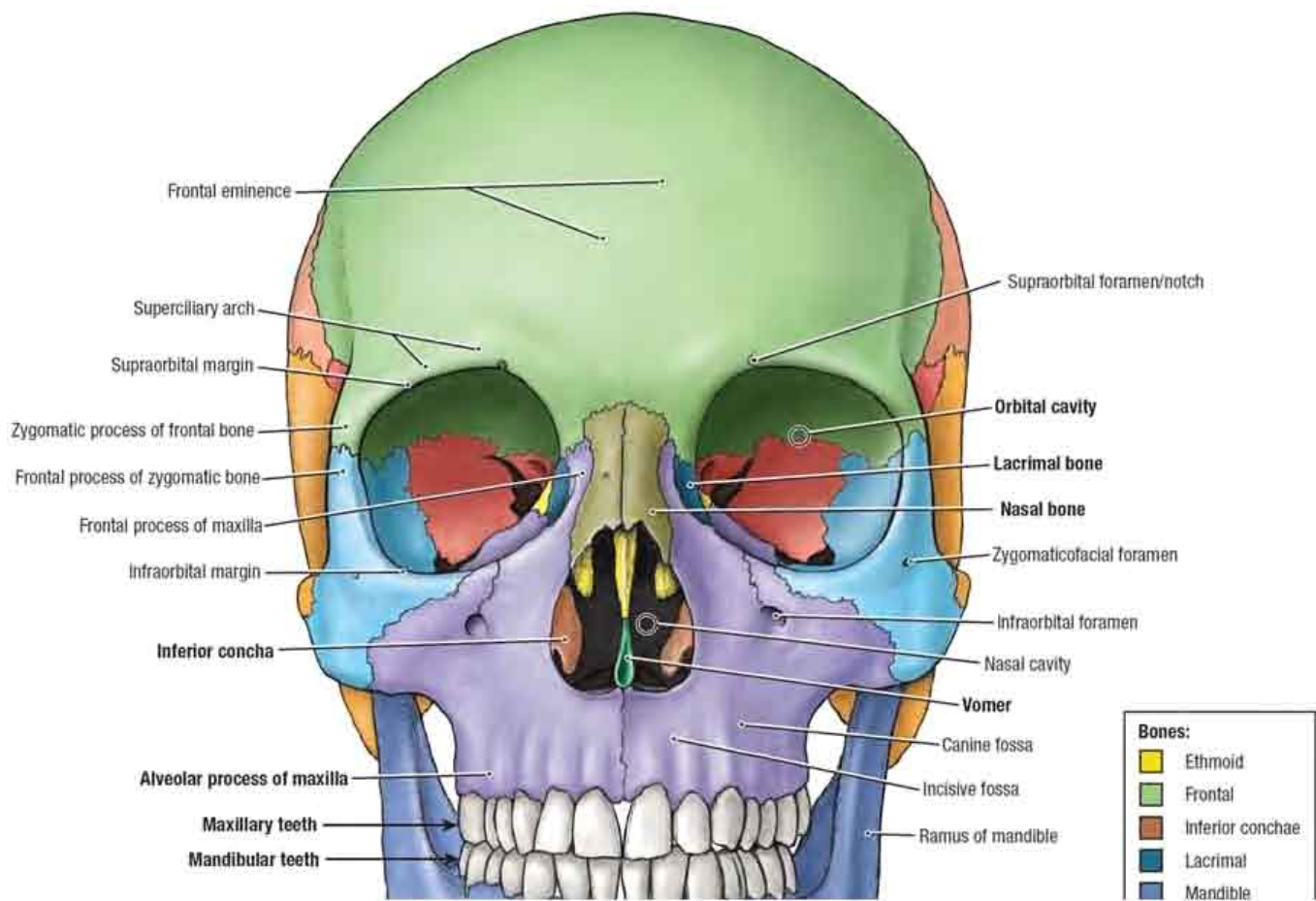
Extraction of teeth causes the alveolar bone to resorb in the affected region(s). Following complete loss or extraction of maxillary teeth, the sockets begin to fill in with bone, and the alveolar process begins to resorb. Similarly, extraction of mandibular teeth causes the bone to resorb. Gradually, the mental foramen lies near the superior border of the body of the mandible. In some cases, the mental foramina disappear, exposing the mental nerves to injury.

P.612





**A. Anterior View**







Authors: Agur, Anne M.R.; Dalley, Arthur F.

Title: *Grant's Atlas of Anatomy, 12th Edition*

Copyright ©2009 Lippincott Williams & Wilkins

> Table of Contents > Chapter 7 - Head > 7.3 Cranium, lateral aspect

---

## 7.3 Cranium, lateral aspect

*Part of "Chapter 7 - Head "*

A . Bony cranium. B. Cranium with bones color coded. The cranium is in the anatomical position when the orbitomeatal plane is horizontal.

The convexity of the neurocranium (braincase) distributes and thereby minimizes the effects of a blow to it. However, hard blows to the head in thin areas of the cranium (e.g., in the temporal fossa) are likely to produce depressed fractures, in which a fragment of bone is depressed inward, compressing and/or injuring the brain. In comminuted fractures, the bone is broken into several pieces. Linear fractures, the most frequent type, usually occur at the point of impact, but fracture lines often radiate away from it in two or more directions.

---

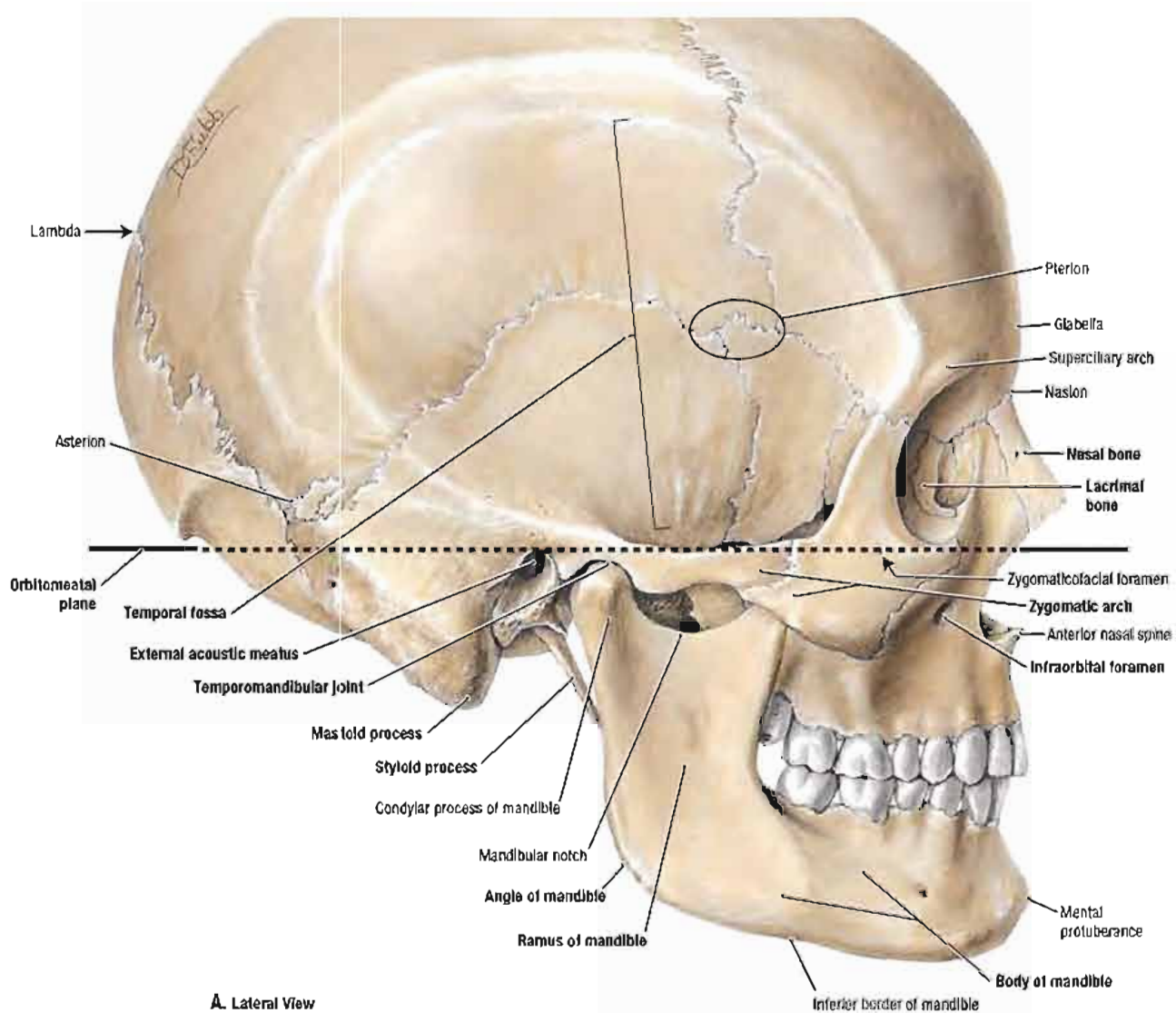
P.613

If the area of the neurocranium is thick at the site of impact, the bone usually bends inward without fracturing; however, a fracture may occur some distance from the site of direct trauma where the calvaria is thinner. In a contrecoup (counterblow) fracture, the fracture occurs on the opposite side of the cranium rather than at the point of impact.

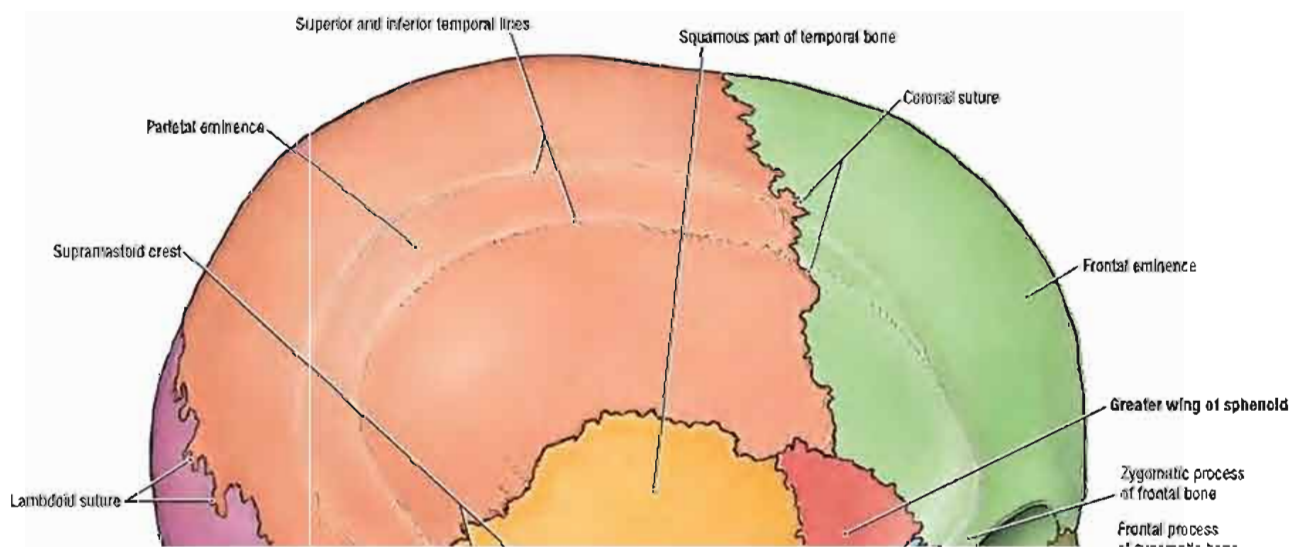
---

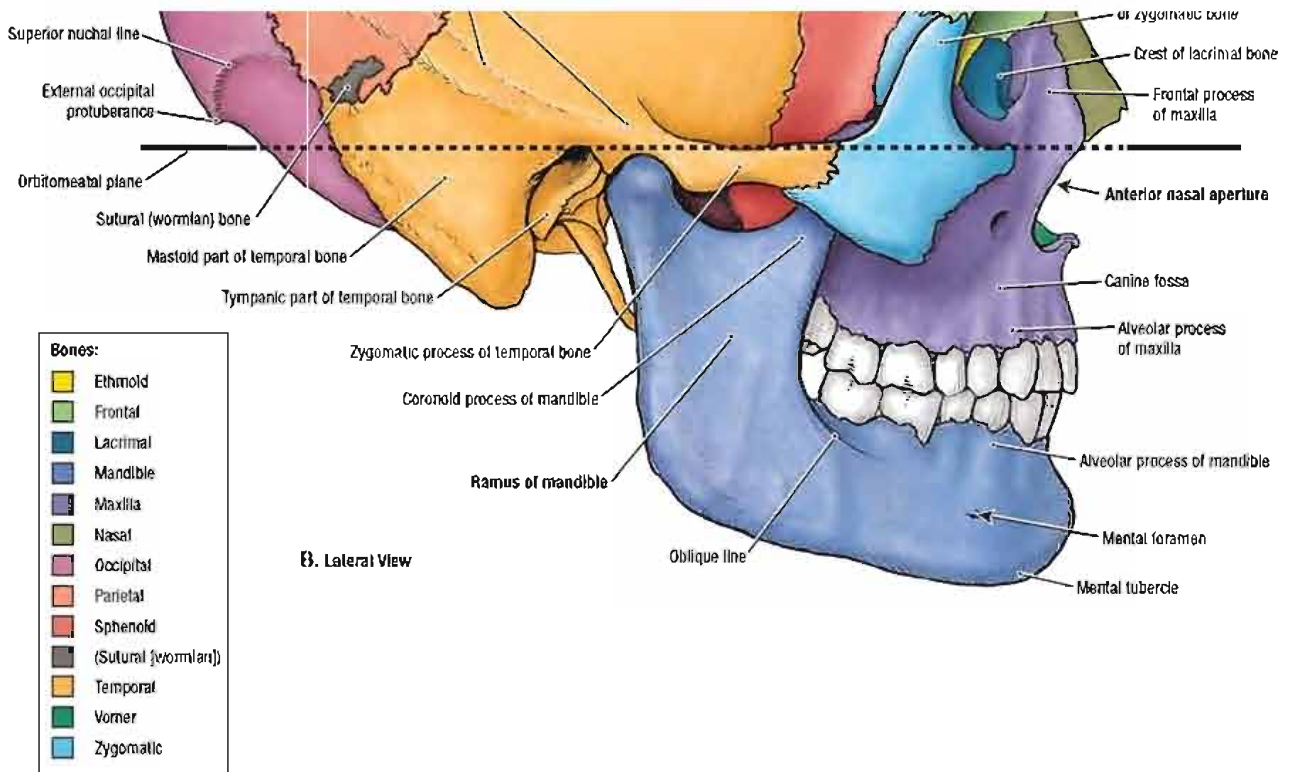
P.614





A. Lateral View





Authors: Agur, Anne M.R.; Dalley, Arthur F.

Title: *Grant's Atlas of Anatomy, 12th Edition*

Copyright ©2009 Lippincott Williams & Wilkins

> Table of Contents > Chapter 7 - Head > 7.4 Cranium, occipital aspect, calvaria, and anterior part of posterior cranial fossa

---

## 7.4 Cranium, occipital aspect, calvaria, and anterior part of posterior cranial fossa

*Part of "Chapter 7 - Head"*

A. Posterior aspect. B. Superior aspect.

A. The lambda, near the center of this convex surface, is located at the junction of the superior and lambdoid sutures. B. The roof of the neurocranium, or calvaria (skullcap), is formed primarily by the paired parietal bones, the frontal bone, and the occipital bone.

Premature closure of the coronal suture results in a high, tower-like cranium, called oxycephaly or turriccephaly. Premature closure of sutures usually does not affect brain development. When premature closure occurs on one side only, the cranium is asymmetrical, a condition known as plagiocephaly.

---

P.615

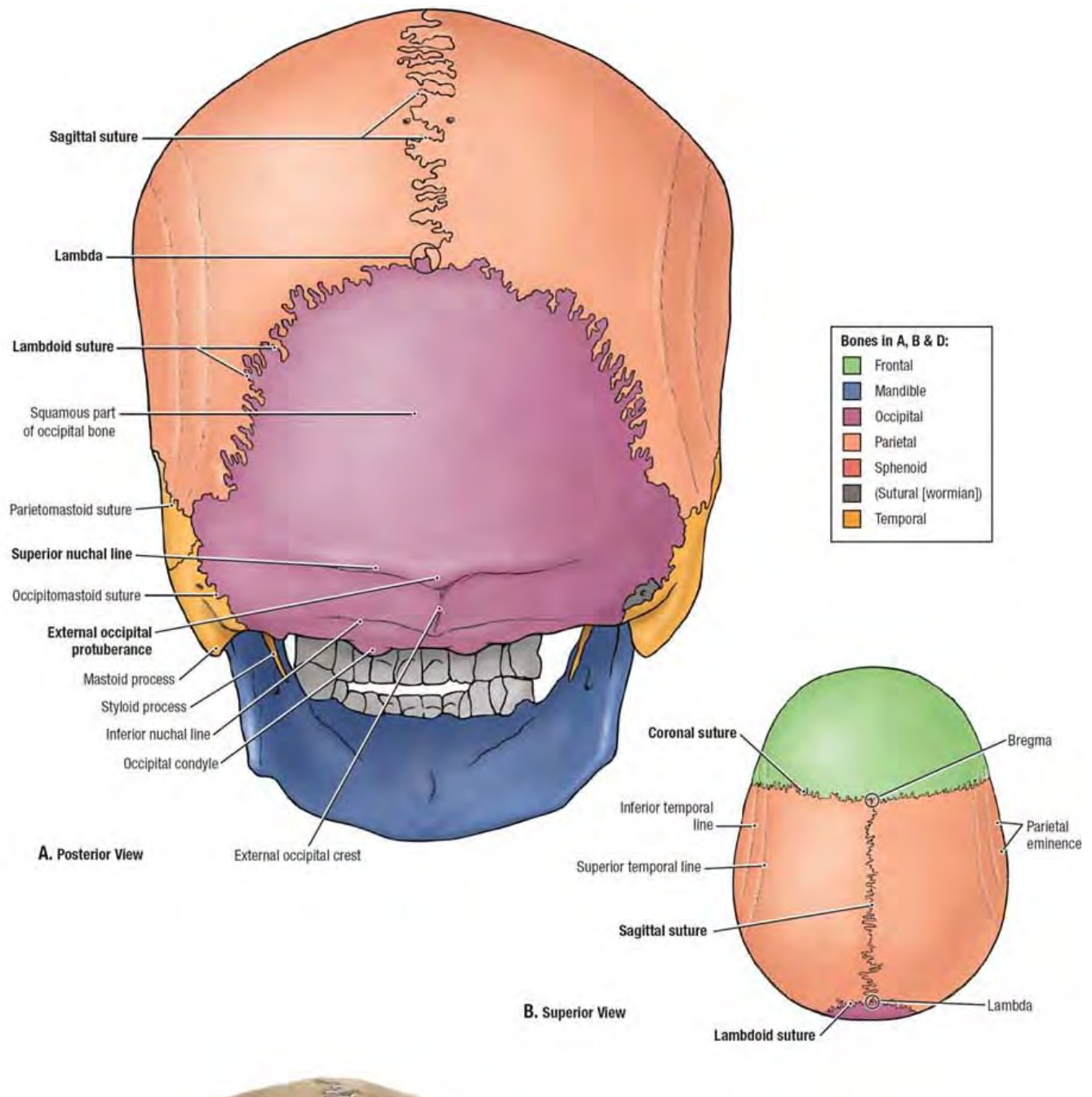
C and D. Cranium after removal of squamous part of occipital bone.

- The dorsum sellae projects from the body of the sphenoid; the posterior clinoid processes form its superolateral corners.
- The clivus is the slope descending from the dorsum sellae to the foramen magnum.
- The grooves for the sigmoid sinus and inferior petrosal sinus lead inferiorly to the

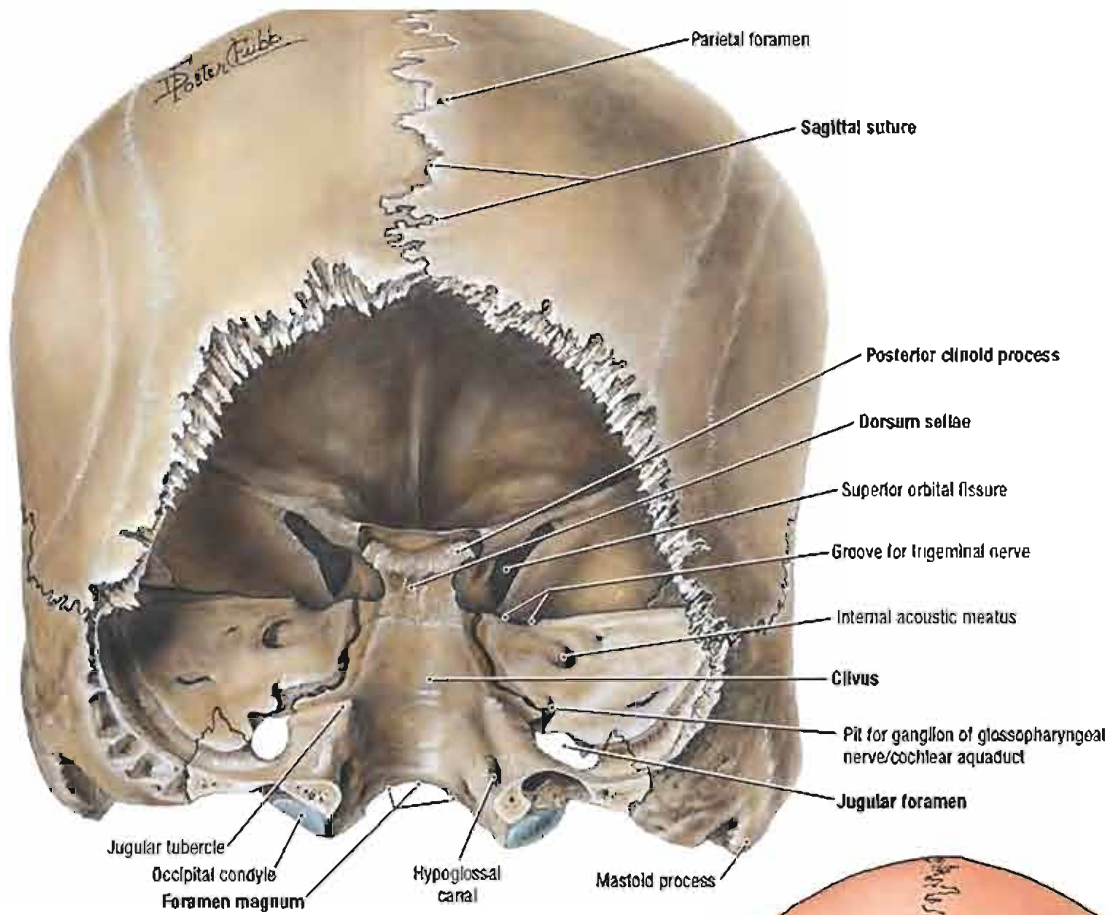
jugular foramen.

Premature closure of the sagittal suture, in which the anterior fontanelle is small or absent, results in a long, narrow, wedge-shaped cranium, a condition called scaphocephaly.

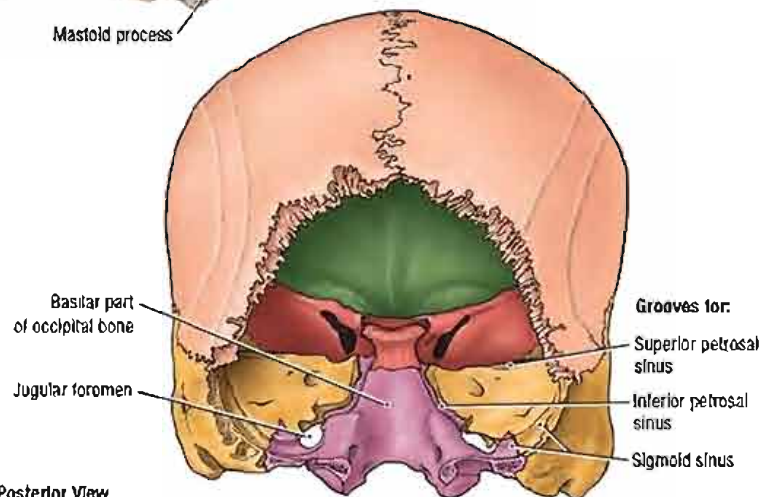
P.616







C. Posterior View



D. Posterior View



Authors: Agur, Anne M.R.; Dalley, Arthur F.  
Title: *Grant's Atlas of Anatomy, 12th Edition*  
Copyright ©2009 Lippincott Williams & Wilkins

> Table of Contents > Chapter 7 - Head > 7.5 Cranium, inferior aspect

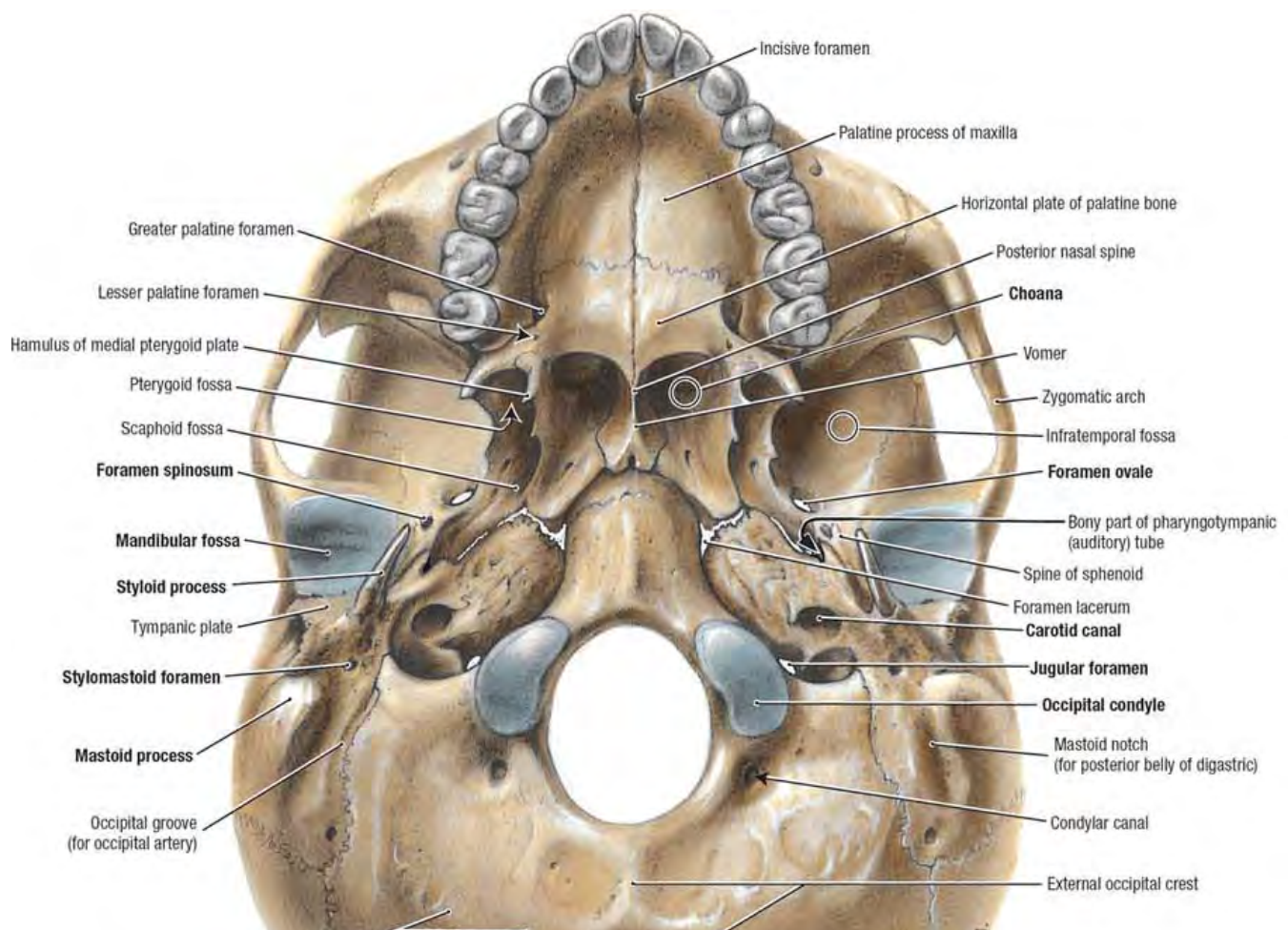
## 7.5 Cranium, inferior aspect

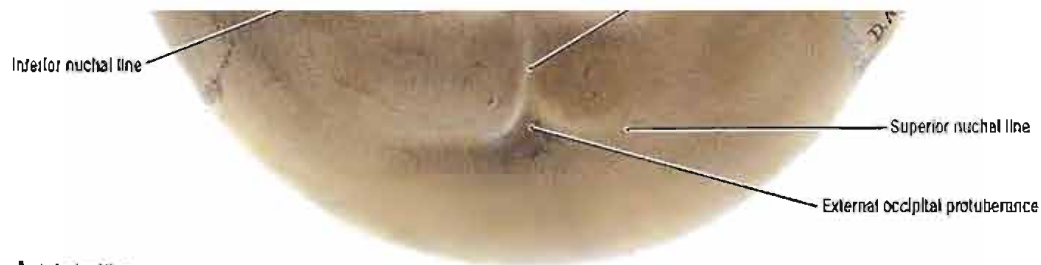
Part of "Chapter 7 - Head "

A. Bony cranium. B. Diagram of cranium with bones color coded.

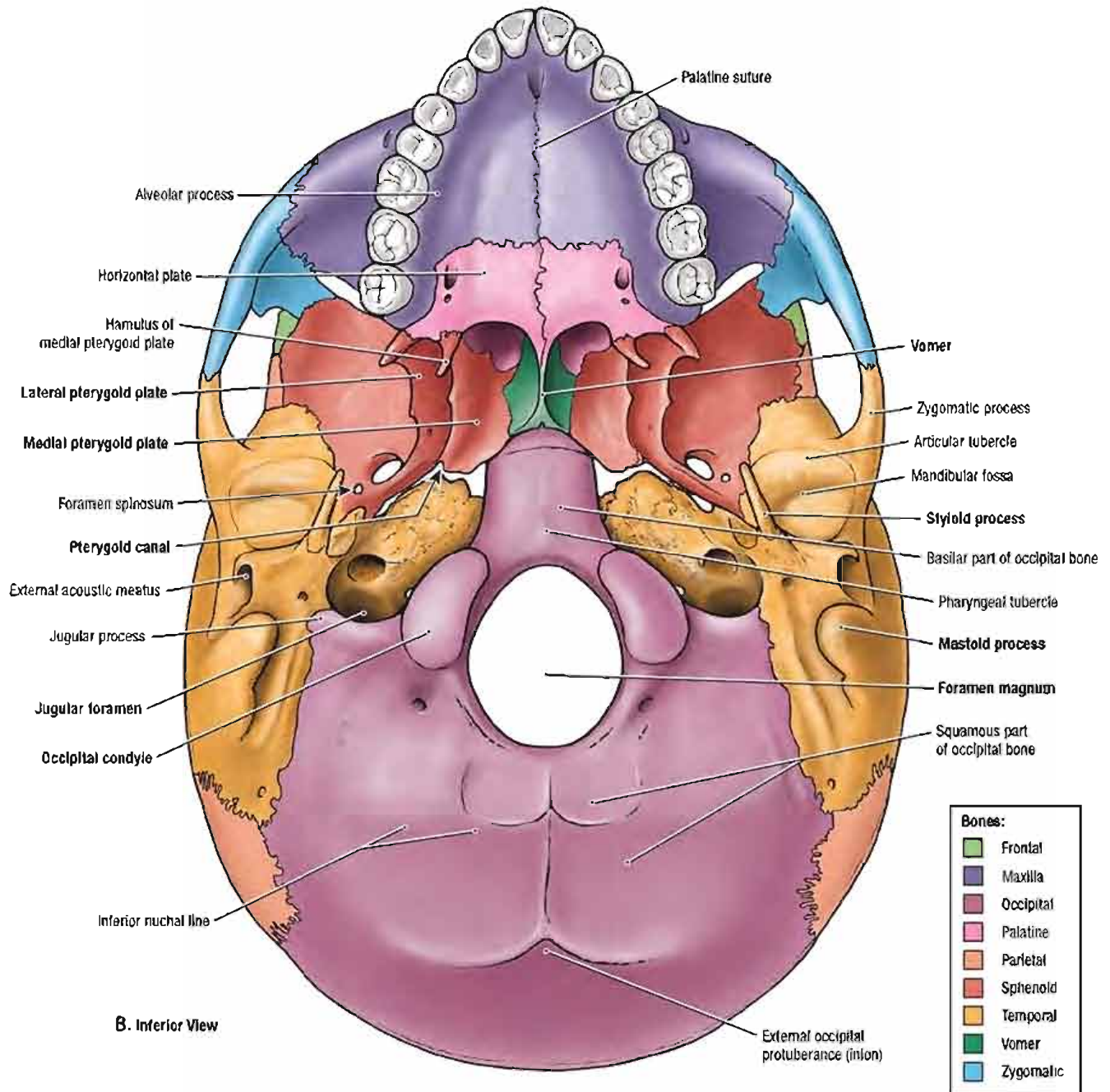
P.617

P.618





A. Inferior View



B. Inferior View

Authors: Agur, Anne M.R.; Dalley, Arthur F.

Title: *Grant's Atlas of Anatomy, 12th Edition*

Copyright ©2009 Lippincott Williams & Wilkins

> Table of Contents > Chapter 7 - Head > 7.6 Interior of the cranial base

---

## 7.6 Interior of the cranial base

*Part of "Chapter 7 - Head "*

A. Bony cranial base. B. Diagrammatic cranial base with bones color coded.

In A:

- Three bones contribute to the anterior cranial fossa: the orbital part of the frontal bone, the cribriform plate of the ethmoid, and the lesser wing of the sphenoid.
- The four parts of the occipital bone are the basilar, right and left lateral, and squamous.

- Fractures in the floor of the anterior cranial fossa may involve the cribriform plate of the ethmoid, resulting in leakage of CSF through the nose (CSF rhinorrhea). CSF rhinorrhea may be a primary indication of a cranial base fracture which increases the risk of meningitis, because an infection could spread to the meninges from the ear or nose.

---

P.619

In B , note the following midline features:

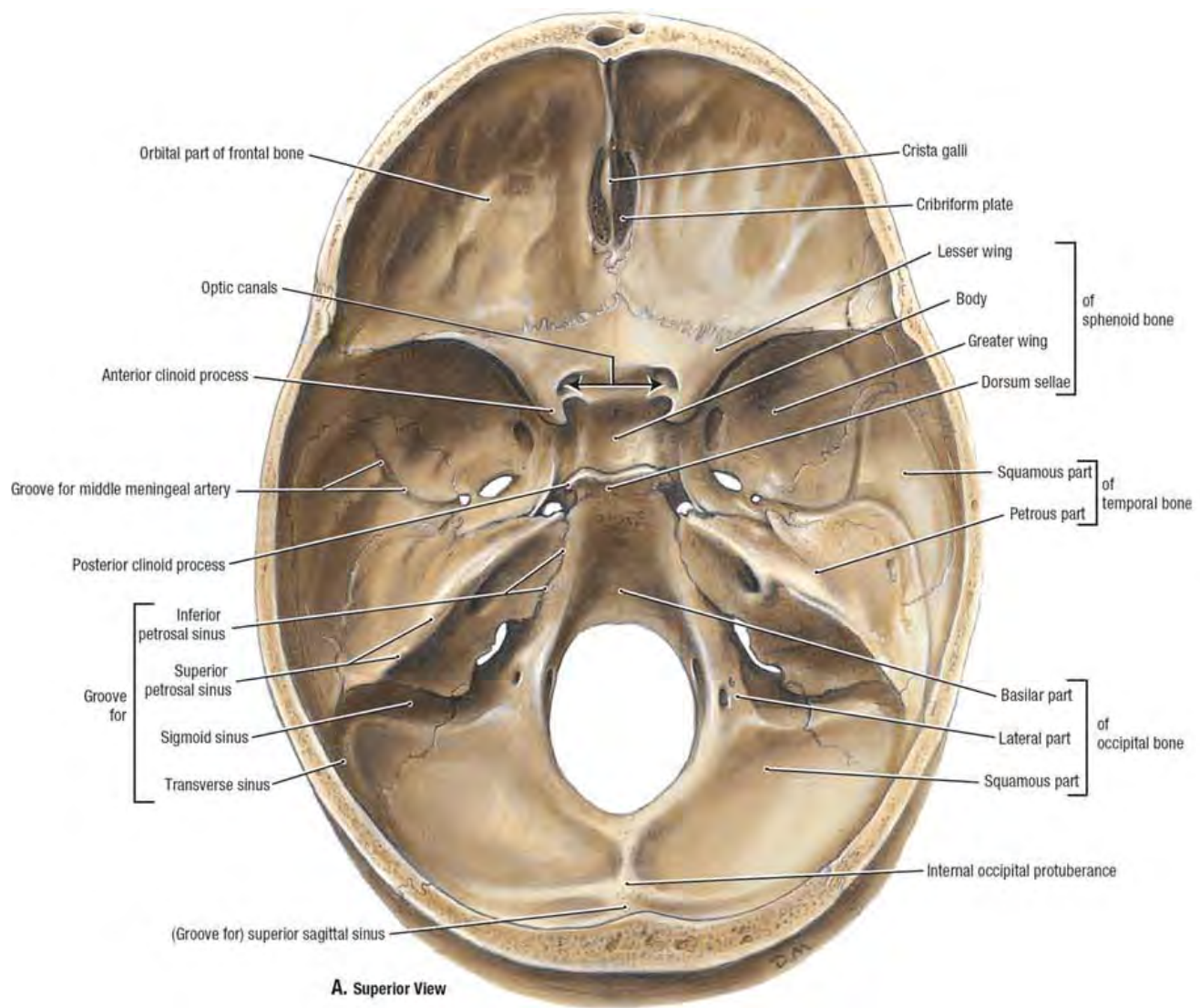
- In the anterior cranial fossa, the frontal crest and crista galli for anterior

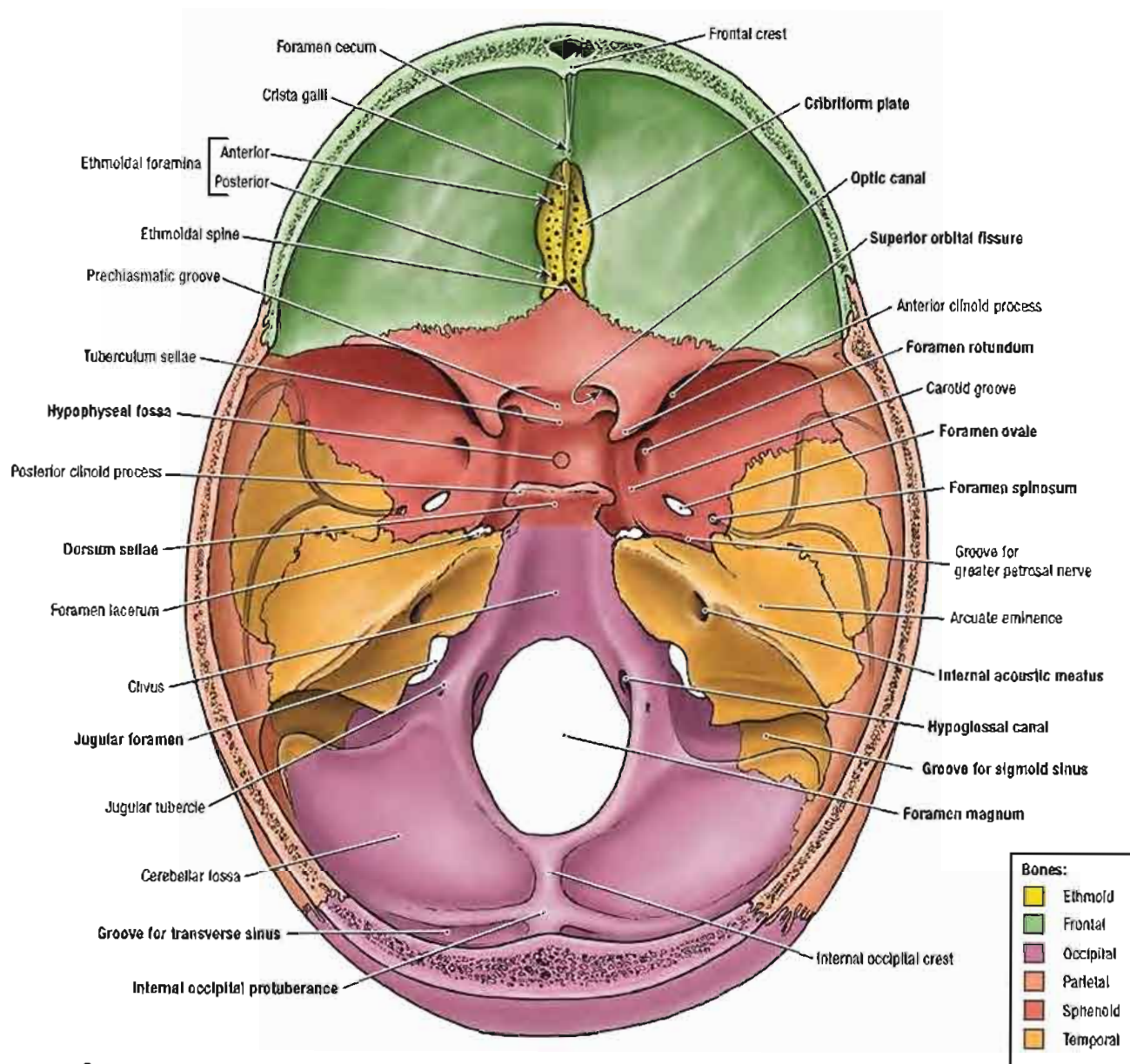


attachment of the falx cerebri have between them the foramen cecum, which, during development, transmits a vein connecting the superior sagittal sinus with the veins of the frontal sinus and root of the nose.

- In the middle cranial fossa, the tuberculum sellae, hypophyseal fossa, dorsum sellae, and posterior clinoid processes constitute the sella turcica (L. Turkish saddle).
- In the posterior cranial fossa, note the clivus, foramen magnum, internal occipital crest for attachment of the falx cerebelli, and the internal occipital protuberance, from which the grooves for the transverse sinuses course laterally.

P.620





**B. Superior View**

Authors: Agur, Anne M.R.; Dalley, Arthur F.

Title: *Grant's Atlas of Anatomy, 12th Edition*

Copyright ©2009 Lippincott Williams & Wilkins

> Table of Contents > Chapter 7 - Head > 7.7 Radiographs of the cranium

---

## 7.7 Radiographs of the cranium

*Part of* "Chapter 7 - Head "

A. Posteroanterior (Caldwell) radiograph. This view places the orbits centrally in the head and is used to examine the orbits and paranasal sinuses. Observe in A:

- The labeled features include the superior orbital fissure (*Sr*), lesser wing of the sphenoid (*S*), superior surface of the petrous part of the temporal bone (*T*), crista galli (*C*), frontal sinus (*F*), mandible (*MM*), and maxillary sinus (*M*).
- The nasal septum is formed by the perpendicular plate of the ethmoid (*E*) and the vomer (*V*); note the inferior and middle conchae (*I*) of the lateral wall of the nose.
- Superimposed on the facial skeleton are the dens (*D*) and lateral masses of the atlas (*A*).

---

P.621

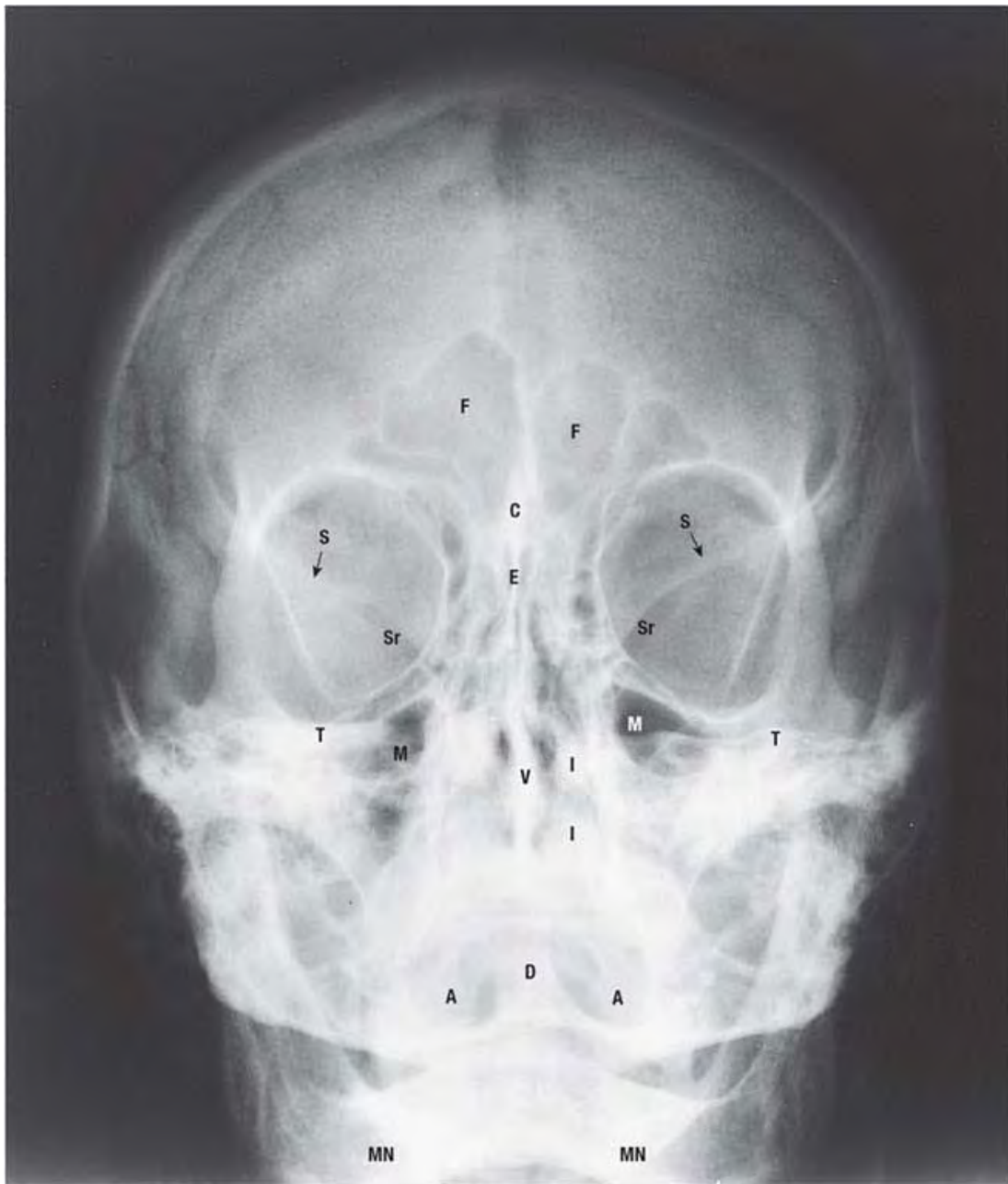B. Lateral radiograph of the cranium. Most of the relatively thin bone of the facial skeleton (viscerocranium) is radiolucent (appears black).

- The labeled features include the ethmoidal cells (*E*), sphenoidal (*S*) and maxillary (*M*) sinuses, the hypophyseal fossa (*H*) for the pituitary gland, the petrous part of the temporal bone (*T*), mastoid cells (*Mc*), grooves for the branches of the middle meningeal vessels (*Mn*), arch of the atlas (*A*), internal occipital protuberance (*P*), and the nasopharynx (*N*).

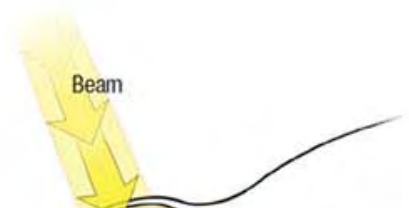

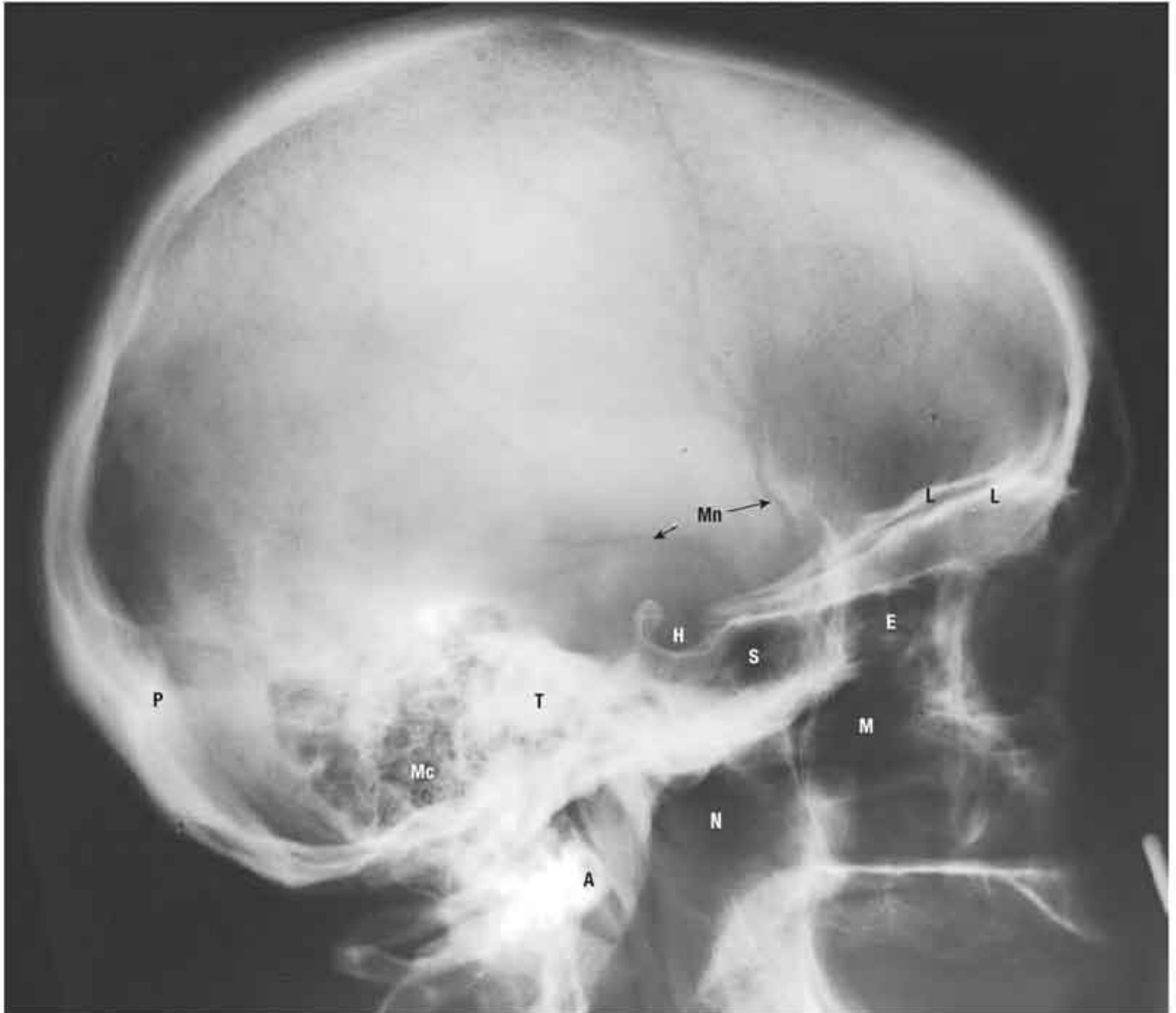
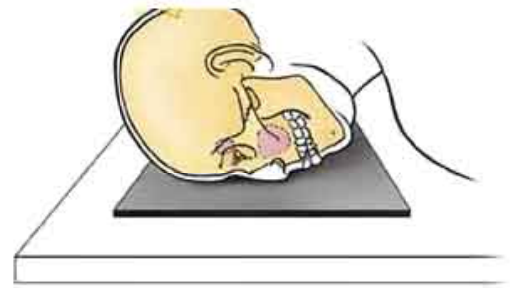
- The right and left orbital plates of the frontal bone are not superimposed; thus, the floor of the anterior cranial fossa appears as two lines ( $\angle$ ).

P.622



A. Anteroposterior View





B. Lateral View

Authors: Agur, Anne M.R.; Dalley, Arthur F.

Title: *Grant's Atlas of Anatomy, 12th Edition*

Copyright ©2009 Lippincott Williams & Wilkins

> Table of Contents > Chapter 7 - Head > 7.8 Superficial bones of facial skeleton

---

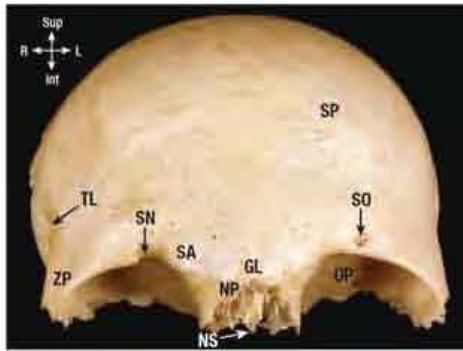
## 7.8 Superficial bones of facial skeleton

*Part of* "Chapter 7 - Head "

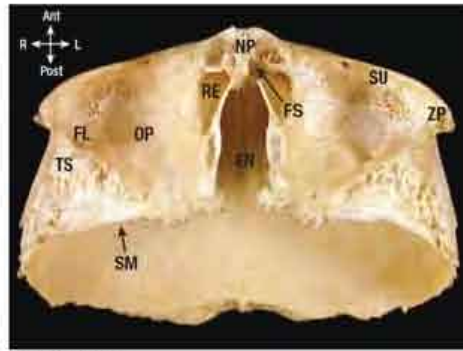
A and B. Frontal bone. C and d. Mandible. E. Maxilla. F. Infratemporal fossa.

---

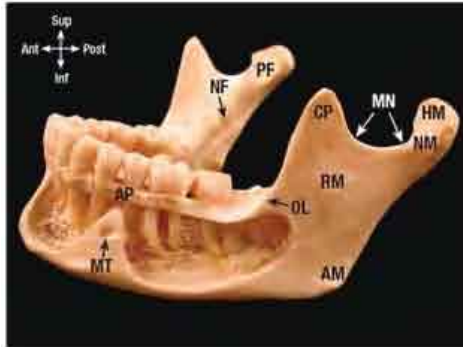
P.623



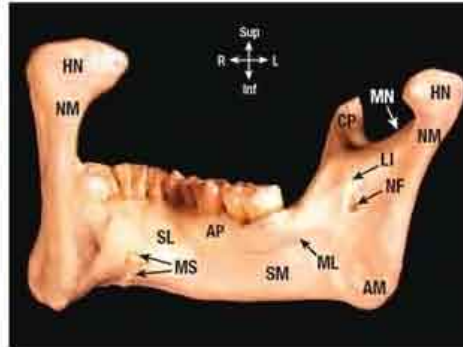
A. Anterior View



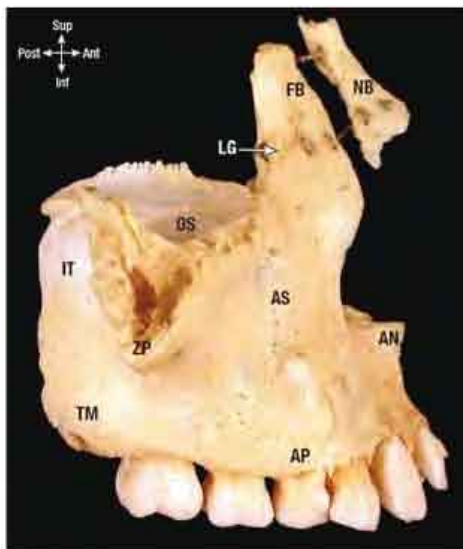
B. Inferior View



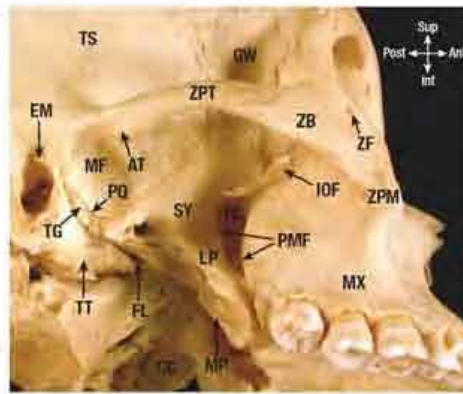
C. Lateral View



D. Posteromedial View



E. Lateral View



F. Inferolateral View

#### Maxilla and nasal bone

AN	Anterior nasal spine
AP	Alveolar part
AS	Anterior surface of maxilla
FP	Frontal process of maxilla
IT	Infratemporal surface of maxilla
LG	Lacrimal groove
NB	Nasal bone
OS	Orbital surface
TM	Tuberosity
ZP	Zygomatic process

#### Key

##### Frontal Bone

EN	Ethmoidal notch
FL	Fossa for lacrimal gland
FS	Opening of frontal sinus
GL	Glabella
NP	Nasal part
NS	Nasal spine
OP	Orbital part
RE	Root of ethmoid cells
SA	Superciliary arch
SM	Sphenoidal margin
SN	Supra-orbital notch
SO	Supra-orbital foramen
SP	Squamous part
SU	Supra-orbital margin
TL	Temporal line
TS	Temporal surface
ZP	Zygomatic process

##### Mandible

AM	Angle of mandible
AP	Alveolar part
CP	Coronoid process
HM	Head of mandible
LI	Lingula
ML	Mylohyoid groove
MN	Mandibular notch
MS	Superior and inferior mental spines
MT	Mental foramen
NF	Mandibular foramen
NM	Neck of mandible
PF	Pterygoid fovea
RM	Ramus of mandible
SL	Sublingual fossa
SM	Submandibular fossa

##### Pterygopalatine fossa

PF	Pterygopalatine fossa
MF	Mandibular fossa
AT	Articular tubercle
ZPT	Zygomatic process of temporal bone
CC	Carotid canal
FL	Foramen lacerum
ZF	Zygomaticofacial foramen
PQ	Petrosquamous fissure
TG	Tegmen tympani
TT	Temporal bone (tympanic part)
ZB	Zygomatic bone
MX	Maxilla
IOF	Inferior orbital fissure
PMF	Pterygomaxillary fissure
ZPM	Zygomatic process of maxilla
EM	External acoustic meatus
GW	Greater wing of sphenoid
LP	Lateral pterygoid plate
MP	Medial pterygoid plate
SY	Stylomastoid foramen

Authors: Agur, Anne M.R.; Dalley, Arthur F.

Title: *Grant's Atlas of Anatomy, 12th Edition*

Copyright ©2009 Lippincott Williams & Wilkins

> Table of Contents > Chapter 7 - Head > 7.9 Deep bones of facial skeleton

---

## 7.9 Deep bones of facial skeleton

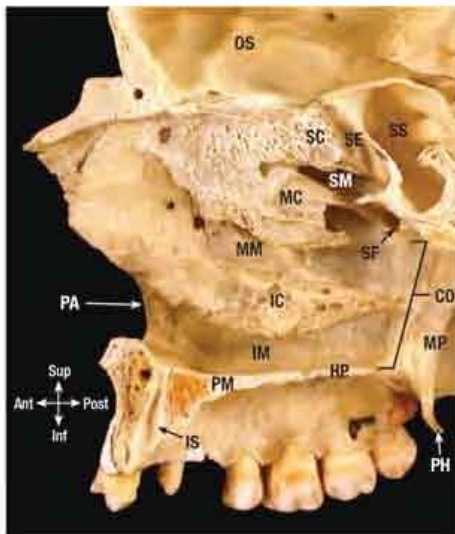
*Part of* "Chapter 7 - Head "

A. Lateral wall of nose. B. Palatine bone. C. E. Ethmoid bone.

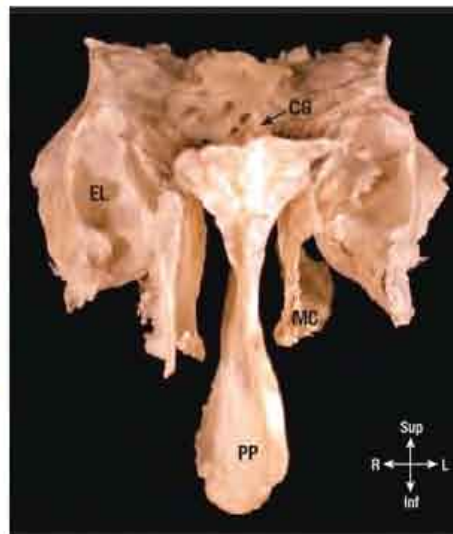
---

P.624

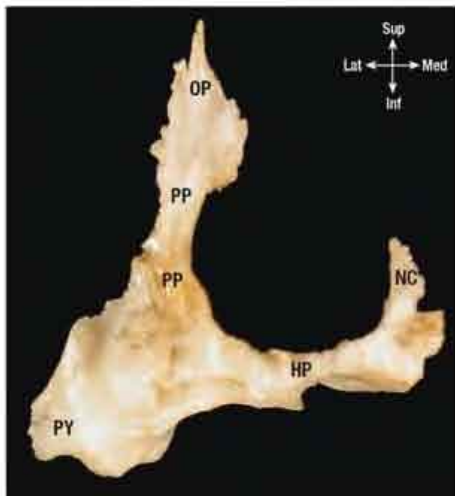




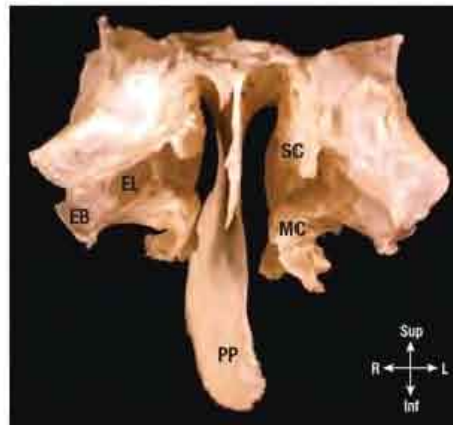
A. Medial View



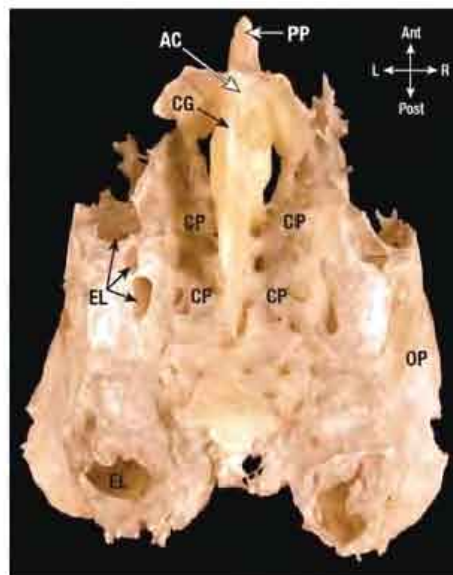
C. Anterior View



B. Anterior View



D. Posterior View



E. Superior View

#### Key

##### Lateral Wall of Nose

CO	Choana (posterior nasal aperture)
HP	Horizontal plate of palatine bone
IC	Inferior nasal concha
IS	Incisive canal
IM	Inferior nasal meatus
MC	Middle nasal concha
MM	Middle nasal meatus
PH	Pterygoid hamulus
PM	Palatine process of maxilla
OS	Orbital surface of frontal bone
PA	Piriform aperture
PM	Palatine process of maxilla
SC	Superior nasal concha
SE	Spheno-ethmoidal recess
SF	Sphenopalatine foramen
SM	Superior nasal meatus
SS	Sphenoidal sinus

##### Palatine Bone

HP	Horizontal plate
NC	Nasal crest
OP	Orbital process
PP	Perpendicular plate
PY	Pyramidal process

##### Ethmoid Bone

AC	Ala of crista galli
CG	Crista galli
CP	Cribriform plate
EB	Ethmoidal bulla
EL	Ethmoidal labyrinth (ethmoidal cells)
MC	Middle nasal concha
OP	Orbital plate
PP	Perpendicular plate
SC	Superior nasal concha





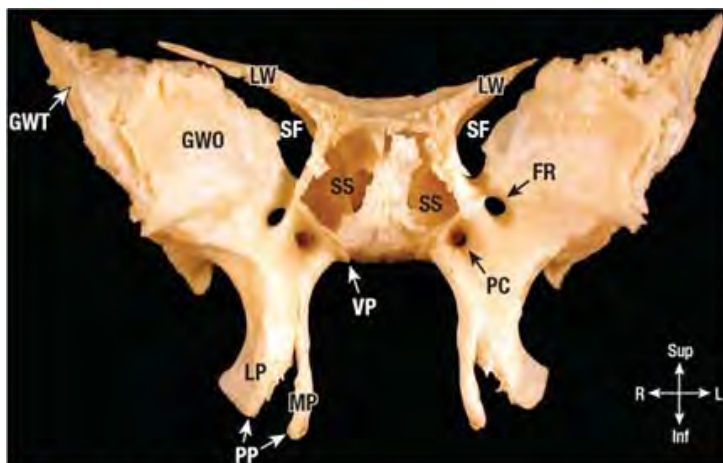
Authors: Agur, Anne M.R.; Dalley, Arthur F.  
 Title: *Grant's Atlas of Anatomy, 12th Edition*  
 Copyright ©2009 Lippincott Williams & Wilkins

> Table of Contents > Chapter 7 - Head > 7.10 Sphenoid bone

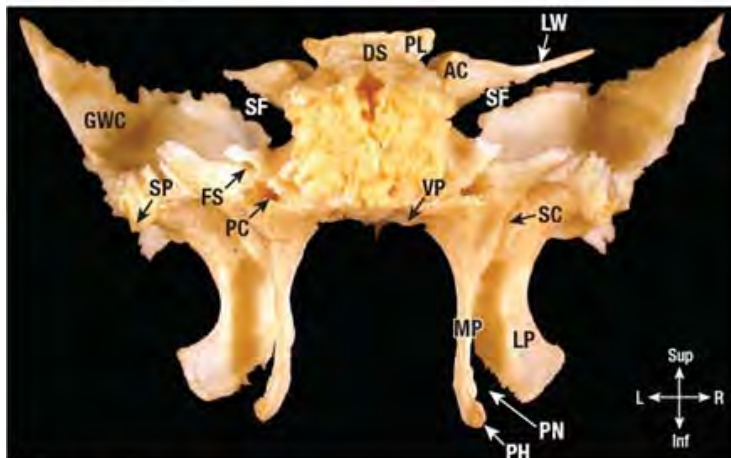
## 7.10 Sphenoid bone

Part of "Chapter 7 - Head "


P.625



A. Anterior View

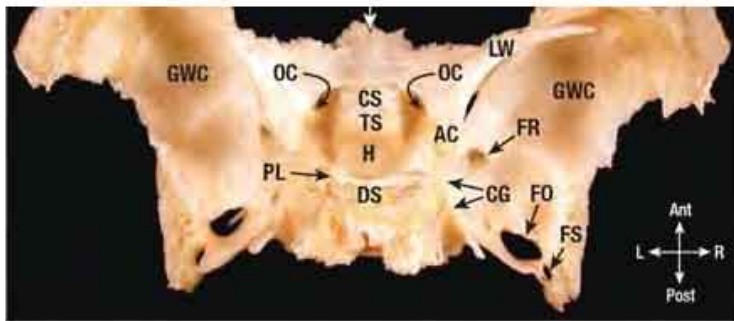


B. Posterior View

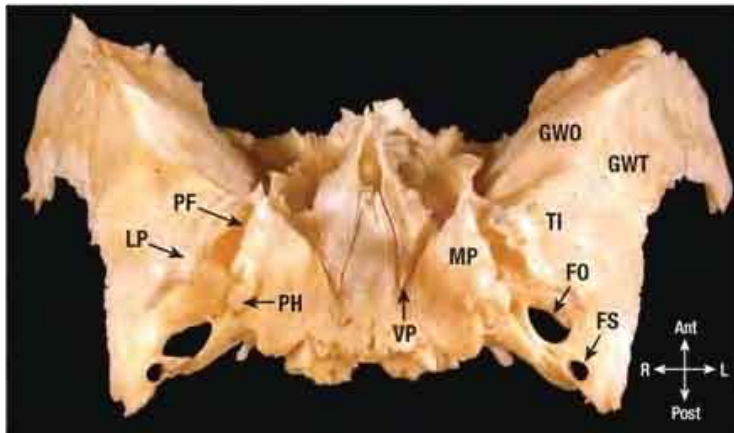


### Key

AC	Anterior clinoid process
CG	Carotid sulcus
CS	Prechiasmatic sulcus
DS	Dorsum sellae
ES	Ethmoidal spine
FO	Foramen ovale
FR	Foramen rotundum
FS	Foramen spinosum
GWC	Greater wing (cerebral surface)
GWO	Greater wing (orbital surface)
GWT	Greater wing (temporal surface)
H	Hypophysial fossa
LP	Lateral pterygoid plate
LW	Lesser wing
MP	Medial pterygoid plate
OC	Optic canal
PC	Pterygoid canal
PF	Pterygoid fossa
PH	Pterygoid hamulus
PL	Posterior clinoid process
PN	Pterygoid notch
PP	Pterygoid process
SC	Scaphoid fossa
SF	Superior orbital fissure
SP	Spine of sphenoid bone
SS	Sphenoidal sinus (in body of sphenoid)
TI	Greater wing of sphenoid (Infratemporal surface)
TS	Tuberculum sellae
VP	Vaginal process



C. Superior View



D. Inferior View

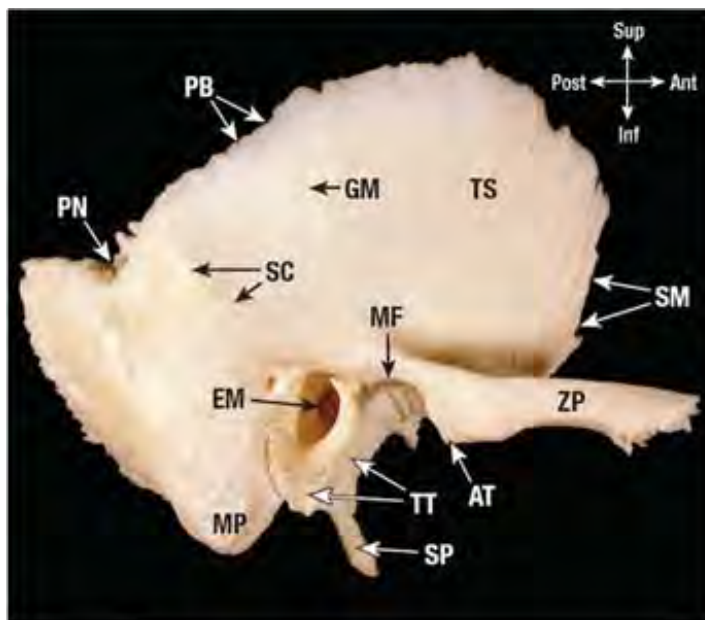
Authors: Agur, Anne M.R.; Dalley, Arthur F.  
 Title: *Grant's Atlas of Anatomy, 12th Edition*  
 Copyright ©2009 Lippincott Williams & Wilkins

> Table of Contents > Chapter 7 - Head > 7.11 Temporal bone

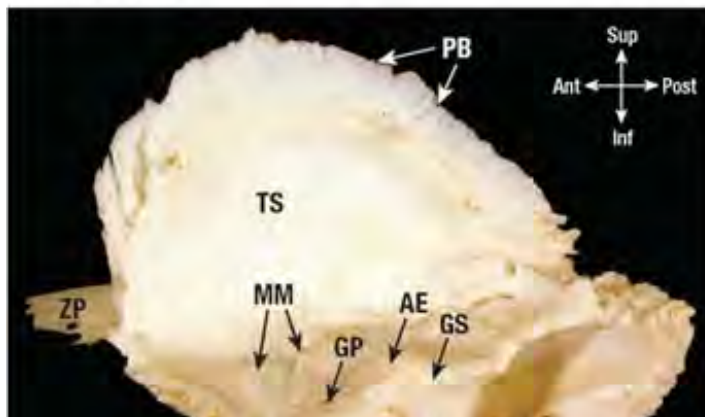
## 7.11 Temporal bone

Part of "Chapter 7 - Head "

P.626

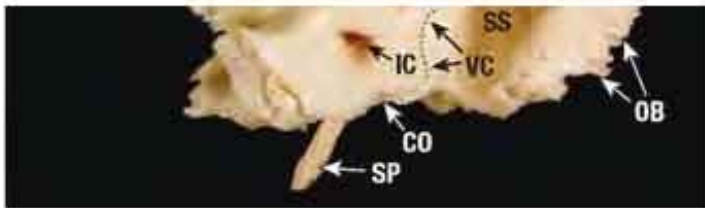


A. Lateral View



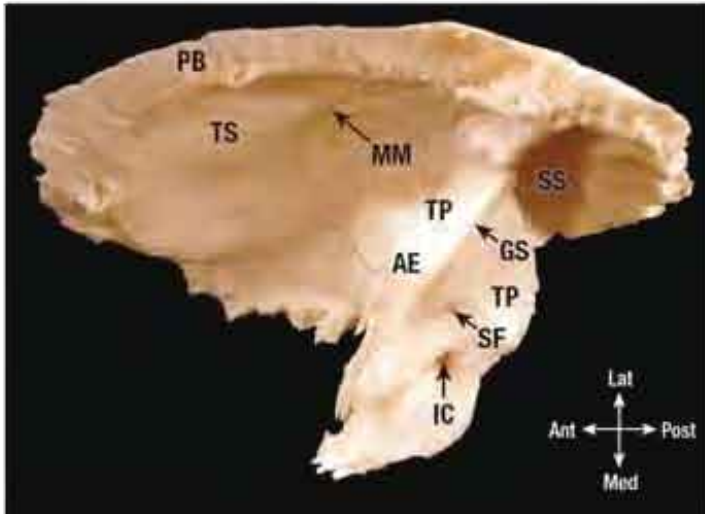
### Key

AE	Arcuate eminence
AT	Articular tubercle
CC	Carotid canal
CO	Cochlear canaliculus
EM	External acoustic meatus
GM	Groove for middle temporal artery
GP	Hiatus for greater petrosal nerve
GS	Groove for superior petrosal sinus
IC	Internal acoustic meatus
JF	Jugular fossa
MF	Mandibular fossa
MM	Groove for middle meningeal artery
MN	Mastoid notch
MP	Mastoid process
OB	Occipital border
PB	Parietal border
PN	Parietal notch
PT	Petrotympanic fissure
SC	Supramastoid crest
SF	Subarcuate fossa
SM	Sphenoid margin
SP	Styloid process
SS	Groove for sigmoid sinus
SY	Stylomastoid foramen
TC	Truncus canaliculus

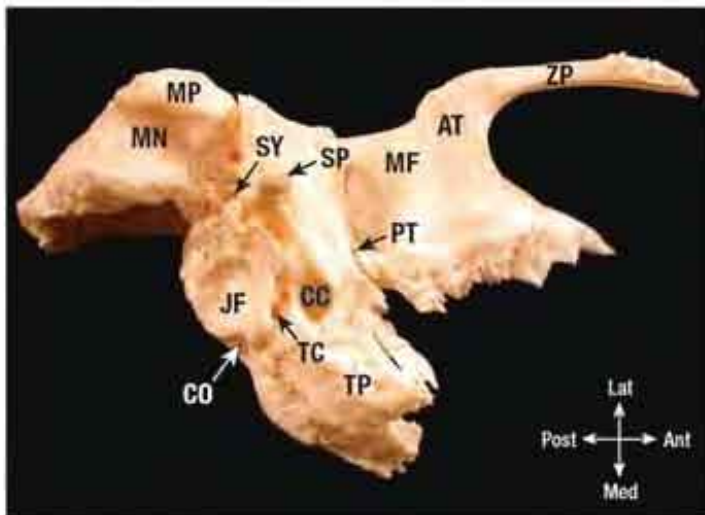


B. Medial View

TP	Temporal bone (petrous part)
TS	Temporal bone (squamous part)
TT	Temporal bone (tympanic part)
VC	Vestibular canaliculus
ZP	Zygomatic process



C. Superior View



D. Inferior View

Authors: Agur, Anne M.R.; Dalley, Arthur F.

Title: *Grant's Atlas of Anatomy, 12th Edition*

Copyright ©2009 Lippincott Williams & Wilkins

> Table of Contents > Chapter 7 - Head > 7.12 Muscles of facial expression and arteries of the face

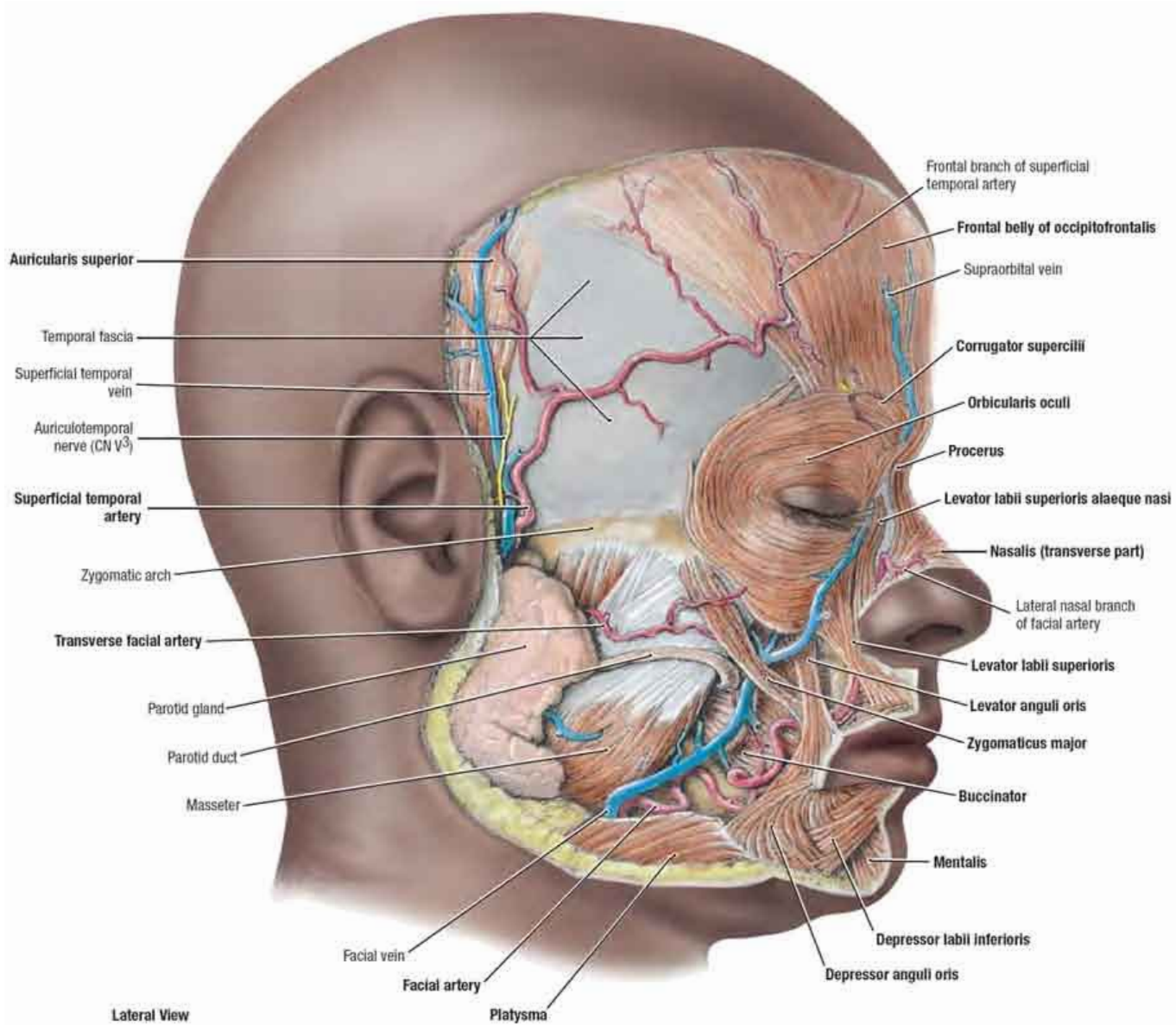
---

## 7.12 Muscles of facial expression and arteries of the face

*Part of "Chapter 7 - Head "*

- The muscles of facial expression are the superficial sphincters and dilators of the openings of the head; all are supplied by the facial nerve (CN VII). The masseter and temporalis (the latter covered here by temporal fascia) are muscles of mastication that are innervated by the trigeminal nerve (CN V).
- The pulses of the superficial temporal and facial arteries can be used for taking the pulse. For example, anesthesiologists at the head of the operating table often take the temporal pulse anterior to the auricle as the artery crosses the zygomatic arch to supply the scalp. The facial pulse can be palpated where the facial artery crosses the inferior border of the mandible immediately anterior to the masseter.





Authors: Agur, Anne M.R.; Dalley, Arthur F.

Title: *Grant's Atlas of Anatomy, 12th Edition*

Copyright ©2009 Lippincott Williams & Wilkins

> Table of Contents > Chapter 7 - Head > 7.13 Relationships of the branches of the facial nerve and vessels to the parotid gland and duct

---

## 7.13 Relationships of the branches of the facial nerve and vessels to the parotid gland and duct

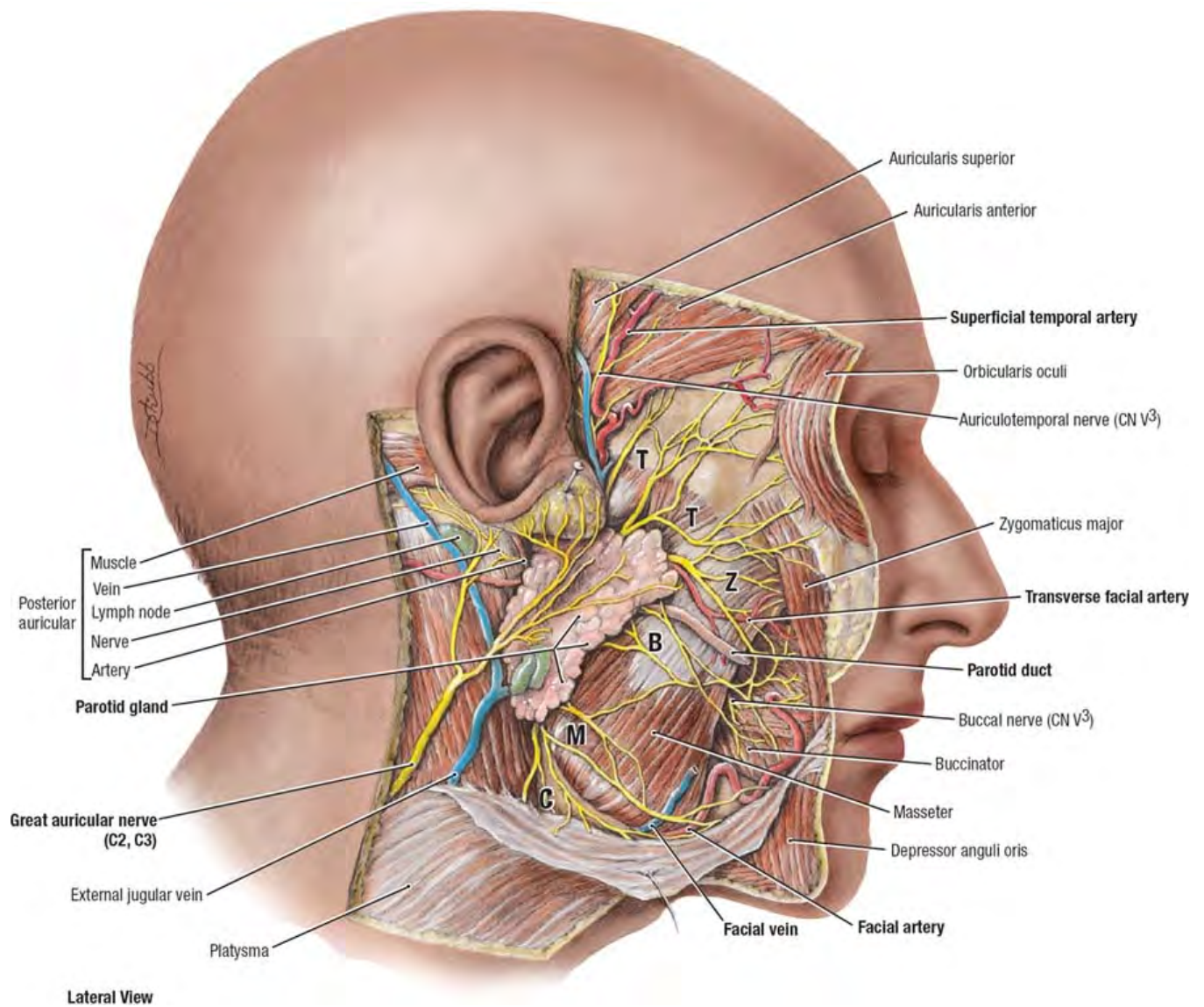
*Part of "Chapter 7 - Head "*

- The parotid duct extends across the masseter muscle just inferior to the zygomatic arch; the duct turns medially to pierce the buccinator.
- The facial nerve (CN VII) innervates the muscles of facial expression; it forms a plexus within the parotid gland, the branches of which radiate over the face, anastomosing with each other and the branches of the trigeminal nerve. After emerging from the stylomastoid foramen, the main stem of the facial nerve has posterior auricular, digastric, and stylohyoid branches; the parotid plexus gives rise to temporal (T), zygomatic (Z), buccal (B), marginal mandibular (M), cervical (C), and posterior auricular branches.

- During parotidectomy (surgical excision of the parotid gland), identification, dissection, and preservation of the branches of the facial nerve are critical.
- The parotid gland may become infected by infectious agents that pass through the bloodstream, as occurs in mumps, an acute communicable viral disease. Infection of the gland causes inflammation (parotiditis) and swelling of the gland. Severe pain occurs because the parotid sheath, innervated by the great auricular

nerve, limits swelling.

P.628



Authors: Agur, Anne M.R.; Dalley, Arthur F.

Title: *Grant's Atlas of Anatomy, 12th Edition*

Copyright ©2009 Lippincott Williams & Wilkins

> Table of Contents > Chapter 7 - Head > 7.14 Muscles of facial expression

---

## 7.14 Muscles of facial expression

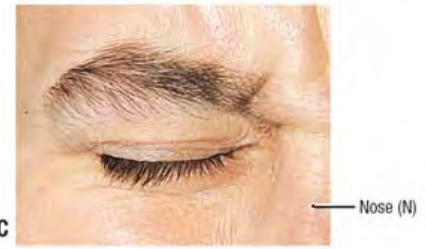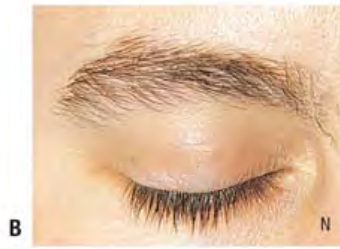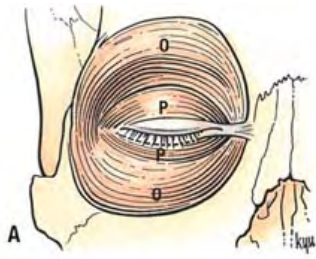
*Part of* "Chapter 7 - Head "

A. Orbicularis oculi: palpebral (P) and orbital (O) parts. The lacrimal portion (not shown) passes posterior to the lacrimal sac and helps spread of lacrimal secretions. B. Gentle closure of eyelid—palpebral part. C. Tight closure of eyelid—orbital part. D. Actions of selected muscles of facial expression.

---

P.629





Occipitofrontalis



Corrugator supercilii



Procerus + transverse part of nasalis




Orbicularis oculi



Lev. labii sup. alaeque nasi + alar part of nasalis



Buccinator + orbicularis oris



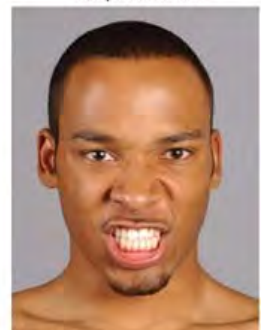
Zygomaticus major + minor



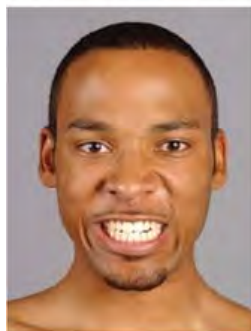Risorius




Risorius + depressor labii inferioris



Levator labii sup. + depressor labii



Dilators of mouth:  
Risorius plus levator labii superioris  
+ depressor labii inferioris



Orbicularis oris



Depressor anguli oris



Mentalis



Platysma

D

Anterior Views

Frontal belly of Occipitofrontalis  
Epicranial aponeurosis  
Skin of forehead  
Elevates eyebrows and forehead

Orbicularis oculi

Medial orbital margin, medial palpebral  
ligament, and lacrimal bone

Skin around margin of orbit; tarsal plate

Closes eyelids

Nasalis

Superior part of canine ridge of maxilla

Nasal cartilages

Flares nostrils

Orbicularis oris

Some fibers arise near median plane of maxilla superiorly and mandible inferiorly; other  
fibers arise from deep surface of skin

Mucous membrane of lips

Compresses and protrudes lips (e.g., purses them during whistling, sucking, and kissing)

Levator labii superioris

Frontal process of maxilla and infraorbital region

Skin of upper lip and alar cartilage of nose

Elevates lip, dilates nostril, and raises angle of mouth

Platysma

Superficial fascia of deltoid and pectoral regions

Mandible, skin of cheek, angle of mouth, and orbicularis oris

Depresses mandible and tenses skin of lower face and neck

Mentalis

Incisive fossa of mandible

Skin of chin

Protrudes lower lip

Buccinator

Mandible, pterygomandibular raphe, and alveolar processes of maxilla and mandible

Angle of mouth

Presses cheek against molar teeth to keep food between teeth; expels air from oral cavity  
as occurs when playing a wind instrument

<sup>a</sup> All of these muscles are supplied by the facial nerve (CN VII) .

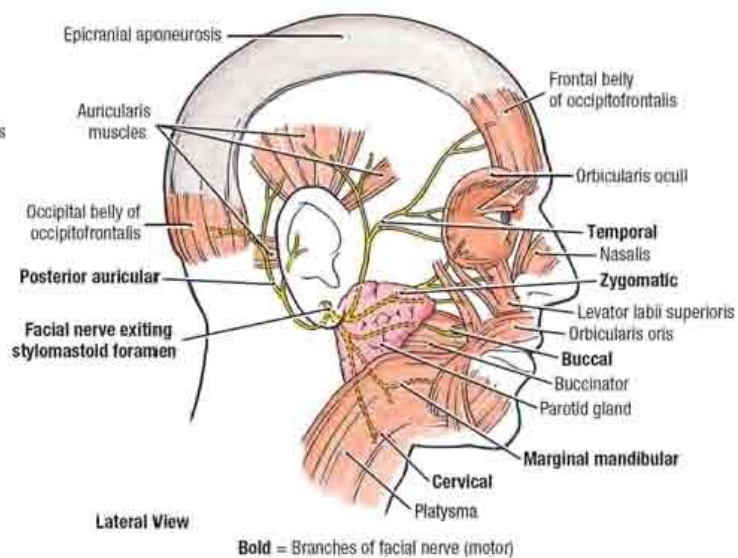
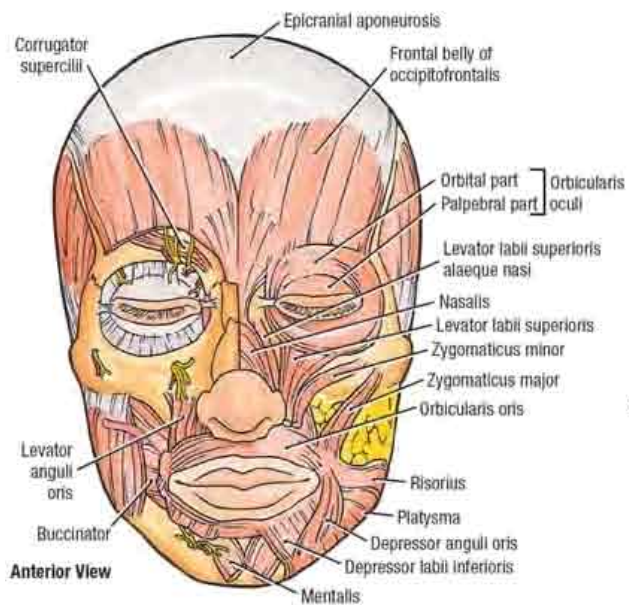
Muscle	Origin	Insertion	Action
--------	--------	-----------	--------

---



## Table 7.1 Main Muscles of Facial Expression <sup>a</sup>

Injury to the facial nerve (CN VII) or its branches produces paralysis of some or all of the facial muscles on the affected side (Bell palsy). The affected area sags, and facial expression is distorted. The loss of tonus of the orbicularis oculi causes the inferior lid to evert (fall away from the surface of the eyeball). As a result, the lacrimal fluid is not spread over the cornea, preventing adequate lubrication, hydration, and flushing of the cornea. This makes the cornea vulnerable to ulceration. If the injury weakens or paralyzes the buccinator and orbicularis oris, food will accumulate in the oral vestibule during chewing, usually requiring continual removal with a finger. When the sphincters or dilators of the mouth are affected, displacement of the mouth (drooping of the corner) is produced by gravity and contraction of unopposed contralateral facial muscles, resulting in food and saliva dribbling out of the side of the mouth. Weakened lip muscles affect speech. Affected people cannot whistle or blow a wind instrument effectively. They frequently dab their eyes and mouth with a handkerchief to wipe the fluid (tears and saliva) that runs from the drooping lid and mouth.



Authors: Agur, Anne M.R.; Dalley, Arthur F.

Title: *Grant's Atlas of Anatomy, 12th Edition*

Copyright ©2009 Lippincott Williams & Wilkins

> Table of Contents > Chapter 7 - Head > 7.15 Cutaneous branches of trigeminal nerve, muscles of facial expression, and eyelid

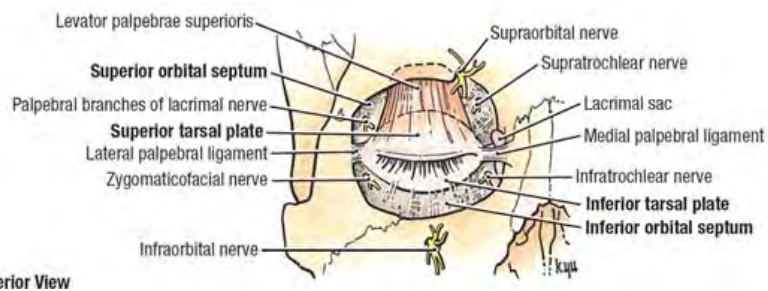
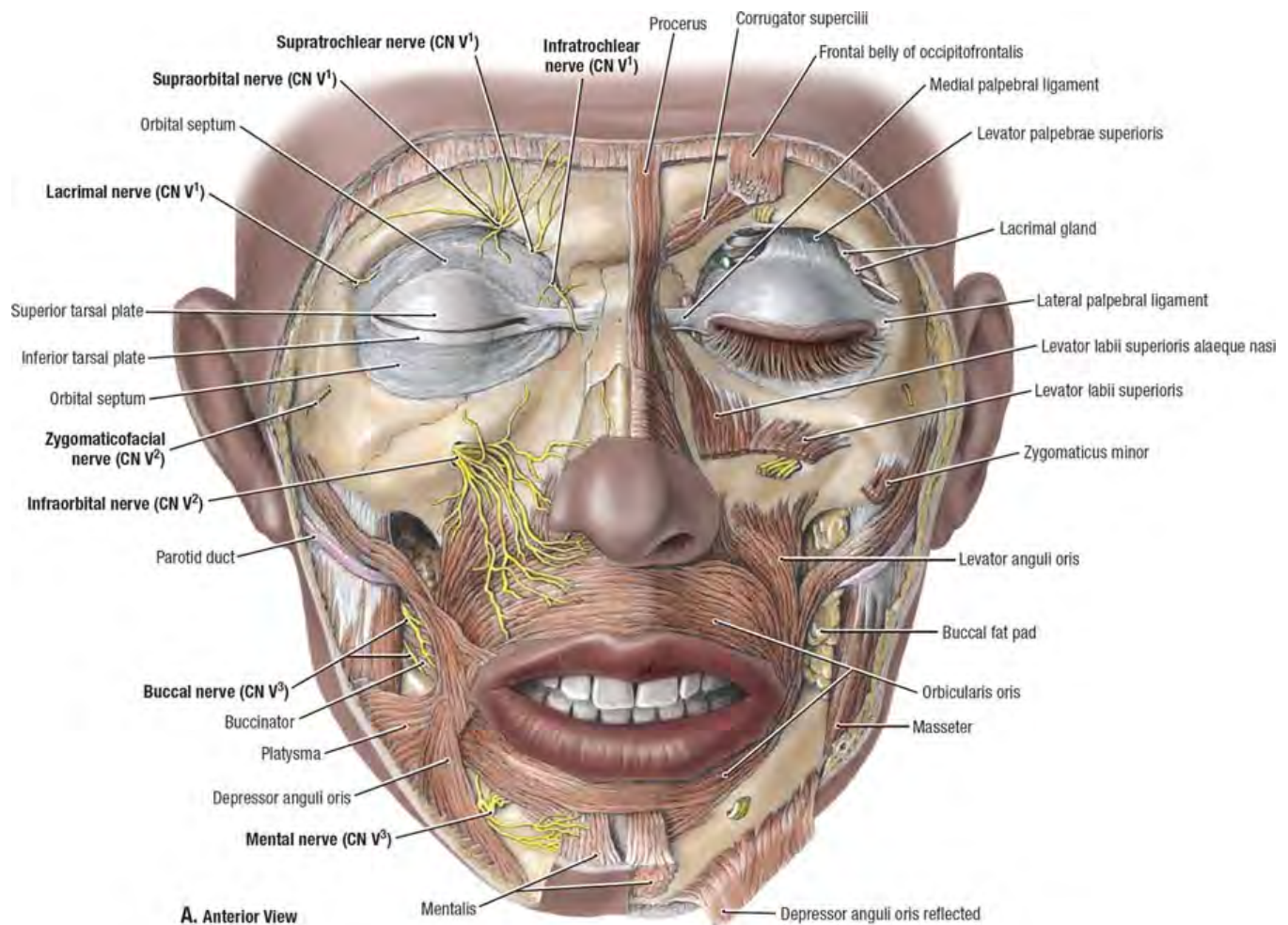
---

## 7.15 Cutaneous branches of trigeminal nerve, muscles of facial expression, and eyelid

*Part of "Chapter 7 - Head "*

A. Dissection of face. B. Orbital septum and eyelid.

Because the face does not have a distinct layer of deep fascia and the subcutaneous tissue is loose between the attachments of facial muscles, facial lacerations tend to gap (part widely). Consequently, the skin must be sutured carefully to prevent scarring. The looseness of the subcutaneous tissue also enables fluid and blood to accumulate in the loose connective tissue after bruising of the face.



## Frontal

### Ophthalmic nerve (CN V<sup>1</sup>)

Crosses orbit on superior aspect of levator palpebrae superioris; divides into supraorbital and supratrochlear branches; nose;

Skin of forehead, scalp, superior eyelid, and nose; conjunctiva of superior lid and mucosa of frontal sinus.

## Supraorbital

Continuation of frontal (CN V<sup>1</sup>)

Emerges through supraorbital notch, or foramen and breaks up into small branches

Mucous membrane of frontal sinus and conjunctiva (lining) of superior eyelid; skin of forehead as far as vertex

## Supratrochlear

Frontal nerve (CN V<sup>1</sup>)

Continues anteromedially along roof of orbit, passing lateral to trochlea

Skin in middle of forehead to hairline

## Infratrochlear

Nasociliary nerve (CN V<sup>1</sup>)

Follows medial wall of orbit passing inferior to trochlea to superior eyelid

Skin and conjunctiva (lining) of superior eye lid

## Lacrimal

Ophthalmic nerve (CN V<sup>1</sup>)

Passes through palpebral fascia of superior eyelid near lateral angle (canthus) of eye

Lacrimal gland and small area of skin and conjunctiva of lateral part of superior eyelid

## External nasal

Anterior ethmoidal nerve (CN V<sup>1</sup>)

Runs in nasal cavity and emerges on face between nasal bone and lateral nasal cartilage

Skin on dorsum of nose, including tip of nose

## Zygomatic

Maxillary nerve (CN V<sup>2</sup>)

Arises in floor of orbit, divides into zygomaticofacial and zygomaticotemporal nerves, which traverse foramina of same name

Skin over zygomatic arch and anterior temporal region; carries postsynaptic parasympathetic fibers from pterygopalatine ganglion to lacrimal nerve

## Infraorbital

Terminal branch of maxillary (CN V<sup>2</sup>)

Runs in floor of orbit and emerges at infraorbital foramen

Skin of cheek, inferior lid, lateral side of nose and inferior septum and superior lip, upper premolar incisors and canine teeth; mucosa of maxillary sinus and superior lip

## Auriculotemporal

Mandibular nerve (CN V<sup>3</sup>)



From posterior division of CN V<sup>3</sup>, it passes between neck of mandible and external acoustic meatus to accompany superficial temporal artery

Skin anterior to ear and posterior temporal region, tragus and part of helix of auricle and ro external acoustic meatus and upper tympanic membrane

Buccal

Mandibular nerve (CN V<sup>3</sup>)

From the anterior division of CN V<sup>3</sup> in infratemporal fossa, it passes anteriorly to reach cheek

Skin and mucosa of cheek, buccal gingiva adjacent to 2nd and 3rd molar teeth

Mental

Terminal branch of inferior alveolar nerve (CN V<sup>3</sup>)

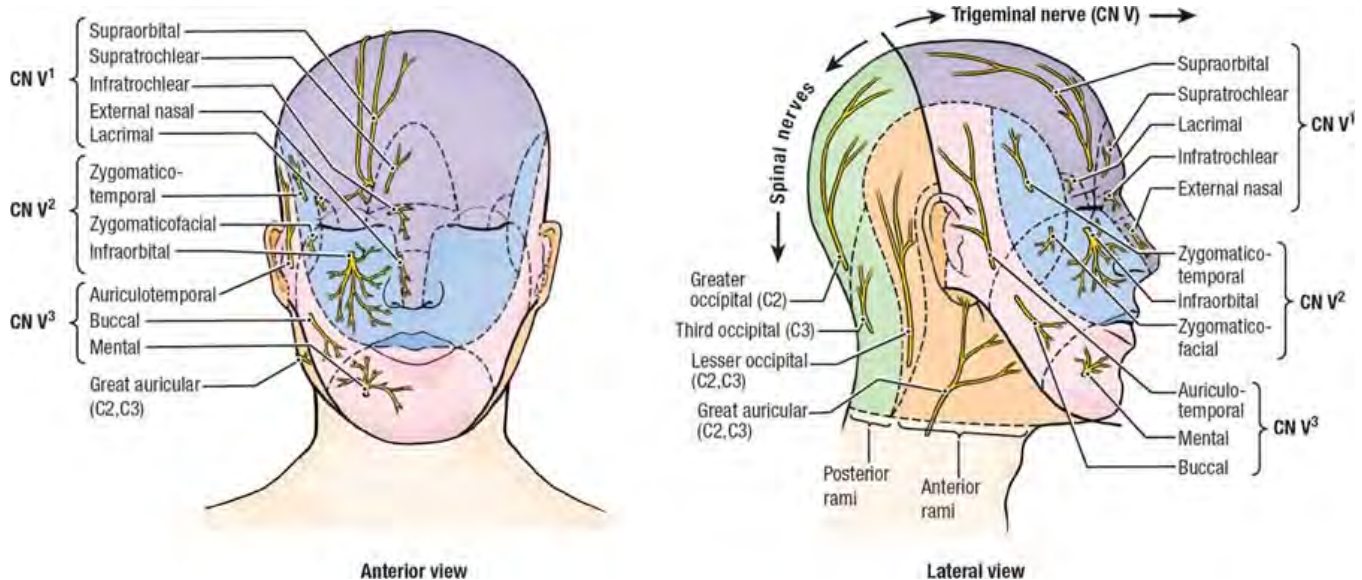
Emerges from mandibular canal at mental foramen

Skin of chin and inferior lip and mucosa of lower lip

Nerve    Origin    Course    Distribution

Table 7.2 Nerves of Face and Scalp

P.632



Facial

External carotid artery

Ascends deep to submandibular gland, winds around inferior border of mandible and enters

Muscles of facial expression and face



Inferior labial

Facial artery near angle of mouth

Runs medially in lower lip

Lower lip and chin

Superior labial

Runs medially in lower lip

Upper lip and ala (side) and septum of nose

Lateral nasal

Facial artery as it ascends alongside nose

Passes to ala of nose

Skin on ala and dorsum of nose

Angular

Terminal branch of facial artery

Passes to medial angle (canthus) of eye

Superior part of cheek and lower eyelid

Occipital

External carotid artery

Passes medial to posterior belly of digastric and mastoid process; accompanies occipital nerve to occipital region

Scalp of back of head, as far as vertex

Posterior auricular

Passes posteriorly, deep to parotid, along styloid process between mastoid and ear

Scalp posterior to auricle and auricle

Superficial temporal

Smaller terminal branch of external carotid artery

Ascends anterior to ear to temporal region and ends in scalp

Facial muscles and skin of frontal and temporal regions

Transverse facial

Superficial temporal artery within parotid gland

Crosses face superficial to masseter and inferior to zygomatic arch

Parotid gland and duct, muscles and skin of face

Mental

Terminal branch of inferior alveolar artery

Emerges from mental foramen and passes to chin

Facial muscles and skin of chin

\*Supraorbital

Terminal branch of ophthalmic artery, a branch of internal carotid artery

Passes superiorly from supraorbital foramen

Muscles and skin of forehead and scalp

\*Supratrochlear

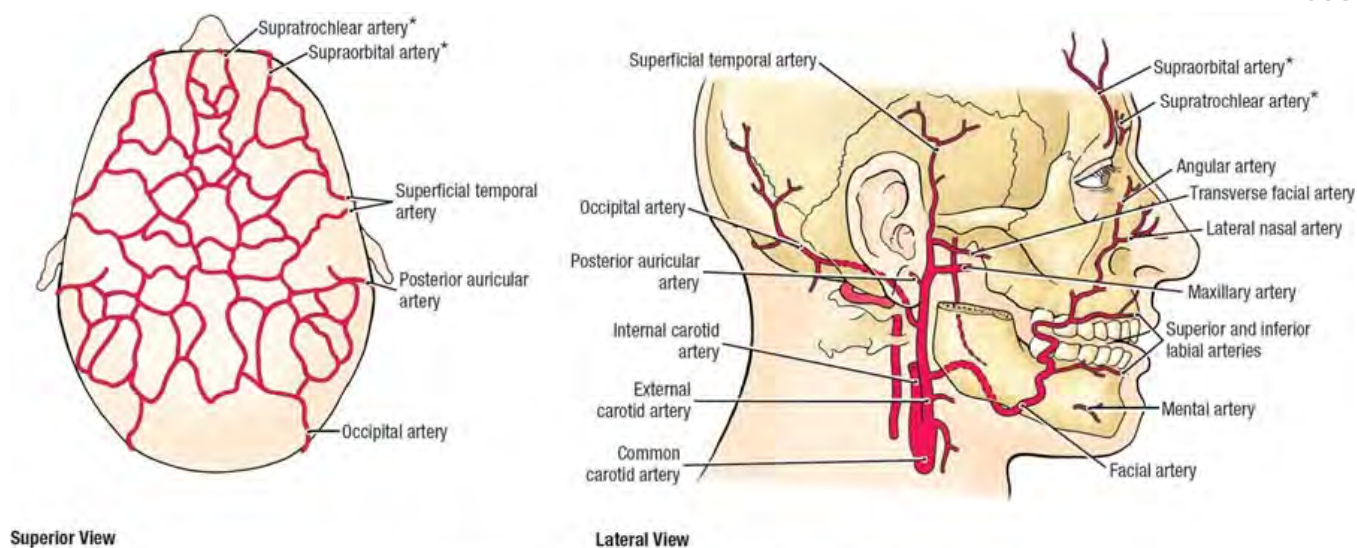
Passes superiorly from supratrochlear notch

Muscles and skin of scalp

Artery    Origin    Course    Distribution

Table 7.3 Arteries of Face and Scalp

P.633



\*Source= internal carotid artery (ophthalmic artery); all other labeled arteries are from external carotid

Supratrochlear

Begins from a venous plexus on the forehead and scalp, through which it communicates with frontal branch of the superficial temporal vein, its contralateral partner, and the supraorbital vein

Descends near the midline of the forehead to the root of the nose where it joins the

supraorbital vein

Angular veins at the root of the nose.

Anterior part of scalp and forehead

Supraorbital

Begins in the forehead by anastomosing with a frontal tributary of the superficial temporal v

Passes medially superior to the orbit and joins the supratrochlear vein; a branch passes thro  
the supra-orbital notch and joins with the superior ophthalmic vein

Angular

Begins at root of nose by union of supratrochlear and supra orbital veins

Descends obliquely along the root and side of the nose to the inferior margin of the orbit

Becomes the facial vein at the inferior margin of the orbit

In addition to above, drains upper and lower lids and conjunctiva; may receive drainage from  
cavernous sinus margin of the orbit

Facial

Continuation of angular vein past inferior margin of orbit

Descends along lateral border of the nose, receiving external nasal and inferior palpebral ve  
then obliquely across face to mandible; receives anterior division of retromandibular vein, &  
which it is sometimes called the common facial vein

Internal jugular vein opposite or inferior to the level of the hyoid bone

Anterior scalp and forehead, eyelids, external nose, and anterior cheek, lips, chin, and  
submandibular gland

Deep facial

Pterygoid venous plexus

Runs anteriorly on maxilla above buccinator and deep to masseter, emerging medial to ante  
border of masseter onto face

Enters posterior aspect of facial vein

Infratemporal fossa (most areas supplied by maxillary artery)

Superficial temporal

Begins from a widespread plexus of veins on the side of the scalp, and along the zygomatic &

Its frontal and parietal tributaries unite anterior to the auricle; it crosses the temporal root  
the zygomatic arch to pass from the temporal region and enters the substance of the paroti  
gland

Joins the maxillary vein posterior to the neck of the mandible to form the retromandibular v

Side of the scalp, superficial aspect of the temporal muscle, and external ear

## Retromandibular

Formed anterior to the ear by the union of the superficial temporal and maxillary veins.

Runs posterior and deep to the ramus of the mandible through the substance of the parotid gland; communicates at its inferior end with the facial vein

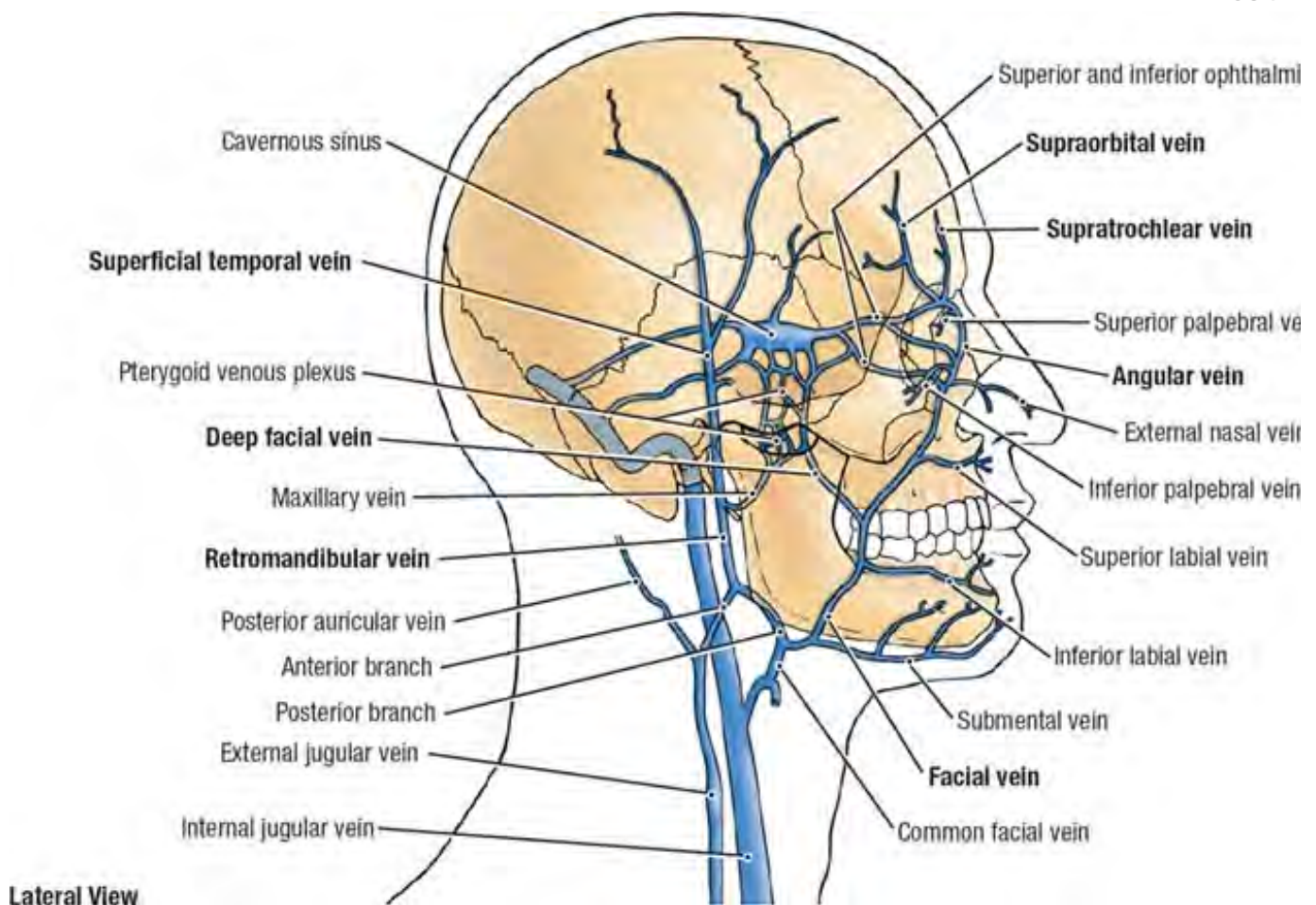
*Anterior branch* unites with facial vein to form common facial vein; *posterior branch* unites with the posterior auricular vein to form the external jugular vein

Parotid gland and masseter muscle

Vein	Origin	Course	Termination	Area Drained
------	--------	--------	-------------	--------------

Table 7.4 Veins of Face

P.634



Authors: Agur, Anne M.R.; Dalley, Arthur F.

Title: *Grant's Atlas of Anatomy, 12th Edition*

Copyright ©2009 Lippincott Williams & Wilkins

> Table of Contents > Chapter 7 - Head > 7.16 Branches of facial nerve, muscles of facial expression, and scalp

---

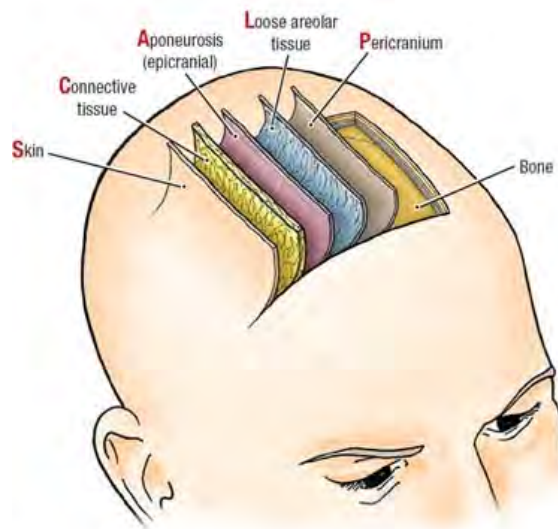
## 7.16 Branches of facial nerve, muscles of facial expression, and scalp

*Part of "Chapter 7 - Head "*

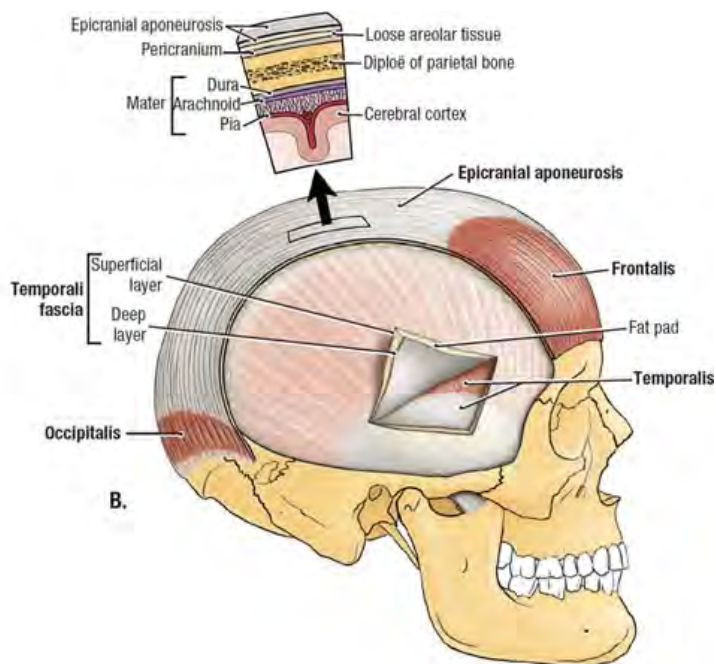
A. Layers of scalp. B. Occipitofrontalis and temporal muscles and fascia. C. Sensory nerves and arteries of the scalp. D. Diploic veins. The outer layer of the compact bone of the cranium has been filed away, exposing the channels for the diploic veins in the cancellous bone that composes the diploë.

The loose areolar tissue layer is the danger area of the scalp because pus or blood spreads easily in it. Infection in this layer can pass into the cranial cavity through emissary veins, which pass through parietal foramina in the calvaria and reach intracranial structures such as the meninges. An infection cannot pass into the neck because the occipital belly of the occipitofrontalis attaches to the occipital bone and mastoid parts of the temporal bones. Neither can a scalp infection spread laterally beyond the zygomatic arches because the epicranial aponeurosis is continuous with the temporalis fascia that attaches to these arches. An infection or fluid (e.g., pus or blood) can enter the eyelids and the root of the nose because the frontal belly of the occipitofrontalis inserts into the skin and dense subcutaneous tissue and does not attach to the bone. Ecchymoses, or purple patches, develop as a result of extravasation of blood into the subcutaneous tissue and skin of the eyelids and surrounding regions.

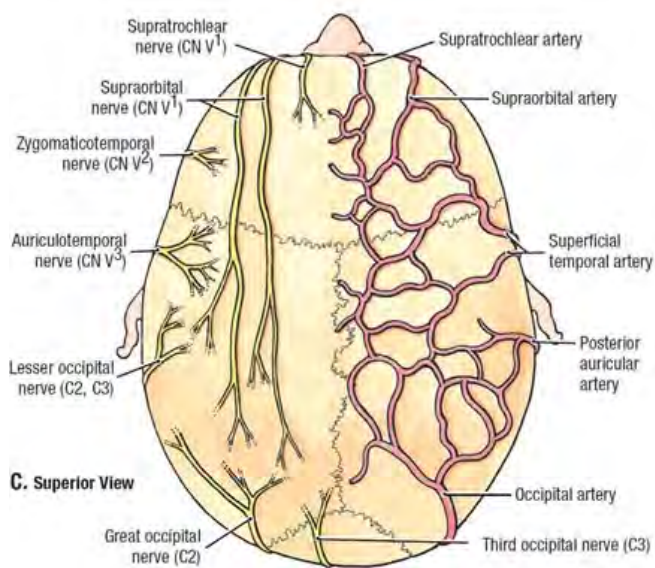




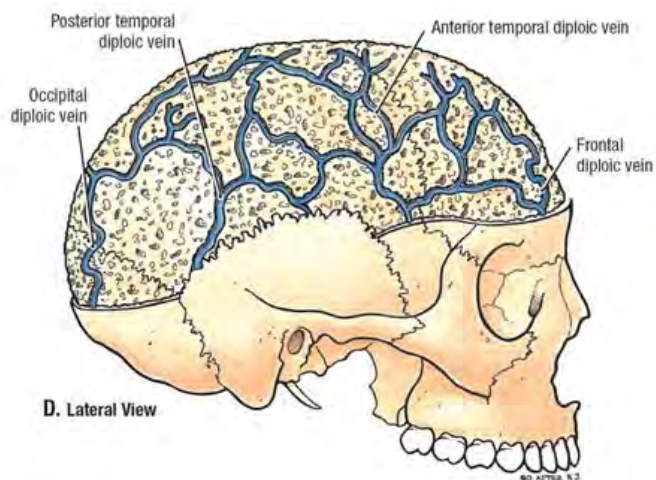
**A. Superolateral view**



**B.**



**C. Superior View**



**D. Lateral View**



Authors: Agur, Anne M.R.; Dalley, Arthur F.

Title: *Grant's Atlas of Anatomy, 12th Edition*

Copyright ©2009 Lippincott Williams & Wilkins

> Table of Contents > Chapter 7 - Head > 7.17 Middle meningeal artery and pterion

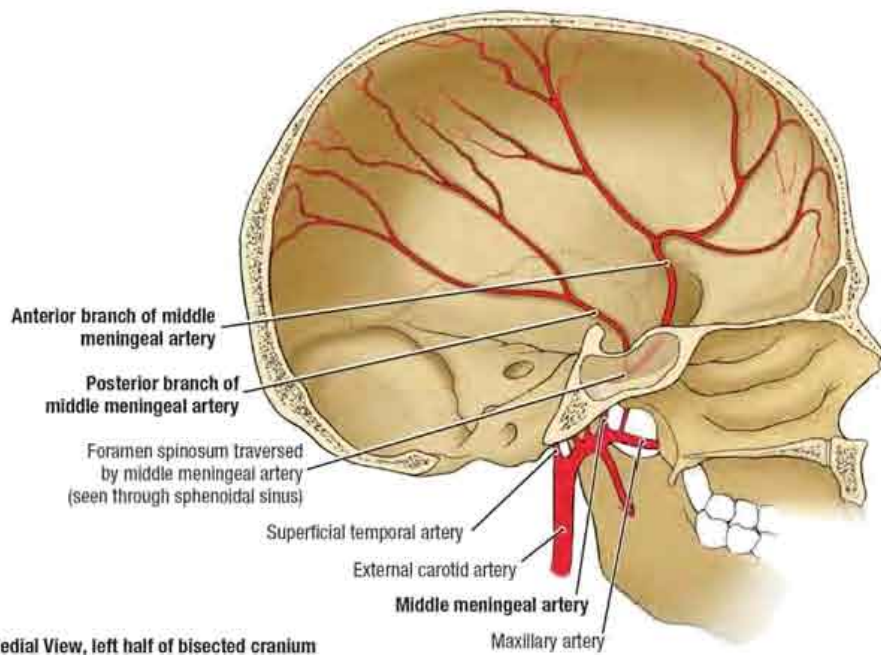
---

## 7.17 Middle meningeal artery and pterion

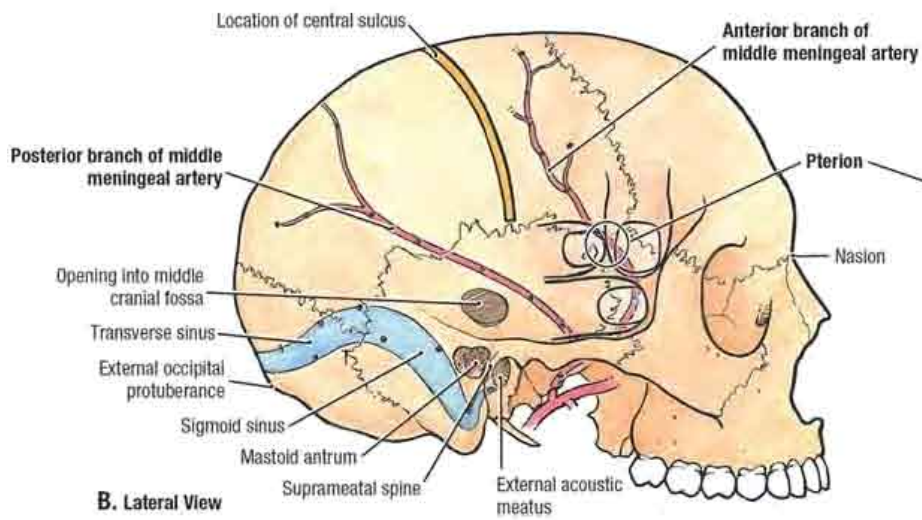
*Part of* "Chapter 7 - Head "

A. Course of the middle meningeal artery in the cranium. B. Surface projections of internal features of the neurocranium. C. Locating the pterion. The pterion is located two fingers breadth superior to the zygomatic arch and one thumb breadth posterior to the frontal process of the zygomatic bone (approximately 4 cm superior to the midpoint of the zygomatic arch); the anterior branch of the middle meningeal artery crosses the pterion.

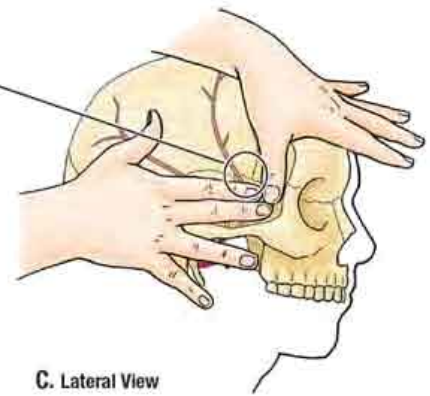
A hard blow to the side of the head may fracture the thin bones forming the pterion, rupturing the anterior branch of the middle meningeal artery crossing the pterion. The resulting extradural (epidural) hematoma exerts pressure on the underlying cerebral cortex. Untreated middle meningeal artery hemorrhage may cause death in a few hours.



**A. Medial View, left half of bisected cranium**



**B. Lateral View**



**C. Lateral View**

Authors: Agur, Anne M.R.; Dalley, Arthur F.

Title: *Grant's Atlas of Anatomy, 12th Edition*

Copyright ©2009 Lippincott Williams & Wilkins

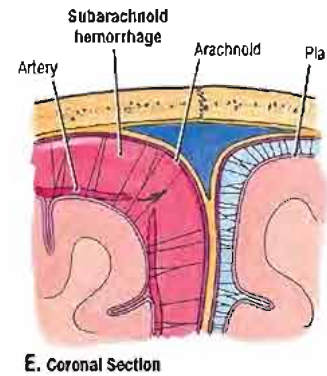
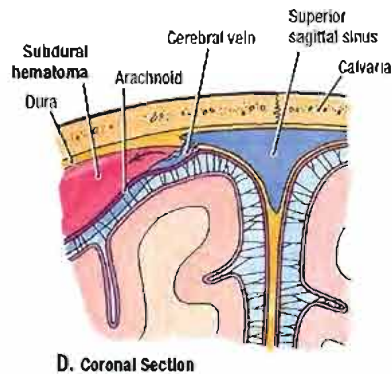
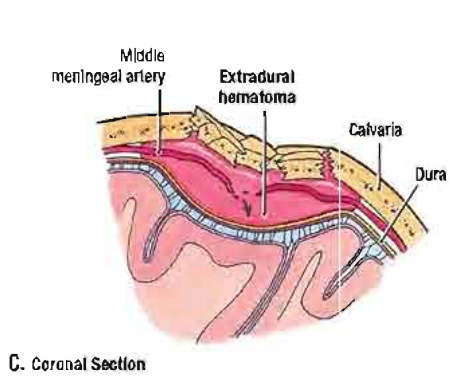
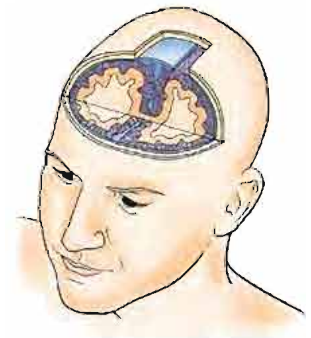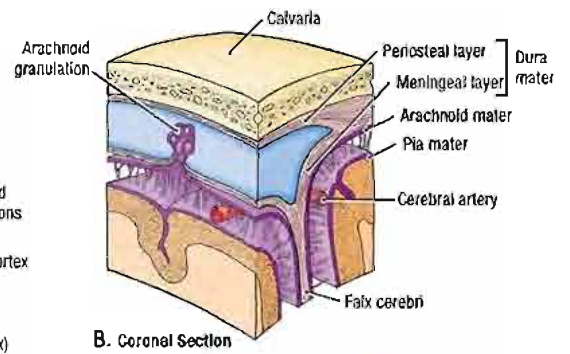
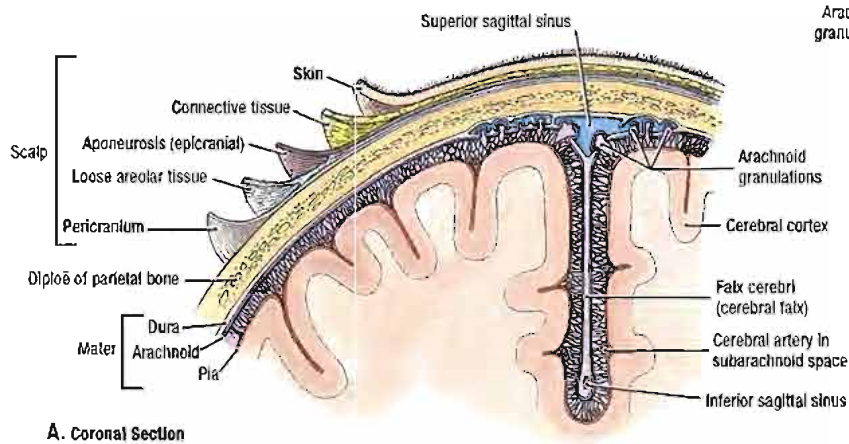
> Table of Contents > Chapter 7 - Head > 7.18 Layers of the scalp and meninges

---

## 7.18 Layers of the scalp and meninges

*Part of "Chapter 7 - Head "*

A. Scalp, cranium, and meninges. B. Meninges and their relationship to the calvaria. The three meningeal spaces include the extradural (epidural) space between the cranial bones and dura, which is a potential space normally (it becomes a real space pathologically if blood accumulates in it); the similarly potential subdural space between the dura and arachnoid; and the subarachnoid space, the normal realized space between the arachnoid and pia, which contains cerebrospinal fluid (CSF). C. Extradural (epidural) hematomas result from bleeding from a torn middle meningeal artery. D. Subdural hematomas commonly result from tearing of a cerebral vein as it enters the superior sagittal sinus. E. Subarachnoid hemorrhage results from bleeding within the subarachnoid space, e.g., from rupture of an aneurysm.



Authors: Agur, Anne M.R.; Dalley, Arthur F.

Title: *Grant's Atlas of Anatomy, 12th Edition*

Copyright ©2009 Lippincott Williams & Wilkins

> Table of Contents > Chapter 7 - Head > 7.19 Dura mater and arachnoid granulations

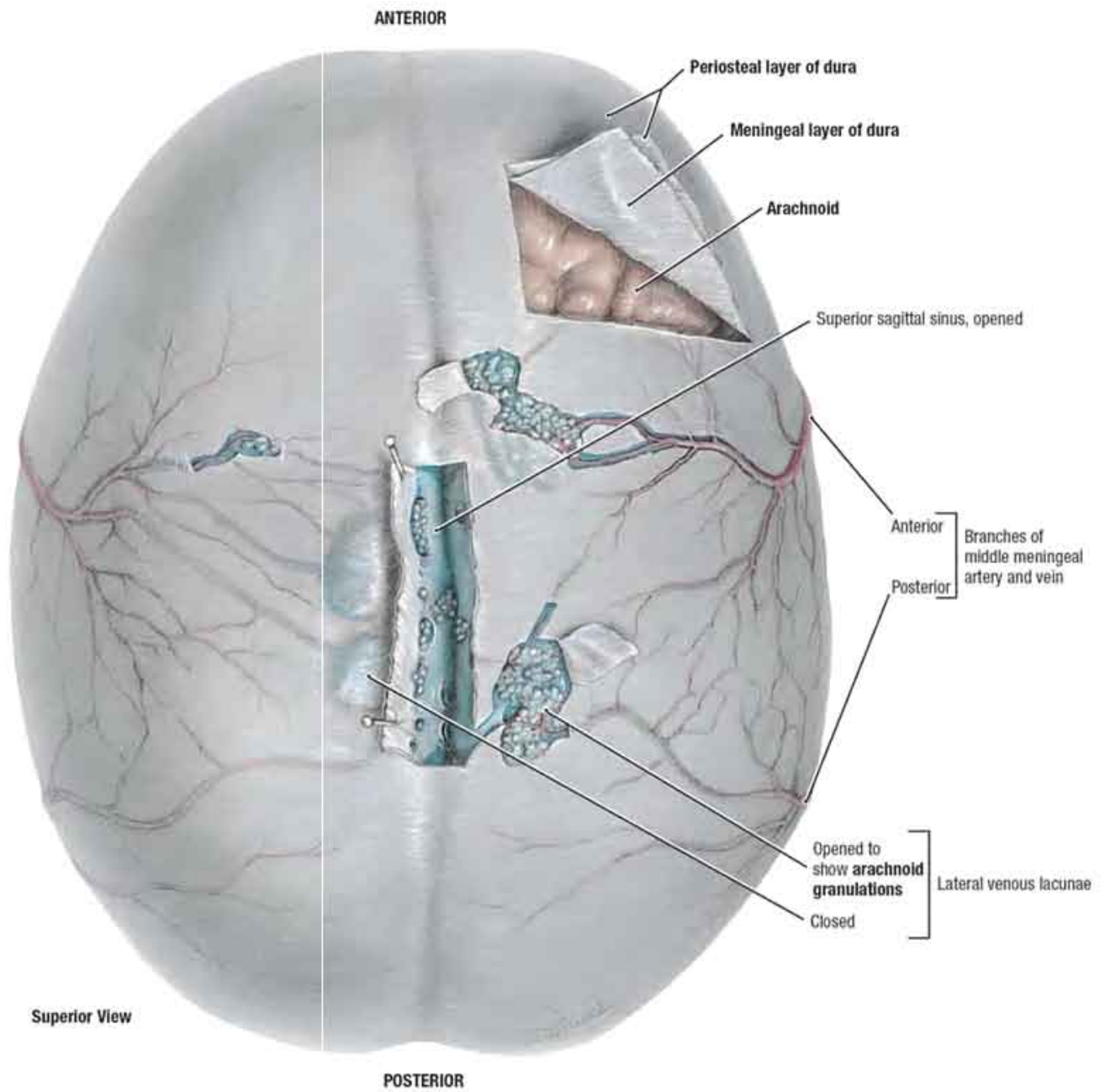
---

## 7.19 Dura mater and arachnoid granulations

*Part of "Chapter 7 - Head"*

- The calvaria is removed. In the median plane, the thick roof of the superior sagittal sinus is partly pinned aside, and laterally, the thin roofs of two lateral lacunae are reflected.
- The middle meningeal artery lies in a venous channel (middle meningeal vein), which enlarges superiorly into a lateral lacunae. Other channels drain the lateral lacunae into the superior sagittal sinus.
- Arachnoid granulations in the lacunae are responsible for absorption of CSF from the subarachnoid space into the venous system.

- The dura is sensitive to pain, especially where it is related to the dural venous sinuses and meningeal arteries. Although the causes of headache are numerous, distention of the scalp or meningeal vessels (or both) is believed to be one cause of headache. Many headaches appear to be dural in origin, such as the headache occurring after a lumbar spinal puncture for removal of CSF. These headaches are thought to result from stimulation of sensory nerve endings in the dura.





Authors: Agur, Anne M.R.; Dalley, Arthur F.

Title: *Grant's Atlas of Anatomy, 12th Edition*

Copyright ©2009 Lippincott Williams & Wilkins

> Table of Contents > Chapter 7 - Head > 7.20 Dura mater

---

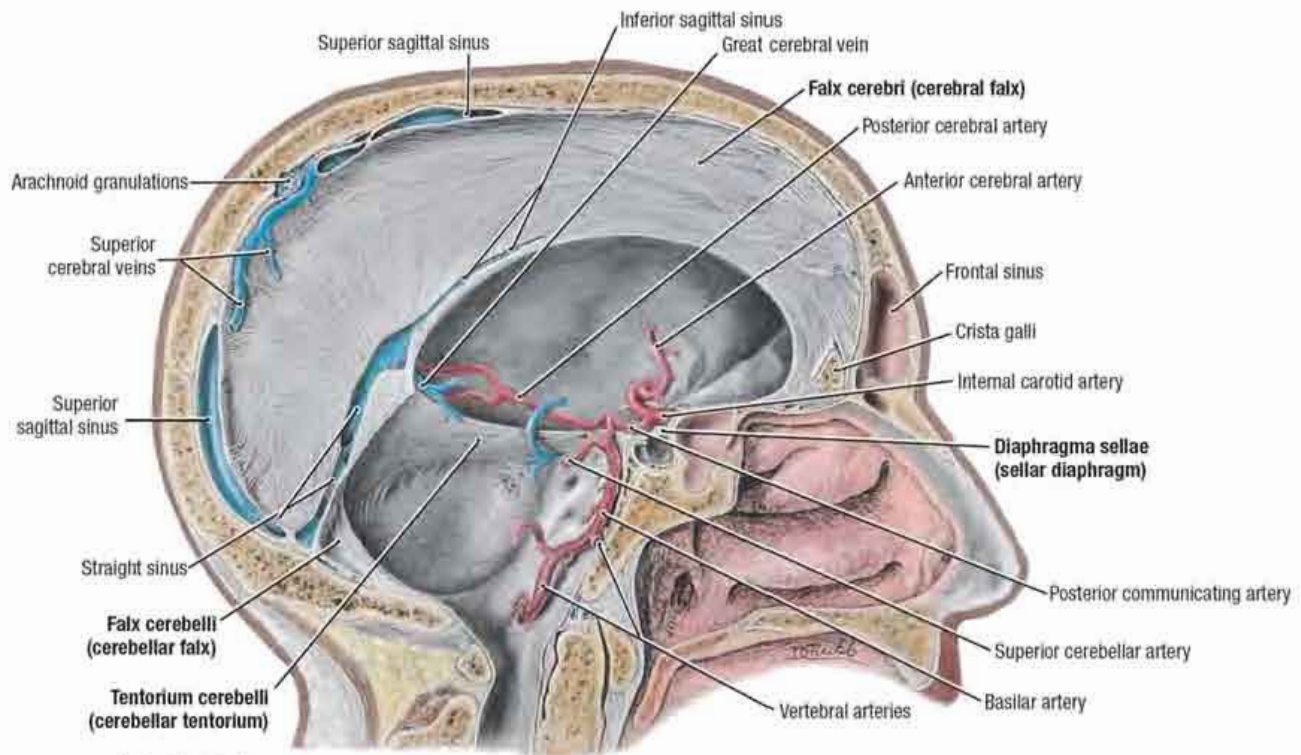
## 7.20 Dura mater

*Part of* "Chapter 7 - Head "

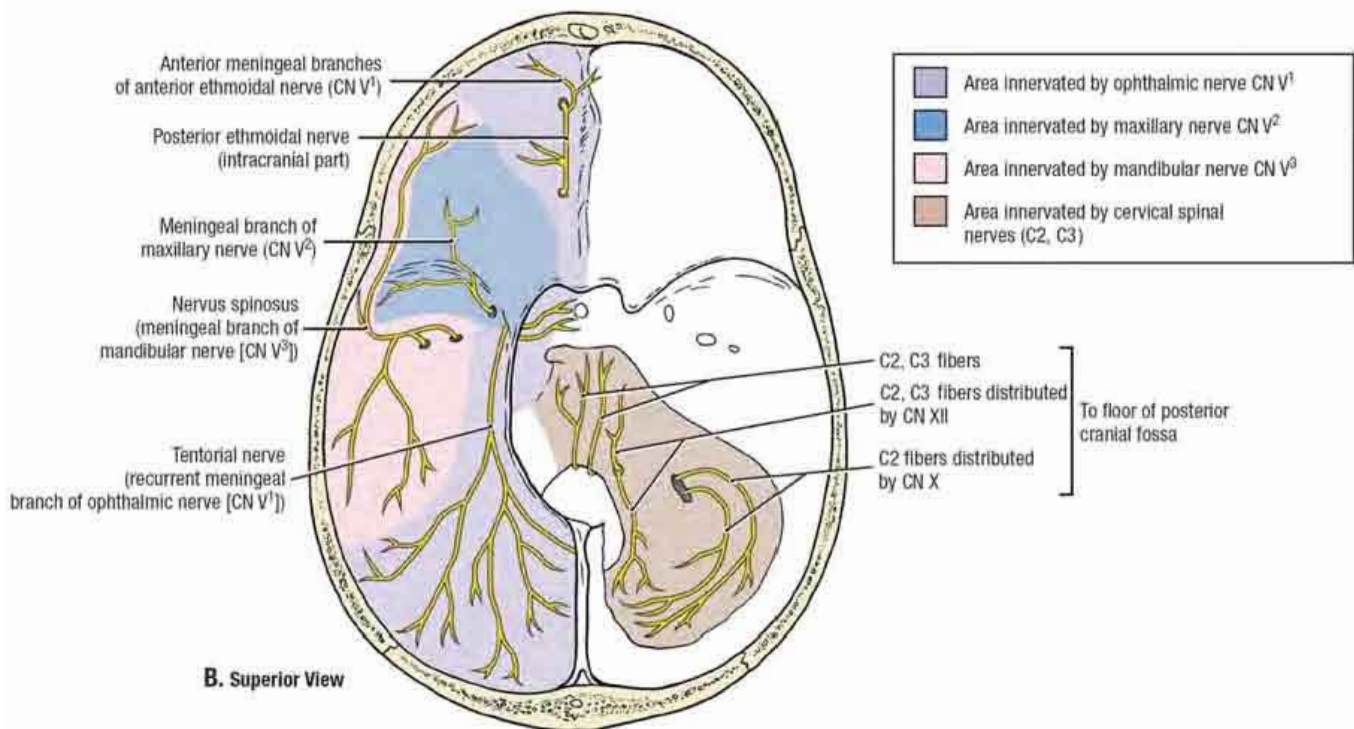
A. Reflections of the dura mater. B. Innervation of the dura of the cranial base. The dura of the cranial base is innervated by branches of the trigeminal nerve and sensory fibers of cervical spinal nerves (C2, C3) passing directly from those nerves or via meningeal branches of the vagus (CN X) and hypoglossal (CN XII) nerves.

---

P.639



**A. Sagittal Section**



**B. Superior View**

Authors: Agur, Anne M.R.; Dalley, Arthur F.

Title: *Grant's Atlas of Anatomy, 12th Edition*

Copyright ©2009 Lippincott Williams & Wilkins

> Table of Contents > Chapter 7 - Head > 7.21 Venous sinuses of the dura mater

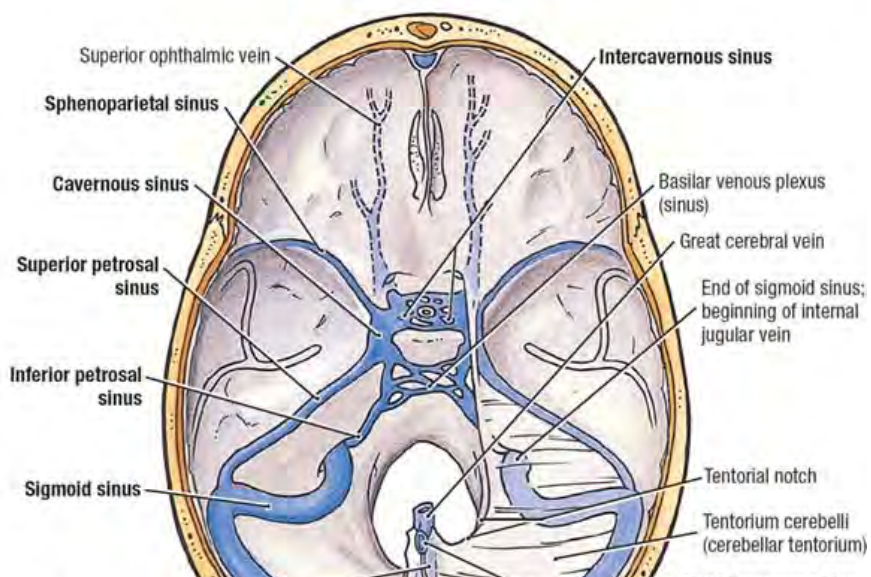
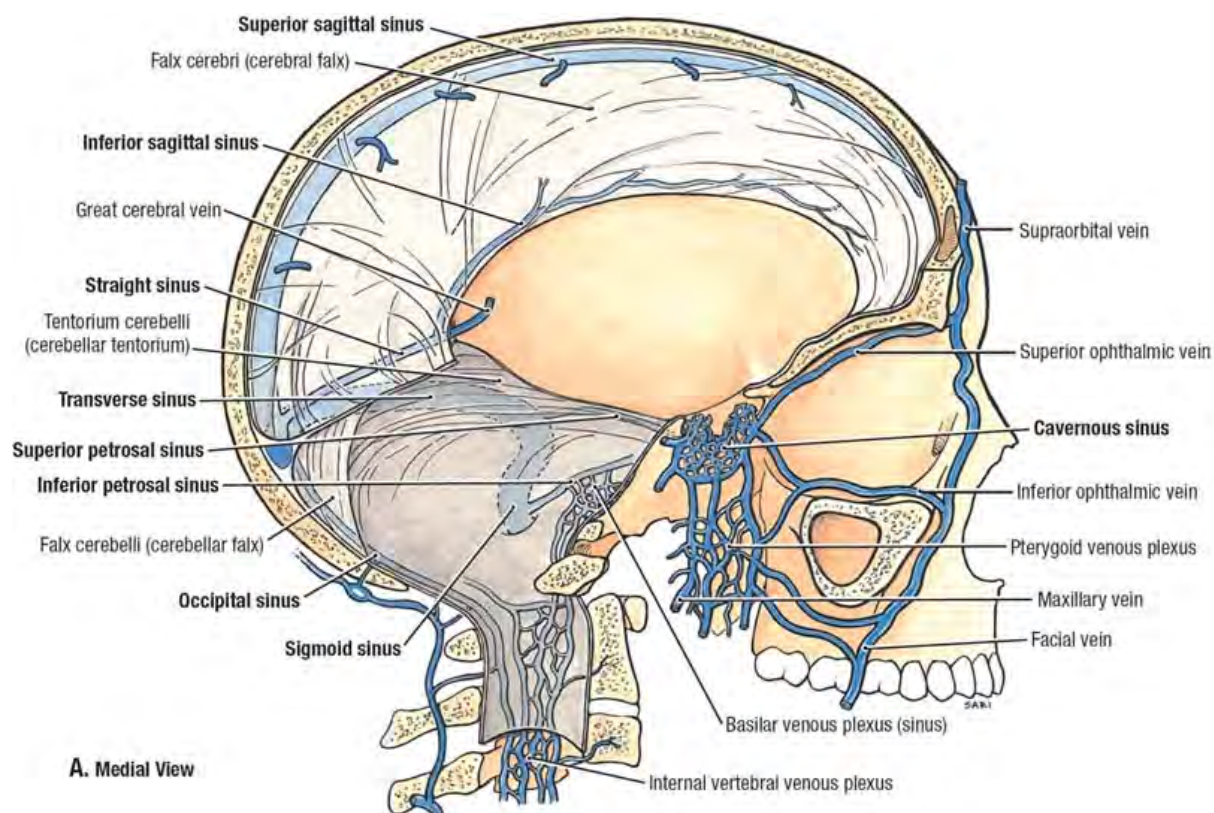
---

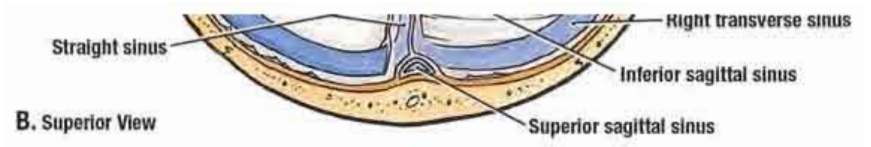## 7.21 Venous sinuses of the dura mater

*Part of "Chapter 7 - Head "*

A. Schematic of left half of cranial cavity and right facial skeleton. B. Venous sinuses of the cranial base.

- The superior sagittal sinus is at the superior border of the falx cerebri, and the inferior sagittal sinus is in its free border. The great cerebral vein joins the inferior sagittal sinus to form the straight sinus.
  - The superior sagittal sinus usually becomes the right transverse sinus, right sigmoid sinus, and right internal jugular vein; the straight sinus similarly drains through the left transverse sinus, left sigmoid sinus, and left internal jugular vein.
  - The cavernous sinus communicates with the veins of the face through the ophthalmic veins and pterygoid plexus of veins and with the sigmoid sinus through the superior and inferior petrosal sinuses.
- The basilar and occipital sinuses communicate through the foramen magnum with the internal vertebral venous plexuses. Because these venous channels are valveless, compression of the thorax, abdomen, or pelvis, as occurs during heavy coughing and straining, may force venous blood from these regions into the internal vertebral venous system and from it into the dural venous sinuses. As a result, pus in abscesses and tumor cells in these regions may spread to the vertebrae and brain.







Authors: Agur, Anne M.R.; Dalley, Arthur F.

Title: *Grant's Atlas of Anatomy, 12th Edition*

Copyright ©2009 Lippincott Williams & Wilkins

> Table of Contents > Chapter 7 - Head > 7.22 Nerves and vessels of the interior of the base of the cranium

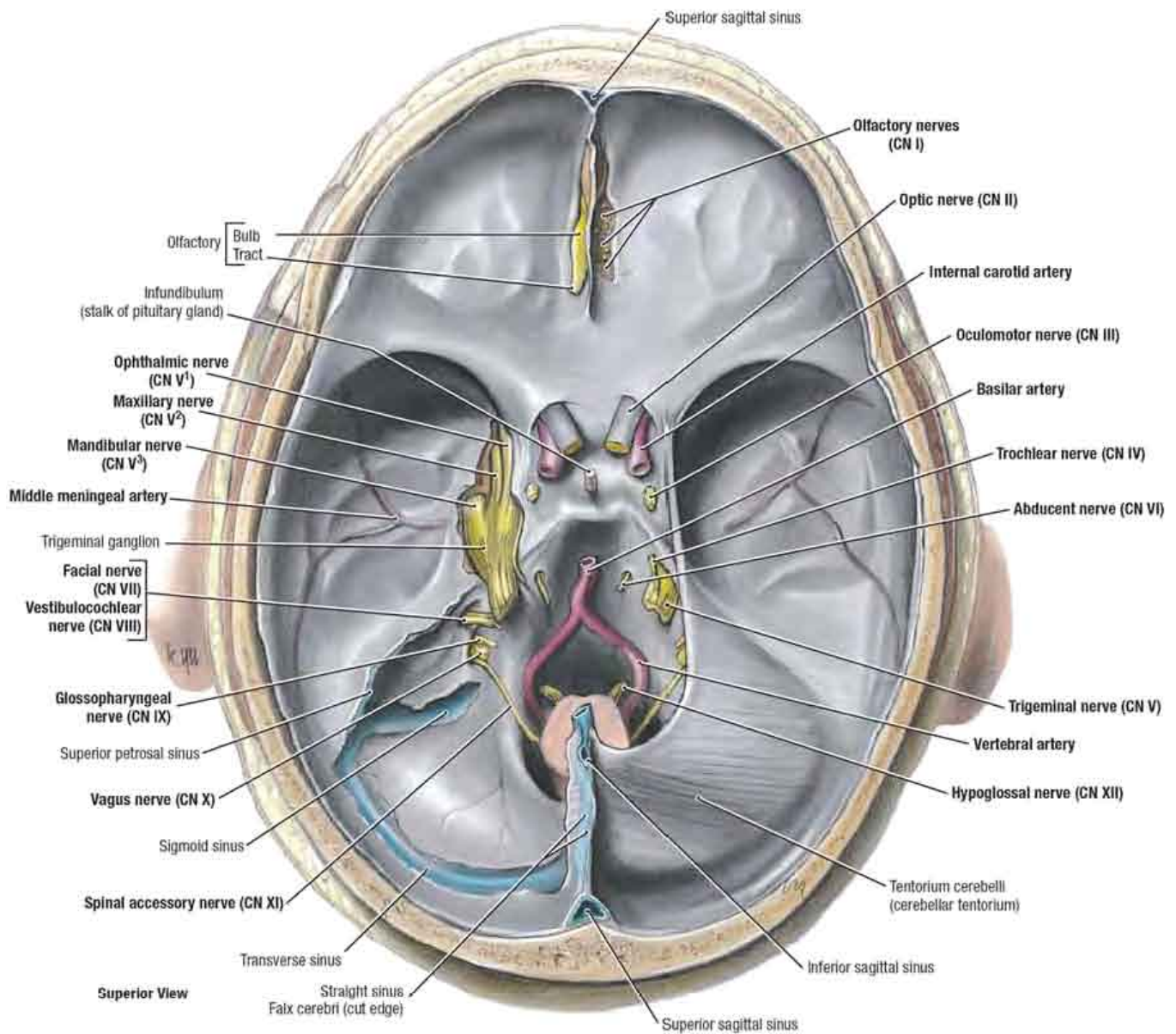
---

## 7.22 Nerves and vessels of the interior of the base of the cranium

*Part of "Chapter 7 - Head "*

- On the left of the specimen, the dura mater forming the roof of the trigeminal cave is cut away to expose the trigeminal nerve and its three branches and the sigmoid sinus. The tentorium cerebelli is removed to reveal the transverse and superior petrosal sinuses.
- The frontal lobes of the cerebrum are located in the anterior cranial fossa, the temporal lobes in the middle cranial fossa, and the brainstem and cerebellum in the posterior cranial fossa; the occipital lobes rest on the tentorium cerebelli.
- The sites where the 12 cranial nerves and the internal carotid, vertebral, basilar, and middle meningeal arteries penetrate the dura mater are shown.





Authors: Agur, Anne M.R.; Dalley, Arthur F.

Title: *Grant's Atlas of Anatomy, 12th Edition*

Copyright ©2009 Lippincott Williams & Wilkins

> Table of Contents > Chapter 7 - Head > 7.23 Base of brain and superficial origins of cranial nerves

---

## 7.23 Base of brain and superficial origins of cranial nerves

*Part of "Chapter 7 - Head "*

Foramina of skull and their associated cranial nerve(s) are listed below.

### Openings by which Cranial Nerves Exit Cranial Cavity

Anterior cranial fossa

Cribriform foramina in cribriform plate

Axons of olfactory cells in olfactory epithelium form olfactory nerves (CN I)

Middle cranial fossa

Optic canal

Optic nerve (CN II)

Superior orbital fissure

Ophthalmic nerve (CN V<sup>1</sup> ), oculomotor nerve (CN III), trochlear nerve (CN IV), abducent nerve (CN VI) and branches of ophthalmic nerve (CN V<sup>1</sup> )

Foramen rotundum

Maxillary nerve (CN V<sup>2</sup> )

Foramen ovale

Mandibular nerve (CN V<sup>3</sup> )

Posterior cranial fossa

Foramen magnum

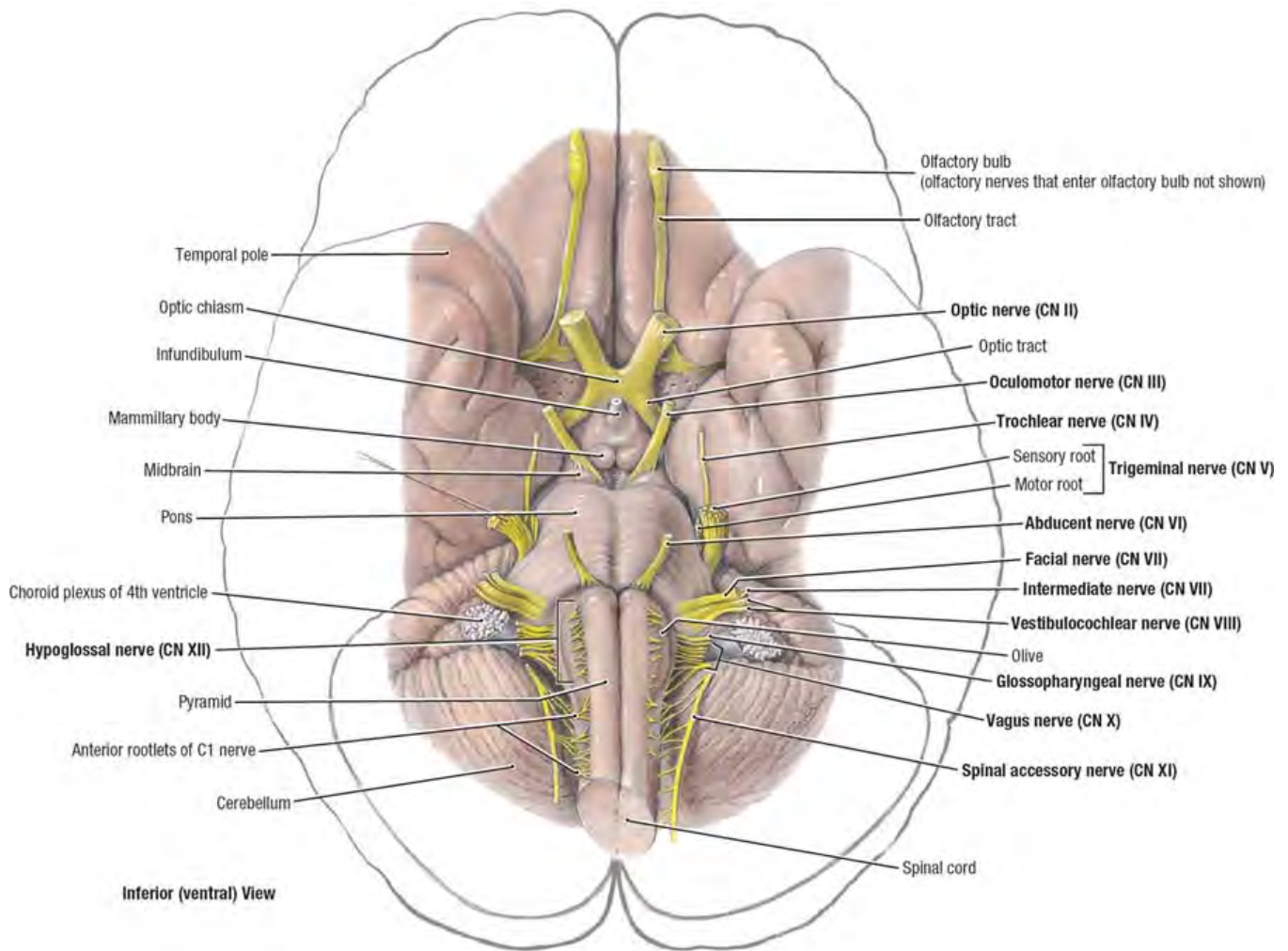
Spinal accessory nerve (CN XI)

Jugular foramen

Glossopharyngeal nerve (CN IX), vagus nerve (CN X), and spinal accessory nerve (CN XI)  
Hypoglossal canal  
Hypoglossal nerve (CN XII)

Foramina/Apertures    Cranial nerve

P.642



Authors: Agur, Anne M.R.; Dalley, Arthur F.

Title: *Grant's Atlas of Anatomy, 12th Edition*

Copyright ©2009 Lippincott Williams & Wilkins

> Table of Contents > Chapter 7 - Head > 7.24 Posterior exposures of cranial nerves

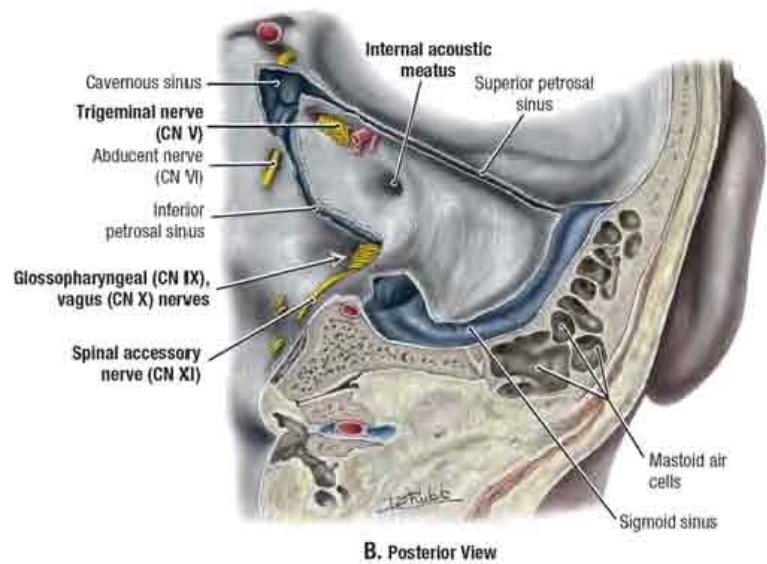
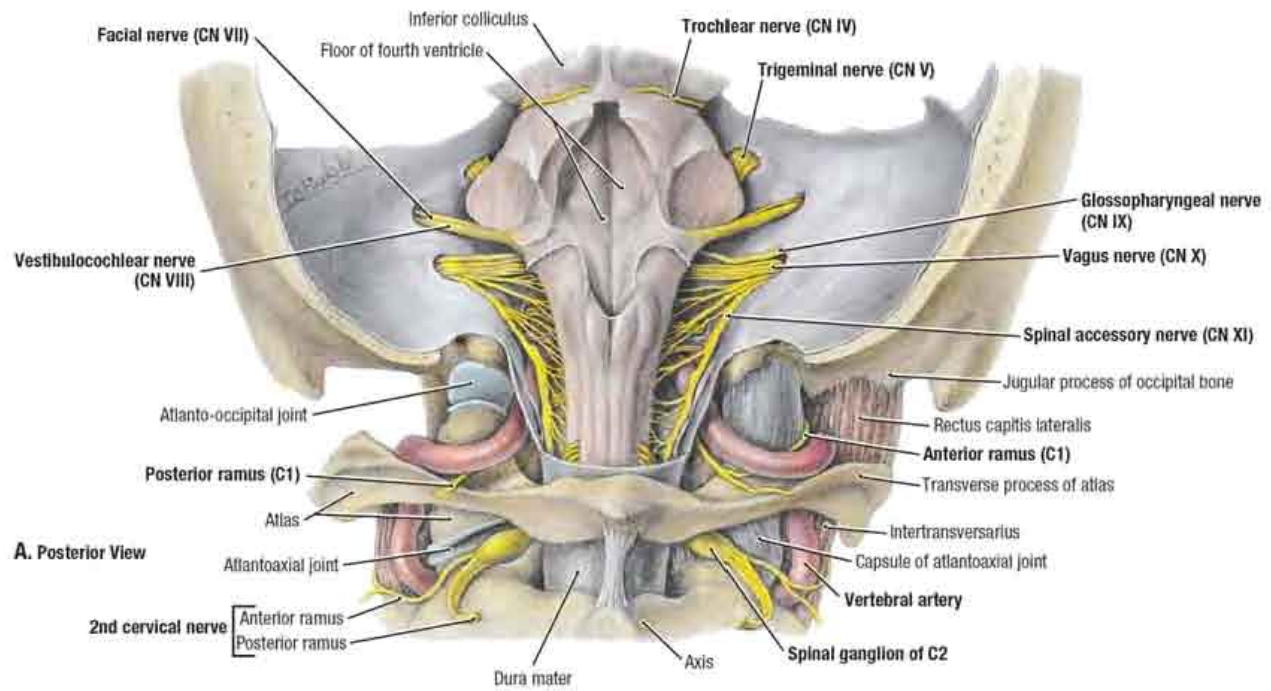
---

## 7.24 Posterior exposures of cranial nerves

*Part of "Chapter 7 - Head "*

A and B. Squamous part of occipital bone has been removed posterior to foramen magnum to reveal posterior cranial fossa. A. Brainstem in situ. B. Right side, with brainstem removed. The trochlear nerves (CN IV) arise from the dorsal aspect of the midbrain, just inferior to the inferior colliculi.

- The sensory and motor roots of the trigeminal nerves (CN V) pass anterolaterally to enter the mouth of the trigeminal cave.
- The facial (CN VII) and vestibulocochlear (CN VIII) nerves course laterally to enter the internal acoustic meatus.
- The glossopharyngeal nerve (CN IX) pierces the dura mater separately but passes with the vagus (CN X) and spinal accessory (CN XI) nerves through the jugular foramen.





Authors: Agur, Anne M.R.; Dalley, Arthur F.

Title: *Grant's Atlas of Anatomy, 12th Edition*

Copyright ©2009 Lippincott Williams & Wilkins

> Table of Contents > Chapter 7 - Head > 7.25 Tentorial notch

---

## 7.25 Tentorial notch

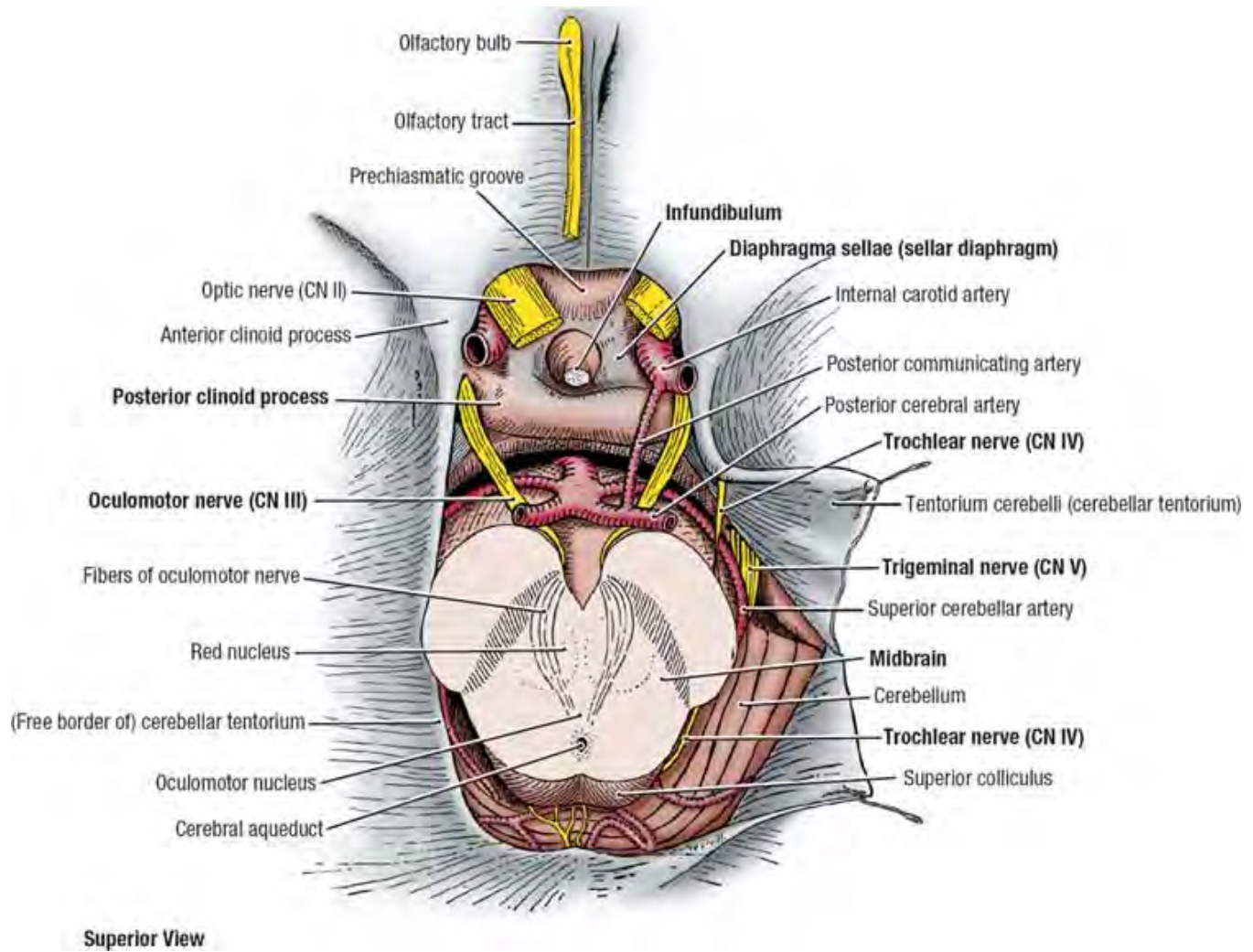
*Part of "Chapter 7 - Head "*

- The brain has been removed by cutting through the midbrain, revealing the tentorial notch through which the brainstem extends from the posterior into the middle cranial fossa.
  - On the right side of the specimen, the tentorium cerebelli is divided and reflected. The trochlear nerve (CN IV) passes around the midbrain under the free edge of the tentorium cerebelli; the roots of the trigeminal nerve (CN V) enter the mouth of the trigeminal cave.
  - There is a circular opening in the diaphragma sellae for the infundibulum, the stalk of the pituitary gland.
  - The oculomotor nerve (CN III) passes laterally around the posterior clinoid process and then passes between the posterior cerebral and superior cerebellar arteries.
- 
- The tentorial notch is the opening in the tentorium cerebelli for the brainstem, which is slightly larger than is necessary to accommodate the midbrain. Hence, space-occupying lesions, such as tumors in the supratentorial compartment, produce increased intracranial pressure that may cause part of the adjacent temporal lobe of the brain to herniate through the tentorial notch. During tentorial herniation, the temporal lobe may be lacerated by the tough tentorium cerebelli, and the oculomotor nerve (CN III) may be stretched, compressed, or



both. Oculomotor lesions may produce paralysis of the extrinsic eye muscles supplied by CN III.

P.644



Authors: Agur, Anne M.R.; Dalley, Arthur F.

Title: *Grant's Atlas of Anatomy, 12th Edition*

Copyright ©2009 Lippincott Williams & Wilkins

> Table of Contents > Chapter 7 - Head > 7.26 Nerves and vessels of middle cranial fossa

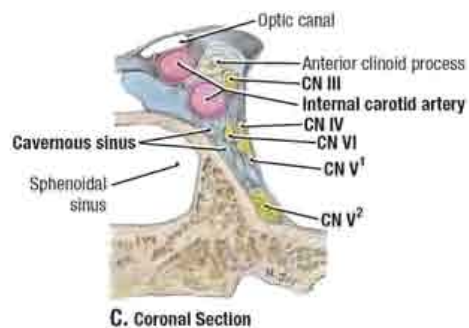
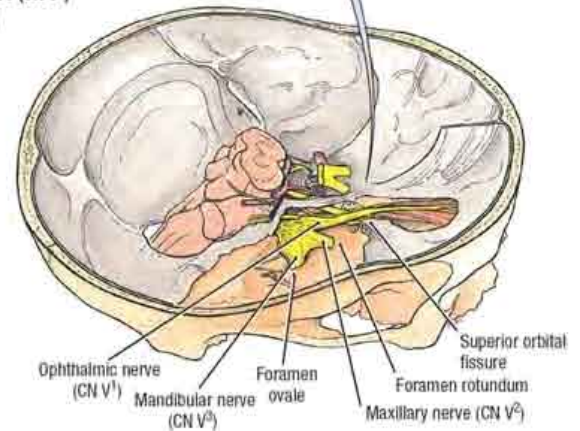
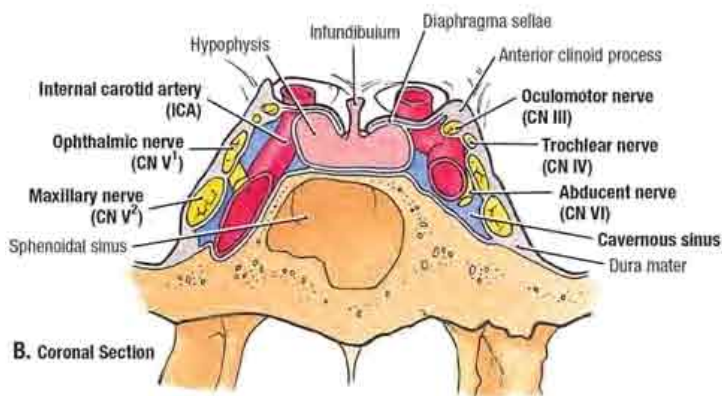
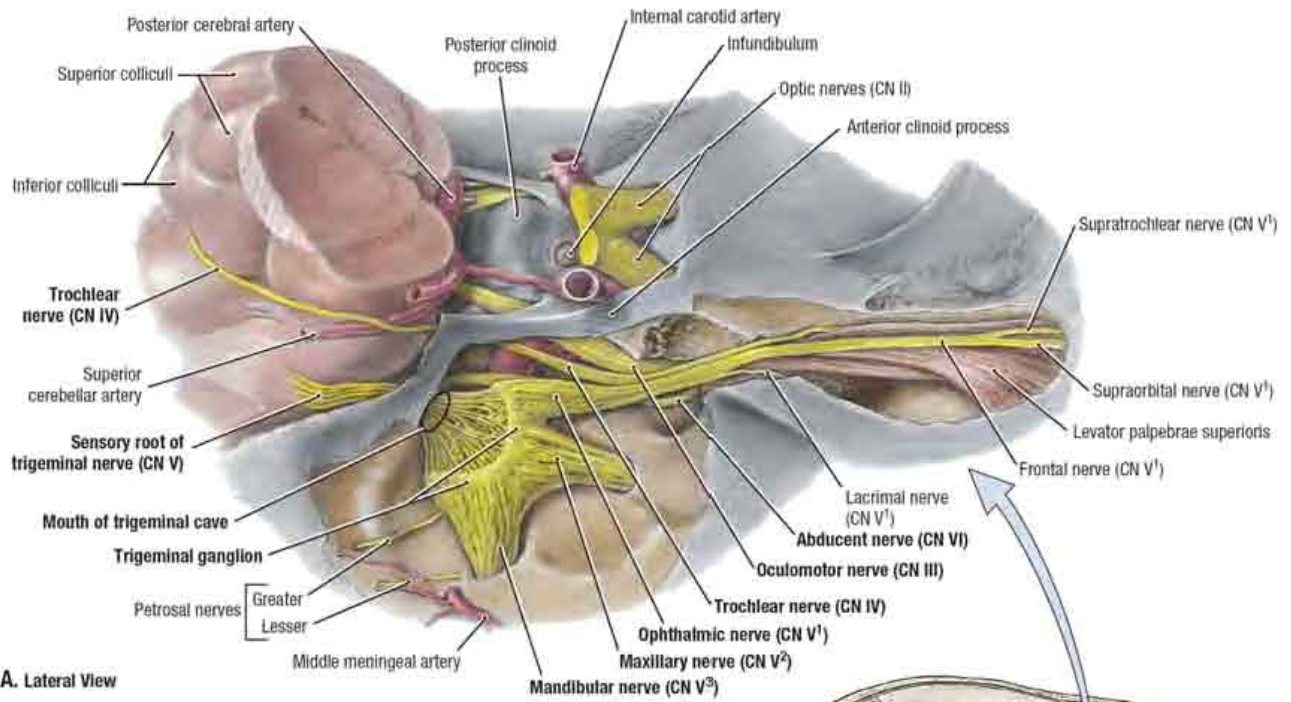
---

## 7.26 Nerves and vessels of middle cranial fossa

*Part of "Chapter 7 - Head"*

A. Superficial dissection. The tentorium cerebelli is cut away. The dura mater is largely removed from the middle cranial fossa. The roof of the orbit is partly removed. B and C. Coronal sections through the cavernous sinus.

In fractures of the cranial base, the internal carotid artery may be torn, producing an arteriovenous fistula within the cavernous sinus. Arterial blood rushes into the sinus, enlarging it and forcing retrograde blood flow into its venous tributaries, especially the ophthalmic veins. As a result, the eyeball protrudes (exophthalmos) and the conjunctiva becomes engorged (chemosis). Because CN III, CN IV, CN VI, CN V1, and CN V2 lie in or close to the lateral wall of the cavernous sinus, these nerves may also be affected.



Authors: Agur, Anne M.R.; Dalley, Arthur F.

Title: *Grant's Atlas of Anatomy, 12th Edition*

Copyright ©2009 Lippincott Williams & Wilkins

> Table of Contents > Chapter 7 - Head > 7.27 Nerves and vessels of middle cranial fossa II

---

## 7.27 Nerves and vessels of middle cranial fossa II

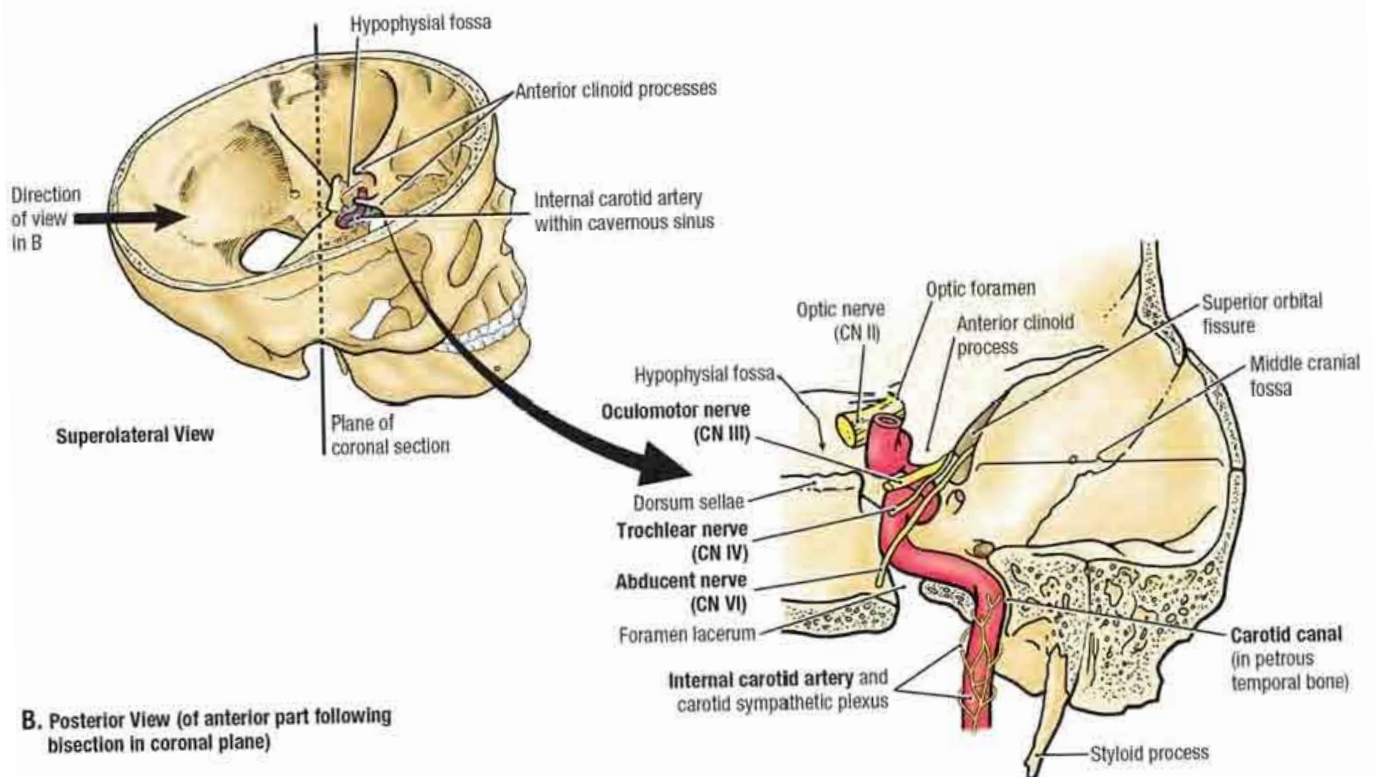
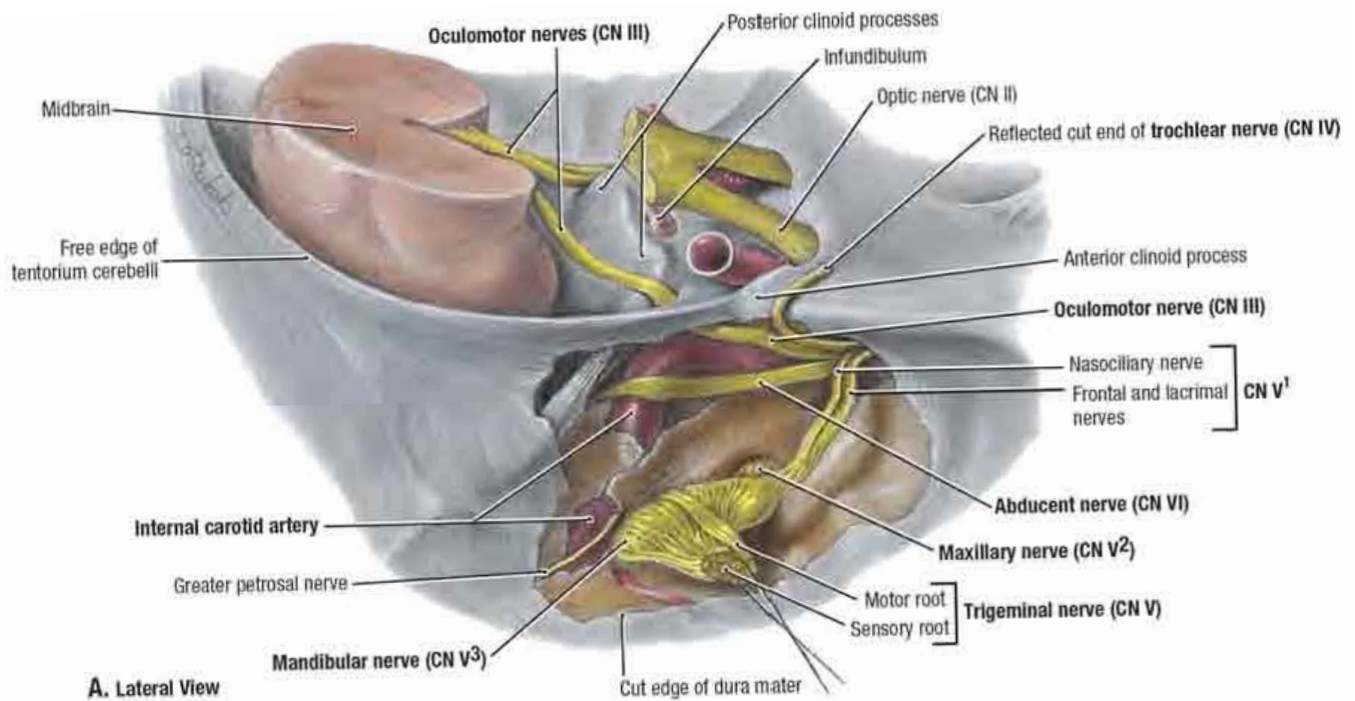
*Part of* "Chapter 7 - Head "

A. Deep dissection. The roots of the trigeminal nerve are divided, withdrawn from the mouth of the trigeminal cave, and turned anteriorly. The trochlear nerve is reflected anteriorly. B. Course of the internal carotid artery.

---

P.646





Authors: Agur, Anne M.R.; Dalley, Arthur F.

Title: *Grant's Atlas of Anatomy, 12th Edition*

Copyright ©2009 Lippincott Williams & Wilkins

> Table of Contents > Chapter 7 - Head > 7.28 Base of brain and cerebral arterial circle

---

## 7.28 Base of brain and cerebral arterial circle

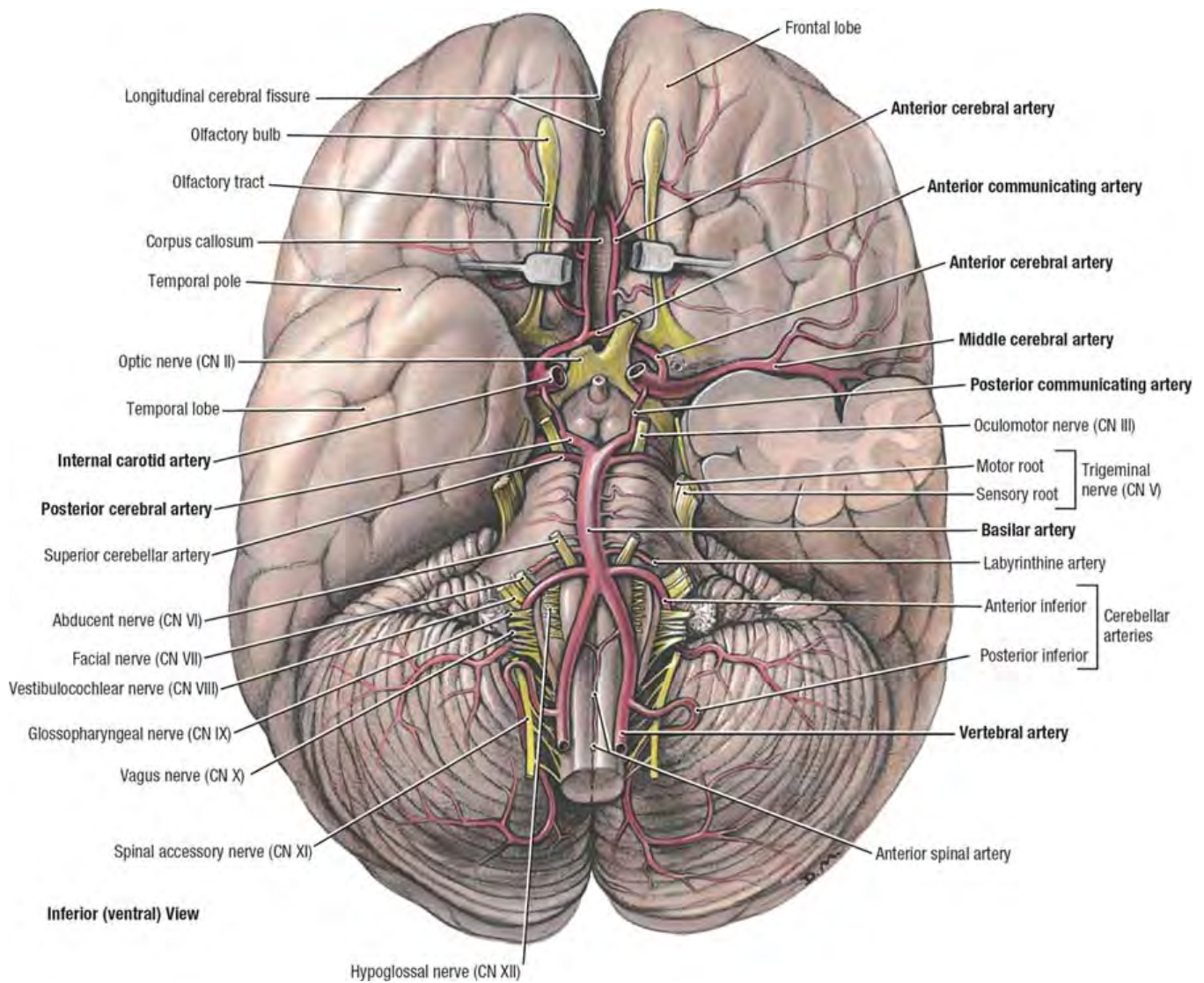
*Part of* "Chapter 7 - Head "

The left temporal pole is removed to enable visualization of the middle cerebral artery in the lateral fissure. The frontal lobes are separated to expose the anterior cerebral arteries and corpus callosum.

An ischemic stroke denotes the sudden development of neurological deficits that are consequences of impaired cerebral blood flow. The most common causes of strokes are spontaneous cerebrovascular accidents such as cerebral embolism, cerebral thrombosis, cerebral hemorrhage, and subarachnoid hemorrhage (Rowland, 2000). The cerebral arterial circle is an important means of collateral circulation in the event of gradual obstruction of one of the major arteries forming the circle. Sudden occlusion, even if only partial, results in neurological deficits. In elderly persons, the anastomoses are often inadequate when a large artery (e.g., internal carotid) is occluded, even if the occlusion is gradual. In such cases function is impaired at least to some degree.

Hemorrhagic stroke follows the rupture of an artery or a saccular aneurysm, a saclike dilation on a weak part of the arterial wall. The most common type of saccular aneurysm is a berry aneurysm, occurring in the vessels of or near the cerebral arterial circle. In time, especially in people with hypertension (high blood pressure), the weak part of the arterial wall expands and may rupture, allowing blood to enter the subarachnoid space.





Vertebral

Subclavian artery

Cranial meninges and cerebellum

Posterior inferior cerebellar

Vertebral artery

Posterior inferior aspect of cerebellum

Basilar

Formed by junction of vertebral arteries

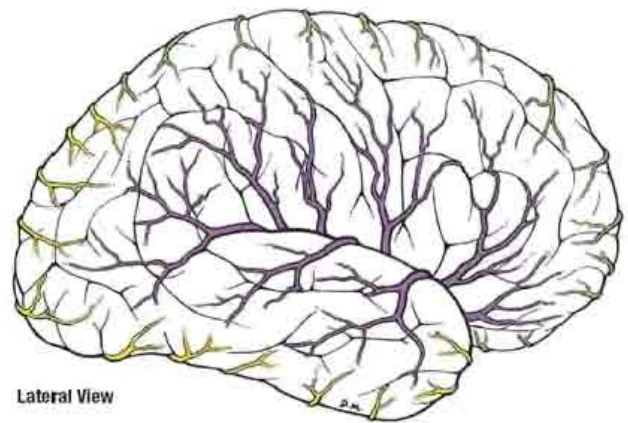
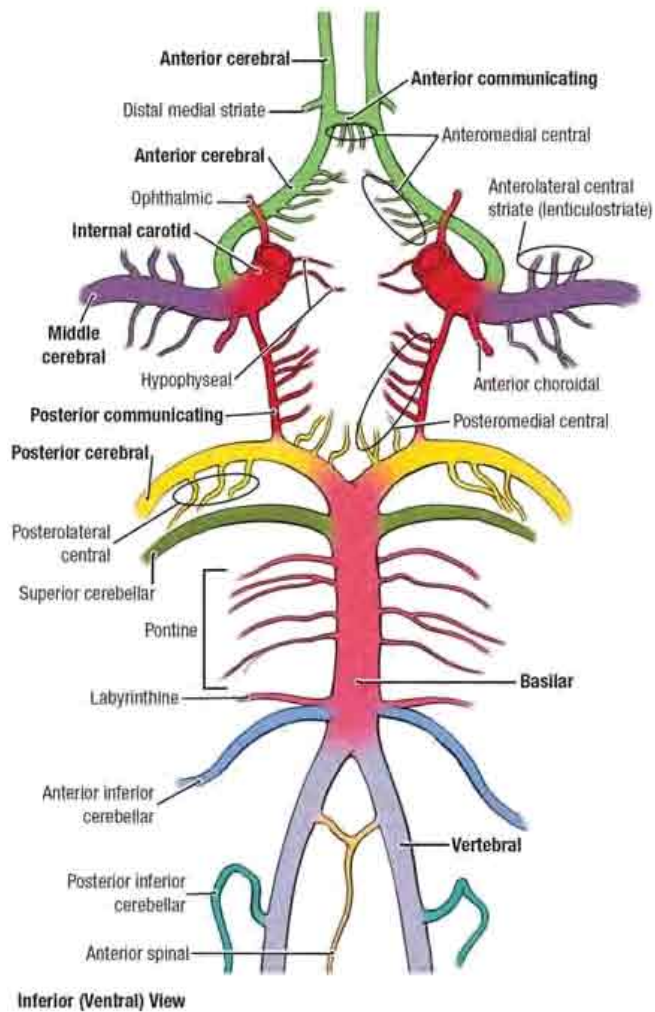
Brainstem, cerebellum, and cerebrum

Pontine

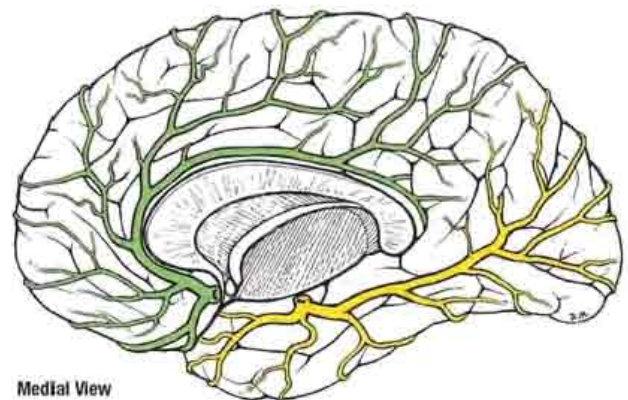
Basilar artery  
 Numerous branches to brainstem  
 Anterior inferior cerebellar  
 Inferior aspect of cerebellum  
 Superior cerebellar  
 Superior aspect of cerebellum  
 Internal carotid  
 Common carotid artery at superior border of thyroid cartilage  
 Gives branches in cavernous sinus and provides supply to brain  
 Anterior cerebral  
 Internal carotid artery  
 Cerebral hemispheres, except for occipital lobes  
 Middle cerebral  
 Continuation of the internal carotid artery distal to anterior cerebral artery  
 Most of lateral surface of cerebral hemispheres  
 Posterior cerebral  
 Terminal branch of basilar artery  
 Inferior aspect of cerebral hemisphere and occipital lobe  
 Anterior communicating  
 Anterior cerebral artery  
 Cerebral arterial circle  
 Posterior communicating  
 Internal carotid artery

Artery    Origin    Distribution

## Table 7.5 Arterial Supply to Brain



Blood is supplied to the cerebral hemispheres by the anterior (green), middle (purple), and posterior (yellow) cerebral arteries.



Authors: Agur, Anne M.R.; Dalley, Arthur F.

Title: *Grant's Atlas of Anatomy, 12th Edition*

Copyright ©2009 Lippincott Williams & Wilkins

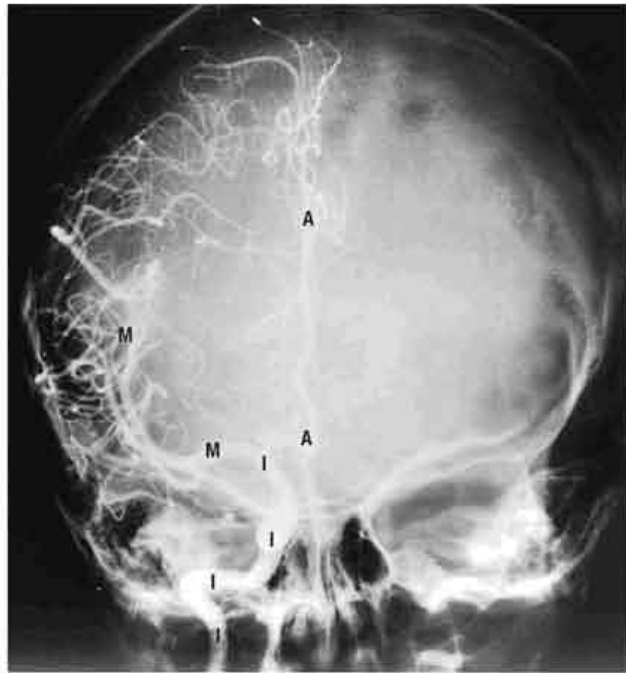
> Table of Contents > Chapter 7 - Head > 7.29 Arteriograms

---

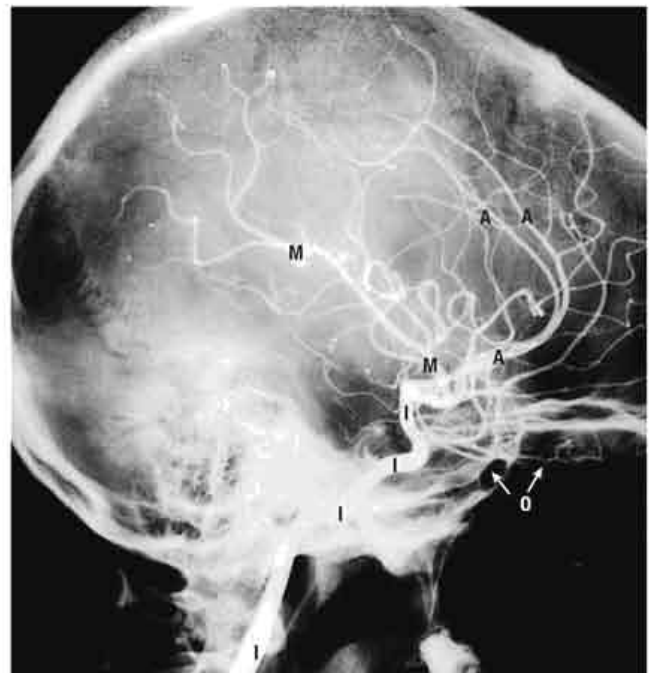
## 7.29 Arteriograms

*Part of "Chapter 7 - Head "*

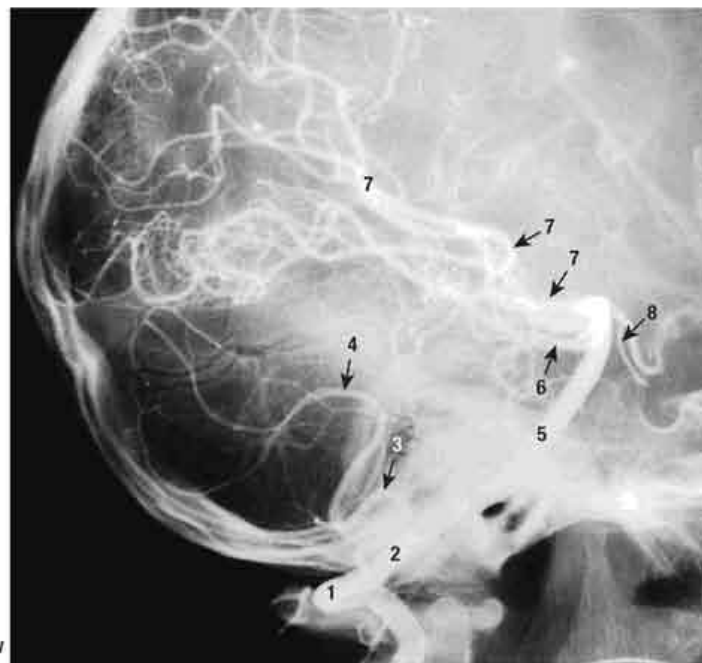
A and B. Carotid arteriogram. The four letter ls indicate the parts of the internal carotid artery: cervical, before entering the cranium; petrous, within the temporal bone; cavernous, within the sinus; and cerebral, within the cranial subarachnoid space. C. Vertebral arteriogram. Transient ischemic attacks (TIAs) refer to neurological symptoms resulting from ischemia (deficient blood supply) of the brain. The symptoms of a TIA may be ambiguous: staggering, dizziness, light-headedness, fainting, and paresthesias (e.g., tingling in a limb). Most TIAs last a few minutes, but some persist longer. Individuals with TIAs are at increased risk for myocardial infarction and ischemic stroke (Brust, 2000).



A. Posteroanterior View



B. Lateral View



C. Lateral View

- |   |  |
|---|--|
| A | Anterior cerebral artery                               |
| M | Middle cerebral artery                                 |
| I | Internal carotid artery                                |
| O | Ophthalmic artery                                      |
| 1 | Vertebral artery on posterior arch of atlas            |
| 2 | Vertebral artery entering skull through foramen magnum |
| 3 | Posterior inferior cerebellar artery                   |
| 4 | Anterior inferior cerebellar artery                    |
| 5 | Basilar artery   |
| 6 | Superior cerebellar artery                             |
| 7 | Posterior cerebellar artery                            |
| 8 | Posterior communicating artery                         |



Authors: Agur, Anne M.R.; Dalley, Arthur F.

Title: *Grant's Atlas of Anatomy, 12th Edition*

Copyright ©2009 Lippincott Williams & Wilkins

> Table of Contents > Chapter 7 - Head > 7.30 Blood supply of head and neck

---

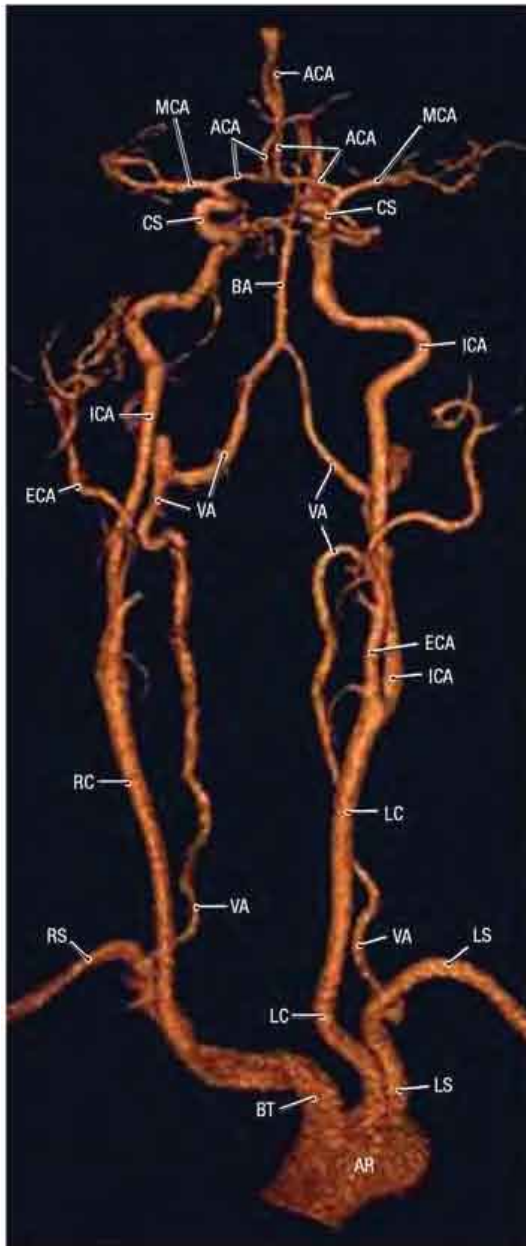
## 7.30 Blood supply of head and neck

*Part of* "Chapter 7 - Head "

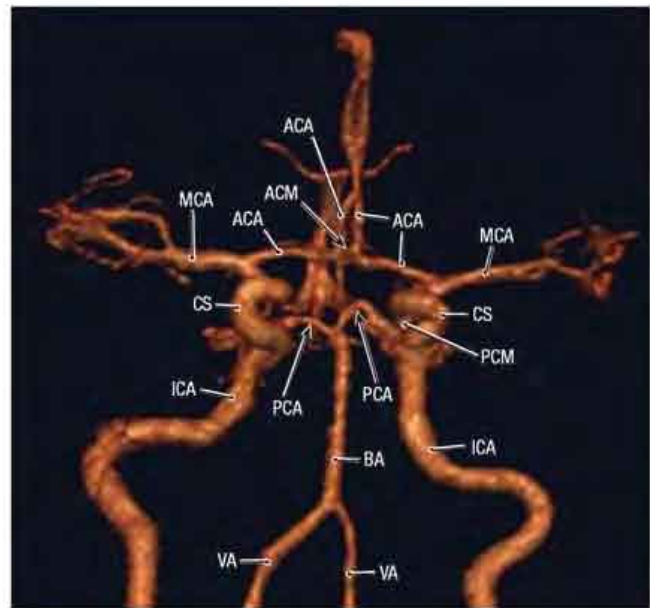
A. CT angiogram of arteries of head and neck. B. CT angiogram of cerebral arterial circle (circle of Willis). C. Schematic diagram of cerebral arterial circle and veins of cerebral base.

---

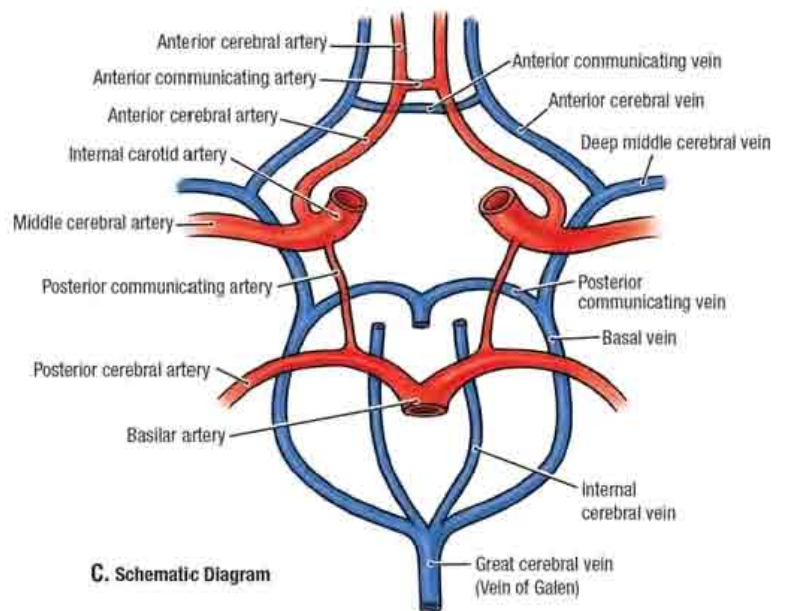
P.650



**A. Anterior View**



**B. Anterior View**



**C. Schematic Diagram**

ACM	Anterior communicating artery	BT	Brachiocephalic trunk	LC	Left common carotid artery	PCM	Posterior communicating artery
ACA	Anterior cerebral artery	CS	Carotid siphon	LS	Left subclavian artery	RC	Right common carotid artery
AR	Arch of aorta	ECA	External carotid artery	MCA	Middle cerebral artery	RS	Right subclavian artery
BA	Basilar artery	ICA	Internal carotid artery	PCA	Posterior cerebral artery	VA	Vertebral artery

Authors: Agur, Anne M.R.; Dalley, Arthur F.

Title: *Grant's Atlas of Anatomy, 12th Edition*

Copyright ©2009 Lippincott Williams & Wilkins

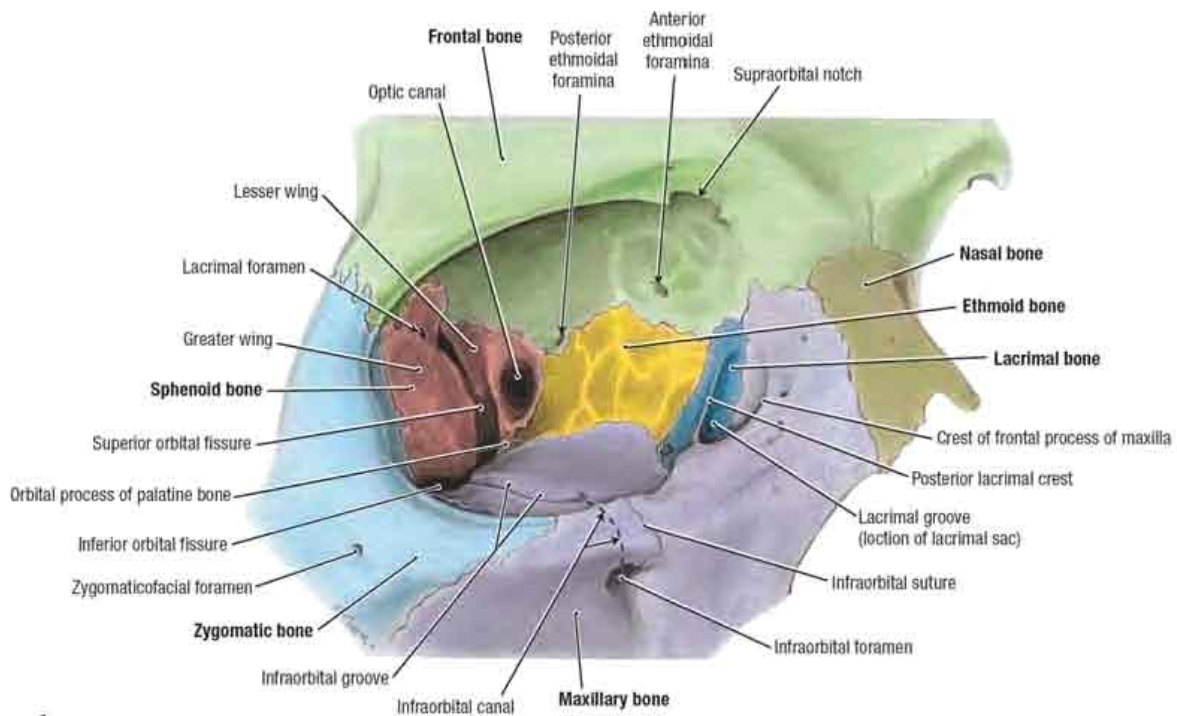
> Table of Contents > Chapter 7 - Head > 7.31 Orbital cavity and surface anatomy of the eye

---

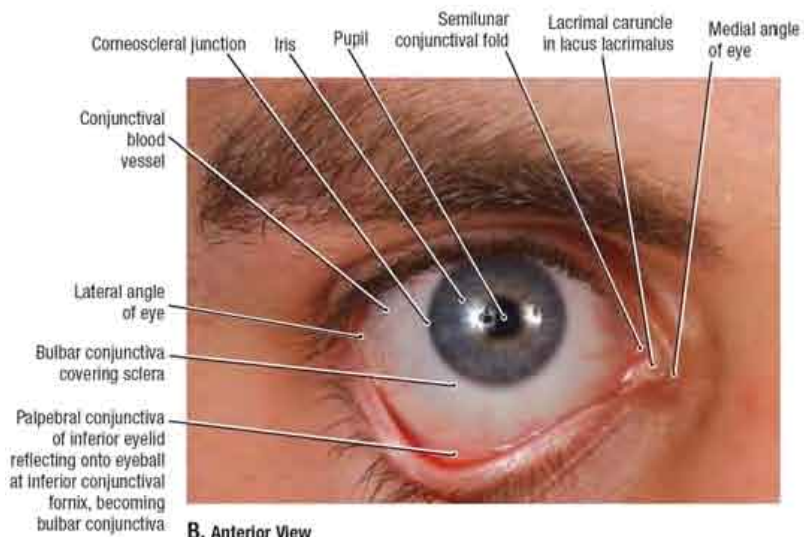
## 7.31 Orbital cavity and surface anatomy of the eye

*Part of "Chapter 7 - Head "*

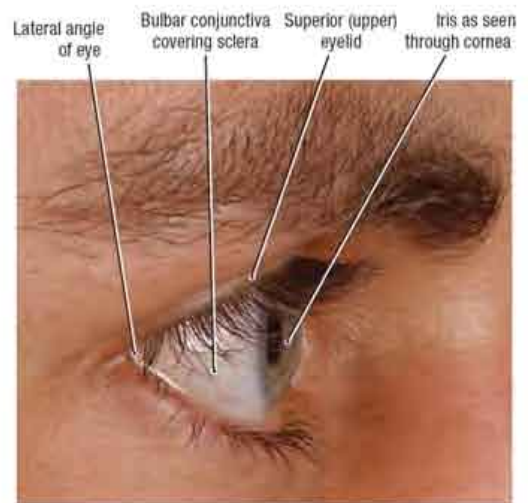
A. Bones and features of the orbital cavity. B and C. Surface anatomy of the eye. In B , the inferior eyelid is everted to demonstrate the palpebral conjunctiva. When powerful blows impact directly on the bony rim of the orbit, the resulting fractures usually occur at the sutures between the bones forming the orbital margin. Fractures of the medial wall may involve the ethmoidal and sphenoidal sinuses, whereas fractures in the inferior wall may involve the maxillary sinus. Although the superior wall is stronger than the medial and inferior walls, it is thin enough to be translucent and may be readily penetrated. Thus, a sharp object may pass through it into the frontal lobe of the brain. Orbital fractures often result in intraorbital bleeding, which exerts pressure on the eyeball, causing exophthalmos (protrusion of the eyeball).



**A. Anterior View**



**B. Anterior View**



**C. Lateral View**

Authors: Agur, Anne M.R.; Dalley, Arthur F.

Title: *Grant's Atlas of Anatomy, 12th Edition*

Copyright ©2009 Lippincott Williams & Wilkins

> Table of Contents > Chapter 7 - Head > 7.32 Eye and lacrimal apparatus

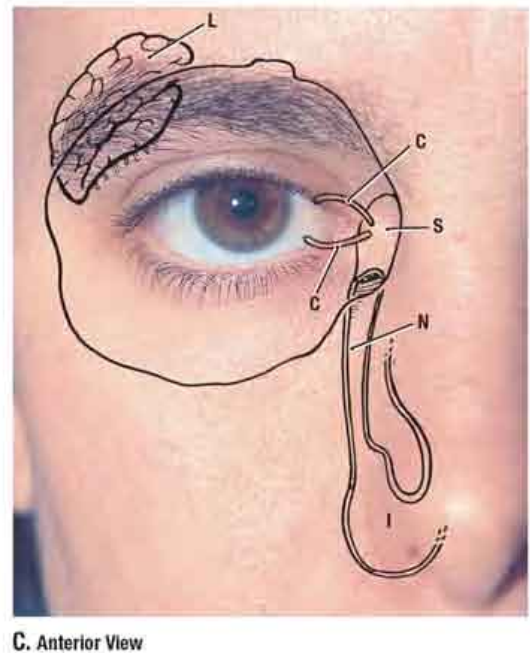
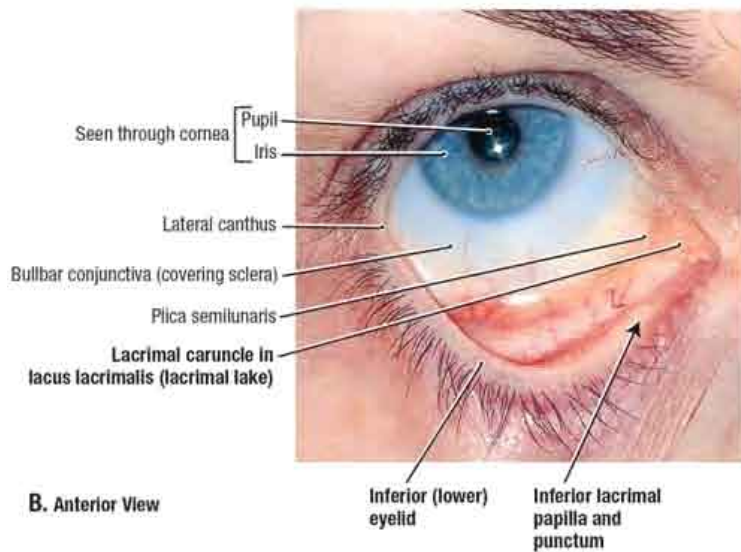
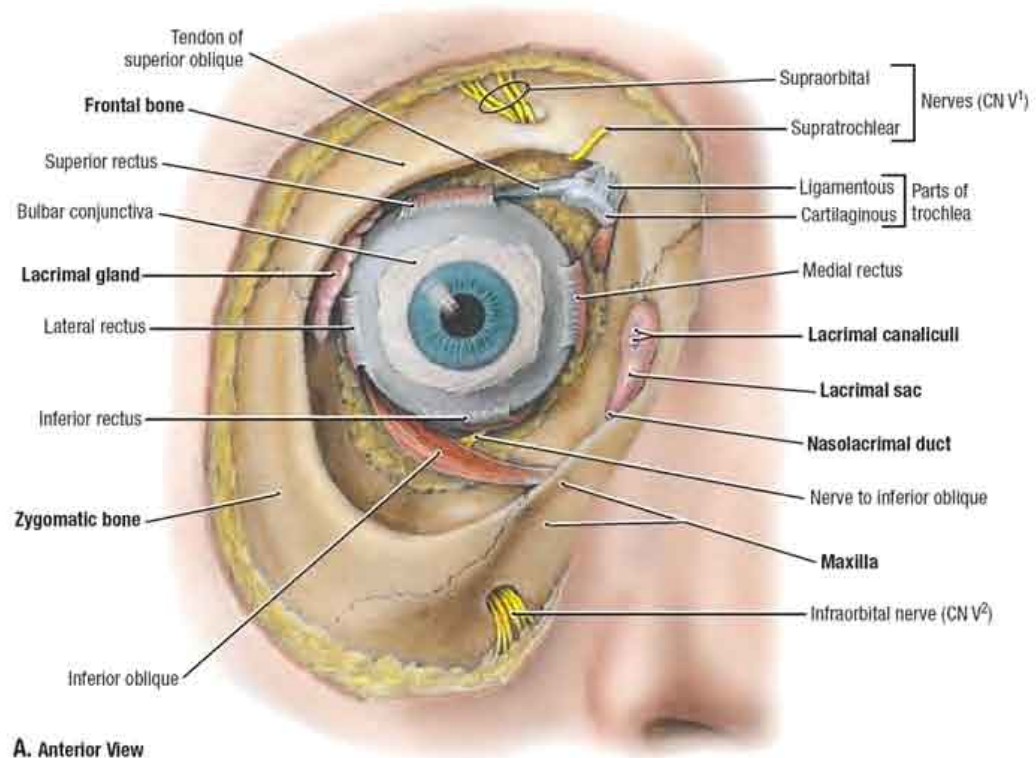
---

## 7.32 Eye and lacrimal apparatus

*Part of "Chapter 7 - Head "*

A. Anterior dissection of orbital cavity. The eyelids, orbital septum, levator palpebrae superioris, and some fat are removed. B. Surface features, with the inferior eyelid everted. C. Surface projection of lacrimal apparatus. Tears, secreted by the lacrimal gland (L) in the superolateral angle of the bony orbit, pass across the eyeball and enter the lacus lacrimalis (lacrimal lake) at the medial angle of the eye; from here they drain through the lacrimal puncta and lacrimal canaliculi (C) to the lacrimal sac (S). The lacrimal sac drains into the nasolacrimal duct (N), which empties into the inferior meatus (I) of the nose.





Authors: Agur, Anne M.R.; Dalley, Arthur F.

Title: *Grant's Atlas of Anatomy, 12th Edition*

Copyright ©2009 Lippincott Williams & Wilkins

> Table of Contents > Chapter 7 - Head > 7.33 Orbital cavity, superior approach

---

## 7.33 Orbital cavity, superior approach

*Part of* "Chapter 7 - Head "

A. Superficial dissection.

On the right side of figure A:

- The orbital plate of the frontal bone is removed.
- The levator palpebrae superioris muscle lies superficial to the superior rectus muscle.
- The trochlear, frontal, and lacrimal nerves lie immediately inferior to the roof of the orbital cavity.

On the left side of figure A:

- The levator palpebrae and superior rectus muscles are reflected.
- The superior division of the oculomotor nerve (CN III) supplies the superior rectus and levator palpebrae muscles.
- The trochlear nerve (CN IV) lies on the medial side of the superior oblique muscle, and the abducent nerve (CN VI) on the medial side of the lateral rectus muscle.
- The lacrimal nerve runs superior to the lateral rectus muscle supplying sensory fibers to the conjunctiva and skin of the superior eyelid; it receives a communicating branch of the zygomaticotemporal nerve carrying secretory motor fibers from the pterygopalatine ganglion to the lacrimal gland.

- The parasympathetic ciliary ganglion, placed between the lateral rectus muscle and the optic nerve (CN II), gives rise to many short ciliary nerves; the nasociliary nerve gives rise to two long ciliary nerves that anastomose with each other and the short ciliary nerves.

P.653

B. Deep dissection before (*right side*) and after (*left side*) section of the optic nerve (CN II).

C. Transverse (axial) MRI of orbital cavity. (The *numbers* refer to structures labeled in B).

Observe on the right side of figure B:

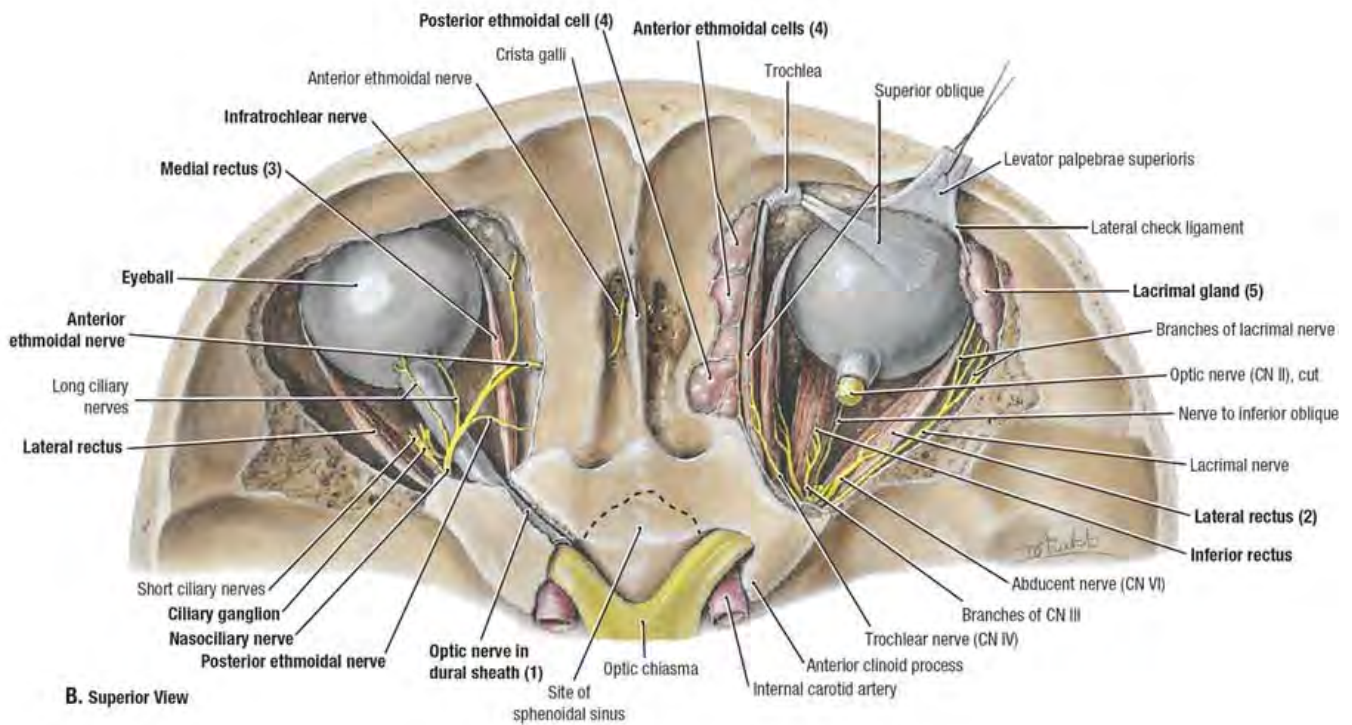
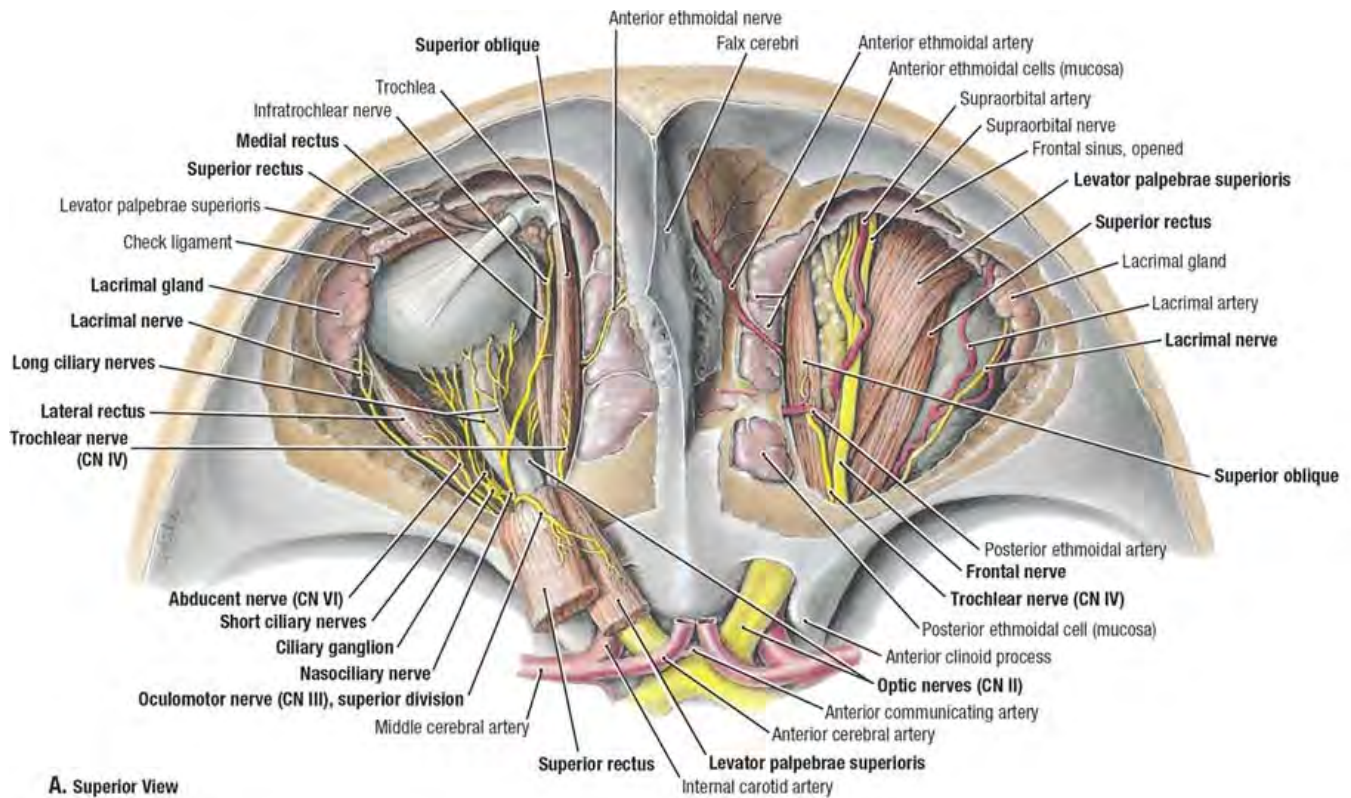
- The eyeball occupies the anterior half of the orbital cavity.
- Nerves supplying the four recti (superior, medial, inferior, lateral) enter their ocular surfaces (the superior rectus is not shown).

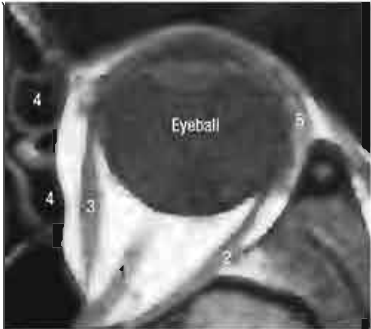
Observe on the left of figure B:

- The parasympathetic ciliary ganglion lies posteriorly between the lateral rectus muscle and the sheath of the optic nerve.
- The nasociliary nerve (CN V<sup>1</sup>) sends a branch to the ciliary ganglion and crosses the optic nerve (CN II), where it gives off two long ciliary nerves (sensory to the eyeball and cornea) and the posterior ethmoidal nerve (to the sphenoidal sinus and posterior ethmoidal cells). The nasociliary nerve then divides into the anterior ethmoidal and infratrochlear nerves.

Because of the closeness of the optic nerve to the sphenoidal sinus and posterior ethmoidal cell, a malignant tumor in these sinuses may erode the thin bony walls of the orbit and compress the optic nerve and orbital contents. Tumors in the orbit produce exophthalmos. A tumor in the middle cranial fossa may enter the orbital cavity through the superior orbital







C. Axial MRI



Authors: Agur, Anne M.R.; Dalley, Arthur F.

Title: *Grant's Atlas of Anatomy, 12th Edition*

Copyright ©2009 Lippincott Williams & Wilkins

> Table of Contents > Chapter 7 - Head > 7.34 Lateral aspect of the orbit and structure of the eyelid

---

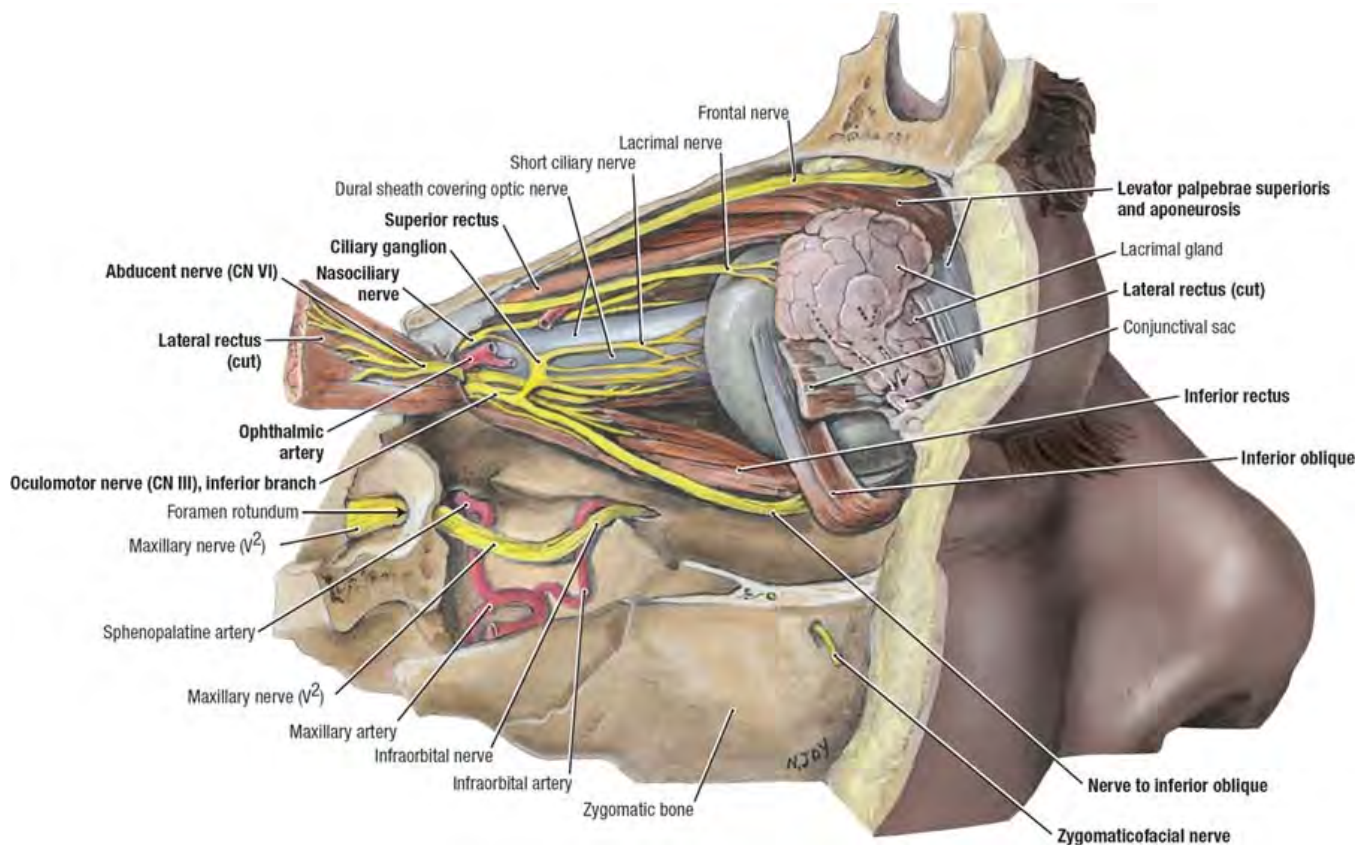
## 7.34 Lateral aspect of the orbit and structure of the eyelid

*Part of "Chapter 7 - Head "*

- The ciliary ganglion receives sensory fibers from the nasociliary branches of VI, postsynaptic sympathetic fibers from the continuation of the internal carotid plexus extending along the ophthalmic artery, and presynaptic parasympathetic fibers from the inferior branch of the oculomotor nerve; only the latter synapse in the ganglion.
- Complete oculomotor nerve palsy affects most of the ocular muscles, the levator palpebrae superioris, and the sphincter pupillae. The superior eyelid droops (ptosis) and cannot be raised voluntarily because of the unopposed activity of the orbicularis oculi (supplied by the facial nerve). The pupil is also fully dilated and nonreactive because of the unopposed dilator pupillae. The pupil is fully abducted and depressed (â€œdown and outâ€• ) because of the unopposed activity of the lateral rectus and superior oblique, respectively.
- A lesion of the abducent nerve results in loss of lateral gaze to the ipsilateral side because of paralysis of the lateral rectus muscle. On forward gaze, the eye is diverted medially because of the lack of normal resting tone in the lateral rectus, resulting in diplopia (double vision). Horner syndrome results from interruption of a cervical

sympathetic trunk and is manifest by the absence of sympathetically stimulated functions on the ipsilateral side of the head. The syndrome includes the following signs: constriction of the pupil (miosis), drooping of the superior eyelid (ptosis), redness and increased temperature of the skin (vasodilatation), and absence of sweating (anhidrosis).

P.655



Authors: Agur, Anne M.R.; Dalley, Arthur F.

Title: *Grant's Atlas of Anatomy, 12th Edition*

Copyright ©2009 Lippincott Williams & Wilkins

> Table of Contents > Chapter 7 - Head > 7.35 Lateral aspect of the orbit and structure of the eyelid

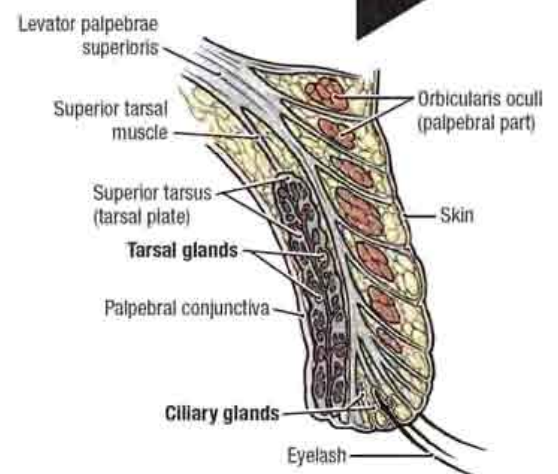
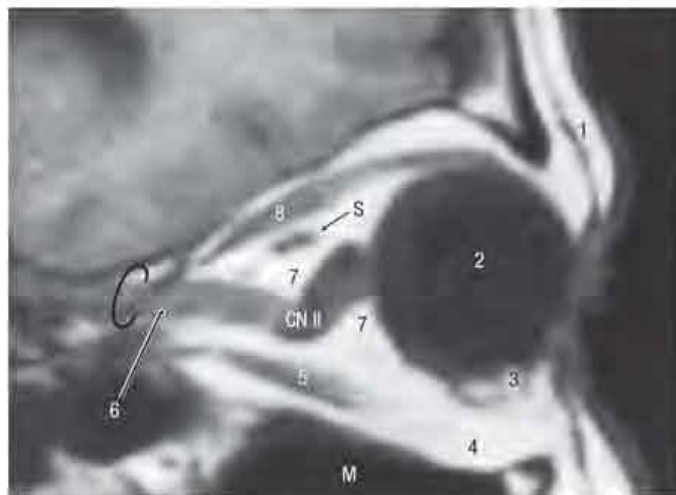
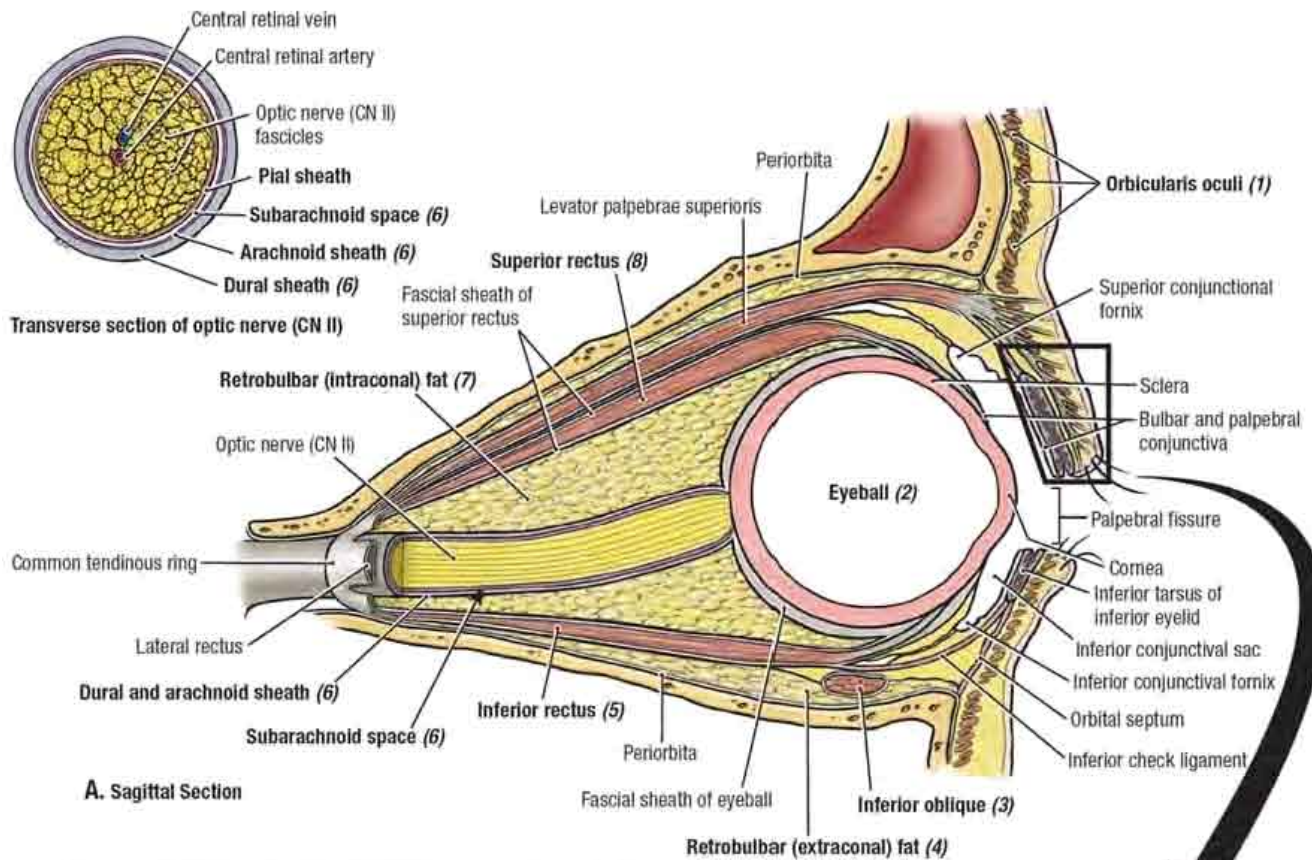
---

## 7.35 Lateral aspect of the orbit and structure of the eyelid

*Part of "Chapter 7 - Head "*

A. Schematic sagittal and cross-section through optic nerve. B. Sagittal MRI. The *numbers* refer to structures labeled in A; *S*, superior ophthalmic vein; *M*, maxillary sinus; *circled*, optic foramen.

- Foreign objects, such as sand or metal filings, produce corneal abrasions that cause sudden, stabbing eye pain and tears. Opening and closing the eyelids is also painful. Corneal lacerations are caused by sharp objects such as fingernails or the corner of a page of a book.
- Any of the glands in the eyelid may become inflamed and swollen from infection or obstruction of their ducts. If the ducts of the ciliary glands are obstructed, a painful red suppurative (pus-producing) swelling, a sty (hordeolum), develops on the eyelid. Obstruction of a tarsal gland produces inflammation, a tarsal chalazion, that protrudes toward the eyeball and rubs against it as the eyelids blink.



Authors: Agur, Anne M.R.; Dalley, Arthur F.

Title: *Grant's Atlas of Anatomy, 12th Edition*

Copyright ©2009 Lippincott Williams & Wilkins

> Table of Contents > Chapter 7 - Head > 7.36 Nerves and veins of the orbit

---

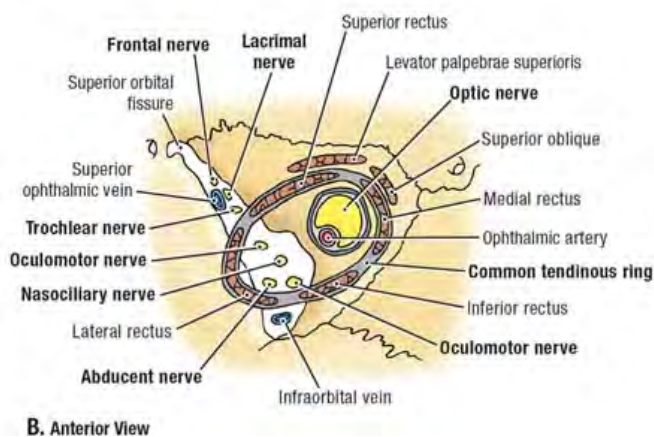
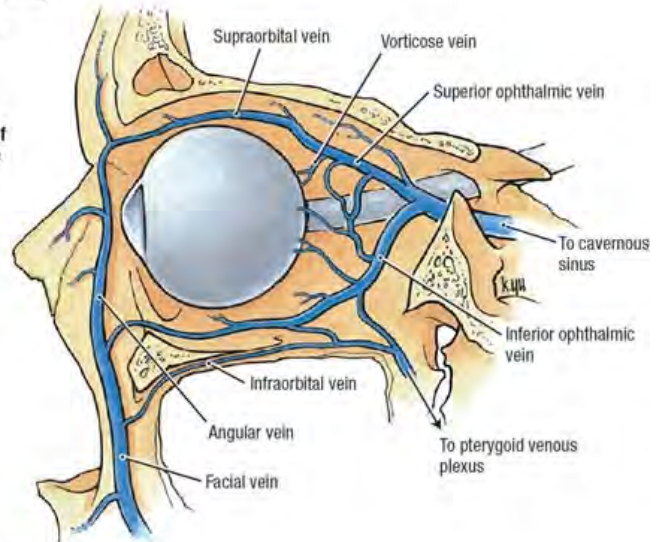
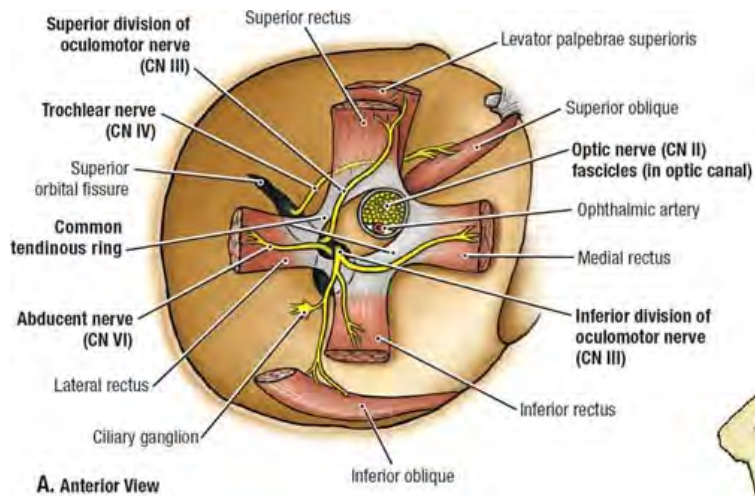
## 7.36 Nerves and veins of the orbit

*Part of "Chapter 7 - Head "*

A and B. Nerves of orbit in relation to the orbital fissures and the common tendinous ring. The common tendinous ring is formed by the origin of the four recti and encircles the dural sheath of the optic nerve, CN VI, and the superior and inferior branches of CN III; the nasociliary nerve (CN V<sup>1</sup>) also passes through this cuff. C. Ophthalmic veins. The superior and inferior ophthalmic veins receive the vorticoses veins from the eyeball and drain into the cavernous sinus posteriorly and the pterygoid plexus inferiorly. They communicate with the facial and supraorbital veins anteriorly.

- The facial veins make clinically important connections with the cavernous sinus through the superior ophthalmic veins. Cavernous sinus thrombosis usually results from infections in the orbit, nasal sinuses, and superior part of the face (the danger triangle). In persons with thrombophlebitis of the facial vein, pieces of an infected thrombus may extend into the cavernous sinus, producing thrombophlebitis of the cavernous sinus. The infection usually involves only one sinus initially but may spread to the opposite side through the intercavernous sinuses.





The terminal branches of the central retinal artery are end arteries. Obstruction of the artery by an embolus results in instant and total blindness. Blockage of the artery is usually unilateral and occurs in older people.

The central vein of the retina enters the cavernous sinus. Thrombophlebitis of this sinus may result in passage of a thrombus to the central retinal vein and produce a blockage in one of the small retinal veins. Occlusion of a branch of the central vein of the retina usually results in slow, painless loss of vision.

Ophthalmic

Internal carotid artery

Traverses optic foramen to reach orbital cavity

Central retinal

Ophthalmic artery

Runs in dural sheath of optic nerve, entering nerve near eyeball; appears at center of optic disc; supplies optic retina (except cones and rods)

Supraorbital

Passes superiorly and posteriorly from supraorbital foramen to supply forehead and scalp

Supratrochlear

Passes from supraorbital margin to forehead and scalp

Lacrimal

Passes along superior border of lateral rectus muscle to supply lacrimal gland, conjunctiva, and eyelids

Dorsal nasal

Courses along dorsal aspect of nose and supplies its surface

Short posterior ciliary

Pierces sclera at periphery of optic nerve to supply choroid, which, in turn, supplies cones and rods of optic retina

Long posterior ciliary

Pierces sclera to supply ciliary body and iris

Posterior ethmoidal

Passes through posterior ethmoidal foramen to posterior ethmoidal cells

Anterior ethmoidal

Passes through anterior ethmoidal foramen to anterior cranial fossa; supplies anterior and middle ethmoidal cells, frontal sinus, nasal cavity, and skin on dorsum of nose

Anterior ciliary

Muscular branches of ophthalmic artery

Pierces sclera at attachments of rectus muscles and forms network in iris and ciliary body

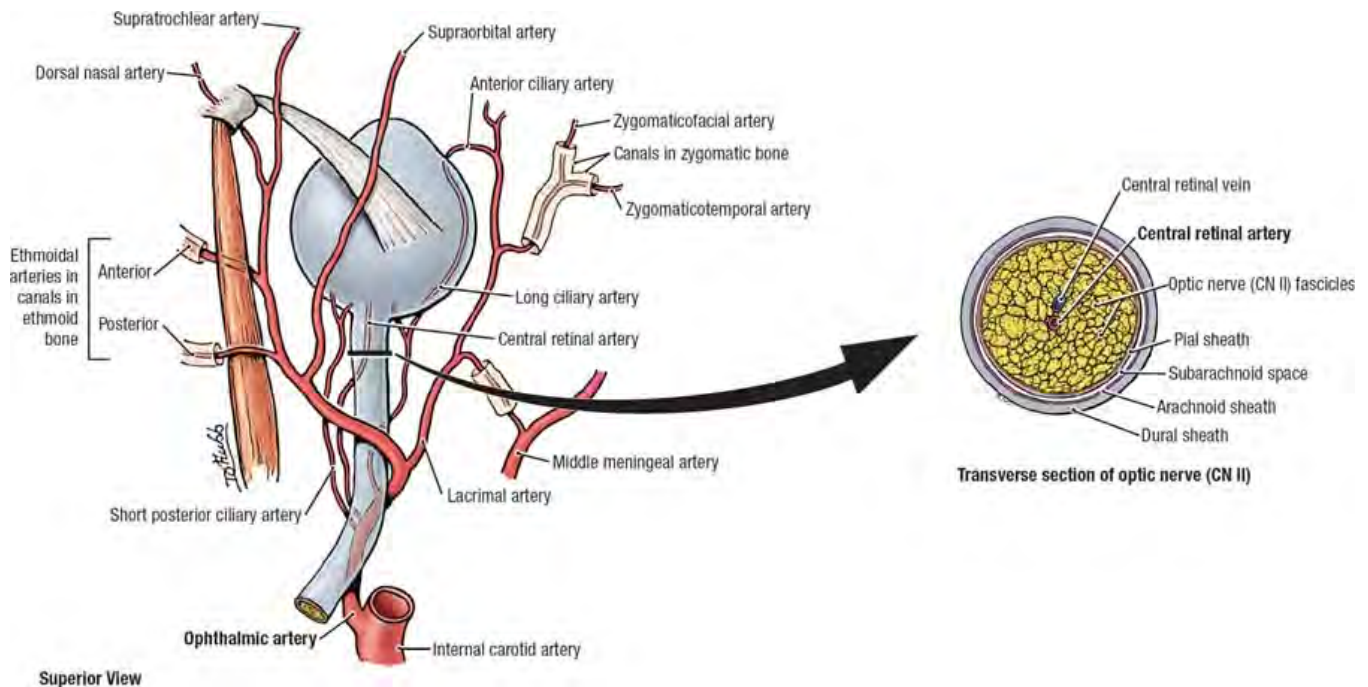
Infraorbital

Third part of maxillary artery

Passes along infraorbital groove and exits through infraorbital foramen to face

Artery    Origin    Course and Distribution

Table 7.6 Arteries of Orbit



Levator palpebrae superioris

Lesser wing of sphenoid bone, superior and anterior to optic canal

Tarsal plate and skin of superior (upper) eyelid

Oculomotor nerve (CN III); deep layer (superior tarsal muscle) is supplied by sympathetic fibers

Elevates superior (upper) eyelid

Superior rectus

Common tendinous ring

Sclera just posterior to cornea

Oculomotor nerve (CN III)

Elevates, adducts, and rotates eyeball medially

Inferior rectus

Depresses, adducts, and rotates eyeball laterally

Lateral rectus

Abducent nerve (CN VI)

Abducts eyeball

Medial rectus

Oculomotor nerve (CN III)

Abducts eyeball

Superior oblique

Body of sphenoid bone

Its tendon passes through the trochlea (fibrous ring), changes its direction, and inserts into sclera deep to superior rectus muscle

Trochlear nerve (CN IV)

Abducts, depresses, and medially rotates eyeball

Inferior oblique

Anterior part of floor of orbit

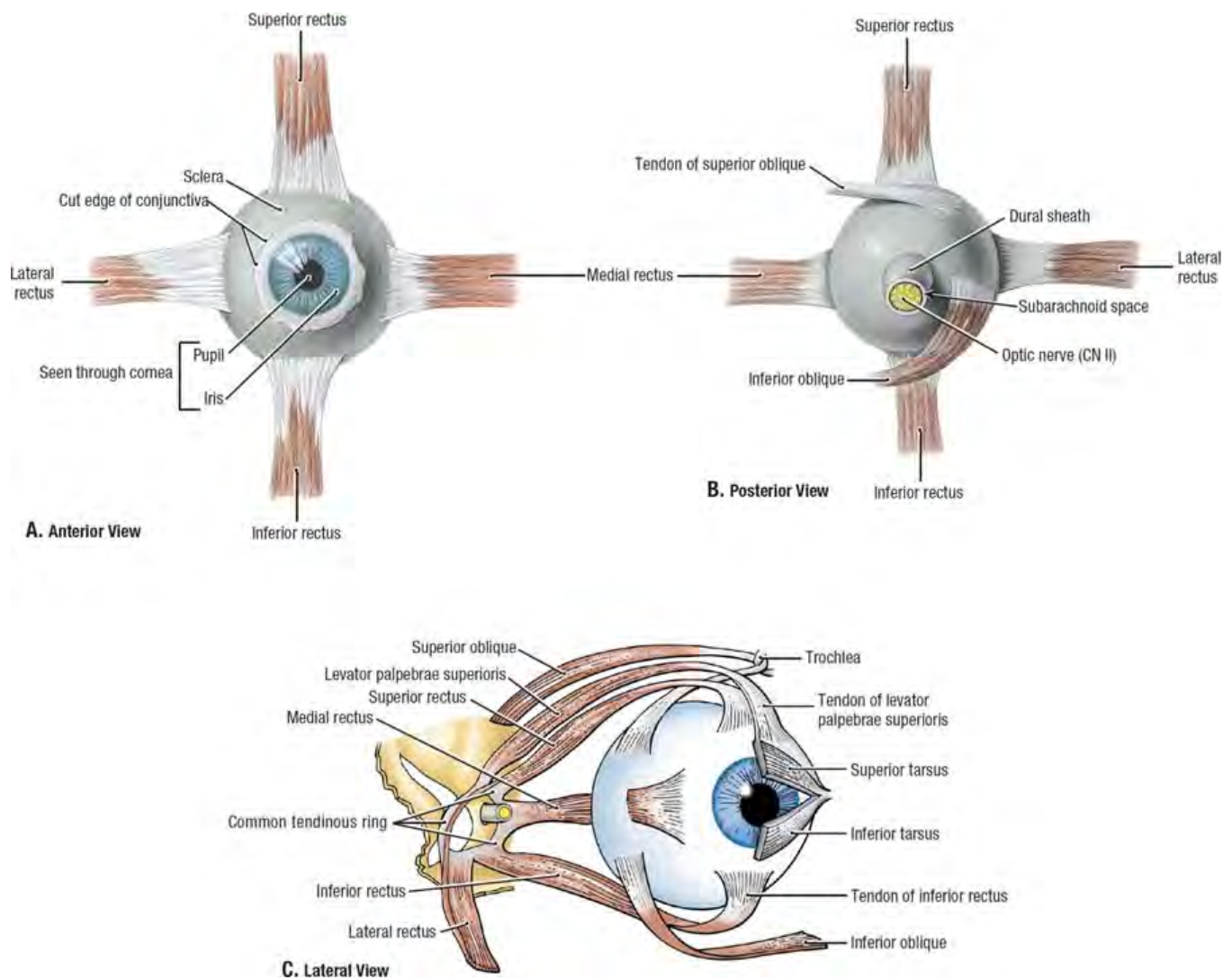
Sclera deep to lateral rectus muscle

Oculomotor nerve (CN III)

Abducts, elevates, and laterally rotates eyeball

Muscle	Origin	Insertion	Innervation	Main Action
--------	--------	-----------	-------------	-------------

Table 7.7 Muscles of Orbit
----------------------------



Superior rectus (SR)

Elevates

Adducts

Rotates medially (intorsion)

Inferior rectus (IR)

Depresses

Adducts

Rotates laterally (extorsion)

Superior oblique (SO)

Depresses

Abducts

Rotates medially (intorsion)



Inferior oblique (IO)

Elevates

Abducts

Rotates laterally (extorsion)

Medial rectus (MR)

N/A

Adducts

N/A

Lateral rectus (LR)

N/A

Abducts

N/A

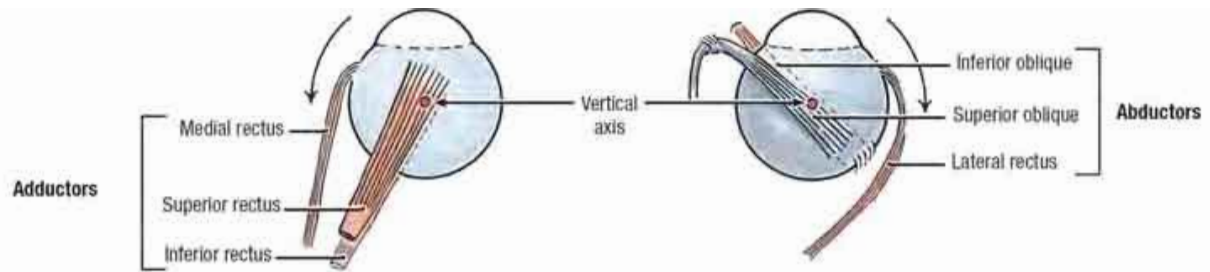
<sup>a</sup>Primary position, gaze directed anteriorly.

#### Main Action

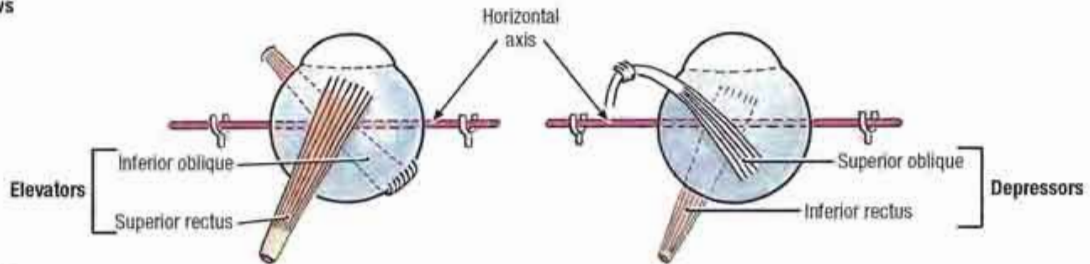
Muscle	Vertical Axis (A)	Horizontal Axis (B)	Anteroposterior Axis (C)
--------	-------------------	---------------------	--------------------------

Table 7.8 Actions of Muscles of the Orbit Starting from Primary Position <sup>a</sup>

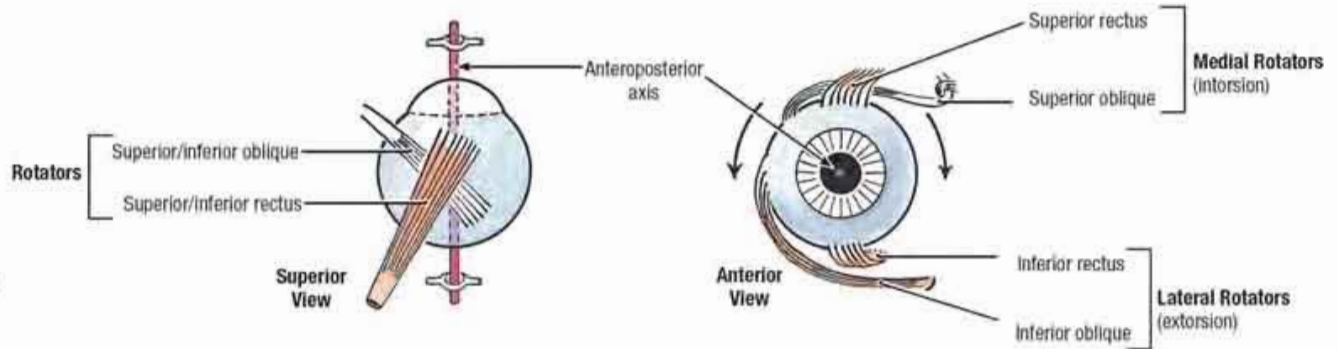
Movement from the primary position always involves more than one muscle acting synergistically. When testing muscles, it is desirable to test actions produced by one muscle acting independently. Because the axes of the orbits diverge and do not correspond to the axis of gaze in the primary position, responsibility for elevation and depression changes with abduction and adduction. When the eye is adducted, the oblique muscles are solely responsible; when the eye is abducted, the rectus muscles are solely responsible.



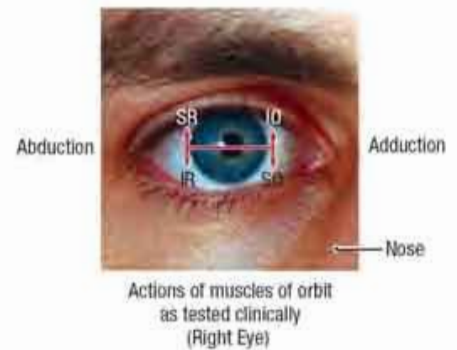
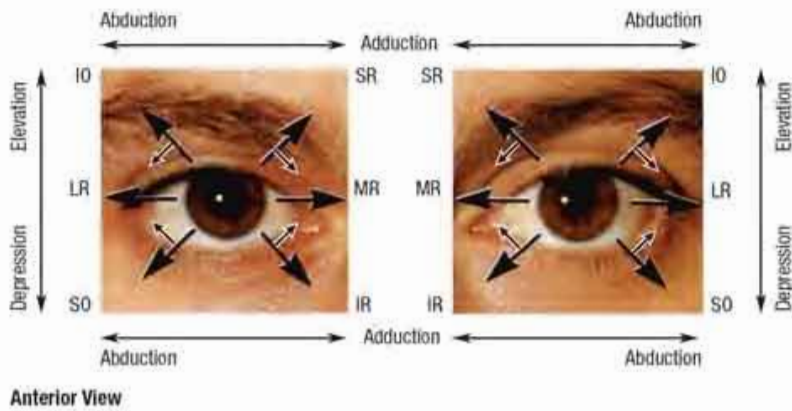
**A. Superior Views**



**B. Superior Views**



**C**



Authors: Agur, Anne M.R.; Dalley, Arthur F.

Title: *Grant's Atlas of Anatomy, 12th Edition*

Copyright ©2009 Lippincott Williams & Wilkins

> Table of Contents > Chapter 7 - Head > 7.37 Illustration of a dissected eyeball

---

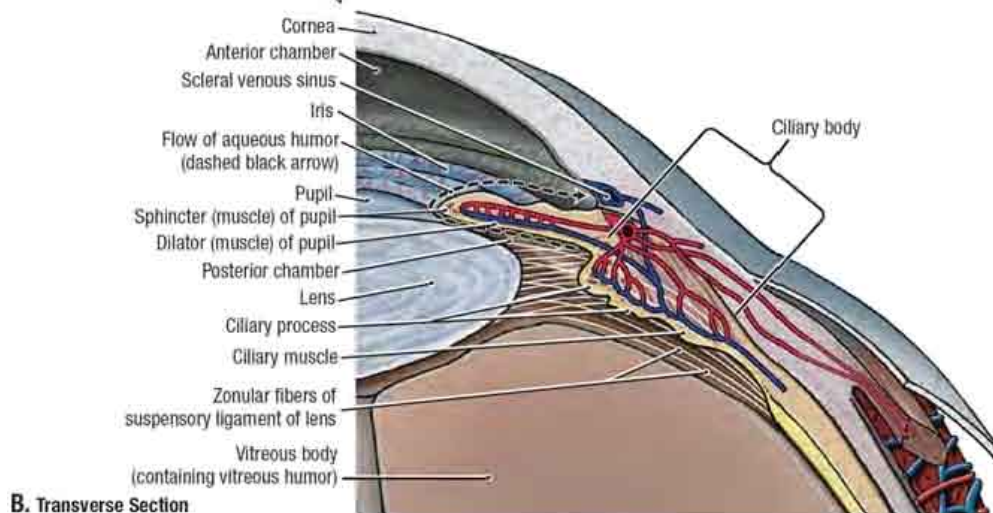
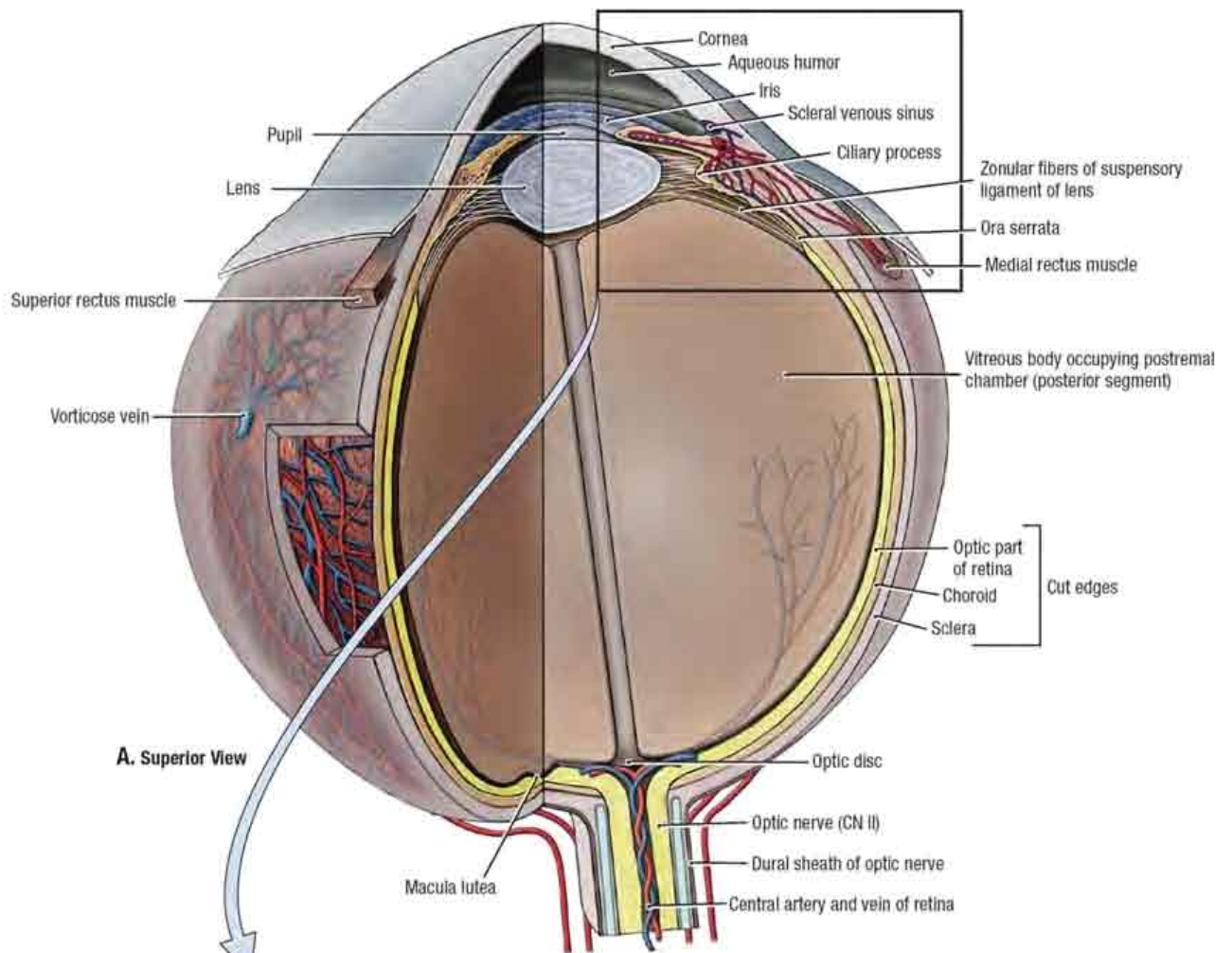
## 7.37 Illustration of a dissected eyeball

*Part of "Chapter 7 - Head "*

A. Parts of the eyeball. B. Ciliary region. The aqueous humor is produced by the ciliary processes and provides nutrients for the avascular cornea and lens; the aqueous humor drains into the scleral venous sinus (also called the *sinus venosus sclerae* or *canal of Schlemm*). If drainage of the aqueous humor is reduced significantly, pressure builds up in the chambers of the eye (glaucoma). Blindness can result from compression of the inner layer of the retina and retinal arteries if aqueous humor production is not reduced to maintain normal intraocular pressure.

---

P.661



Authors: Agur, Anne M.R.; Dalley, Arthur F.

Title: *Grant's Atlas of Anatomy, 12th Edition*

Copyright ©2009 Lippincott Williams & Wilkins

> Table of Contents > Chapter 7 - Head > 7.38 Ocular fundus and blood supply to the eyeball

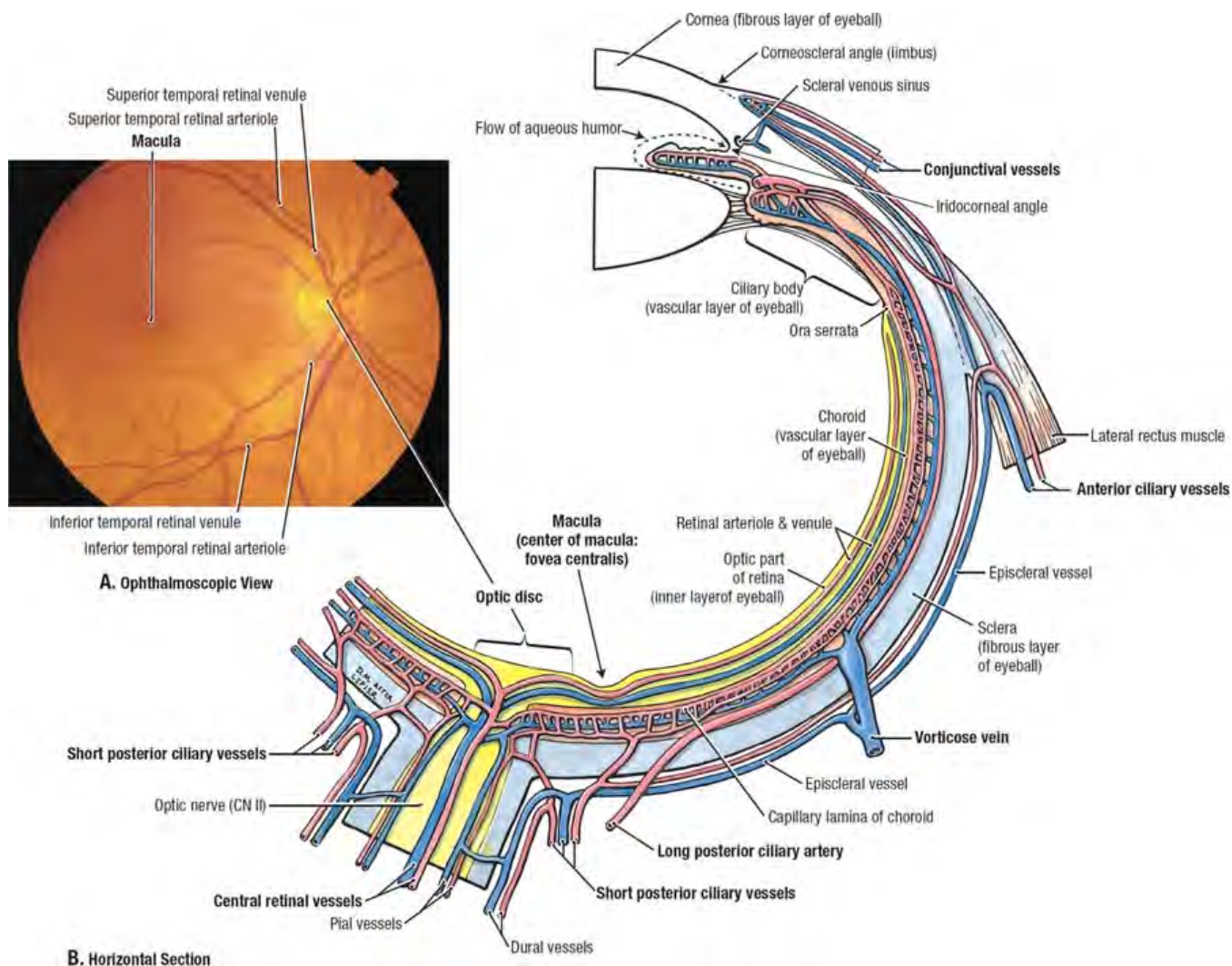
---

## 7.38 Ocular fundus and blood supply to the eyeball

*Part of* "Chapter 7 - Head "

A. Right ocular fundus, ophthalmoscopic view. Retinal venules (wider) and retinal arterioles (narrower) radiate from the center of the oval optic disc, formed in relation to the entry of the optic nerve into the eyeball. The round, dark area lateral to the disc is the macula; branches of vessels extend to this area, but do not reach its center, the fovea centralis, a depressed spot that is the area of most acute vision. It is avascular but, like the rest of the outermost (cones and rods) layer of the retina, is nourished by the adjacent choriocapillaris. An increase in CSF pressure slows venous return from the retina, causing edema of the retina (fluid accumulation). The edema is viewed during ophthalmoscopy as swelling of the optic disc, a condition called papilledema. B. Blood supply to eyeball. The eyeball has three layers: (a) the external, fibrous layer is the sclera and cornea; (b) the middle, vascular layer is the choroid, ciliary body, and iris; and (c) the internal, neural layer or retina consists of a pigment cell layer and a neural layer. The central artery of the retina, a branch of the ophthalmic artery, is an end artery. Of the eight posterior ciliary arteries, six are short posterior ciliary arteries and supply the choroid, which in turn nourishes the outer, nonvascular layer of the retina. Two long posterior ciliary arteries, one on each side of the eyeball, run between the sclera and choroid to anastomose with the anterior ciliary arteries, which are derived from muscular branches. The choroid is drained by posterior ciliary veins, and four to five vorticoses veins drain into the ophthalmic veins.





Authors: Agur, Anne M.R.; Dalley, Arthur F.

Title: *Grant's Atlas of Anatomy, 12th Edition*

Copyright ©2009 Lippincott Williams & Wilkins

> Table of Contents > Chapter 7 - Head > 7.39 Parotid region

---

## 7.39 Parotid region

*Part of "Chapter 7 - Head "*

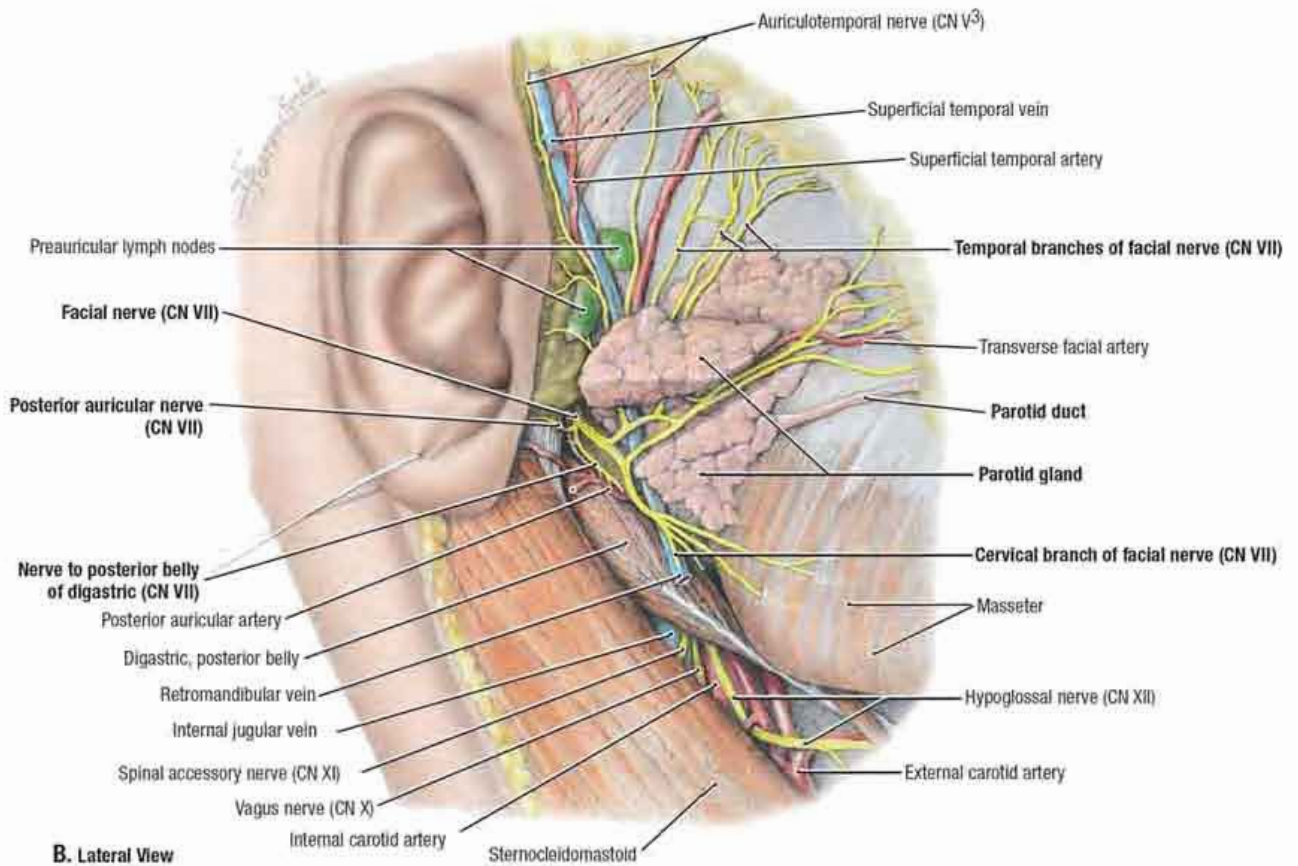
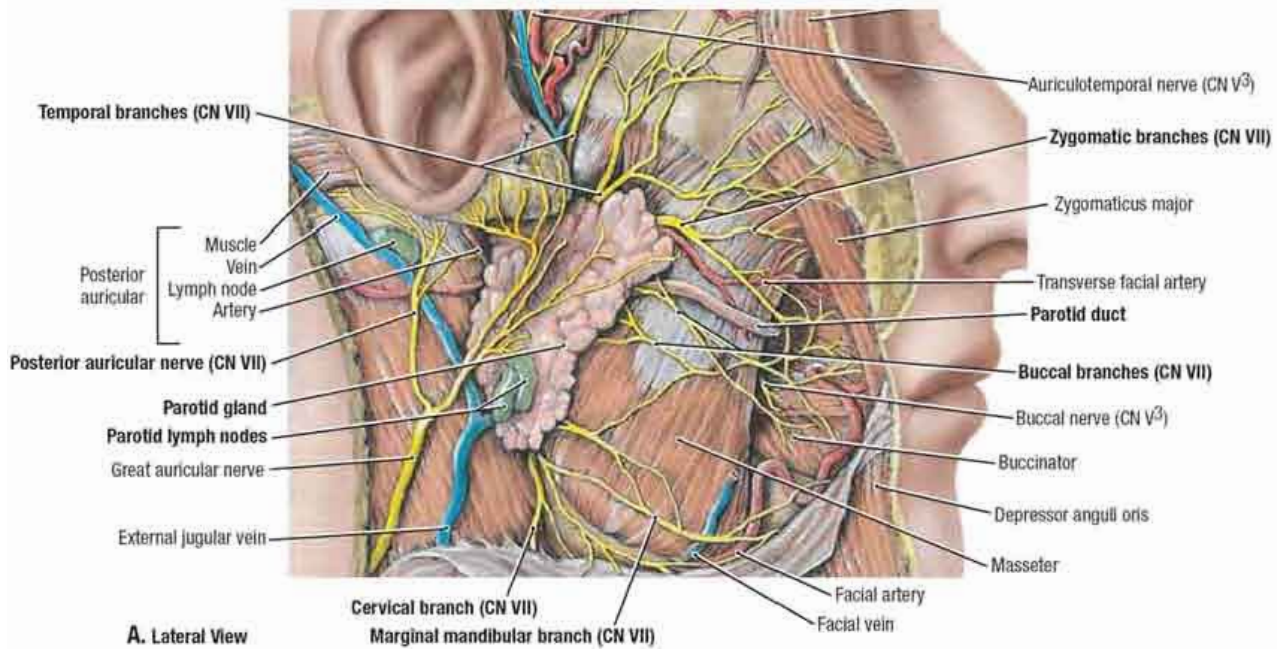
A. Superficial dissection. B. Deep dissection with part of the gland removed. The facial nerve (CN VII) supplies motor innervation to the muscles of facial expression; it forms a plexus within the parotid gland and the branches of which radiate over the face, anastomosing with each other and the branches of the trigeminal nerve. During parotidectomy (surgical excision of the parotid gland), identification, dissection, and preservation of the facial nerve are critical. C. Deep dissection following removal of the parotid gland. The facial nerve, posterior belly of the digastric muscle, and its nerve are retracted; the external carotid artery, stylohyoid muscle, and the nerve to the stylohyoid remain in situ. The internal jugular vein, internal carotid artery, and glossopharyngeal (CN IX), vagus (CN X), accessory (CN XI), and hypoglossal (CN XII) nerves cross anterior to the transverse process of the atlas and deep to the styloid process.

Care must be taken during surgical procedures involving the temporomandibular joint to preserve the branches of the facial nerve that overlie the joint and the articular branches of the auriculotemporal nerve that enter the joint.

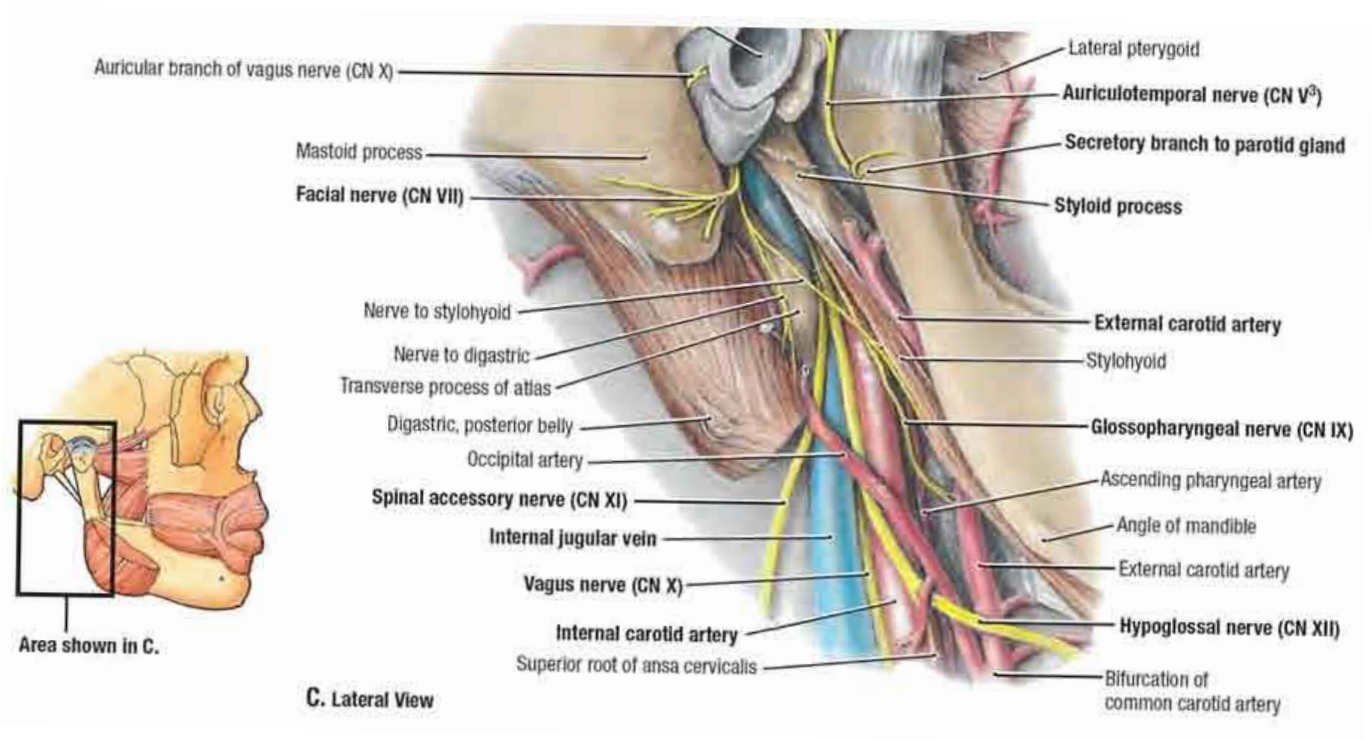
Trauma, such as a fractured mandible, may injure the hypoglossal nerve (CN XII), resulting in paralysis and eventual atrophy of one side of the tongue. The tongue deviates to the paralyzed side during protrusion.

P.664









## 7.40 Temporal and infratemporal fossa and mandible

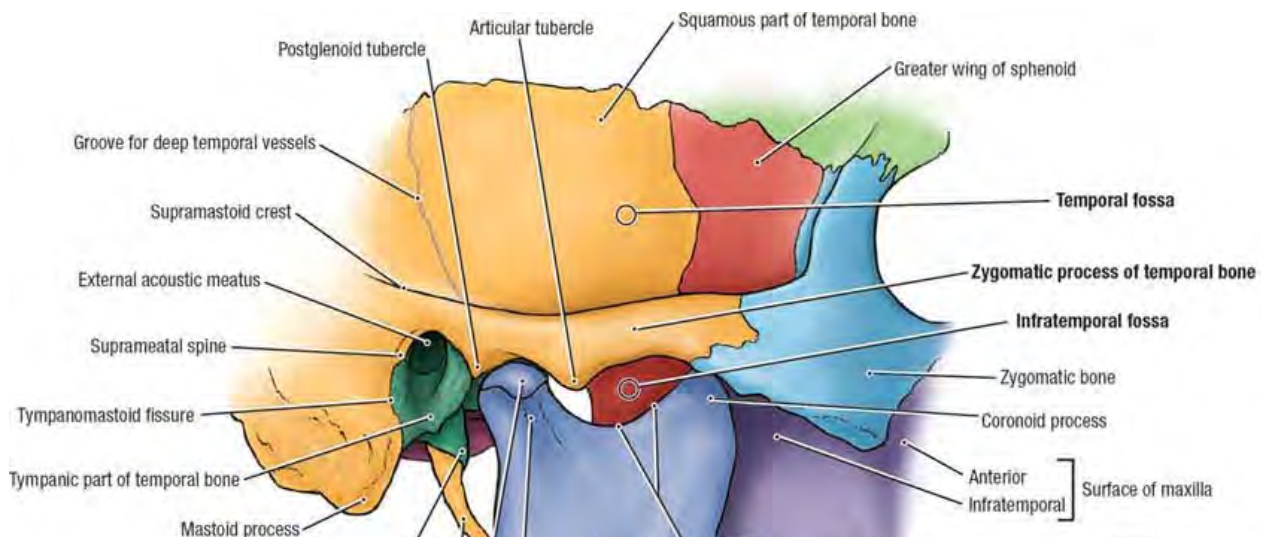
Part of "Chapter 7 - Head "

A. Bones and bony features. Note that superficially the zygomatic process of the temporal bone is the boundary between the temporal fossa superiorly and the infratemporal fossa inferiorly. B. External surface of the mandible. C. Temporal fossa (gray area).

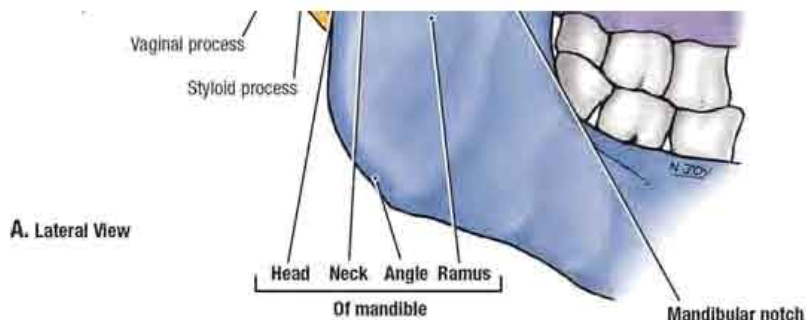
P.665

D. Bones and bony features of the infratemporal fossa. The mandible and part of the zygomatic arch have been removed. Deeply, the infratemporal crest separates the temporal and infratemporal fossae. E. Infratemporal fossa (gray area). F. Internal surface of the mandible.

P.666

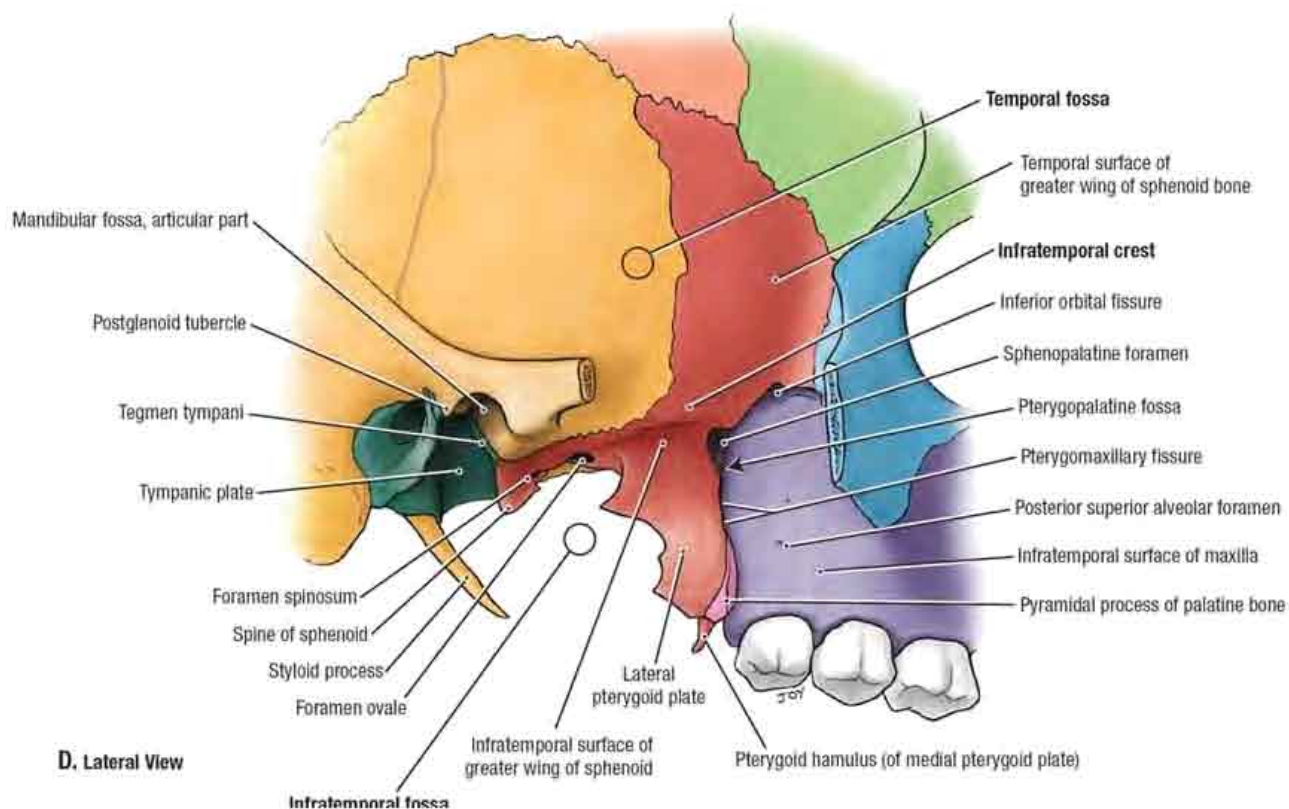
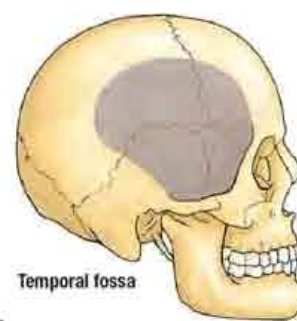
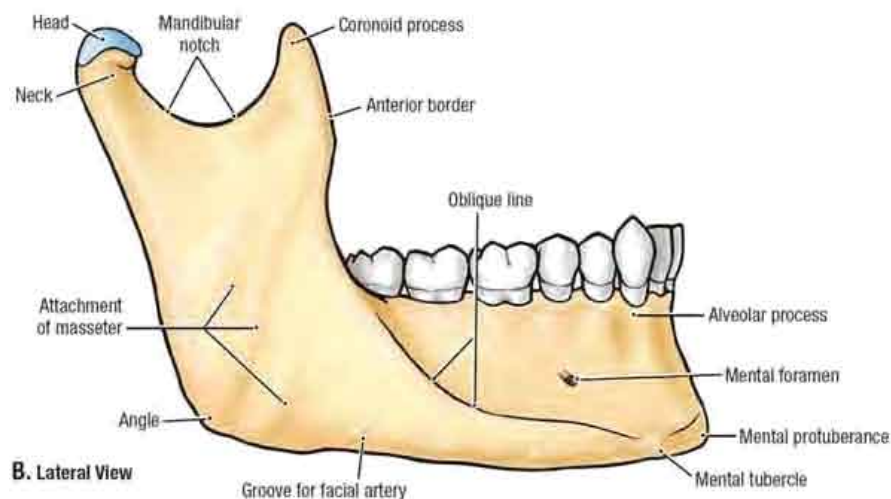


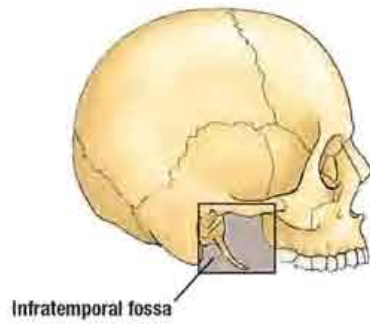




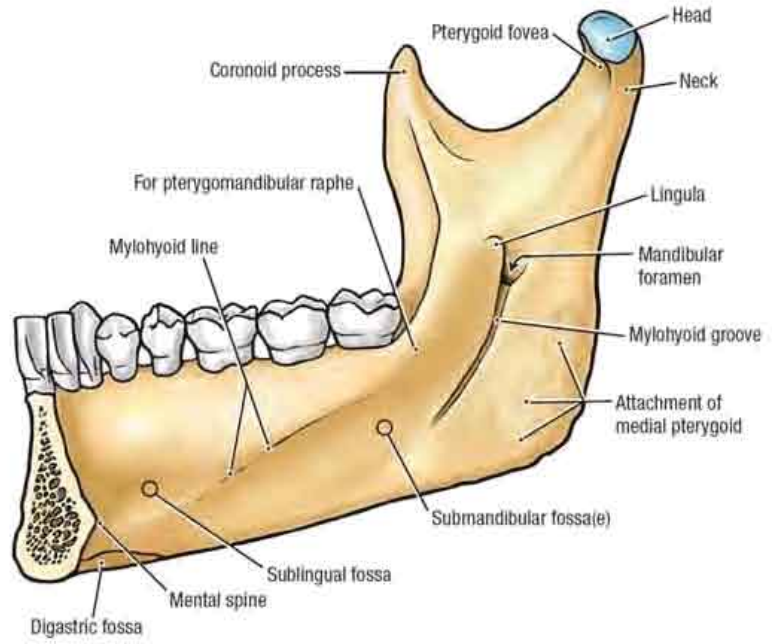
**Bones in A & D:**

Frontal
Mandible
Maxilla
Occipital
Palatine
Parietal
Sphenoid
Temporal (squamous part)
Temporal (tympanic part)
Zygomatic





**E. Lateral View**



**F. Medial View**

Authors: Agur, Anne M.R.; Dalley, Arthur F.

Title: *Grant's Atlas of Anatomy, 12th Edition*

Copyright ©2009 Lippincott Williams & Wilkins

> Table of Contents > Chapter 7 - Head > 7.41 Temporalis and masseter

---

## 7.41 Temporalis and masseter

*Part of "Chapter 7 - Head "*

### A. Superficial dissection.

- The temporalis and masseter muscles are supplied by the trigeminal nerve (CN V), and both elevate the mandible. The buccinator muscle, supplied by the facial nerve (CN VII), functions during chewing to keep food between the teeth but does not act on the mandible.
- The sternocleidomastoid muscle, supplied by the spinal accessory nerve (CN XI), is the chief flexor of the head and neck; it forms the lateral part of the posterior boundary of the parotid region/parotid bed.

---

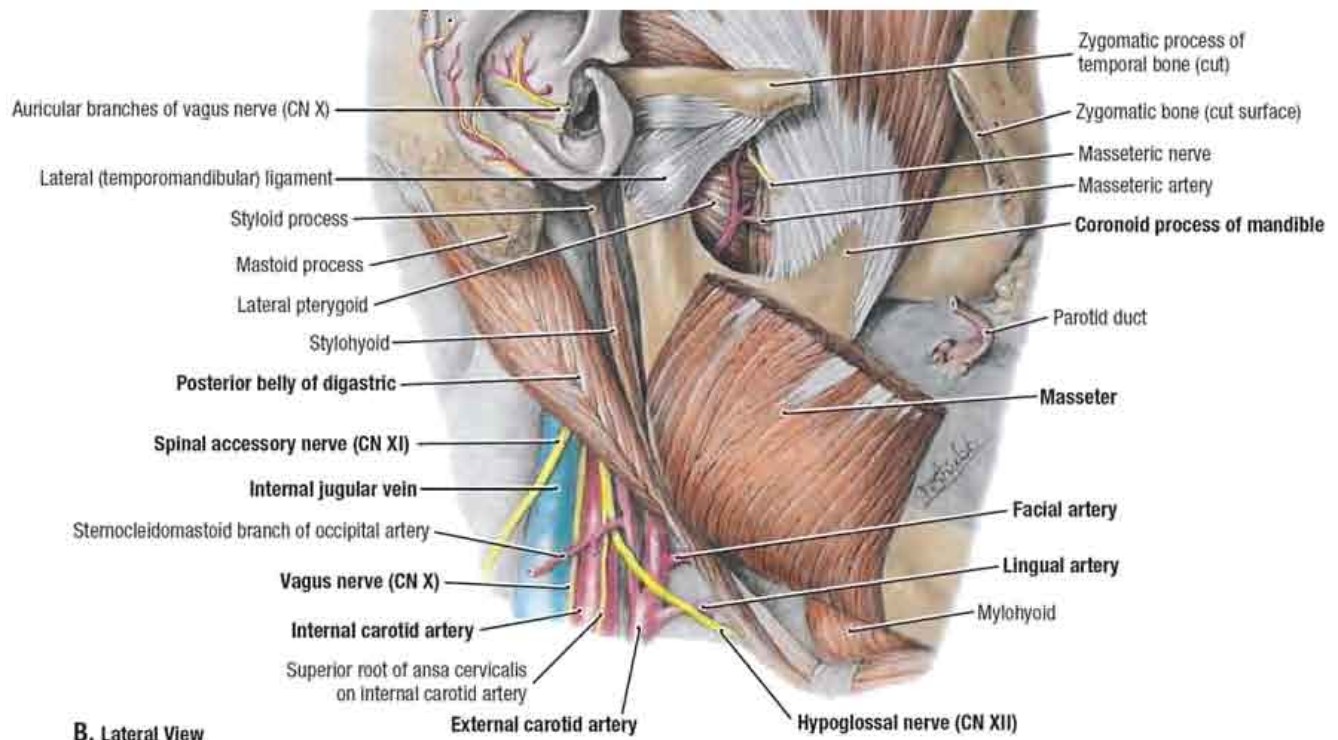
P.667

### B. Deep dissection.

- Parts of the zygomatic arch and the masseter muscle have been removed to expose the attachment of the temporalis muscle to the coronoid process of the mandible.
- The carotid sheath surrounding the internal jugular vein, internal carotid artery, and the vagus nerve (CN X) has been removed. The external carotid artery and its lingual, facial, and occipital branches, and the spinal accessory (CN XI) and hypoglossal (CN XII) nerves pass deep to the posterior belly of the digastric muscle.









Authors: Agur, Anne M.R.; Dalley, Arthur F.

Title: *Grant's Atlas of Anatomy, 12th Edition*

Copyright ©2009 Lippincott Williams & Wilkins

> Table of Contents > Chapter 7 - Head > 7.42 Infratemporal region

---

## 7.42 Infratemporal region

*Part of* "Chapter 7 - Head "

### A. Superficial dissection.


- The maxillary artery, the larger of two terminal branches of the external carotid, is divided into three parts relative to the lateral pterygoid muscle.
- The buccinator is pierced by the parotid duct, the ducts of the buccal glands, and sensory branches of the buccal nerve.
- The lateral pterygoid muscle arises by two heads (parts), one head from the roof, and the other head from the medial wall of the infratemporal fossa; both heads insert in relation to the temporomandibular joint—the superior head attaching primarily to the articular disc of the joint and the inferior head primarily to the anterior aspect of the neck of the mandible (pterygoid fovea).

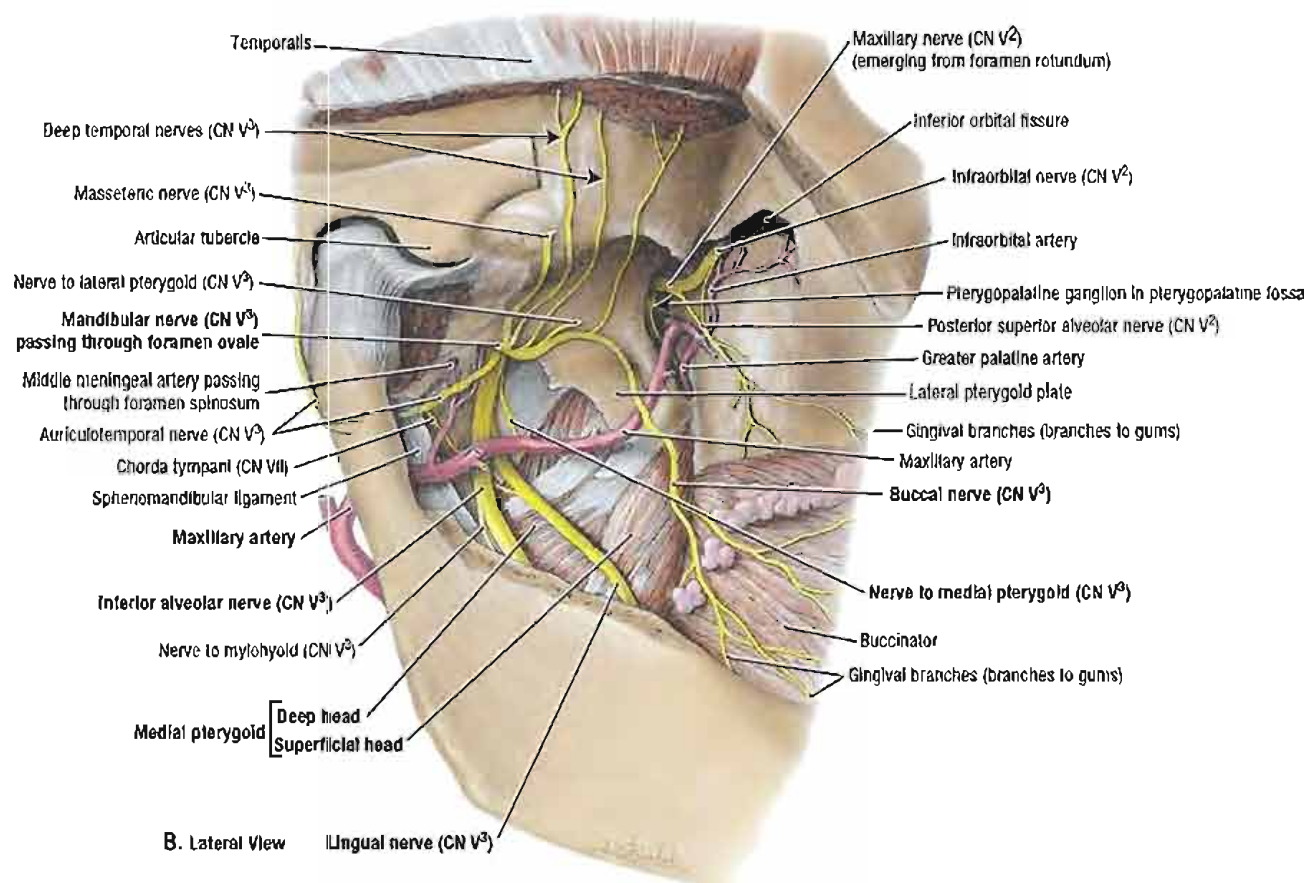
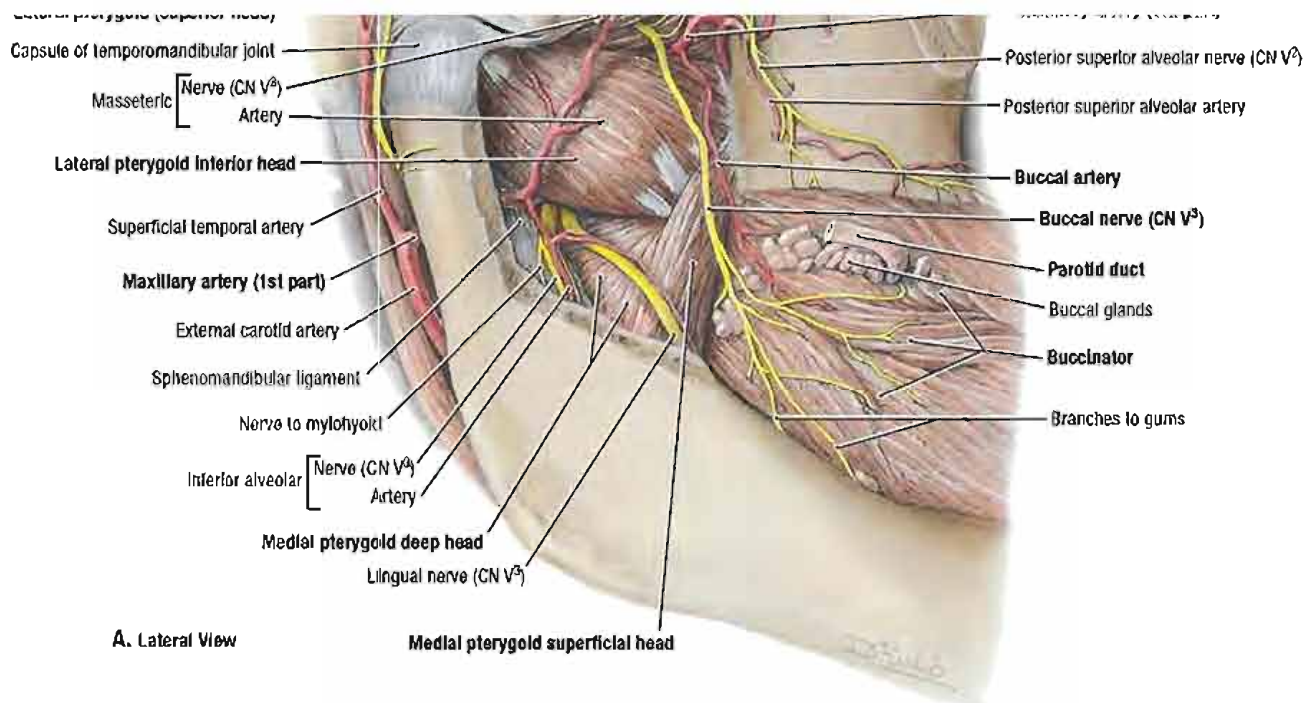
- Because of the close relationship of the facial and auriculotemporal nerves to the temporomandibular joint (TMJ), care must be taken during surgical procedures to preserve both the branches of the facial nerve overlying it and the articular branches of the auriculotemporal nerve that enter the posterior part of the joint. Injury to articular branches of the auriculotemporal nerve supplying the TMJ—associated with traumatic dislocation and rupture of the joint capsule and lateral ligament—leads to laxity and instability of the TMJ.

## B. Deeper dissection.

- The lateral pterygoid muscle and most of the branches of the maxillary artery have been removed to expose the mandibular nerve (CN V<sup>3</sup>) entering the infratemporal fossa through the foramen ovale and the middle meningeal artery passing through the foramen spinosum.
- The deep head of the medial pterygoid muscle arises from the medial surface of the lateral pterygoid plate and the pyramidal process of the palatine bone. It has a small, superficial head that arises from the tuberosity of the maxilla.
- The inferior alveolar and lingual nerves descend on the medial pterygoid muscle. The inferior alveolar nerve gives off the nerve to mylohyoid and nerve to anterior belly of the digastric muscle, and the lingual nerve receives the chorda tympani, which carries secretory parasympathetic fibers and fibers of taste.
- Motor nerves arising from CN V<sup>3</sup> supply the four muscles of mastication: the masseter, temporalis, and lateral and medial pterygoids. The buccal nerve from the mandibular nerve is sensory; the buccal branch of the facial nerve is the motor supply to the buccinator muscle.

- To perform a mandibular nerve block, an anesthetic agent is injected near the mandibular nerve where it enters the infratemporal fossa. This block usually anesthetizes the auriculotemporal, inferior alveolar, lingual, and buccal branches of the mandibular nerve.





Authors: Agur, Anne M.R.; Dalley, Arthur F.

Title: *Grant's Atlas of Anatomy, 12th Edition*

Copyright ©2009 Lippincott Williams & Wilkins

> Table of Contents > Chapter 7 - Head > 7.43 Branches of maxillary artery

---

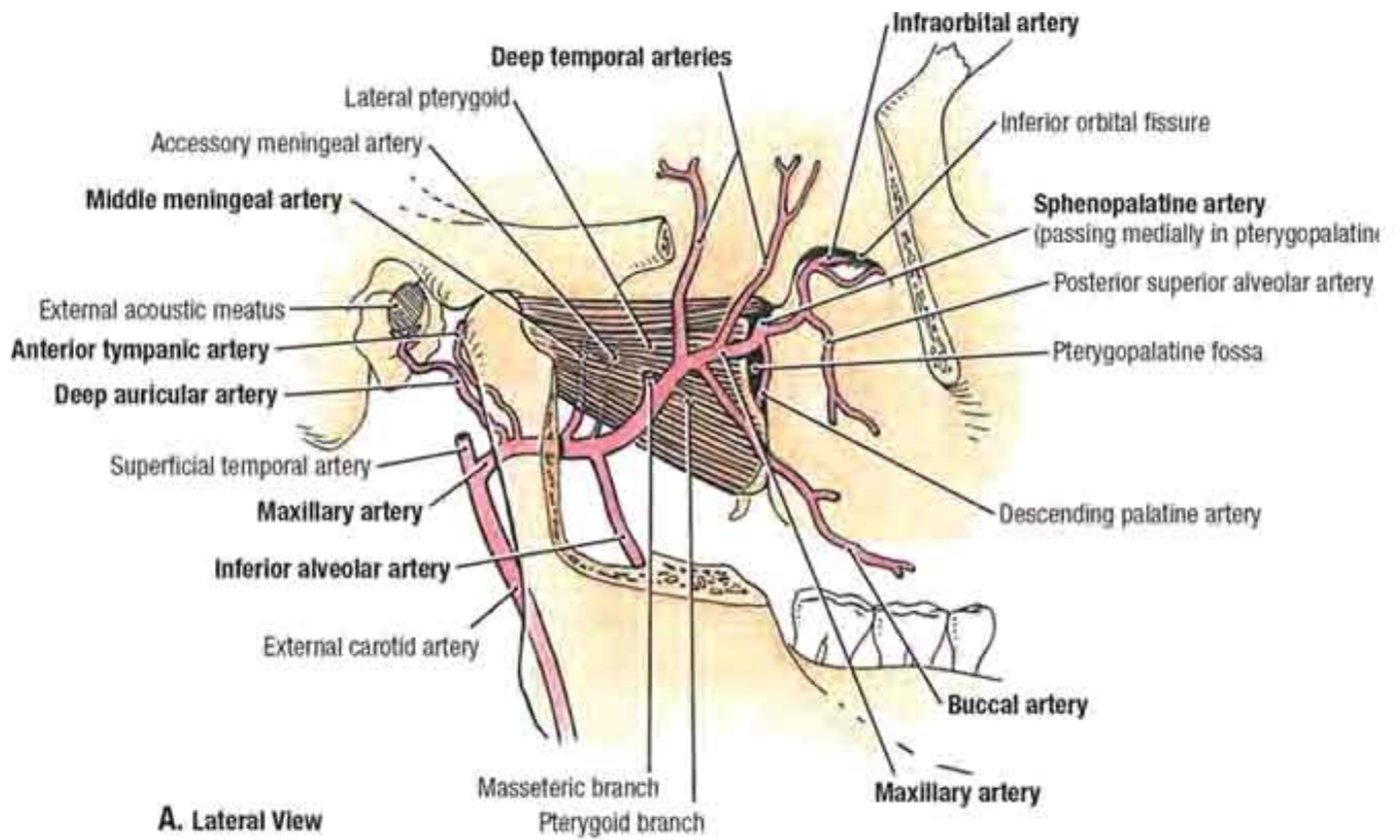
## 7.43 Branches of maxillary artery

*Part of* "Chapter 7 - Head "

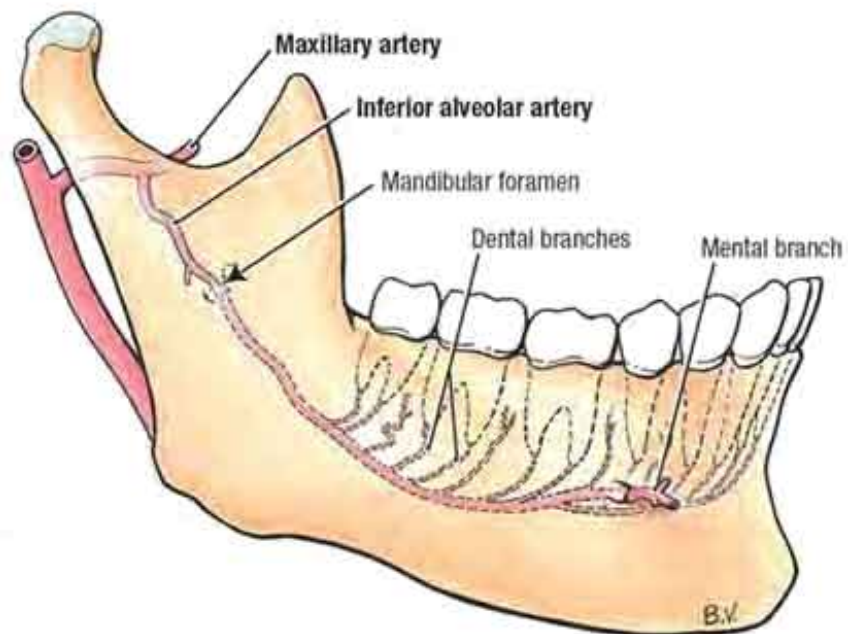
A. Infratemporal region. B. Mandible.

- The maxillary artery arises at the neck of the mandible and is divided into three parts: the first (retromandibular), the second (directly related to the lateral pterygoid), and the third (pterygopalatine). The first part gives off the deep auricular, anterior tympanic, middle meningeal, and inferior alveolar arteries. The second part gives off the masseteric, deep temporal, pterygoid, and buccal arteries. The third part gives off the posterior superior alveolar, infraorbital, descending palatine, and sphenopalatine arteries.
- The maxillary artery arises at the neck of the mandible and is divided into three parts: the first (retromandibular), the second (directly related to the lateral pterygoid), and the third (pterygopalatine). The first part gives off the deep auricular, anterior tympanic, middle meningeal, and inferior alveolar arteries. The second part gives off the masseteric, deep temporal, pterygoid, and buccal arteries. The third part gives off the posterior superior alveolar, infraorbital, descending palatine, and sphenopalatine arteries.
- The branches of the first or retromandibular part pass through foramina or canals: the deep auricular to the external acoustic meatus, the anterior tympanic to the tympanic cavity, the middle and accessory meningeal to the cranial cavity, and the inferior alveolar to the mandible and teeth.
- The branches of the second part (directly related to the lateral pterygoid) supply muscles via the masseteric, deep temporal, pterygoid, and buccal branches.
- The branches of the third (pterygopalatine) part (posterior superior alveolar, infraorbital, descending palatine, and sphenopalatine arteries) arise immediately proximal to and within the pterygopalatine fossa.





**B. Lateral View**





Authors: Agur, Anne M.R.; Dalley, Arthur F.

Title: *Grant's Atlas of Anatomy, 12th Edition*

Copyright ©2009 Lippincott Williams & Wilkins

> Table of Contents > Chapter 7 - Head > 7.44 Branches of maxillary and mandibular nerves

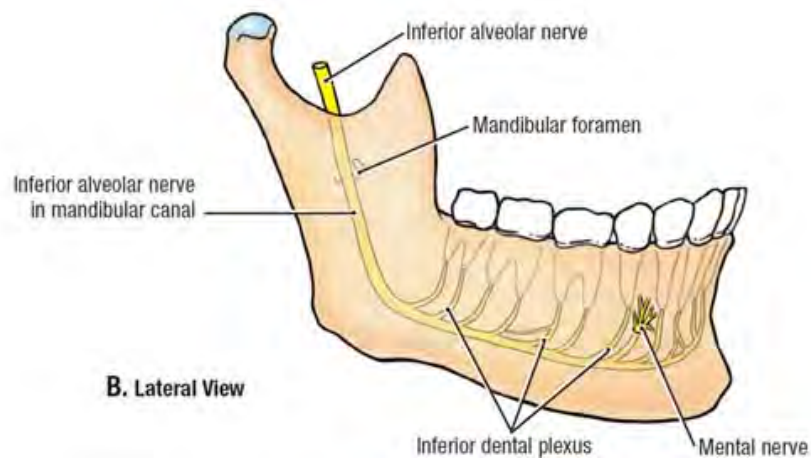
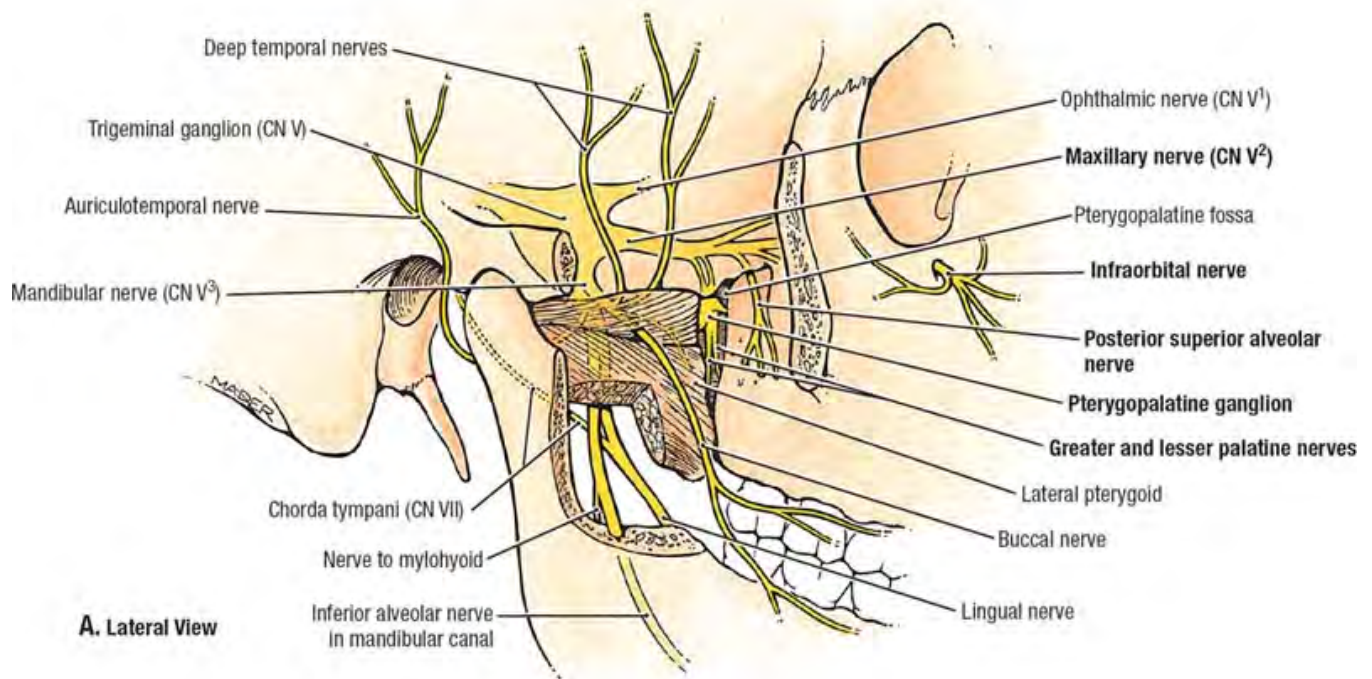
---

## 7.44 Branches of maxillary and mandibular nerves

*Part of* "Chapter 7 - Head "

A. Infratemporal region and pterygopalatine fossa. Branches of the maxillary (CN V<sup>2</sup>) and mandibular (CN V<sup>3</sup>) nerves accompany branches from the three parts of the maxillary artery. B. Mandible and inferior alveolar nerve.

An alveolar nerve block—commonly used by dentists when repairing mandibular teeth—anesthetizes the inferior alveolar nerve, a branch of CN V<sup>3</sup>. The anesthetic agent is injected around the mandibular foramen, the opening into the mandibular canal on the medial aspect of the ramus of the mandible. This canal gives passage to the inferior alveolar nerve, artery, and vein. When this nerve block is successful, all mandibular teeth are anesthetized to the median plane. The skin and mucous membrane of the lower lip, the labial alveolar mucosa and gingiva, and the skin of the chin are also anesthetized because they are supplied by the mental branch of this nerve.



## Temporails

Floor of temporal fossa and deep surface of temporal fascia

Tip and medial surface of coronoid process and anterior border of ramus of mandible

Deep temporal branches of mandibular nerve (CN V<sup>3</sup>)

Elevates mandible, closing jaws; posterior fibers retrude mandible after protrusion

## Masseter

Inferior border and medial surface of zygomatic arch

Lateral surface of ramus of mandible and coronoid process

Mandibular nerve (CN V<sup>3</sup>) through masseteric nerve that enters deep surface of the muscle

Elevates and protrudes mandible, thus closing jaws; deep fibers retract it

## Lateral pterygoid

*Superior head:* infratemporal surface and infratemporal crest of greater wing of sphenoid bone

*Inferior head:* lateral surface of lateral pterygoid plate

Neck of mandible, articular disc, and capsule of temporomandibular joint

Mandibular nerve (CN V<sup>3</sup>) through lateral pterygoid nerve which enters its deep surface

*Acting bilaterally*, protrude mandible and depress chin; *Acting unilaterally* alternately, they produce side-to-side movements of mandible

## Medial pterygoid

*Deep head:* medial surface of lateral pterygoid plate and pyramidal process of palatine bone

*Superficial head:* tuberosity of maxilla

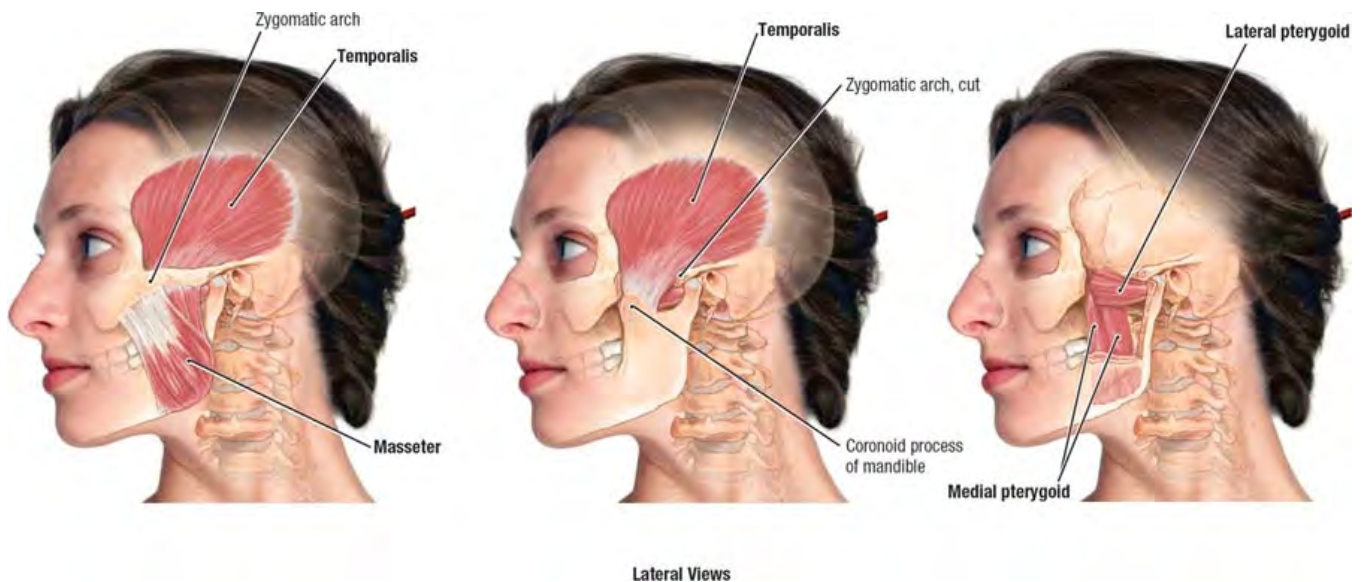
Medial surface of ramus of mandible, inferior to mandibular foramen

Mandibular nerve (CN V<sup>3</sup>) through medial pterygoid nerve

Helps elevate mandible, closing jaws; *acting bilaterally* protrude mandible; *acting unilaterally*, protrudes side of jaw; acting alternately, they produce a grinding motion

Muscle	Origin	Insertion	Innervation	Main Action
--------	--------	-----------	-------------	-------------

<p>Table 7.9 Muscles of Mastication (Acting on Temporomandibular Joint)</p>
---



Elevation (close mouth) (A)

Temporalis, masseter, and medial pterygoid

Depression (open mouth) (B)

Lateral pterygoid; suprahyoid and infrahyoid muscles; gravity

Protrusion (protrude chin) (C and E)

Lateral pterygoid, masseter, and medial pterygoid

Retrusion (retrude chin) (D)

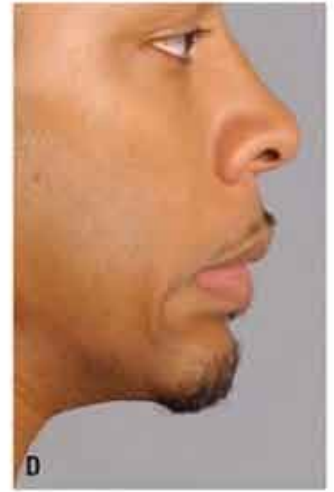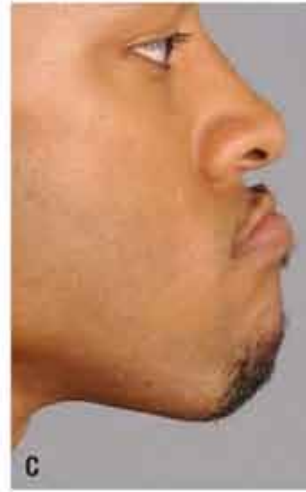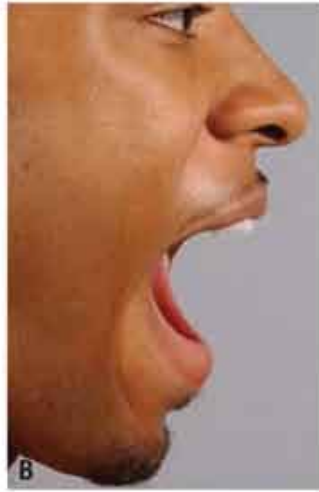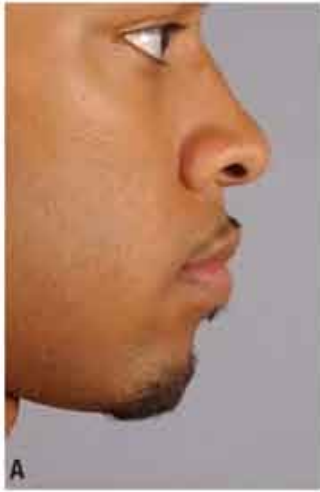Temporalis (posterior oblique and near horizontal fibers) and masseter

Lateral movements (grinding and chewing) (F and G)

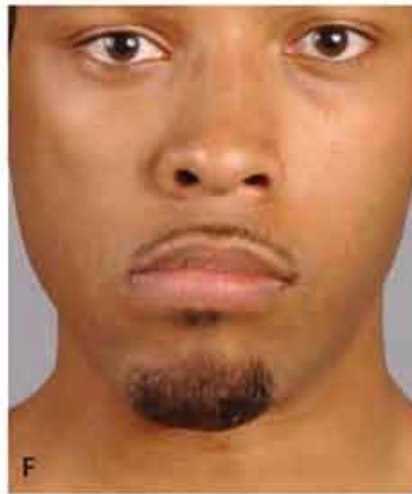
Temporalis of same side, pterygoids of opposite side, and masseter

Movements    Muscles

## Table 7.10 Movements of the Temporomandibular Joint



Lateral Views



Anterior Views



Authors: Agur, Anne M.R.; Dalley, Arthur F.

Title: *Grant's Atlas of Anatomy, 12th Edition*

Copyright ©2009 Lippincott Williams & Wilkins

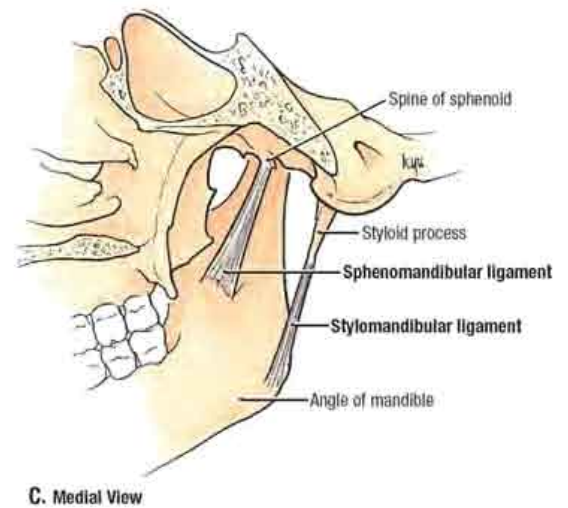
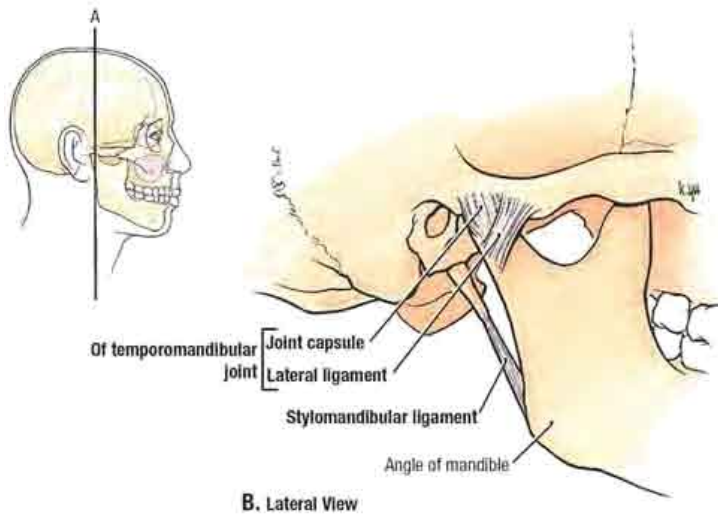
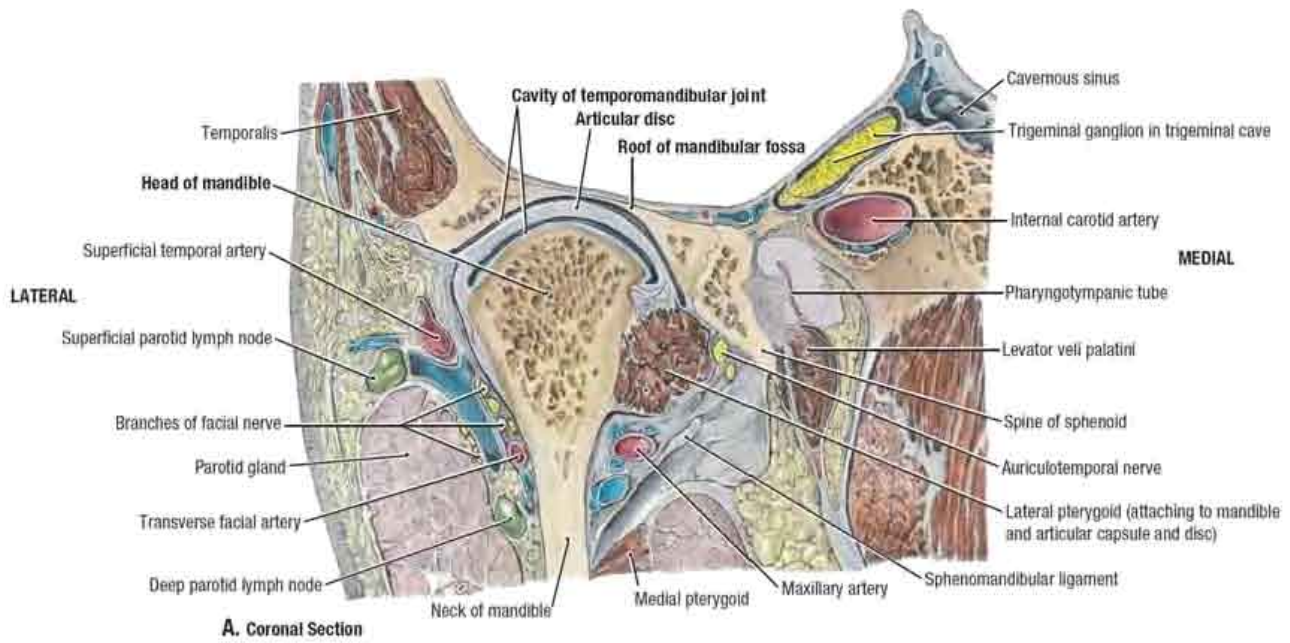
> Table of Contents > Chapter 7 - Head > 7.45 Temporomandibular joint

---

## 7.45 Temporomandibular joint

*Part of "Chapter 7 - Head "*

A. Coronal section. B. Temporomandibular joint and stylomandibular ligament. The joint capsule of the temporomandibular joint attaches to the margins of the mandibular fossa and articular tubercle of the temporal bone and around the neck of the mandible; the lateral (temporomandibular) ligament strengthens the lateral aspect of the joint. C. Stylomandibular and sphenomandibular ligaments. The strong sphenomandibular ligament descends from near the spine of the sphenoid to the lingula of the mandible and is the "swinging hinge" by which the mandible is suspended; the weaker stylomandibular ligament is a thickened part of the parotid sheath that joins the styloid process to the angle of the mandible.



Authors: Agur, Anne M.R.; Dalley, Arthur F.

Title: *Grant's Atlas of Anatomy, 12th Edition*

Copyright ©2009 Lippincott Williams & Wilkins

> Table of Contents > Chapter 7 - Head > 7.46 Sectional anatomy of temporomandibular joint (TMJ)

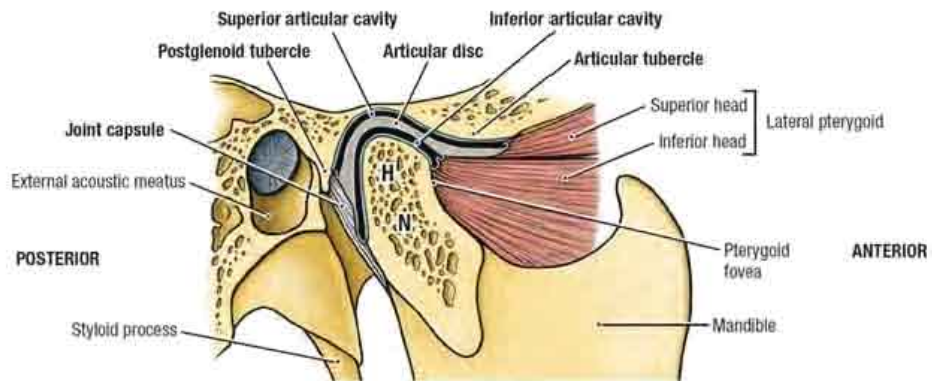
---

## 7.46 Sectional anatomy of temporomandibular joint (TMJ)

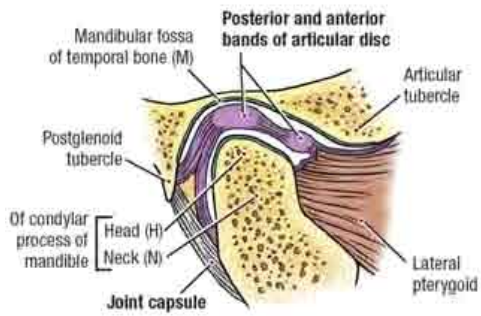
*Part of "Chapter 7 - Head "*

A. TMJ and related structures, sagittal section. B. Sagittal orientation figure, CT, and MRI—mouth closed. C. Sagittal orientation figure, CT, and MRI—mouth opened widely. The articular disc divides the articular cavity into superior and inferior compartments, each lined by a separate synovial membrane.

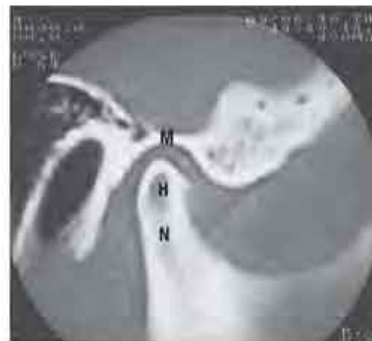During yawning or taking large bites, excessive contraction of the lateral pterygoids can cause the head of the mandible to dislocate (pass anterior to the articular tubercle). In this position, the mouth remains wide open, and the person cannot close it without manual distraction.



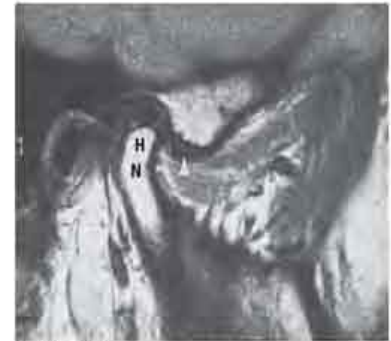**A. Sagittal Section**



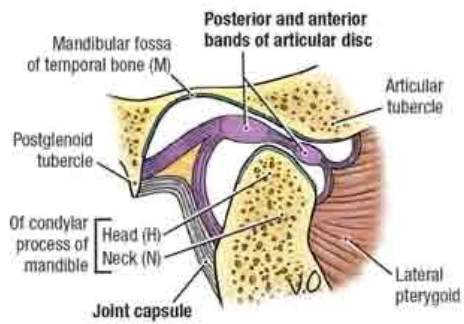
**B. Closed Mouth, Sagittal Section**



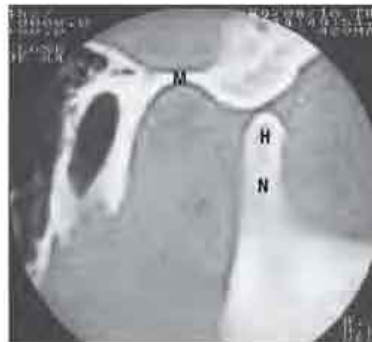**Sagittal CT**



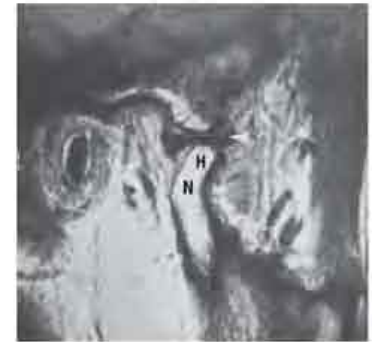**Sagittal MRI**



**C. Open Mouth, Sagittal Section**



**Sagittal CT**



**Sagittal MRI**

## 7.47 Tongue

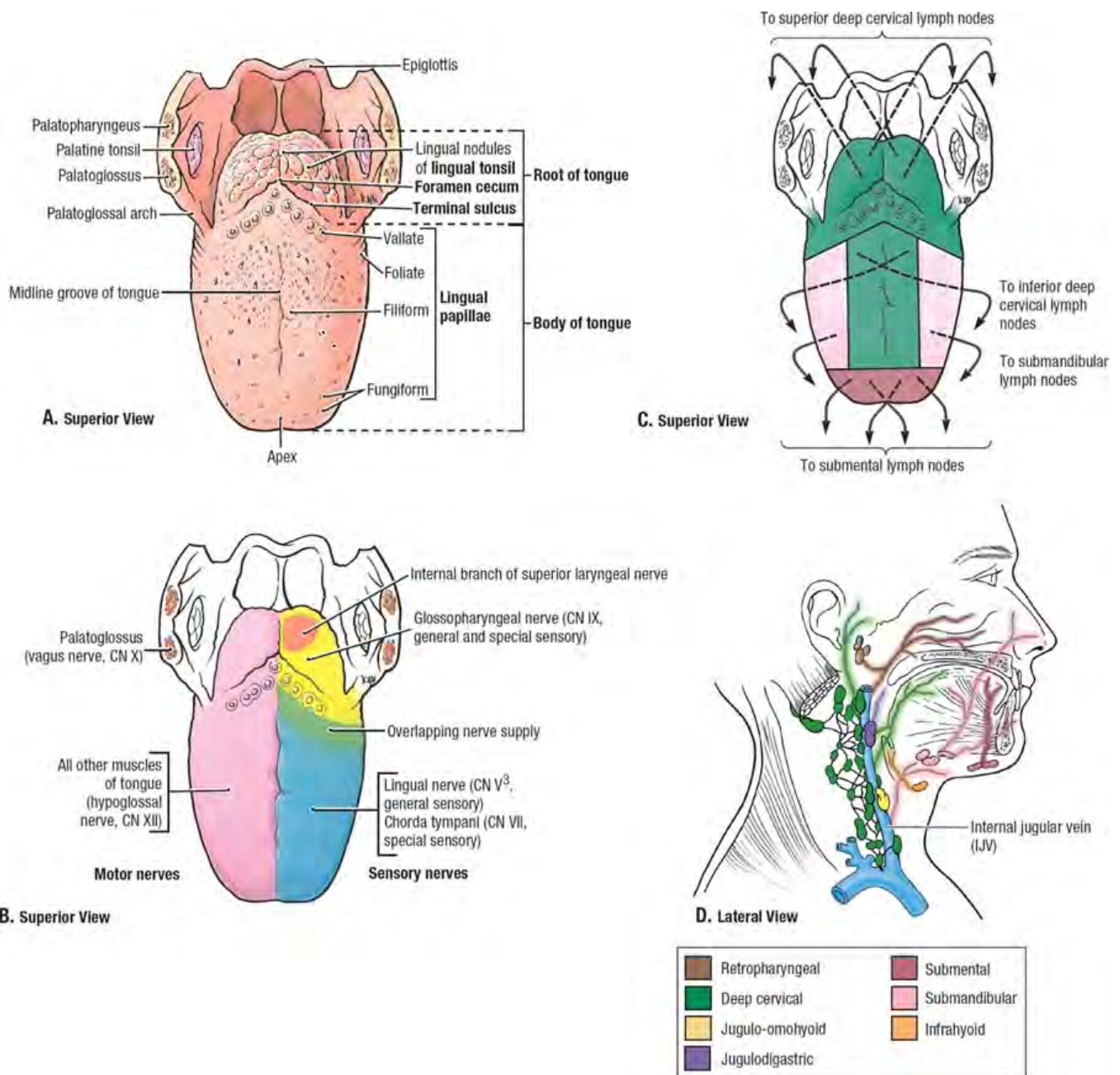
*Part of "Chapter 7 - Head "*

A. Features of dorsum of the tongue. The foramen cecum is the upper end of the primitive thyroglossal duct; the arms of the V-shaped terminal sulcus diverge from the foramen, demarcating the posterior third of the tongue from the anterior two thirds. B. General sensory, special sensory (taste), and motor innervation of tongue. C. Lymphatic drainage of dorsum of tongue. D. Lymphatic drainage of tongue, mouth, nasal cavity, and nose.

Malignant tumors in the posterior part of the tongue metastasize to the superior deep cervical lymph nodes on both sides. In contrast, tumors in the apex and anterolateral parts usually do not metastasize to the inferior deep cervical nodes until late in the disease. Because the deep nodes are closely related to the internal jugular vein (IJV), metastases from the carcinoma may spread to the submental and submandibular regions and along the IJV into the neck.

One may touch the anterior part of the tongue without feeling discomfort; however, when the posterior part is touched, one usually gags. CN IX and CN X are responsible for the muscular contraction of each side of the pharynx. Glossopharyngeal branches (CN IX) provide the afferent limb of the gag reflex.





## Genioglossus

Superior part of mental spine of mandible

Dorsum of tongue and body of hyoid bone

Hypoglossal nerve (CN XII)

Depresses tongue; its posterior part pulls tongue anteriorly for protrusion

Hyoglossus

Body and greater horn of hyoid bone

Side and inferior aspect of tongue

Depresses and retracts tongue

Styloglossus

Styloid process of temporal bone and stylohyoid ligament

Side and inferior aspect of tongue

Retracts tongue and draws it up to create a trough for swallowing

Palatoglossus

Palatine aponeurosis of soft palate

Side of tongue

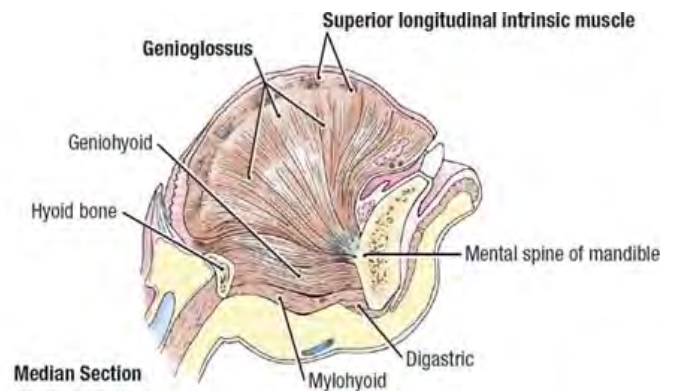
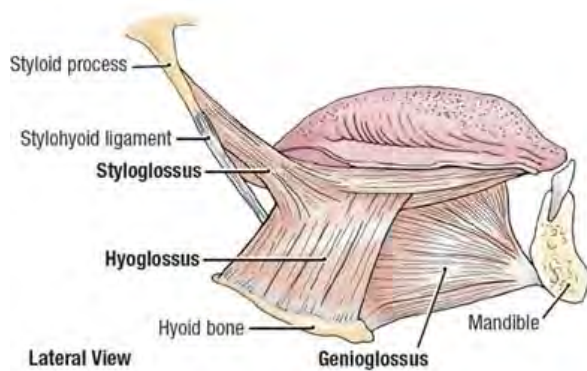
CN X and pharyngeal plexus

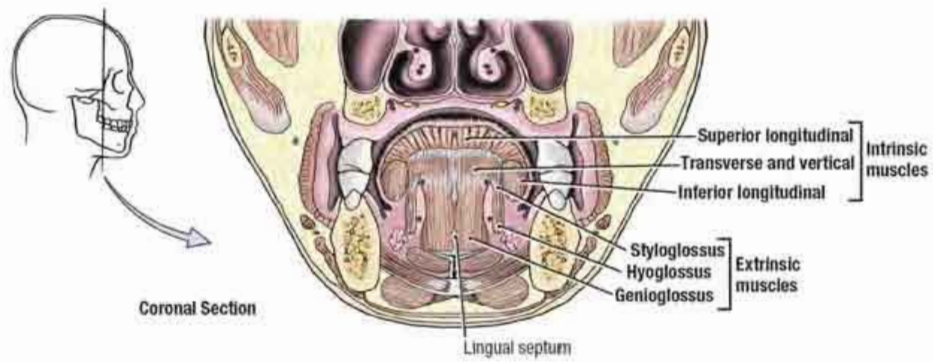
Elevates posterior part of tongue

### Extrinsic Muscles

Muscle	Origin	Insertion	Innervation	Main Action
--------	--------	-----------	-------------	-------------

Table 7.11 Muscles of Tongue





Intrinsic Muscles				
Muscle	Origin	Insertion	Innervation	Main Action
<b>Superior longitudinal</b>	Submucous fibrous layer and lingual septum	Margins and mucous membrane of tongue	Hypoglossal nerve (CN XII)	Curls tip and sides of tongue superiorly and shortens tongue
<b>Inferior longitudinal</b>	Root of tongue and body of hyoid bone	Apex of tongue		Curls tip of tongue inferiorly and shortens tongue
<b>Transverse</b>	Lingual septum	Fibrous tissue at margins of tongue		Narrows and elongates the tongue <sup>a</sup>
<b>Vertical</b>	Superior surface of borders of tongue	Inferior surface of borders of tongue		Flattens and broadens the tongue <sup>a</sup>

<sup>a</sup>Acts simultaneously to protrude tongue.

Authors: Agur, Anne M.R.; Dalley, Arthur F.

Title: *Grant's Atlas of Anatomy, 12th Edition*

Copyright ©2009 Lippincott Williams & Wilkins

> Table of Contents > Chapter 7 - Head > 7.48 Sections through mouth

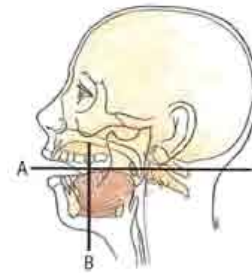
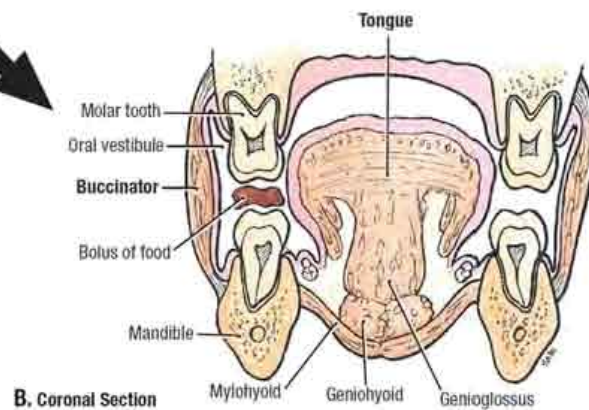
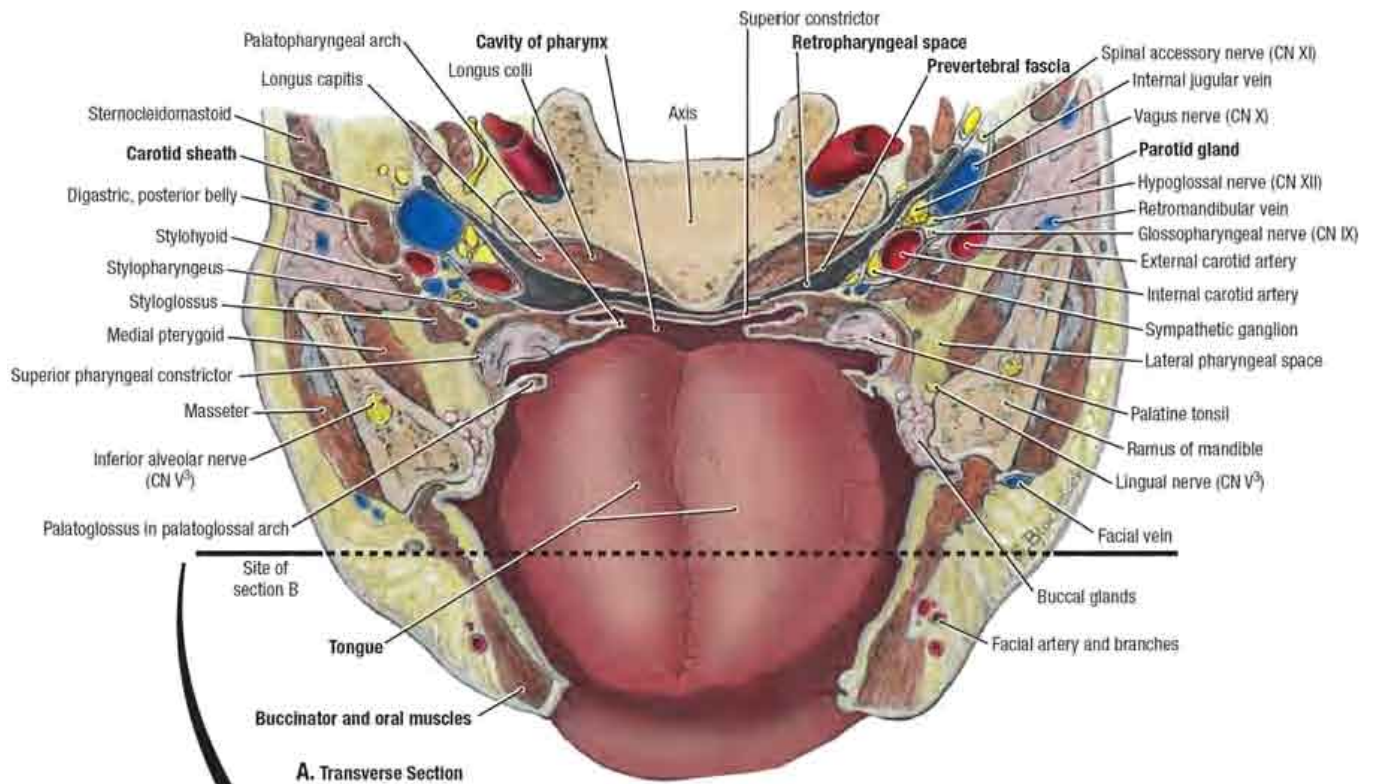
---

## 7.48 Sections through mouth

*Part of "Chapter 7 - Head "*

A. The viscerocranium has been sectioned at the C1 vertebral level, the plane of section passing through the oral fissure anteriorly. The retropharyngeal space (opened up in this specimen) allows the pharynx to contract and relax during swallowing; the retropharyngeal space is closed laterally at the carotid sheath and limited posteriorly by the prevertebral fascia. The beds of the parotid glands are also demonstrated. B. Schematic coronal section demonstrating how the tongue and buccinator (or, anteriorly, the orbicularis oris) work together to retain food between the teeth when chewing. The buccinator and superior part of the orbicularis oris are innervated by the buccal branch of the facial nerve (CN VII).







Authors: Agur, Anne M.R.; Dalley, Arthur F.

Title: *Grant's Atlas of Anatomy, 12th Edition*

Copyright ©2009 Lippincott Williams & Wilkins

> Table of Contents > Chapter 7 - Head > 7.49 Tongue and floor of mouth

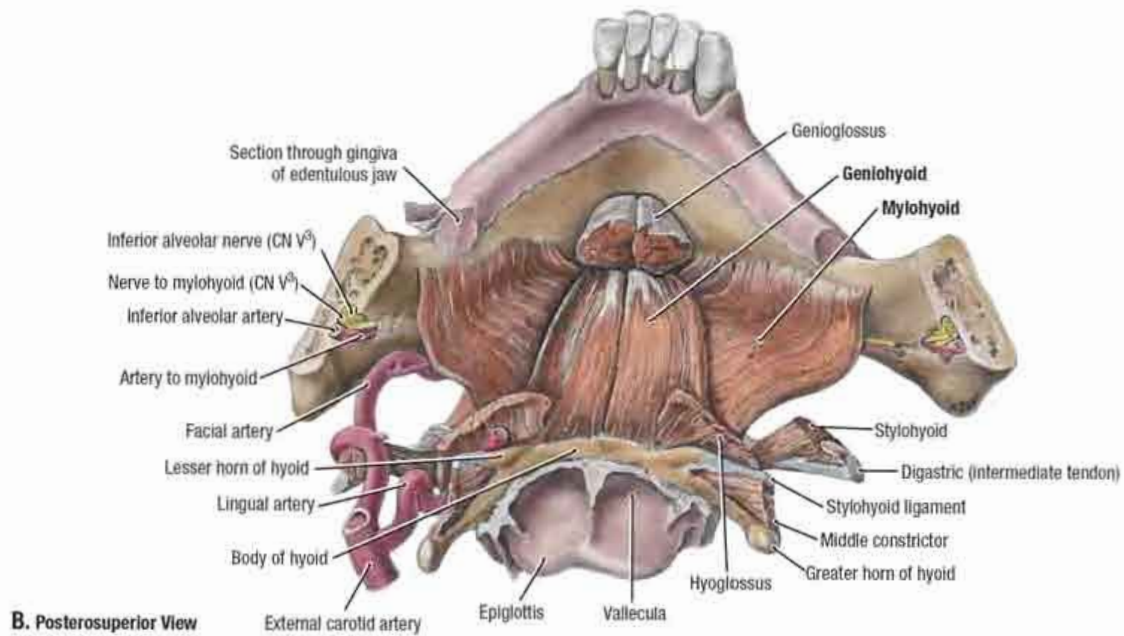
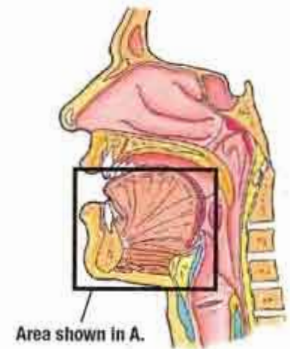
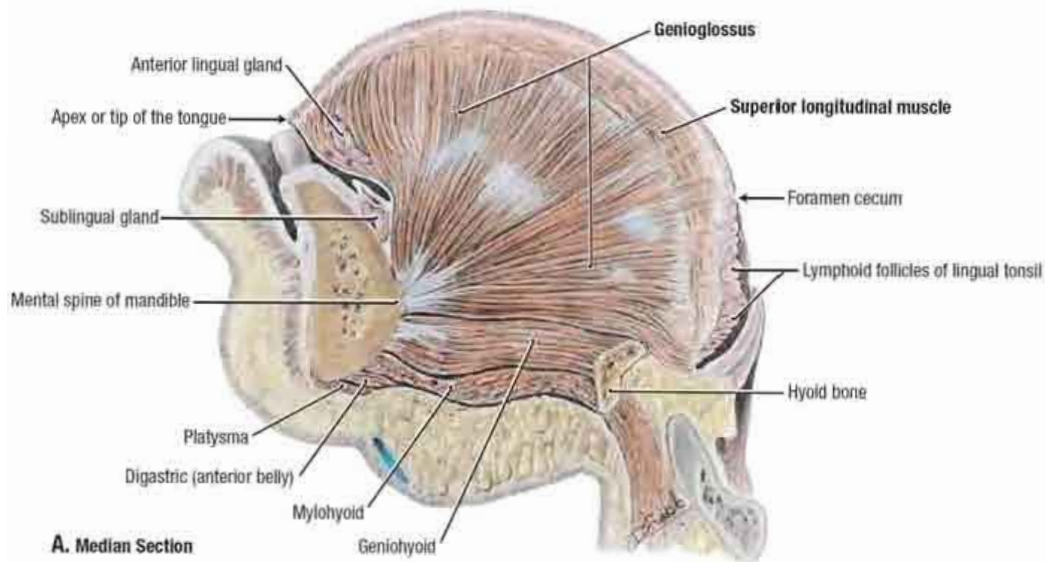
---

## 7.49 Tongue and floor of mouth

*Part of "Chapter 7 - Head "*

A. Median section through the tongue and lower jaw. The tongue is composed mainly of muscle; extrinsic muscles alter the position of the tongue, and intrinsic muscles alter its shape. The genioglossus is the extrinsic muscle apparent in this plane, and the superior longitudinal muscle is the intrinsic muscle. B. Muscles of the floor of the mouth viewed posterosuperiorly. The mylohyoid muscle extends between the two mylohyoid lines of the mandible. It has a thick, free posterior border and becomes thinner anteriorly.

When the genioglossus is paralyzed, the tongue mass has a tendency to shift posteriorly, obstructing the airway and presenting the risk of suffocation. Total relaxation of the genioglossus muscles occurs during general anesthesia; therefore, the tongue of an anesthetized patient must be prevented from relapsing by inserting an airway.



Authors: Agur, Anne M.R.; Dalley, Arthur F.

Title: *Grant's Atlas of Anatomy, 12th Edition*

Copyright ©2009 Lippincott Williams & Wilkins

> Table of Contents > Chapter 7 - Head > 7.50 Arteries and nerves of the tongue

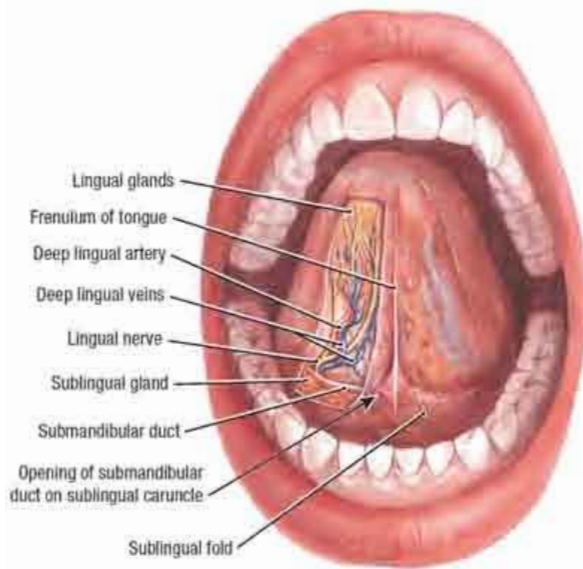
---

## 7.50 Arteries and nerves of the tongue

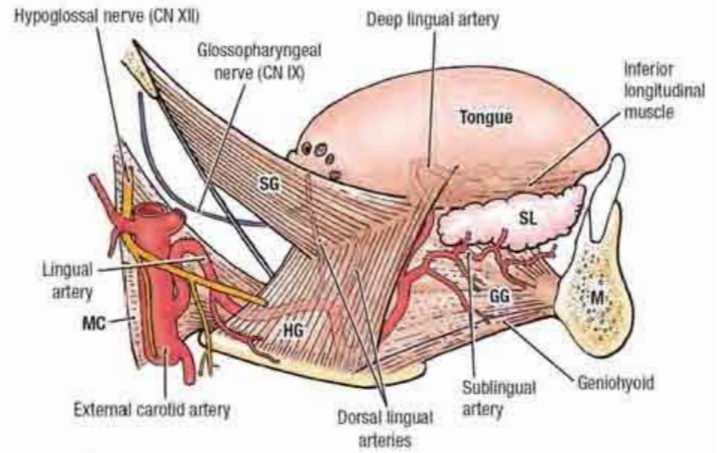
*Part of "Chapter 7 - Head "*

A. Inferior surface of the tongue and floor of the mouth. The thin sublingual mucosa has been removed on the left side. B. Course and distribution of the lingual artery. C. Dissection of right side of floor of mouth. Letters in parentheses refer to B .

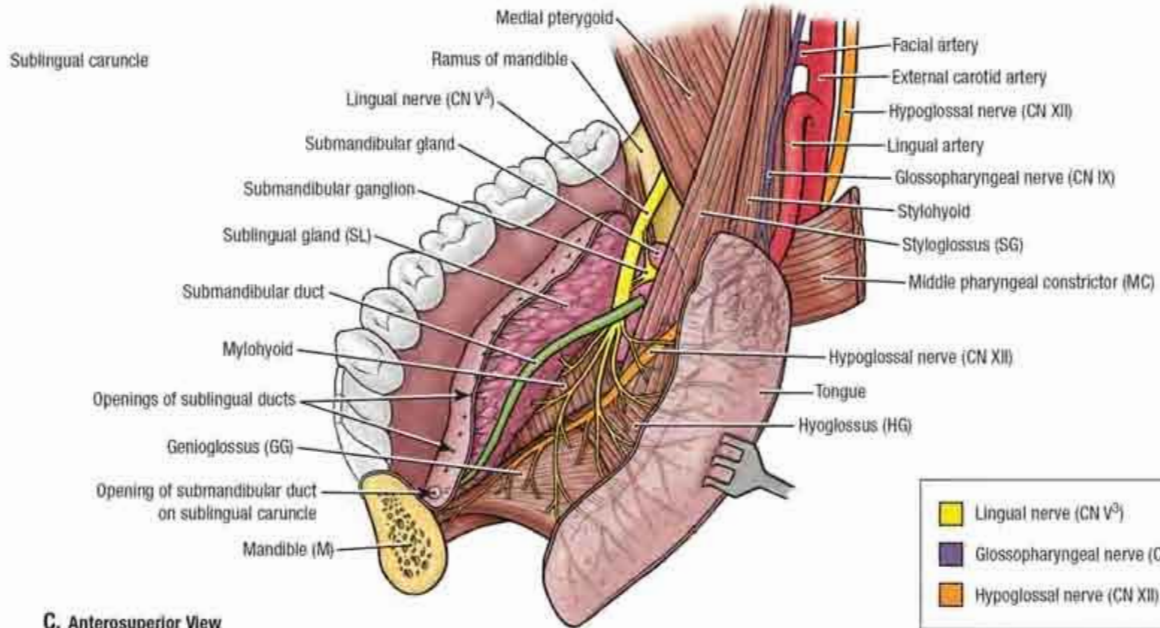
The parotid and submandibular salivary glands may be examined radiographically after the injection of a contrast medium into their ducts. This special type of radiograph (sialogram) demonstrates the salivary ducts and some secretory units. Because of the small size and number of sublingual ducts of the sublingual glands, one cannot usually inject contrast medium into them.



**A. Anterior View**



**B. Lateral View**



**C. Anterosuperior View**

Authors: Agur, Anne M.R.; Dalley, Arthur F.

Title: *Grant's Atlas of Anatomy, 12th Edition*

Copyright ©2009 Lippincott Williams & Wilkins

> Table of Contents > Chapter 7 - Head > 7.51 Muscles, glands, and vessels of floor of mouth and medial aspect of mandible

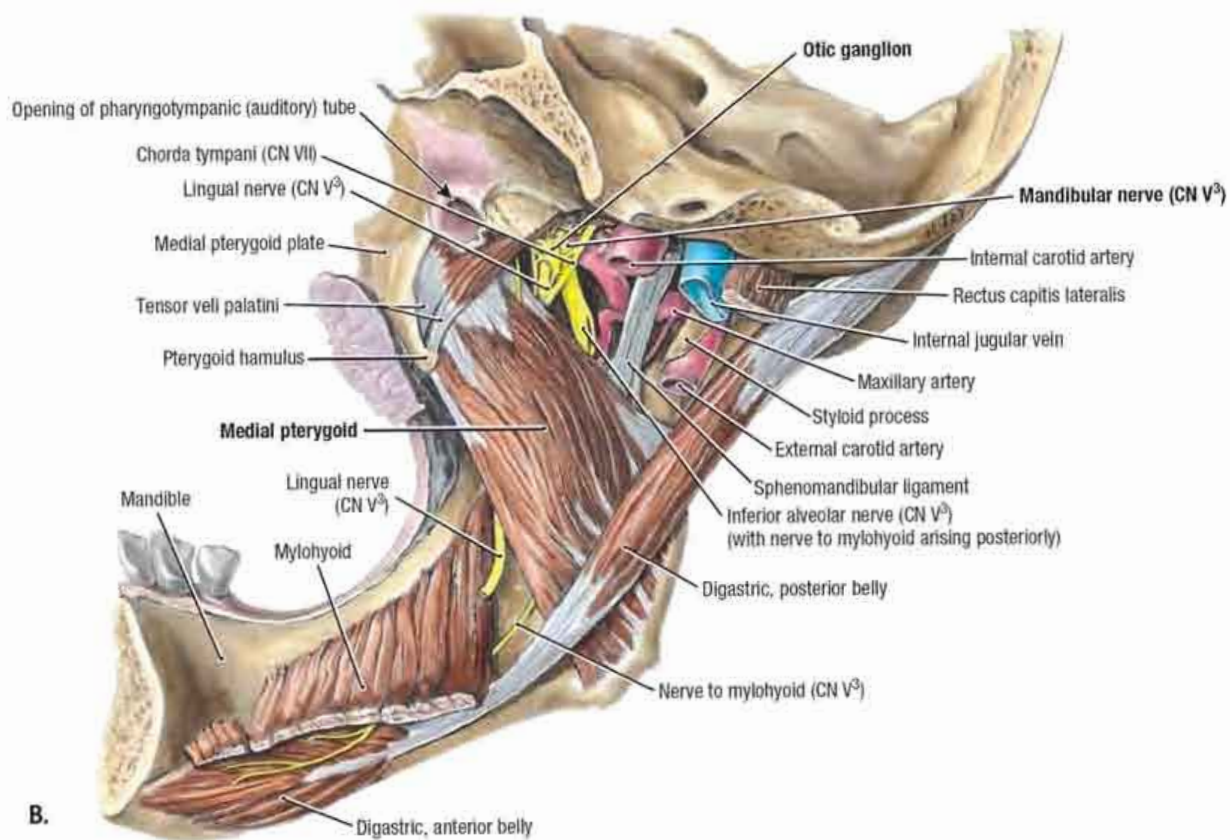
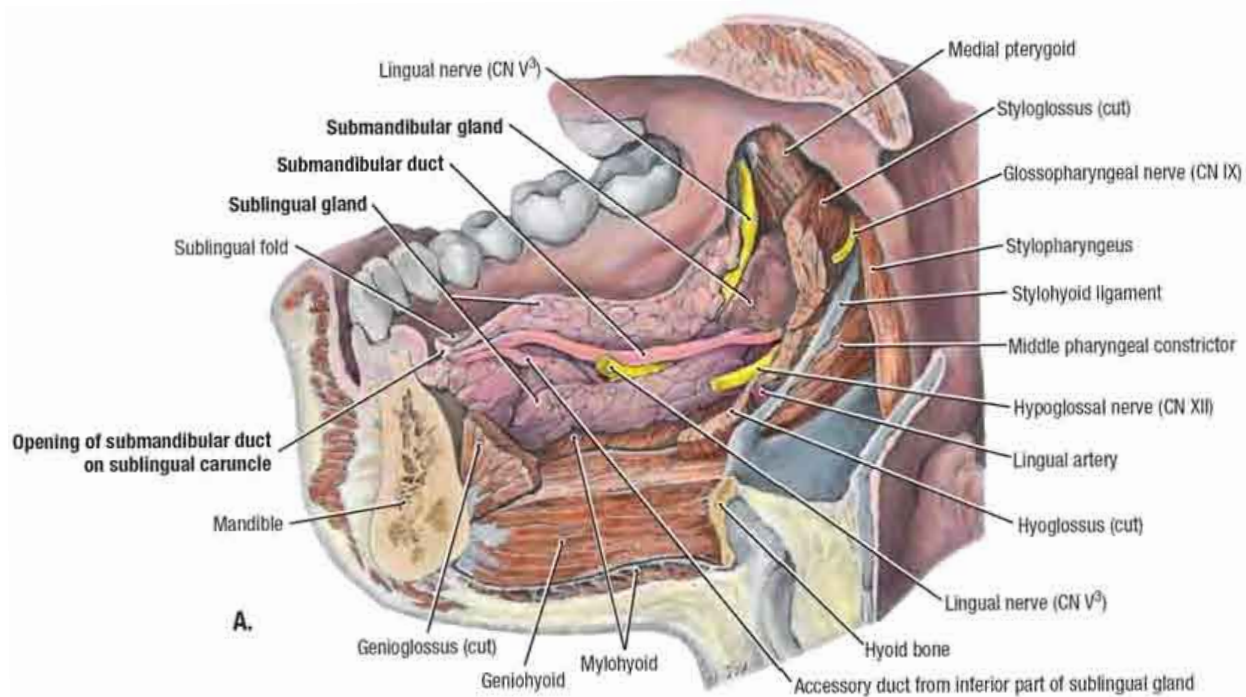
---

## 7.51 Muscles, glands, and vessels of floor of mouth and medial aspect of mandible

*Part of "Chapter 7 - Head "*

A. Sublingual and submandibular glands. The tongue has been excised. B. Structures related to the medial surface of the mandible. The otic ganglion lies medial to the mandibular nerve (CN V<sup>3</sup>) and between the foramen ovale superiorly and the medial pterygoid muscle inferiorly.





**Medial Views**

## 7.52 Palate

*Part of "Chapter 7 - Head "*

A. Bones of the hard palate. The palatine aponeurosis, which forms the fibrous "skeleton" of the soft palate, stretches between the hamuli of the medial pterygoid plates. B. Mucous membrane and glands of palate.

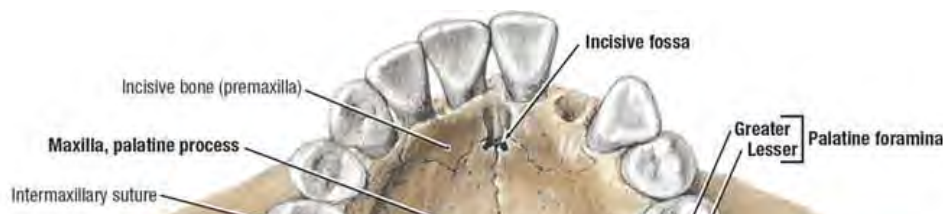---

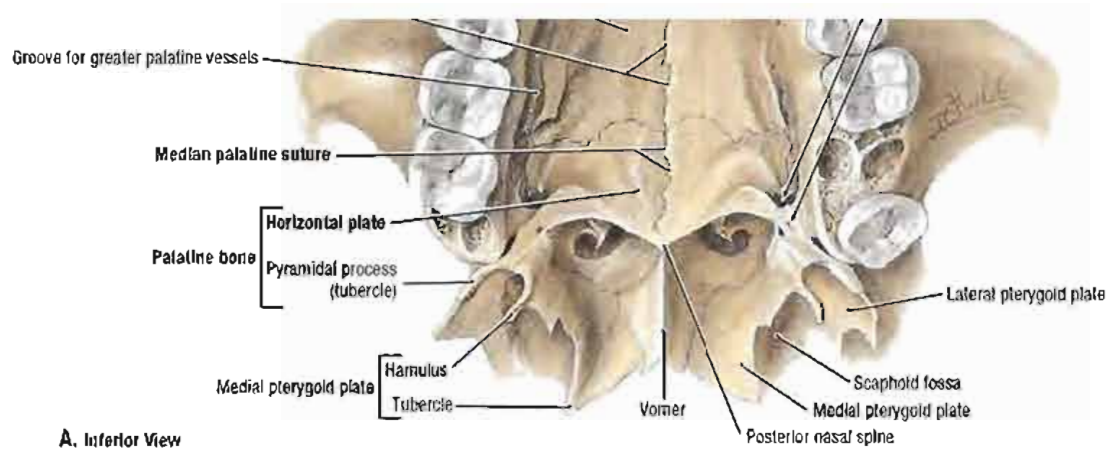
P.683

C. Nerves and vessels of palatine canal. The lateral wall of the nasal cavity is shown. The posterior ends of the middle and inferior conchae are excised along with the mucoperiosteum; the thin, perpendicular plate of the palatine bone is removed to expose the palatine nerves and arteries. D. Dissection of an edentulous palate. The greater palatine nerve supplies the gingivae and hard palate, the nasopalatine nerve the incisive region, and the lesser palatine nerves the soft palate. The nasopalatine nerves can be anesthetized by injecting anesthetic into the mouth of the incisive fossa in the hard palate. The anesthetized tissues are the palatal mucosa, the lingual gingivae, the six anterior maxillary teeth, and associated alveolar bone. The greater palatine nerve can be anesthetized by injecting anesthetic into the greater palatine foramen. The nerve emerges between the second and third maxillary molar teeth. This nerve block anesthetizes the palatal mucosa and lingual gingivae posterior to the maxillary canine teeth, and the underlying bone of the palate.

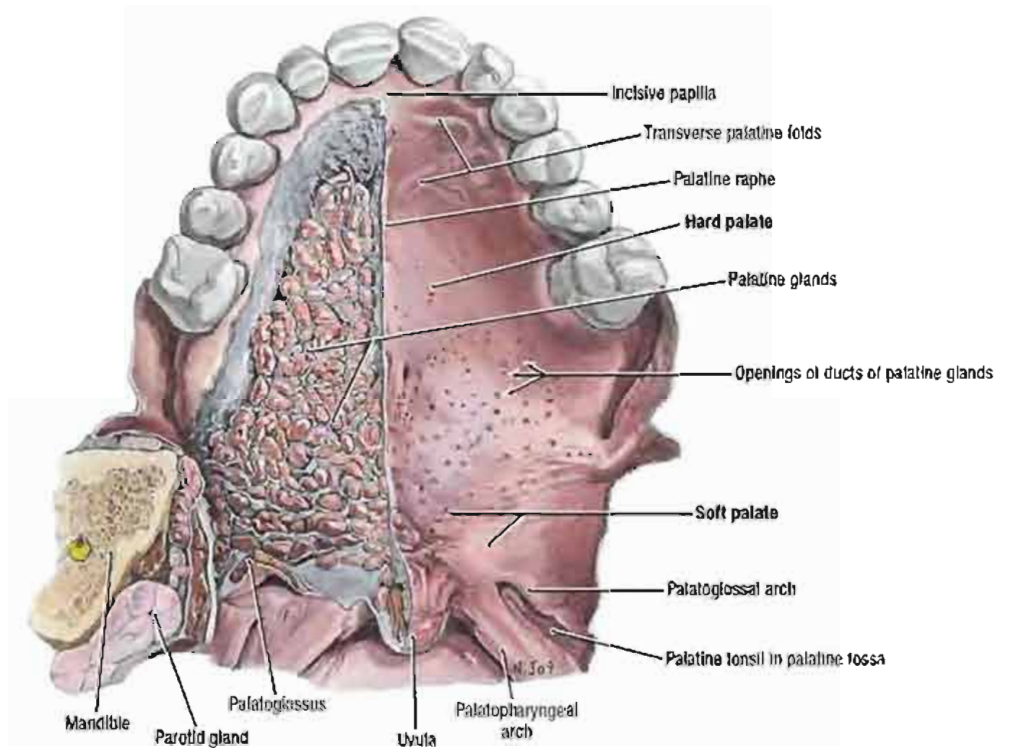
---

P.684

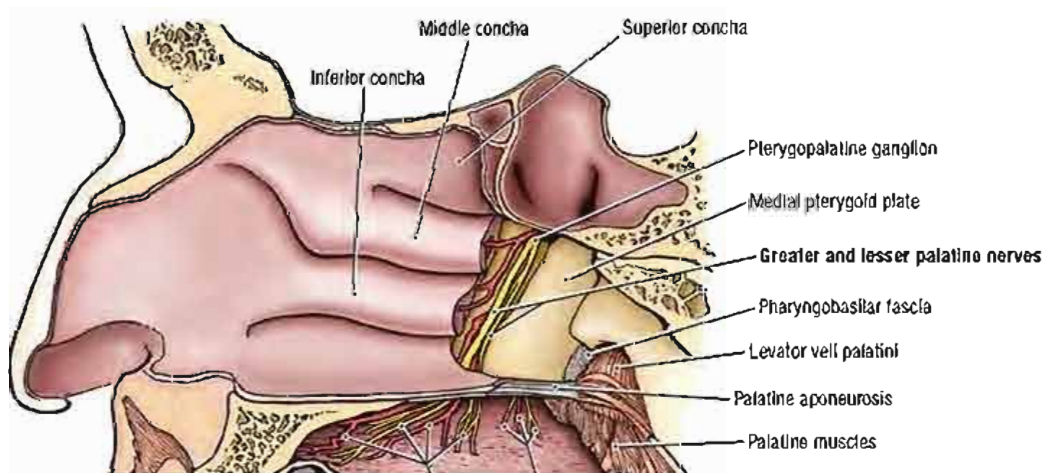




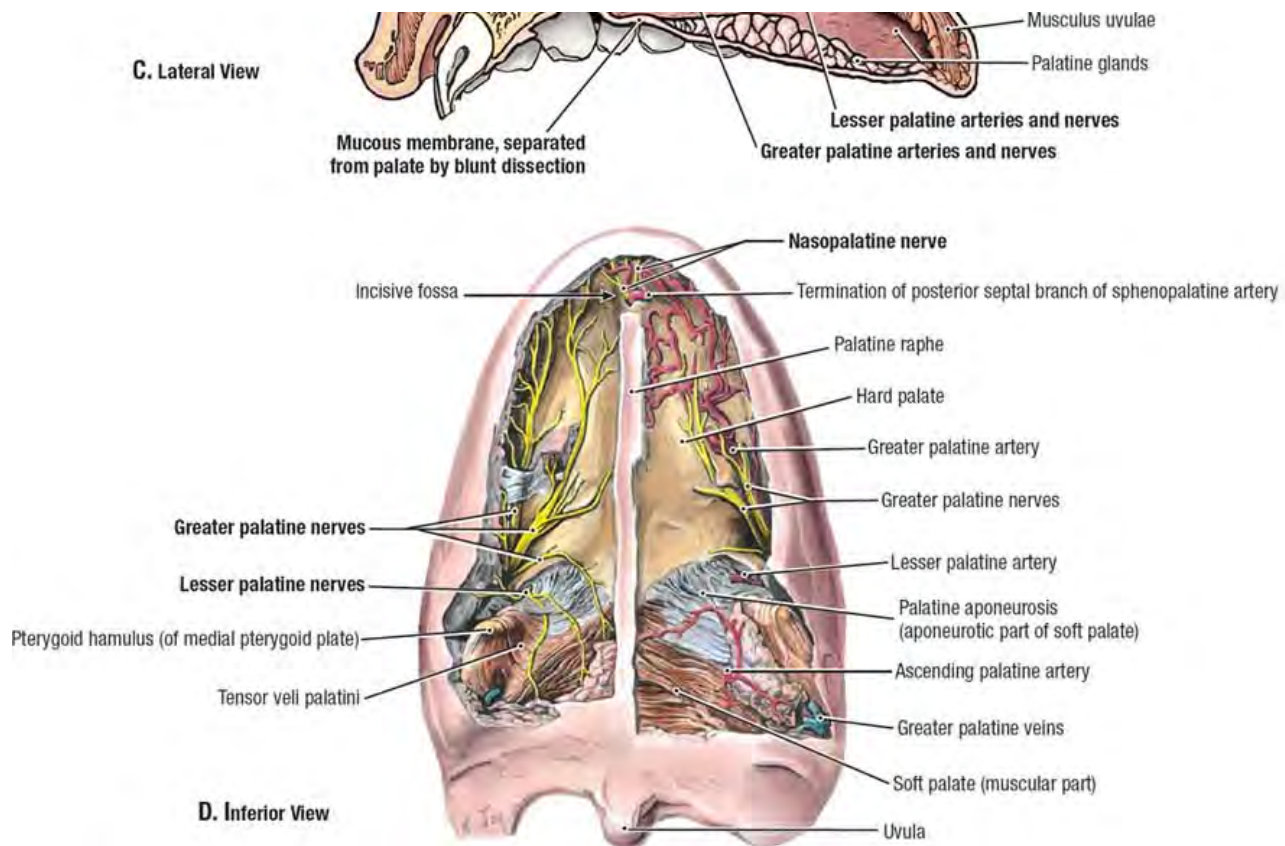
**A. Inferior View**



**B. Inferior View**







Levator veli palatini

Cartilage of pharyngotympanic tube and petrous part of temporal bone

Palatine aponeurosis

Pharyngeal branch of vagus nerve through pharyngeal plexus

Elevates soft palate during swallowing and yawning

Tensor veli palatini

Scaphoid fossa of medial pterygoid plate, spine of sphenoid bone, and cartilage of Medial pterygoid nerve (CN V<sup>3</sup>) through otic ganglion

Tenses soft palate and opens mouth of and yawning pharyngotympanic tube during swallowing and yawning

Palatoglossus

Palatine aponeurosis

Side of tongue

Pharyngeal branch of vagus nerve (CN X) via pharyngeal plexus

Elevates posterior part of tongue and draws soft palate onto tongue

Palatopharyngeus

Hard palate and palatine aponeurosis

Lateral wall of pharynx

Tenses soft palate and pulls walls of pharynx superiorly, anteriorly, and medially during swallowing

Musculus uvulae

Posterior nasal spine and palatine aponeurosis

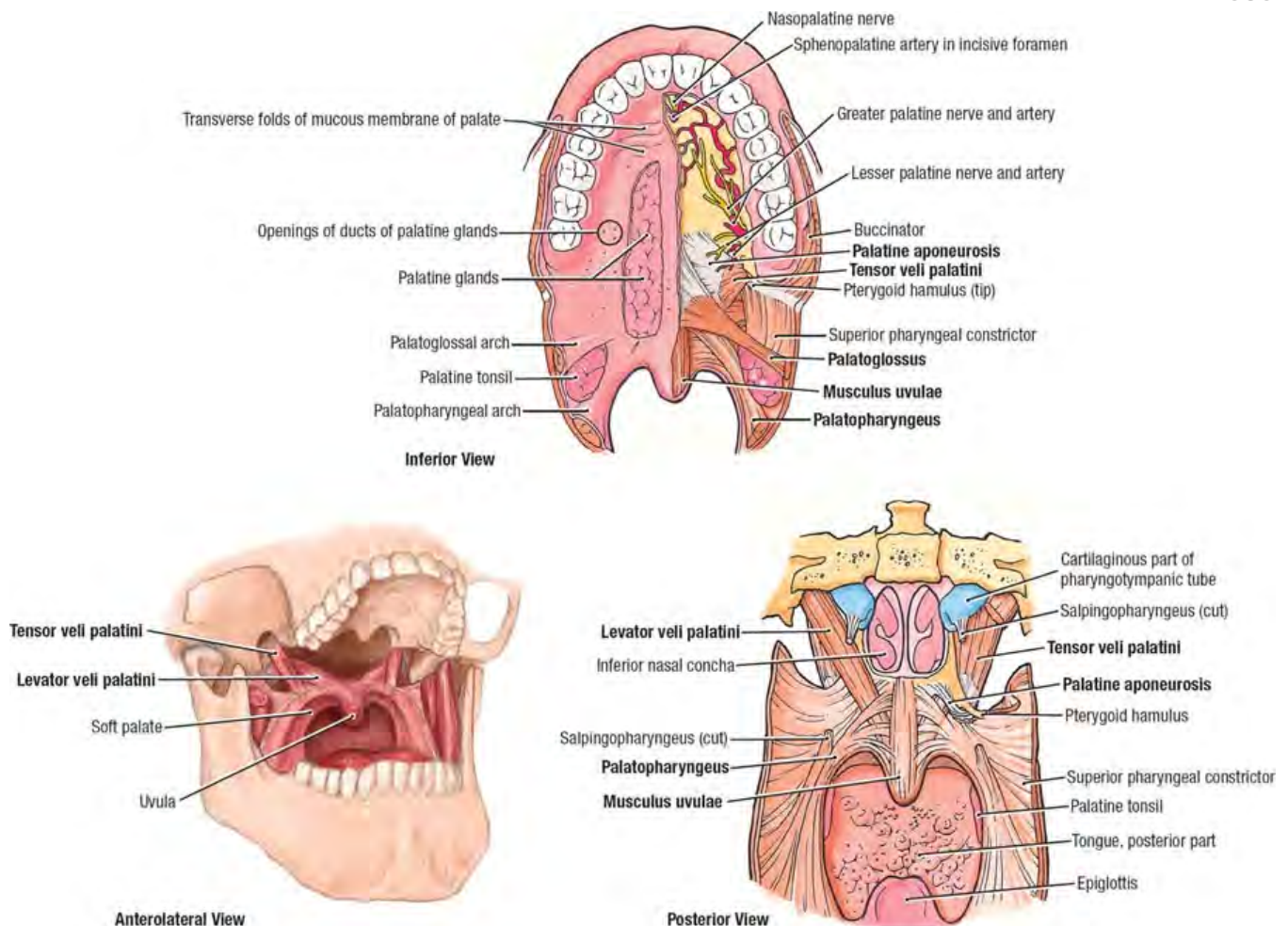
Mucosa of uvula

Shortens uvula and pulls it superiorly

Muscle	Superior Attachment	Inferior Attachment	Innervation	Main Action(s)
--------	---------------------	---------------------	-------------	----------------

Table 7.12 Table Muscles of Soft Palate

P.685





Authors: Agur, Anne M.R.; Dalley, Arthur F.

Title: *Grant's Atlas of Anatomy, 12th Edition*

Copyright ©2009 Lippincott Williams & Wilkins

> Table of Contents > Chapter 7 - Head > 7.53 Permanent teeth

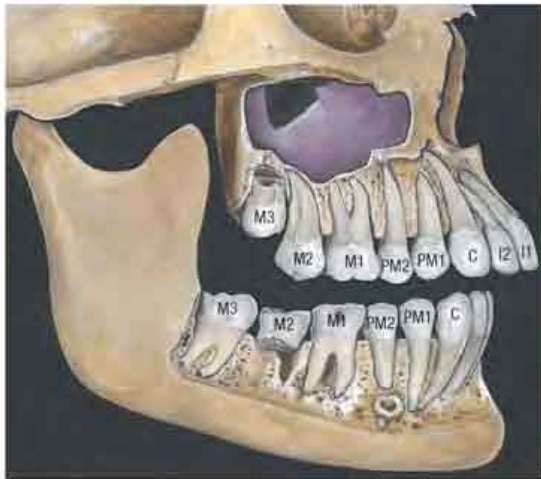---

## 7.53 Permanent teeth

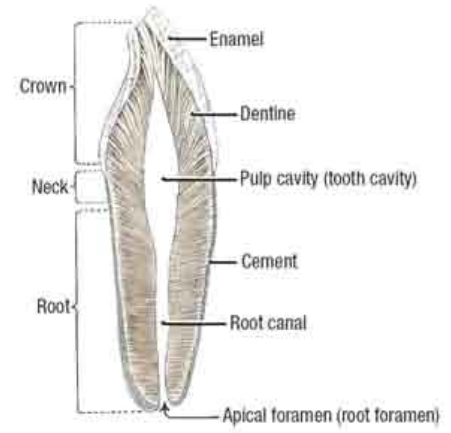
Part of "Chapter 7 - Head "

A. Teeth in situ with roots exposed. Incisors (*I1, I2*), canine (*C1*), premolars (*PM1, PM2*), and molars (*M1, M2, M3*). The roots of the 2nd lower molar have been removed. B. Lateral radiograph. (1)enamel, (2)dentin, (3)pulp chamber, (4)pulp canal, (5)buccal cusp, (6)alveolar bone, and (7)root apex. C. Longitudinal sections of an incisor and a molar tooth. D. Pantomographic radiograph of mandible and maxilla. The left lower third molar is not present.

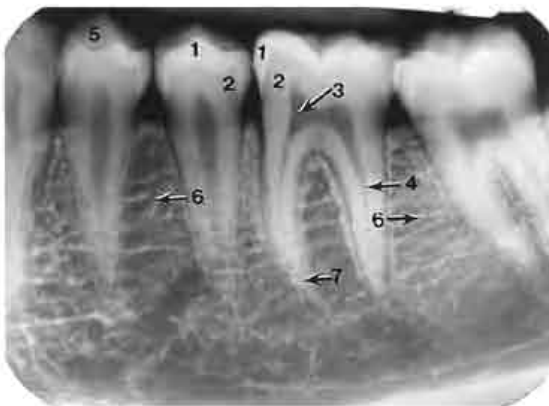Decay of the hard tissues of a tooth results in the formation of dental caries (cavities). Invasion of the pulp of the tooth by a carious lesion (cavity) results in infection and irritation of the tissues in the pulp cavity. This condition causes an inflammatory process (pulpitis). Because the pulp cavity is a rigid space, the swollen pulpal tissues cause pain (toothache).



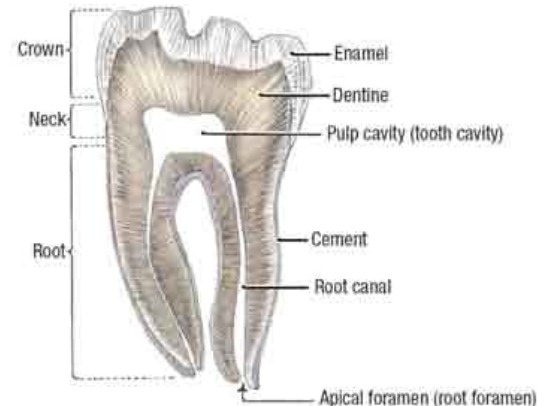
**A. Lateral View**



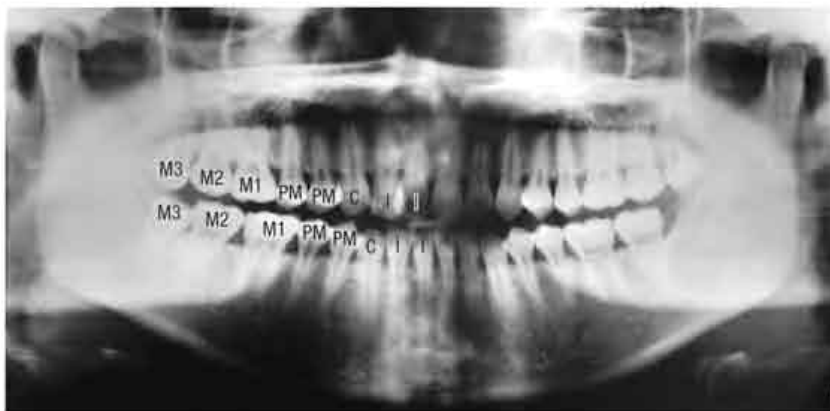**Incisor Tooth, Longitudinal Section**



**B. Lateral Radiograph**



**C. Molar Tooth, Longitudinal Section**



**D. Pantomographic Radiograph**

Authors: Agur, Anne M.R.; Dalley, Arthur F.

Title: *Grant's Atlas of Anatomy, 12th Edition*

Copyright ©2009 Lippincott Williams & Wilkins

> Table of Contents > Chapter 7 - Head > 7.54 Permanent teeth

---

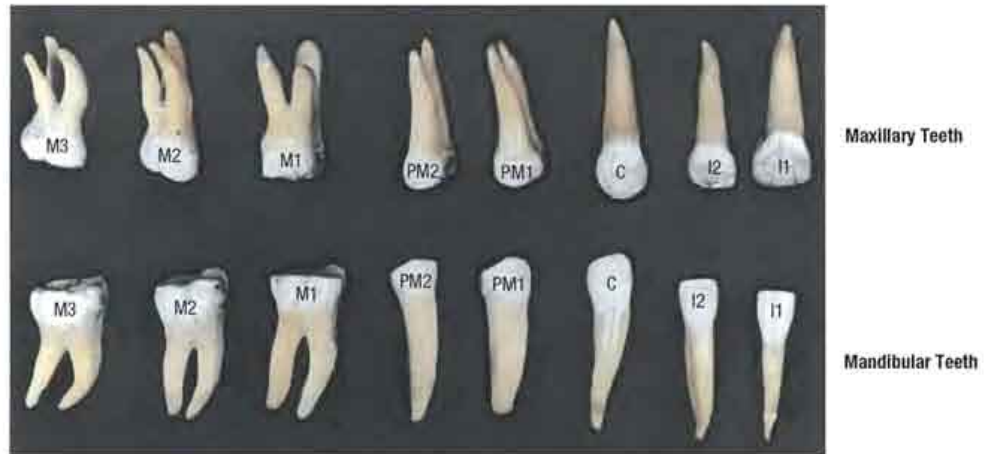## 7.54 Permanent teeth

*Part of "Chapter 7 - Head"*

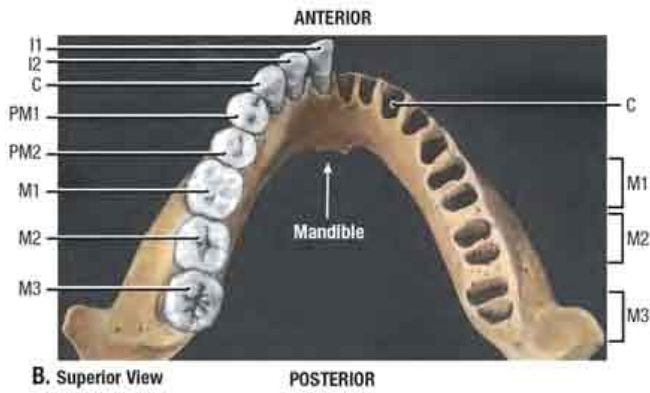
A. Removed teeth, displaying roots. There are 32 permanent teeth; 8 are on each side of each dental arch on the top (maxillary teeth) and bottom (mandibular teeth): 2 incisors (*I1*), 1 canine (*C*), 2 premolars (*PM1*), and 3 molars (*M1*). B. Permanent mandibular teeth and their sockets. C. Permanent maxillary teeth and their sockets. D. Teeth in occlusion. E. Vestibule and gingivae of the maxilla

---

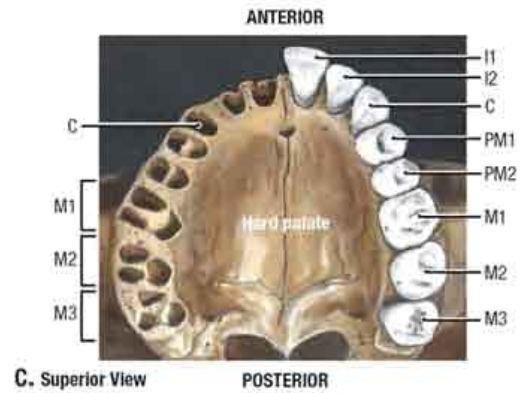
P.687



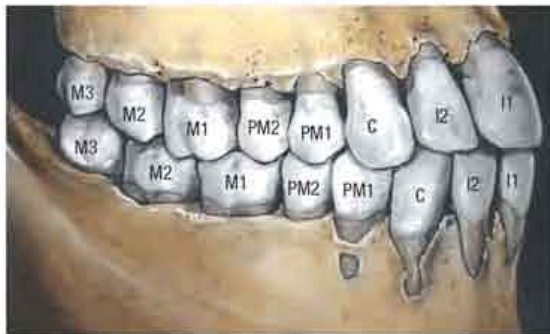
A. Vestibular View



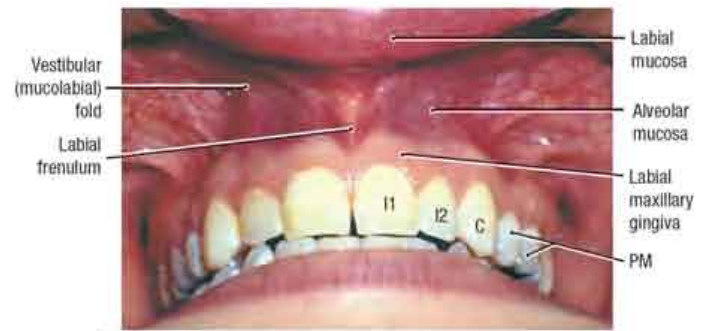
B. Superior View



C. Superior View



D. Anterolateral View



E. Anterior View

Authors: Agur, Anne M.R.; Dalley, Arthur F.

Title: *Grant's Atlas of Anatomy, 12th Edition*

Copyright ©2009 Lippincott Williams & Wilkins

> Table of Contents > Chapter 7 - Head > 7.55 Innervation of teeth

---

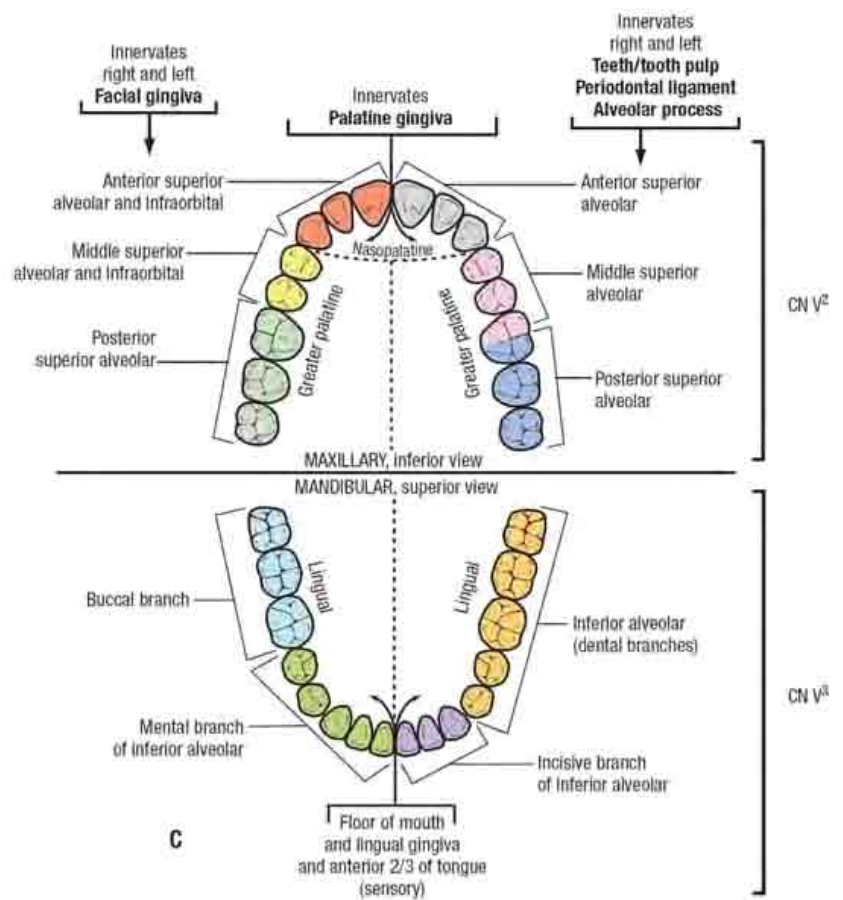
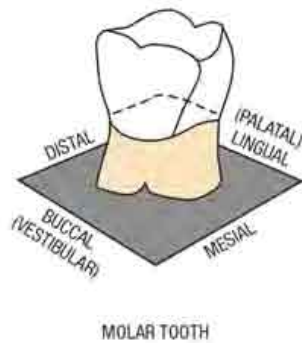
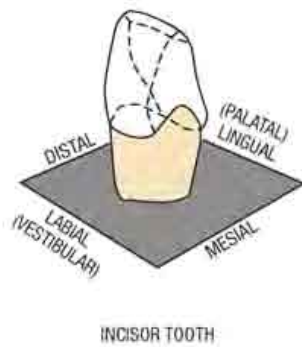
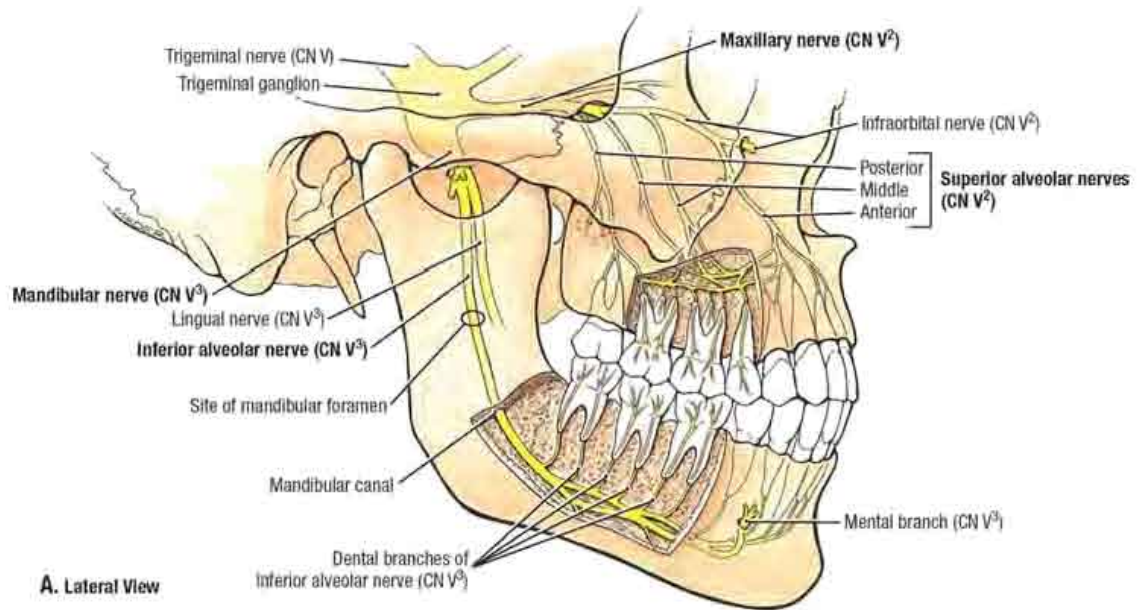
## 7.55 Innervation of teeth

*Part of "Chapter 7 - Head "*

A. Superior and inferior alveolar nerves. B. Surfaces of an incisor and molar tooth. C. Innervation of the mouth and teeth.

Improper oral hygiene results in food deposits in tooth and gingival crevices, which may cause inflammation of the gingivae (gingivitis). If untreated, the disease spreads to other supporting structures (including the alveolar bone), producing periodontitis. Periodontitis results in inflammation of the gingivae and may result in absorption of alveolar bone and gingival recession. Gingival recession exposes the sensitive cement of the teeth.





## 7.56 Primary teeth

*Part of* "Chapter 7 - Head "

A. Removed teeth. There are 20 primary (deciduous) teeth, 5 in each half of the mandible and 5 in each maxilla. They are named central incisor, lateral incisor, canine, 1st molar (*M1*), and 2nd molar (*M2*). Primary teeth differ from permanent teeth in that the primary teeth are smaller and whiter; the molars also have more bulbous crowns and more divergent roots. B. Teeth in situ, younger than 2 years of age. Permanent teeth are colored orange; the crowns of the unerupted 1st and 2nd permanent molars are partly visible.

---

P.689

Eruption(months)<sup>a</sup>

6-8

8-10

16-20

12-16

20-24

Shedding (years)

6-7

7-8

10-12

9-11

10-12

<sup>a</sup>In some normal infants, the first teeth (medial incisors) may not erupt until 12 to 13 months of age

Deciduous  
Teeth

Medial  
Incisor

Lateral  
Incisor

Canine

First  
Molar

Second  
Molar

Table 7.13 Primary and Secondary Dentition

MAXILLARY TEETH

MANDIBULAR TEETH

A. Vestibular View

2nd molar

1st molar

Canine

Lateral incisor

Central incisor

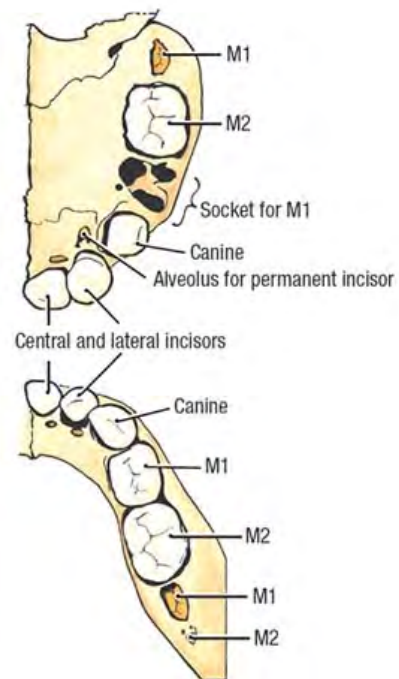
INFERIOR VIEW OF MAXILLARY TEETH

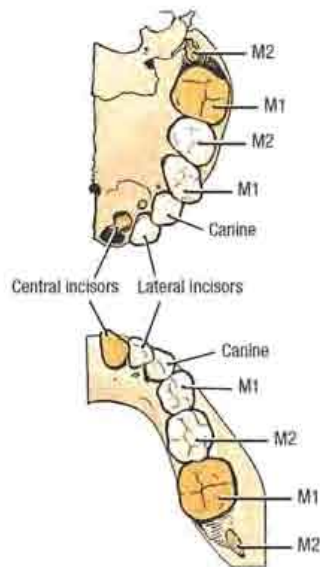
Hard palate

SUPERIOR VIEW OF MANDIBULAR TEETH

Mandible

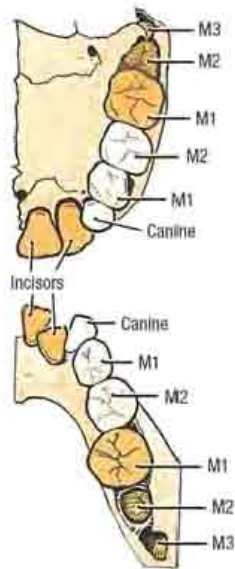
B





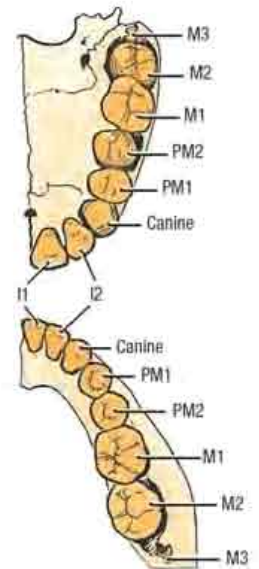
#### Age: 6-7 years

The 1st molars (6-year molars) have fully erupted, the primary central incisor has been shed, the lower central incisor is almost fully erupted, and the upper central incisor is descending into the vacated socket.



#### Age: 8 years

All of the permanent incisors have erupted; however, the lower lateral incisor is only partially erupted.



#### Age: 12 years

The primary teeth have been replaced by 20 permanent teeth, and the 1st and 2nd molars (12-year molars) have erupted; the canines, 2nd premolars, and 2nd molars (especially those in the upper jaw) have not erupted fully, nor have their bony sockets closed around them. By age 12, 28 permanent teeth are in evidence; the last 4 teeth, the 3rd molars, may erupt any time after this, or never.

Permanent Teeth	Medial Incisor	Lateral Incisor	Canine	First Premolar	Second Premolar	First Molar	Second Molar	Third Molar
Eruption (years)	7-8	8-9	10-12	10-11	11-12	6-7	12	13-25



Authors: Agur, Anne M.R.; Dalley, Arthur F.

Title: *Grant's Atlas of Anatomy, 12th Edition*

Copyright ©2009 Lippincott Williams & Wilkins

> Table of Contents > Chapter 7 - Head > 7.57 Surface anatomy, cartilages, and bones of nose

---

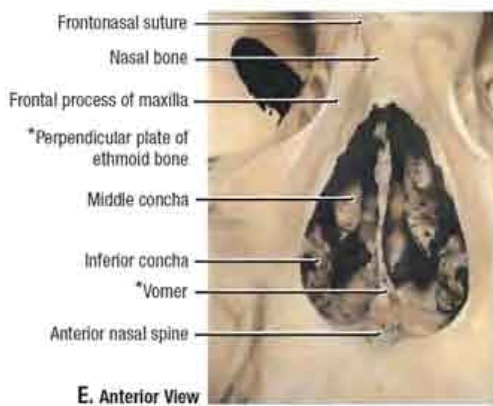
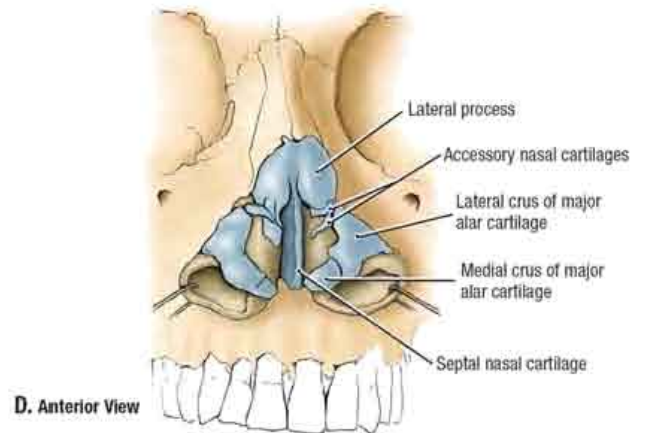
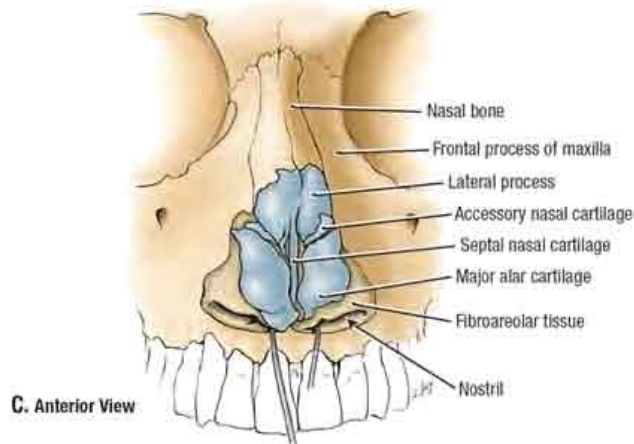
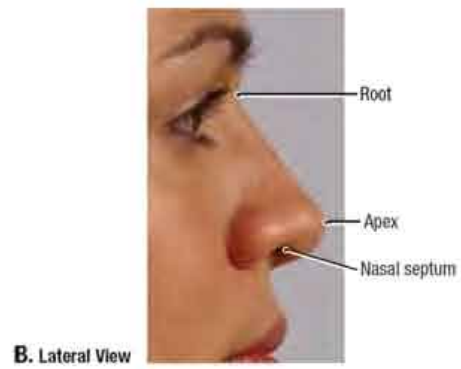
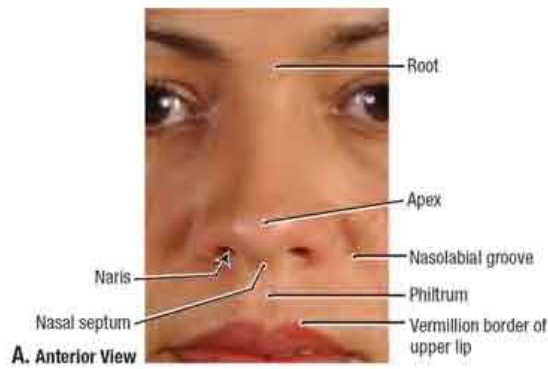
## 7.57 Surface anatomy, cartilages, and bones of nose

*Part of* "Chapter 7 - Head "

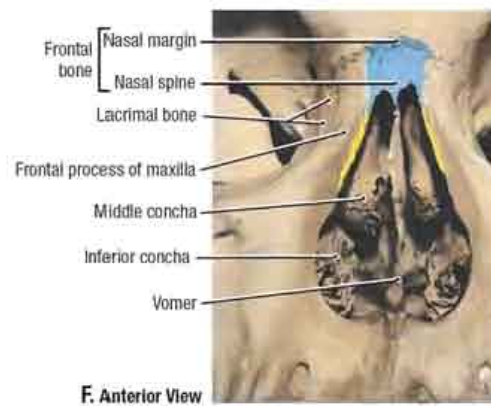
A. Surface features of anterior aspect of nose. B. Surface features of lateral aspect of nose. C. Nasal cartilages, with the septum pulled inferiorly. D. Nasal cartilages, separated and retracted laterally. E. Lower conchae and bony septum seen through the piriform aperture. The margin of the piriform aperture is sharp and formed by the maxillae and nasal bones. F. Nasal bones removed. The areas of the frontal processes of the maxillae (*yellow*) and of the frontal bone (*blue*) that articulate with the nasal bones can be seen.

---

P.691



\*Bony nasal septum



Authors: Agur, Anne M.R.; Dalley, Arthur F.

Title: *Grant's Atlas of Anatomy, 12th Edition*

Copyright ©2009 Lippincott Williams & Wilkins

> Table of Contents > Chapter 7 - Head > 7.58 Bones of the lateral wall and septum of the nose

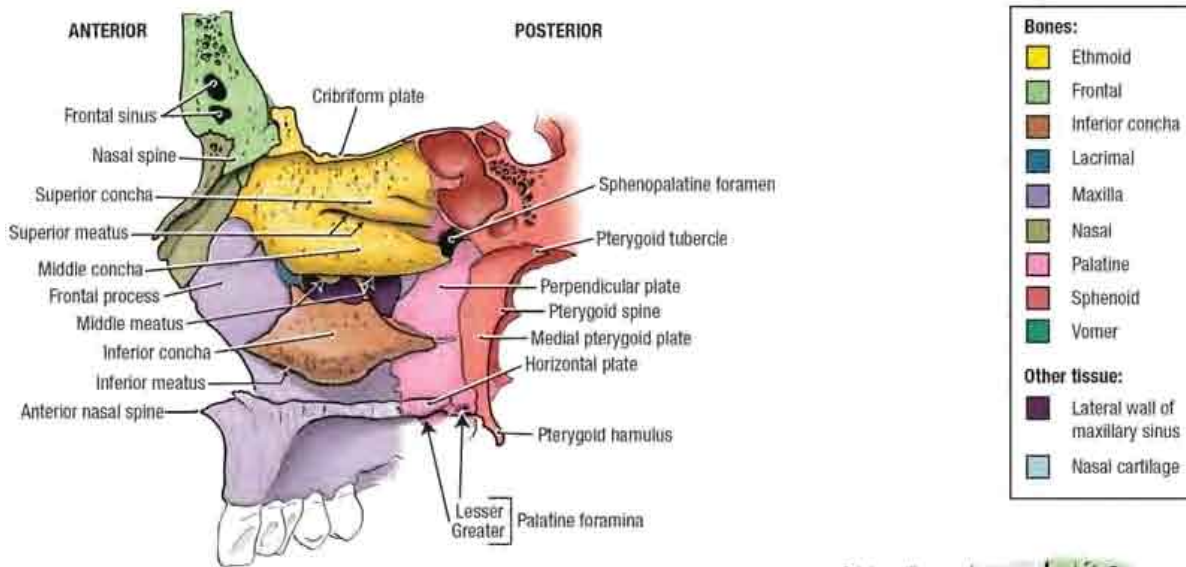
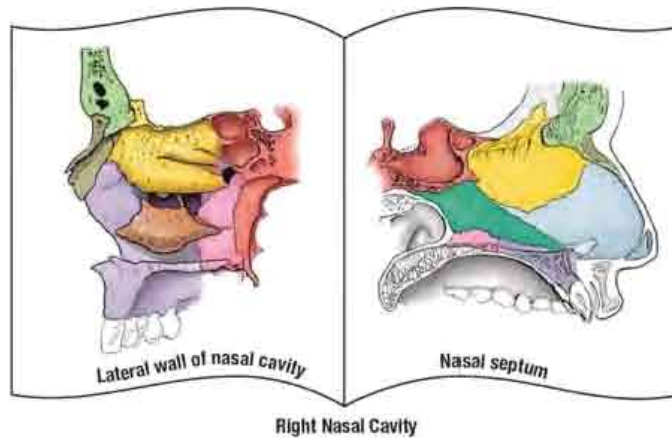
---

## 7.58 Bones of the lateral wall and septum of the nose

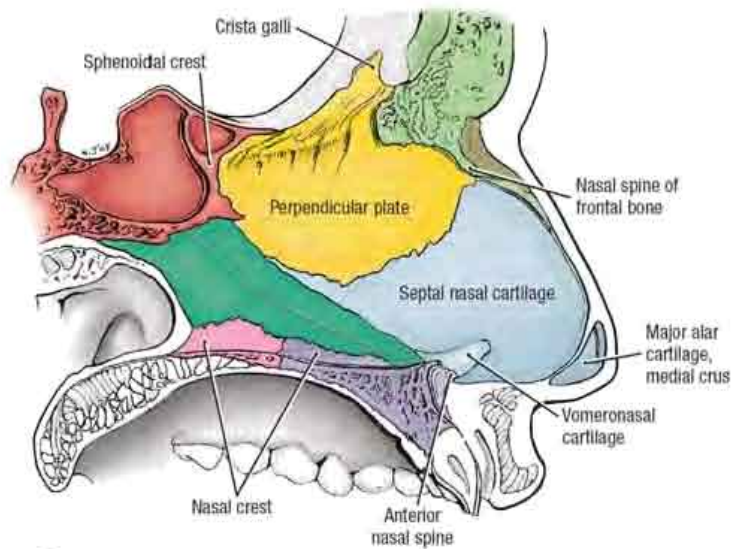
*Part of "Chapter 7 - Head "*

A. Lateral wall of nose. The superior and middle conchae are parts of the ethmoid bone, whereas the inferior concha is itself a bone. B. Nasal septum.

Deformity of the external nose usually is present with a fracture, particularly when a lateral force is applied by someone's elbow, for example. When the injury results from a direct blow (e.g., from a hockey stick), the cribriform plate of the ethmoid bone may fracture, resulting in CSF rhinorrhea.



A. Medial View of Lateral Wall



B. Lateral View of Nasal Septum

Authors: Agur, Anne M.R.; Dalley, Arthur F.

Title: *Grant's Atlas of Anatomy, 12th Edition*

Copyright ©2009 Lippincott Williams & Wilkins

> Table of Contents > Chapter 7 - Head > 7.59 Innervation of lateral wall and septum of the nose

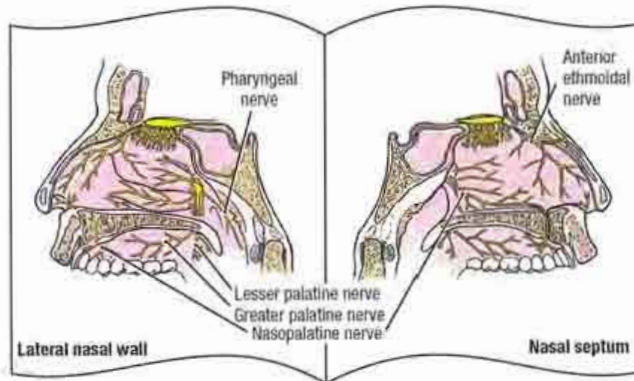
---

## 7.59 Innervation of lateral wall and septum of the nose

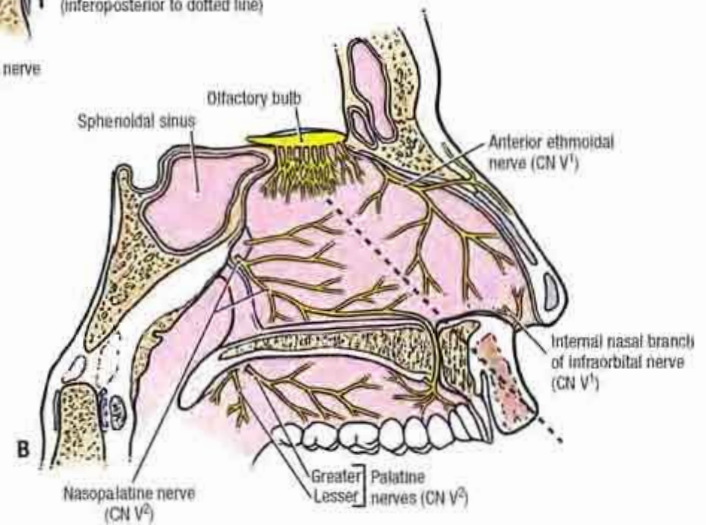
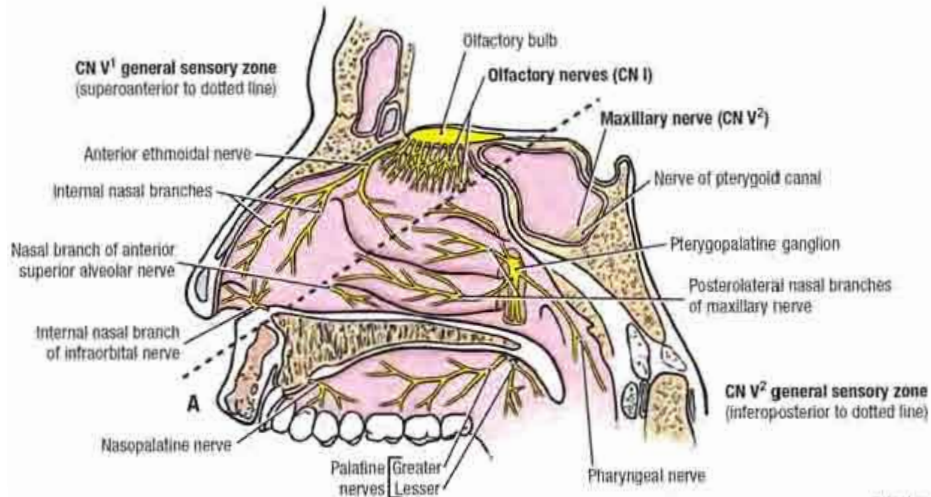
*Part of* "Chapter 7 - Head "

A. Lateral wall of nose. *Dotted diagonal lines* demarcate CN V<sup>1</sup> and CN V<sup>2</sup> general sensory zones. The olfactory neuroepithelium is in the superior part of the lateral and septal walls of the nasal cavity. The central processes of the olfactory neurosensory cells of each side form approximately 20 bundles that together form an olfactory nerve (CN I). B. Nasal septum. The nasopalatine nerve from the pterygopalatine ganglion supplies the posteroinferior septum, and the anterior ethmoidal nerve (branch of V<sup>1</sup>) supplies the anterosuperior septum.





Right Nasal Cavity



Authors: Agur, Anne M.R.; Dalley, Arthur F.

Title: *Grant's Atlas of Anatomy, 12th Edition*

Copyright ©2009 Lippincott Williams & Wilkins

> Table of Contents > Chapter 7 - Head > 7.60 Arteries of lateral wall and septum of the nose

---

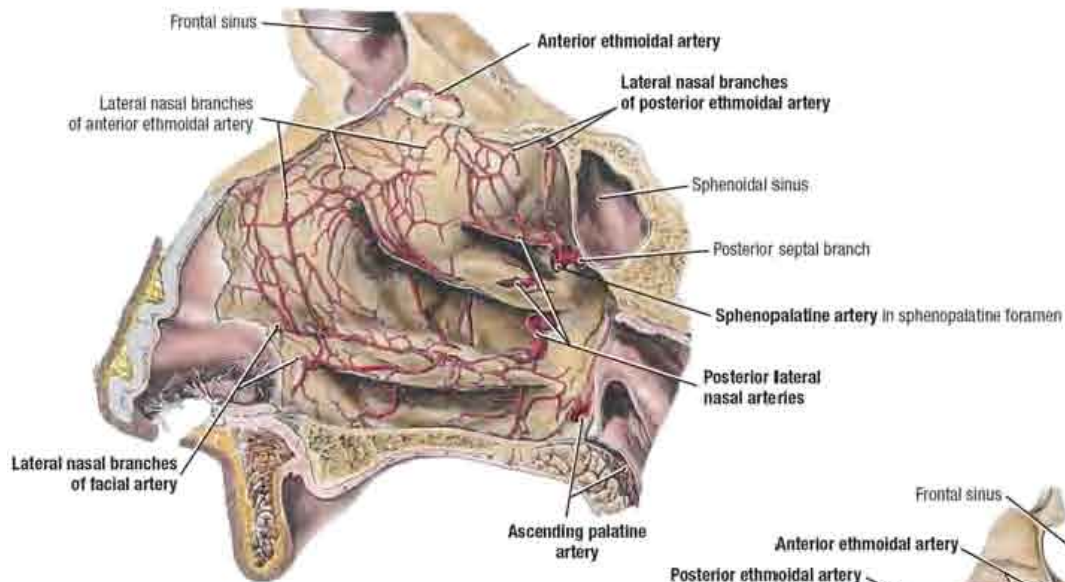
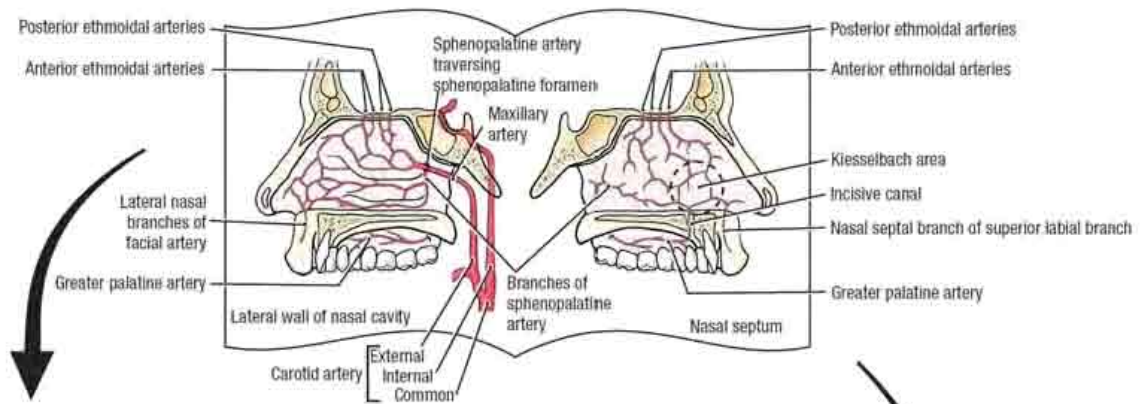
## 7.60 Arteries of lateral wall and septum of the nose

*Part of* "Chapter 7 - Head "

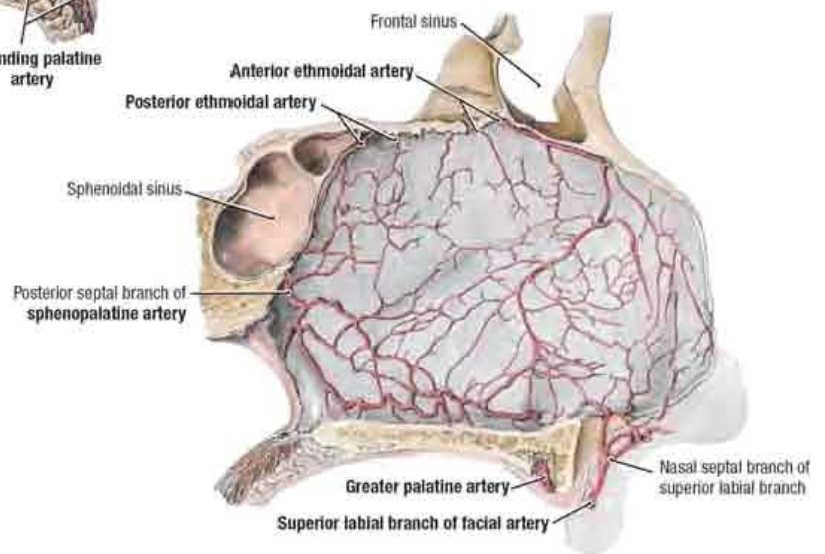
A. Lateral wall of nose. B. Nasal septum. On the anterior part of the nasal septum is an area rich in capillaries (Kiesselbach area) where all five arteries (sphenopalatine, anterior and posterior ethmoidal, greater palatine and superior labial and lateral nasal branches of the facial artery) supplying the nasal septum anastomose. This area is often where profuse bleeding from the nose (epistaxis) occurs.

---

P.694



**A. Medial View of Lateral Wall**



**B. Lateral View of Nasal Septum**

Authors: Agur, Anne M.R.; Dalley, Arthur F.

Title: *Grant's Atlas of Anatomy, 12th Edition*

Copyright ©2009 Lippincott Williams & Wilkins

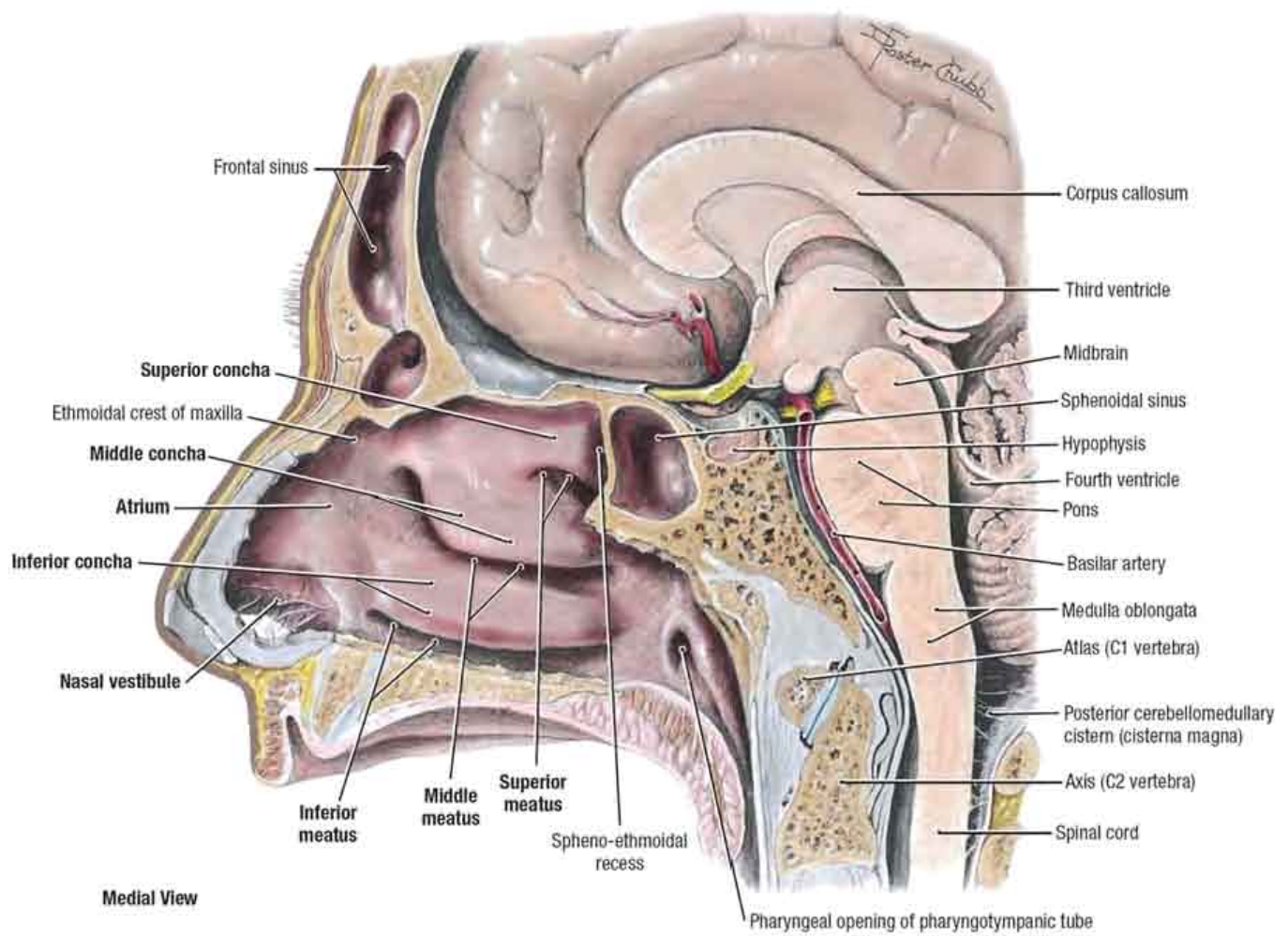
> Table of Contents > Chapter 7 - Head > 7.61 Right half of hemisected head demonstrating upper respiratory tract

---

## 7.61 Right half of hemisected head demonstrating upper respiratory tract

*Part of "Chapter 7 - Head "*

- The vestibule is superior to the nostril and anterior to the inferior meatus; hairs grow from its skin-lined surface. The atrium is superior to the vestibule and anterior to the middle meatus.
- The inferior and middle conchae curve inferiorly and medially from the lateral wall, dividing it into three nearly equal parts and covering the inferior and middle meatuses, respectively. The middle concha ends inferior to the sphenoidal sinus, and the inferior concha ends inferior to the middle concha, just anterior to the orifice of the auditory tube. The superior concha is small and anterior to the sphenoidal sinus.
- The roof comprises an anterior sloping part corresponding to the bridge of the nose; an intermediate horizontal part; a perpendicular part anterior to the sphenoidal sinus; and a curved part, inferior to the sinus, that is continuous with the roof of the nasopharynx.





**Authors:** Agur, Anne M.R.; Dalley, Arthur F.

**Title:** *Grant's Atlas of Anatomy, 12th Edition*

Copyright ©2009 Lippincott Williams & Wilkins

> Table of Contents > Chapter 7 - Head > 7.62 Communications through the lateral wall of the nasal cavity

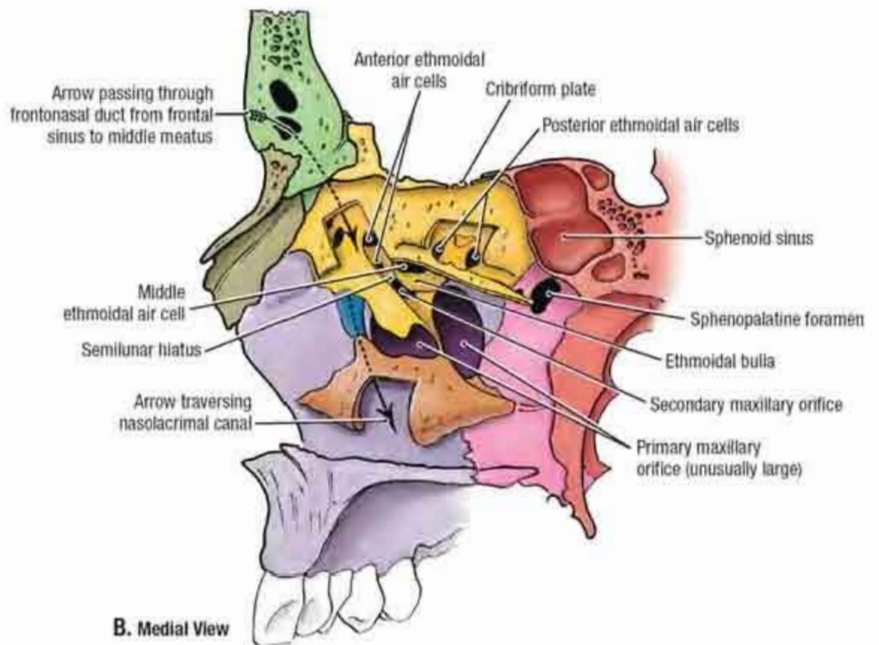
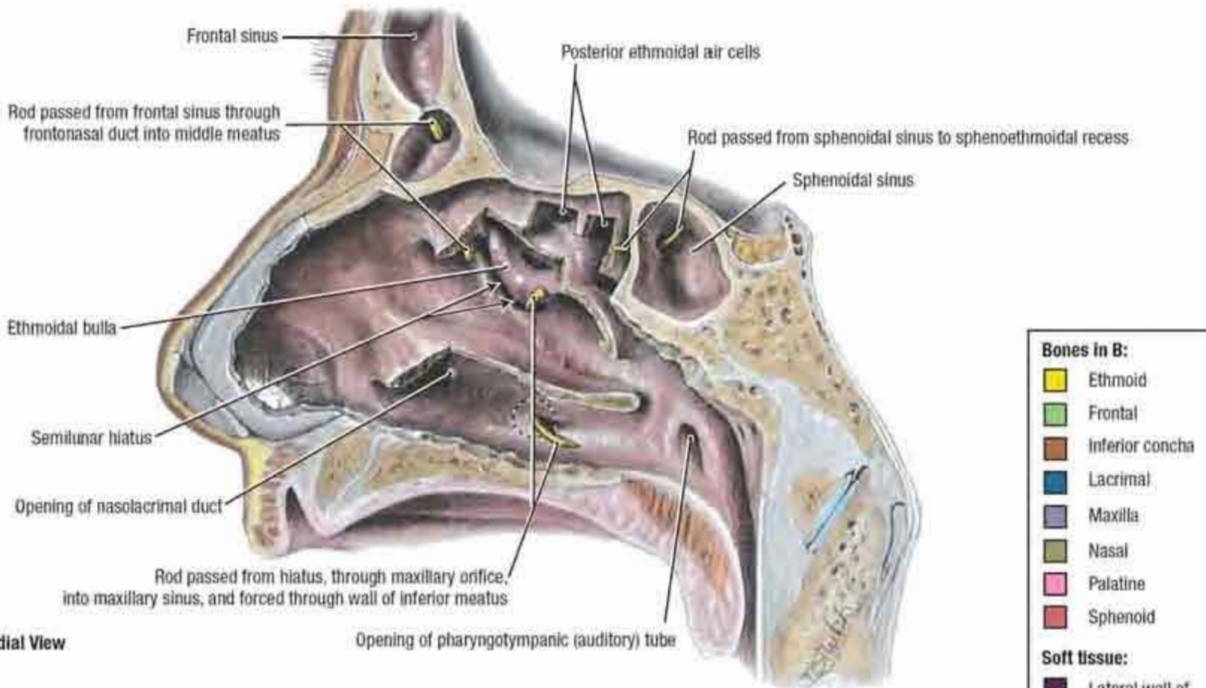
---

## 7.62 Communications through the lateral wall of the nasal cavity

*Part of "Chapter 7 - Head "*

A. Dissection. Parts of the superior, middle, and inferior conchae are cut away to reveal the openings of the air sinuses. B. Diagrams of the bones and openings of the lateral wall of nasal cavity following dissection. Note one *arrow* passing from the frontal sinus through the frontonasal duct into the middle meatus and another *arrow* coming from the anteromedial orbit via the nasolacrimal canal.

The nasal mucosa becomes swollen and inflamed (rhinitis) during upper respiratory infections and allergic reactions (e.g., hay fever). Swelling of this mucous membrane occurs readily because of its vascularity and abundant mucosal glands. Infections of the nasal cavities may spread to the anterior cranial fossa through the cribriform plate, nasopharynx and retropharyngeal soft tissues, middle ear through the pharyngotympanic (auditory) tube, paranasal sinuses, lacrimal apparatus, and conjunctiva.



Authors: Agur, Anne M.R.; Dalley, Arthur F.

Title: *Grant's Atlas of Anatomy, 12th Edition*

Copyright ©2009 Lippincott Williams & Wilkins

> Table of Contents > Chapter 7 - Head > 7.63 Paranasal sinuses, openings, and palatine muscles in the lateral wall of the nasal cavity

---

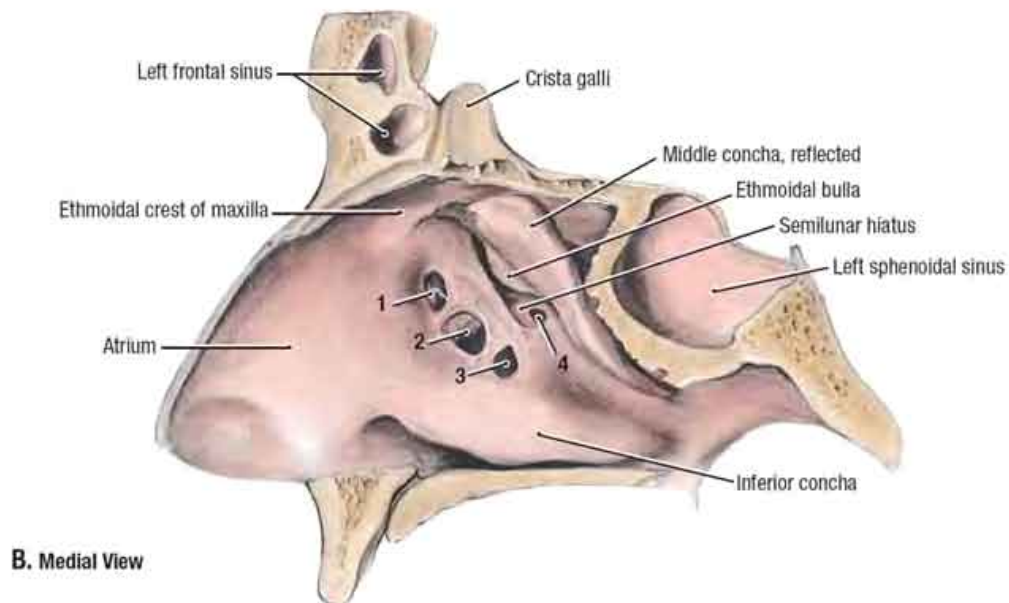
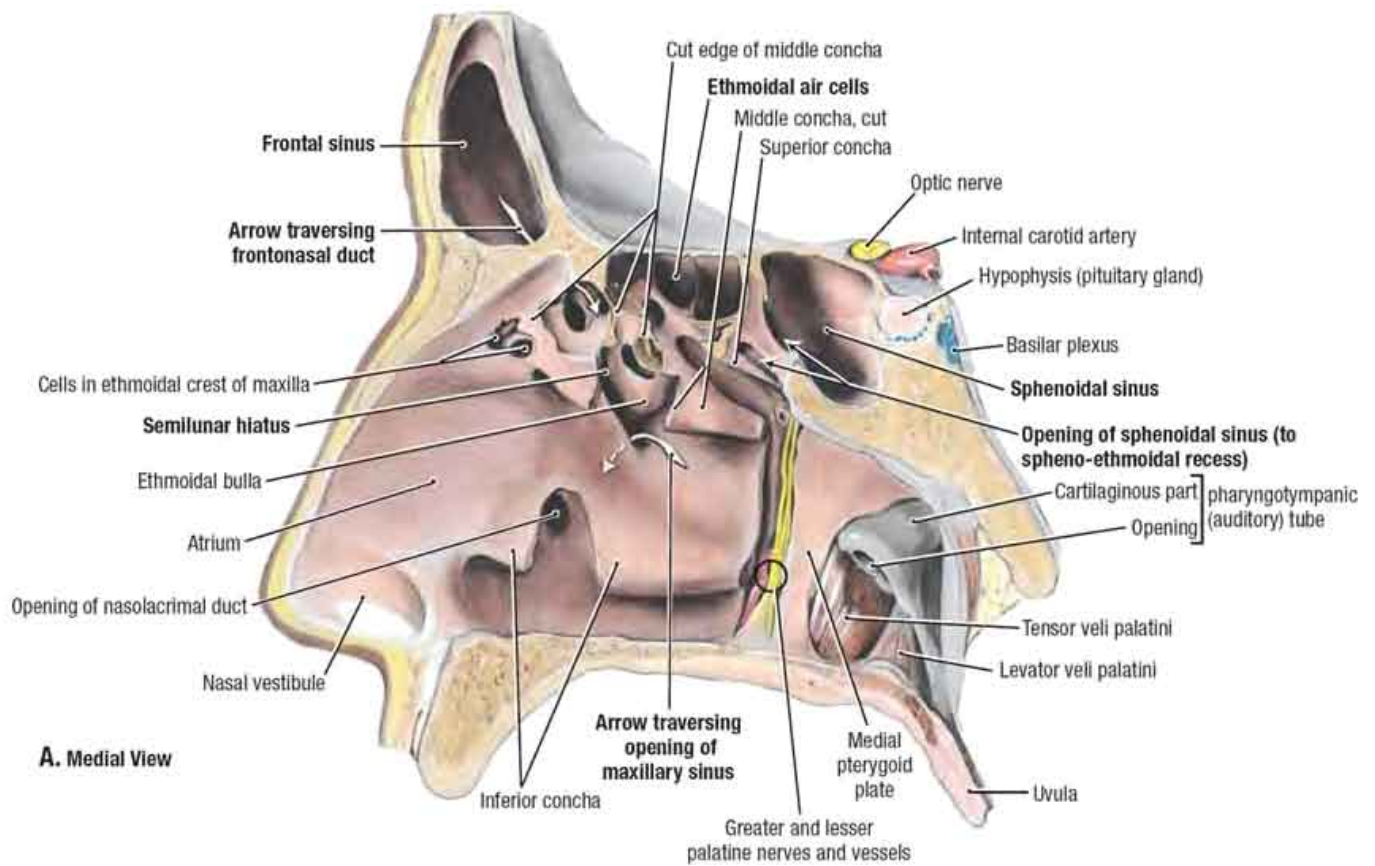
## 7.63 Paranasal sinuses, openings, and palatine muscles in the lateral wall of the nasal cavity

*Part of* "Chapter 7 - Head "

A. Dissection. Parts of the middle and inferior conchae and lateral wall of the nasal cavity are cut away to expose the nerves and vessels in the palatine canal and the extrinsic palatine muscles. B. Accessory maxillary orifices. In addition to the primary, or normal, ostium (not shown), there are four secondary, or acquired, ostia (numbered 1–4).

---

P.697



Authors: Agur, Anne M.R.; Dalley, Arthur F.

Title: *Grant's Atlas of Anatomy, 12th Edition*

Copyright ©2009 Lippincott Williams & Wilkins

> Table of Contents > Chapter 7 - Head > 7.64 Paranasal sinuses and nasal cavity

---

## 7.64 Paranasal sinuses and nasal cavity

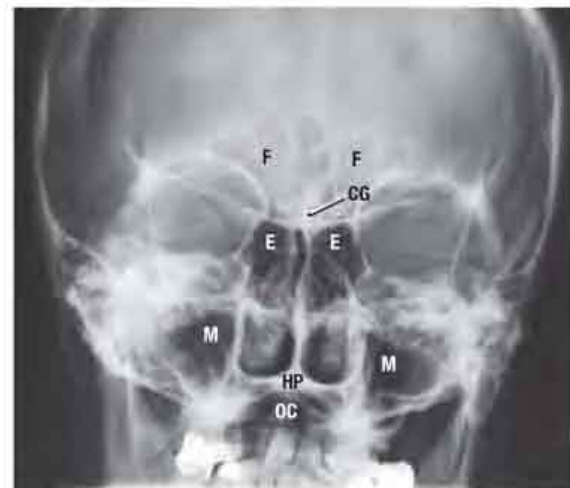
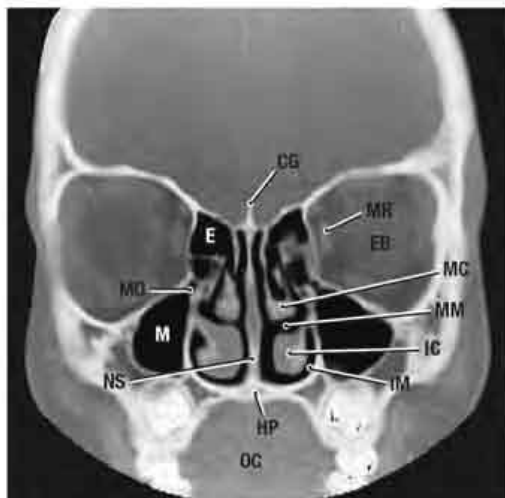
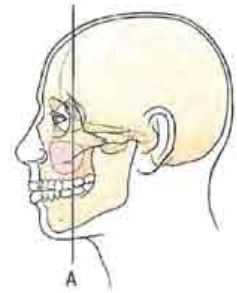
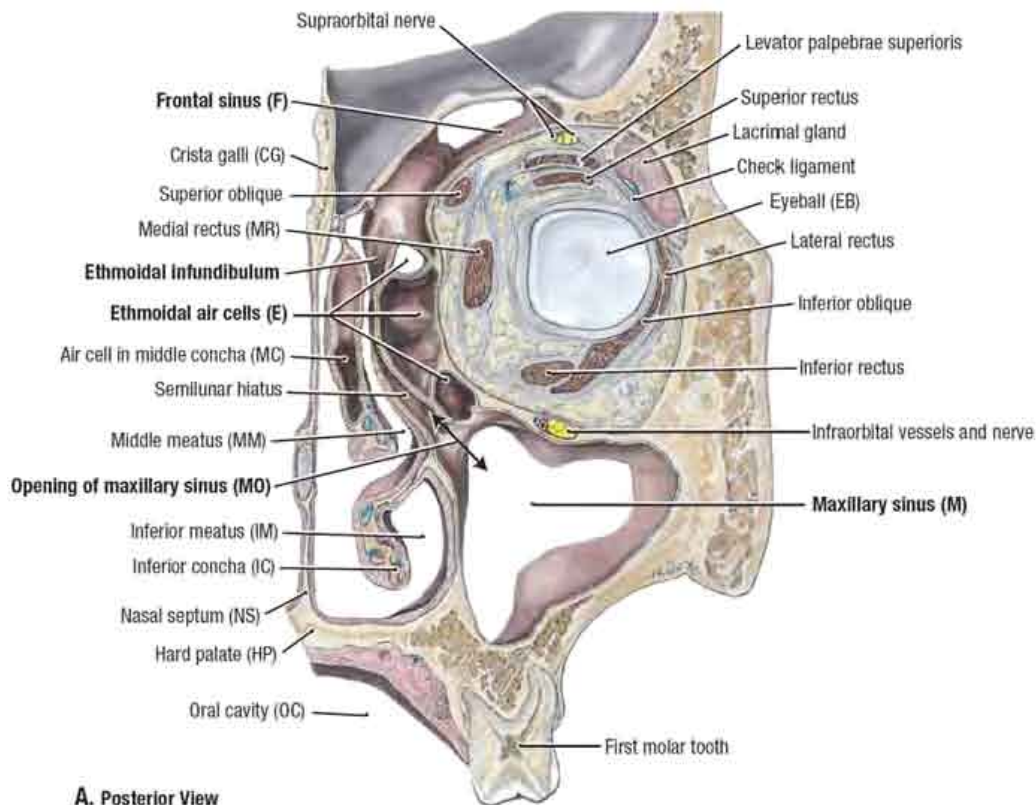
*Part of "Chapter 7 - Head "*

A. Coronal section of right side of the head. B. CT scan. C. Radiograph of cranium.  
Letters in B and C refer to structures labeled in A .

If nasal drainage is blocked, infections of the ethmoidal cells of the ethmoidal sinuses may break through the fragile medial wall of the orbit. Severe infections from this source may cause blindness but could also affect the dural sheath of the optic nerve, causing optic neuritis.

During removal of a maxillary molar tooth, a fracture of a root may occur. If proper retrieval methods are not used, a piece of the root may be driven superiorly into the maxillary sinus.





Authors: Agur, Anne M.R.; Dalley, Arthur F.

Title: *Grant's Atlas of Anatomy, 12th Edition*

Copyright ©2009 Lippincott Williams & Wilkins

> Table of Contents > Chapter 7 - Head > 7.65 Paranasal sinuses

---

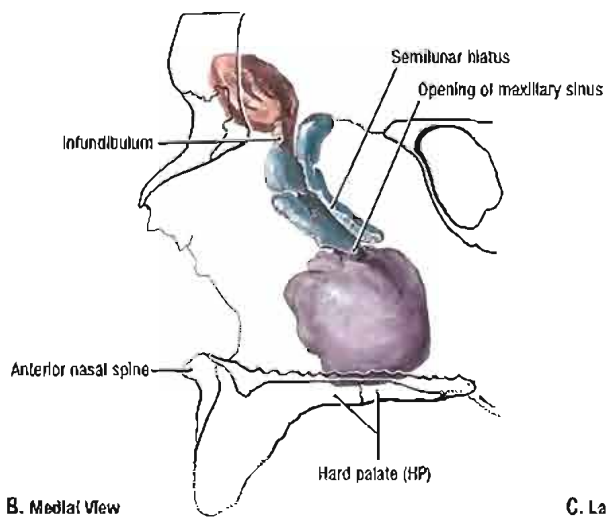
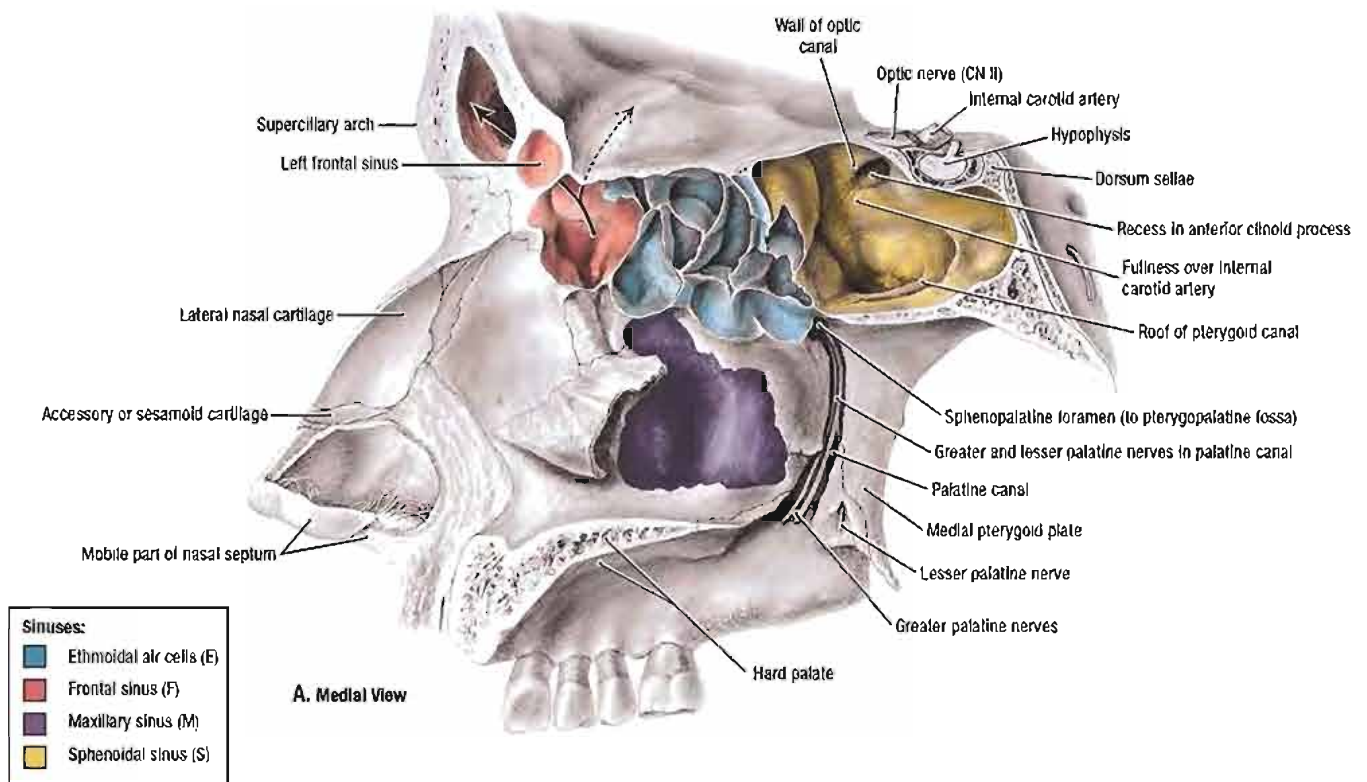
## 7.65 Paranasal sinuses

*Part of "Chapter 7 - Head "*

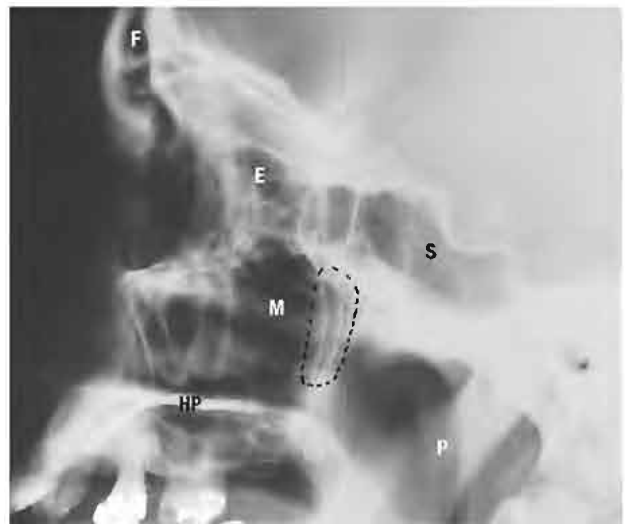
A. Opened sinuses, color coded. B. Cast of frontal and maxillary sinuses. C. Radiograph of cranium. *P*, pharynx; *dotted lines*, pterygopalatine fossa. Letters refer to structures labeled in B. The maxillary sinuses are the most commonly infected, probably because their ostia are small and located high on their superomedial walls, a poor location for natural drainage of the sinus. When the mucous membrane of the sinus is congested, the maxillary ostia often are obstructed. The maxillary sinus can be cannulated and drained by passing a canula from the nares through the maxillary ostium into the sinus.

---

P.699



**C. Lateral View**



Authors: Agur, Anne M.R.; Dalley, Arthur F.

Title: *Grant's Atlas of Anatomy, 12th Edition*

Copyright ©2009 Lippincott Williams & Wilkins

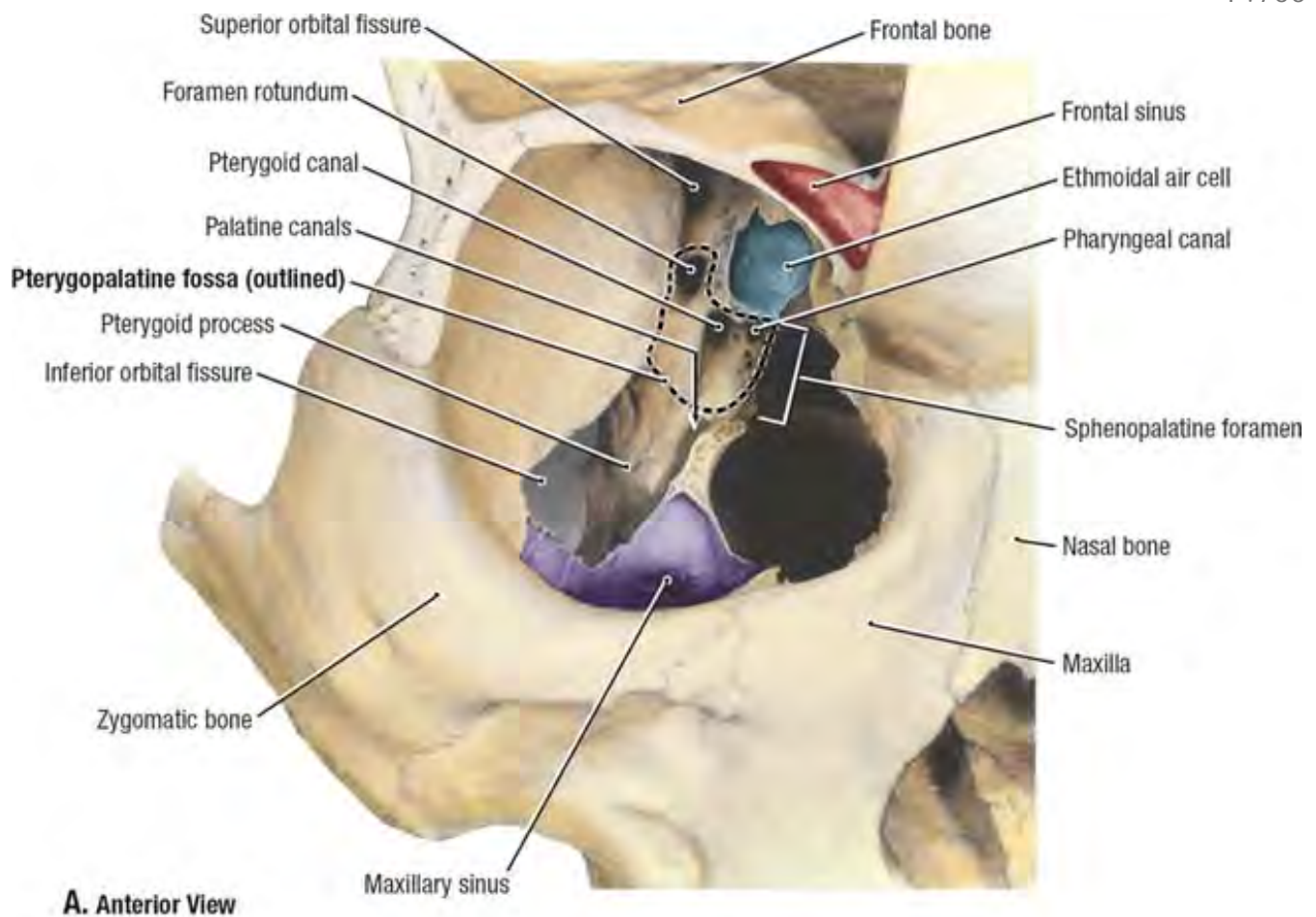
> Table of Contents > Chapter 7 - Head > 7.66 Pterygopalatine fossa, orbital approach

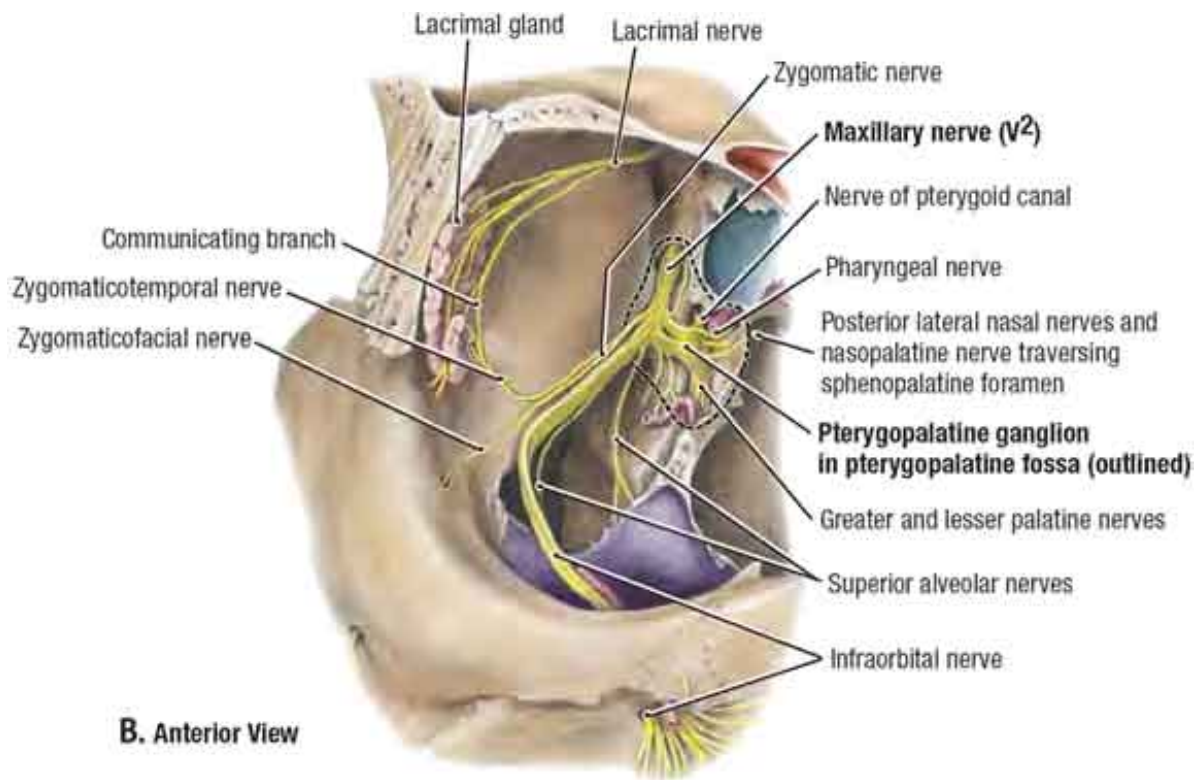
## 7.66 Pterygopalatine fossa, orbital approach

Part of "Chapter 7 - Head "

A. Bones and foramina. B. Maxillary nerve. In A and B , the pterygopalatine fossa has been exposed through the floor of the orbit and maxillary sinus.

P.700







Authors: Agur, Anne M.R.; Dalley, Arthur F.

Title: *Grant's Atlas of Anatomy, 12th Edition*

Copyright ©2009 Lippincott Williams & Wilkins

> Table of Contents > Chapter 7 - Head > 7.67 Nerves of the pterygopalatine fossa

---

## 7.67 Nerves of the pterygopalatine fossa

Part of "Chapter 7 - Head "

A. Medial half of the right viscerocranium following sagittal sectioning through the maxillary sinus. The inferior concha (*orange*) and palatine bone (*pink*) form part of the medial wall of the maxillary sinus. Note the ethmoid (*yellow*) and lacrimal (*blue*) bones of the medial wall of the orbital cavity and the sphenopalatine foramen opening into the nasal cavity from the pterygopalatine fossa. B. Maxillary nerve (CN V<sup>2</sup>) and branches.

---

P.701

C. Autonomic innervation of the lacrimal gland and glands of the palatine and nasal mucosa. D. Sphenoid bone, anterior surface of the body, pterygoid process, and central parts of the greater and lesser wings.

---

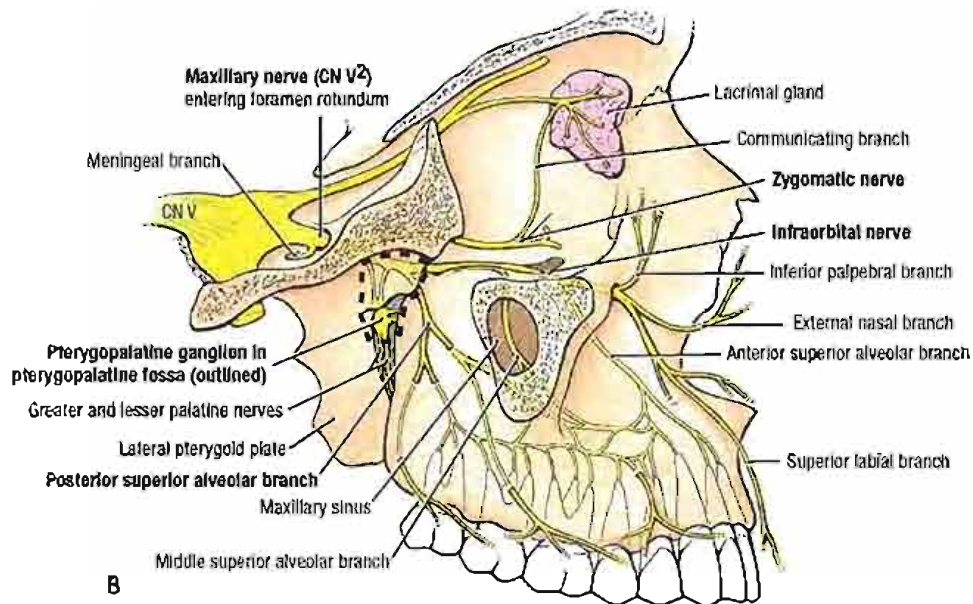
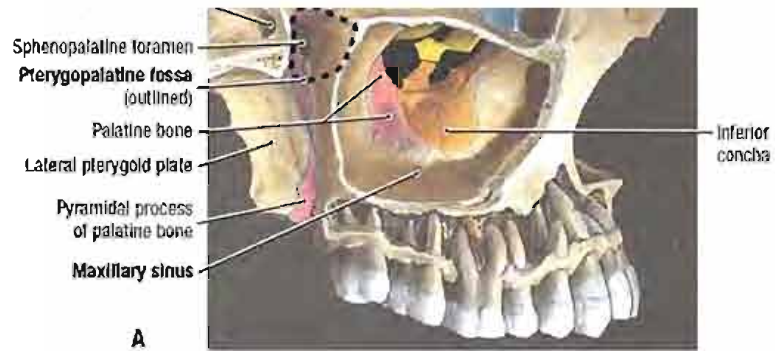
P.702

E. Coronal section through nasal cavities, sphenoidal sinuses, and right pterygopalatine fossa, in the plane of the palatine canal, demonstrating the course of the nasopalatine and greater and lesser palatine nerves. F. Anterior part of cranium following coronal sectioning in the plane of the foramen lacerum demonstrating the posterior wall of the pterygopalatine fossa.

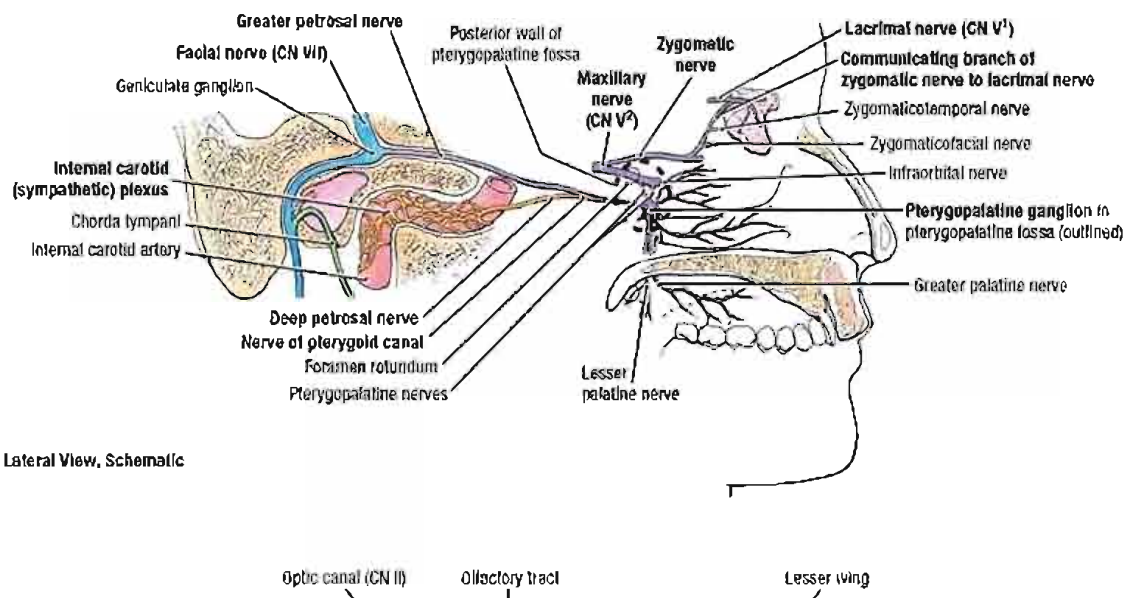
---

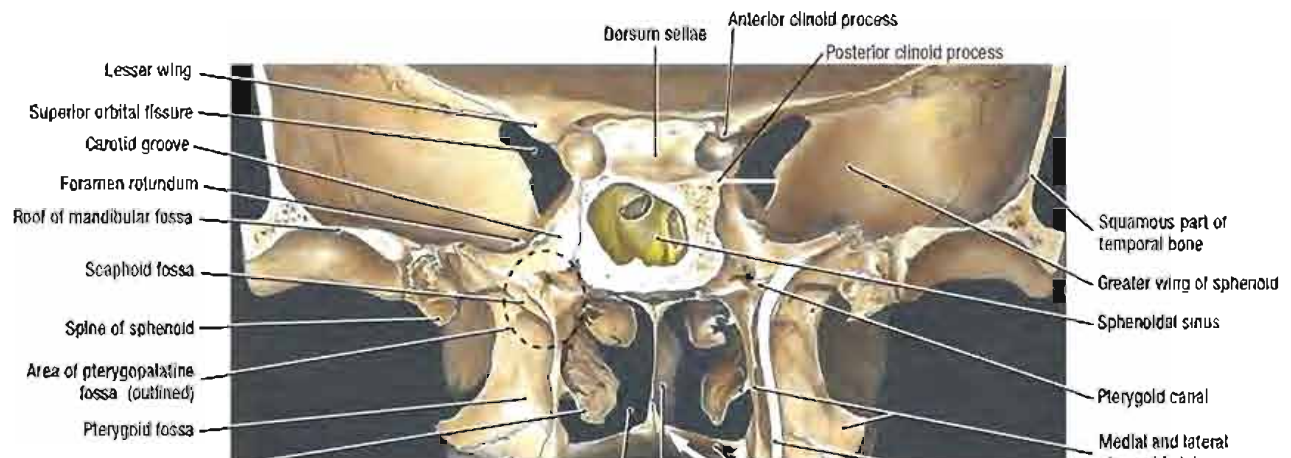
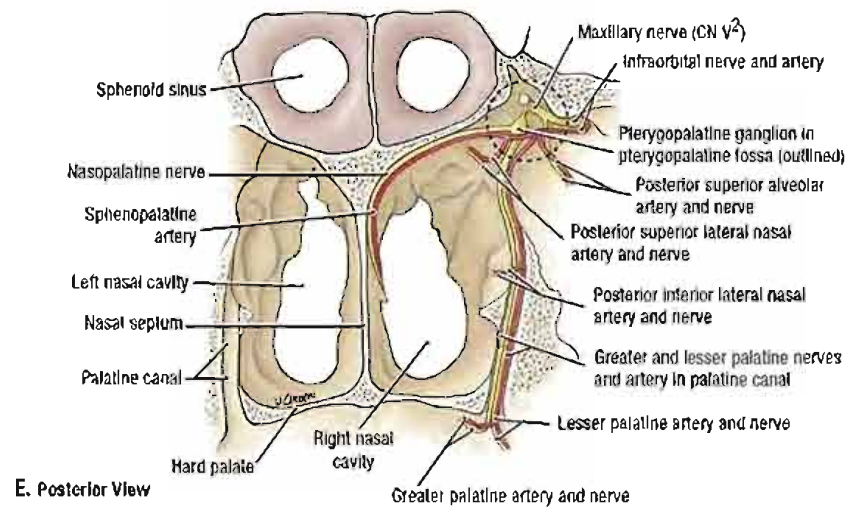
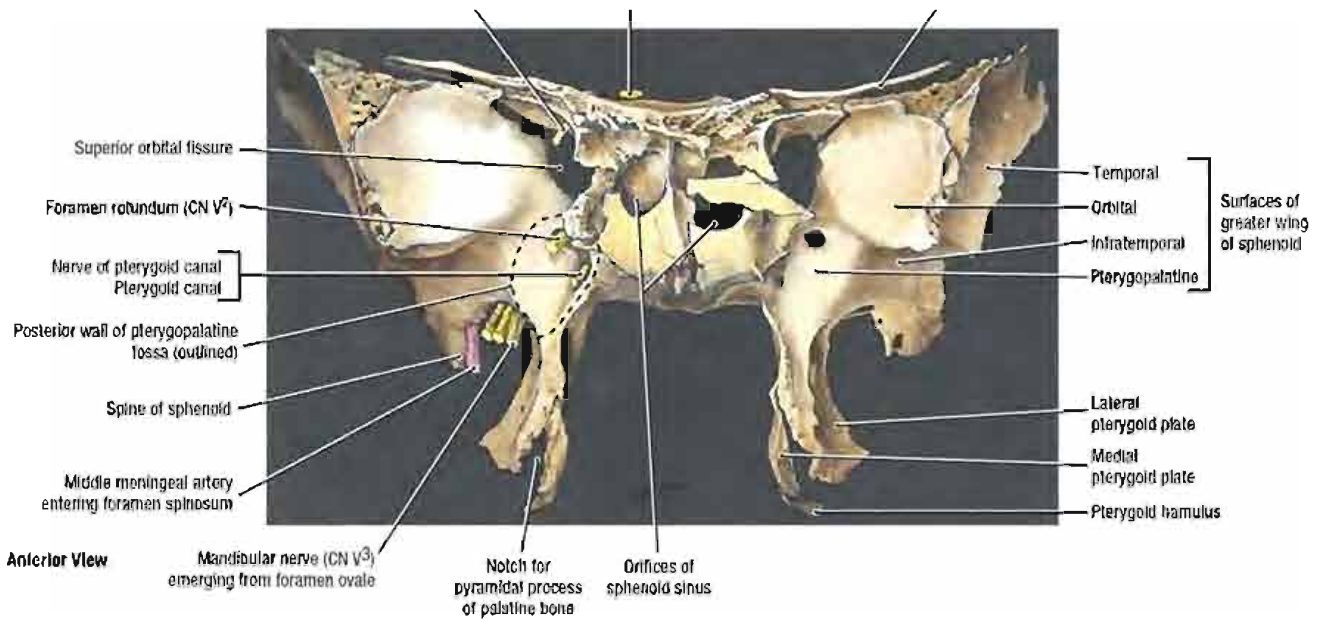
P.703






#### Lateral Views







Authors: Agur, Anne M.R.; Dalley, Arthur F.

Title: *Grant's Atlas of Anatomy, 12th Edition*

Copyright ©2009 Lippincott Williams & Wilkins

> Table of Contents > Chapter 7 - Head > 7.68 Auricle

---

## 7.68 Auricle

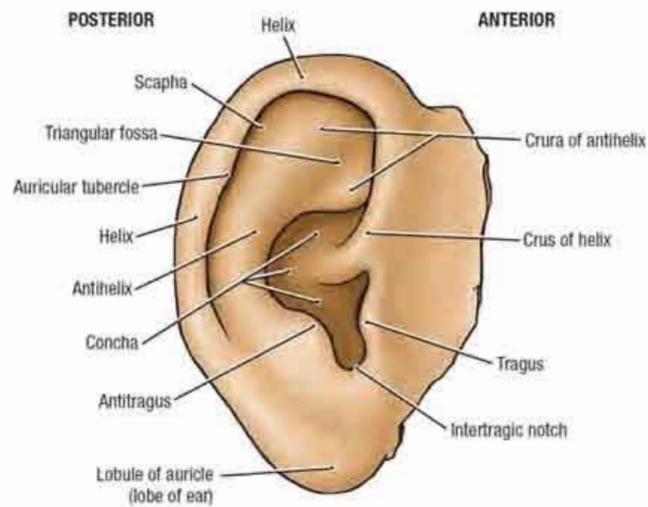
*Part of* "Chapter 7 - Head "

A. Features of auricle. B. Cartilage of auricle. C. Surface anatomy of auricle.

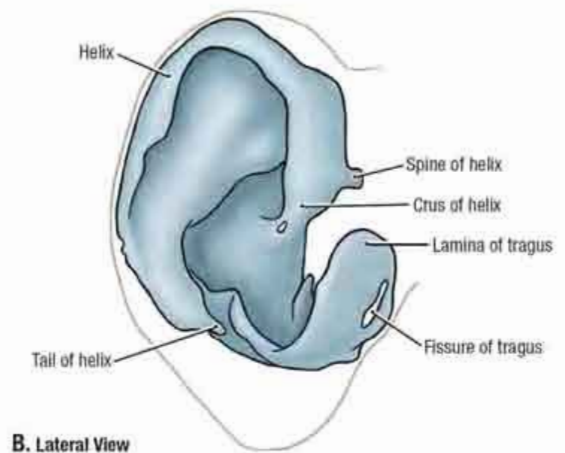
---

P.704

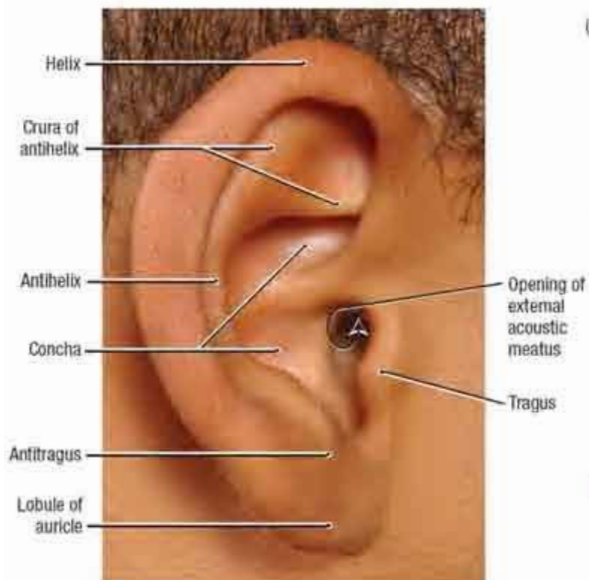




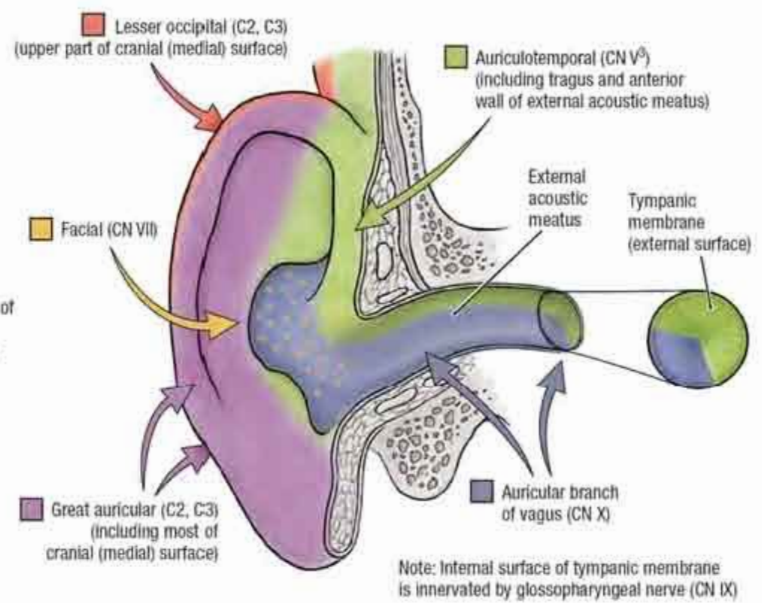
**A. Lateral View**



**B. Lateral View**



**C. Lateral View**



**D. Schematic Section**

Authors: Agur, Anne M.R.; Dalley, Arthur F.

Title: *Grant's Atlas of Anatomy, 12th Edition*

Copyright ©2009 Lippincott Williams & Wilkins

> Table of Contents > Chapter 7 - Head > 7.69 External, middle, and internal ear "I":  
overviews

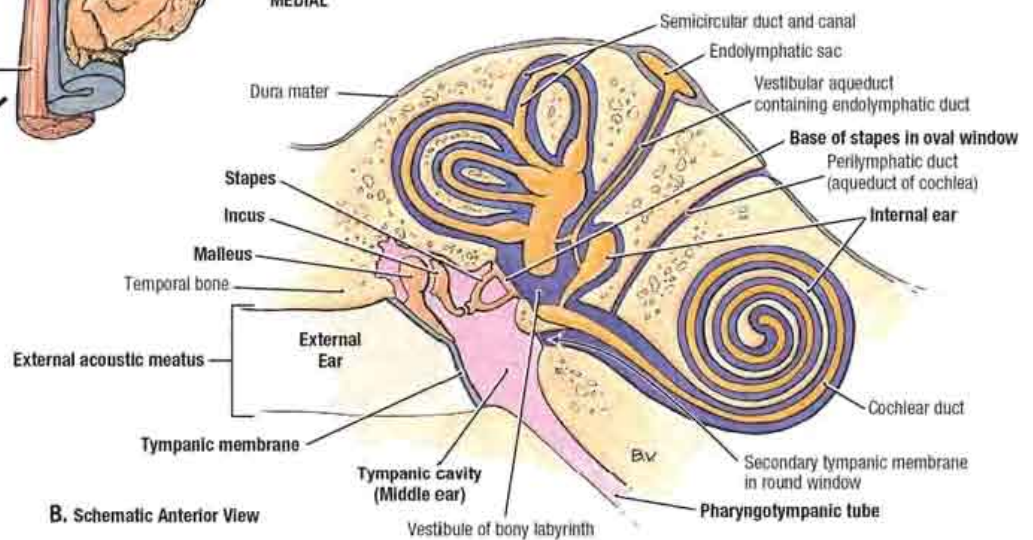
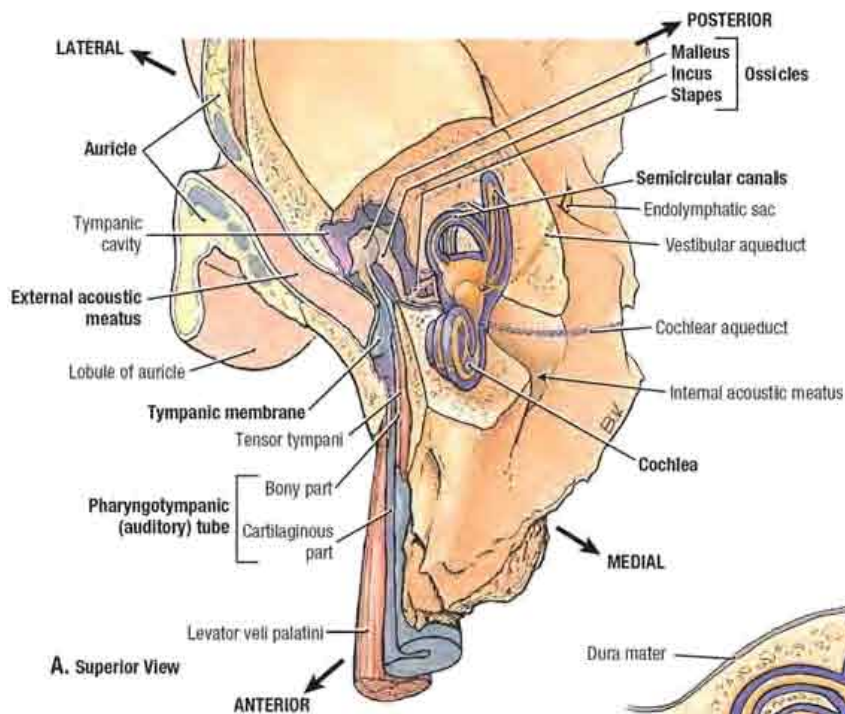
---

## 7.69 External, middle, and internal ear "I": overviews

*Part of* "Chapter 7 - Head "

A. Right temporal bone and auricle, sectioned in planes of (1) externa acoustic meatus and (2) pharyngotympanic tube. B. Schematic section of petrous temporal bone.

- The external ear comprises the auricle and external acoustic (auditory) meatus.
- The middle ear (tympanum) lies between the tympanic membrane and internal ear. Three ossicles extend from the lateral to the medial walls of the tympanum. Of these, the malleus is attached to the tympanic membrane. The stapes is attached by the annular ligament to the fenestra vestibuli (oval window), and the incus connects to the malleus and stapes. The pharyngotympanic tube, extending from the nasopharynx, opens into the anterior wall of the tympanic cavity.
- The membranous labyrinth comprises a closed system of membranous tubes and bulbs filled with fluid (endolymph) and bathed in surrounding fluid, called *perilymph* (*purple* in B ); both membranous labyrinth and perilymph are contained within the bony labyrinth.



Authors: Agur, Anne M.R.; Dalley, Arthur F.

Title: *Grant's Atlas of Anatomy, 12th Edition*

Copyright ©2009 Lippincott Williams & Wilkins

> Table of Contents > Chapter 7 - Head > 7.70 External, middle, and internal ear II:  
coronally sectioned

---

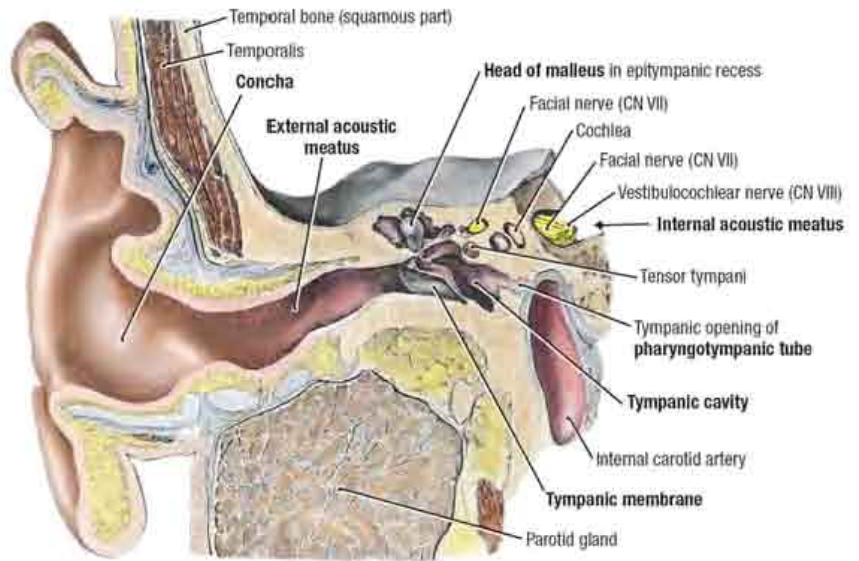
## 7.70 External, middle, and internal ear II: coronally sectioned

*Part of* "Chapter 7 - Head "

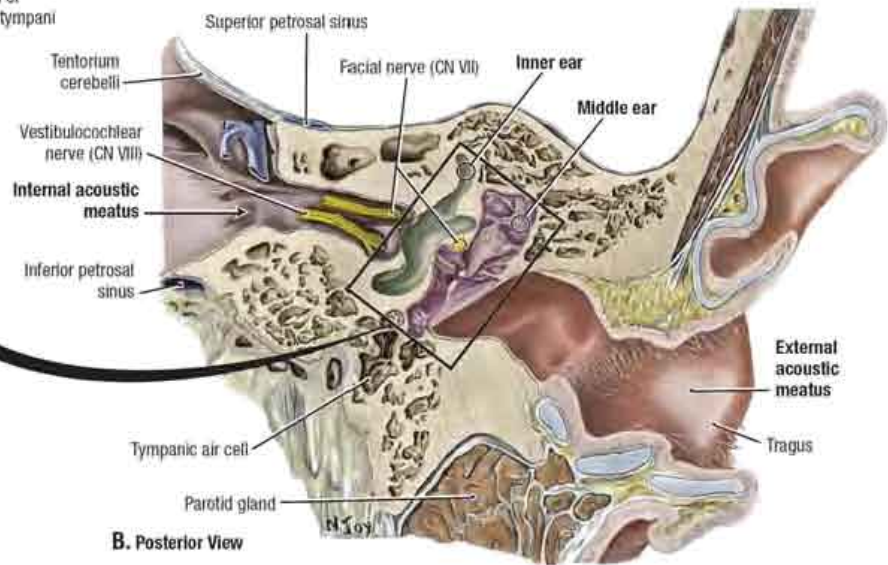
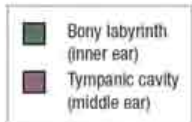
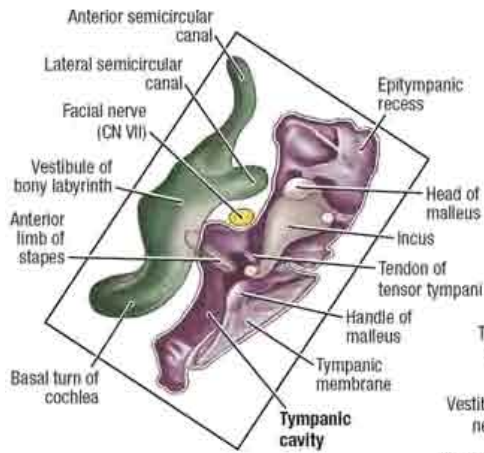
A. Anterior portion. B. Posterior portion. The inset (*outlined by the box*) is an enlargement of the structures of the middle and internal ear as they appear in B.

- The external acoustic meatus is about 3 cm long; half is cartilaginous and half is bony. It is narrowest at the isthmus, near the junction of the cartilaginous and bony parts.
- The external acoustic meatus is innervated by the auriculotemporal branch of the mandibular nerve (CN V<sup>3</sup>) and the auricular branches of the vagus nerve (CN X); the middle ear is innervated by the glossopharyngeal nerve (CN IX).
- The cartilaginous part of the external acoustic meatus is lined with thick skin; the bony part is lined with thin epithelium that adheres to the periosteum and forms the outermost layer of the tympanic membrane.





**A. Anterior View**



**B. Posterior View**



Authors: Agur, Anne M.R.; Dalley, Arthur F.

Title: *Grant's Atlas of Anatomy, 12th Edition*

Copyright ©2009 Lippincott Williams & Wilkins

> Table of Contents > Chapter 7 - Head > 7.71 Tympanic membrane

---

## 7.71 Tympanic membrane

*Part of* "Chapter 7 - Head "

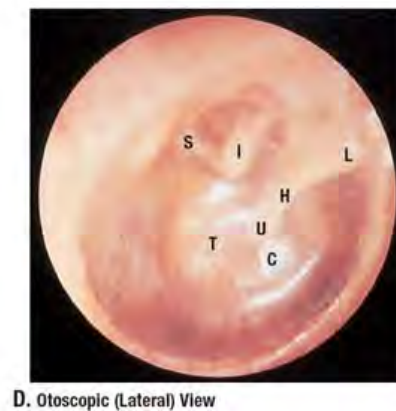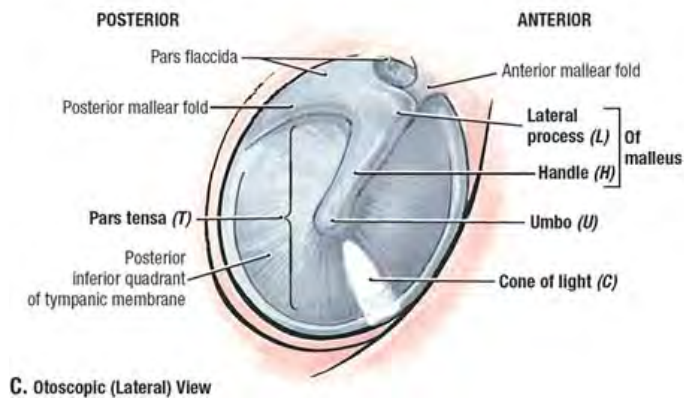
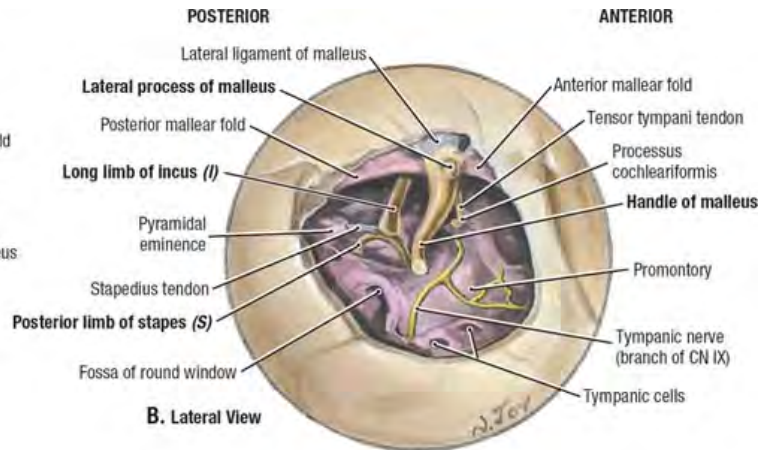
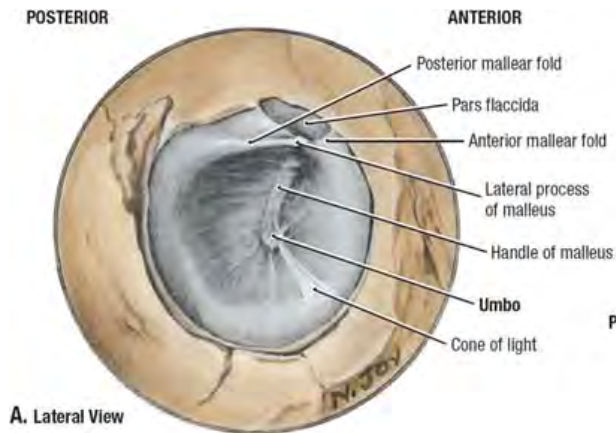
A. External (lateral) surface of tympanic membrane. B. Tympanic membrane removed, demonstrating structures that lie medially. C. Diagram of otoscopic view of tympanic membrane. D. Otoscopic view of tympanic membrane. Letter labels are identified in C .

- The oval tympanic membrane is a shallow cone deepest at the central apex, the umbo, where the membrane is attached to the tip of the handle of the malleus. The handle of the malleus is attached to the membrane along its entire length as it extends anterosuperiorly toward the periphery of the membrane.
- Superior to the lateral process of the malleus, the membrane is thin (pars flaccida); the flaccid part lacks the radial and circular fibers present in the remainder of the membrane (pars tensa). The junction between the two parts is marked by anterior and posterior malleolar folds.
- The lateral surface of the tympanic membrane is innervated by the auricular branch of the auriculotemporal nerve (CN V<sup>3</sup>) and the auricular branch of the vagus nerve (CN X); the medial surface is innervated by tympanic branches of CN IX.

Examination of the external acoustic meatus and tympanic membrane begins by straightening the meatus. In adults, the helix is grasped and pulled posterosuperiorly (up, out, and back). These movements reduce the curvature of the external acoustic meatus, facilitating insertion of the

otoscope. The external acoustic meatus is relatively short in infants; therefore, extra care must be taken to prevent damage to the tympanic membrane.

P.707



Authors: Agur, Anne M.R.; Dalley, Arthur F.

Title: *Grant's Atlas of Anatomy, 12th Edition*

Copyright ©2009 Lippincott Williams & Wilkins

> Table of Contents > Chapter 7 - Head > 7.72 Ossicles of the middle ear

---

## 7.72 Ossicles of the middle ear

*Part of "Chapter 7 - Head "*

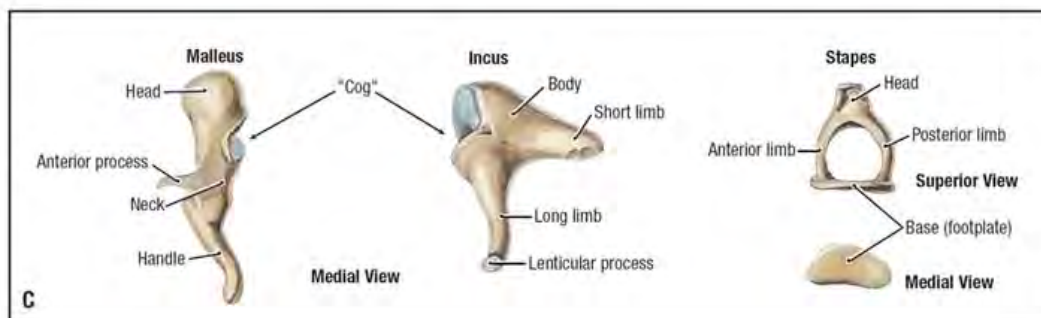
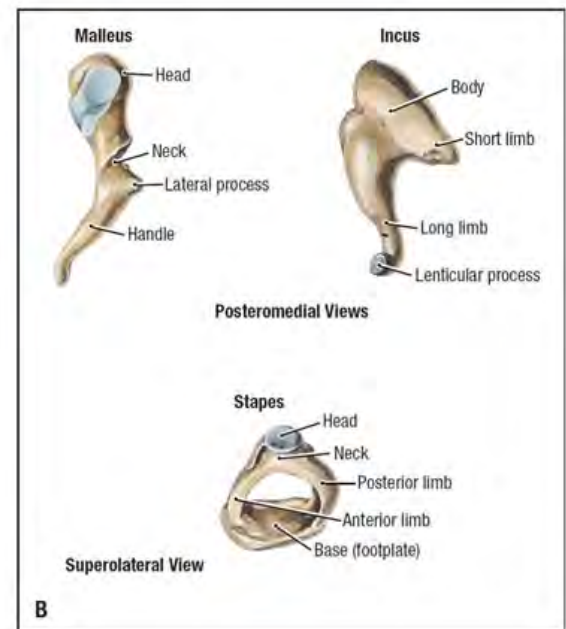
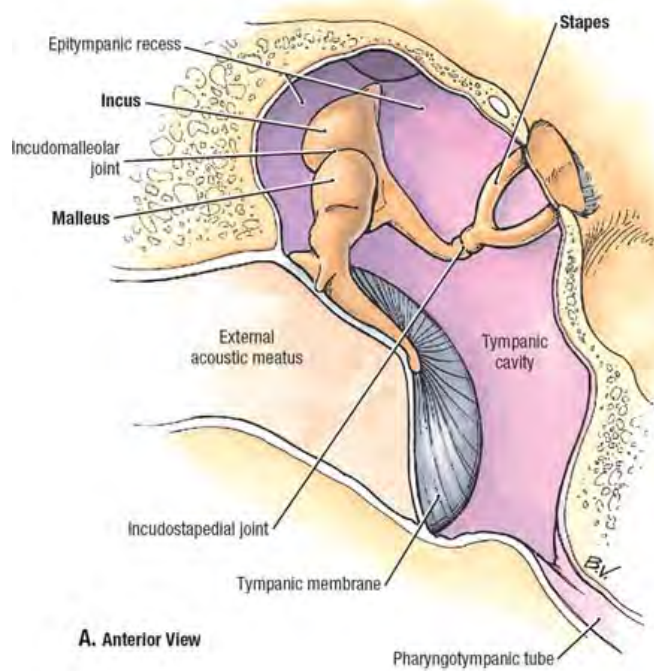
A. Ossicles in situ, as revealed by a coronal section of the temporal bone. B and C. Isolated ossicles.

- The head of the malleus and body and short process of the incus lie in the epitympanic recess, and the handle of the malleus is embedded in the tympanic membrane.
- The saddle-shaped articular surface of the head of the malleus and the reciprocally shaped articular surface of the body of the incus form the incudomalleolar synovial joint.
- A convex articular facet at the end of the long process of the incus articulates with the head of the stapes to compose the incudostapedial synovial joint.

- An earache and bulging red tympanic membrane may indicate pus or fluid in the middle ear, a sign of otitis media. Infection of the middle ear often is secondary to upper respiratory infections. Inflammation and swelling of the mucous membrane lining the tympanic cavity may cause partial or complete blockage of the pharyngotympanic tube. The tympanic membrane becomes red and bulges, and the person may complain of "ear popping." • If untreated, otitis media may produce impaired hearing as the result of scarring of the auditory ossicles, limiting the ability of these bones to move in

response to sound.

P.708



Authors: Agur, Anne M.R.; Dalley, Arthur F.

Title: *Grant's Atlas of Anatomy, 12th Edition*

Copyright ©2009 Lippincott Williams & Wilkins

> Table of Contents > Chapter 7 - Head > 7.73 Structures of the tympanic cavity

---

## 7.73 Structures of the tympanic cavity

*Part of "Chapter 7 - Head "*

A. Schematic illustration of the tympanic cavity with the anterior wall removed. B. Lateral wall of the tympanic cavity. The facial nerve lies within the facial canal surrounded by a tough periosteal tube; the chorda tympani leaves the facial nerve and lies within two crescentic folds of mucous membrane, crossing the neck of the malleus superior to the tendon of tensor tympani.

Perforation of the tympanic membrane (ruptured eardrum) may result from otitis media. Perforation may also result from foreign bodies in the external acoustic meatus, trauma, or excessive pressure. Because the superior half of the tympanic membrane is much more vascular than the inferior half, incisions are made posteroinferiorly through the membrane. This incision also avoids injury to the chorda tympani nerve and auditory ossicles.





Authors: Agur, Anne M.R.; Dalley, Arthur F.

Title: *Grant's Atlas of Anatomy, 12th Edition*

Copyright ©2009 Lippincott Williams & Wilkins

> Table of Contents > Chapter 7 - Head > 7.74 Middle and inner ear in situ

---

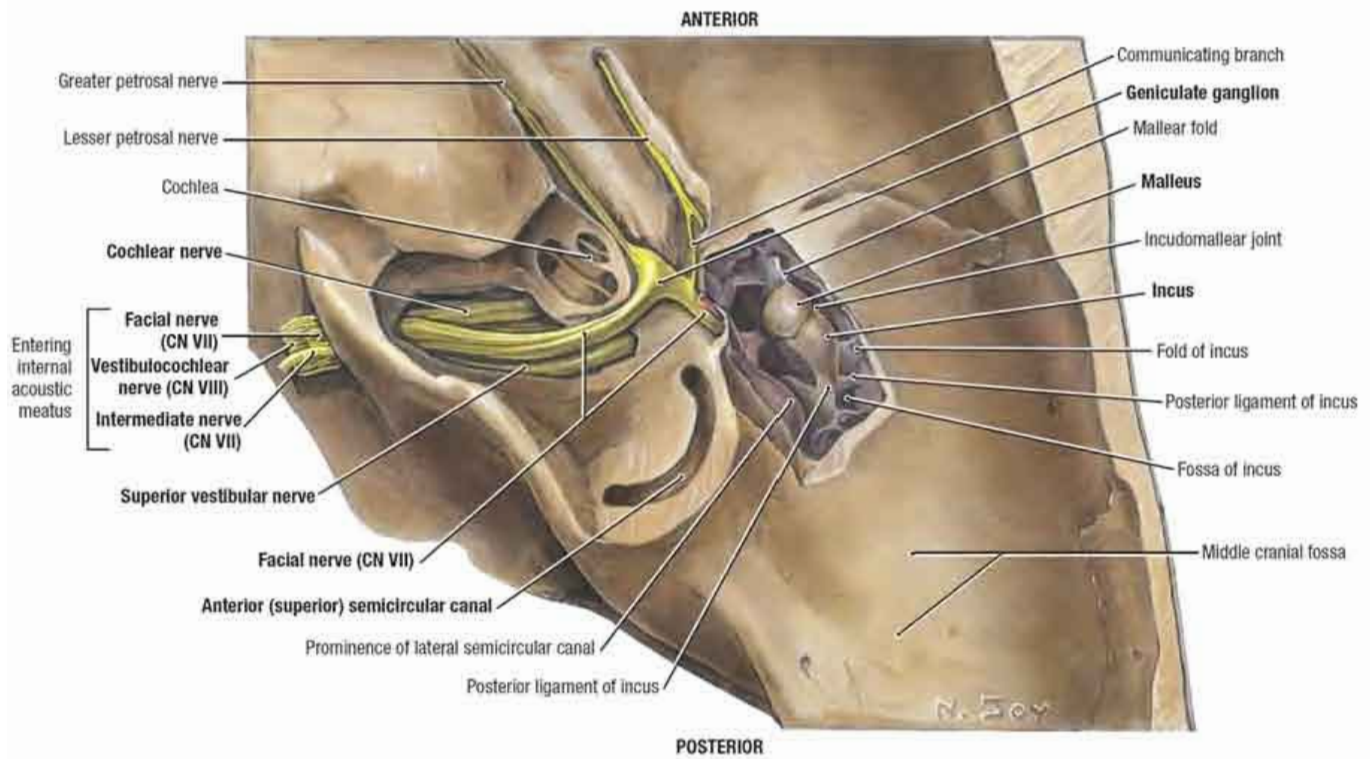
## 7.74 Middle and inner ear *in situ*

*Part of* "Chapter 7 - Head "

The tegmen tympani has been removed to expose the middle ear, the arcuate eminence has been removed to expose the anterior semicircular canal, and the course of the facial and vestibulocochlear nerves through the internal acoustic meatus and internal ear is demonstrated. At the geniculate ganglion, the facial nerve executes a sharp bend, called the genu, and then curves posteroinferiorly within the bony facial canal; the thin lateral wall of the facial canal separates the facial nerve from the tympanic cavity of the middle ear.

---

P.710



Authors: Agur, Anne M.R.; Dalley, Arthur F.

Title: *Grant's Atlas of Anatomy, 12th Edition*

Copyright ©2009 Lippincott Williams & Wilkins

> Table of Contents > Chapter 7 - Head > 7.75 Right tympanic cavity and pharyngotympanic tube

## 7.75 Right tympanic cavity and pharyngotympanic tube

*Part of "Chapter 7 - Head"*

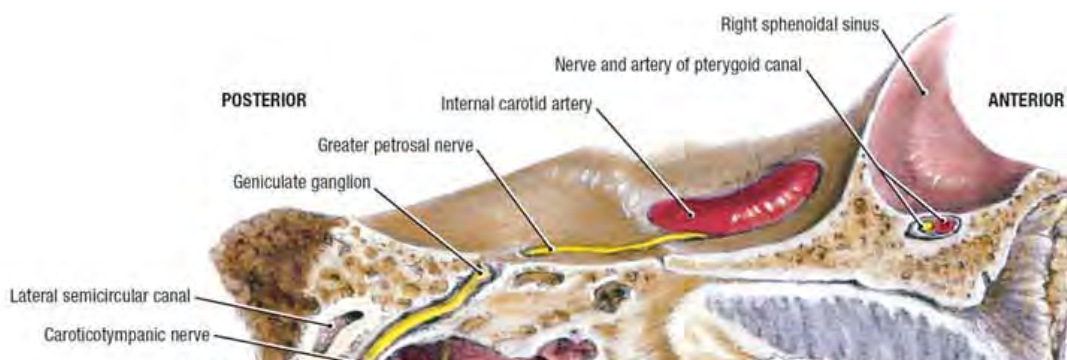
The cut surfaces of this longitudinally sectioned specimen are displayed as pages in a book. A. Dissection of medial wall. B. Schematic illustration of medial wall.

P.711

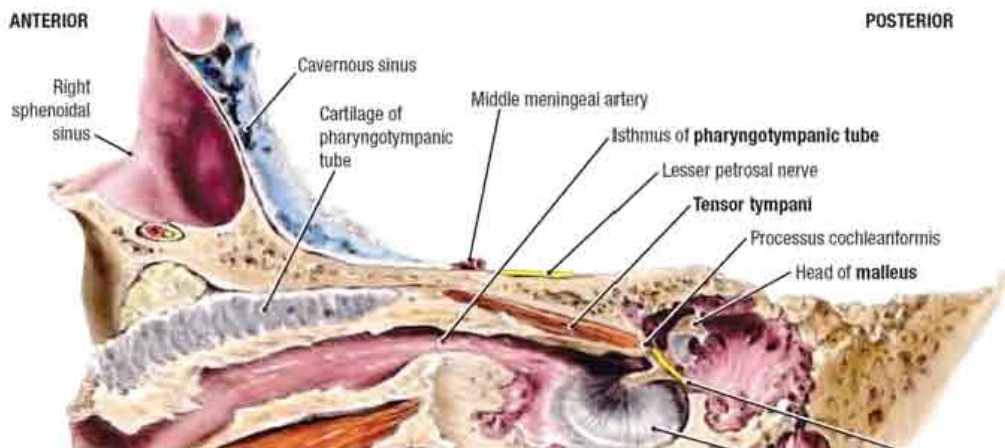
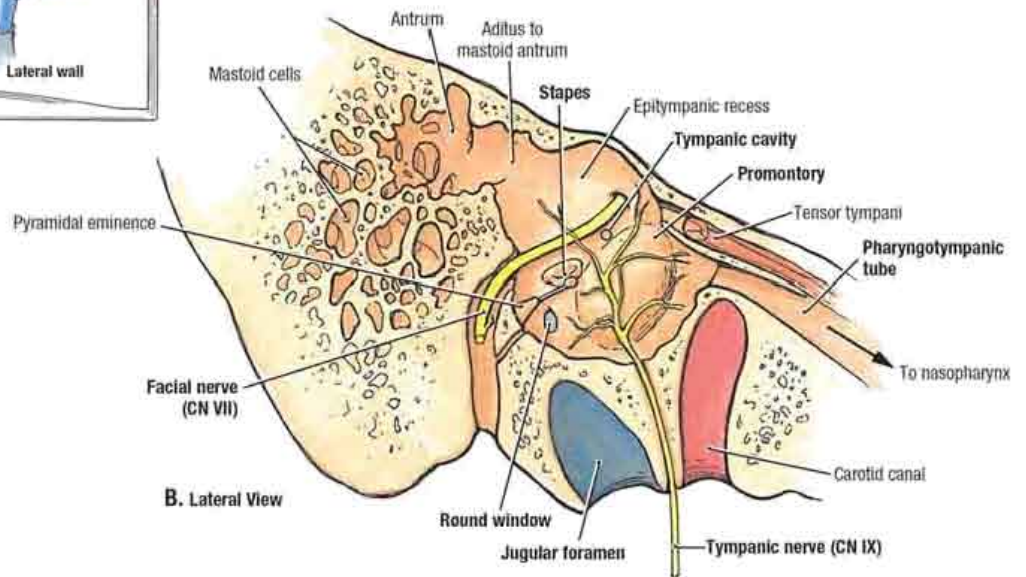
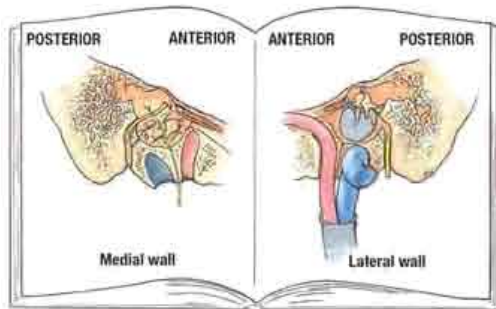
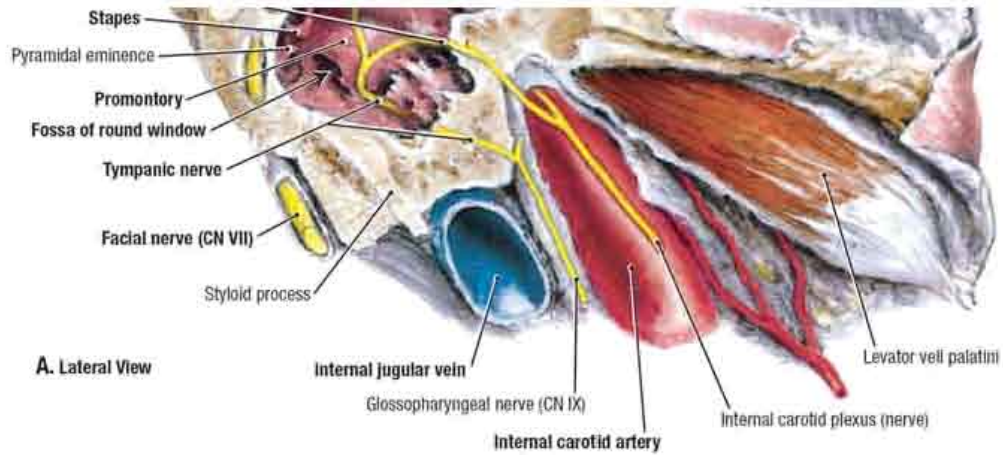
C. Dissection of lateral wall. D. Schematic illustration of lateral wall.

Infections of the mastoid antrum and mastoid cells (mastoiditis) result from middle ear infections that cause inflammation of the mastoid process. Infections may spread superiorly into the middle cranial fossa through the petrosquamous fissure in children or may cause osteomyelitis (bone infection) of the tegmen tympani. Since the advent of antibiotics, mastoiditis is uncommon.

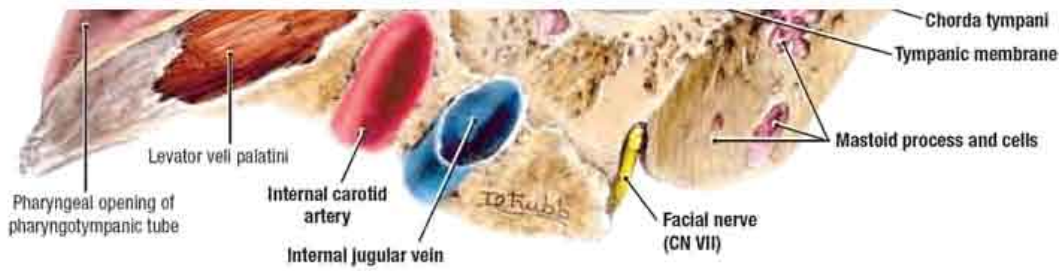
P.712



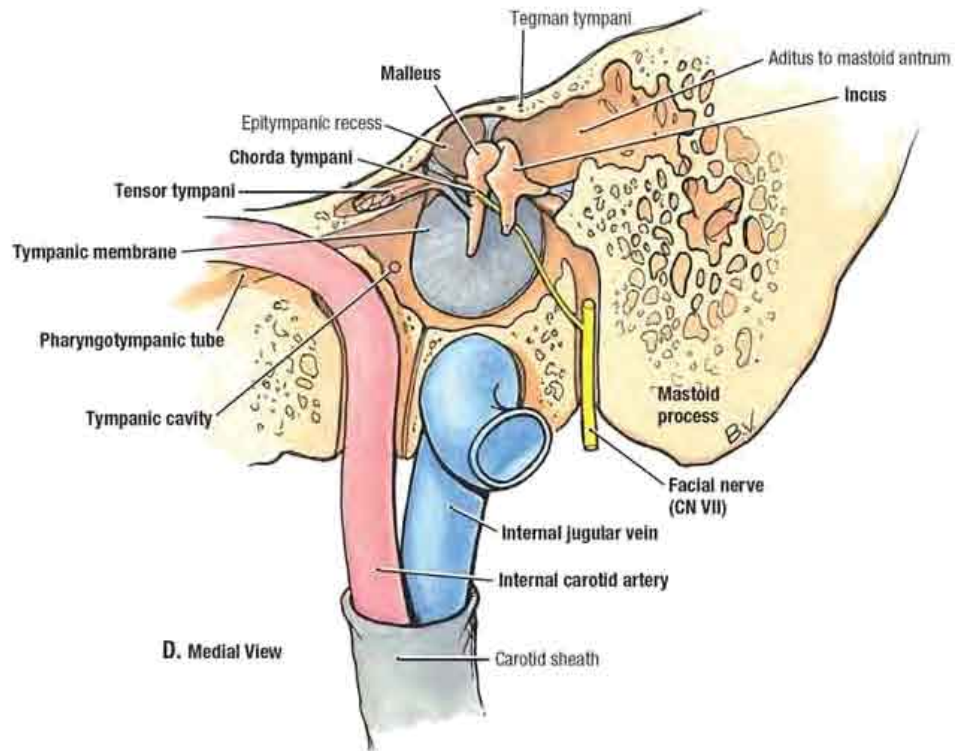








**C. Medial View**



**D. Medial View**

Authors: Agur, Anne M.R.; Dalley, Arthur F.

Title: *Grant's Atlas of Anatomy, 12th Edition*

Copyright ©2009 Lippincott Williams & Wilkins

> Table of Contents > Chapter 7 - Head > 7.76 Right tympanic cavity and pharyngotympanic tube

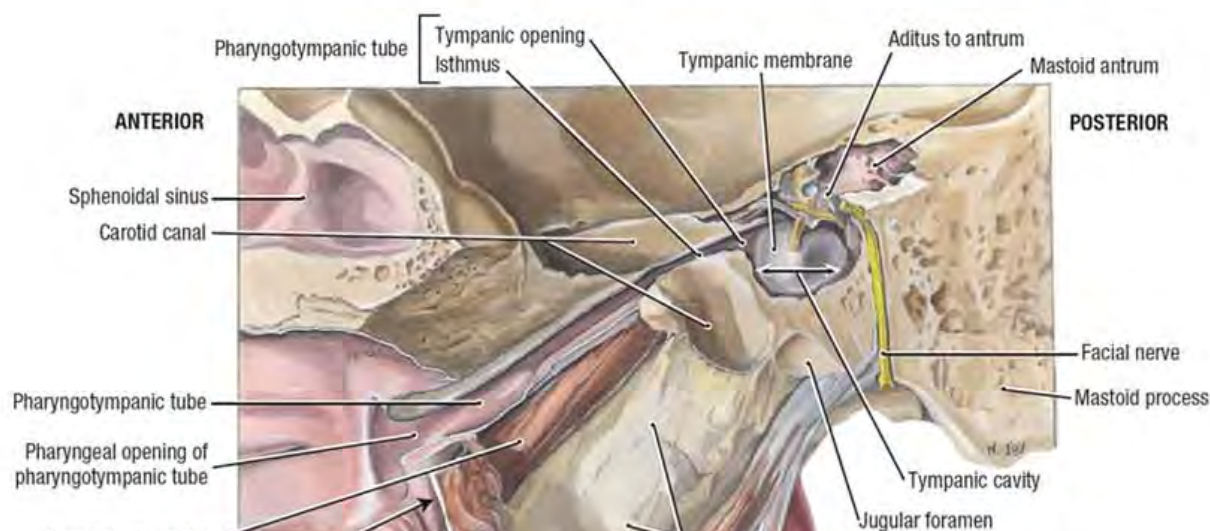
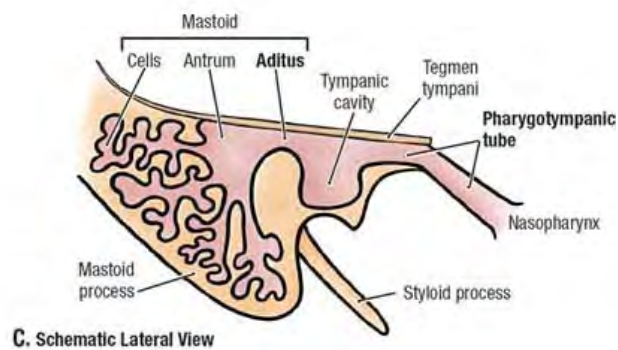
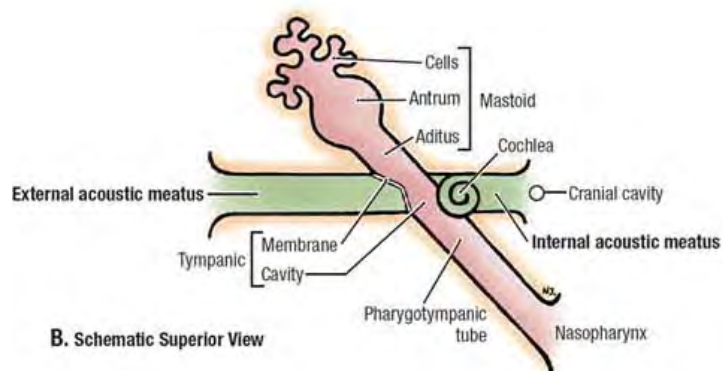
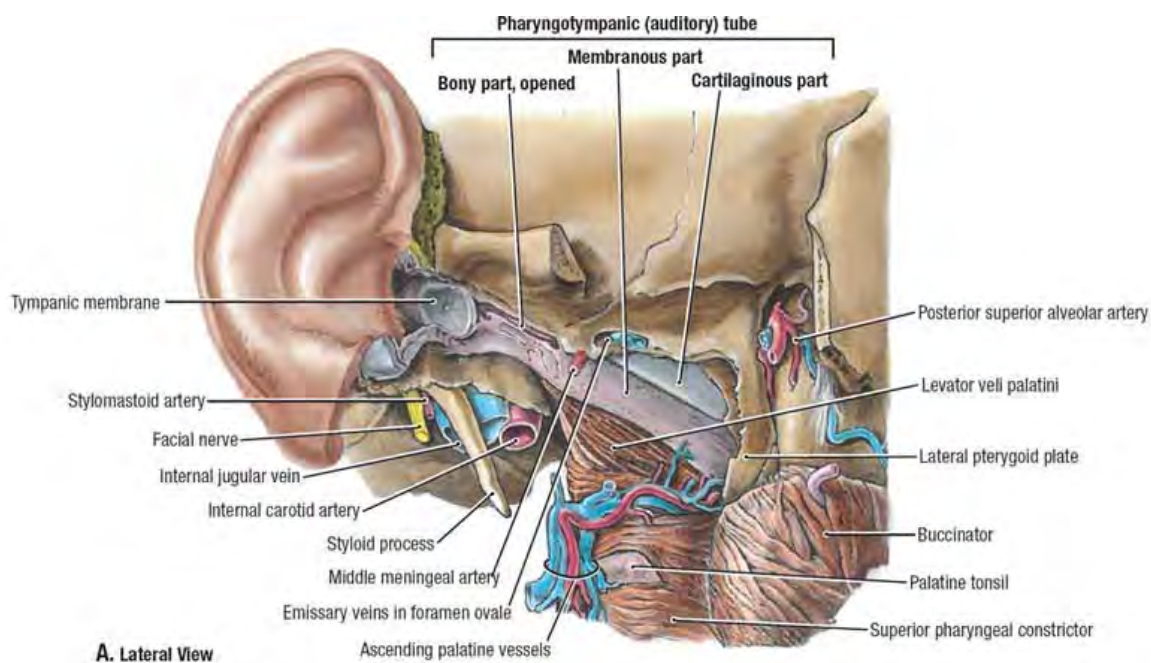
---

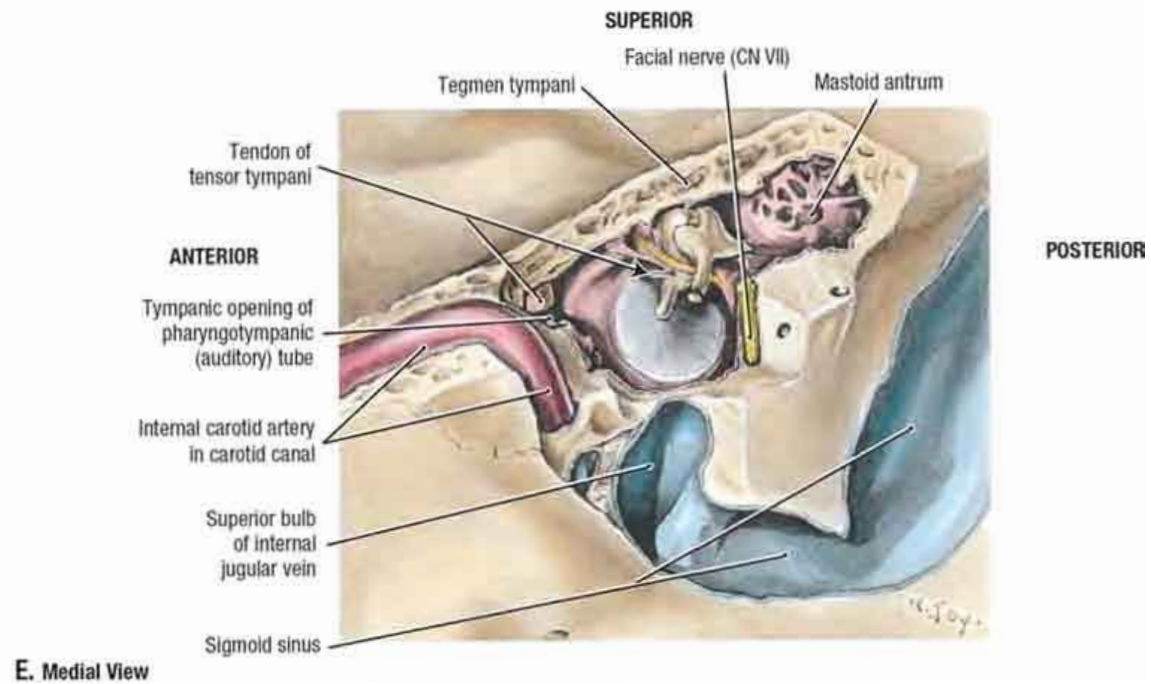
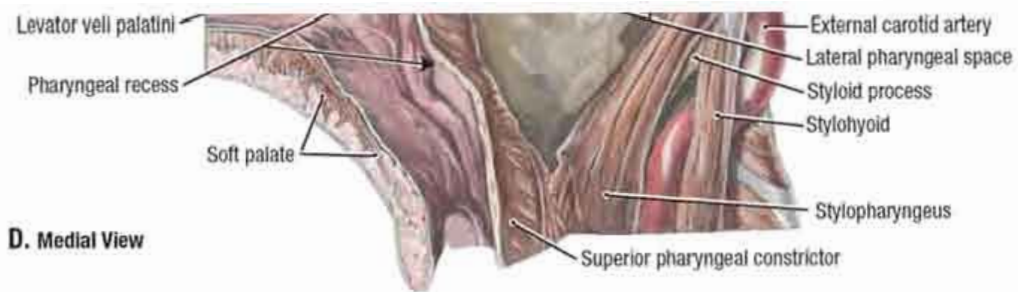
## 7.76 Right tympanic cavity and pharyngotympanic tube

*Part of "Chapter 7 - Head "*

A. Dissection demonstrating lateral aspect of pharyngotympanic tube and structures located medially. B. Schematic illustration demonstrating relationship between internal and external acoustic meatuses. C. Diagram of tegmen tympani. D. Spaces of tympanic bone. E. Relationship of tympanic cavity to internal carotid artery, sigmoid sinus, and middle cranial fossa.

- The general direction of the pharyngotympanic tube is superior, posterior, and lateral from the nasopharynx to the tympanic cavity.
- The cartilaginous part of the tube rests throughout its length on the levator veli palatini muscle.
- The line of the meatuses and the line of the airway, from nasopharynx to mastoid cells, intersect at the tympanic cavity.
- The tegmen tympani forms the roof of the tympanic cavity and mastoid antrum.
- The internal carotid artery is the primary relationship of the anterior wall, the internal jugular vein is the primary relationship of the floor, and the facial nerve is the primary relationship of the posterior wall.





Authors: Agur, Anne M.R.; Dalley, Arthur F.

Title: *Grant's Atlas of Anatomy, 12th Edition*

Copyright ©2009 Lippincott Williams & Wilkins

> Table of Contents > Chapter 7 - Head > 7.77 Bony and membranous labyrinths

---

## 7.77 Bony and membranous labyrinths

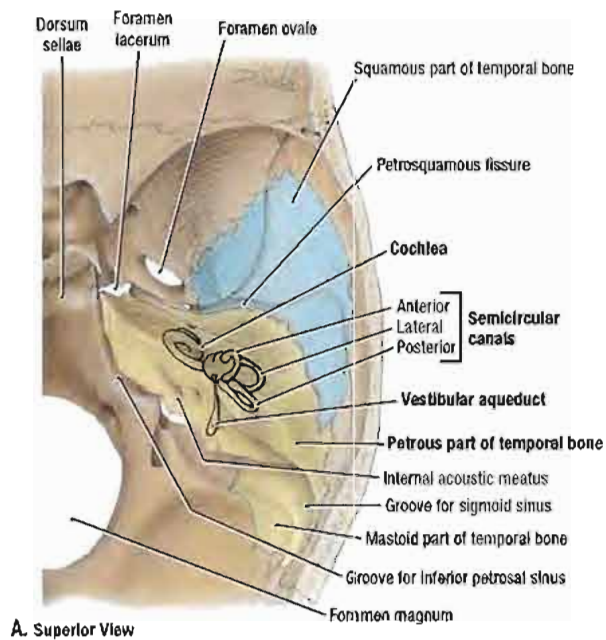
*Part of* "Chapter 7 - Head "

A. Location and orientation of bony labyrinth within petrous temporal bone. B. Semicircular canals and aqueducts *in situ*. The tegmen tympani has been excised, and the softer bone surrounding the harder bone of the otic capsule has been drilled away. C. Walls of left bony labyrinth (otic capsule). The bony labyrinth is the fluid-filled space contained within this formation. D. Membranous labyrinth as it lies within the surrounding bony labyrinth. E. Isolated left membranous labyrinth.

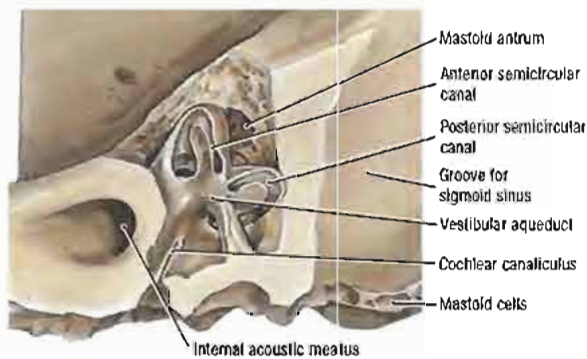
---

P.715

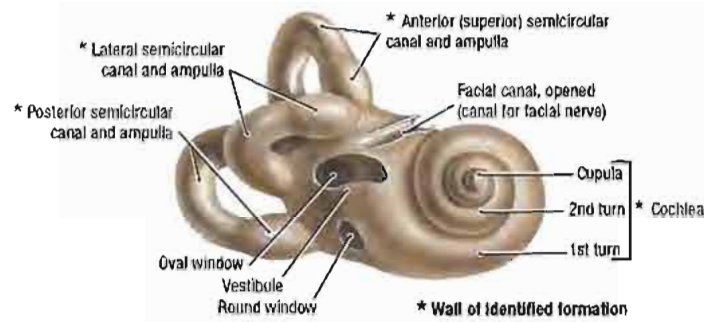




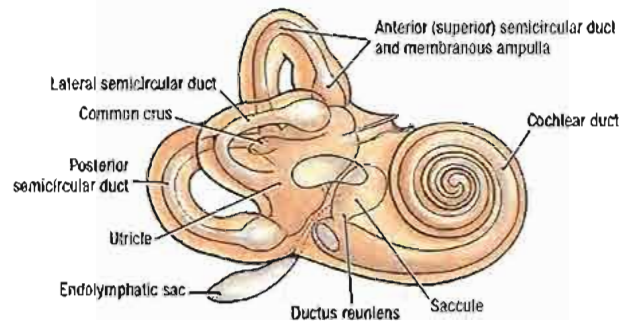
A. Superior View



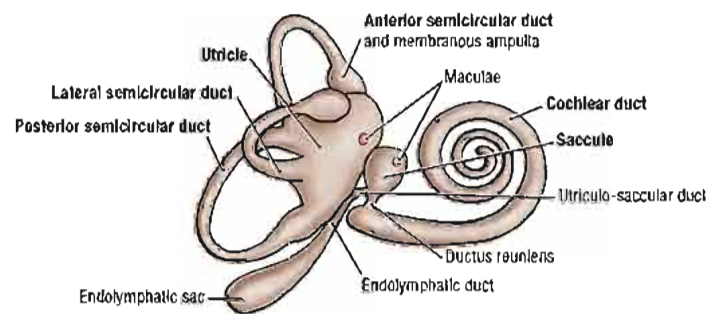
B. Posterosuperior View



C. Anterolateral View



D. Anterolateral View



E. Anterolateral View

Authors: Agur, Anne M.R.; Dalley, Arthur F.

Title: *Grant's Atlas of Anatomy, 12th Edition*

Copyright ©2009 Lippincott Williams & Wilkins

> Table of Contents > Chapter 7 - Head > 7.78 Vestibulocochlear nerve and structure of cochlea

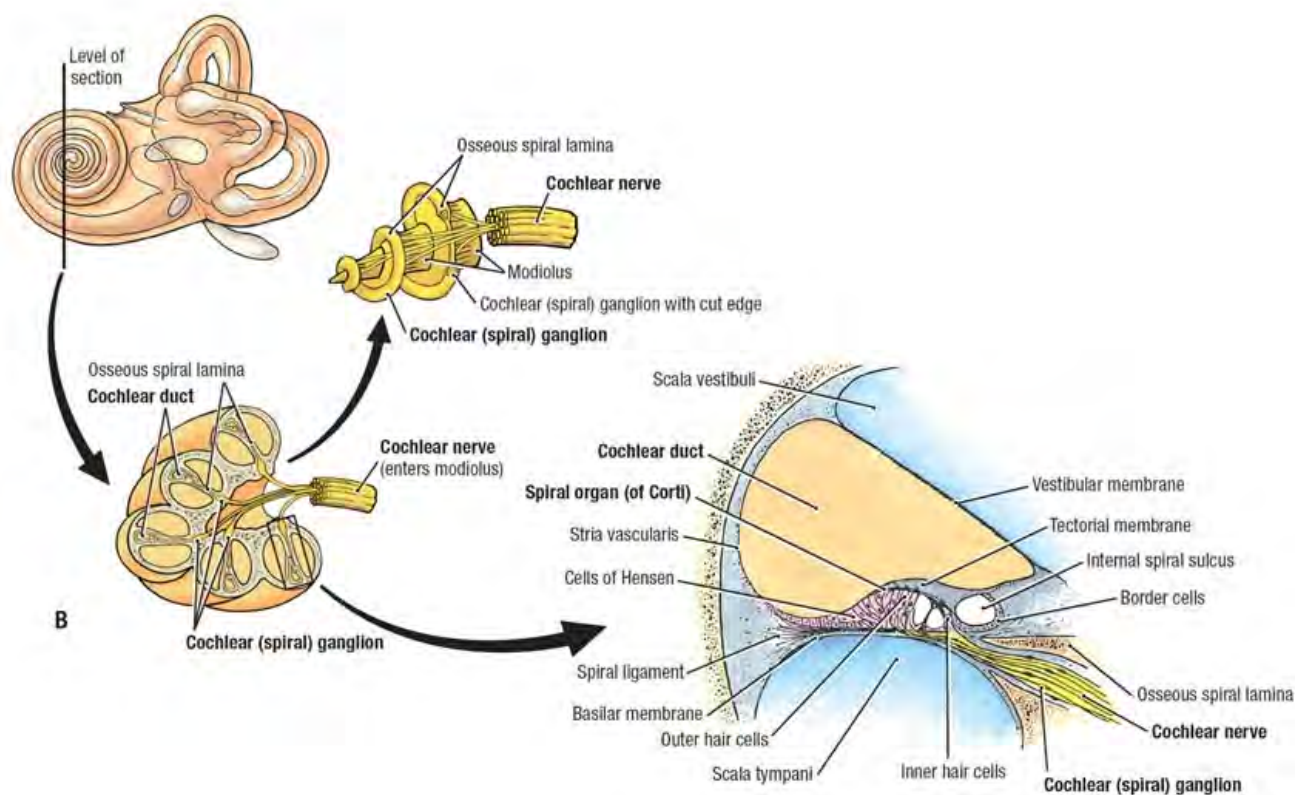
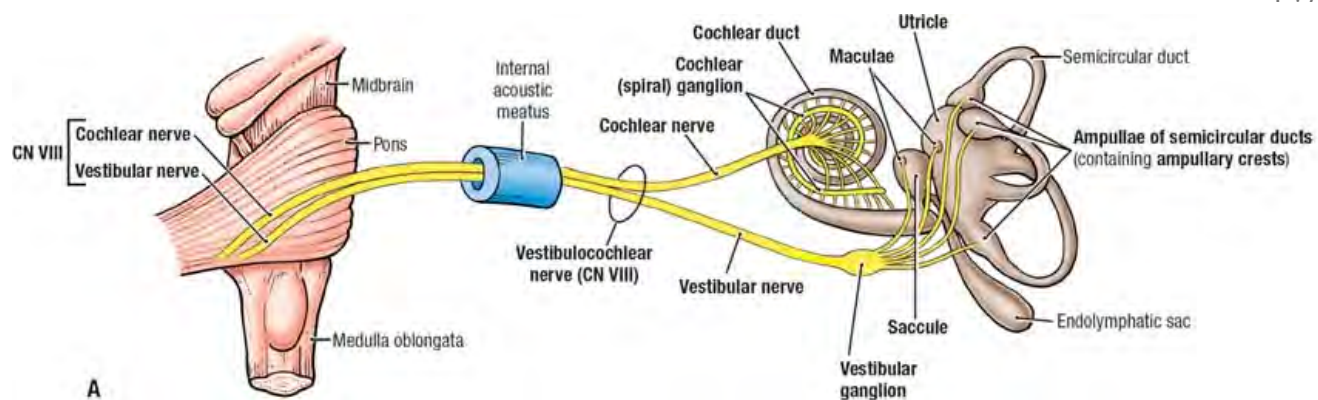
---

## 7.78 Vestibulocochlear nerve and structure of cochlea

*Part of* "Chapter 7 - Head "

A. Distribution of vestibulocochlear nerve (schematic). B. Structure of cochlea. The cochlea has been sectioned along the bony core of the cochlea (modiolus), the axis about which the cochlea winds. An isolated modiolus is shown after the turns of the cochlea are removed, leaving only the spiral lamina winding around it. The *large drawing* shows the details of the *area enclosed in the rectangle*, including a cross-section of the cochlear duct of the membranous labyrinth.

- The maculae of the membranous labyrinth are primarily static organs, which have small dense particles (otoliths) embedded among the hair cells. Under the influence of gravity, the otoliths cause bending of the hair cells, which stimulate the vestibular nerve and provide awareness of the position of the head in space; the hairs also respond to quick tilting movements and to linear acceleration and deceleration. Motion sickness results mainly from discordance between vestibular and visual stimuli.
- Persistent exposure to excessively loud sound causes degenerative changes in the spiral organ, resulting in high-tone deafness. This type of hearing loss commonly occurs in workers who are exposed to loud noises and do not wear protective earmuffs.



Authors: Agur, Anne M.R.; Dalley, Arthur F.

Title: *Grant's Atlas of Anatomy, 12th Edition*

Copyright ©2009 Lippincott Williams & Wilkins

> Table of Contents > Chapter 7 - Head > 7.79 Lymphatic and venous drainage of the head and neck

---

## 7.79 Lymphatic and venous drainage of the head and neck

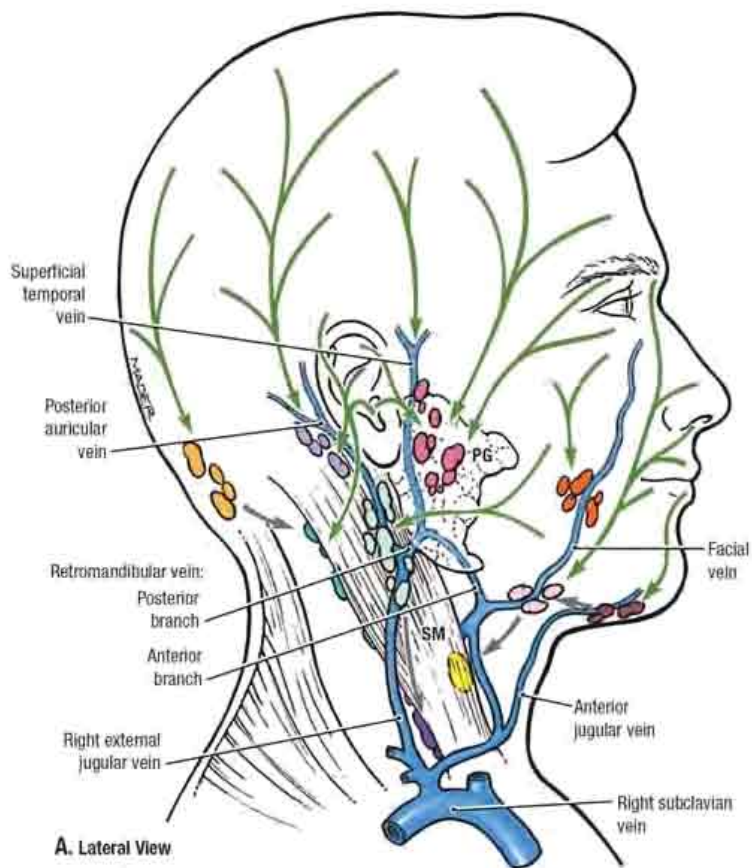
*Part of* "Chapter 7 - Head "

A. Superficial drainage. B. Drainage of the trachea, thyroid gland, larynx, and floor of mouth. C. Termination of right and left jugular lymphatic trunks. D. Deep drainage.

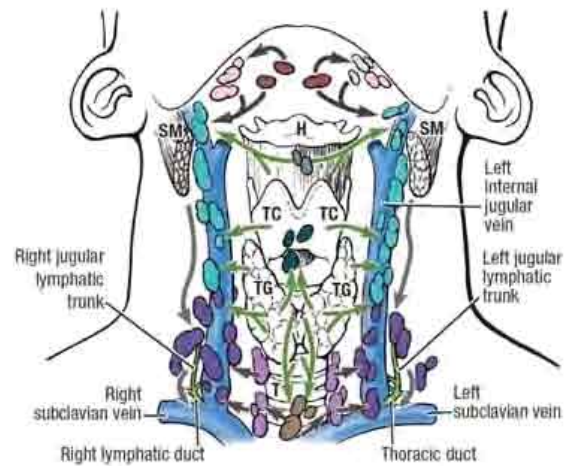
---

P.717

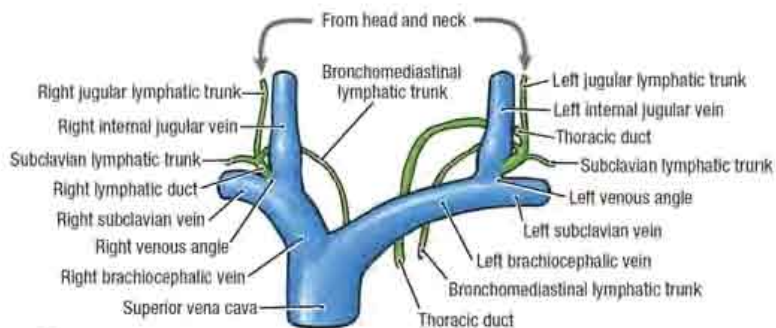




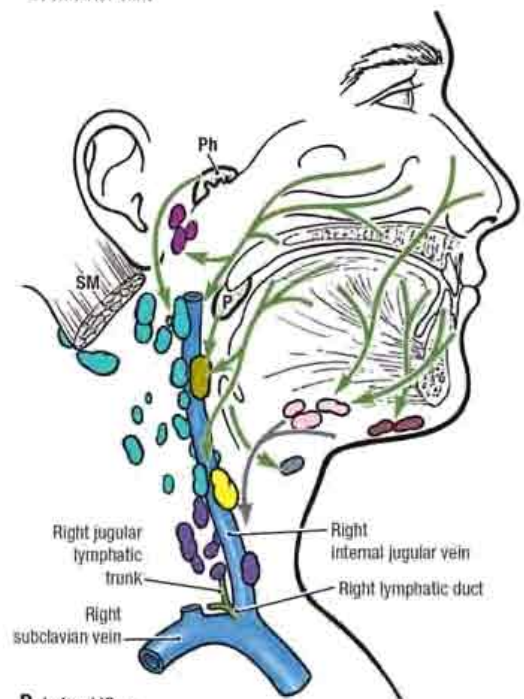
**A. Lateral View**



**B. Anterior View**



**C. Anterior View**



**D. Lateral View**

Buccinator	Paratracheal	Superficial cervical	T Trachea
Inferior deep cervical	Parotid	Superior deep cervical	TC Thyroid cartilage
Infrahyoid	Pretaryngeal	H Hyoid	TG Thyroid gland
Jugulodigastric	Pretracheal	P Palatine tonsil	
Jugulo-omohyoid	Retropharyngeal	PG Parotid gland	
Mastoid (retroauricular)	Submandibular	Ph Pharyngeal tonsil	
Occipital	Submental	SM Sternocleidomastoid	

→ Initial drainage  
→ Secondary (subsequent) drainage



**Authors:** Agur, Anne M.R.; Dalley, Arthur F.

**Title:** *Grant's Atlas of Anatomy, 12th Edition*

Copyright ©2009 Lippincott Williams & Wilkins

> Table of Contents > Chapter 7 - Head > 7.80 Autonomic innervation of the head

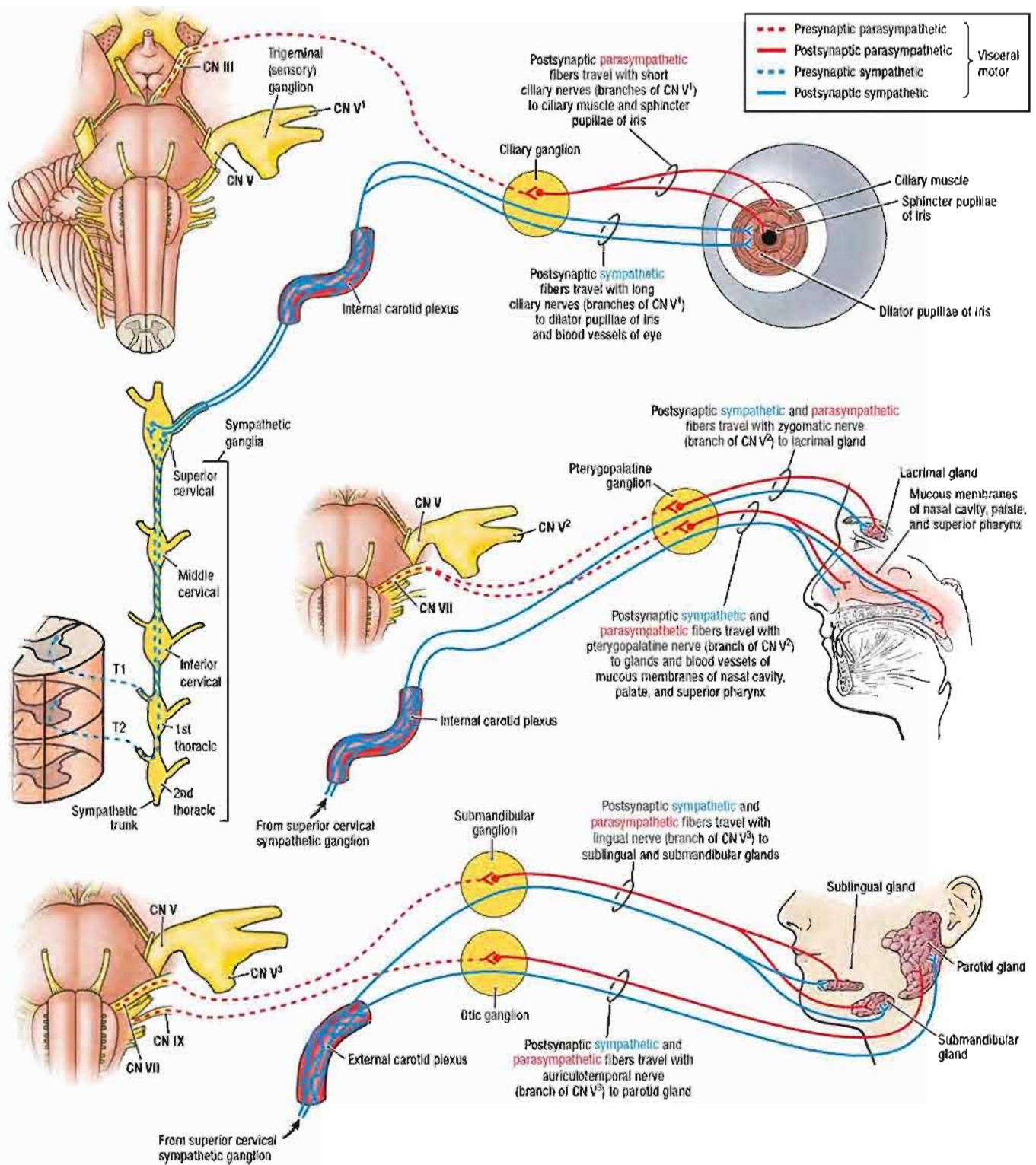
---

## 7.80 Autonomic innervation of the head

*Part of* "Chapter 7 - Head "

---

P.718



Authors: Agur, Anne M.R.; Dalley, Arthur F.  
Title: *Grant's Atlas of Anatomy, 12th Edition*  
Copyright ©2009 Lippincott Williams & Wilkins

> Table of Contents > Chapter 7 - Head > 7.81 Coronal section and MRI imaging of nasopharynx and oral cavity

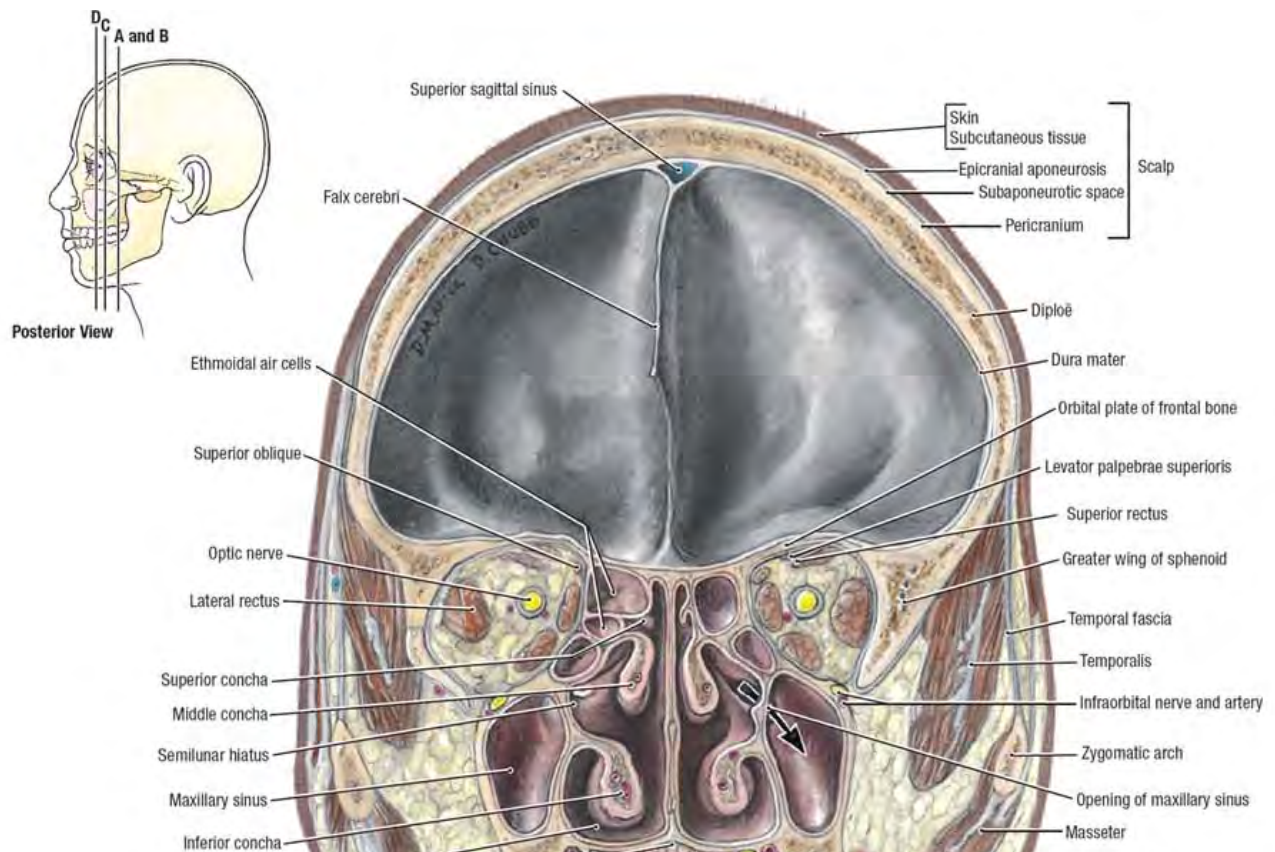
## 7.81 Coronal section and MRI imaging of nasopharynx and oral cavity

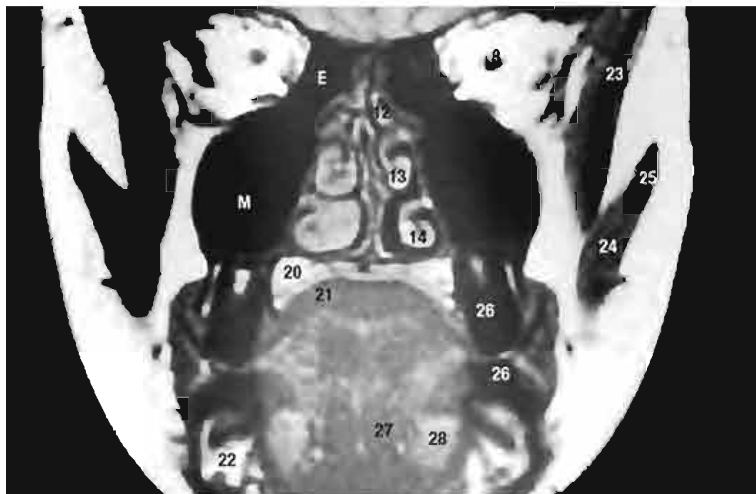
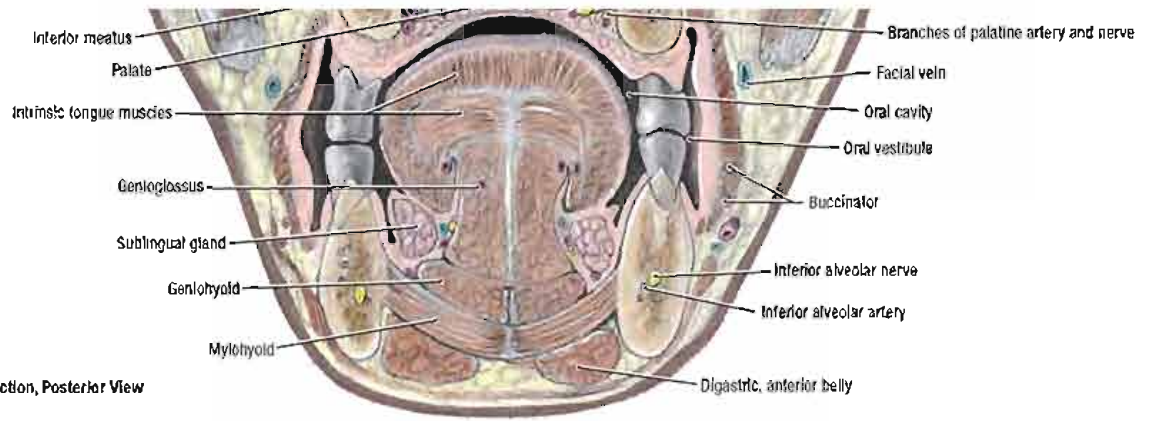
Part of "Chapter 7 - Head "

A. Coronal section. B. D. Coronal MRIs.

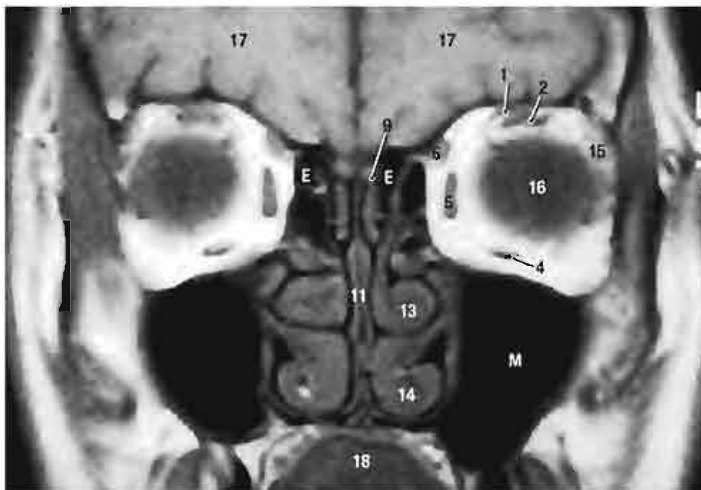
P.719

P.720

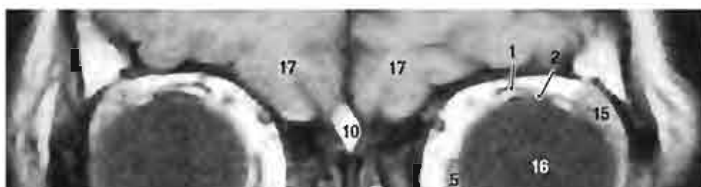




**B**



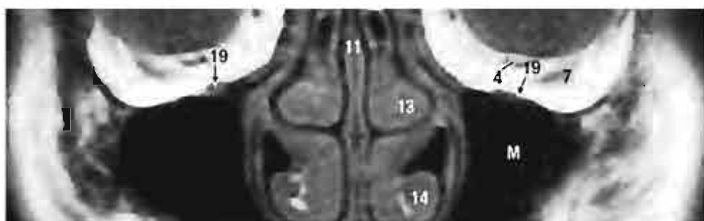**C**



- |    |                                |
|----|--------------------------------|
| 1  | Levator palpebrae superioris   |
| 2  | Superior rectus                |
| 3  | Lateral rectus                 |
| 4  | Inferior rectus                |
| 5  | Medial rectus                  |
| 6  | Superior oblique               |
| 7  | Inferior oblique               |
| 8  | Optic nerve                    |
| 9  | Olfactory bulb                 |
| 10 | Crista galli                   |
| 11 | Nasal septum                   |
| 12 | Superior concha                |
| 13 | Middle concha                  |
| 14 | Inferior concha                |
| 15 | Lacrimal gland                 |
| 16 | Eyeball                        |
| 17 | Frontal lobe                   |
| 18 | Tongue                         |
| 19 | Infraorbital vessels and nerve |
| 20 | Hard palate                    |
| 21 | Intrinsic muscles of tongue    |
| 22 | Mandible                       |
| 23 | Temporals                      |
| 24 | Masseter                       |
| 25 | Zygomatic arch                 |
| 26 | Molar teeth                    |
| 27 | Genioglossus                   |
| 28 | Sublingual gland               |
| M  | Maxillary sinus                |
| E  | Ethmoidal air cell             |



Posterior  
Views



D



Authors: Agur, Anne M.R.; Dalley, Arthur F.

Title: *Grant's Atlas of Anatomy, 12th Edition*

Copyright ©2009 Lippincott Williams & Wilkins

> Table of Contents > Chapter 7 - Head > 7.82 Transverse section and MRI imaging of nasal cavity and nasopharynx

---

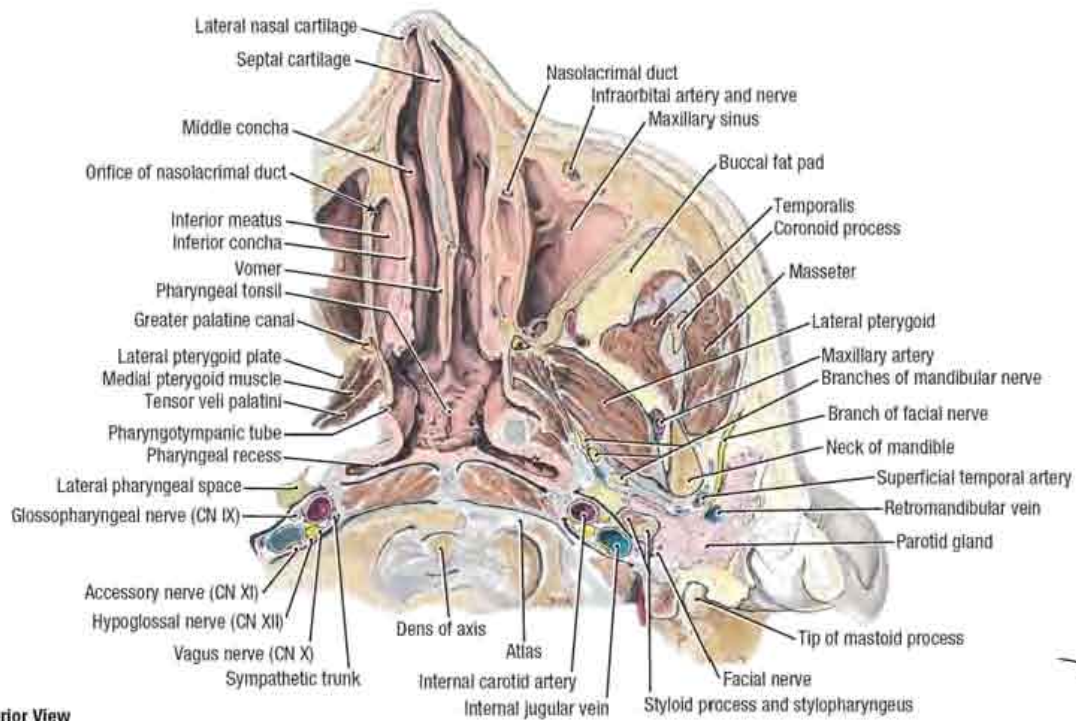
## 7.82 Transverse section and MRI imaging of nasal cavity and nasopharynx

*Part of* "Chapter 7 - Head "

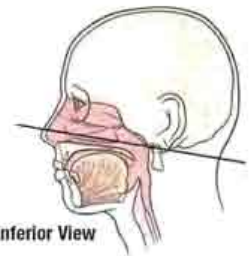
A. Transverse section of left side of head. B. Transverse (axial) MRI scan.

---

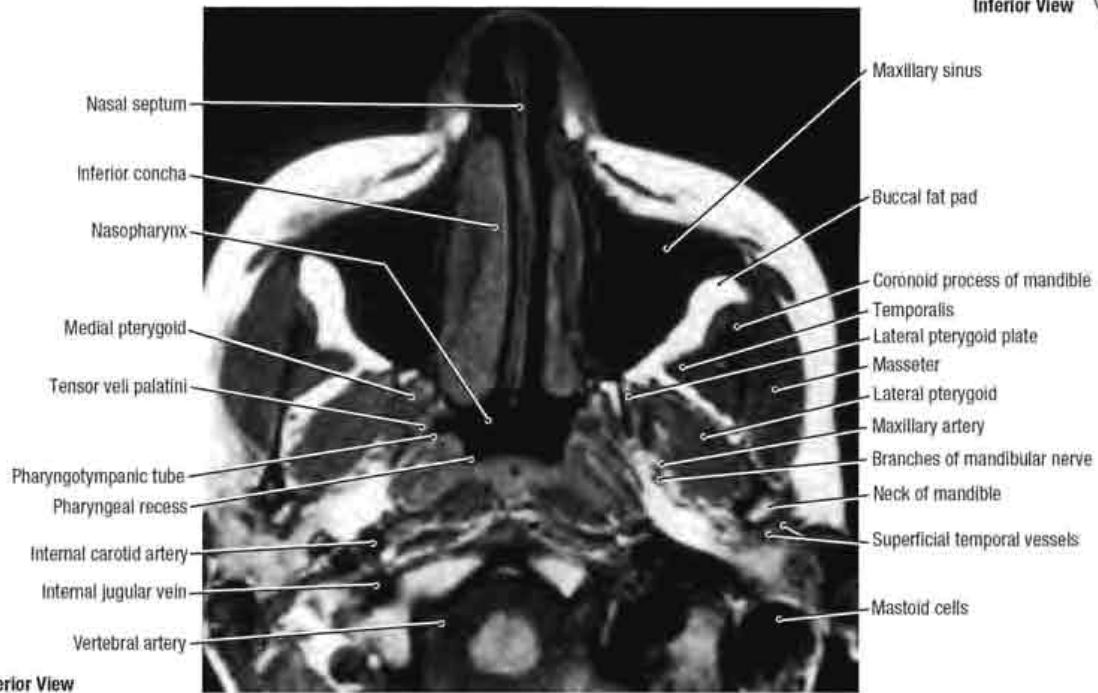
P.721



**A. Inferior View**



**Inferior View**



**B. Inferior View**

Authors: Agur, Anne M.R.; Dalley, Arthur F.

Title: *Grant's Atlas of Anatomy, 12th Edition*

Copyright ©2009 Lippincott Williams & Wilkins

> Table of Contents > Chapter 7 - Head > 7.83 MRIs of oropharynx

---

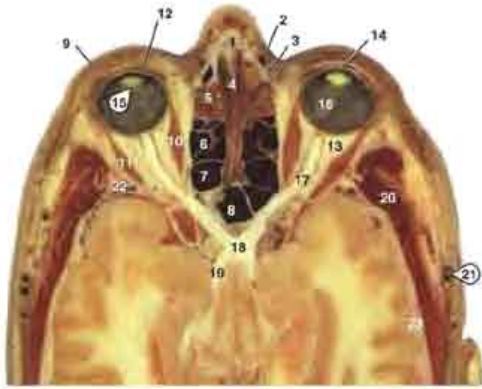
## 7.83 MRIs of oropharynx

*Part of* "Chapter 7 - Head "

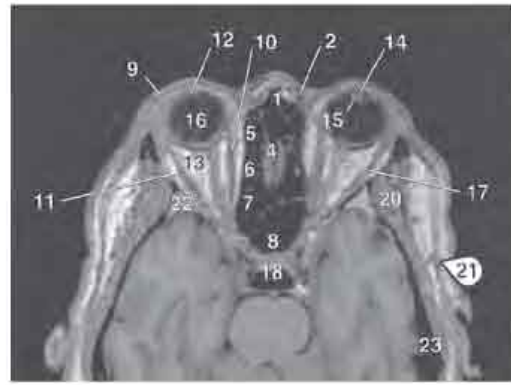
A and B. Transverse (axial) MRIs. C and D. Coronal MRIs. E. Sagittal MRI

---

P.722



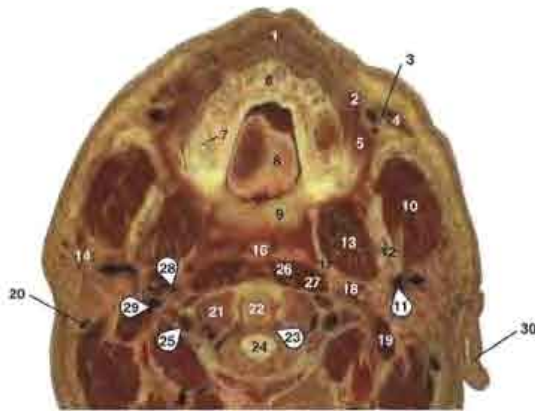
**A. Transverse Section**



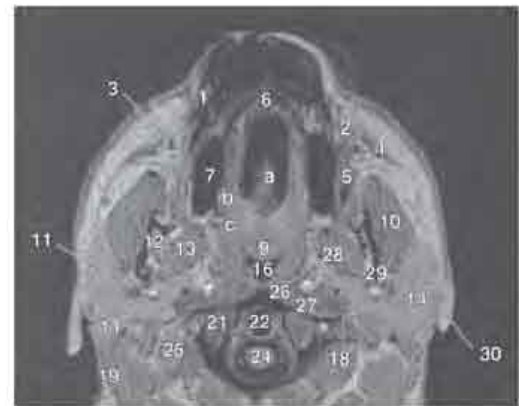
**B. Transverse (axial) MRI Scan**

**Key**

1 Nasal bones	7 Posterior ethmoidal air cell	13 Retrobulbar fat	19 Optic tract
2 Angular artery	8 Sphenoid sinus	14 Anterior chamber	20 Temporalis muscle
3 Frontal process of maxilla	9 Orbicularis oculi muscle	15 Lens	21 Superficial temporal vessels
4 Nasal septum	10 Medial rectus muscle	16 Vitreous body	22 Greater wing of sphenoid
5 Anterior ethmoidal cell	11 Lateral rectus muscle	17 Optic nerve	23 Squamous portion of temporal bone
6 Middle ethmoidal cell	12 Cornea	18 Optic chiasm	



**C. Transverse Section**



**D. Transverse (axial) MRI Scan**

**Key**

1 Orbicularis oris muscle	12 Ramus of mandible	23 Transverse ligament of Atlas
2 Levator anguli oris muscle	13 Lateral pterygoid muscle	24 Spinal cord
3 Facial artery and vein	14 Parotid gland	25 Vertebral artery in foramina transversaria
4 Zygomaticus major muscle	15 Superficial temporal vessels	26 Longus colli muscle
5 Buccinator muscle	16 Region of pharyngeal tubercle	27 Longus capitis muscle
6 Maxilla	17 Sphenoid bone	28 Internal carotid artery
7 Alveolar process of maxilla	18 Stylohyoid ligament and muscle	29 Internal jugular vein
8 Dorsum of the tongue	19 Posterior belly of digastric muscle	30 Interior portion of helix of auricle
9 Soft palate (uvula apparent in radiographs)	20 Occipital artery	a Hard palate
10 Masseter muscle	21 First cervical vertebrae (Atlas)	b Palatoglossus muscle
11 Retromandibular vein	22 Dens (Axis)	c Palatopharyngeus muscle

## 7.84 Brain

Part of "Chapter 7 - Head "

A. Cerebrum, cerebellum, and brainstem, lateral aspect. B. Lobes of the cerebral hemispheres, lateral aspect. C. Lobes of the cerebral hemispheres, superior aspect.

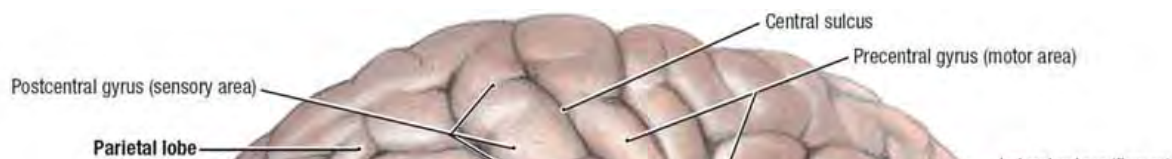Cerebral contusion (bruising) results from brain trauma in which the pia is stripped from the injured surface of the brain and may be torn, allowing blood to enter the subarachnoid space. The bruising results from the sudden impact of the moving brain against the stationary cranium or from the suddenly moving cranium against the stationary brain. Cerebral contusion may result in an extended loss of consciousness

P.723

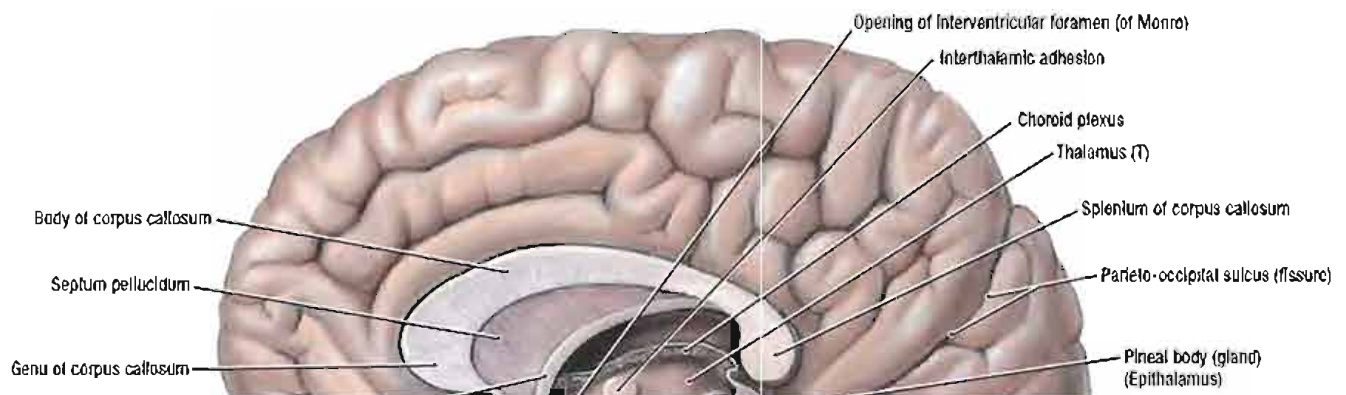
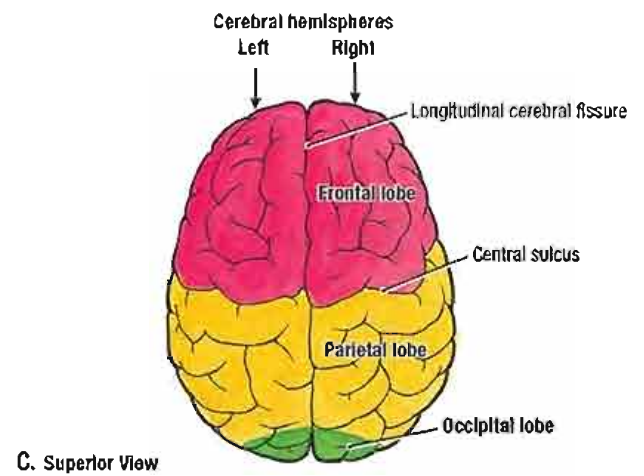
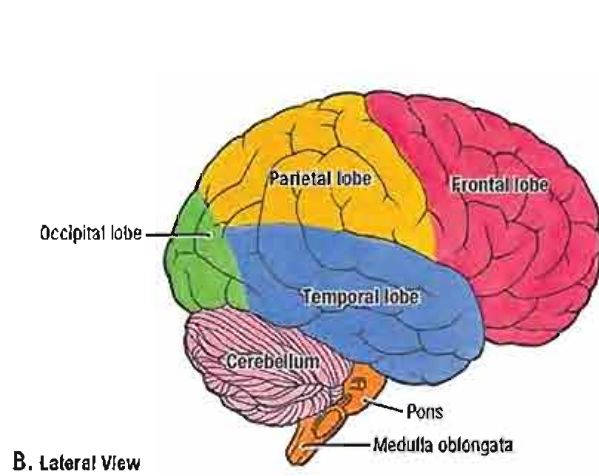
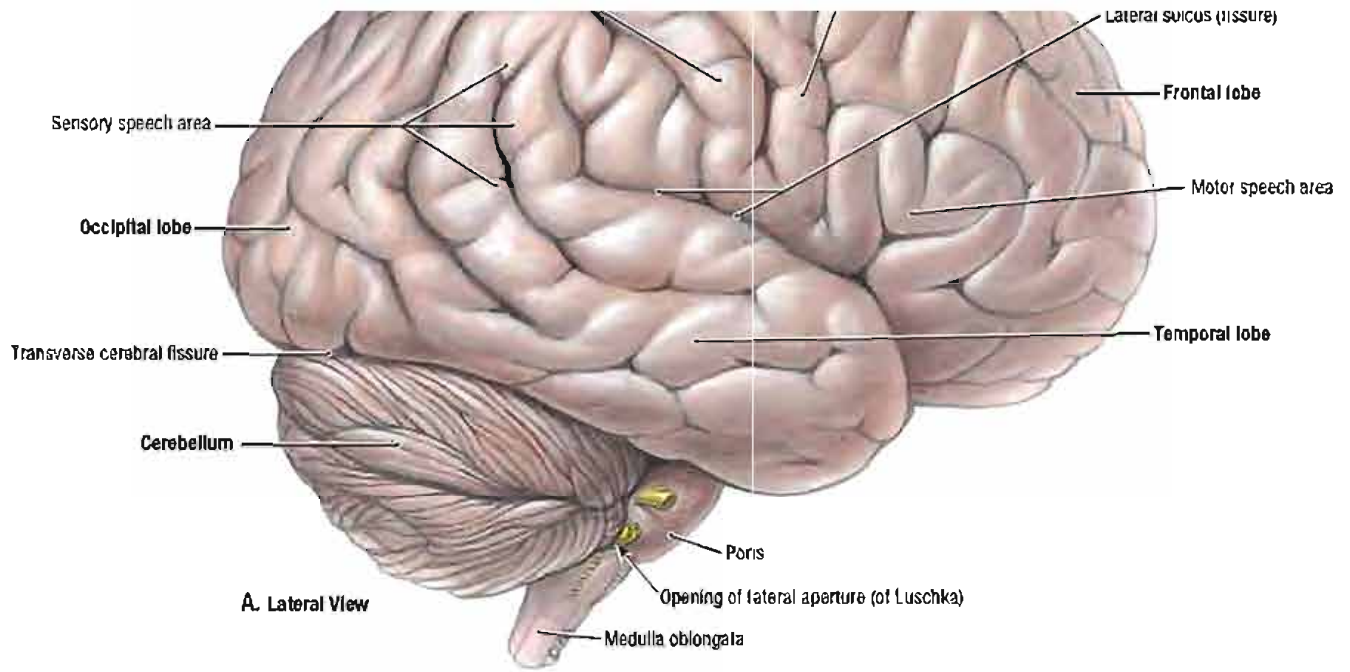
D. Cerebrum, cerebellum, and brainstem, median section. E. Parts of the brain, median section. F. Lobes of the cerebral hemisphere, median section. See D for labeling key.

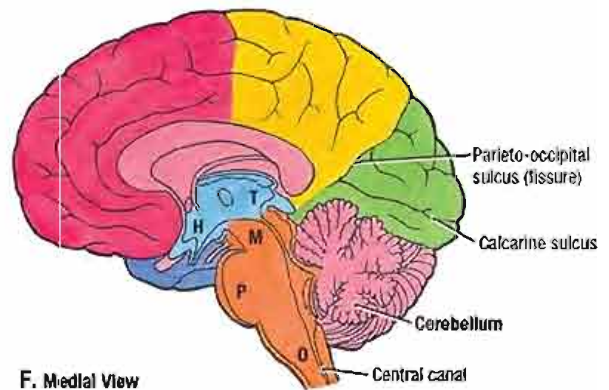
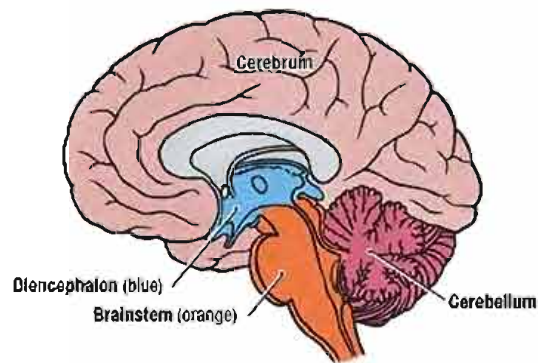
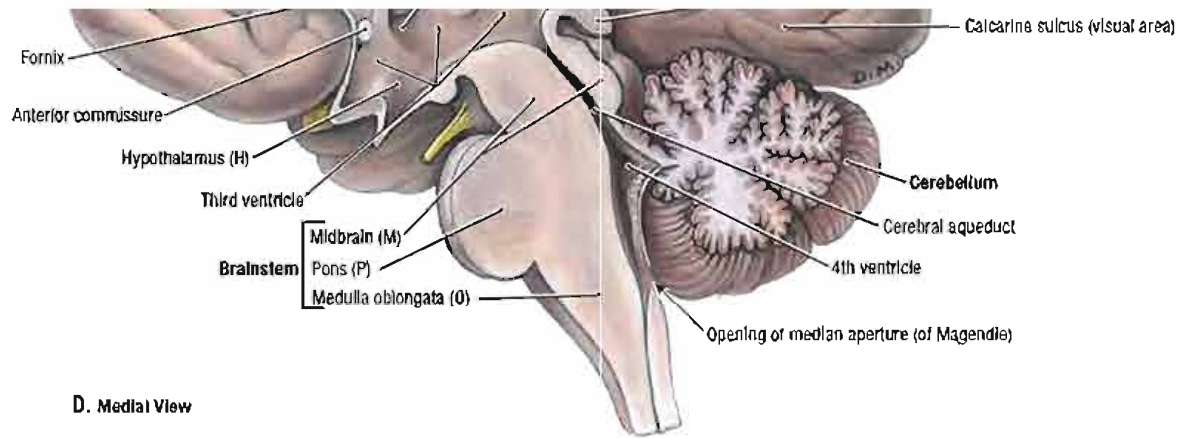
Cerebral compression may be produced by intracranial collections of blood, obstruction of CSF circulation or absorption, intracranial tumors or abscesses, and brain swelling caused by brain edema, an increase in brain volume resulting from an increase in water and sodium content.

P.724









Authors: Agur, Anne M.R.; Dalley, Arthur F.

Title: *Grant's Atlas of Anatomy, 12th Edition*

Copyright ©2009 Lippincott Williams & Wilkins

> Table of Contents > Chapter 7 - Head > 7.85 Ventricular system

---

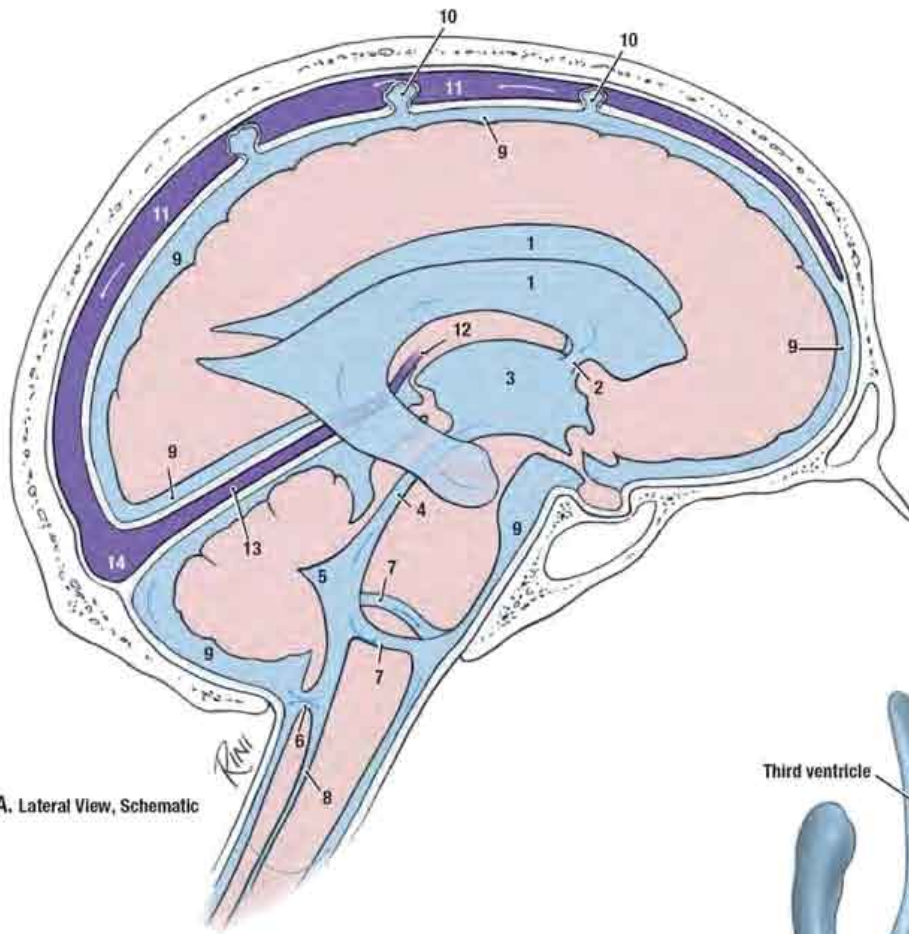
## 7.85 Ventricular system

*Part of* "Chapter 7 - Head "

A. Circulation of cerebrospinal fluid (CSF). B. Ventricles: lateral, third, and fourth.

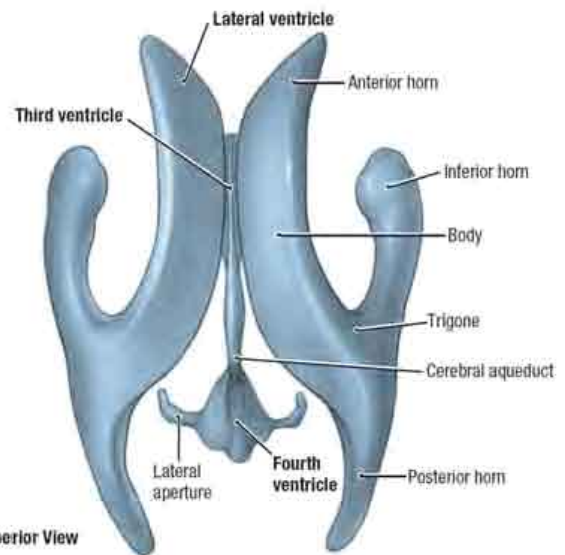
- The ventricular system consists of two lateral ventricles located in the cerebral hemispheres, a third ventricle located between the right and left halves of the diencephalon, and a fourth ventricle located in the posterior parts of the pons and medulla.
- CSF secreted by choroid plexus in the ventricles drains via the interventricular foramen from the lateral to the third ventricle, via the cerebral aqueduct from the third to the fourth ventricle, and via median and lateral apertures into the subarachnoid space. CSF is absorbed by arachnoid granulations into the venous sinuses (especially the superior sagittal sinus).

- Overproduction of CSF, obstruction of its flow, or interference with its absorption results in an excess of CSF in the ventricles and enlargement of the head, a condition known as hydrocephalus. Excess CSF dilates the ventricles; thins the brain; and, in infants, separates the bones of the calvaria because the sutures and fontanelles are still open.



A. Lateral View, Schematic

- 1 Right and left lateral ventricles
- 2 Interventricular foramen
- 3 Third ventricle
- 4 Cerebral aqueduct
- 5 Fourth ventricle
- 6 Median aperture
- 7 Lateral apertures
- 8 Central canal
- 9 Subarachnoid space
- 10 Arachnoid granulations
- 11 Superior sagittal sinus
- 12 Great cerebral vein
- 13 Straight sinus
- 14 Confluence of sinuses



B. Superior View

**Authors:** Agur, Anne M.R.; Dalley, Arthur F.

**Title:** *Grant's Atlas of Anatomy, 12th Edition*

Copyright ©2009 Lippincott Williams & Wilkins

> Table of Contents > Chapter 7 - Head > 7.86 Serial dissections of the lateral aspect of the cerebral hemisphere

---

## 7.86 Serial dissections of the lateral aspect of the cerebral hemisphere

*Part of "Chapter 7 - Head "*

The dissections begin from the lateral surface of the cerebral hemisphere (A) and proceed sequentially medially (B–F) .

A. Sulci and gyri of the lateral surface of one cerebral hemisphere. Each gyrus is a fold of cerebral cortex with a core of white matter. The furrows are called *sulci*. The pattern of sulci and gyri formed shortly before birth is recognizable in some adult brains, as shown in this specimen. Usually the expanding cortex acquires secondary foldings, which make identification of this basic pattern more difficult. B. Superior longitudinal fasciculus, transverse temporal gyri, and insula. The cortex and short association fiber bundles around the lateral fissure have been removed.

---

P.726

C. Uncinate and inferior fronto-occipital fasciculi and external capsule. The external capsule consists of projection fibers that pass between the claustrum laterally and the lentiform nucleus medially. D. Lentiform nucleus and corona radiata. The inferior longitudinal and uncinate fasciculi, claustrum, and external capsule have been removed. The fibers of the optic radiations convey impulses from the right half of the retina of each eye; the fibers extending closest to the temporal pole (Meyer's loop) carry impulses from the lower portion of each retina.

---

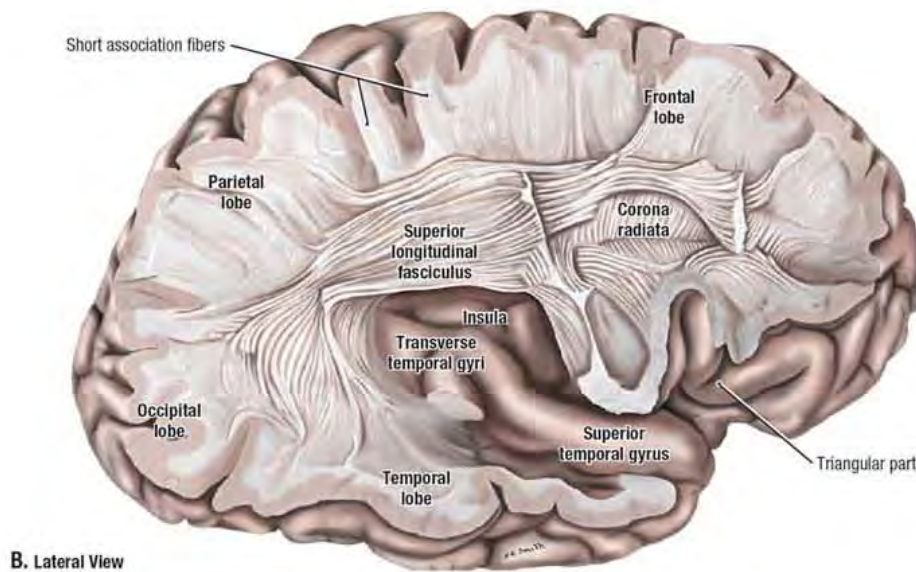
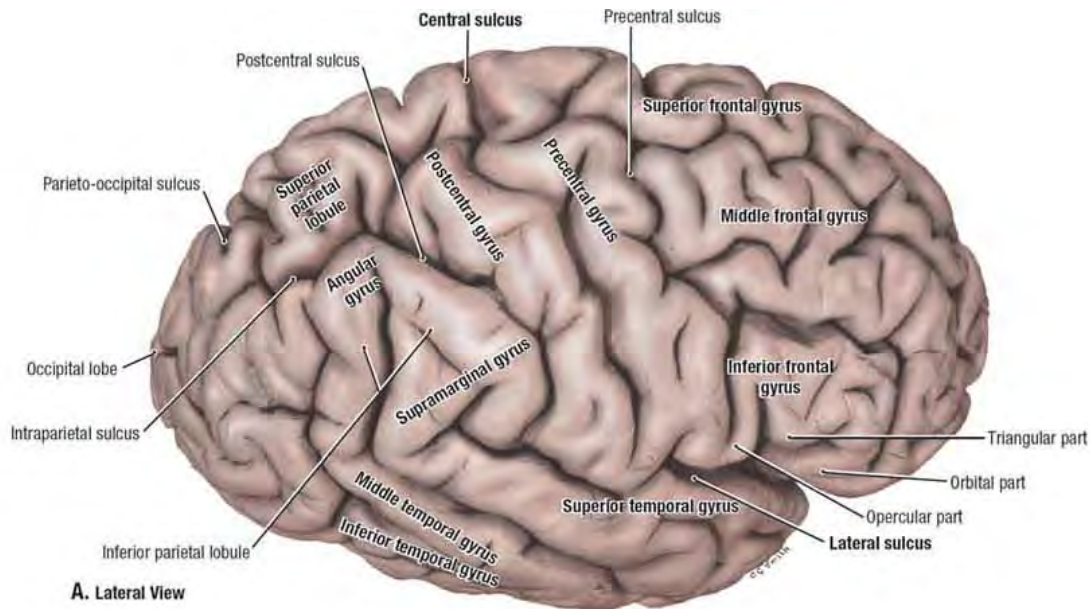
P.727

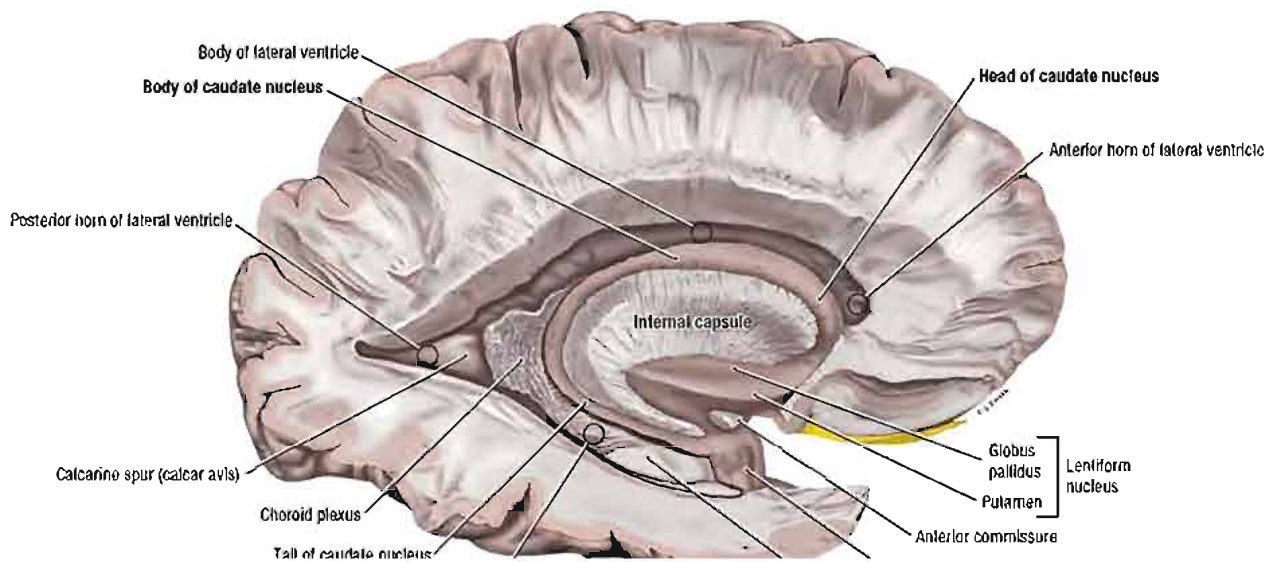
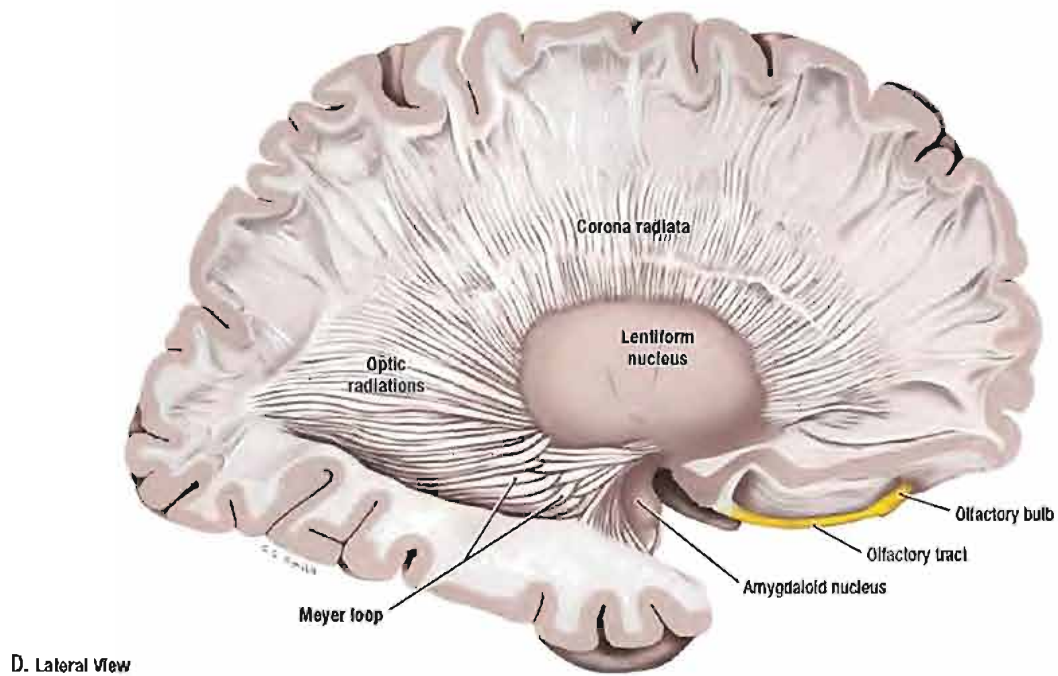
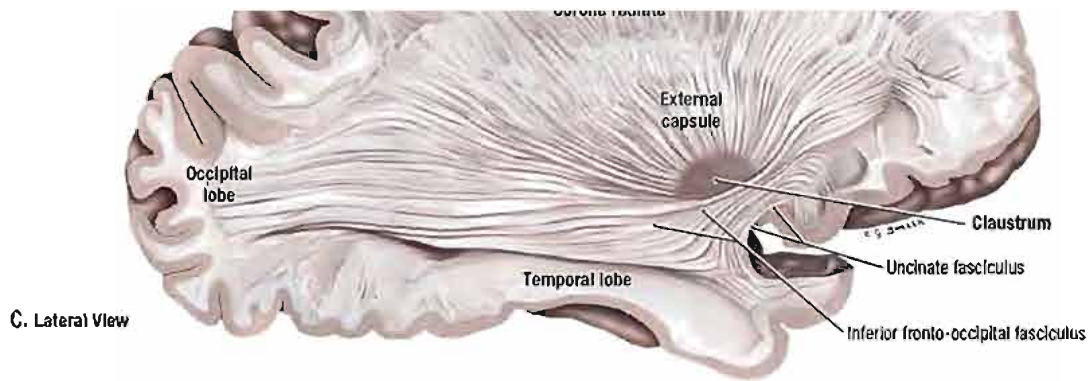
E. Caudate and amygdaloid nuclei and internal capsule. The lateral wall of the lateral



ventricle, the marginal part of the internal capsule, the anterior commissure, and the superior part of the lentiform nucleus have been removed. F. Lateral ventricle, hippocampus, and diencephalon. The inferior parts of the lentiform nucleus, internal capsule, and caudate nucleus have been removed.

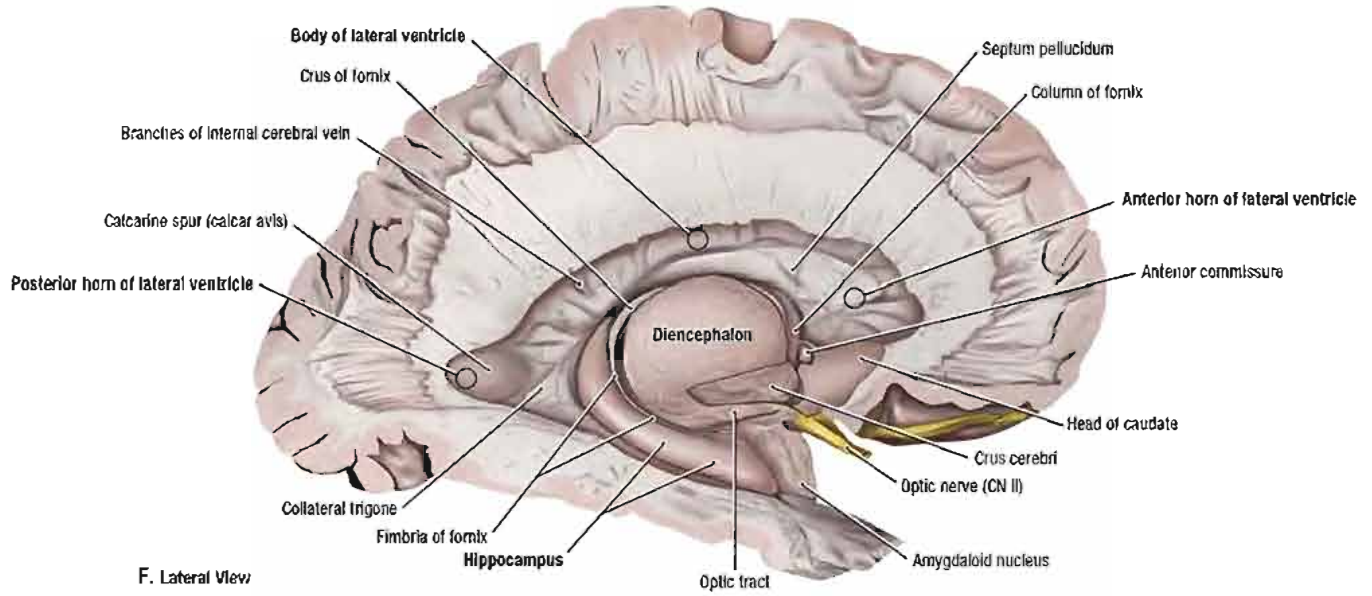
P.728





E. Lateral View

Inferior horn of lateral ventricle  
Amygdaloid nucleus  
Hippocampus





Authors: Agur, Anne M.R.; Dalley, Arthur F.

Title: *Grant's Atlas of Anatomy, 12th Edition*

Copyright ©2009 Lippincott Williams & Wilkins

> Table of Contents > Chapter 7 - Head > 7.87 Serial dissections of the medial aspect of cerebral hemisphere

---

## 7.87 Serial dissections of the medial aspect of cerebral hemisphere

*Part of "Chapter 7 - Head "*

The dissections begin from the medial surface of the cerebral hemisphere (A) and proceed sequentially laterally (B–D) .

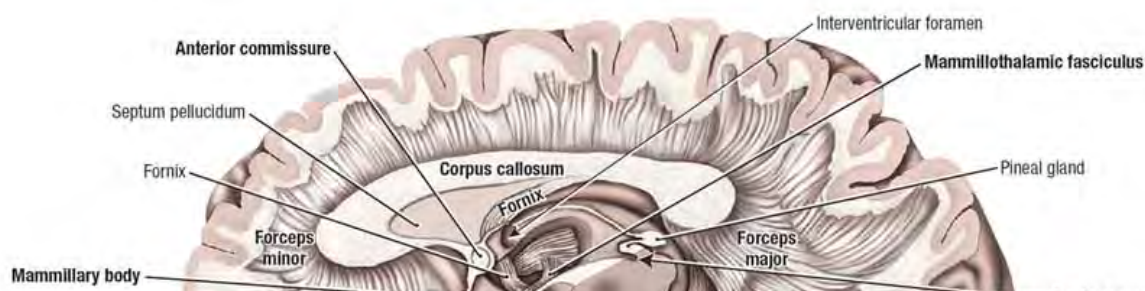
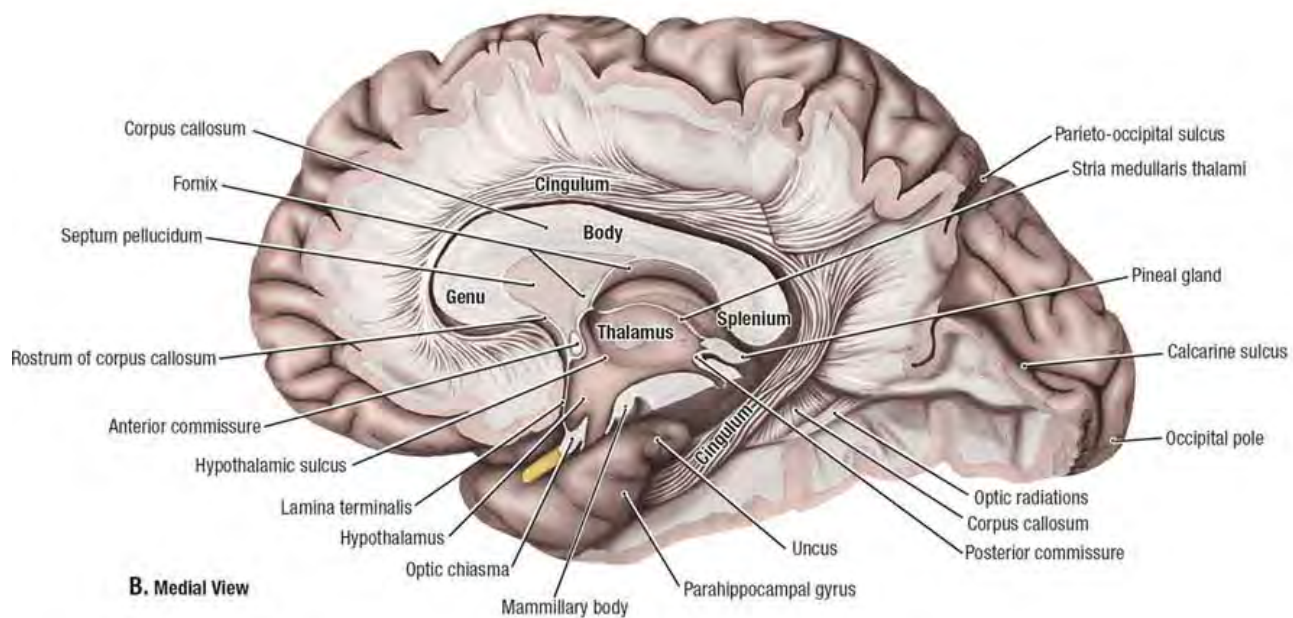
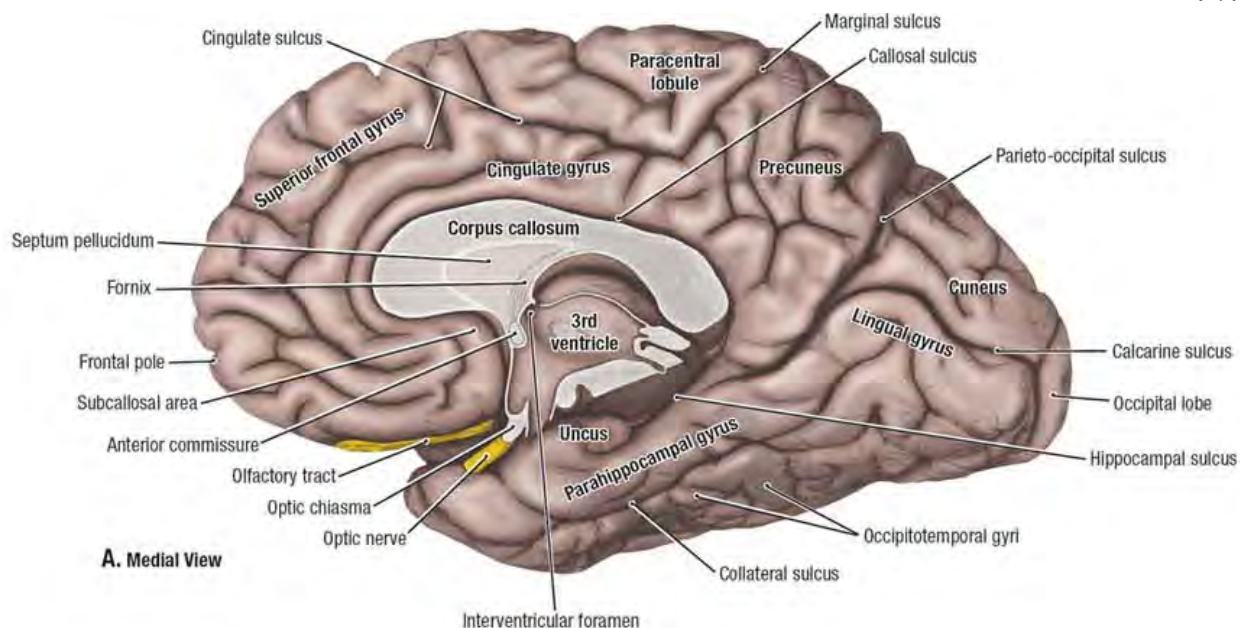
A. Sulci and gyri of medial surface of cerebral hemisphere. The corpus callosum consists of the rostrum, genu, body, and splenium; the cingulate and parahippocampal gyri from the limbic lobe. B. Cingulum. The cortex and short association fibers were removed from the medial aspect of the hemisphere. The cingulum is a long association fiber bundle that lies in the core of the cingulate and parahippocampal gyri.

---

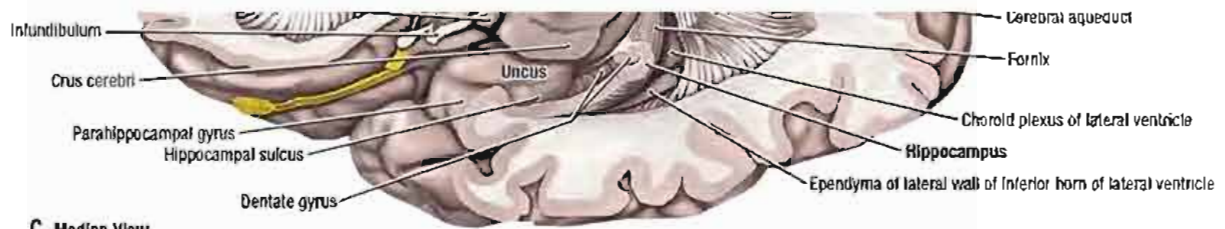
P.729

C. Fornix, mamillothalamic fasciculus, and forceps major and minor. The cingulum and a portion of the wall of the third ventricle have been removed. The fornix begins at the hippocampus and terminates in the mammillary body by passing anterior to the interventricular foramen and posterior to the anterior commissure. The mamillothalamic fasciculus emerges from the mammillary body and terminates in the anterior nucleus of the thalamus. D. Caudate nucleus and internal capsule. The diencephalon was removed, along with the ependyma of the lateral ventricle, except where it covers the caudate and amygdaloid nuclei. E. Corpus callosum. The body of the corpus callosum connects the two cerebral hemispheres; the minor (frontal) forceps (at the genu of corpus callosum) connects the frontal lobes, and the major (occipital) forceps (at splenium) connects the occipital lobes.

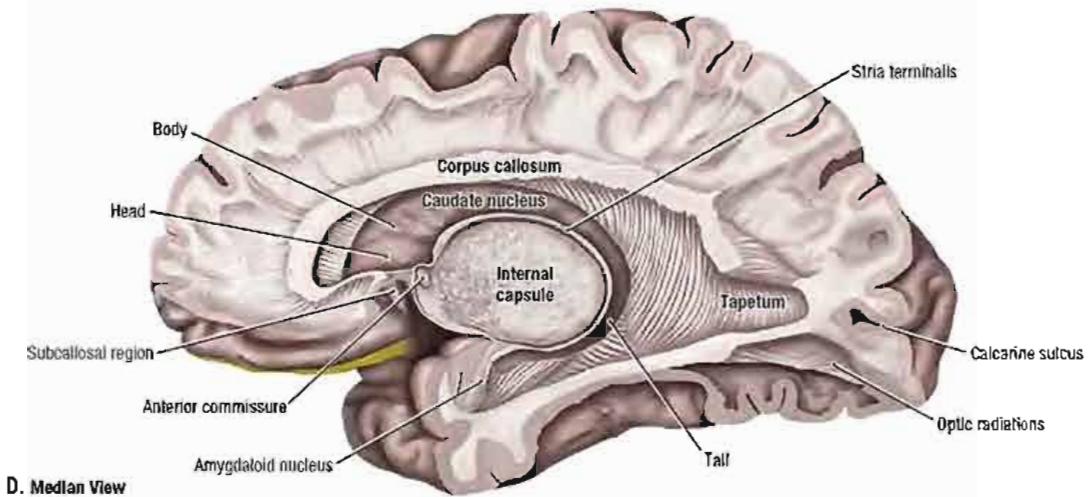
---



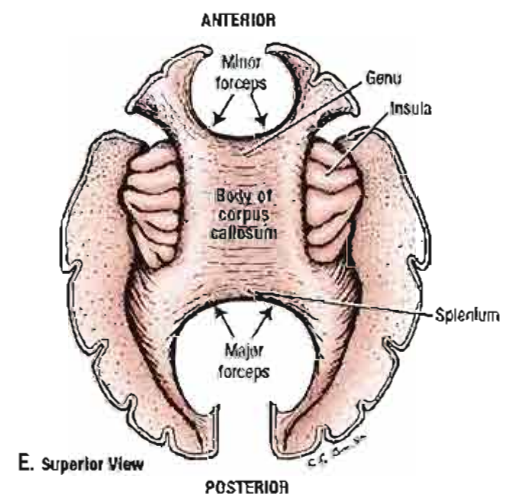




C. Medial View



D. Medial View



E. Superior View

Authors: Agur, Anne M.R.; Dalley, Arthur F.

Title: *Grant's Atlas of Anatomy, 12th Edition*

Copyright ©2009 Lippincott Williams & Wilkins

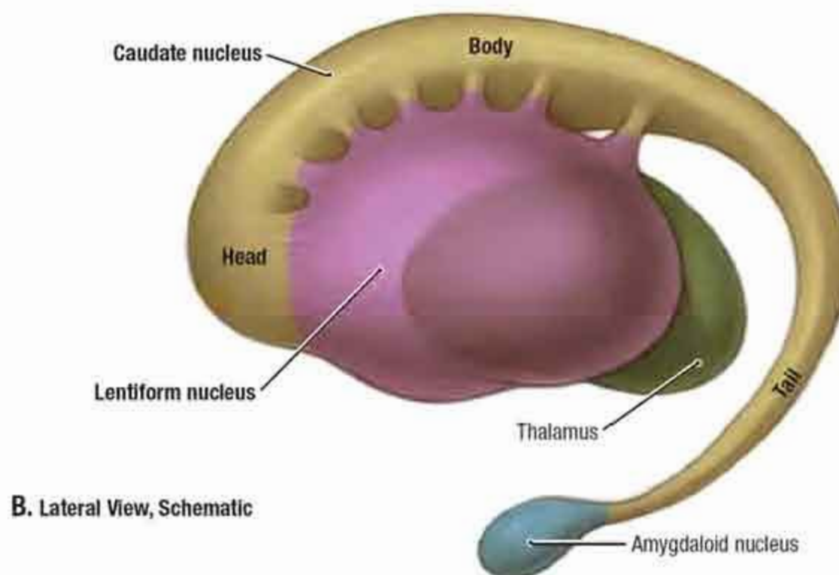
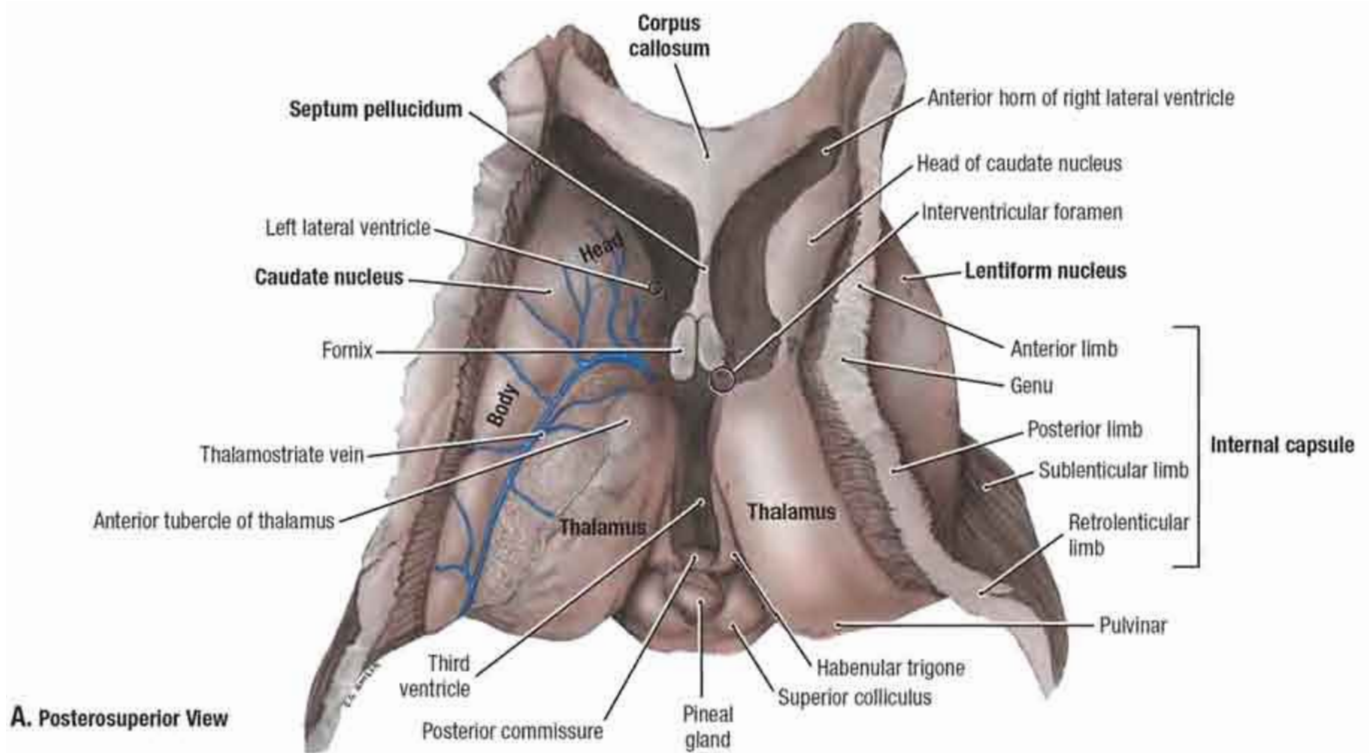
> Table of Contents > Chapter 7 - Head > 7.88 Caudate and lentiform nuclei

---

## 7.88 Caudate and lentiform nuclei

*Part of "Chapter 7 - Head "*

A. Relationship to the lateral ventricles and internal capsule. The dorsal surface of the diencephalon has been exposed by dissecting away the two cerebral hemispheres, except the anterior part of the corpus callosum, the inferior part of the septum pellucidum, the internal capsule, and the caudate and lentiform nuclei. On the right side of the specimen, the thalamus, caudate, and lentiform nuclei have been cut horizontally at the level of the interventricular foramen. The parts of the internal capsule include the anterior, posterior, retrolenticular sublenticular limbs, and genu. B. Schematic illustration of nuclei.



Authors: Agur, Anne M.R.; Dalley, Arthur F.

Title: *Grant's Atlas of Anatomy, 12th Edition*

Copyright ©2009 Lippincott Williams & Wilkins

> Table of Contents > Chapter 7 - Head > 7.89 Axial sections through the thalamus, caudate nucleus, and lentiform nucleus

---

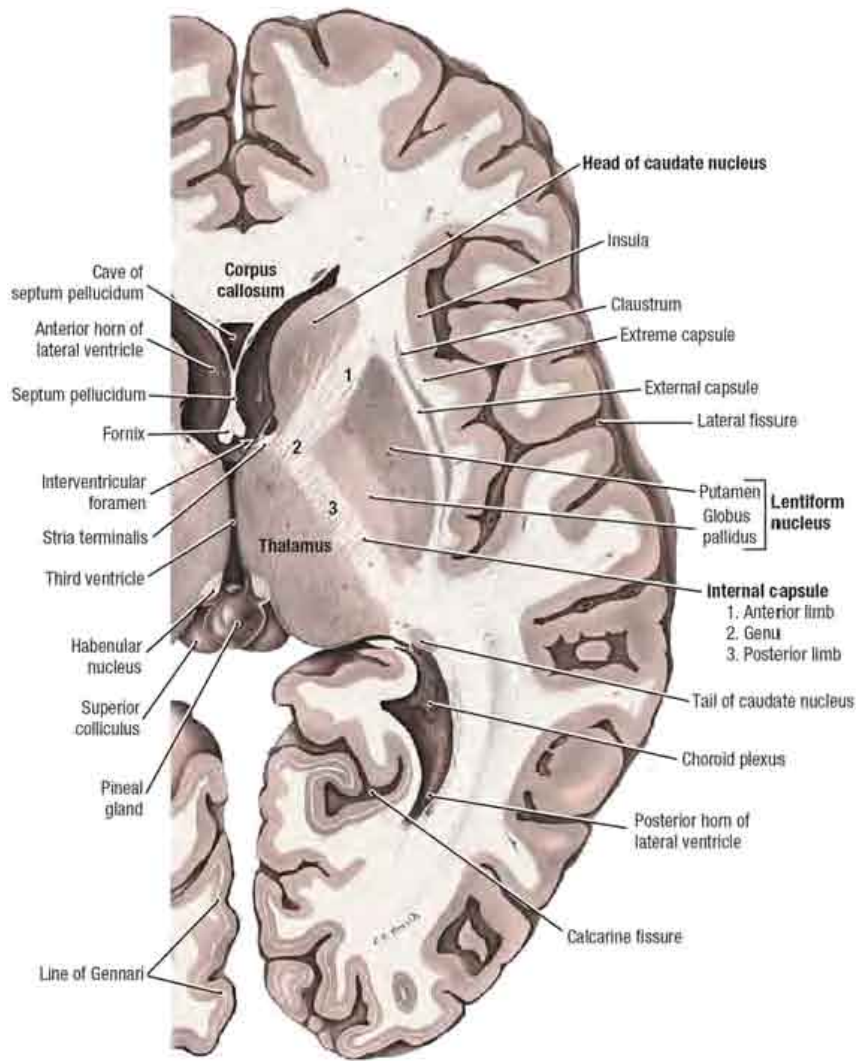
## 7.89 Axial sections through the thalamus, caudate nucleus, and lentiform nucleus

*Part of* "Chapter 7 - Head "

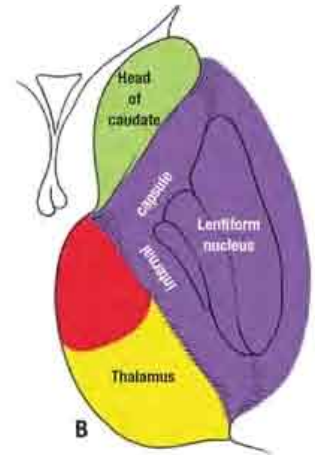
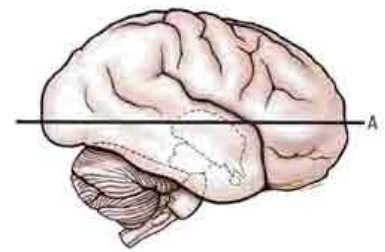
A. Relationships of the internal capsule. B. Blood supply of region.

---

P.732



A. Transverse Section



<span style="color: green;">■</span>	Anteromedial central arteries
<span style="color: purple;">■</span>	Anterolateral striate (lenticulostriate) arteries
<span style="color: red;">■</span>	Posteromedial central (thalamoperforating) arteries
<span style="color: yellow;">■</span>	Posterolateral central (thalamogeniculate) arteries



Authors: Agur, Anne M.R.; Dalley, Arthur F.

Title: *Grant's Atlas of Anatomy, 12th Edition*

Copyright ©2009 Lippincott Williams & Wilkins

> Table of Contents > Chapter 7 - Head > 7.90 Axial (transverse) MRIs through the cerebral hemispheres

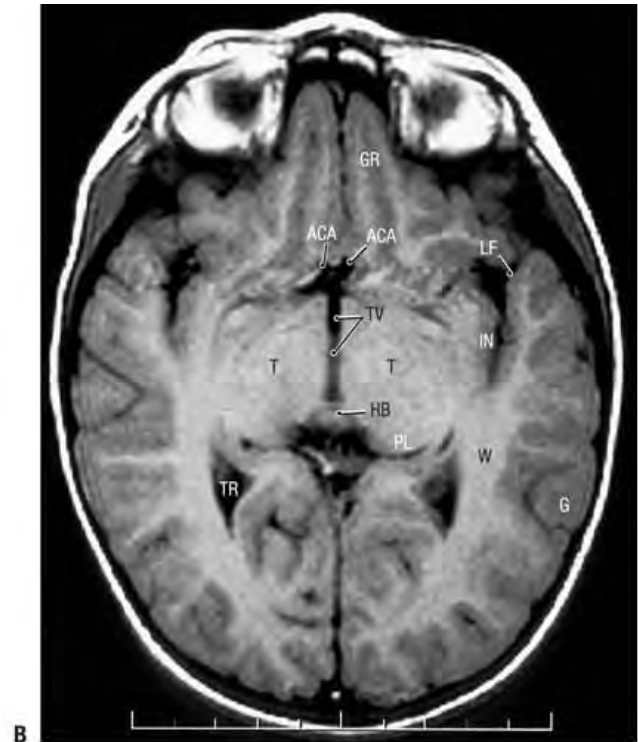
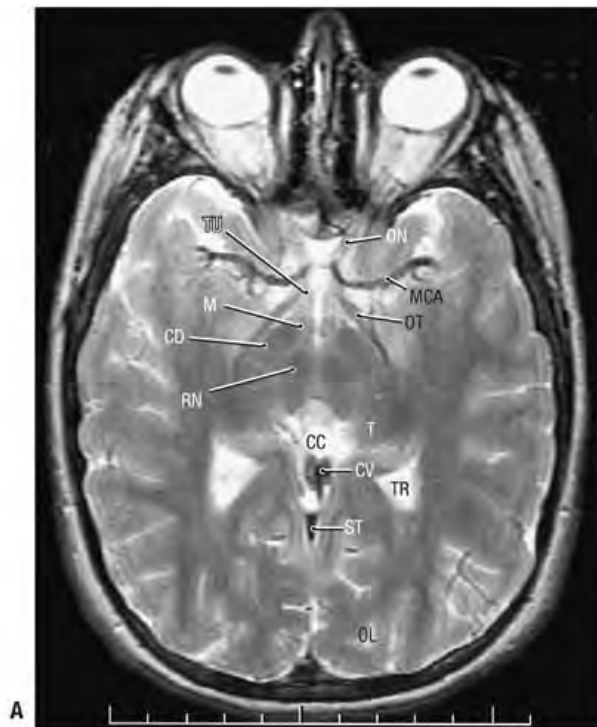
## 7.90 Axial (transverse) MRIs through the cerebral hemispheres

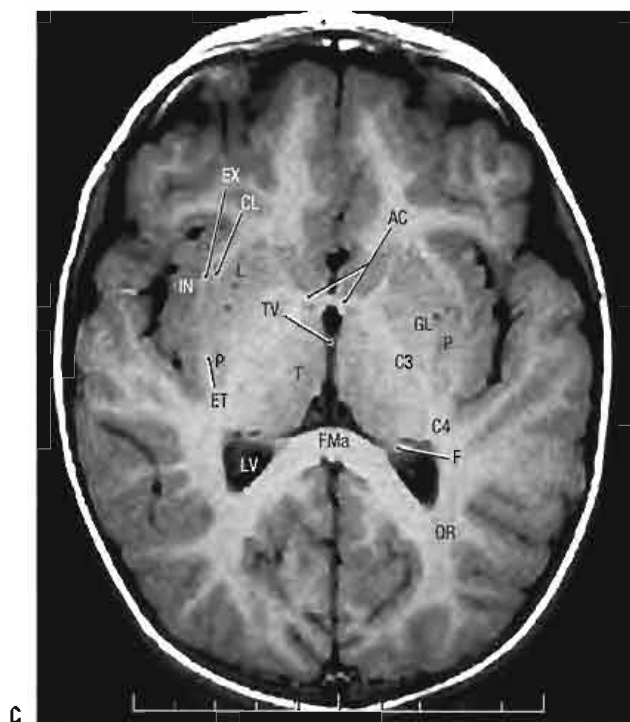*Part of "Chapter 7 - Head"*

See orientation drawing for sites of scans A–F. A is T2 weighted, and B–F are T1 weighted.

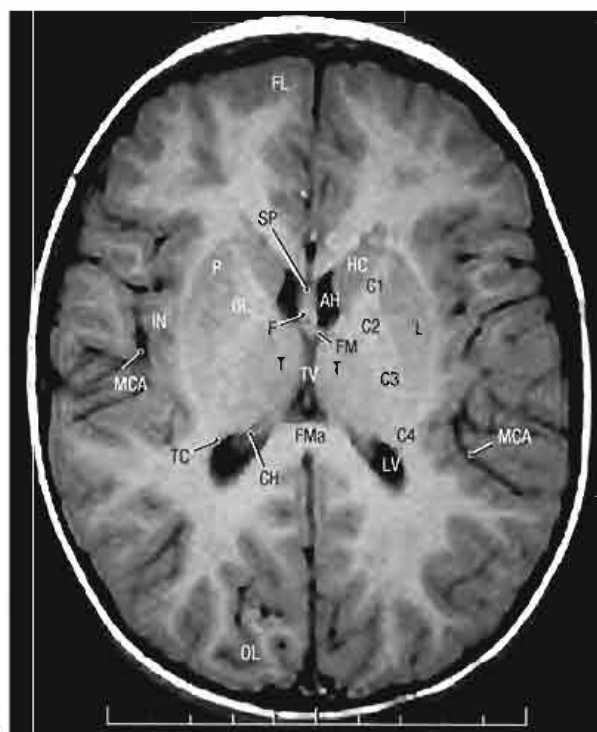
P.733

P.734

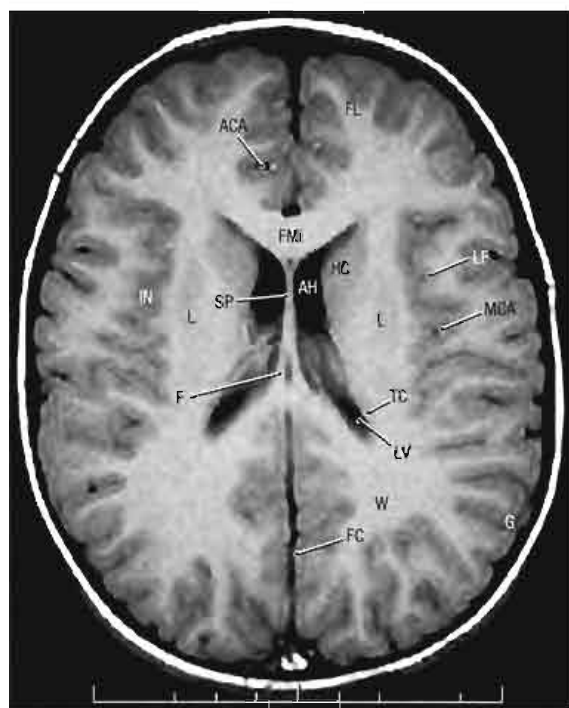



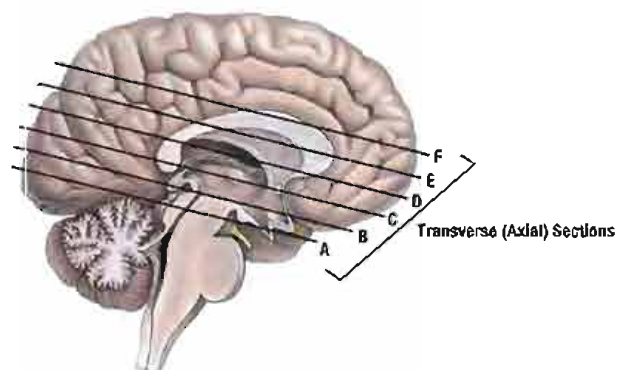
C



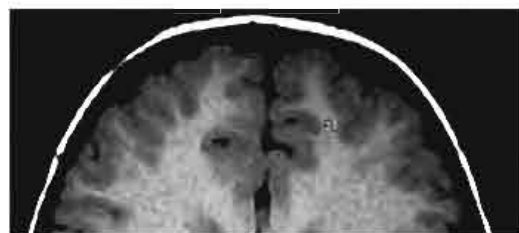D



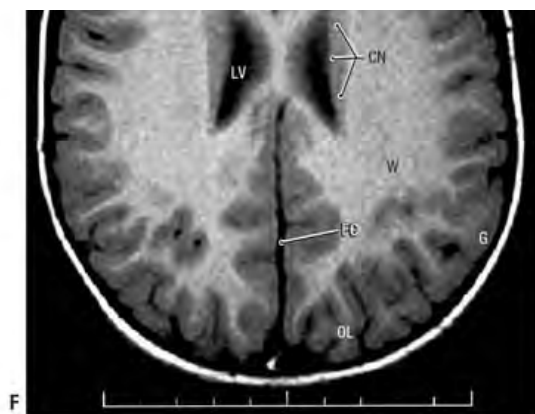
E



Transverse (Axial) Sections



AC	Anterior commissure	GL	Globus pallidus
ACA	Anterior cerebral artery	GR	Gyrus rectus
AH	Anterior horn of lateral ventricle	HB	Habenular commissure
C1	Anterior limb of internal capsule	HC	Head of caudate nucleus
C2	Genu of internal capsule	IN	Insular cortex
C3	Posterior limb of internal capsule	L	Lentiform nucleus
		LF	Lateral fissure



	capsule	LV	Lateral ventricle
C4	Retrolenticular limb of internal capsule	M	Mammillary body
CC	Collicular cistern	MCA	Middle cerebral artery
CD	Cerebral peduncle	OL	Occipital lobe
CH	Choroid plexus	ON	Optic nerve
CL	Clastrum	OR	Optic radiations
CN	Caudate nucleus	OT	Optic tract
CV	Great cerebral vein	P	Putamen
ET	External capsule	PL	Pulvinar
EX	Extreme capsule	RN	Red nucleus
F	Fornix	SP	Septum pellucidum
FC	Falx cerebri	ST	Straight sinus
FL	Frontal lobe	T	Thalamus
FM	Interventricular foramen	TC	Tail of caudate nucleus
FMa	Forceps major	TR	Trigone of lateral ventricle
FMI	Forceps minor	TU	Tuber cinereum
G	Gray matter	TV	Third ventricle
		W	White matter

Authors: Agur, Anne M.R.; Dalley, Arthur F.

Title: *Grant's Atlas of Anatomy, 12th Edition*

Copyright ©2009 Lippincott Williams & Wilkins

> Table of Contents > Chapter 7 - Head > 7.91 Brainstem

---

## 7.91 Brainstem

*Part of* "Chapter 7 - Head "

The brainstem has been exposed by removing the cerebellum, all of the right cerebral hemisphere, and the major portion of the left hemisphere. A. Ventral aspect.

- The brainstem consists of the medulla oblongata, pons, and midbrain.
- The pyramid is on the ventral surface of the medulla; the decussation of the pyramids is formed by the decussating (crossing) lateral corticospinal tract.
- The trigeminal nerve (CN V) emerges as sensory and motor roots.
- The crus cerebri are part of the midbrain;
- The oculomotor nerve emerges from the interpeduncular fossa.

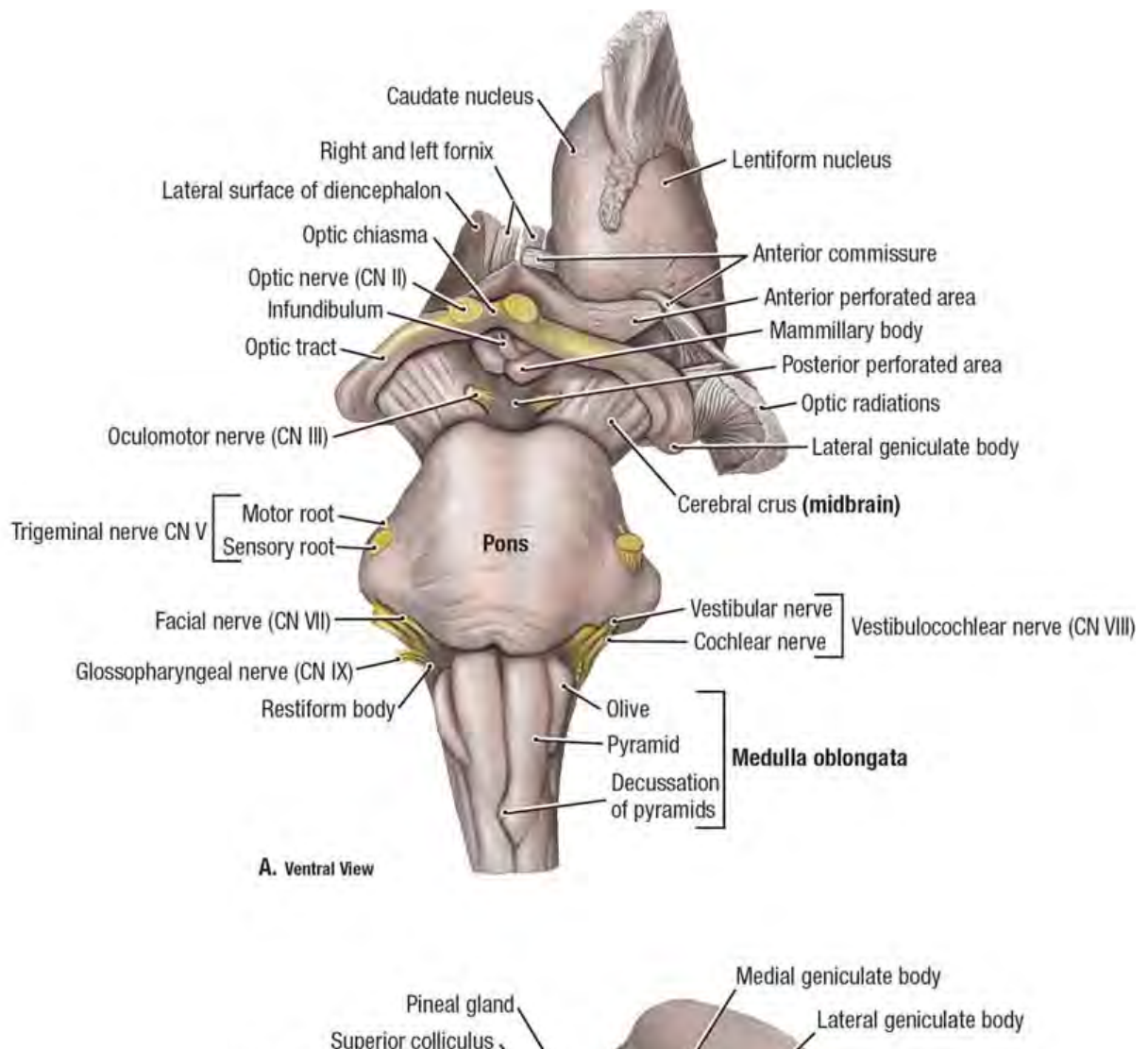
B. Lateral aspect.

- The vestibulocochlear nerve (CN VIII) consists of two nerves, the vestibular and cochlear nerves.
- The spinal tract of the trigeminal nerve is exposed where it comes to the surface of the medulla to form the tuber cinereum.
- The three are cerebellar peduncles: superior, middle, and inferior.
- The medial and lateral lemnisci on the lateral aspect of the midbrain

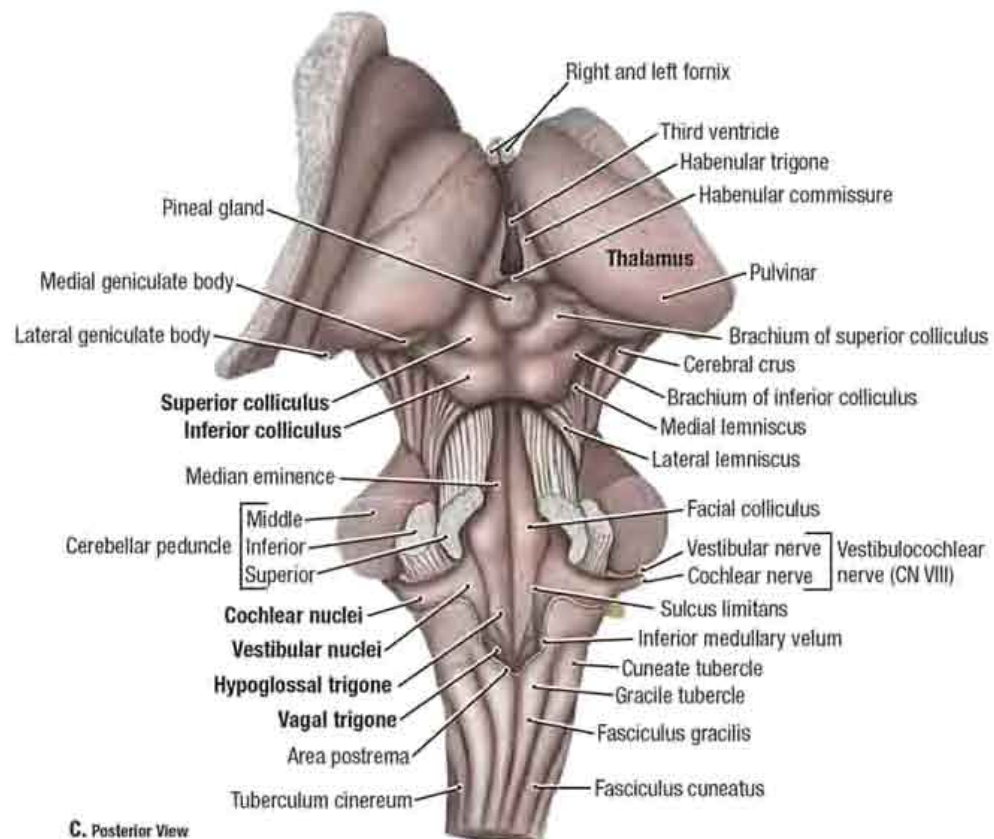
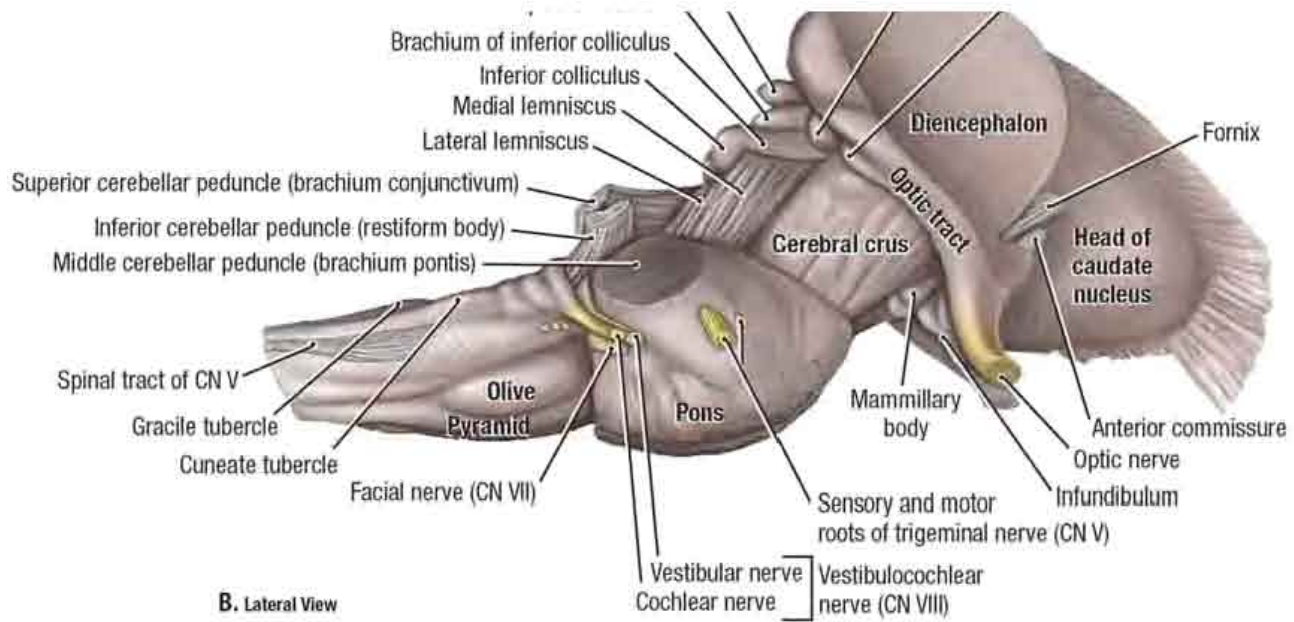
### C. Dorsal aspect.

- Ridges are formed by the fasciculus gracilis and cuneatus.
- The gracile and cuneate tubercles are the site of the nucleus cuneatus and nucleus gracilis.
- The diamond-shaped floor of the fourth ventricle; lateral to the sulcus limitans are the vestibular and cochlear nuclei and medially are the hypoglossal and vagal trigones and the facial colliculus.
- The superior and inferior colliculi form the dorsal surface of the midbrain.

P.736







Authors: Agur, Anne M.R.; Dalley, Arthur F.

Title: *Grant's Atlas of Anatomy, 12th Edition*

Copyright ©2009 Lippincott Williams & Wilkins

> Table of Contents > Chapter 7 - Head > 7.92 Cerebellum

---

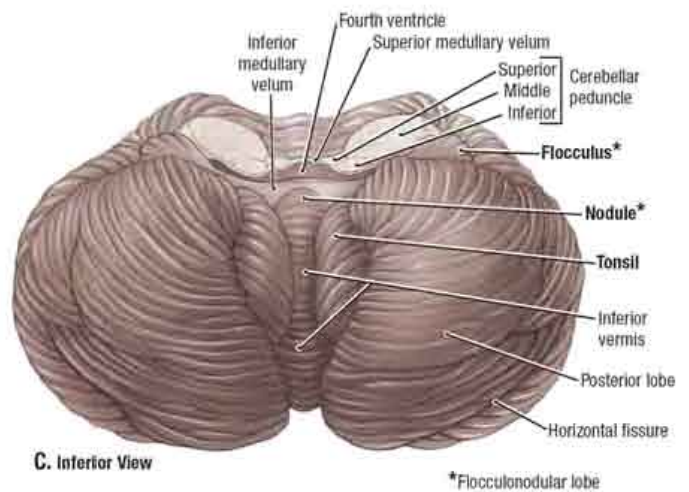
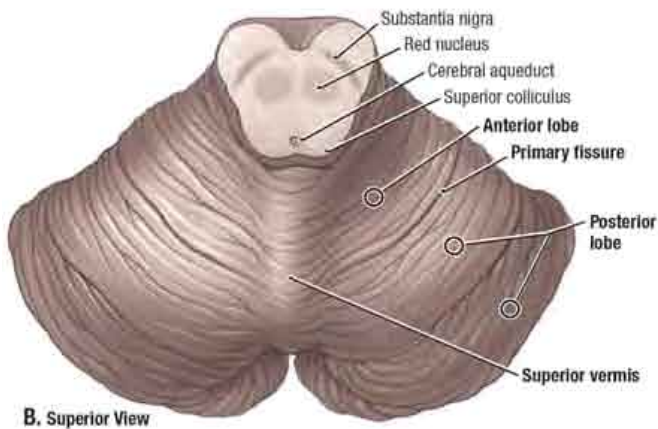
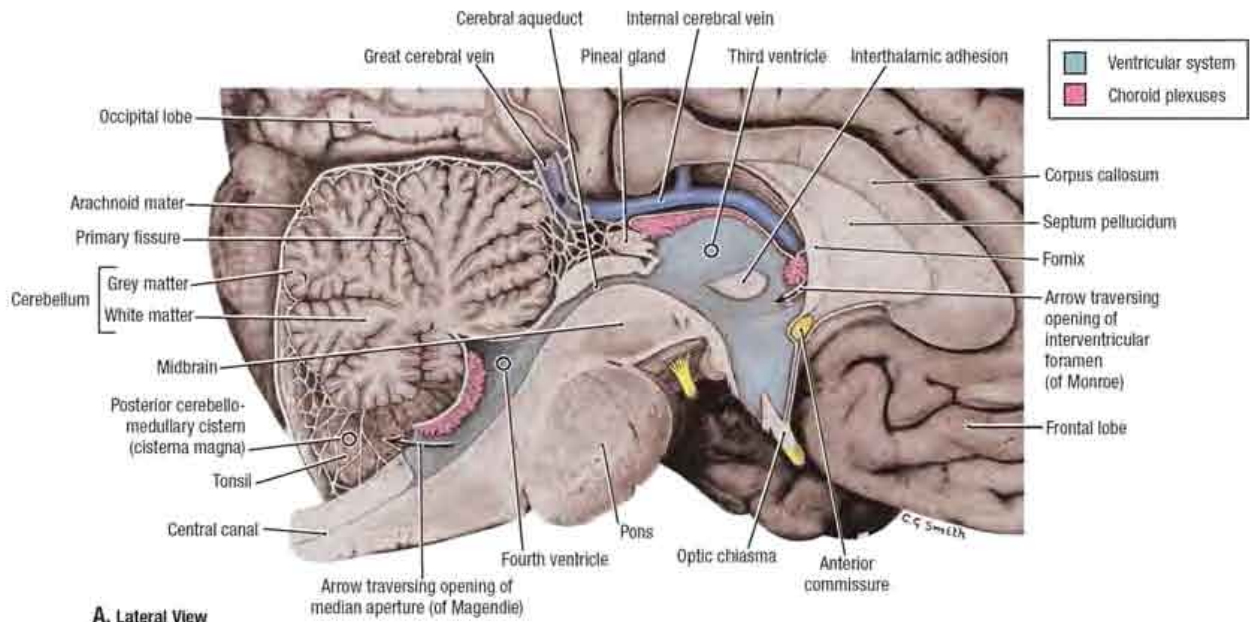
## 7.92 Cerebellum

*Part of "Chapter 7 - Head "*

A. Median section. The arachnoid mater was removed except where it covered the cerebellum and the occipital lobe. CSF may be obtained, for diagnostic purposes, from the posterior cerebellomedullary cistern, using a procedure known as cisternal puncture. The subarachnoid space or the ventricular system may also be entered for measuring or monitoring CSF pressure, injecting antibiotics, or administering contrast media for radiography. B. Superior view of the cerebellum. The right and left cerebellar hemispheres are united by the superior vermis; the anterior and posterior lobes are separated by the primary fissure. C. Inferior view of cerebellum. The flocculonodular lobe, the oldest part of the cerebellum, consists of the flocculus and nodule; the cerebellar tonsils typically extend into the foramen magnum.

---

P.737



Authors: Agur, Anne M.R.; Dalley, Arthur F.

Title: *Grant's Atlas of Anatomy, 12th Edition*

Copyright ©2009 Lippincott Williams & Wilkins

> Table of Contents > Chapter 7 - Head > 7.93 Serial dissections of the cerebellum

---

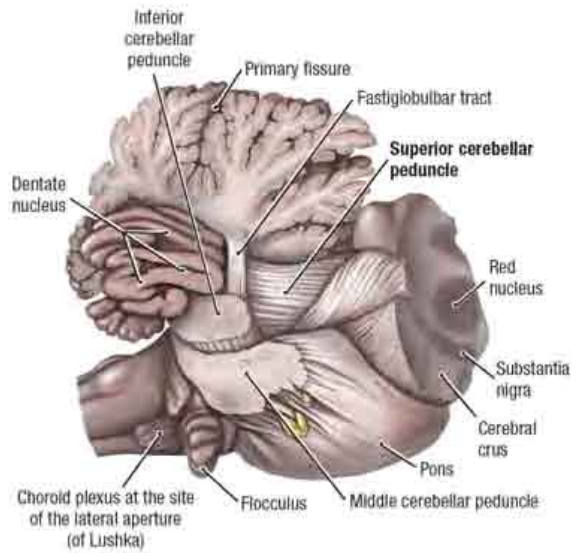
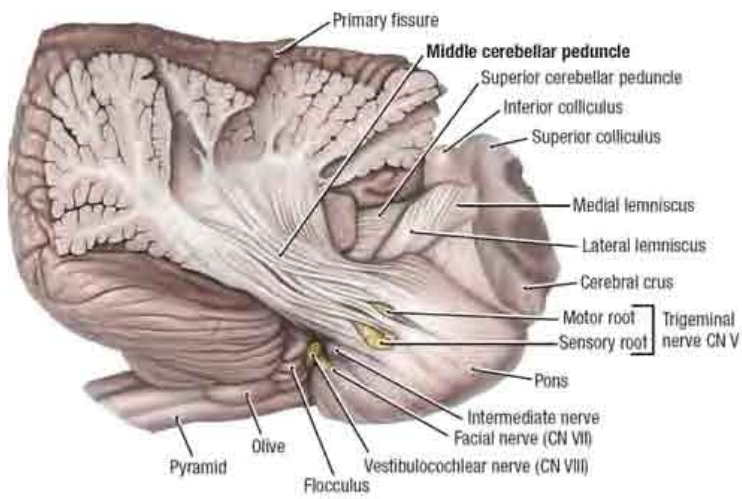
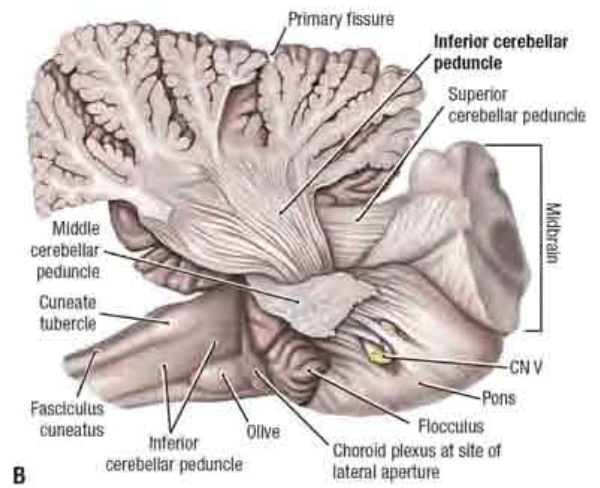
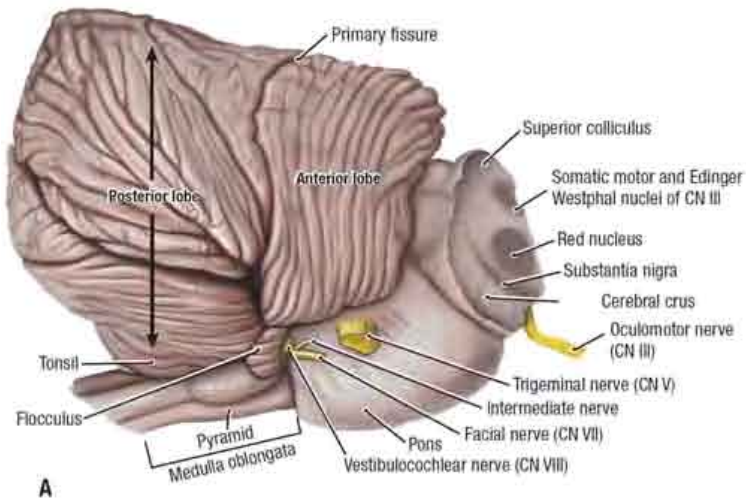
## 7.93 Serial dissections of the cerebellum

*Part of "Chapter 7 - Head "*

The series begins with the lateral surface of the cerebellar hemispheres (A) and proceeds medially in sequence (B–D) .

A. Cerebellum and brainstem. B. Inferior cerebellar peduncle. The fibers of the middle cerebellar peduncle were cut dorsal to the trigeminal nerve and peeled away to expose the fibers of the inferior cerebellar peduncle. C. Middle cerebellar peduncle. The fibers of the middle cerebellar peduncle were exposed by peeling away the lateral portion of the lobules of the cerebellar hemisphere. D. Superior cerebellar peduncle and dentate nucleus. The fibers of the inferior cerebellar peduncle were cut just dorsal to the previously sectioned middle cerebellar peduncle and peeled away until the gray matter of the dentate nucleus could be seen.





**Lateral Views**



Authors: Agur, Anne M.R.; Dalley, Arthur F.  
 Title: *Grant's Atlas of Anatomy, 12th Edition*  
 Copyright ©2009 Lippincott Williams & Wilkins

> Table of Contents > Chapter 7 - Head > 7.94 Axial (transverse) MRIs through the brainstem, inferior views

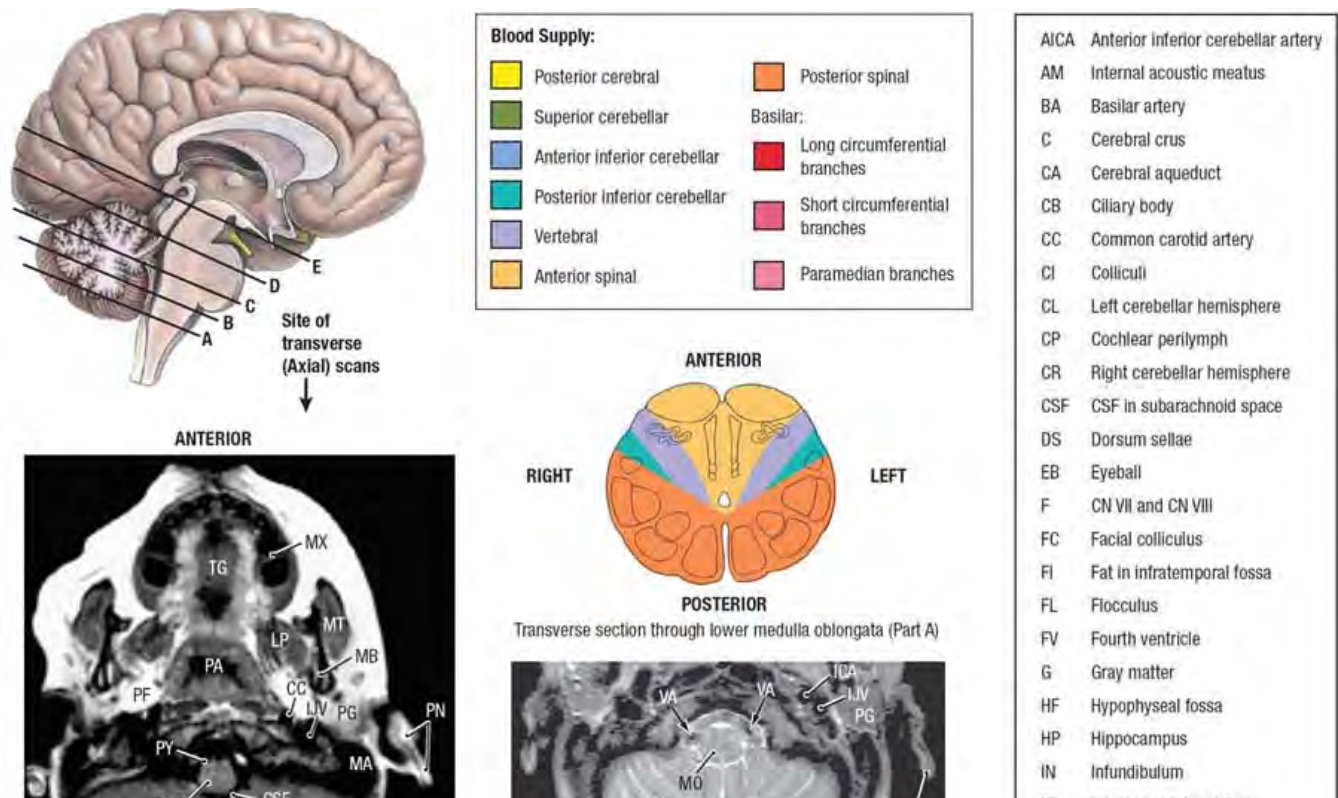
## 7.94 Axial (transverse) MRIs through the brainstem, inferior views

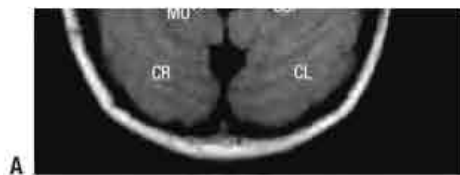Part of "Chapter 7 - Head "

P.739

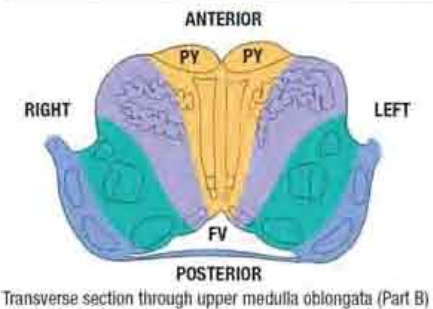
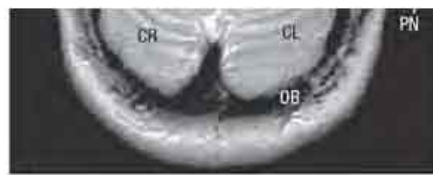Images on left side of page are T1 weighted, and images on the right side are T2 weighted.

P.740

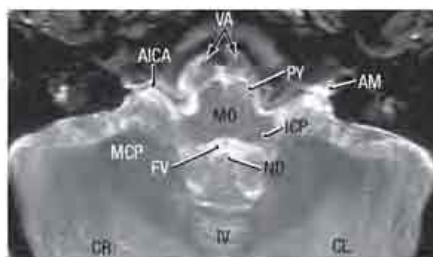



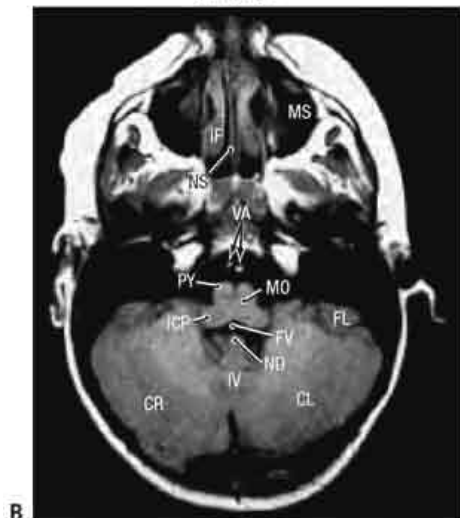
**A**  
POSTERIOR  
ANTERIOR



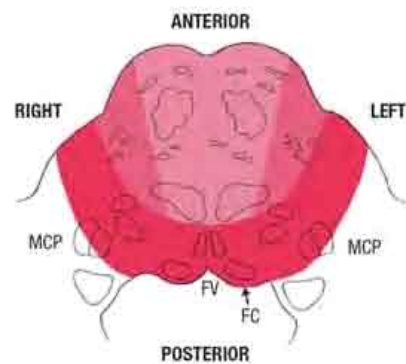
Transverse section through upper medulla oblongata (Part B)



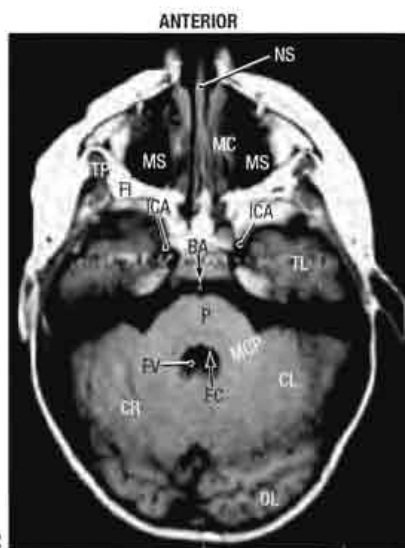
IC	Interpeduncular cistern
ICA	Internal carotid artery
ICP	Inferior cerebellar peduncle
IF	Inferior concha
IH	Inferior horn (lateral ventricle)
IJV	Internal jugular vein
IP	Interpeduncular fossa
IV	Inferior vermis
L	Lens
LP	Lateral pterygoid
MA	Mastoid air cells
MB	Mandible
MC	Middle concha
MCP	Middle cerebellar peduncle
MD	Midbrain
MO	Medulla oblongata
MS	Maxillary sinus
MT	Masseter
MX	Maxilla
ND	Nodule of cerebellum
NS	Nasal septum
OB	Occipital bone
OC	Optic chiasm



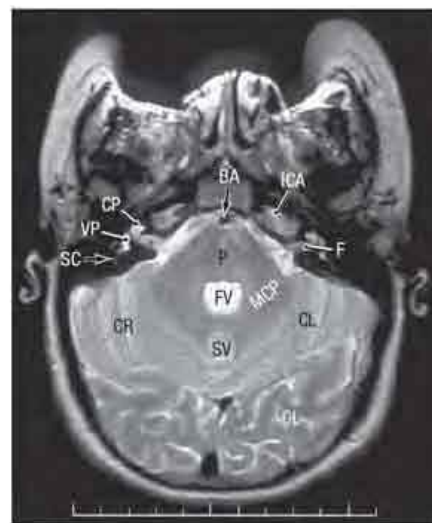
**B**  
POSTERIOR  
ANTERIOR



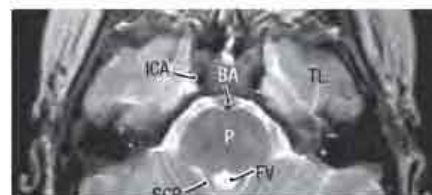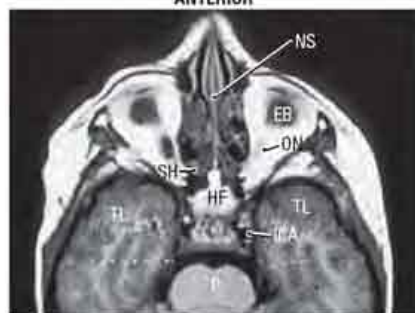
Transverse section through pons (Parts C & D)



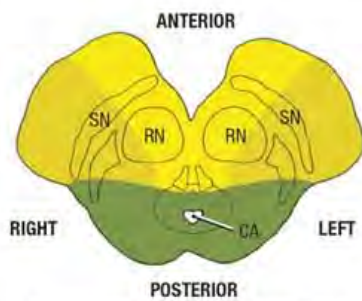
**C**  
POSTERIOR  
ANTERIOR



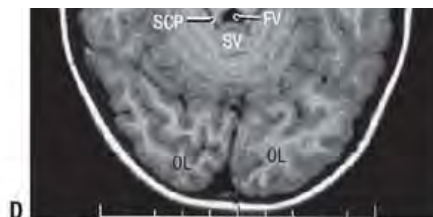
DL	Occipital lobe
ON	Optic nerve (CN II)
P	Pons
PA	Pharynx
PCA	Posterior cerebral artery
PF	Parapharyngeal fat
PG	Parotid gland
PH	Posterior horn (lateral ventricle)
PN	Pinna
PY	Pyramid
RN	Red nucleus
SC	Semicircular canal
SCP	Superior cerebellar peduncle
SE	Suprasellar cistern



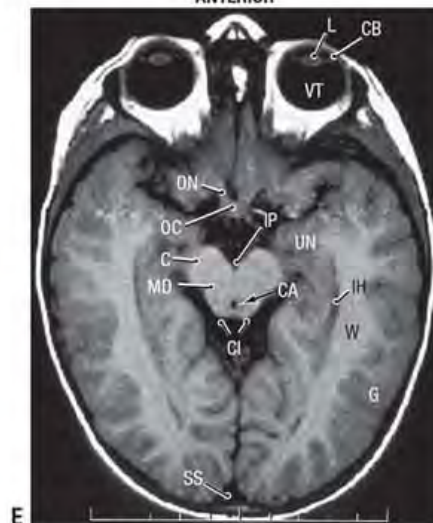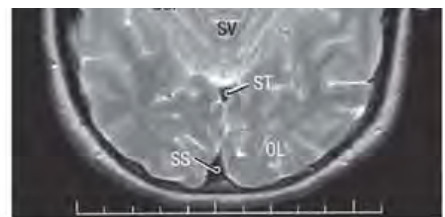
SH	Superior concha
SN	Substantia nigra
SS	Superior sagittal sinus
ST	Straight sinus
SV	Superior vermis
TG	Tongue
TL	Temporal lobe
TP	Temporals
UN	Uncus
VA	Vertebral artery
VP	Vestibular perilymph
VT	Vitreous body
W	White matter



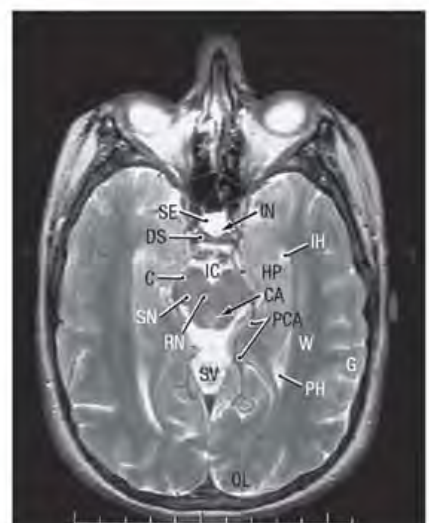Transverse section through midbrain (Part E)



D  
POSTERIOR  
ANTERIOR



E  
POSTERIOR





Authors: Agur, Anne M.R.; Dalley, Arthur F.  
 Title: *Grant's Atlas of Anatomy, 12th Edition*  
 Copyright ©2009 Lippincott Williams & Wilkins

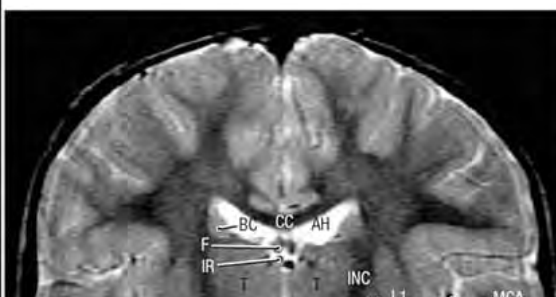
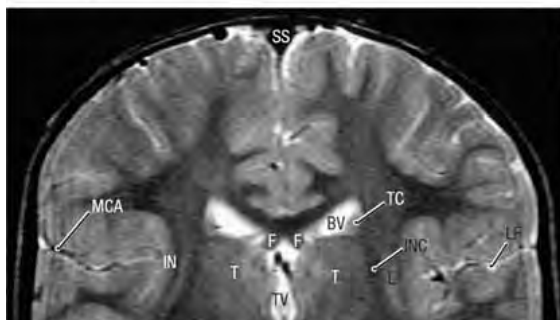
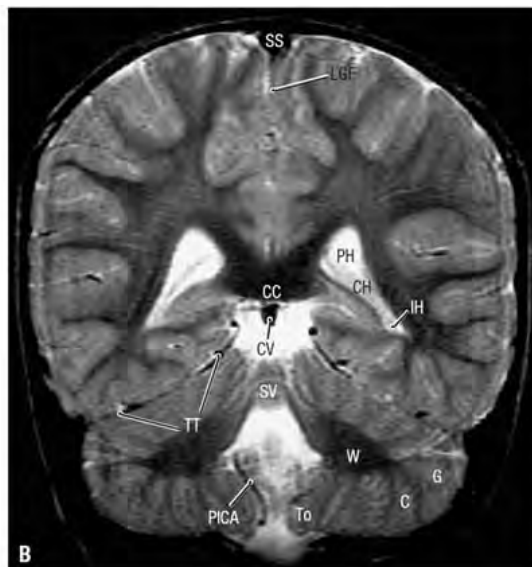
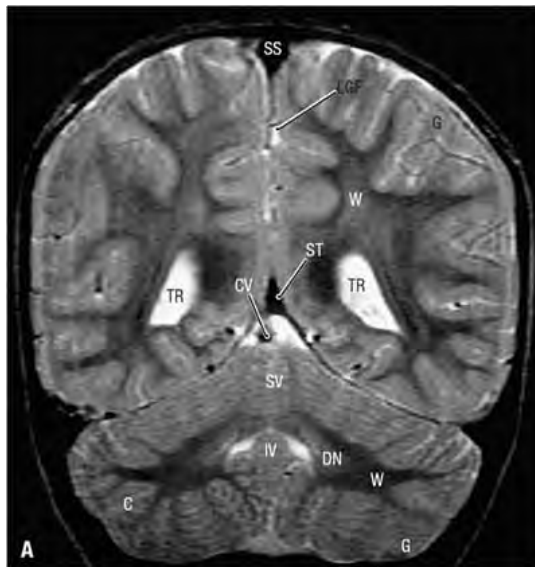
> Table of Contents > Chapter 7 - Head > 7.95 Coronal MRIs (T2 weighted) and sections of brain

## 7.95 Coronal MRIs (T2 weighted) and sections of brain

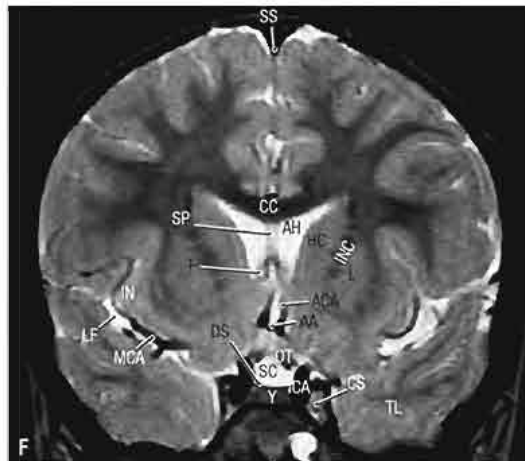
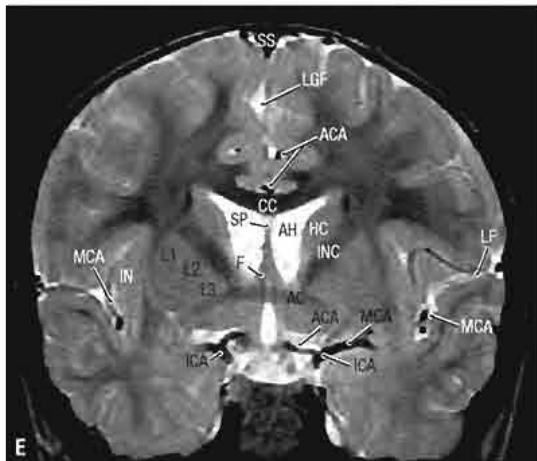
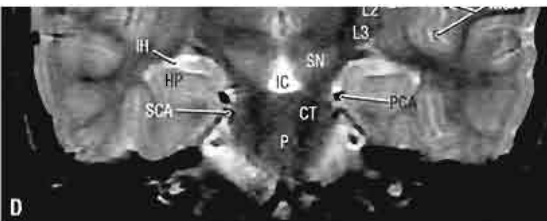
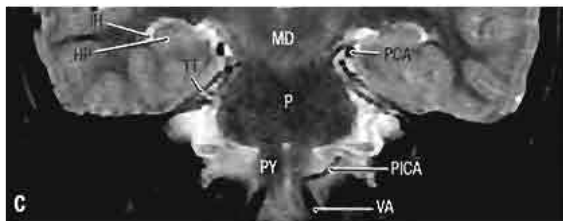
Part of "Chapter 7 - Head "

À F. Coronal MRIs. À H. Coronal sections, posterior views.

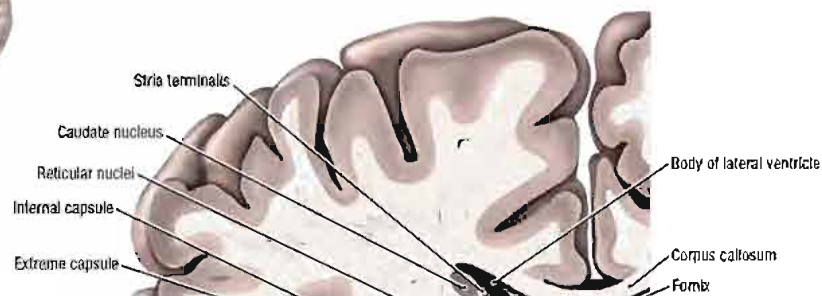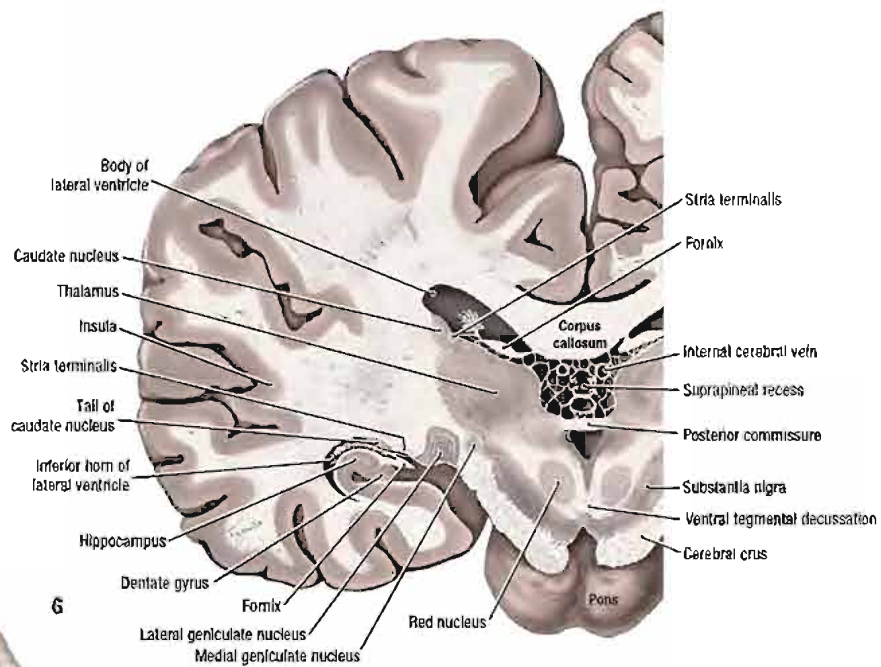
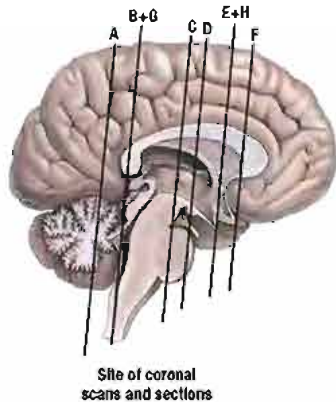
P.742



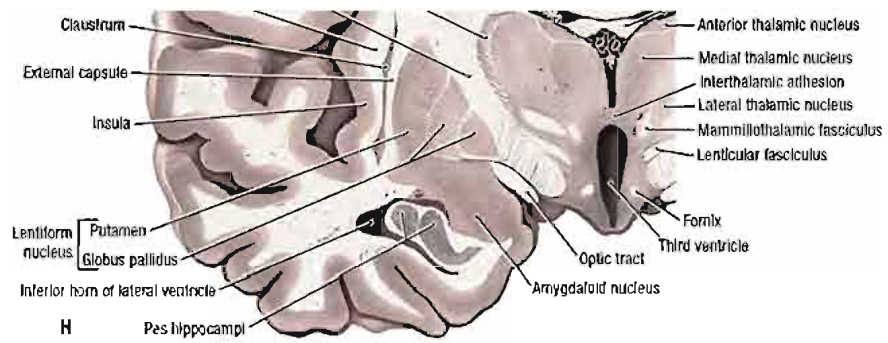
- AA Anterior communicating artery
- AC Anterior commissure
- ACA Anterior cerebral artery
- AH Anterior horn of lateral ventricle
- BC Body of caudate nucleus
- BV Body of lateral ventricle
- C Cerebellum
- CC Corpus callosum
- CH Choroid plexus
- CS Cavernous sinus
- CT Corticospinal tract
- CV Great cerebral vein
- DN Dentate nucleus
- DS Diaphragma sellae
- F Fornix
- FV Fourth ventricle
- G Gray matter
- HC Head of caudate nucleus
- HP Hippocampus
- IC Interpeduncular cistern
- ICA Internal carotid artery
- IH Interior horn of lateral ventricle
- IN Insular cortex
- INC Internal capsule
- IR Interventricular vein
- IV Inferior vermis
- L Lentiform nucleus
- L1 Putamen
- L2 External (lateral) segment of globus pallidus
- L3 Internal (medial) segment of globus pallidus
- LF Lateral fissure
- LGF Longitudinal fissure
- MCA Middle cerebral artery
- MD Midbrain
- OT Optic tract
- P Pons
- PCA Posterior cerebral artery
- PH Posterior horn of lateral ventricle



PICA Posterior inferior cerebellar artery  
 PY Pyramid  
 S Carotid siphon  
 SC Supracerebellar cistern  
 SCA Superior cerebellar artery  
 SN Substantia nigra  
 SP Septum pellucidum  
 SS Superior sagittal sinus  
 ST Straight sinus  
 SV Superior vermis  
 T Thalamus  
 TC Tail of caudate nucleus  
 TL Temporal lobe  
 To Cerebellar tonsil  
 TR Trigone of lateral ventricle  
 TT Tentorium cerebelli  
 TV Third ventricle  
 VA Vertebral artery  
 W White matter  
 Y Hypophysis





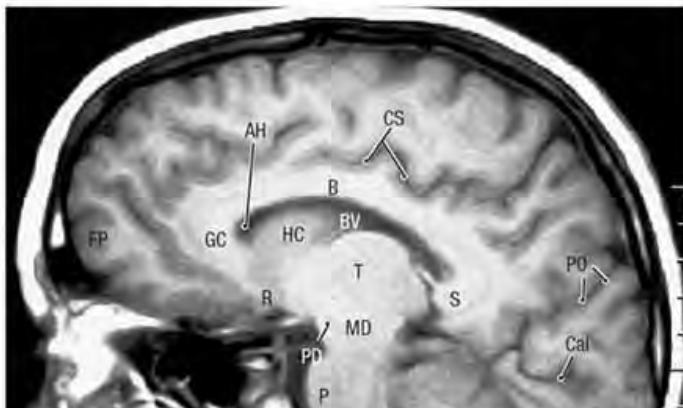
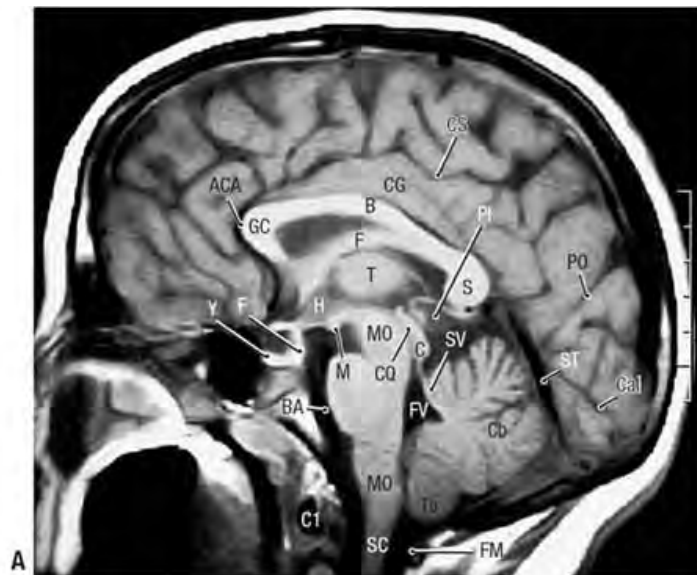


Authors: Agur, Anne M.R.; Dalley, Arthur F.  
 Title: *Grant's Atlas of Anatomy, 12th Edition*  
 Copyright ©2009 Lippincott Williams & Wilkins

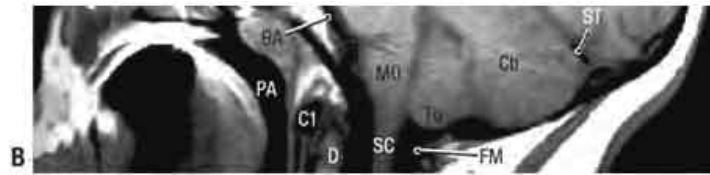
> Table of Contents > Chapter 7 - Head > 7.96 Sagittal MRIs (T1 weighted) and median section of brain

## 7.96 Sagittal MRIs (T1 weighted) and median section of brain

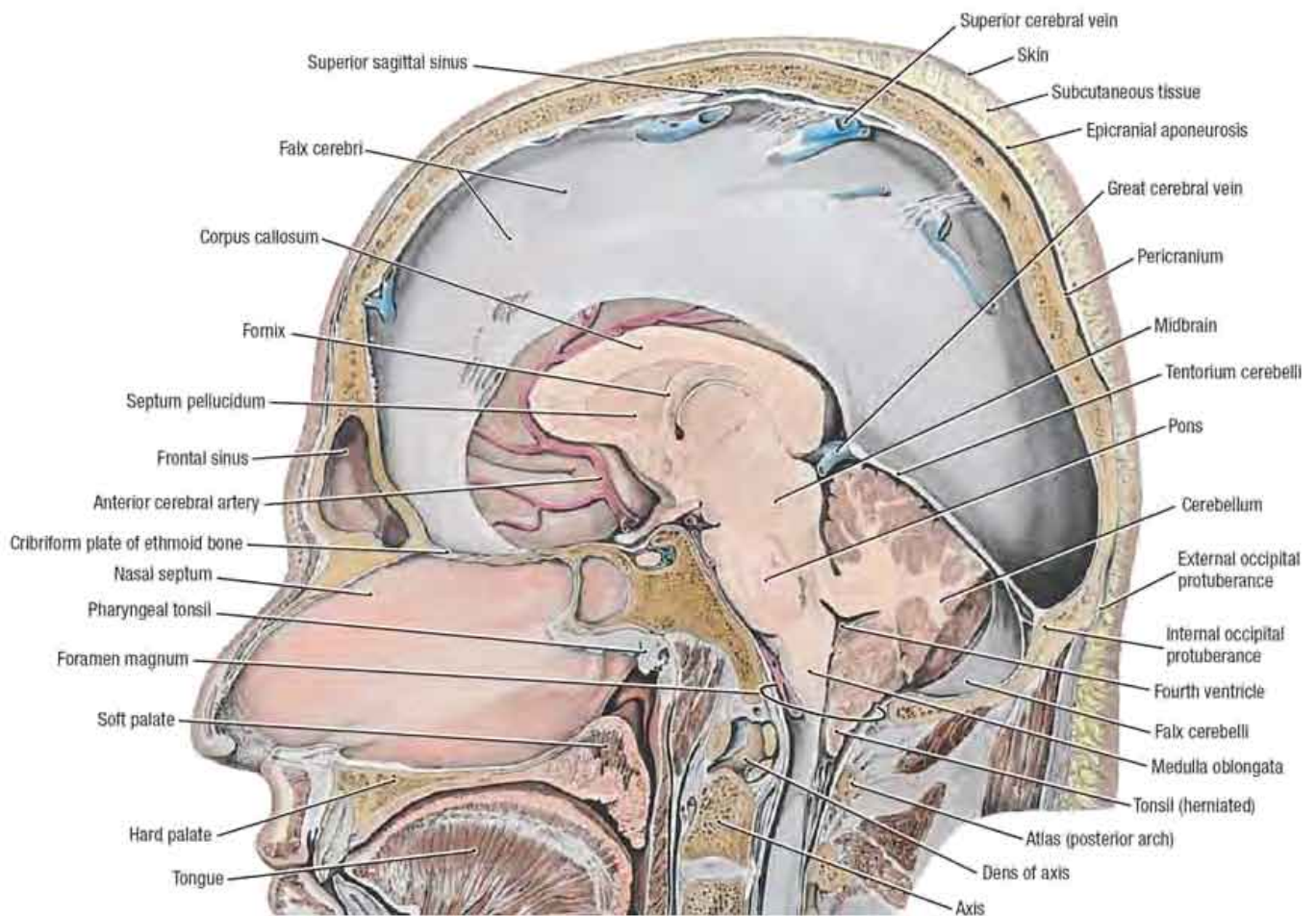
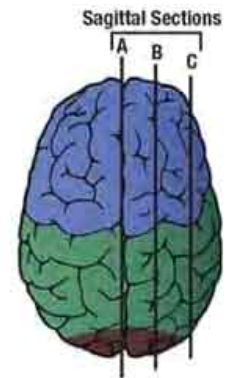
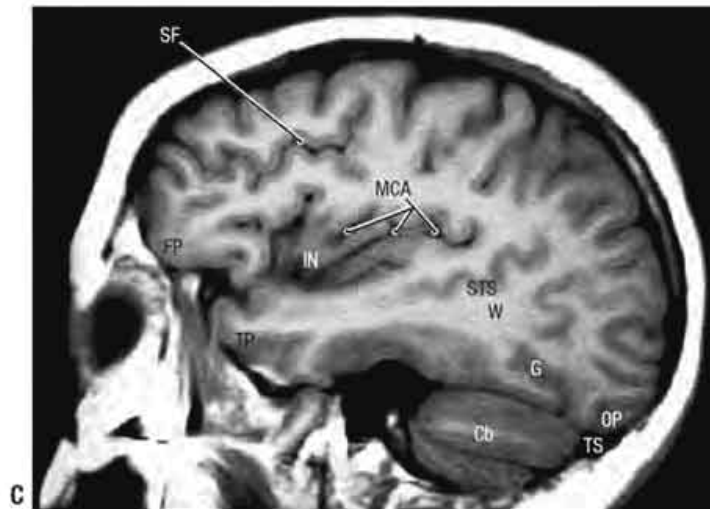
Part of "Chapter 7 - Head "

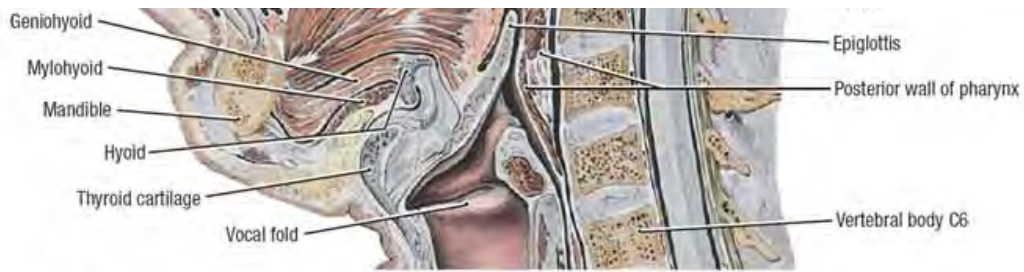

ACA	Anterior cerebral artery
AH	Anterior horn of lateral ventricle
B	Body of corpus callosum
BA	Basilar artery
BV	Body of lateral ventricle
C	Colliculi
C1	Anterior tubercle of atlas
Cal	Calcarine sulcus
Cb	Cerebellum
CG	Cingulate nucleus
CQ	Cerebral aqueduct
CS	Cingulate sulcus
D	Dens (odontoid process)
F	Fornix
FM	Foramen magnum
FP	Frontal pole
FV	Fourth ventricle
G	Cerebral cortex (gray matter)
GC	Genus of corpus callosum
H	Hypothalamus
HC	Head of caudate nucleus
I	Infundibulum
IN	Insular cortex
M	Mammillary body
MCA	Middle cerebral artery
MD	Midbrain
OP	Occipital pole
P	Pons
PA	Pharynx
PD	Cerebral peduncle
PI	Pineal
PO	Parieto-occipital fissure
R	Rostrum of corpus callosum
S	Splenium of corpus callosum
SC	Spinal cord
SF	Superior frontal sulcus
ST	Straight sinus
STS	Superior temporal sulcus
SV	Superior medullary vellum
T	Thalamus
To	Cerebral tonsil
TO	Tentorium



IP Temporal pole  
 TS Transverse sinus  
 W White matter  
 Y Hypophysis





**D. Median Section**

See orientation drawing for sites of scans A–C.

P.743

Increased intracranial pressure (e.g., due to a tumor) may cause displacement of the cerebellar tonsils through the foramen magnum, resulting in a tonsillar herniation. Compression of the brainstem, if severe, may result in respiratory and cardiac arrest.

Authors: Agur, Anne M.R.; Dalley, Arthur F.

Title: *Grant's Atlas of Anatomy, 12th Edition*

Copyright ©2009 Lippincott Williams & Wilkins

> Table of Contents > Chapter 8 - Neck > Chapter 8 - Neck

---

# Chapter 8

## Neck

- 8.1 Subcutaneous tissue and deep fascia of neck
- 8.2 Superficial veins of the neck
- 8.3 Surface anatomy of hyoid and cartilages of anterior neck
- 8.4 Bones and cartilages of the neck
- 8.5 Serial dissection of lateral cervical region (posterior triangle of neck)
- 8.6 Supra- and infrahyoid muscles
- 8.7 Infrahyoid region, superficial muscular layer
- 8.8 Suprahyoid region (submental triangle)
- 8.9 Superficial dissection of carotid triangle
- 8.10 Deep dissection of carotid triangle
- 8.11 Relationships of nerves and vessels in the carotid triangle of the neck
- 8.12 Deep veins of the neck
- 8.13 Endocrine layer of visceral compartmentâ€”I
- 8.14 Endocrine layer of visceral compartmentâ€”II
- 8.15 Respiratory layer of visceral compartment
- 8.16 Alimentary layer of visceral compartment



- 8.17 Root of the neck
- 8.18 Brachial plexus and sympathetic trunk in the root of the neck
- 8.19 Serial dissection of submandibular region and floor of mouthâ€”I
- 8.19 Serial dissection of submandibular region and floor of mouthâ€”II
- 8.19 Serial dissection of submandibular region and floor of mouthâ€”IV
- 8.20 Lingual and facial arteries in submandibular region and floor of mouth
- 8.21 Suboccipital region
- 8.22 Posterior cervical regionâ€”base of skull and transverse section
- 8.23 External pharynxâ€”I
- 8.23 External pharynxâ€”II
- 8.23 External pharynxâ€”III
- 8.24 Internal pharynxâ€”I
- 8.24 Internal pharynxâ€”II
- 8.25 Surface anatomy of isthmus of the fauces (oropharyngeal isthmus)
- 8.26 Palatine tonsil
- 8.27 Serial dissection of isthmus of fauces and lateral wall of nasopharynxâ€”I
- 8.27 Serial dissection of isthmus of fauces and lateral wall of nasopharynxâ€”II
- 8.27 Serial dissection of isthmus of the fauces and lateral wall of nasopharynxâ€”III
- 8.27 Serial dissection of isthmus of the fauces lateral wall of nasopharynxâ€”IV
- 8.28 Cartilages of the laryngeal skeleton
- 8.29 External larynx and laryngeal nerves
- 8.30 Internal larynx
- 8.31 Laryngoscopic examination and MRI imaging of larynx
- 8.32 Lymphatic drainage of thyroid gland, larynx, and trachea

- 8.33 Sympathetic trunk and sympathetic periarterial plexus
- 8.34 Transverse MRIs of neck
- 8.35 Transverse anatomical sections of neck
- 8.36 Median section and MRI scan of head and neck
- 8.37 Doppler US color flow study of carotid artery

## Platysma

*Anterior part:* Fibers interlace with contralateral muscle

*Intermediate part:* Fibers pass deep to depressors anguli oris and labii inferioris to attach to inferior border of mandible *Posterior part:* Skin/subcutaneous tissue of lower face lateral to mouth

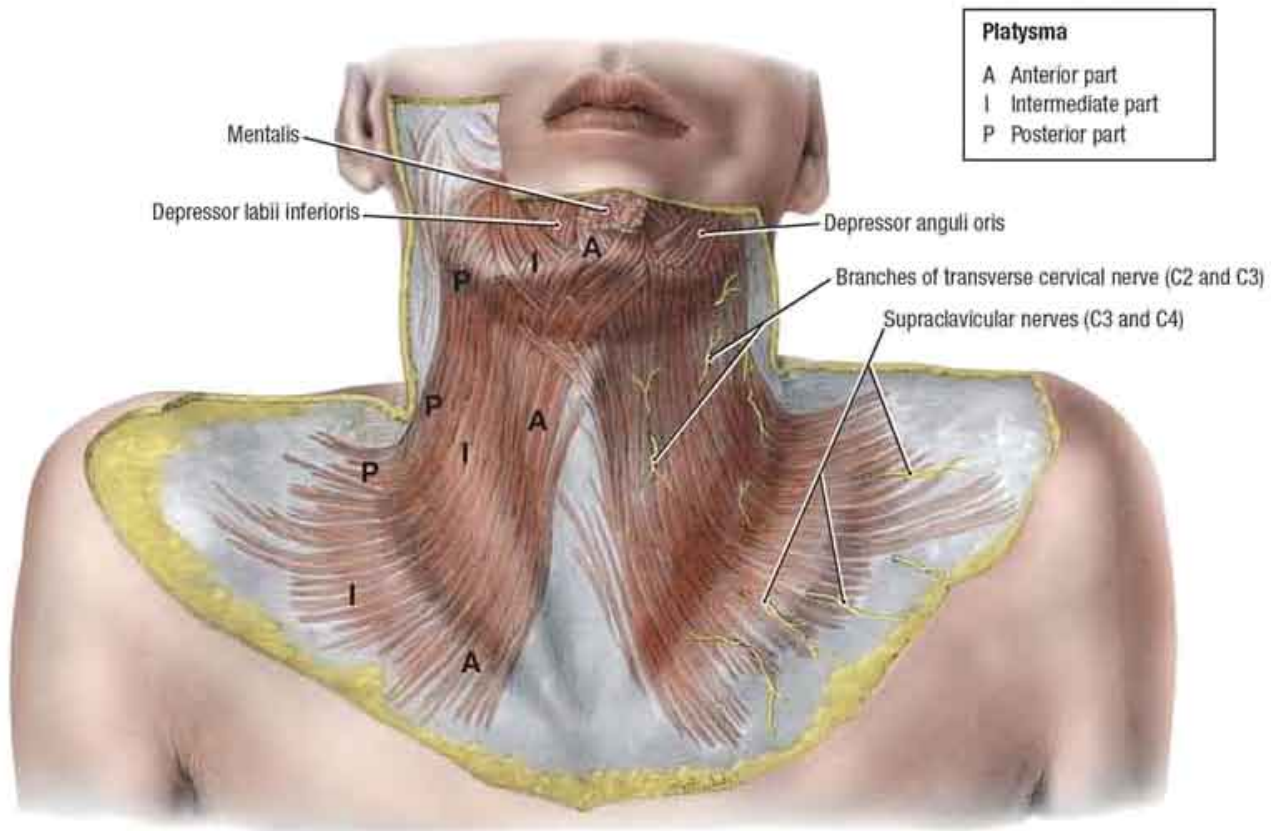
Subcutaneous tissue overlying superior parts of pectoralis major and sometimes deltoid muscles

Cervical branch of facial nerve (CN VII)

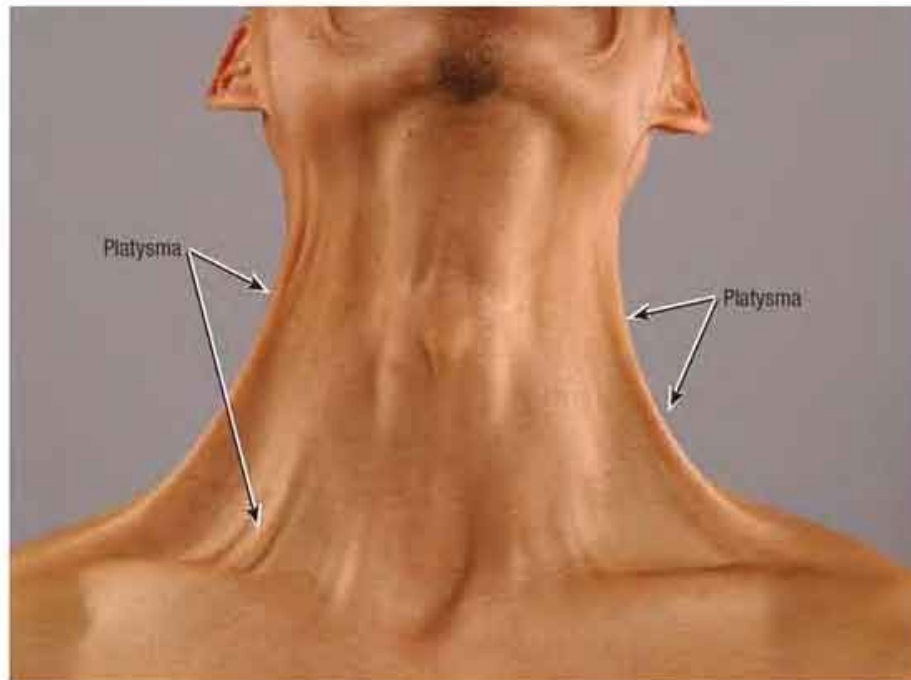Draws corner of mouth inferiorly and widens it as in expressions of sadness and fright; draws the skin of the neck superiorly, forming tense vertical and oblique ridges over the anterior neck

Muscle	Superior Attachment	Inferior Attachment	Innervation	Main Action
--------	---------------------	---------------------	-------------	-------------

Table 8.1 Platysma



A. Anterior View



Authors: Agur, Anne M.R.; Dalley, Arthur F.

Title: *Grant's Atlas of Anatomy, 12th Edition*

Copyright ©2009 Lippincott Williams & Wilkins

> Table of Contents > Chapter 8 - Neck > 8.1 Subcutaneous tissue and deep fascia of neck

---

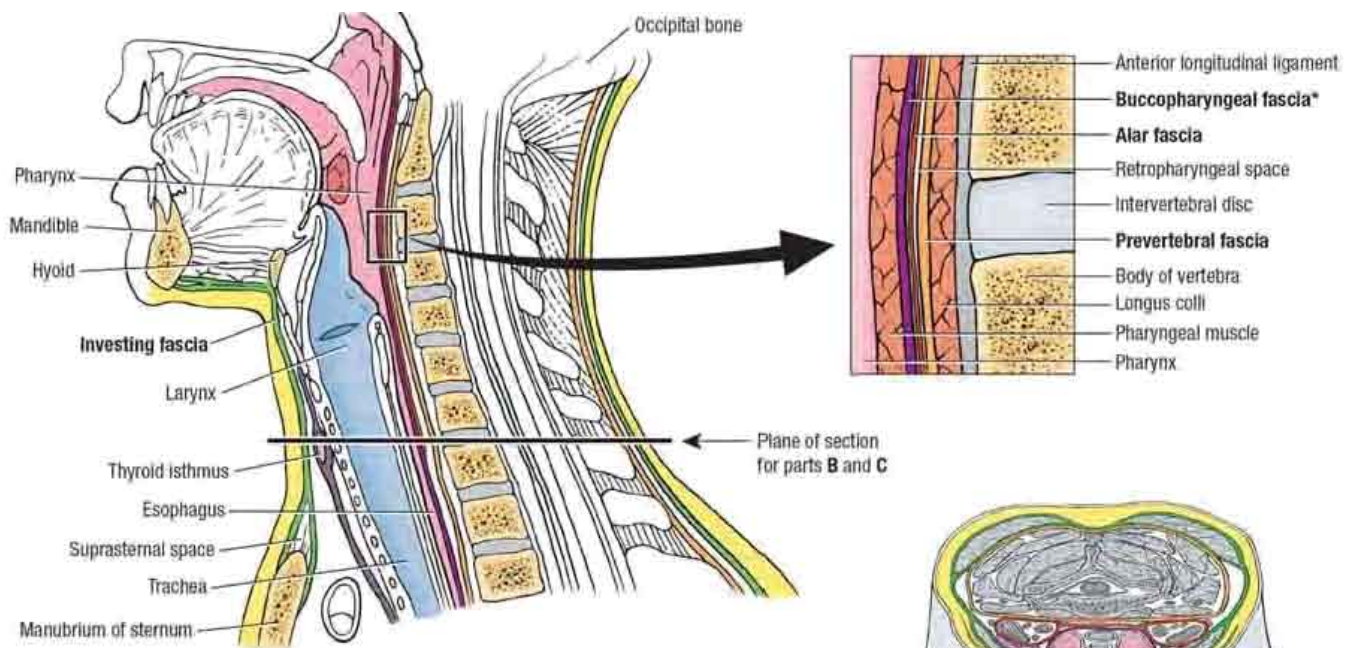
## 8.1 Subcutaneous tissue and deep fascia of neck

*Part of* "Chapter 8 - Neck "

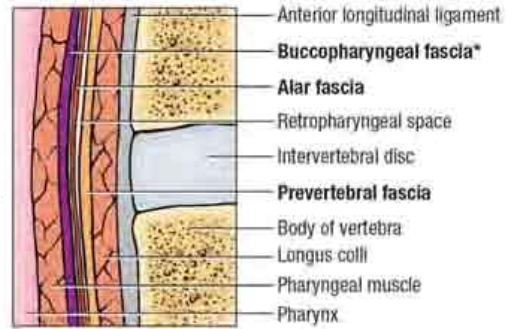
Sectional demonstrations of the fasciae of the neck. A. Fasciae of the neck are continuous inferiorly and superiorly with thoracic and cranial fasciae. The *inset* illustrates the fascia of the retropharyngeal region. B. Relationship of the main layers of deep cervical fascia and the carotid sheath. Midline access to the cervical viscera is possible with minimal disruption of tissues. C. The concentric layers of fascia are apparent in this transverse section of neck at the level indicated in A.

---

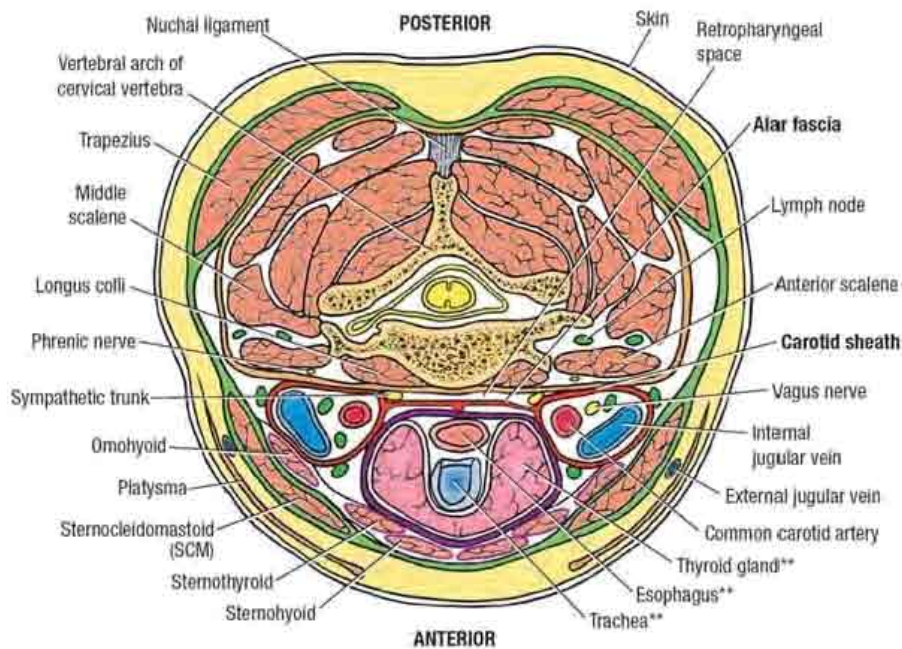
P.748



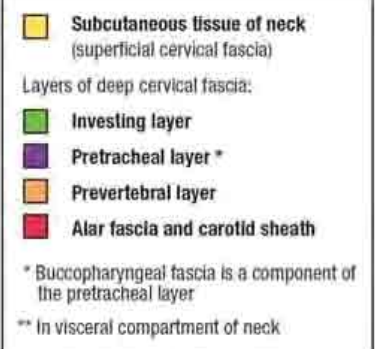
**A. Medial View**



**B. Anterosuperior View of Part C**



**C. Superior View of Transverse Section (at level of C7 vertebra)**



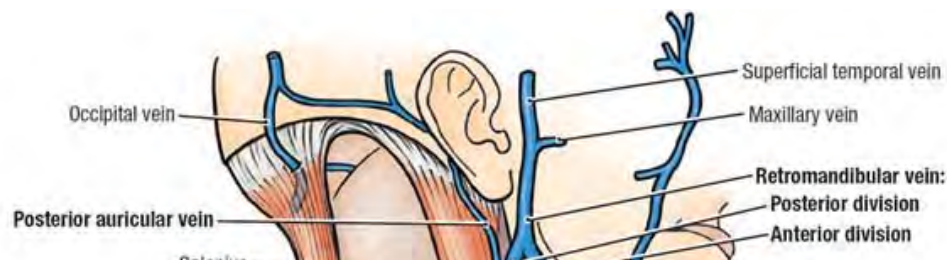


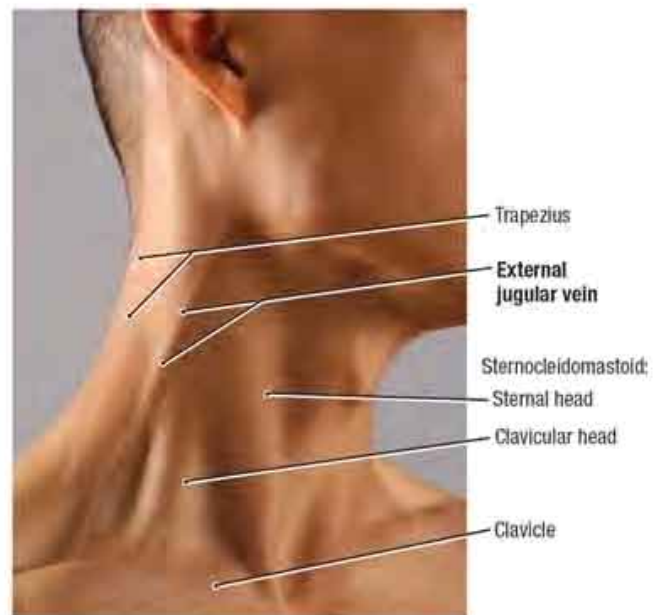
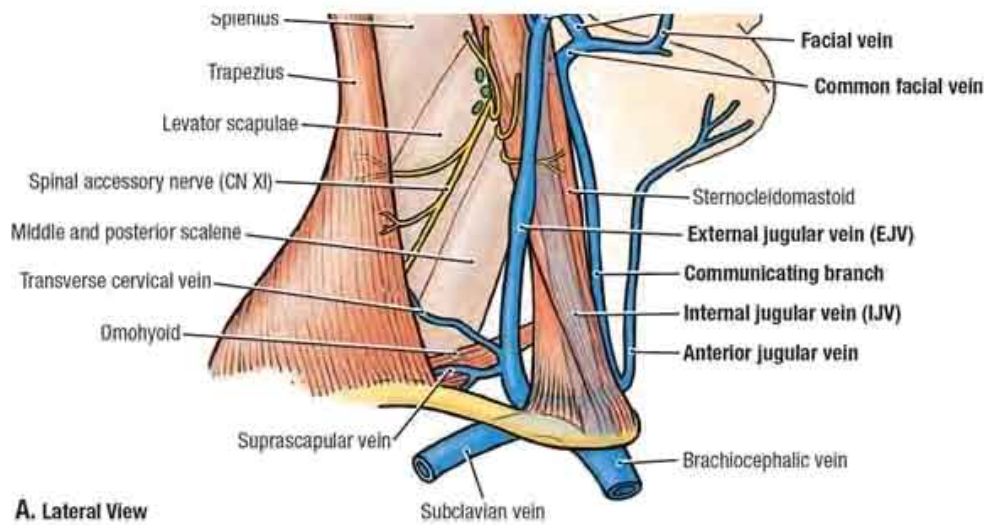
## 8.2 Superficial veins of the neck

Part of "Chapter 8 - Neck "

A. Schematic illustration of superficial veins of the neck. The superficial temporal and maxillary veins merge to form the retromandibular vein. The posterior division of the retromandibular vein unites with the posterior auricular vein to form the external jugular vein (EJV). The facial vein receives the anterior division of the retromandibular vein, forming the common facial vein that empties into the internal jugular vein. B. Surface anatomy of the external jugular vein and the muscles bounding the lateral cervical region (posterior triangle) of the neck.

The EJV may serve as an "internal barometer." • When venous pressure is in the normal range, the EJV is usually visible superior to the clavicle for only a short distance. However, when venous pressure rises (e.g., as in heart failure) the vein is prominent throughout its course along the side of the neck. Consequently, routine observation for distention of the EJVs during physical examinations may reveal diagnostic signs of heart failure, obstruction of the superior vena cava, enlarged supraclavicular lymph nodes, or increased intrathoracic pressure.





Authors: Agur, Anne M.R.; Dalley, Arthur F.

Title: *Grant's Atlas of Anatomy, 12th Edition*

Copyright ©2009 Lippincott Williams & Wilkins

> Table of Contents > Chapter 8 - Neck > 8.3 Surface anatomy of hyoid and cartilages of anterior neck

---

## 8.3 Surface anatomy of hyoid and cartilages of anterior neck

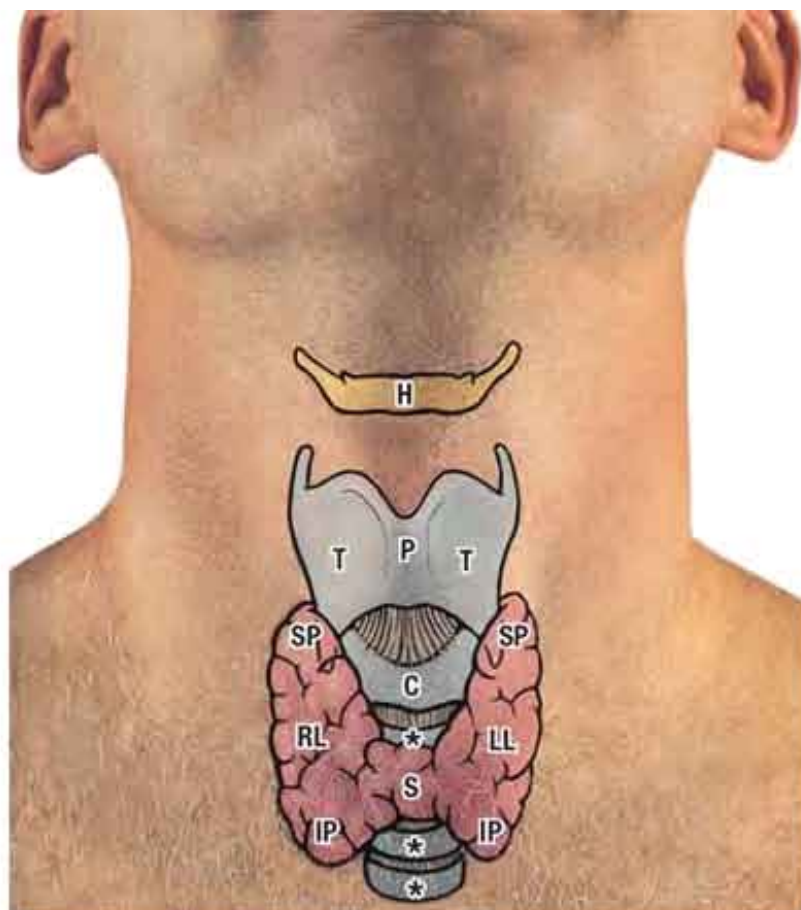
*Part of* "Chapter 8 - Neck"

The U-shaped hyoid lies superior to the thyroid cartilage at the level of the C4 and C5 vertebrae. The laryngeal prominence is produced by the fused laminae of the thyroid cartilage, which meet in the median plane. The cricoid cartilage can be felt inferior to the laryngeal prominence. It lies at the level of the C6 vertebra. The cartilaginous tracheal rings are palpable in the inferior part of the neck. The 2nd–4th rings cannot be felt because the isthmus of the thyroid, connecting its right and left lobes, covers them. The first tracheal ring is just superior to the isthmus.

### Tracheostomy

A transverse incision through the skin of the neck and anterior wall of the trachea (*tracheostomy*) establishes an airway in patients with upper airway obstruction or respiratory failure. The infrahyoid muscles are retracted laterally, and the isthmus of the thyroid gland is either divided or retracted superiorly. An opening is made in the trachea between the 1st and 2nd tracheal rings or through the 2nd through 4th rings. A *tracheostomy tube* is then inserted into the trachea and secured. To avoid complications during a tracheostomy, the following anatomical relationships are important:

- The *inferior thyroid veins* arise from a venous plexus on the thyroid gland and descend anterior to the trachea (see Fig. 8.13).
- A small *thyroid ima artery* is present in approximately 10% of people; it ascends from the brachiocephalic trunk or the arch of the aorta to the isthmus of the thyroid gland (see Fig. 8.15).
- The *left brachiocephalic vein*, jugular venous arch, and pleurae may be encountered, particularly in infants and children.
- The *thymus* covers the inferior part of the trachea in infants and children.
- The trachea is small, mobile, and soft in infants, making it easy to cut through its posterior wall and damage the esophagus.



**Anterior View**

C	Cricoid cartilage	RL	Right lobe of thyroid gland
H	Hyoid	S	Isthmus
IP	Inferior pole of thyroid gland	SP	Superior pole of thyroid gland
LL	Left lobe of thyroid gland	T	Thyroid cartilage
P	Laryngeal prominence	*	Tracheal rings



## 8.4 Bones and cartilages of the neck

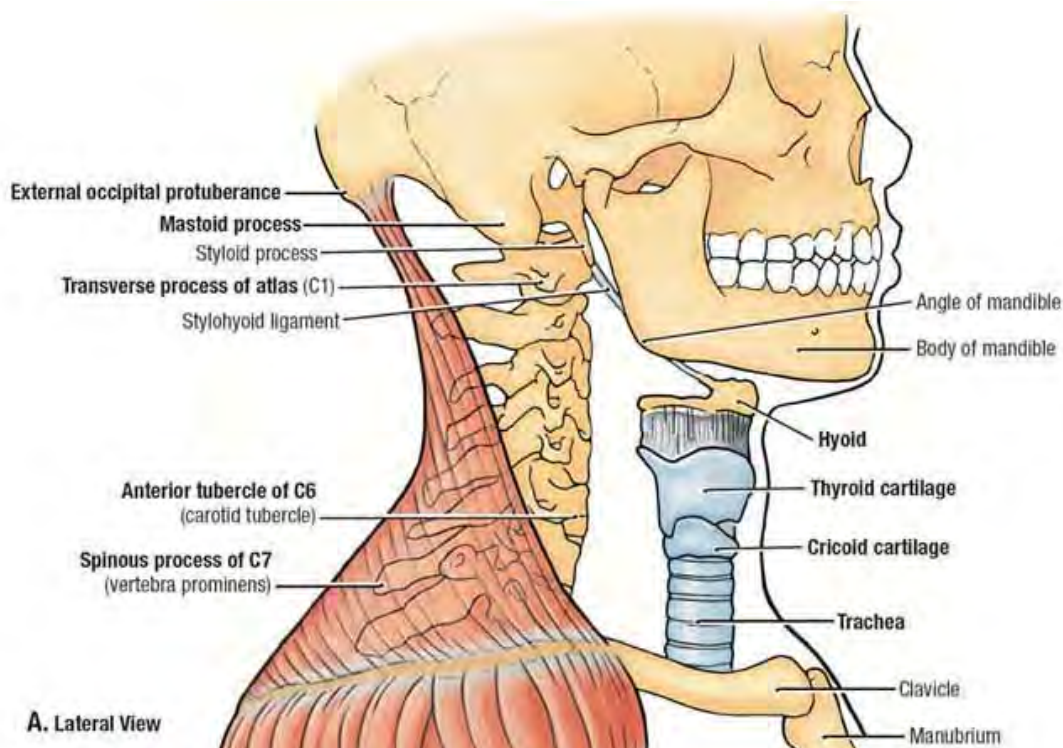
Part of "Chapter 8 - Neck "

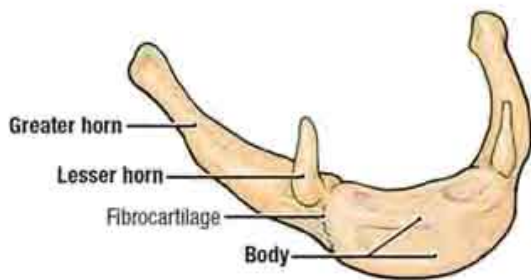
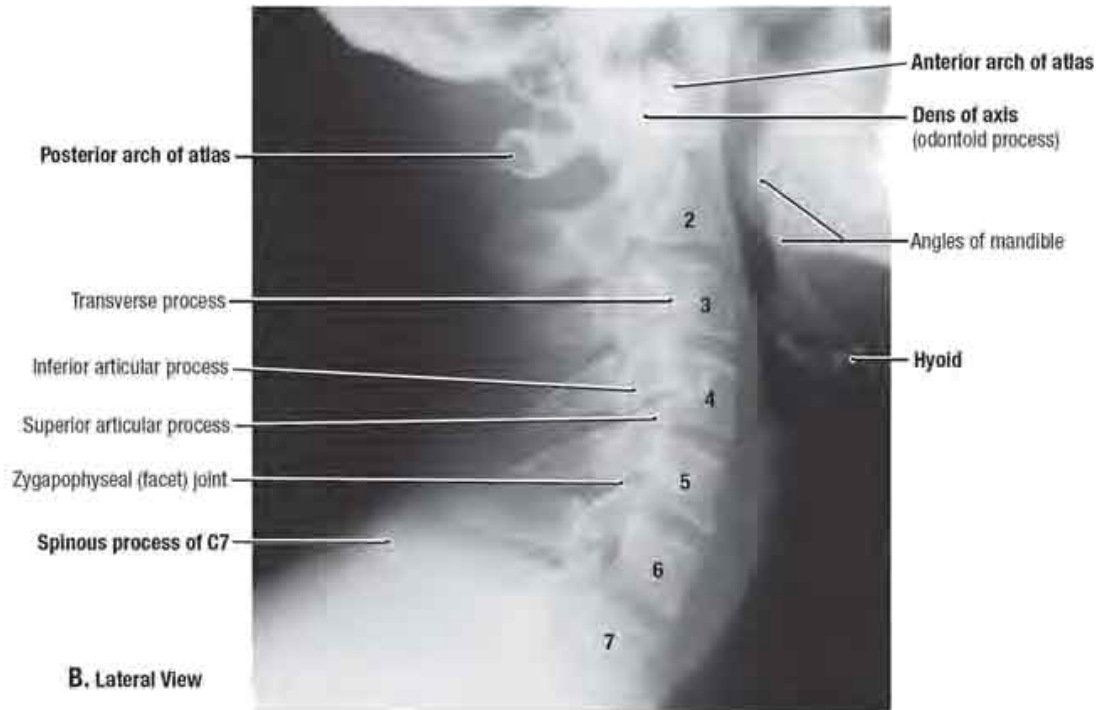
A. Bony and cartilaginous landmarks of the neck. B. Radiograph of hyoid bone and cervical vertebrae. Because the upper cervical vertebrae lie posterior to the upper and lower jaws and teeth, they are best seen radiographically in lateral views.

P.751

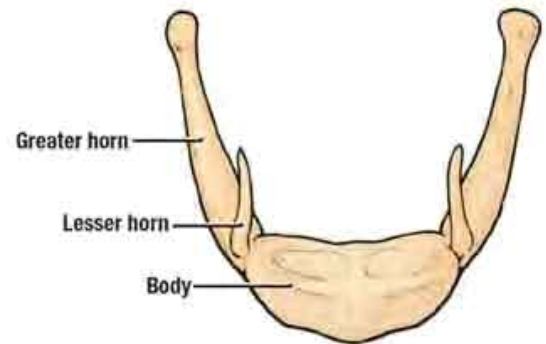
C and D. Features of hyoid bone. E and F. Articulated cervical vertebrae. G. Features of typical cervical vertebrae.

P.752

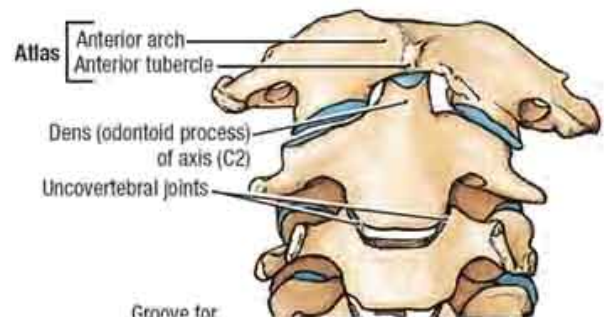
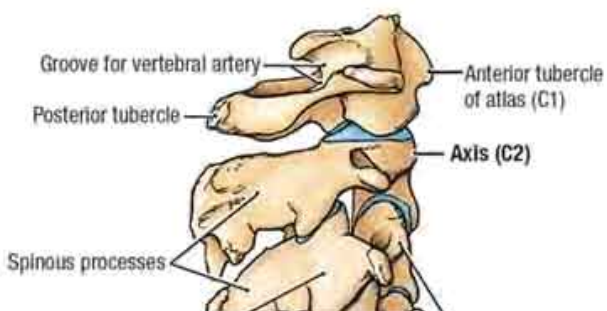


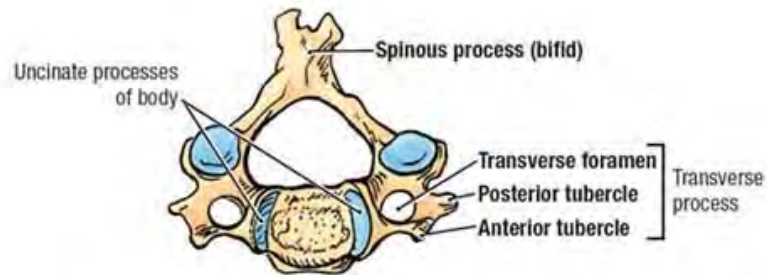
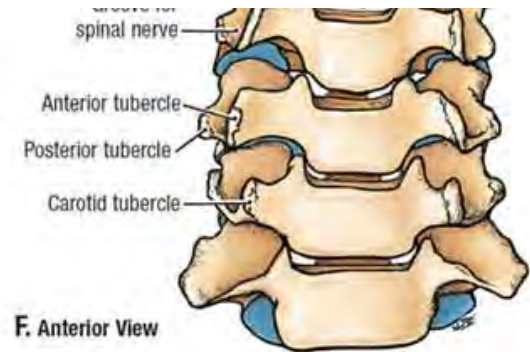
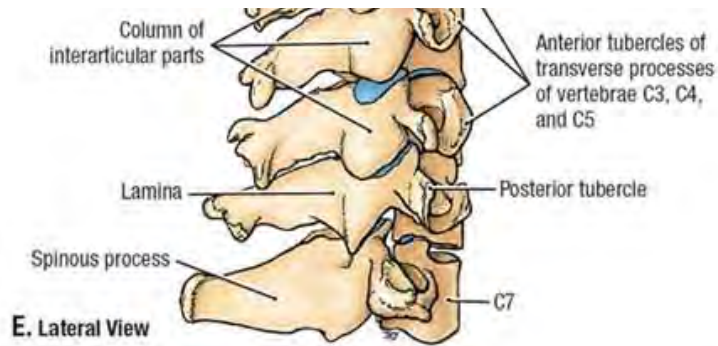


**C. Right Anterolateral View of Hyoid**



**D. Anterosuperior View of Hyoid**





**G. Superior View of Typical Cervical Vertebra (e.g., C4)**

Sternocleidomastoid region (A)

Lesser supraclavicular fossa (1)

Sternocleidomastoid (SCM) muscle; superior part of the external jugular vein; greater auricular nerve; transverse cervical nerve

Inferior part of internal jugular vein

Posterior cervical region (B)

Trapezius muscle; cutaneous branches of posterior rami of cervical spinal nerves; suboccipital region (E) lies deep to superior part of this region

Lateral cervical region (posterior triangle) (C)

Occipital triangle (2)

Omoclavicular triangle

Anterior cervical region (anterior triangle) (D)

Submandibular (digastric) triangle (4)

Submental triangle (5)

Carotid triangle (6)

Muscular (omotracheal) triangle (7)

Part of external jugular vein; posterior branches of cervical plexus of nerves; spinal accessory nerve; trunks of brachial plexus; transverse cervical artery; cervical lymph

nodes

Subclavian artery (3rd part); part of subclavian vein (variable); suprascapular artery; supraclavicular lymph nodes

Submandibular gland almost fills triangle; submandibular lymph nodes; hypoglossal nerve; mylohyoid nerve; parts of facial artery and vein

Submental lymph nodes and small veins that unite to form anterior jugular vein

Common carotid artery and its branches; internal jugular vein and its tributaries; vagus nerve; external carotid artery and some of its branches; hypoglossal nerve and superior root of ansa cervicalis; spinal accessory nerve; thyroid gland, larynx, and pharynx; deep cervical lymph nodes; branches of cervical plexus

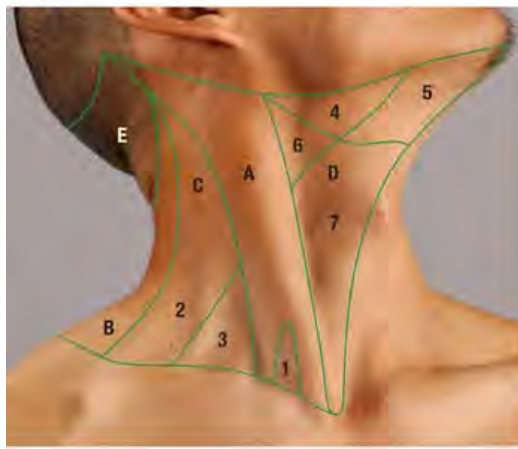
Sternothyroid and sternohyoid muscles; thyroid and parathyroid glands

<sup>a</sup> Letters and numbers in parentheses refer to Figures A and B.

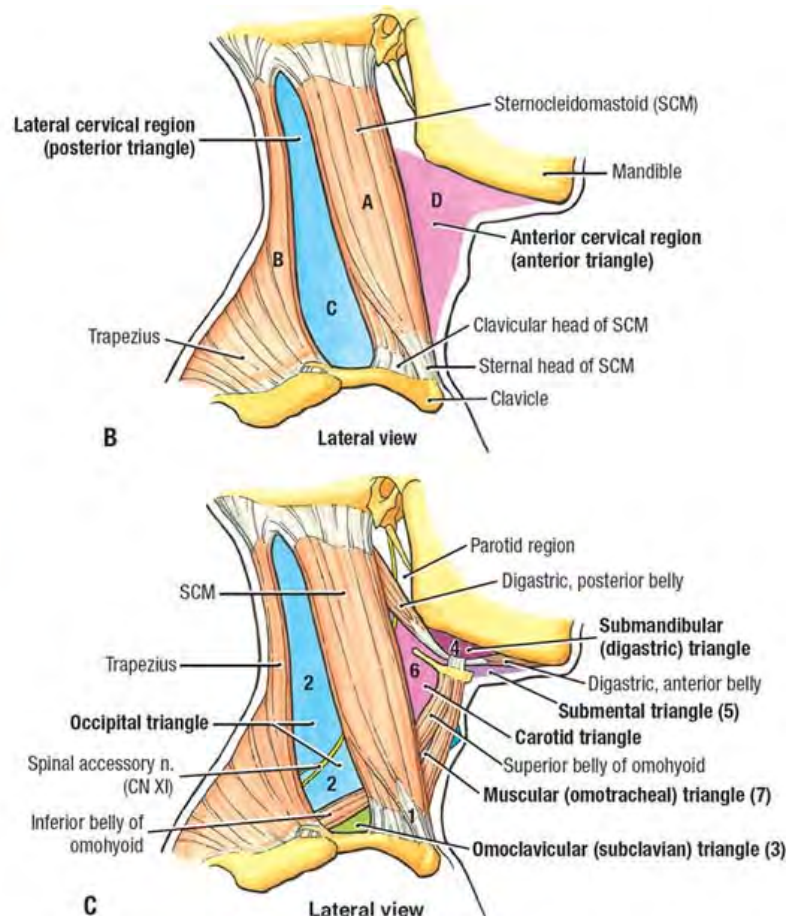
Region    Main Contents and Underlying Structures

## Table 8.2 Cervical Regions and Contents <sup>a</sup>





A Anterolateral view



## Sternocleidomastoid

Lateral surface of mastoid process of temporal bone; lateral half of superior nuchal line

*Sternal head:* anterior surface of manubrium of sternum

*Clavicular head:* superior surface of medial third of clavicle

Spinal accessory nerve (CN XI) [motor] and C2 and C3 nerves (pain and proprioception)

*Unilateral contraction:* laterally flexes neck; rotates neck so face is turned superiorly toward opposite side; *Bilateral contraction:* (1) extends neck at atlanto-occipital joints, (2) flexes cervical vertebrae so that chin approaches manubrium, or (3) extends superior cervical vertebrae while flexing inferior vertebrae, so chin is thrust forward with head kept level; with cervical vertebrae fixed, may elevate manubrium and medial end of clavicles, assisting deep respiration.

## Trapezius

Medial third of superior nuchal line, external occipital protuberance, nuchal ligament, spinous processes of C7–T12 vertebrae, lumbar and sacral spinous processes

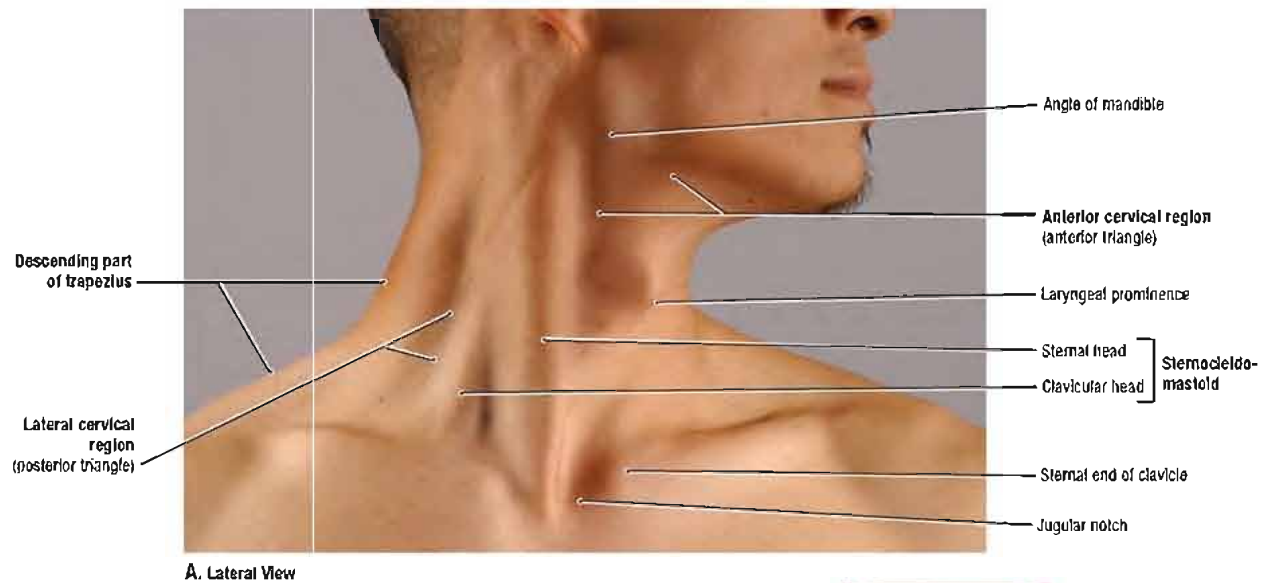
Lateral third of clavicle, acromion, spine of scapula



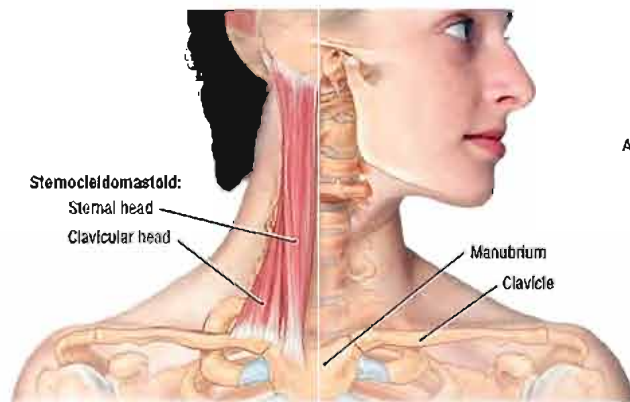
Spinal accessory nerve (CN XI) [motor] and C2 and C3 nerves (pain and proprioception)  
*Superior fibers* elevate pectoral girdle, maintain level of shoulders against gravity or resistance; *middle fibers* retract scapula; and *inferior fibers* depress shoulders; *superior* and *inferior fibers* work together to rotate scapula upward; *when shoulders are fixed*, bilateral contraction extends neck; unilateral contraction produces lateral flexion to same

Muscle	Superior Attachment	Inferior Attachment	Innervation	Main Action
--------	---------------------	---------------------	-------------	-------------

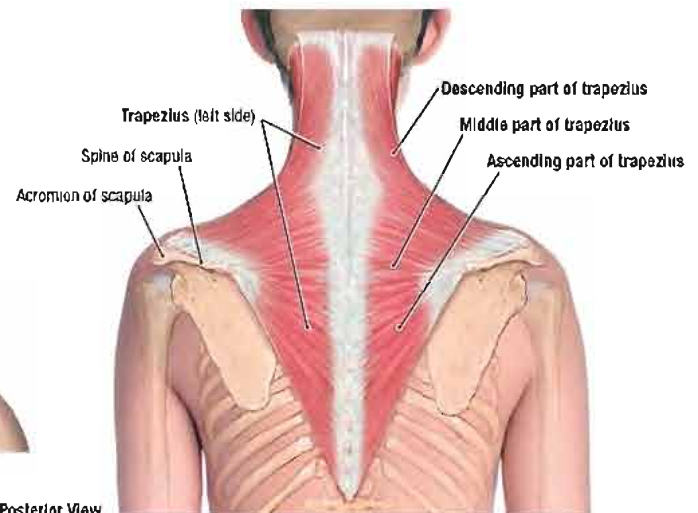
Table 8.3 Sternocleidomastoid and Trapezius
---



A. Lateral View



B. Anterior View



C. Posterior View

Authors: Agur, Anne M.R.; Dalley, Arthur F.

Title: *Grant's Atlas of Anatomy, 12th Edition*

Copyright ©2009 Lippincott Williams & Wilkins

> Table of Contents > Chapter 8 - Neck > 8.5 Serial dissection of lateral cervical region  
(posterior triangle of neck)

---

## 8.5 Serial dissection of lateral cervical region (posterior triangle of neck)

*Part of* "Chapter 8 - Neck "

A. External jugular vein and cutaneous branches of cervical plexus. Subcutaneous fat, the part of the plasma overlying the inferior part of the lateral cervical region, and the investing layer of deep cervical fascia have all been removed. The external jugular vein descends vertically across the sternocleidomastoid and pierces the prevertebral layer of deep cervical fascia superior to the clavicle.

B and C. Branches of the cervical plexus

- Branches arising from the nerve loop between the anterior rami of C2 and C3 are the lesser occipital, great auricular, and transverse cervical nerves.
- Branches arising from the loop formed between the anterior rami of C3 and C4 are the supraclavicular nerves, which emerge as a common trunk under cover of the SCM.

Regional anesthesia is often used for surgical procedures in the neck region or upper limb. In a cervical plexus block, an anesthetic agent is injected at several points along the posterior border of the SCM, mainly at its midpoint, the nerve point of the neck.

D. Muscles forming the floor of the lateral cervical region. The prevertebral layer of deep cervical fascia has been partially removed, and the motor nerves and most of the floor of the region are exposed.

- The spinal accessory nerve (CN XI) supplies the SCM and trapezius muscles; between them, it courses along the levator scapulae muscle but is separated from it by the prevertebral layer of deep cervical fascia.
- The phrenic nerve (C3, C4, C5) supplies the diaphragm and is located deep to the prevertebral layer of deep cervical fascia on the anterior surface of the anterior scalene muscle.

Severance of a phrenic nerve results in an ipsilateral paralysis of the diaphragm. A phrenic nerve block produces a short period of paralysis of the diaphragm on one side (e.g., for a lung operation). The anesthetic agent is injected around the nerve where it lies on the anterior surface of the anterior scalene muscle.

E. Vessels and motor nerves of the lateral cervical region. The clavicular head of the pectoralis major muscle and part of the clavicle have been removed.

The muscles that form the floor of the region are the semispinalis capitis, splenius capitis and levator scapulae superiorly and the anterior middle and posterior scalenes and serratus anterior inferiorly.

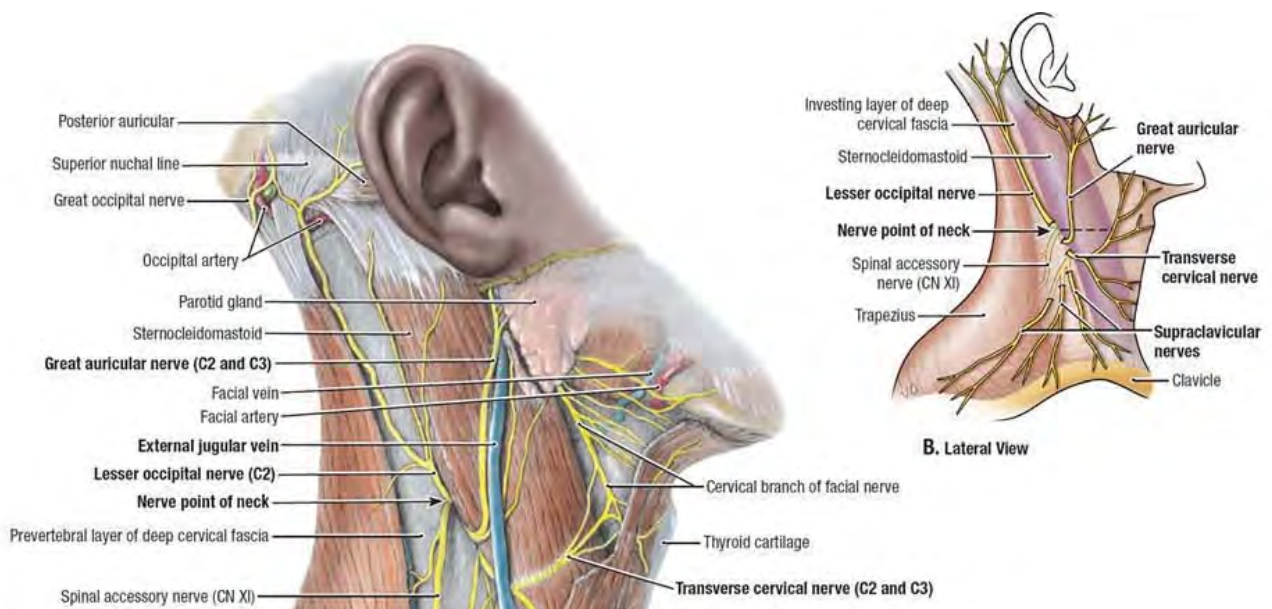
- The brachial plexus emerges between the anterior and middle scalene muscles.

A supraclavicular brachial plexus block may be utilized for anesthesia of the upper limb. The anesthetic agent is injected around the supraclavicular part of the brachial plexus. The main injection site is superior to the midpoint of the clavicle.

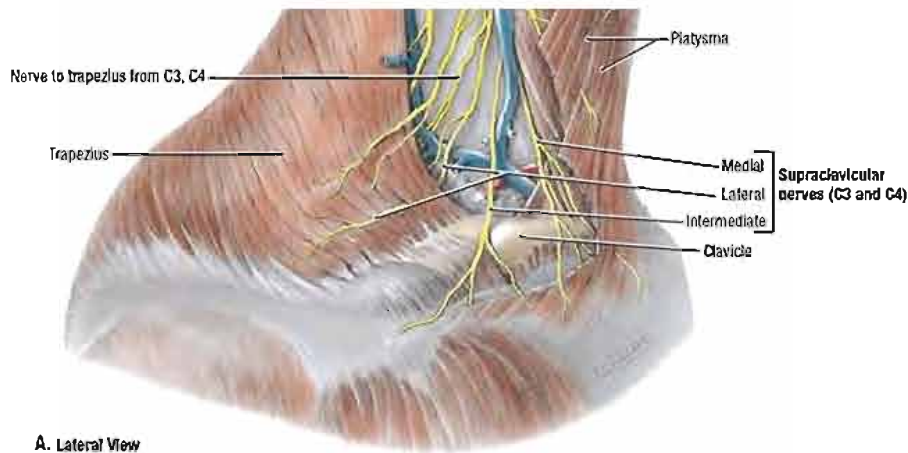
F. Structures of the omoclavicular (subclavian) triangle. The omohyoid muscle and fascia have been removed, exposing the brachial plexus and subclavian vessels.

- The anterior rami of C5–T1 form the brachial plexus (the anterior ramus of T1 lies posterior to the subclavian artery).
- The brachial plexus and subclavian artery emerge between the middle and anterior scalene muscles.
- The anterior scalene muscle lies between the subclavian artery and vein.

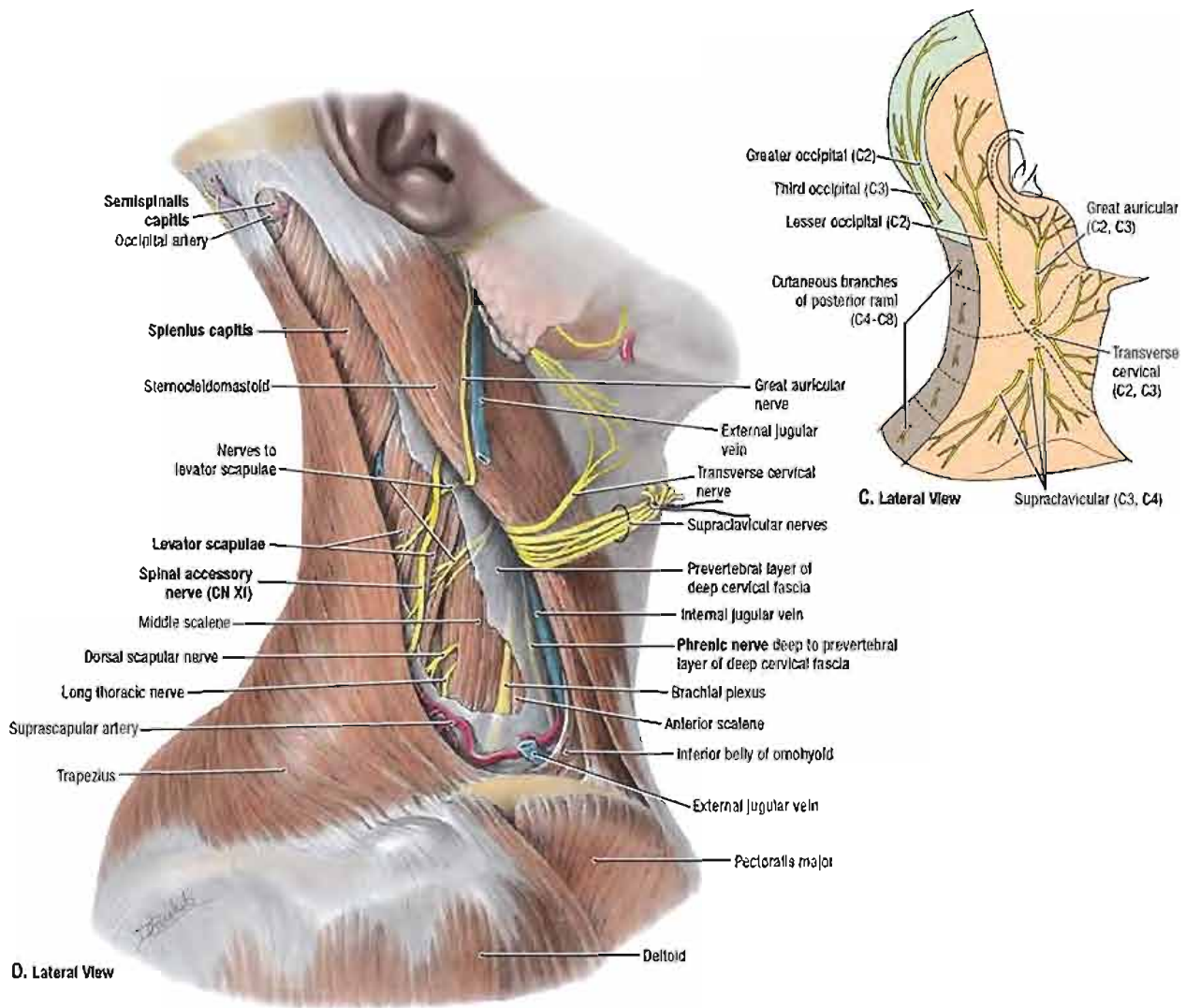
The right or left subclavian vein is often the site of placement for a central venous catheter, used to insert intravenous tubes (‘‘central venous lines’’ • ) for the administration of parenteral nutritional fluids or medications, for testing blood chemistry or central venous pressure, or inserting electrode wires for heart pacemaker devices. The relationships of the subclavian vein to the sternocleidomastoid muscle, clavicle, sternoclavicular joint and 1st rib are of clinical importance in line placement, and there is danger of puncture of the pleura or subclavian artery if the procedure is not performed correctly.

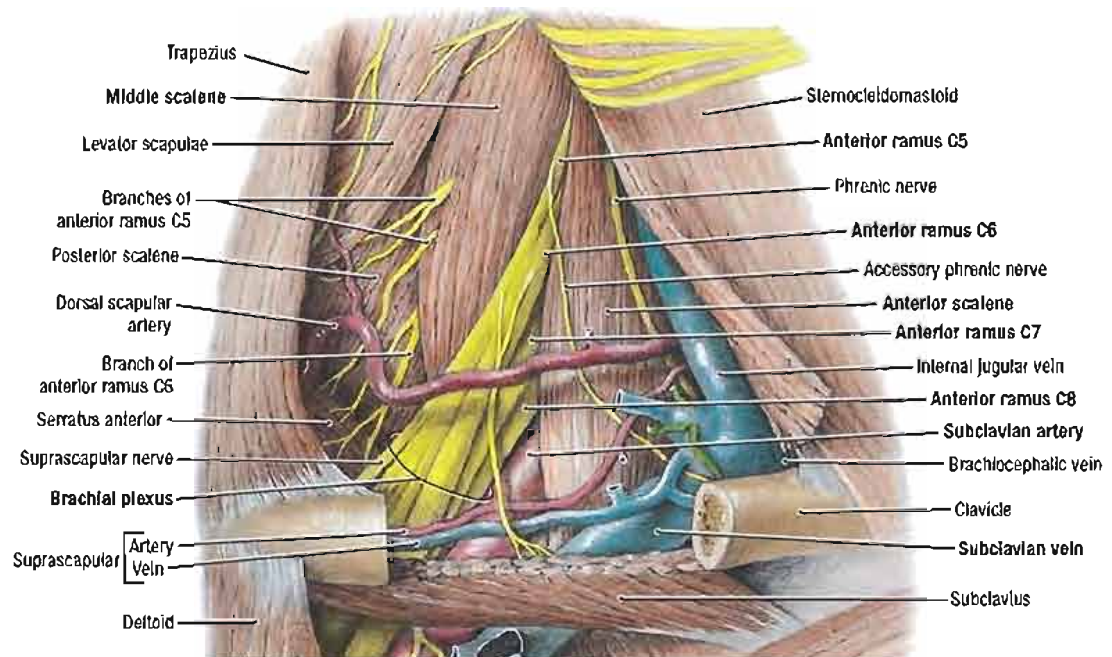
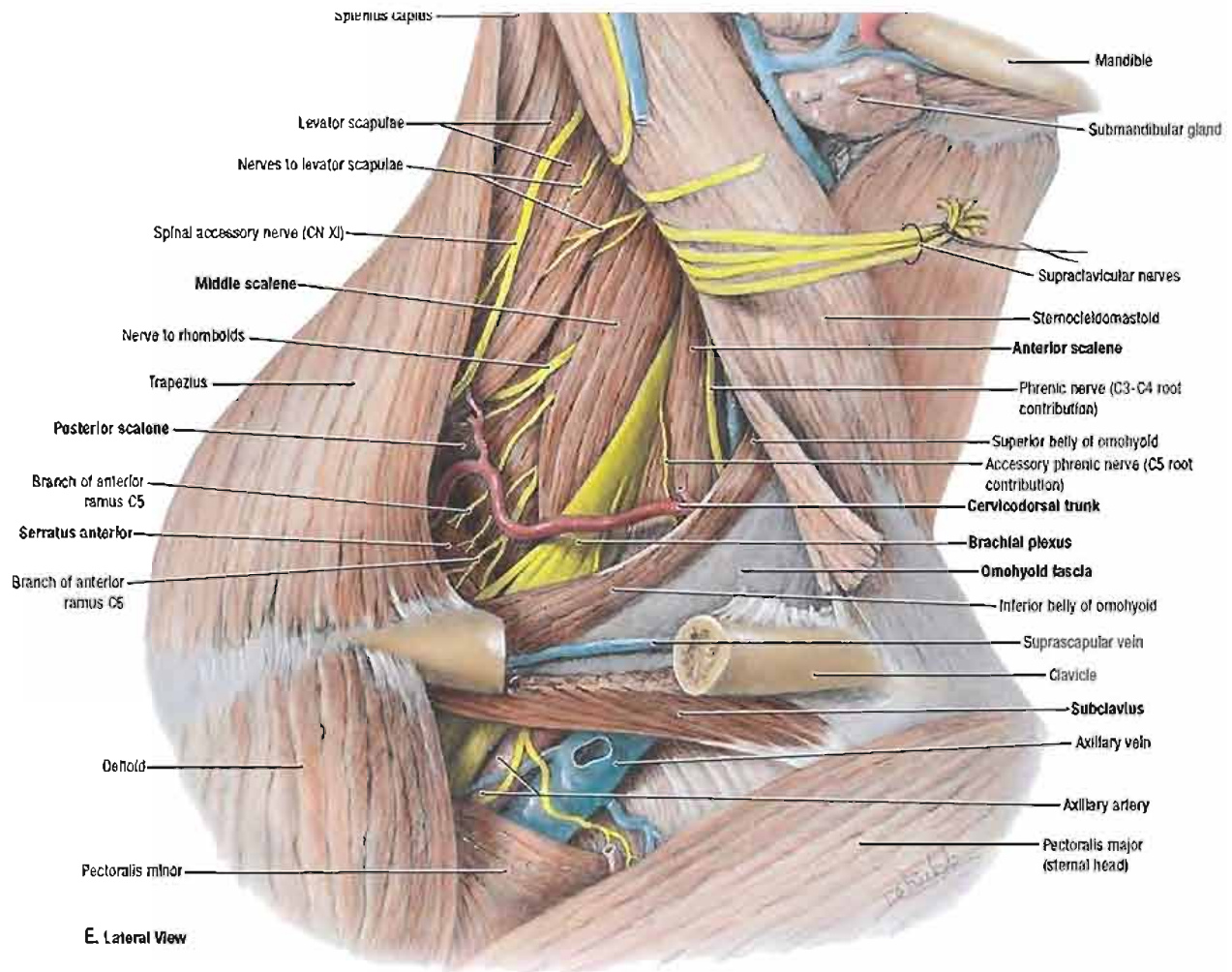




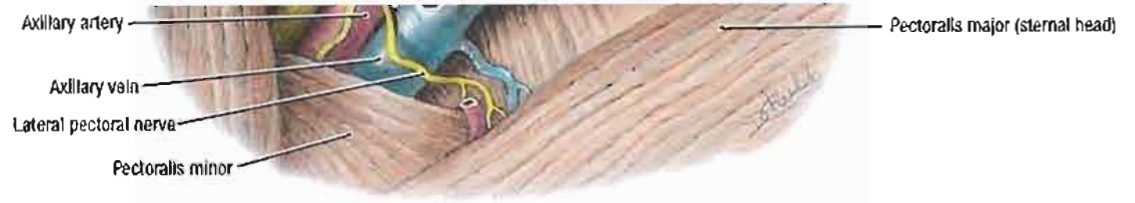

A. Lateral View





**F. Lateral View**



Authors: Agur, Anne M.R.; Dalley, Arthur F.

Title: *Grant's Atlas of Anatomy, 12th Edition*

Copyright ©2009 Lippincott Williams & Wilkins

> Table of Contents > Chapter 8 - Neck > 8.6 Supra- and infrahyoid muscles

---

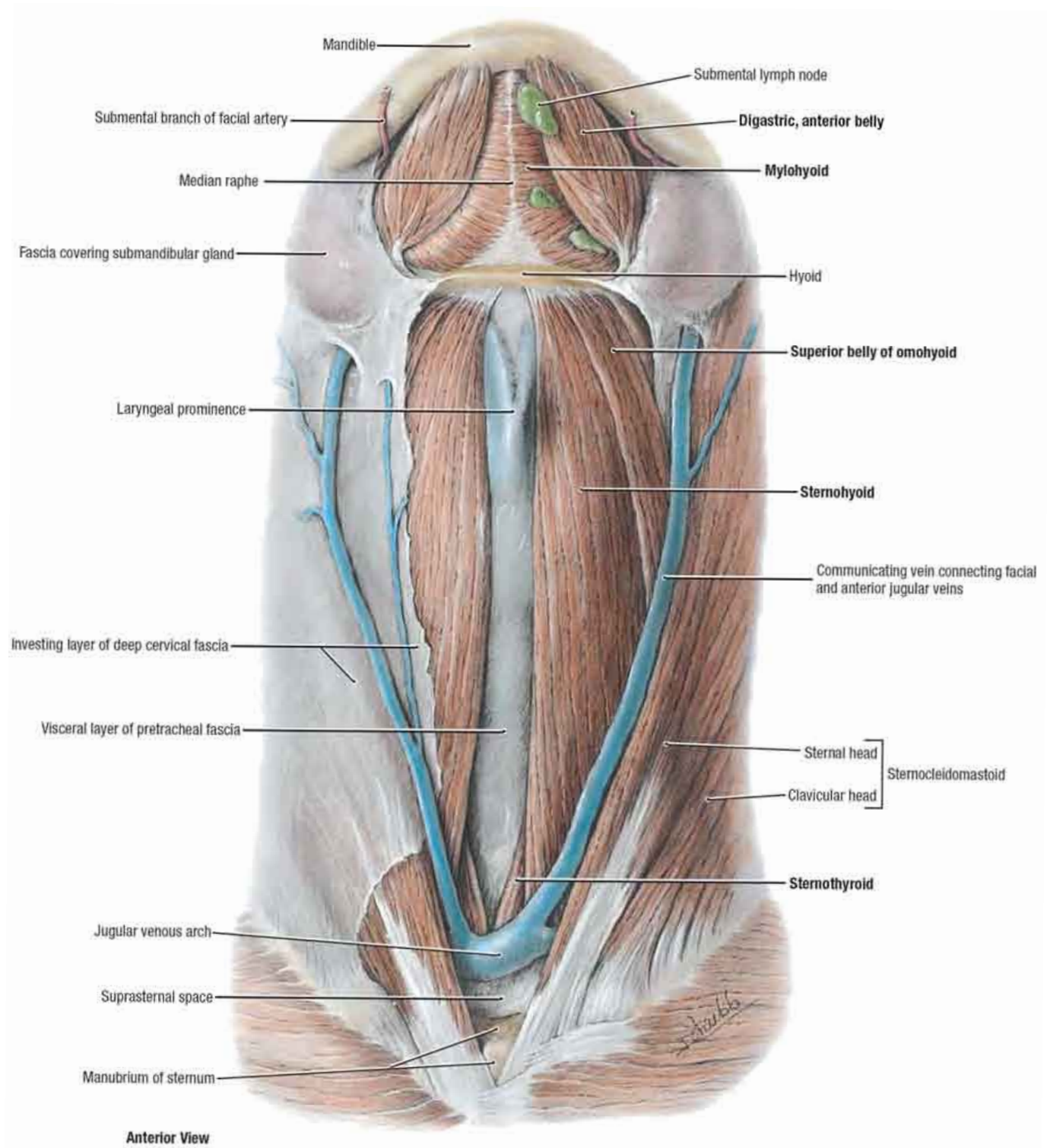
## 8.6 Supra- and infrahyoid muscles

*Part of "Chapter 8 - Neck "*

Much of the investing layer of deep cervical fascia has been removed.

- The anterior bellies of the digastric muscles form the sides of the suprahyoid part of the anterior cervical region, or submental triangle (floor of mouth). The hyoid bone forms the triangle's base, and the mylohyoid muscles are its floor.
- The infrahyoid part of the anterior cervical region is shaped like an elongated diamond bounded by the sternohyoid muscle superiorly and sternothyroid muscle inferiorly.







Authors: Agur, Anne M.R.; Dalley, Arthur F.

Title: *Grant's Atlas of Anatomy, 12th Edition*

Copyright ©2009 Lippincott Williams & Wilkins

> Table of Contents > Chapter 8 - Neck > 8.7 Infrahyoid region, superficial muscular layer

---

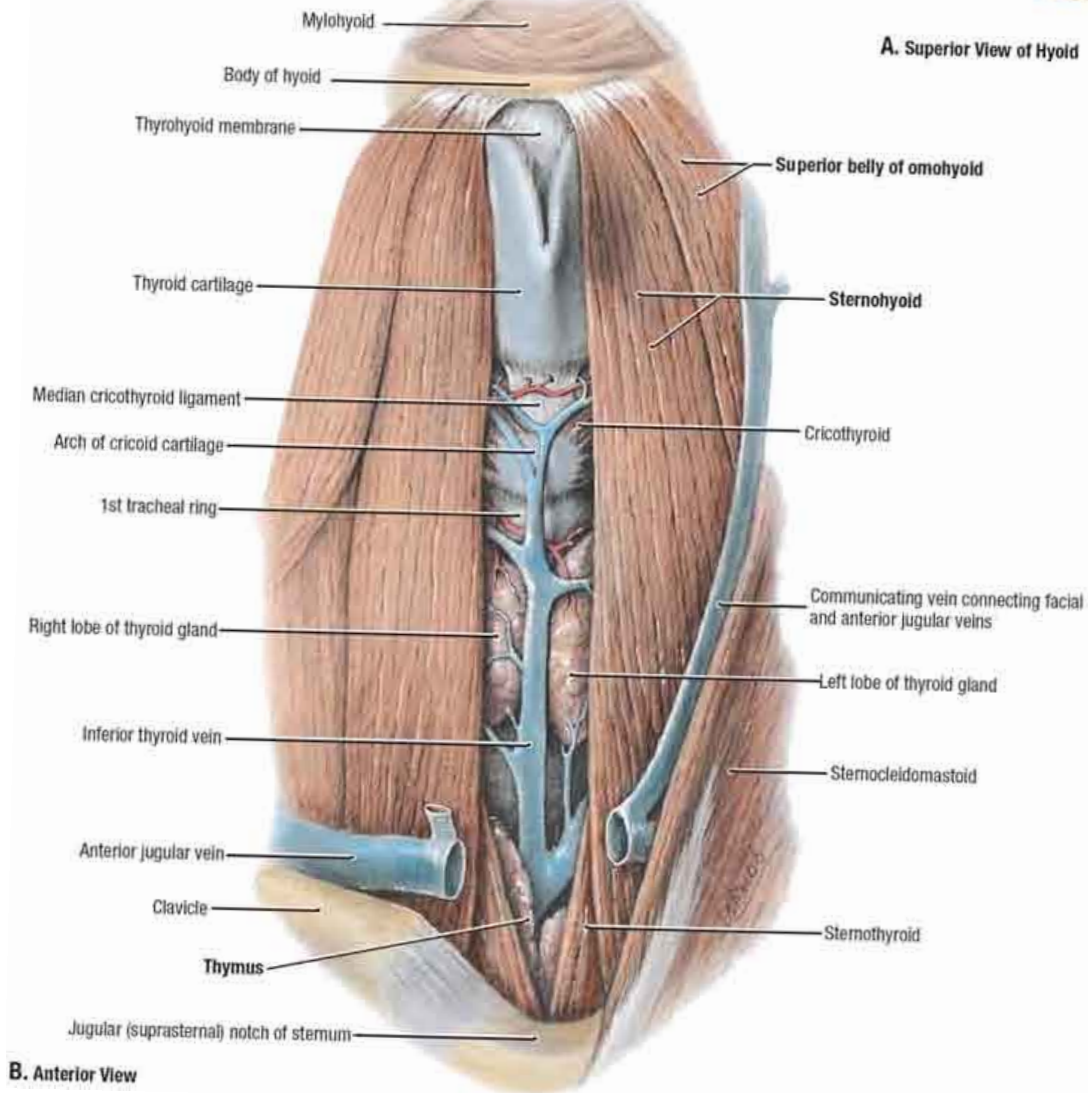
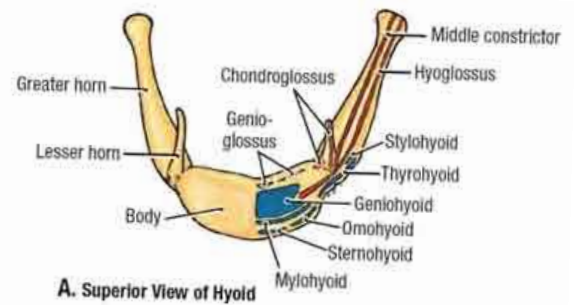
## 8.7 Infrahyoid region, superficial muscular layer

*Part of* "Chapter 8 - Neck "

A. Muscular attachments onto the hyoid bone.

B. The pretracheal fascia, right anterior jugular vein, and jugular venous arch have been removed.

- A persistent thymus projects superiorly from the thorax.
- The two superficial depressors of the larynx (œstrap muscles•) are the omohyoid (only the superior belly of which is seen here) and sternohyoid.



Authors: Agur, Anne M.R.; Dalley, Arthur F.

Title: *Grant's Atlas of Anatomy, 12th Edition*

Copyright ©2009 Lippincott Williams & Wilkins

> Table of Contents > Chapter 8 - Neck > 8.8 Suprahyoid region (submental triangle)

---

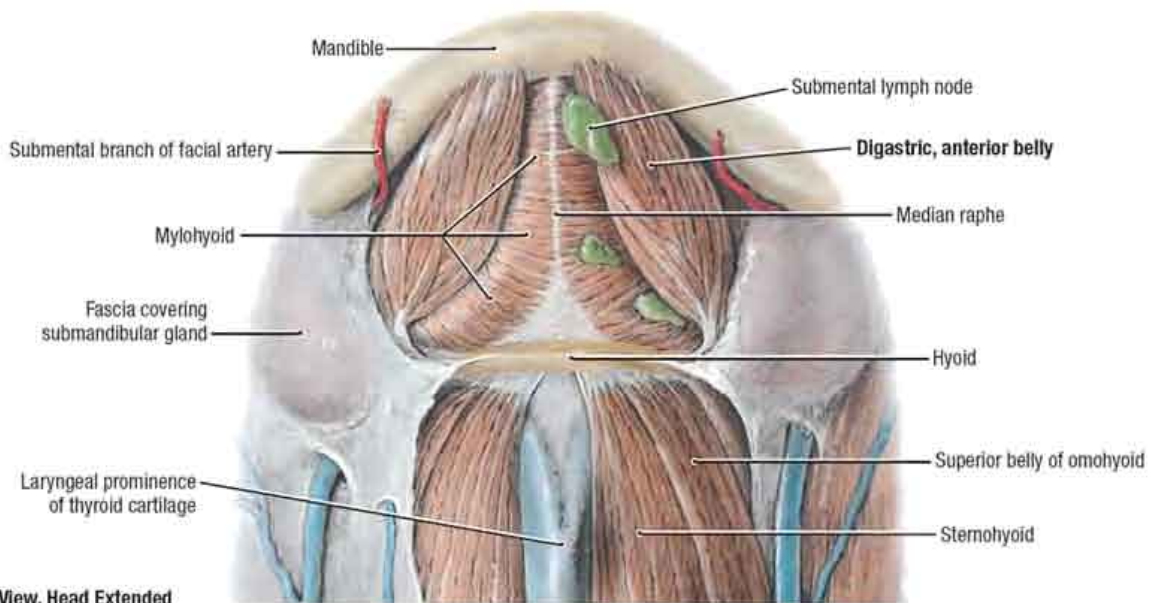
## 8.8 Suprahyoid region (submental triangle)

*Part of* "Chapter 8 - Neck "

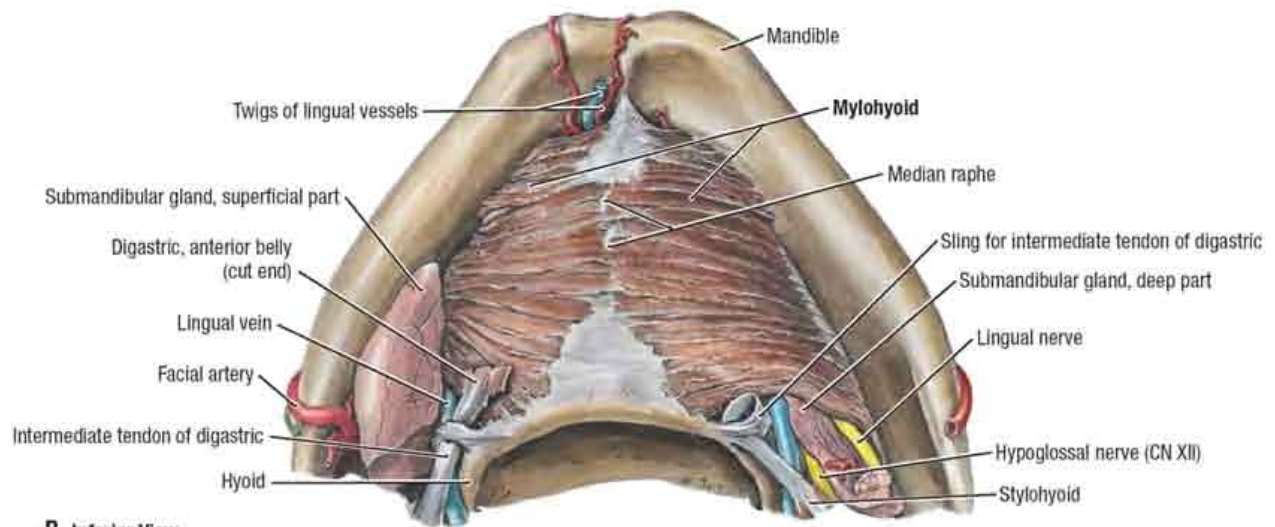
A. Superficial layer— anterior belly of digastric. B. Intermediate layer— mylohyoid muscles. C. Deep layer— geniohyoid muscles.

---

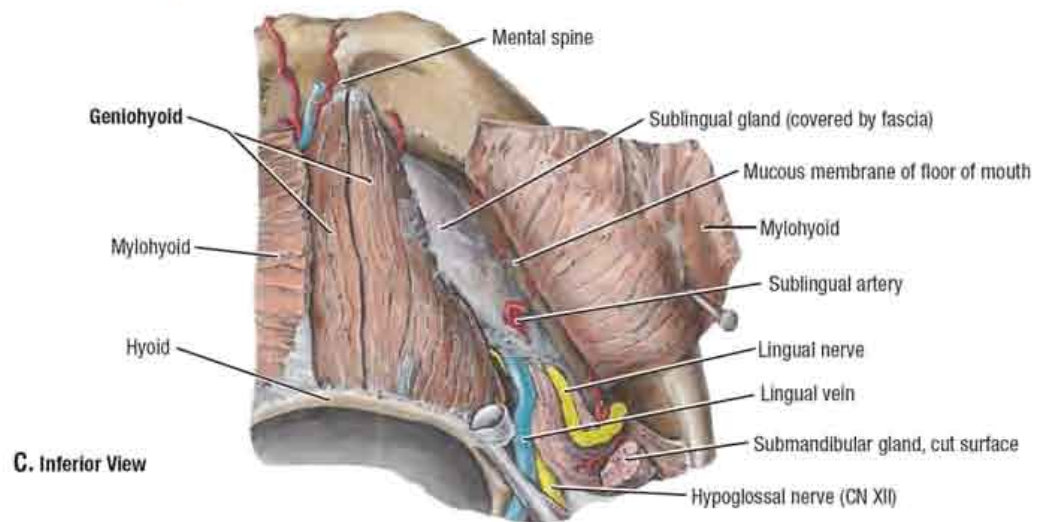
P.761



**A. Anterior View, Head Extended**



**B. Inferior View**



**C. Inferior View**

Suprahyoid muscles

Mylohyoid

Mylohyoid line of mandible

Raphe and body of hyoid bone

Nerve to mylohyoid, a branch of inferior alveolar nerve (CN V<sup>3</sup> )

Elevates hyoid bone, floor of mouth and tongue during swallowing and speaking

Digastric

*Anterior belly:* digastric fossa of mandible

*Posterior belly:* mastoid notch of temporal bone

Intermediate tendon to body and greater horn of hyoid bone

*Anterior belly:* nerve to mylohyoid, a branch of inferior alveolar nerve (CN V<sup>3</sup> ) *Posterior belly:* facial nerve (CN VII)

Elevates hyoid bone and steadies it during swallowing and speaking; depresses mandible against resistance

Geniohyoid

Inferior mental spine of mandible

Body of hyoid bone

C1 via the hypoglossal nerve (CN XII)

Pulls hyoid bone anterosuperiorly, shortens floor of mouth, and widens pharynx

Stylohyoid

Styloid process of temporal bone

Cervical branch of facial nerve (CN VII)

Elevates and retracts hyoid bone, thereby elongating floor of mouth

Infrahyoid muscles

Sternohyoid

Manubrium of sternum and medial end of clavicle

Body of hyoid bone

C1–C3 by a branch of ansa cervicalis

Depresses hyoid bone after it has been elevated during swallowing

Omoxyoid

Superior border of scapula near suprascapular notch

Inferior border of hyoid bone

Depresses, retracts, and steadies hyoid bone

Sternothyroid



Posterior surface of manubrium of sternum

Oblique line of thyroid cartilage

C2 and C3 by a branch of ansa cervicalis

Depresses hyoid bone and larynx

Thyrohyoid

Oblique line of thyroid cartilage

Inferior border of body and greater horn of hyoid bone

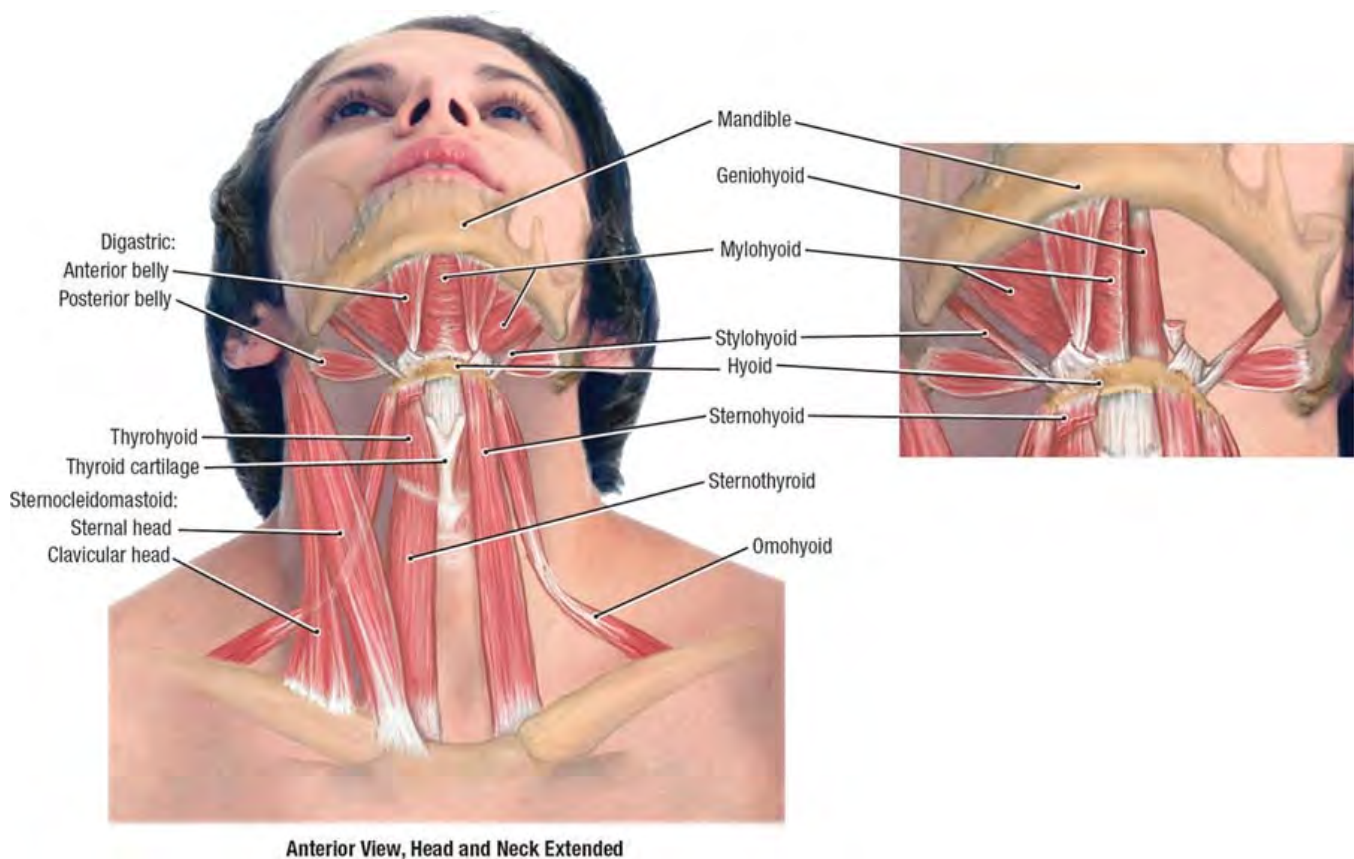
C1 via hypoglossal nerve (CN XII)

Depresses hyoid bone and elevates larynx

Muscle	Origin	Insertion	Innervation	Main Action
--------	--------	-----------	-------------	-------------

Table 8.4 Suprahyoid and Infrahyoid Muscles

P.762



Authors: Agur, Anne M.R.; Dalley, Arthur F.

Title: *Grant's Atlas of Anatomy, 12th Edition*

Copyright ©2009 Lippincott Williams & Wilkins

> Table of Contents > Chapter 8 - Neck > 8.9 Superficial dissection of carotid triangle

---

## 8.9 Superficial dissection of carotid triangle

*Part of* "Chapter 8 - Neck "

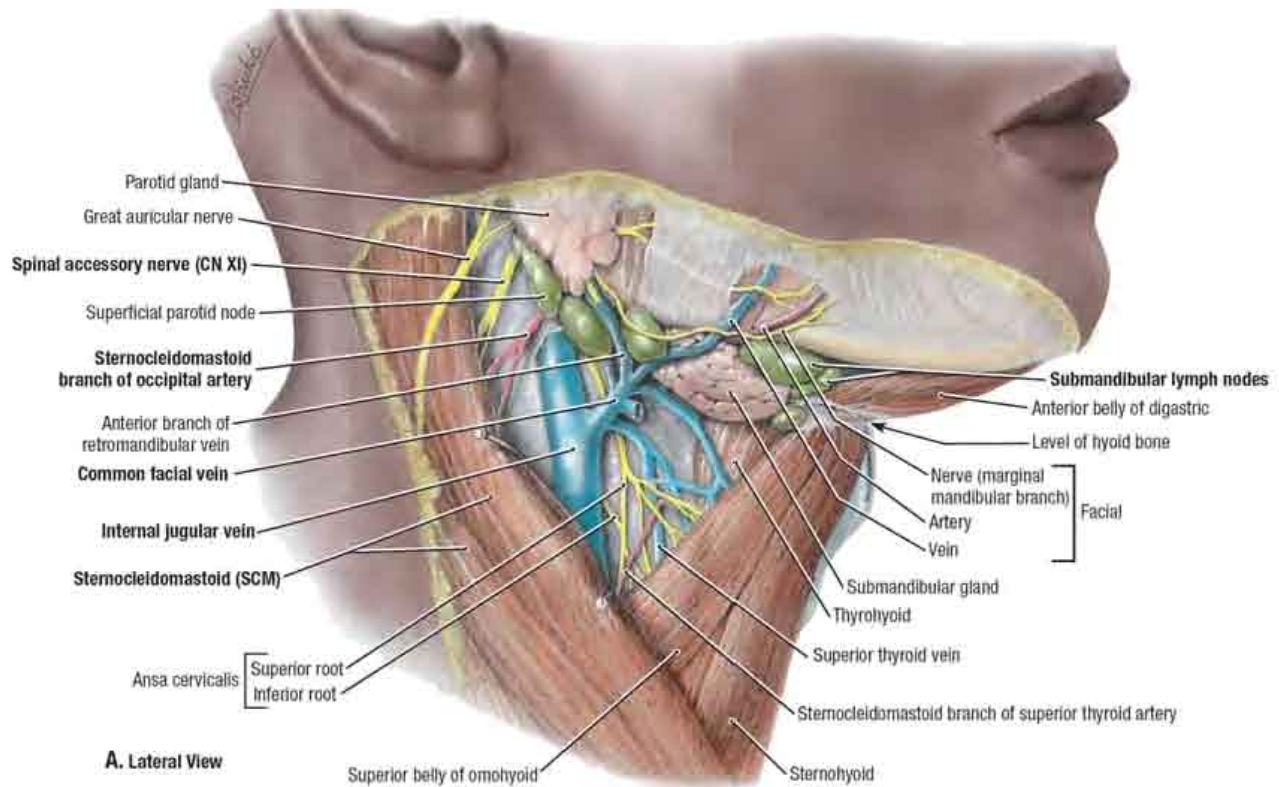
A. The skin, subcutaneous tissue (with platysma), and the investing layer of deep cervical fascia, including the sheaths of the parotid and submandibular glands, have been removed.

- The spinal accessory nerve (XI) enters the deep surface of the sternocleidomastoid muscle and is joined along its anterior border by the sternocleidomastoid branch of the occipital artery.
- The (common) facial vein joins the internal jugular vein near the level of the hyoid bone; here, the facial vein is joined by several other veins.
- The submandibular lymph nodes lie deep to the investing layer of deep cervical fascia in the submandibular triangle; some of the nodes lie deep in the submandibular gland.

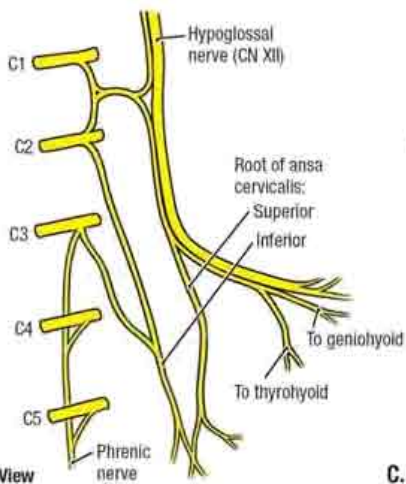
B. Diagram of the motor branches of cervical plexus.

C. Typical relationships of ansa cervicalis, spinal accessory nerve (CN XI), and phrenic nerve to the internal jugular and subclavian veins.

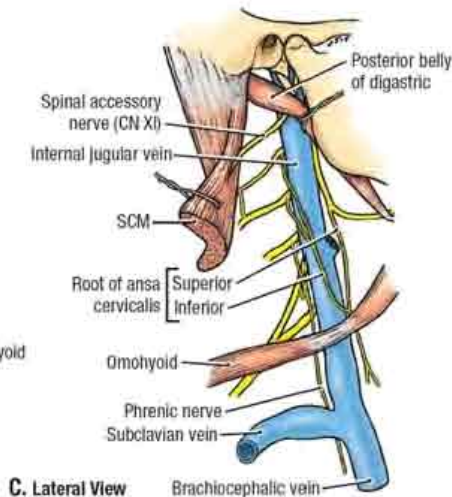
D. Atypical relationships.



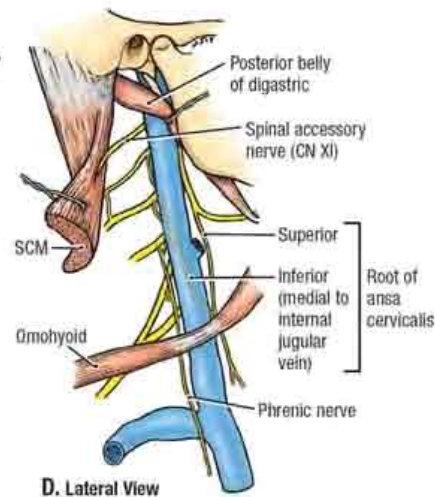
**A. Lateral View**



**B. Lateral View**



**C. Lateral View**



**D. Lateral View**

Authors: Agur, Anne M.R.; Dalley, Arthur F.

Title: *Grant's Atlas of Anatomy, 12th Edition*

Copyright ©2009 Lippincott Williams & Wilkins

> Table of Contents > Chapter 8 - Neck > 8.10 Deep dissection of carotid triangle

---

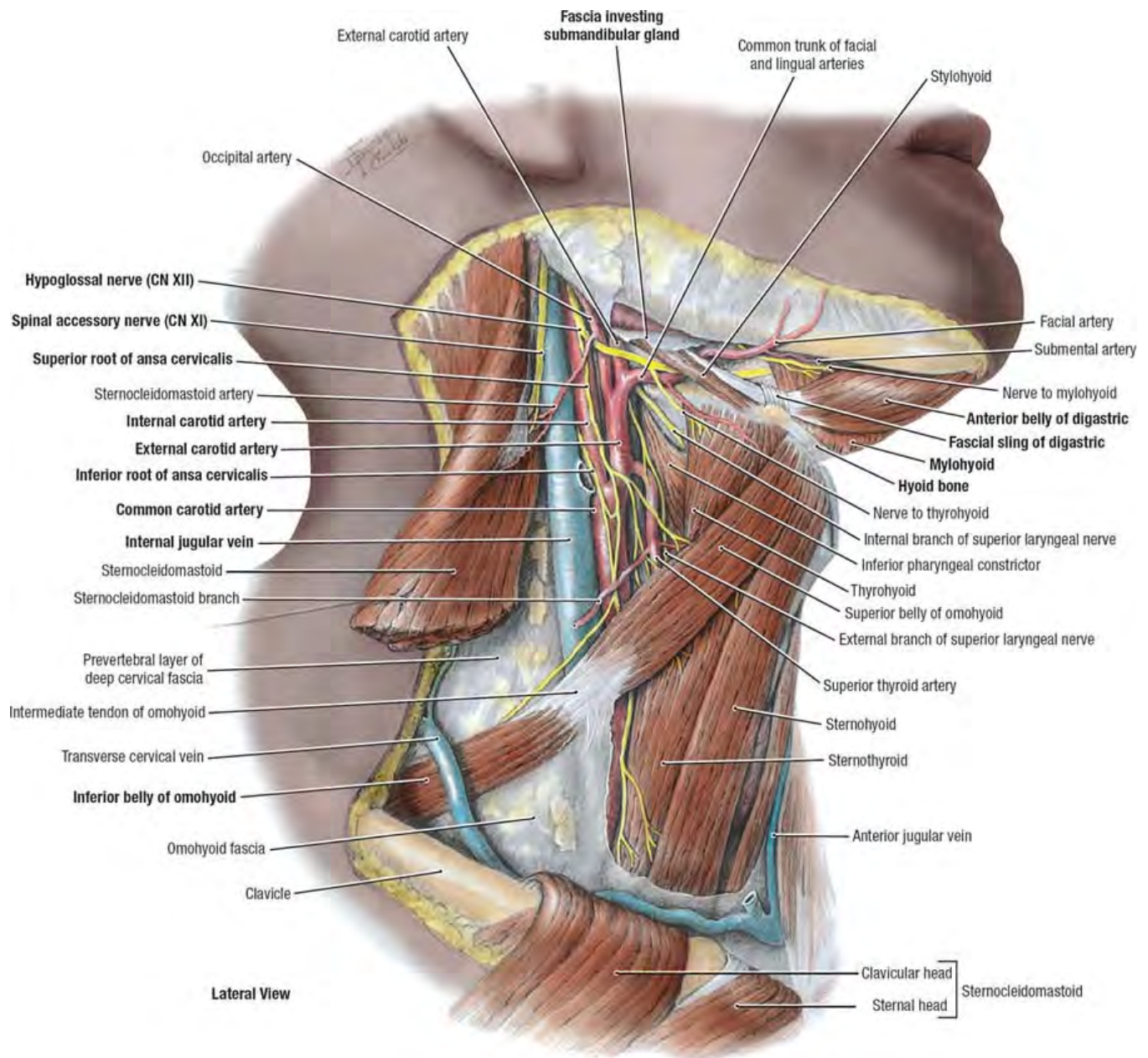
## 8.10 Deep dissection of carotid triangle

*Part of* "Chapter 8 - Neck "

The sternocleidomastoid muscle has been severed; the inferior portion reflected inferiorly and superior portion posteriorly.

- The tendon of the digastric muscle is connected to the hyoid bone by a fascial sling derived from the muscular part of the pretracheal layer of deep cervical fascia; the tendon of the omohyoid muscle is similarly tethered to the clavicle.
- In this specimen, the facial and lingual arteries arise from a common trunk and pass deep to the stylohyoid and digastric muscles.
- The hypoglossal nerve (CN XII) crosses the internal and external carotid arteries and gives off two branches, the superior root of the ansa cervicalis and the nerve to the thyrohyoid, before passing anteriorly deep to the mylohyoid muscle. In this specimen, the inferior root of the ansa cervicalis lies deep to the internal jugular vein and emerges at its medial aspect.





Right common carotid

Bifurcation of brachiocephalic trunk

Ascends in neck within carotid sheath with the internal jugular vein and vagus nerve (CN X). Terminates at superior border of thyroid cartilage (C4 vertebral level) by dividing into internal and external carotid arteries

Left common carotid

Arch of aorta

Right and left common carotid



Right and left external

No branches in the neck. Enters cranium via carotid canal to supply brain and orbits.

Proximal part location of carotid sinus, a baroreceptor that reacts to change in arterial blood pressure. The carotid body, a chemoreceptor that monitors oxygen level in blood, is located in bifurcation of common carotid

Right and left internal carotid

Supplies most structures external to cranium; the orbit, part of forehead, and scalp are major exceptions (supplied by ophthalmic artery from intracranial internal carotid artery)

Ascending pharyngeal

External carotid

Ascends on pharynx to supply pharynx, prevertebral muscles, middle ear, and cranial meninges

Occipital

Passes posteriorly, medial and parallel to the posterior belly of digastric, ending in the posterior scalp

Posterior auricular

Ascends posteriorly between external acoustic meatus and mastoid process to supply adjacent muscles, parotid gland, facial nerve, auricle, and scalp

Superior thyroid

Runs anteroinferiorly deep to infrahyoid muscles to reach thyroid gland. Supplies thyroid gland, infrahyoid muscles, SCM, and larynx via *superior laryngeal artery*

Lingual

Lies on middle constrictor muscle of pharynx; arches superoanteriorly and passes deep to CN XIII, stylohyoid muscle, and posterior belly of digastric then passes deep to hyoglossus, giving branches to the posterior tongue and bifurcating into *deep lingual* and *sublingual arteries*

Facial

After giving rise to *ascending palatine artery* and a tonsillar branch, it passes superiorly under cover of the angle of the mandible. It then loops anteriorly to supply the submandibular gland and give rise to the *submental artery* to the floor of the mouth before entering the face

Maxillary

Terminal branches of external carotid

Passes posterior to neck of mandible, enters infratemporal fossa then pterygopalatine

fossa to supply teeth, nose, ear, and face

Superficial temporal

Ascends anterior to auricle to temporal region and ends in scalp

Vertebral

Subclavian

Passes through the transverse foramina of the transverse processes of vertebrae C1–C6, runs in a groove on the posterior arch of the atlas, and enters the cranial cavity through the foramen magnum

Internal thoracic

No branches in neck; enters thorax

Thyrocervical trunk

Has two branches: the *inferior thyroid artery*, the main visceral artery of the neck; the cervicodorsal trunk sending branches to the lateral cervical region, trapezius, and medial scapular arteries

Costocervical trunk

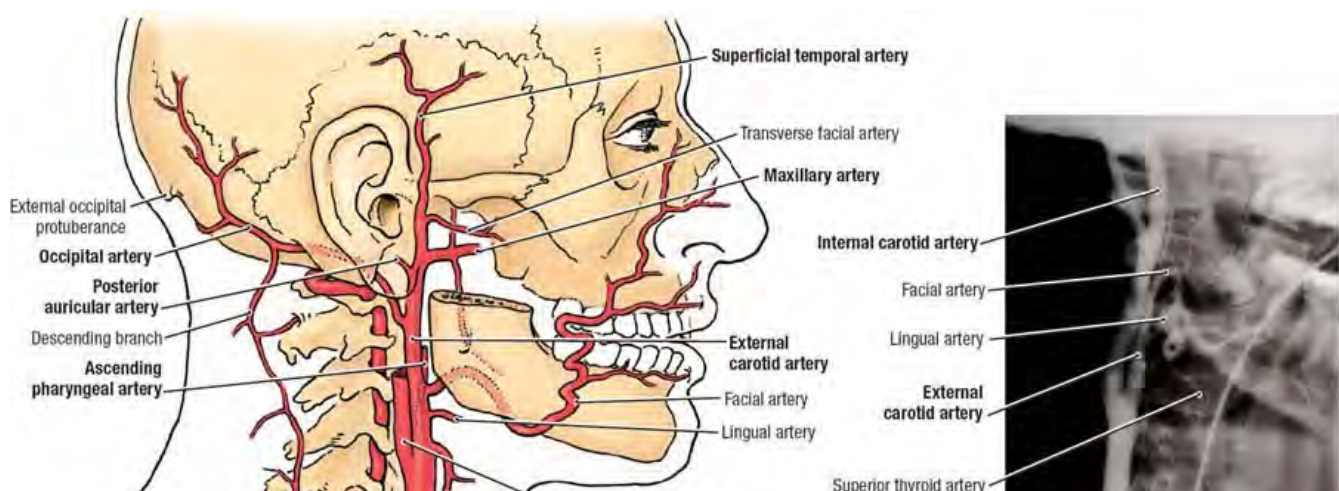
Trunk passes posterosuperiorly and divides into *superior intercostal* and *deep cervical arteries* to supply the 1st and 2nd intercostal spaces and posterior deep cervical muscles, respectively

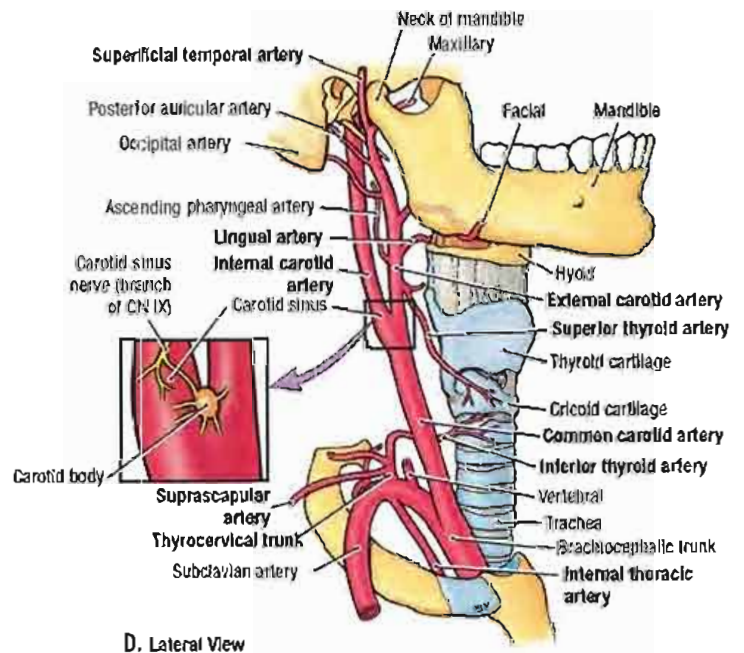
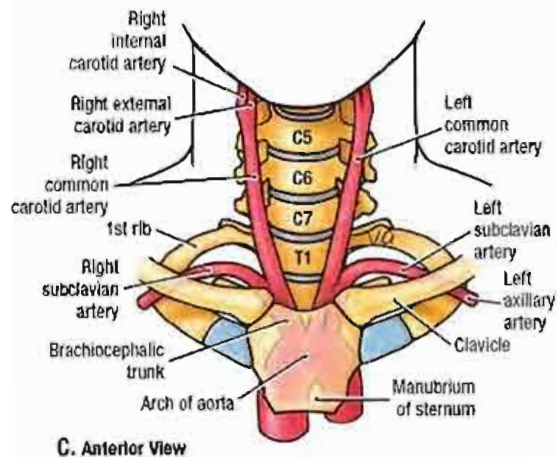
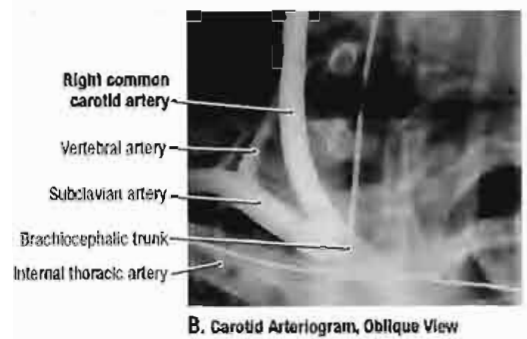
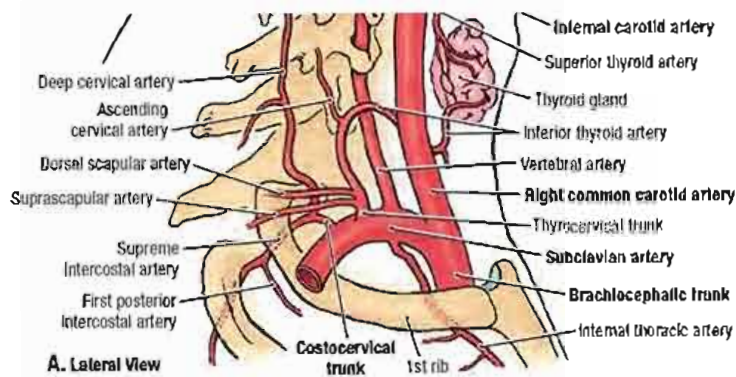
Artery    Origin    Course and Distribution

Table 8.5 Arteries of The Neck

P.765

P.766





Authors: Agur, Anne M.R.; Dalley, Arthur F.

Title: *Grant's Atlas of Anatomy, 12th Edition*

Copyright ©2009 Lippincott Williams & Wilkins

> Table of Contents > Chapter 8 - Neck > 8.11 Relationships of nerves and vessels in the carotid triangle of the neck

---

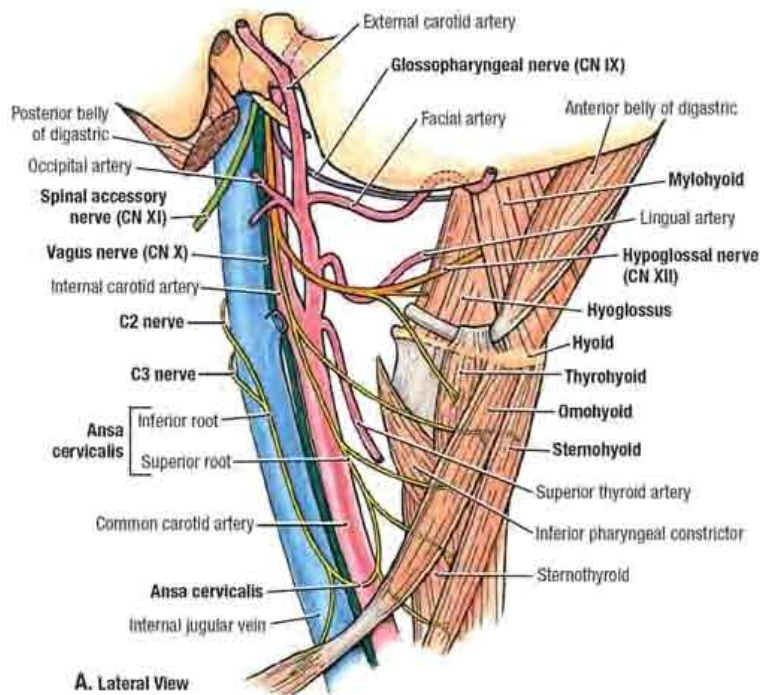
## 8.11 Relationships of nerves and vessels in the carotid triangle of the neck

*Part of "Chapter 8 - Neck "*

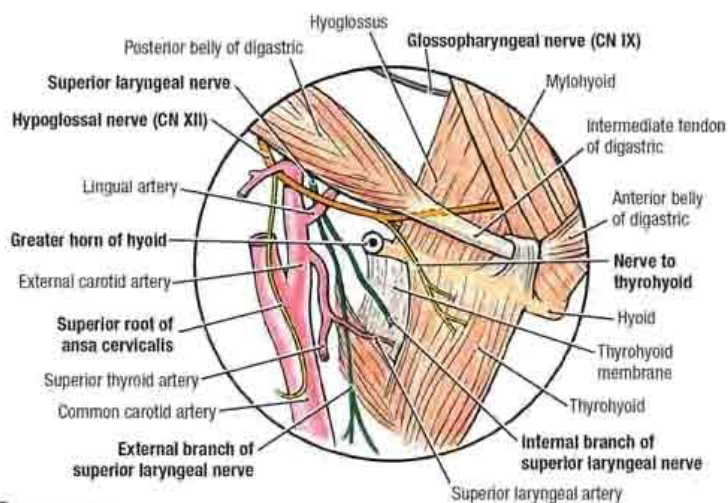
A. Ansa cervicalis and the strap muscles. B. Hypoglossal nerve (CN XII) and internal and external branches of superior laryngeal nerve (CN X). The tip of the greater hyoid bone, indicated with a *circle* is the reference point for many structures. C. Variation in the origin of the lingual artery as studied by Dr. Grant in 211 specimens. In 80%, the superior thyroid, lingual, and facial arteries arose separately (C) ; in 20%, the lingual and facial arteries arose from a common stem inferiorly (D) or high on the external carotid artery (E) . In one specimen, the superior thyroid and lingual arteries arose from a common stem.

*Carotid occlusion* , causing stenosis (narrowing) can be relieved by opening the artery at its origin and stripping off the atherosclerotic plaque with the artery's lining (intima). This procedure is called carotid endarterectomy. Because of the relationships of the internal carotid artery, there is a risk of cranial nerve injury during the procedure involving one or more of the following nerves: CN IX, CN X (or its branch, the superior laryngeal nerve), CN XI, or CN XII.



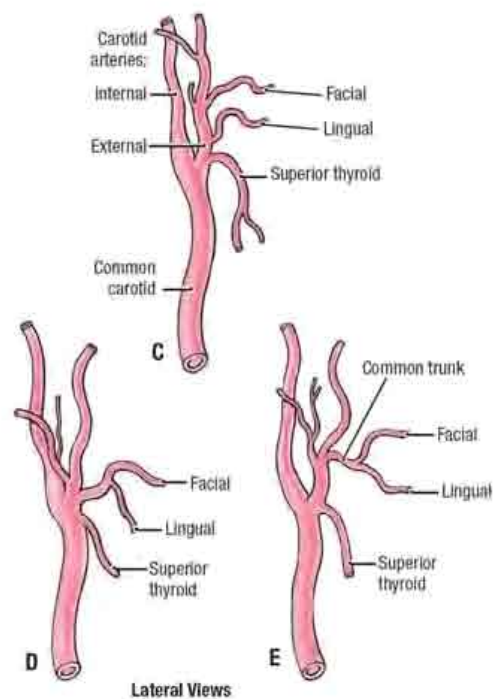


A. Lateral View



B. Lateral View

<b>Glossopharyngeal—CN IX</b> <b>Motor:</b> stylopharyngeus, parotid gland <b>Sensory:</b> taste; posterior third of tongue; general sensation: pharynx, tonsillar sinus, pharyngotympanic tube, middle ear cavity	<b>Vagus—CN X</b> <b>Motor:</b> palate, pharynx, larynx, trachea, bronchial tree, heart, GI tract to left colic flexure <b>Sensory:</b> pharynx, larynx; reflex sensory from tracheo-bronchial tree, lungs, heart, GI tract to left colic flexure
<b>Spinal accessory—CN XI</b> <b>Motor:</b> sternocleidomastoid and trapezius	<b>Hypoglossal—CN XII</b> <b>Motor:</b> all intrinsic and extrinsic muscles of tongue (excluding palatoglossus—a palatine muscle)



Lateral Views



Authors: Agur, Anne M.R.; Dalley, Arthur F.

Title: *Grant's Atlas of Anatomy, 12th Edition*

Copyright ©2009 Lippincott Williams & Wilkins

> Table of Contents > Chapter 8 - Neck > 8.12 Deep veins of the neck

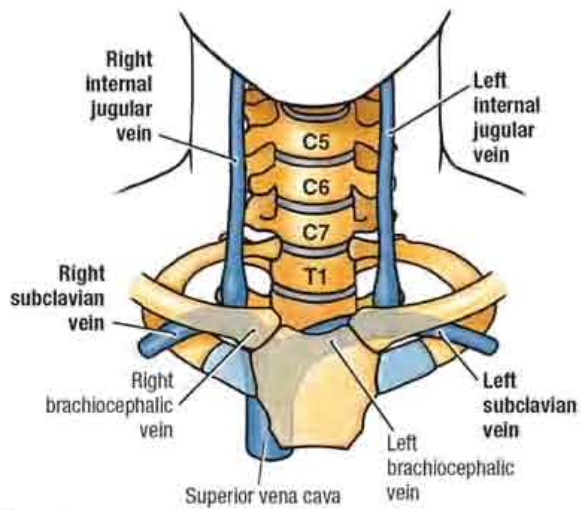
---

## 8.12 Deep veins of the neck

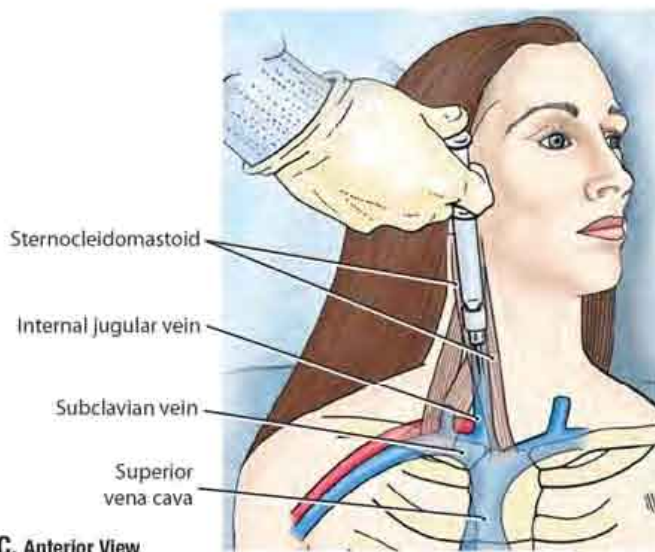
*Part of* "Chapter 8 - Neck "

A. Internal jugular and subclavian veins. B. Tributaries of the internal jugular vein (IJV). The IJV begins at the jugular foramen as the continuation of the sigmoid sinus. From a dilated origin, the superior bulb of the IJV, the vein runs inferiorly through the neck in the carotid sheath. Posterior to the sternal end of the clavicle the vein merges perpendicularly with the subclavian vein, forming the "œvenous angle"• that marks the origin of the brachiocephalic vein. The inferior end of the IJV dilates superior to its terminal valve, forming the inferior bulb of the IJV. The valve permits blood to flow toward the heart while preventing backflow into the IJV.

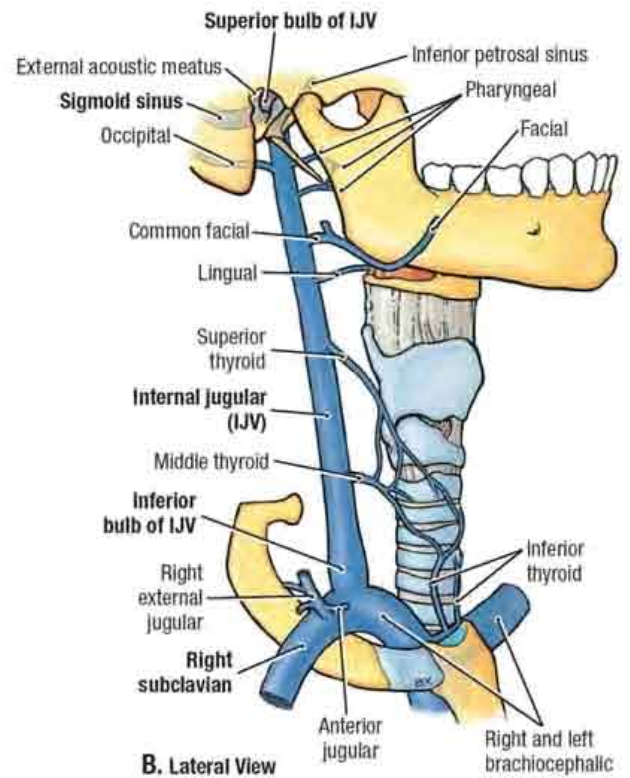
C. Internal jugular vein puncture. A needle and catheter may be inserted into the IJV for diagnostic or therapeutic purposes. The right internal jugular vein is preferable because it is usually larger and straighter. During this procedure, the clinician palpates the common carotid artery and inserts the needle into the IJV just lateral to it at a 30° angle, aiming at the apex of the triangle between the sternal and clavicular heads of the SCM. The needle is then directed inferolaterally toward the ipsilateral nipple.



**A. Anterior View**



**C. Anterior View**



**B. Lateral View**

Authors: Agur, Anne M.R.; Dalley, Arthur F.

Title: *Grant's Atlas of Anatomy, 12th Edition*

Copyright ©2009 Lippincott Williams & Wilkins

> Table of Contents > Chapter 8 - Neck > 8.13 Endocrine layer of visceral compartment

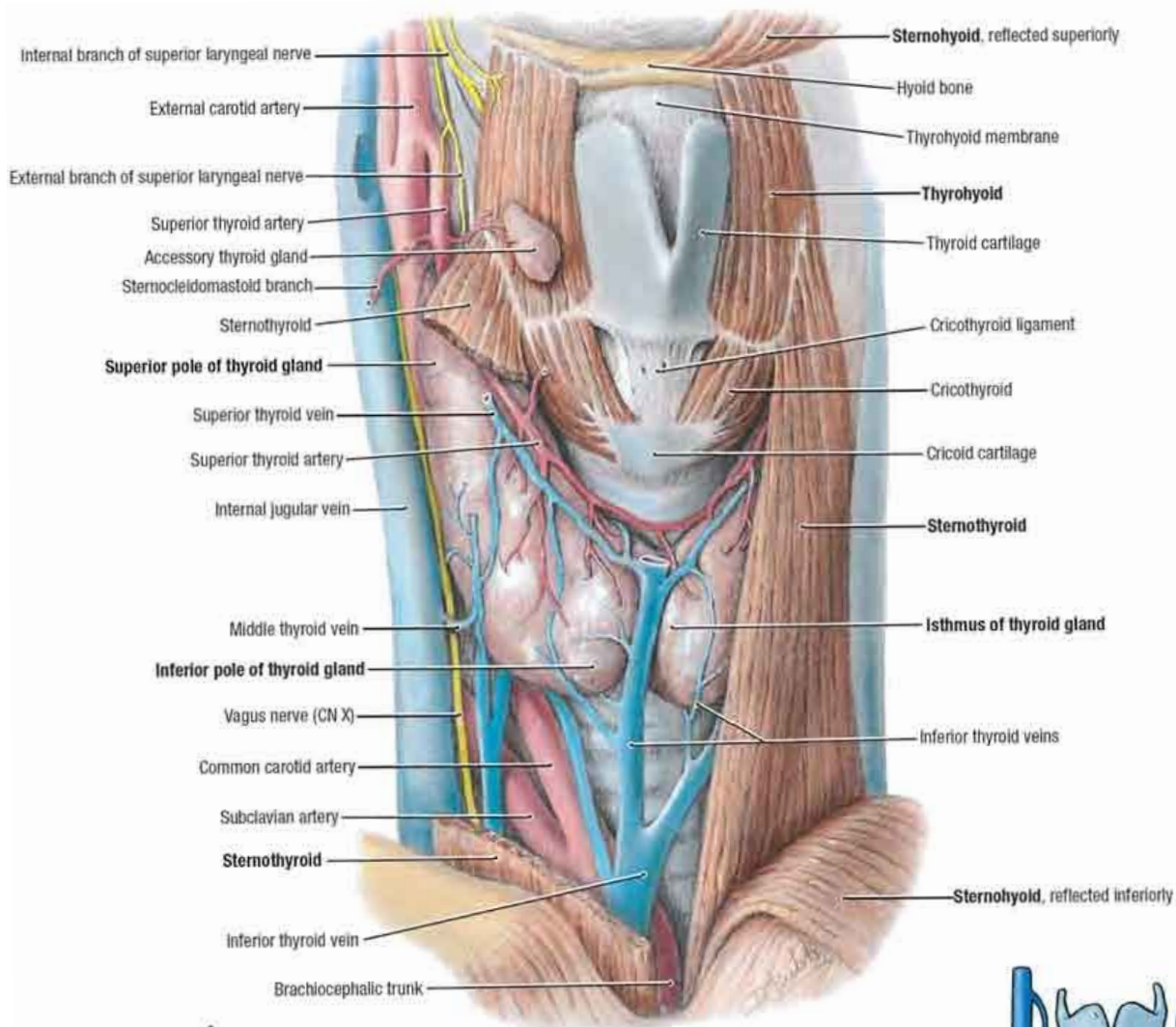
---

## 8.13 Endocrine layer of visceral compartment

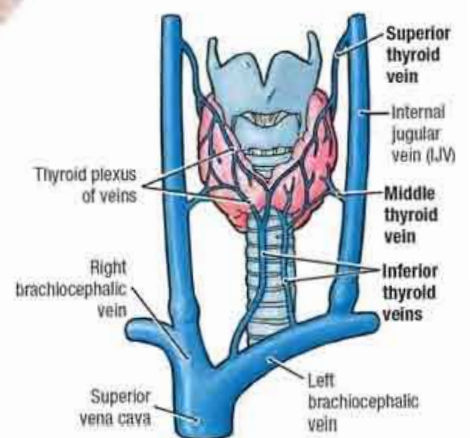
*Part of* "Chapter 8 - Neck "

A. On the left side of the specimen, the sternohyoid and omohyoid muscles are reflected, exposing the sternothyroid and the thyrohyoid muscles; on the right side of the specimen, the sternothyroid muscle is largely excised. B. Schematic illustration of the venous drainage of the thyroid gland. Except for the superior thyroid veins, the thyroid veins are not paired with arteries of corresponding names.

The carotid pulse (neck pulse) is easily felt by palpating the common carotid artery in the side of the neck, where it lies in a groove between the trachea and the infrahyoid muscles. It is usually easily palpated just deep to the anterior border of the SCM at the level of the superior border of the thyroid cartilage. It is routinely checked during cardiopulmonary resuscitation (CPR). Absence of a carotid pulse indicates cardiac arrest.



**A. Anterior View**



**B. Anterior View**

Authors: Agur, Anne M.R.; Dalley, Arthur F.

Title: *Grant's Atlas of Anatomy, 12th Edition*

Copyright ©2009 Lippincott Williams & Wilkins

> Table of Contents > Chapter 8 - Neck > 8.14 Endocrine layer of visceral compartment II

---

## 8.14 Endocrine layer of visceral compartment II

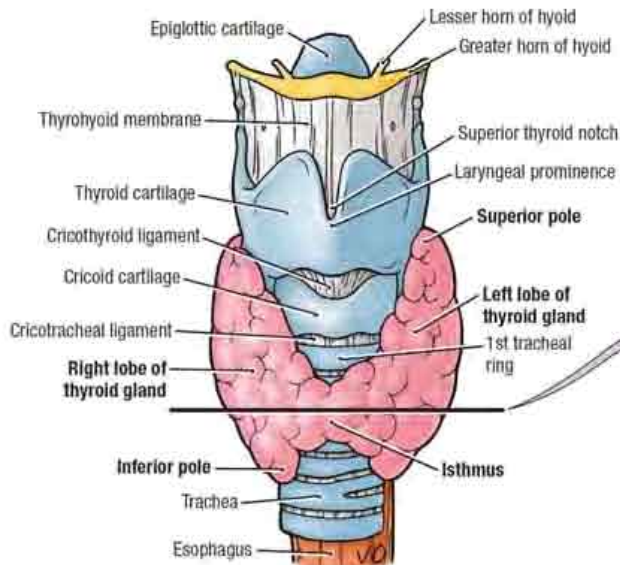
*Part of* "Chapter 8 - Neck "

A. Relations of thyroid gland with transverse section showing alimentary, respiratory, and endocrine layers of visceral compartment. B. Fascia. C. Accessory thyroid tissue along the course of the thyroglossal duct. D. Approximately 50% of glands have a pyramidal lobe that extends from near the isthmus to or toward the hyoid bone; the isthmus is occasionally absent, in which case the gland is in two parts. E. An accessory thyroid gland can occur between the suprahyoid region and arch of the aorta (see Fig. 8.13A ).

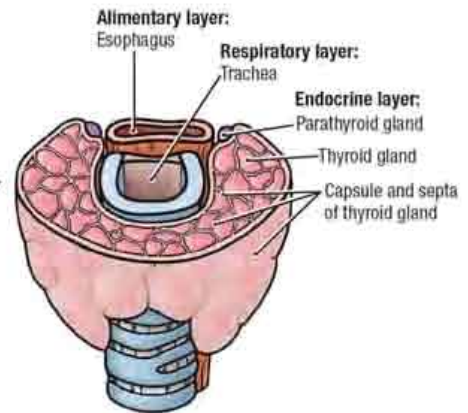
---

P.770

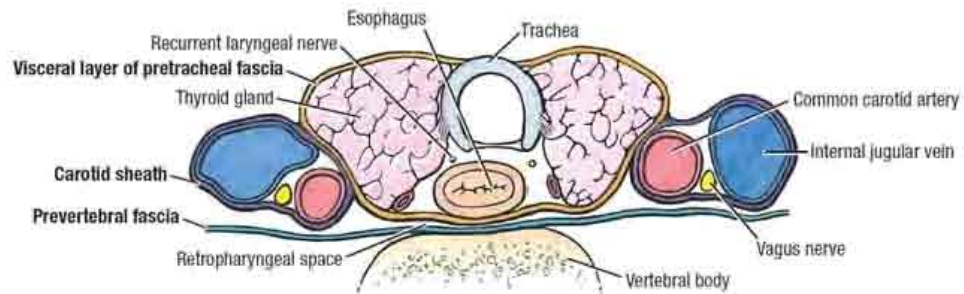




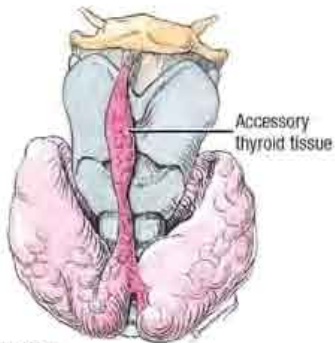
**A. Anterior View**



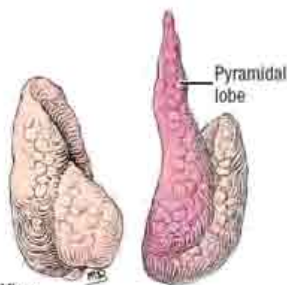
**Anterosuperior View**



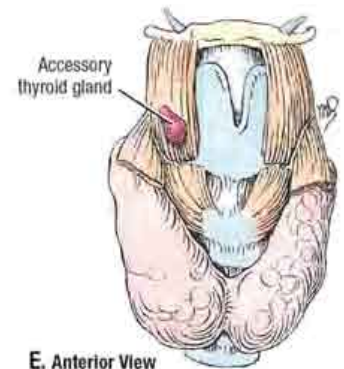
**B. Transverse Section, Inferior View**



**C. Anterior View**



**D. Anterior View**



**E. Anterior View**

Authors: Agur, Anne M.R.; Dalley, Arthur F.

Title: *Grant's Atlas of Anatomy, 12th Edition*

Copyright ©2009 Lippincott Williams & Wilkins

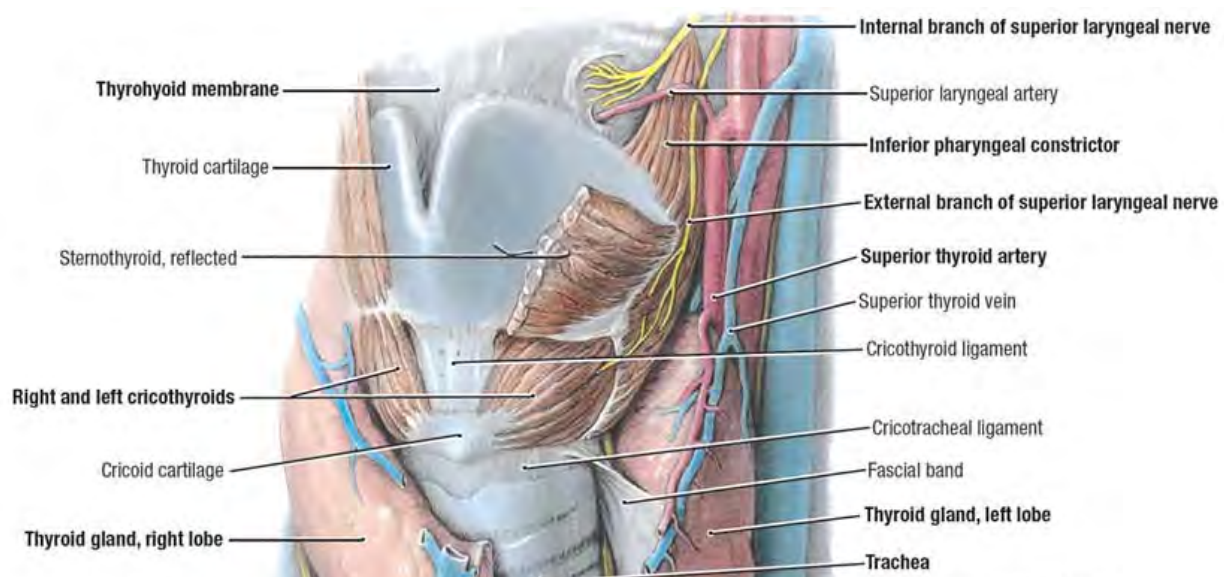
> Table of Contents > Chapter 8 - Neck > 8.15 Respiratory layer of visceral compartment

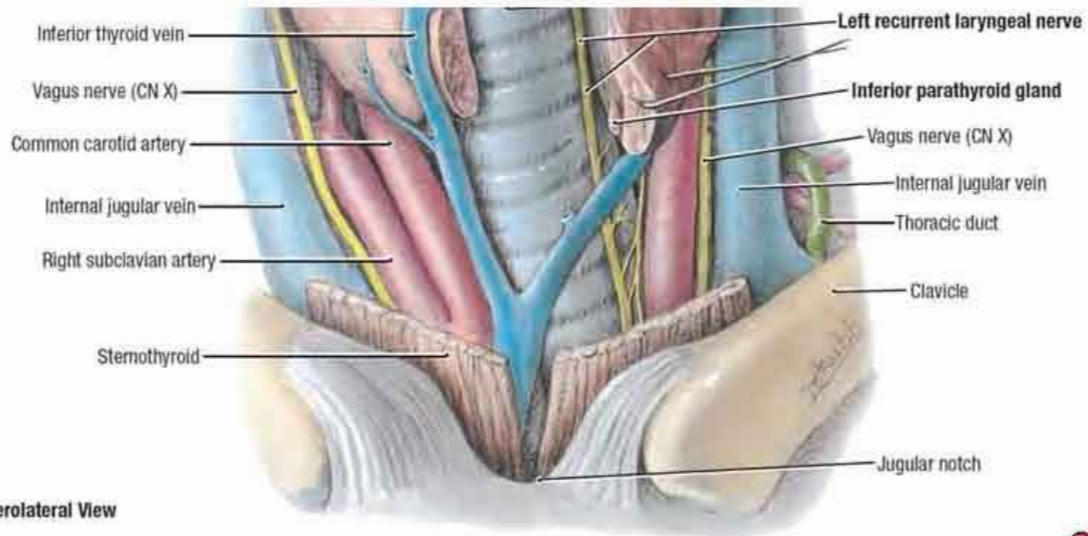
## 8.15 Respiratory layer of visceral compartment

*Part of* "Chapter 8 - Neck "

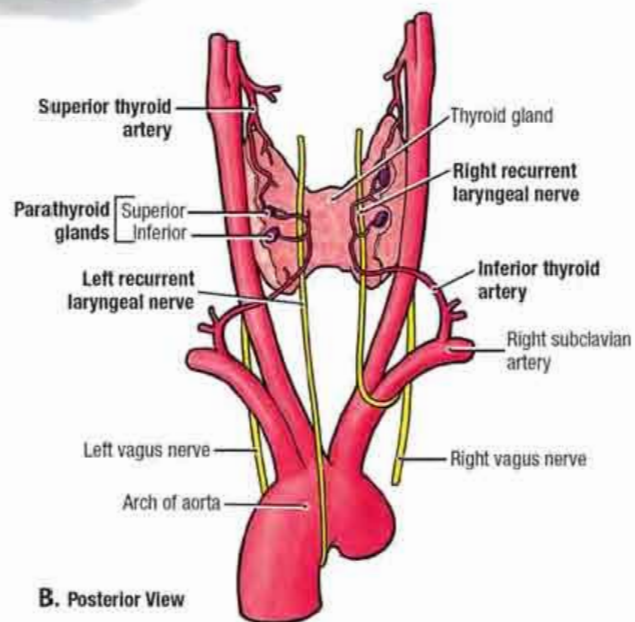
A. The isthmus of the thyroid gland is divided, and the left lobe is retracted. The left recurrent laryngeal nerve ascends on the lateral aspect of the trachea between the trachea and esophagus. The internal branch of the superior laryngeal nerve runs along the superior border of the inferior pharyngeal constrictor muscle and pierces the thyrohyoid membrane. The external branch of the superior laryngeal nerve lies adjacent to the inferior pharyngeal constrictor muscle and supplies its lower portion; it continues to run along the anterior border of the superior thyroid artery, passing deep to the superior attachment of the sternothyroid muscle, and then supplies the cricothyroid muscle. B. Blood supply of the parathyroid glands and courses of the left and right recurrent laryngeal nerves.

P.771





**A. Anterolateral View**



**B. Posterior View**

Authors: Agur, Anne M.R.; Dalley, Arthur F.

Title: *Grant's Atlas of Anatomy, 12th Edition*

Copyright ©2009 Lippincott Williams & Wilkins

> Table of Contents > Chapter 8 - Neck > 8.16 Alimentary layer of visceral compartment

---

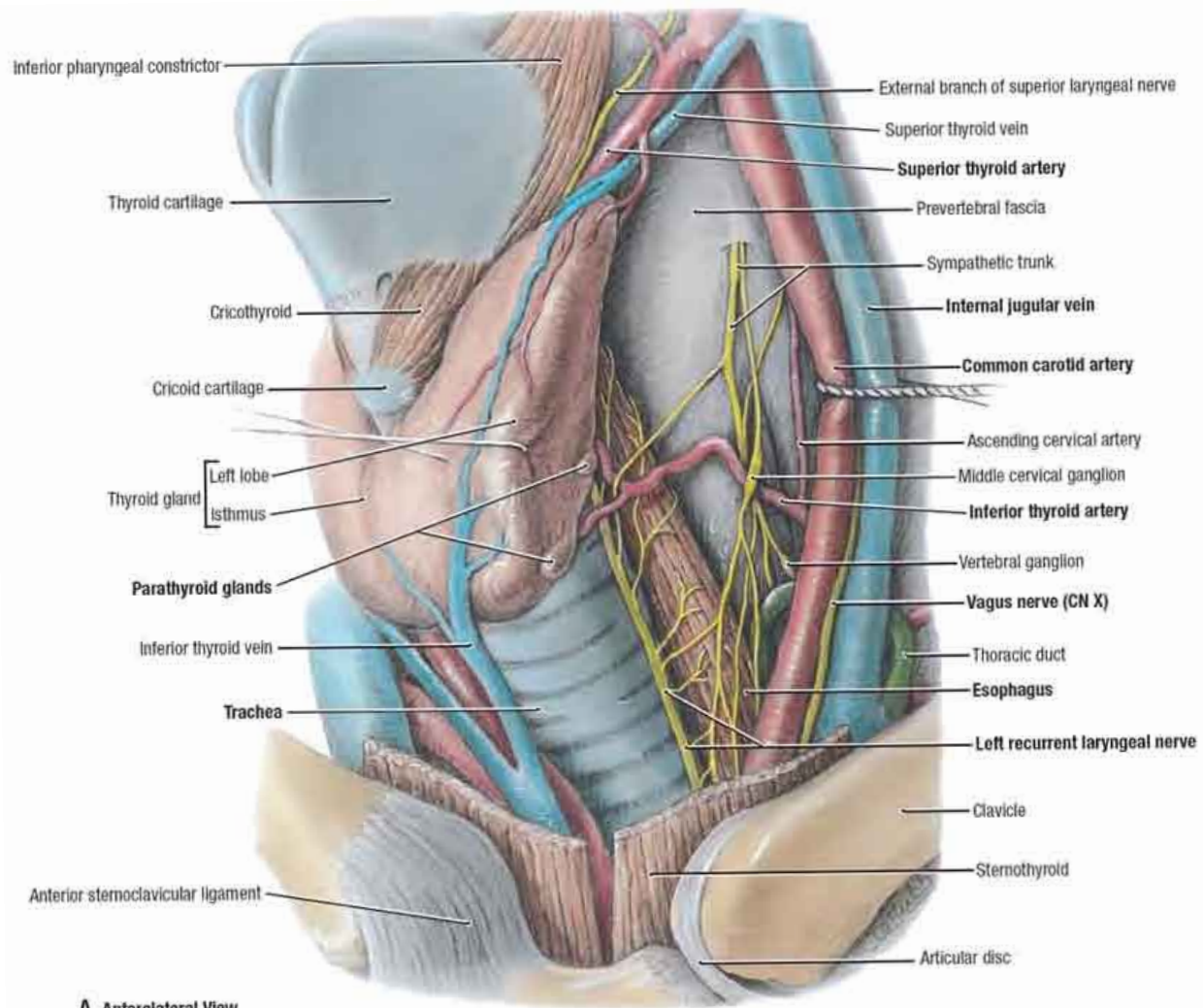
## 8.16 Alimentary layer of visceral compartment

*Part of* "Chapter 8 - Neck "

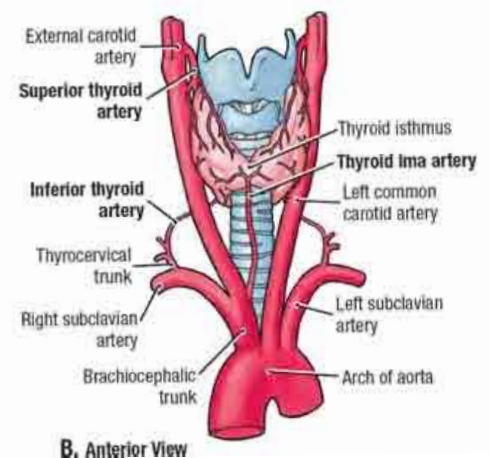
A. Dissection of the left side of the root of the neck. The three structures contained in the carotid sheath (internal jugular vein, common carotid artery, and vagus nerve) are retracted. The left recurrent laryngeal nerve ascends on the lateral aspect of the trachea, just anterior to the recess between the trachea and esophagus. B. Arterial supply of thyroid gland. The thyroid ima artery is infrequent (10%) and variable in its origin.

During a total thyroidectomy (e.g., excision of a malignant thyroid gland), the parathyroid glands are in danger of being inadvertently damaged or removed. These glands are safe during *subtotal thyroidectomy* because the most posterior part of the thyroid gland usually is preserved. Variability in the position of the parathyroid glands, especially the inferior ones, puts them in danger of being removed during surgery on the thyroid gland. If the parathyroid glands are inadvertently removed during surgery, the patient suffers from *tetany*, a severe convulsive disorder. The generalized convulsive muscle spasms result from a fall in blood calcium levels.





**A. Anterolateral View**



**B. Anterior View**



Authors: Agur, Anne M.R.; Dalley, Arthur F.

Title: *Grant's Atlas of Anatomy, 12th Edition*

Copyright ©2009 Lippincott Williams & Wilkins

> Table of Contents > Chapter 8 - Neck > 8.17 Root of the neck

---

## 8.17 Root of the neck

*Part of* "Chapter 8 - Neck "

A. Dissection of the right side of the root of the neck. The clavicle is cut, sections of the common carotid artery and internal jugular vein are removed, and the right lobe of the thyroid gland is retracted. The right vagus nerve crosses the first part of the subclavian artery and gives off an inferior cardiac branch and the right recurrent laryngeal nerve. The right recurrent laryngeal nerve loops inferior to the subclavian artery and passes posterior to the common carotid artery on its way to the posterolateral aspect of the trachea.

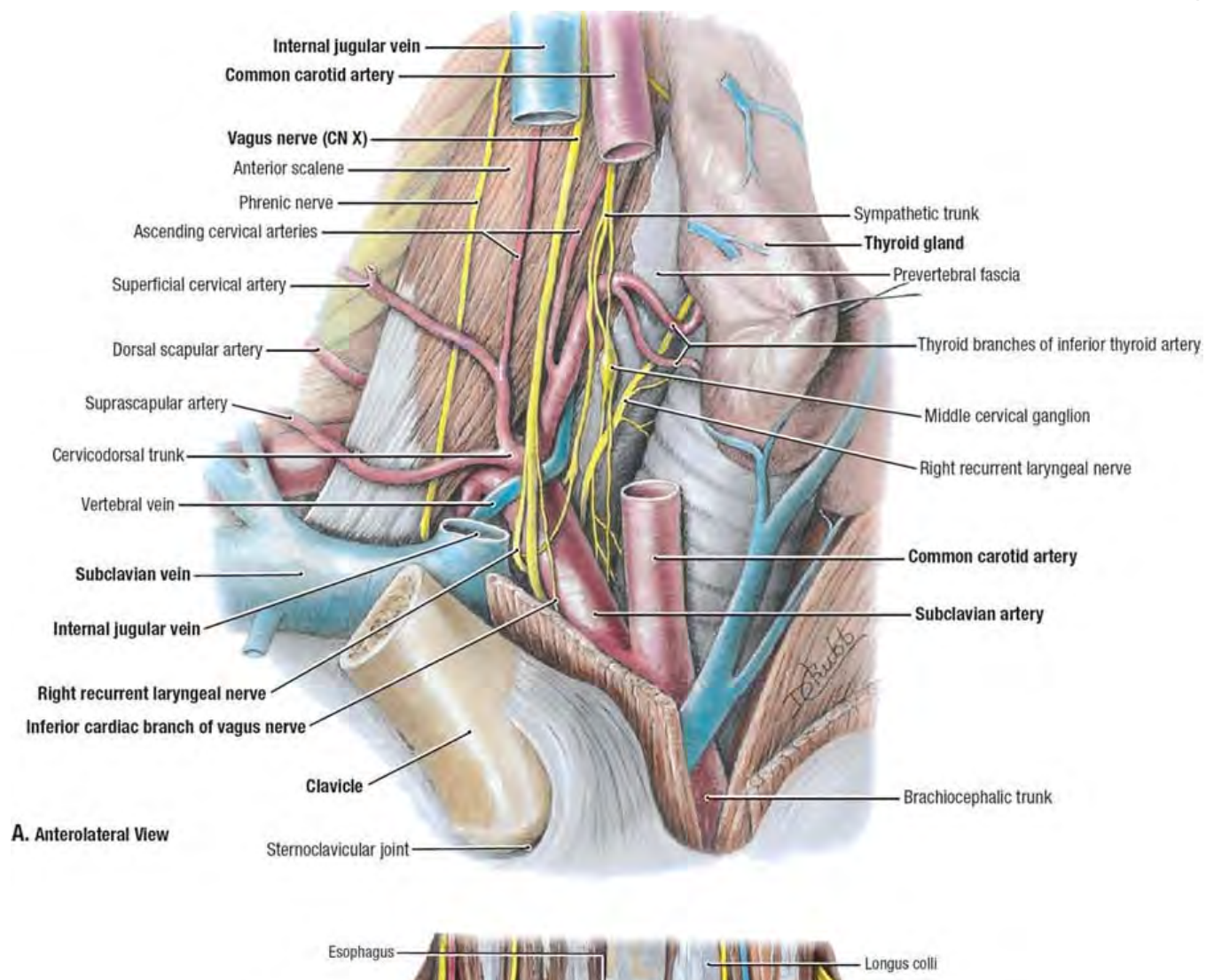
- The recurrent laryngeal nerves are vulnerable to injury during thyroidectomy and other surgeries in the anterior cervical region of the neck. Because the terminal branch of this nerve, the inferior laryngeal nerve, innervates the muscles moving the vocal folds, injury to the nerve results in paralysis of the vocal folds.
- A non-neoplastic and noninflammatory enlargement of the thyroid gland, other than the variable enlargement that may occur during menstruation and pregnancy, is called a goiter. A *goiter* results from a lack of iodine. It is common in certain parts of the world where the soil and water are deficient in iodine and iodized salt is unavailable. The enlarged gland causes a swelling in the neck that may compress the trachea, esophagus, and recurrent laryngeal nerves. When the gland enlarges, it may do so anteriorly, posteriorly, inferiorly, or laterally. It cannot move superiorly because of the superior

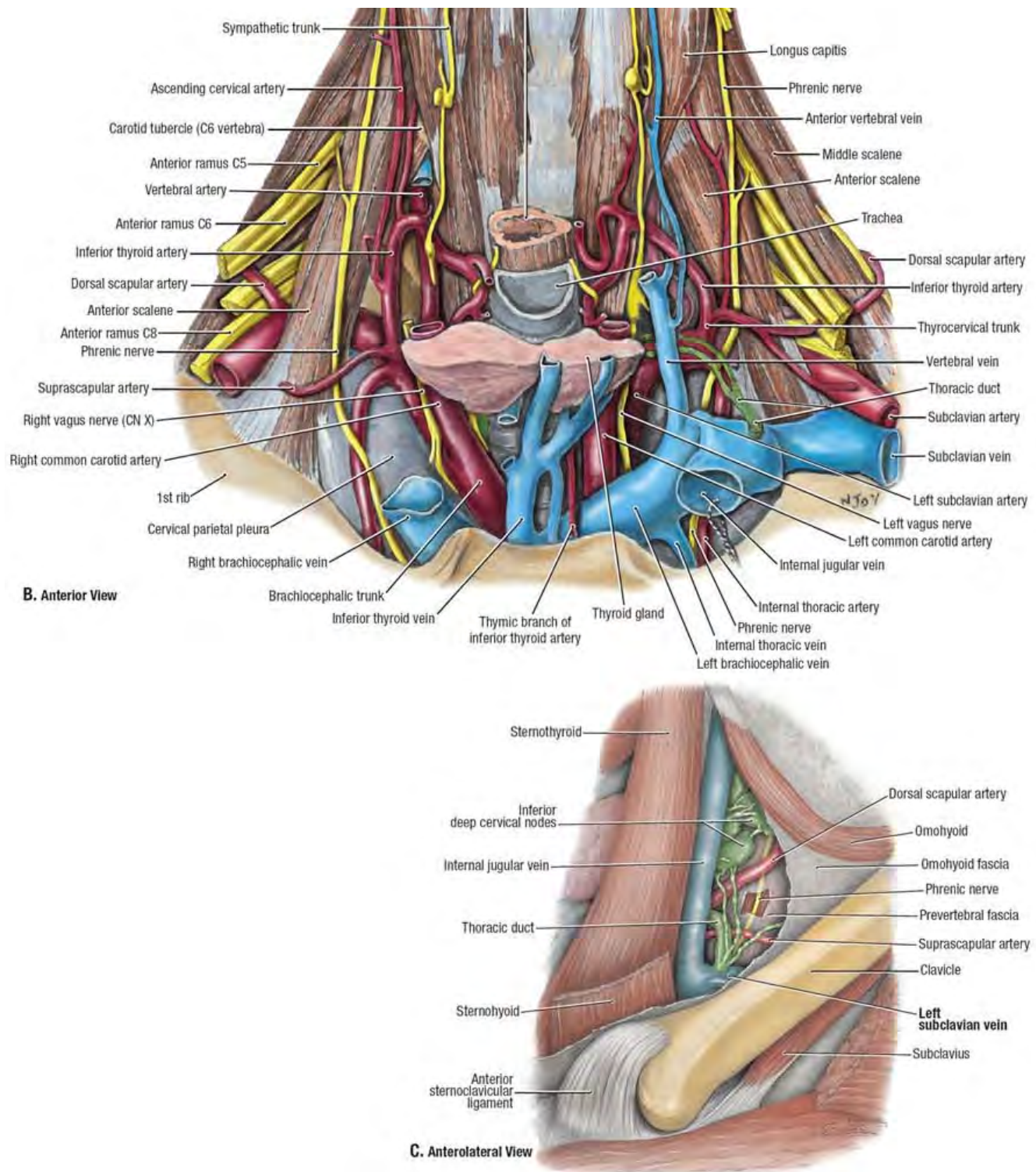
attachments of the sternothyroid and sternohyoid muscles.  
Substernal extension of a goiter is also common.

P.773

B. Deep anterior dissection. C. Dissection of termination of the thoracic duct. The sternocleidomastoid muscle is removed, the sternohyoid muscle is resected, and the omohyoid portion of the pretracheal fascia is partially removed. The thoracic duct arches laterally in the neck, passing posterior to the carotid sheath and anterior to the vertebral artery, thyrocervical trunk, and subclavian arteries; it enters the angle formed by the junction of the left subclavian and internal jugular veins to form the left brachiocephalic vein (the left venous angle).

P.774





Longus colli

Anterior tubercle of C1 vertebra (atlas); bodies of C1–C3 and transverse processes of C3–C6 vertebrae



Bodies of C5–T3 vertebrae, transverse processes of C3–C5 vertebrae  
 Anterior rami of C2–C6 spinal nerves  
 Flexes neck with rotation (torsion) to opposite side if acting unilaterally<sup>a</sup>

Longus capitis

Basilar part of occipital bone (basiocciput)

Anterior tubercles of C3–C6 transverse processes

Anterior rami of C1–C3 spinal nerves

Flexes head<sup>b</sup>

Rectus capitis lateralis

Jugular process of occipital bone

Transverse process of C1 vertebra (atlas)

From loop between C1 and C2 spinal nerves

Flexes head and helps to stabilize it<sup>b</sup>

Rectus capitis anterior

Base of cranium, just anterior to occipital condyle

Anterior surface of lateral mass of atlas (C1 vertebra)

Branches from loop between C1 and C2 spinal nerves

Flexes head<sup>b</sup>

<sup>a</sup>Flexion of neck, anterior (or lateral) bending of cervical vertebrae C2–C7.

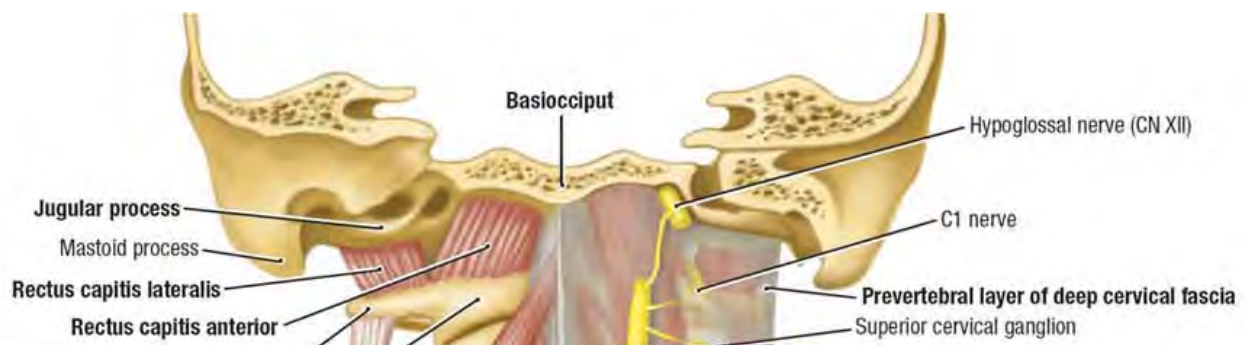
<sup>b</sup>Flexion of head, anterior (or lateral) bending of head relative to vertebral column at atlanto-occipital joints.

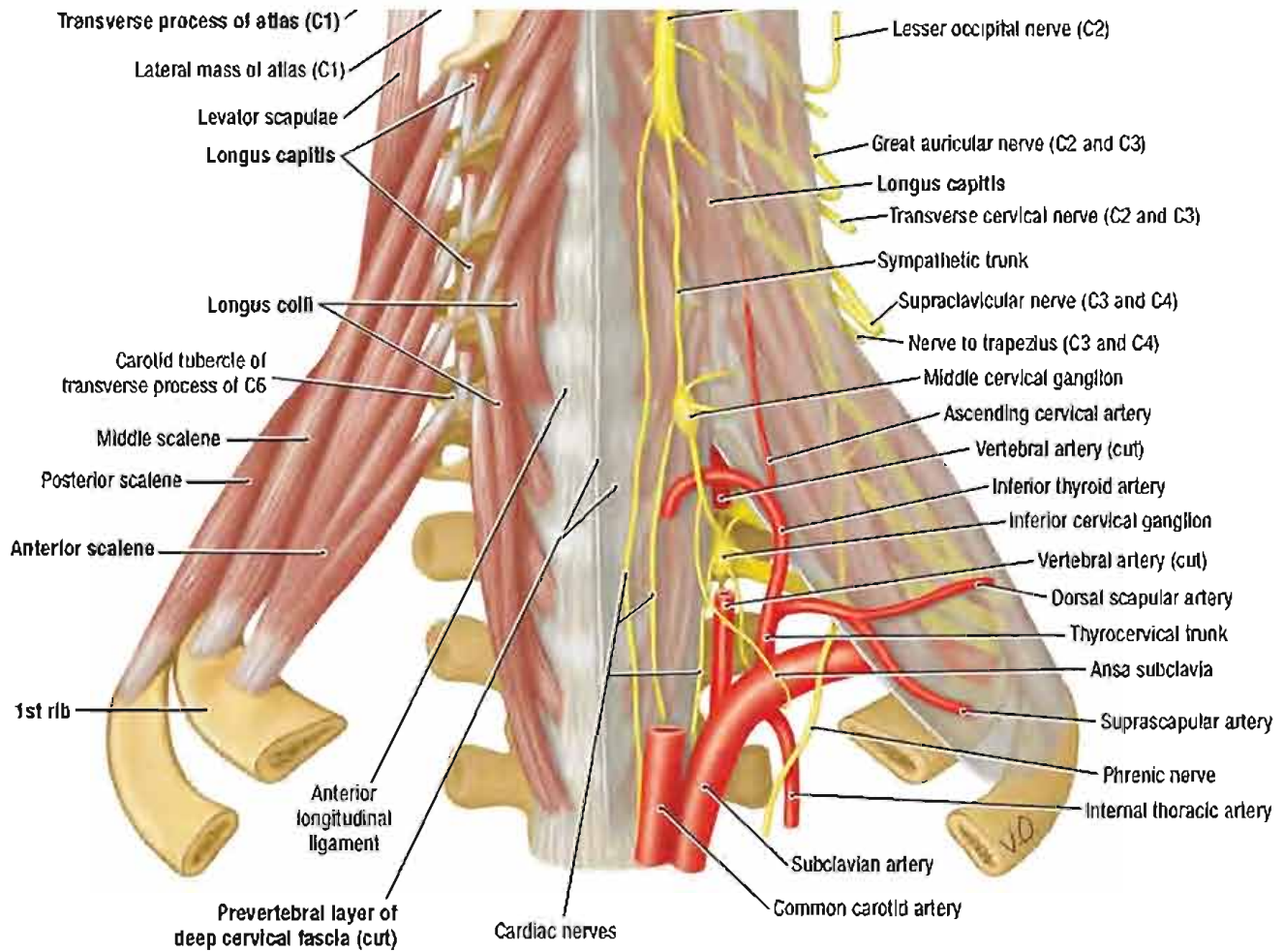
Muscle	Superior Attachment	Inferior Attachment	Innervation	Main Action
--------	---------------------	---------------------	-------------	-------------

Table 8.6 Anterior Vertebral Muscles

P.775

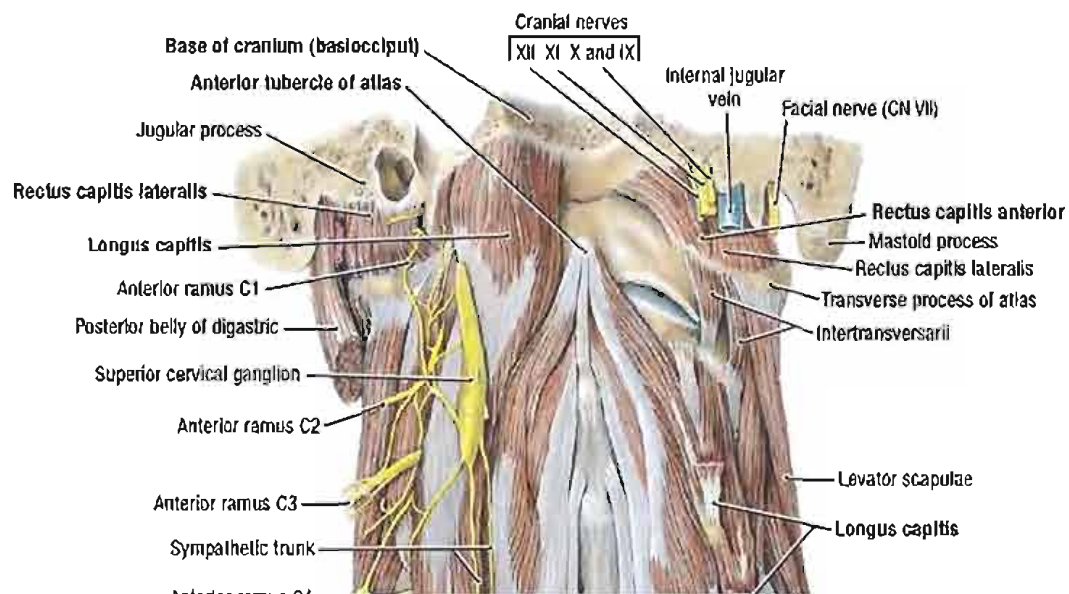
P.776



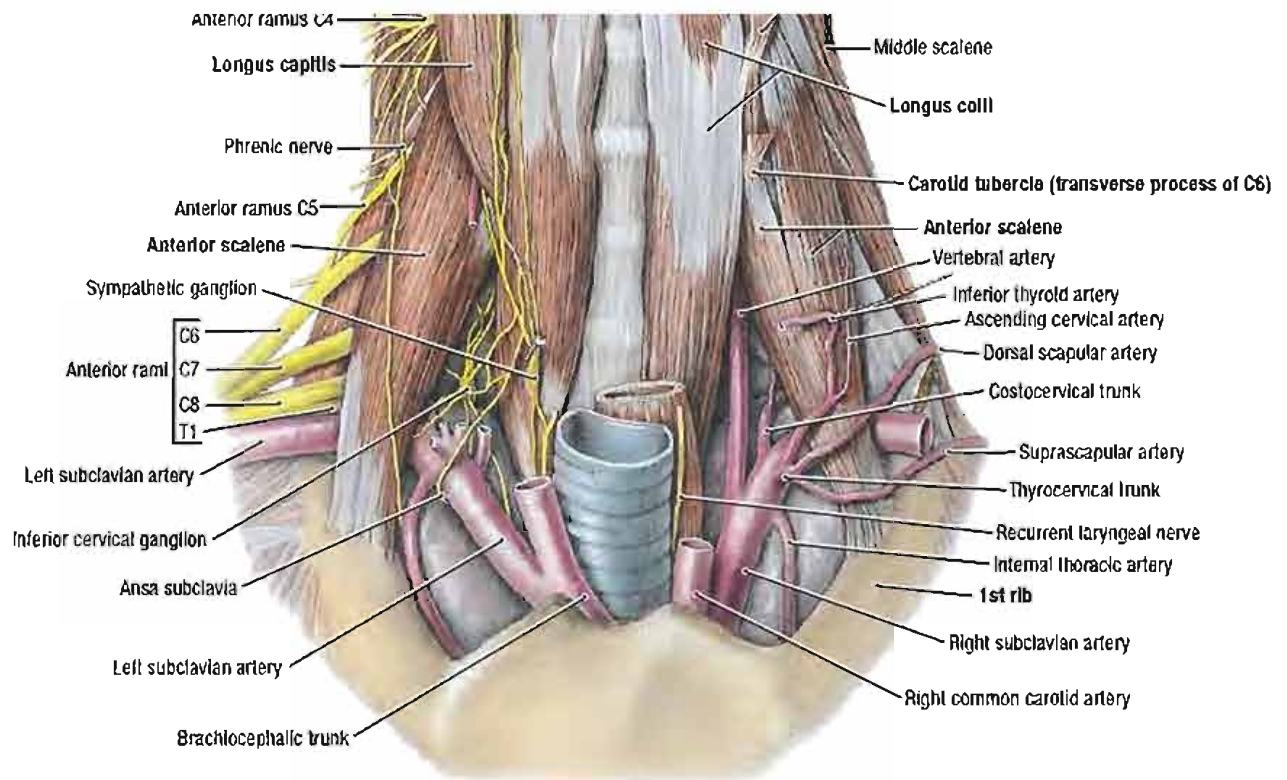


A. Anterior View

### Prevertebral region - I







B. Anterior View

Prevertebral region ~ II

Authors: Agur, Anne M.R.; Dalley, Arthur F.

Title: *Grant's Atlas of Anatomy, 12th Edition*

Copyright ©2009 Lippincott Williams & Wilkins

> Table of Contents > Chapter 8 - Neck > 8.18 Brachial plexus and sympathetic trunk in the root of the neck

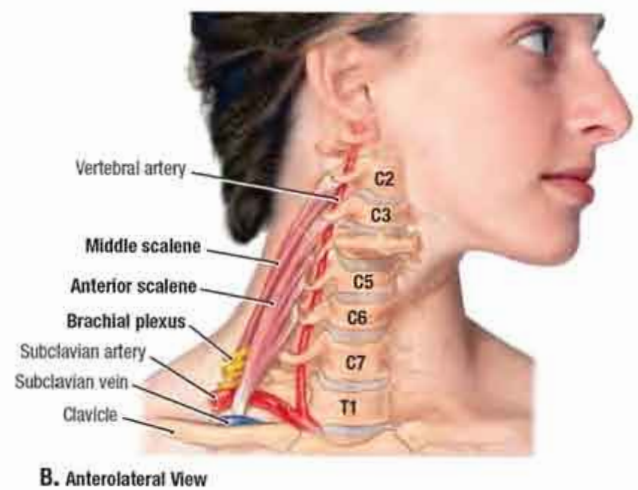
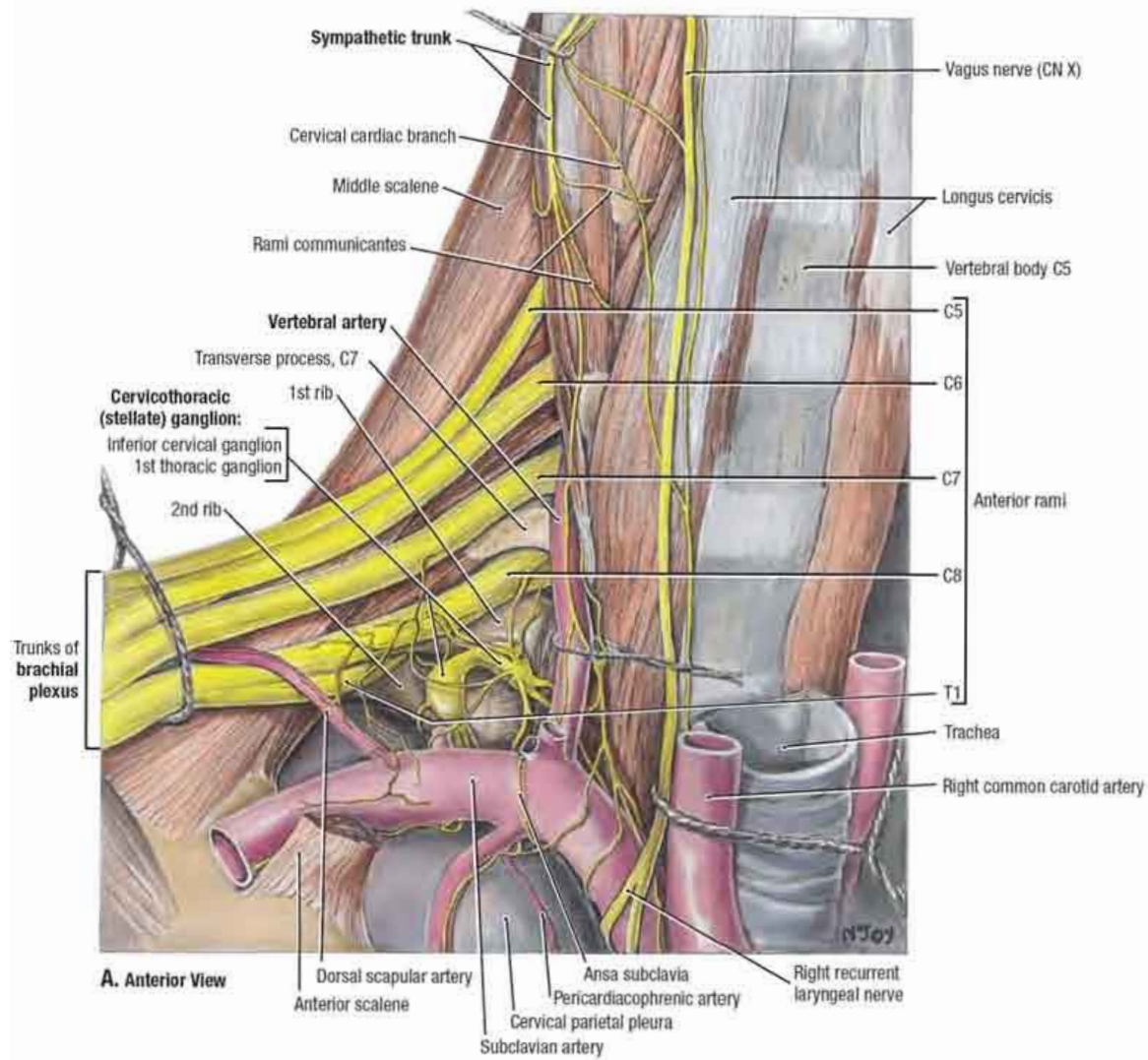
---

## 8.18 Brachial plexus and sympathetic trunk in the root of the neck

*Part of "Chapter 8 - Neck "*

A. Dissection of right side of specimen. The pleura has been depressed, the vertebral artery retracted medially, and the brachial plexus retracted superiorly to reveal the cervicothoracic (stellate) ganglion (the combined inferior cervical and 1st thoracic ganglia).

Anesthetic injected around the cervicothoracic (stellate) ganglion blocks transmission of stimuli through the cervical and superior thoracic ganglia. This ganglion block may relieve vascular spasms involving the brain and upper limb. It is also useful when deciding if surgical resection of the ganglion would be beneficial to a person with excess vasoconstriction of the ipsilateral limb. B. Relation of brachial plexus and subclavian artery to anterior and middle scalene muscles.



## Splenius capitis

Inferior half of nuchal ligament and spinous processes of C7 and superior 3–4 thoracic vertebrae

Lateral aspect of mastoid process and lateral third of superior nuchal line

Posterior rami of middle cervical spinal nerves

Laterally flexes and rotates head and neck to same side; acting bilaterally, extend head and neck<sup>a</sup>

## Levator scapulae

Posterior tubercles of transverse processes of C1–C4 vertebrae

Superior part of medial border of scapula

Dorsal scapular nerve (C5) and cervical spinal nerves C3 and C4

Elevates scapula and tilts its glenoid cavity inferiorly by rotating scapula

## Middle scalene

Posterior tubercles of transverse processes of C2–C7 vertebrae

Superior surface of 1st rib posterior to groove for subclavian artery

Anterior rami of cervical spinal nerves

Flexes neck laterally; elevates 1st rib during forced inspiration<sup>b</sup>

## Posterior scalene

External border of 2nd rib

Anterior rami of cervical spinal nerves C4 to C8

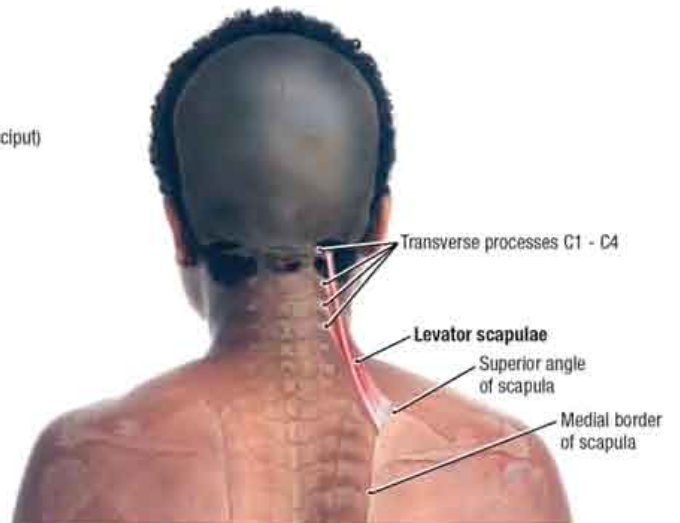
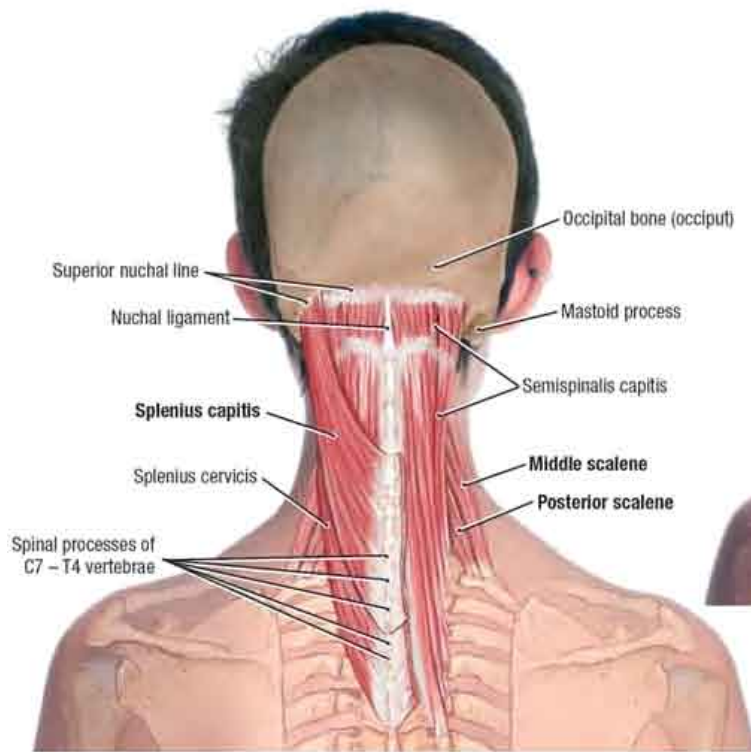
Flexes neck laterally; elevates 2nd rib during forced inspiration<sup>b</sup>

<sup>a</sup>Rotation of head occurs at atlantoaxial joints.

<sup>b</sup>Flexion of neck anterior (or lateral) bending of cervical vertebrae C2–C7.

Muscle	Superior Attachment	Inferior Attachment	Innervation	Main Action
--------	---------------------	---------------------	-------------	-------------

Table 8.7 Lateral Vertebral Muscles
-------------------------------------





Authors: Agur, Anne M.R.; Dalley, Arthur F.

Title: *Grant's Atlas of Anatomy, 12th Edition*

Copyright ©2009 Lippincott Williams & Wilkins

> Table of Contents > Chapter 8 - Neck > 8.19 Serial dissection of submandibular region and floor of mouth

---

## 8.19 Serial dissection of submandibular region and floor of mouth

*Part of* "Chapter 8 - Neck"

Mylohyoid and digastric muscles. A. Structures overlying the mandible and a portion of the body of the mandible have been removed.

- The stylohyoid and posterior belly and intermediate tendon of the digastric muscle form the posterior border of the submandibular triangle; the facial artery passes superficial to these muscles.
- The anterior belly of the digastric muscle forms the anterior border of the submandibular triangle. In this specimen, the anterior belly has an additional origin from the hyoid bone; the mylohyoid muscle forms the medial wall of the triangle and has a thick, free posterior border.
- The nerve to mylohyoid, which supplies the mylohyoid muscle and anterior belly of the digastric muscle, is accompanied by the mylohyoid branch of the inferior alveolar artery posteriorly and the submental artery from the facial artery anteriorly.

Authors: Agur, Anne M.R.; Dalley, Arthur F.

Title: *Grant's Atlas of Anatomy, 12th Edition*

Copyright ©2009 Lippincott Williams & Wilkins

> Table of Contents > Chapter 8 - Neck > 8.19 Serial dissection of submandibular region and floor of mouth II

---

## 8.19 Serial dissection of submandibular region and floor of mouth II

*Part of* "Chapter 8 - Neck"

---

P.779

B. Sublingual and submandibular glands. The body and adjacent portion of the ramus of the mandible have been removed.

- The sublingual salivary gland lies posterior to the mandible and is in contact with the deep part of the submandibular gland posteriorly.
- Numerous fine ducts pass from the superior border of the sublingual gland to open on the sublingual fold of the overlying mucosa.
- The lingual nerve lies between the sublingual gland and the deep part of the submandibular gland; the submandibular ganglion is suspended from this nerve.
- Spinal nerve C1 fibers, conveyed by the hypoglossal nerve (CN XII), pass to the thyrohyoid muscle before the hypoglossal nerve passes deep to the mylohyoid muscle.

---

P.780

C. Hyoglossus muscle, lingual and hypoglossal nerves (CN XII). All of the right half of the mandible, except the superior part of the ramus, has been removed. The

stylohyoid muscle is reflected superiorly, and the posterior belly of the digastric muscle is left in situ.

- The hyoglossus muscle ascends from the greater horn and body of the hyoid bone to the side of the tongue.
- The styloglossus muscle is crossed by the tonsillar branch of the facial artery posterosuperiorly, and its oblique part interdigitates with bundles of the hyoglossus muscle inferiorly.
- The hypoglossal nerve supplies all of the muscles of the tongue, both extrinsic and intrinsic, except the palatoglossus (a palatine muscle, innervated by CN X).
- The submandibular duct runs anteriorly in contact with the hyoglossus and genioglossus muscles to its opening on the side of the frenulum of the tongue.
- The lingual nerve is in contact with the mandible posteriorly, looping inferior to the submandibular duct and ending in the tongue. The submandibular ganglion is suspended from the lingual nerve; twigs leave the nerve to supply the mucous membrane.

Authors: Agur, Anne M.R.; Dalley, Arthur F.  
Title: *Grant's Atlas of Anatomy, 12th Edition*  
Copyright ©2009 Lippincott Williams & Wilkins

> Table of Contents > Chapter 8 - Neck > 8.19 Serial dissection of submandibular region and floor of mouth " IV

## 8.19 Serial dissection of submandibular region and floor of mouth " IV

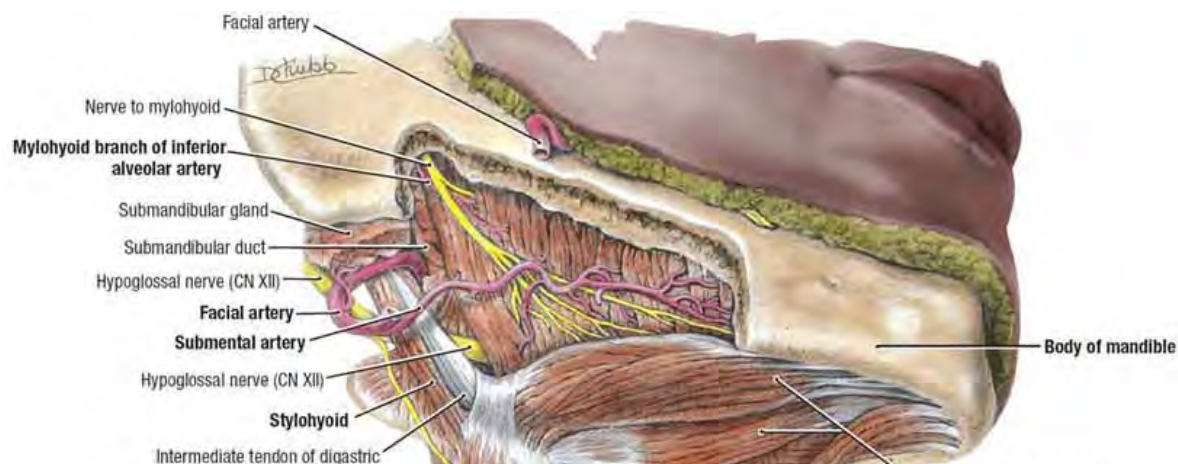
Part of "Chapter 8 - Neck "

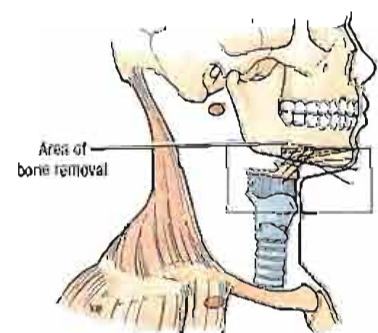
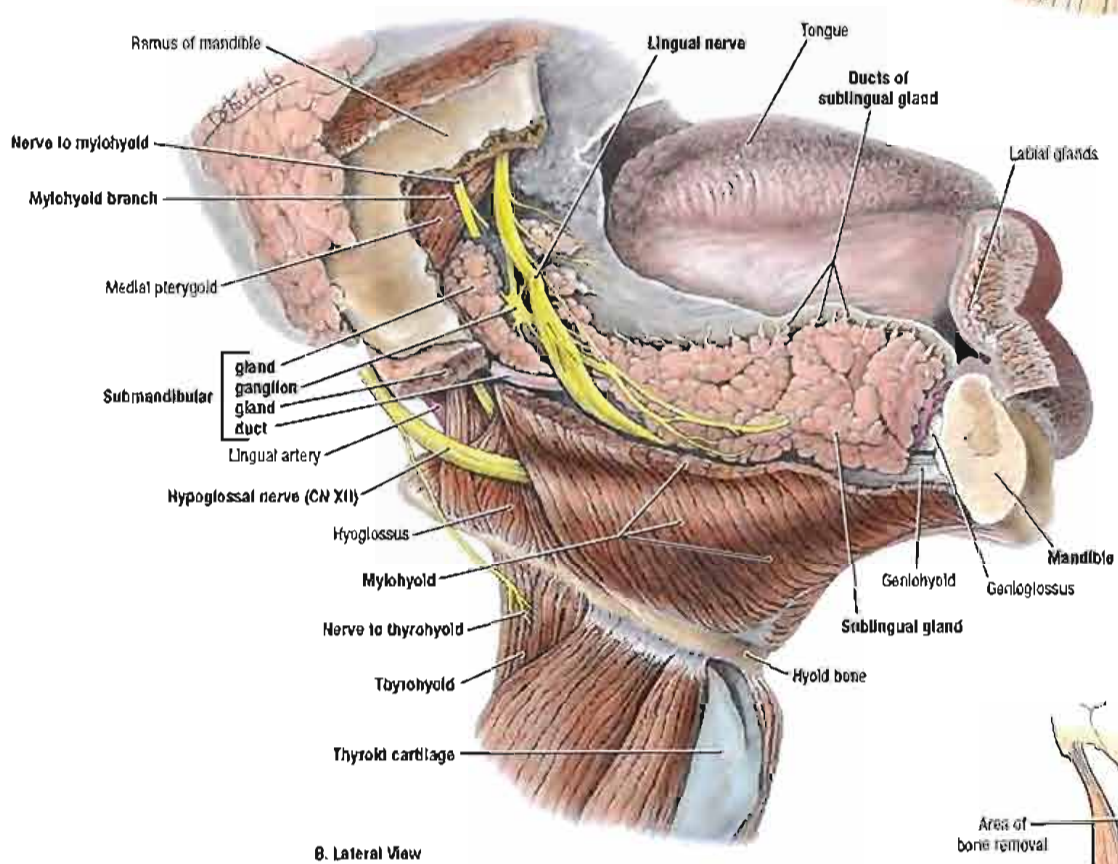
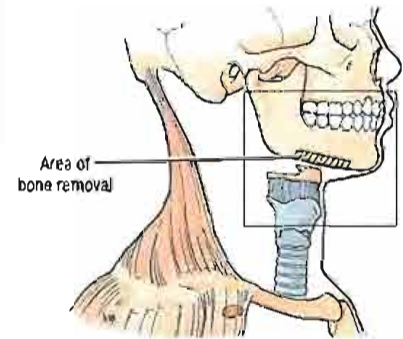
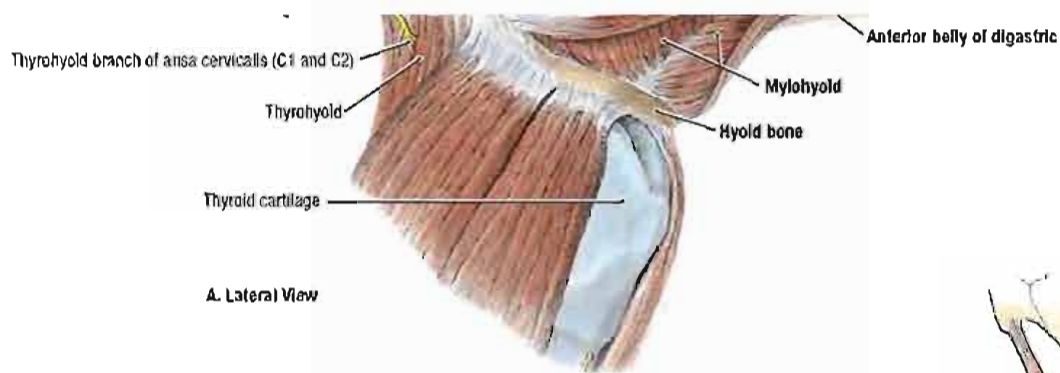
P.781

D. Genioglossus and geniohyoid muscles. The stylohyoid, posterior belly and intermediate tendon of the digastric muscle are reflected superiorly, the hypoglossal nerve is divided, and the hyoglossus muscle is mostly removed.

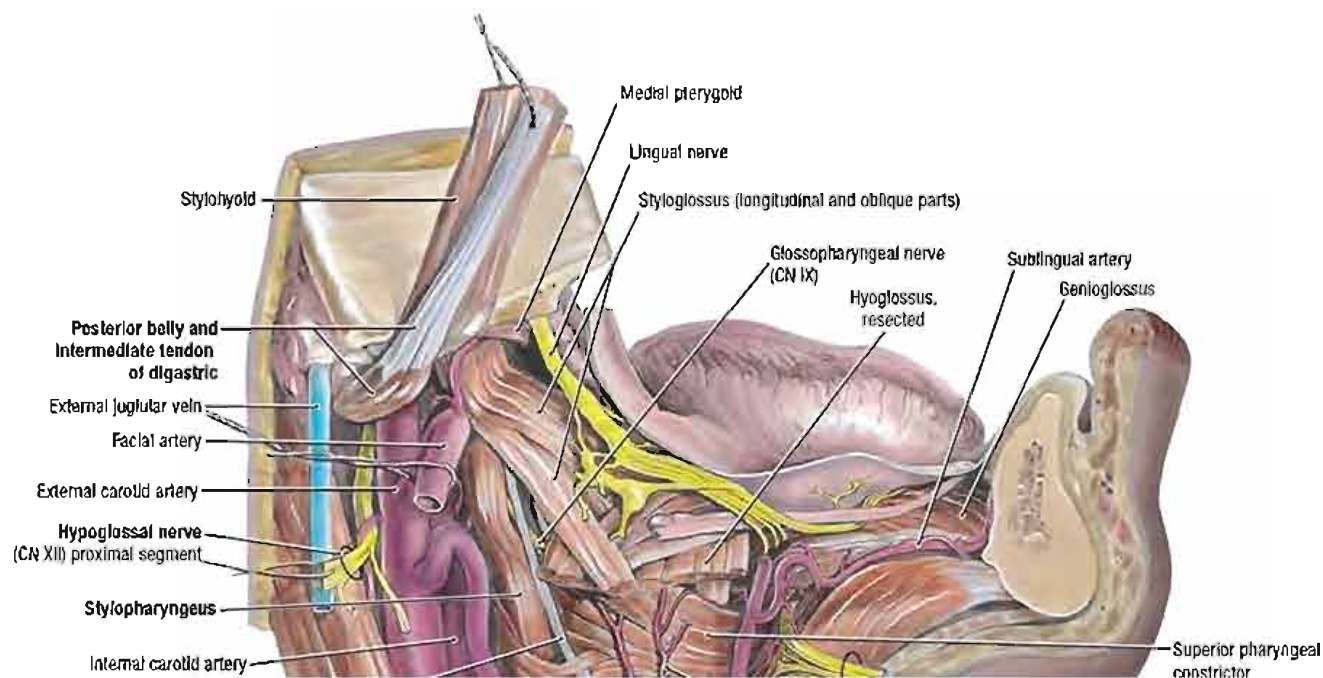
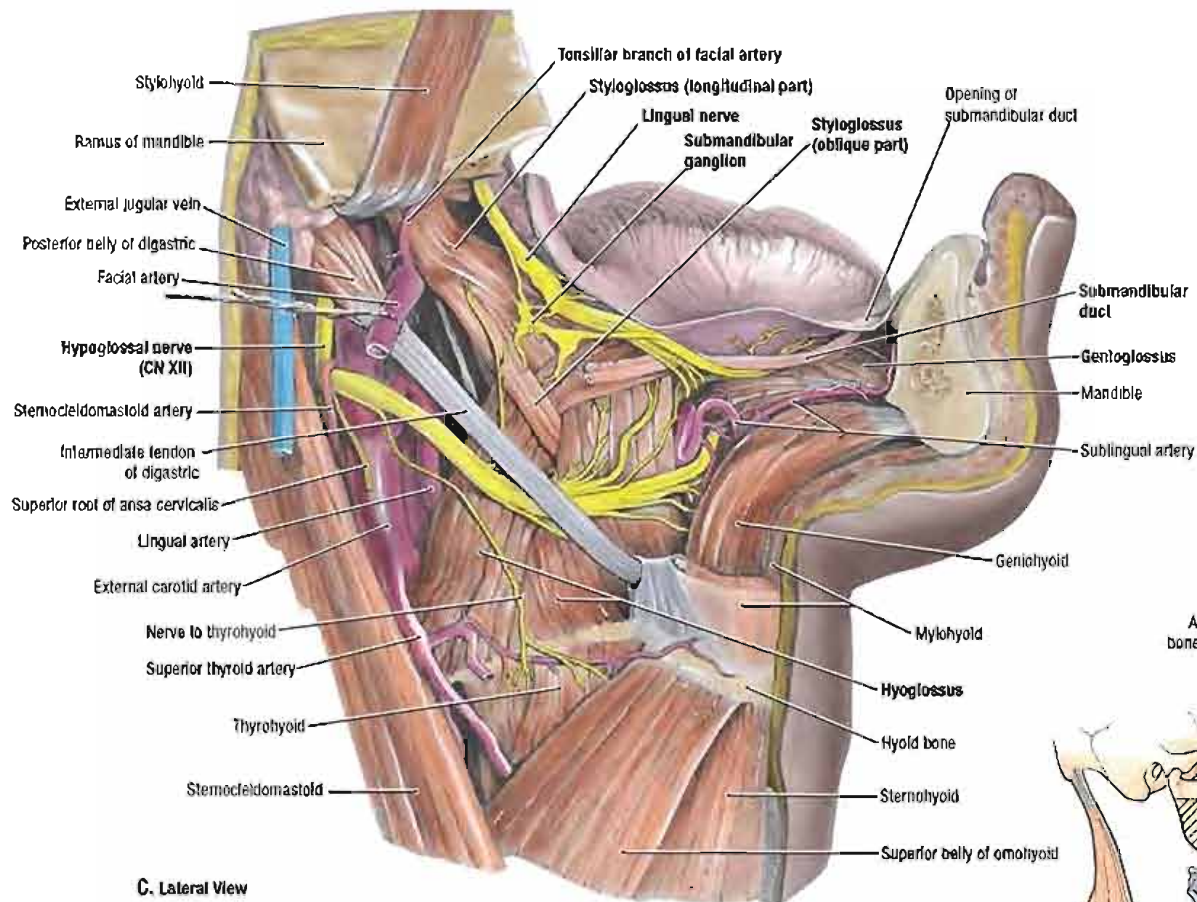
- The lingual artery passes deep to the hyoglossus muscle (resected here), close to the greater horn of the hyoid, and then passes lateral to the middle pharyngeal constrictor muscle, stylohyoid ligament, and genioglossus muscle and turns into the tongue as the deep lingual arteries.

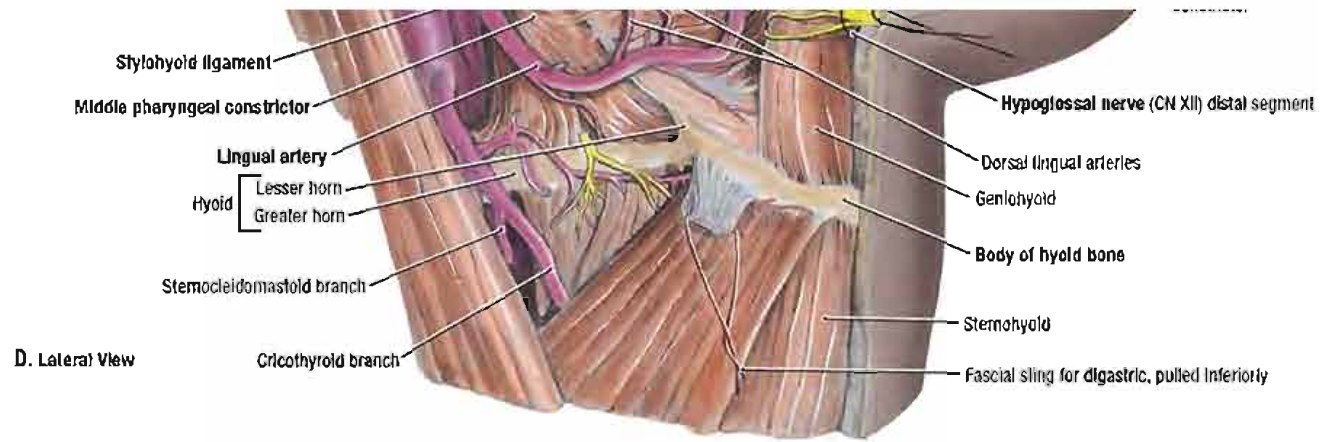
P.782











Authors: Agur, Anne M.R.; Dalley, Arthur F.

Title: *Grant's Atlas of Anatomy, 12th Edition*

Copyright ©2009 Lippincott Williams & Wilkins

> Table of Contents > Chapter 8 - Neck > 8.20 Lingual and facial arteries in submandibular region and floor of mouth

---

## 8.20 Lingual and facial arteries in submandibular region and floor of mouth

*Part of* "Chapter 8 - Neck "

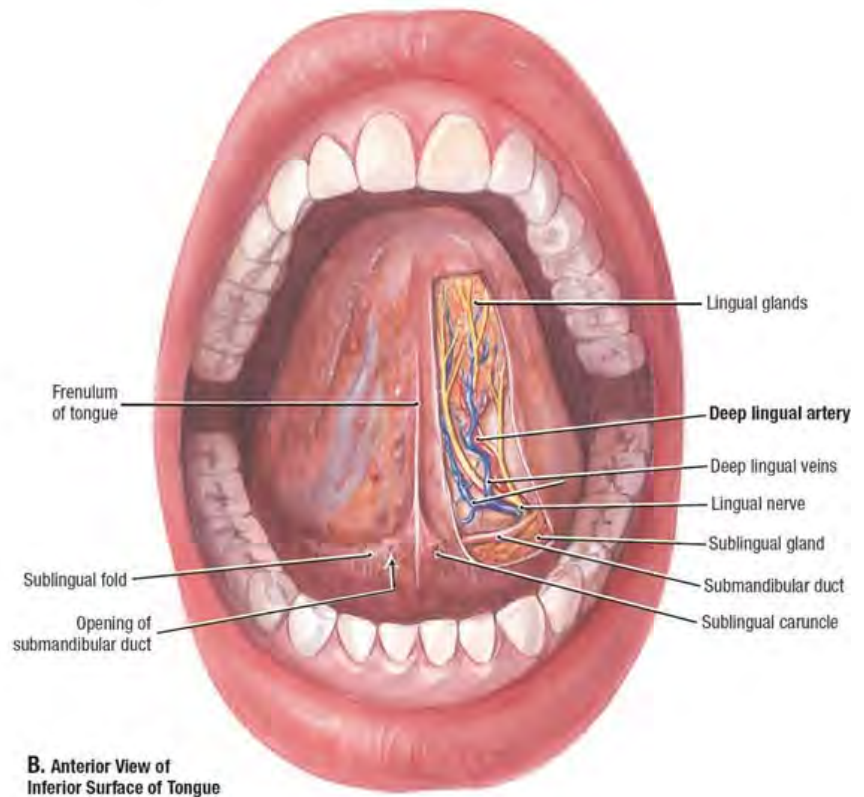
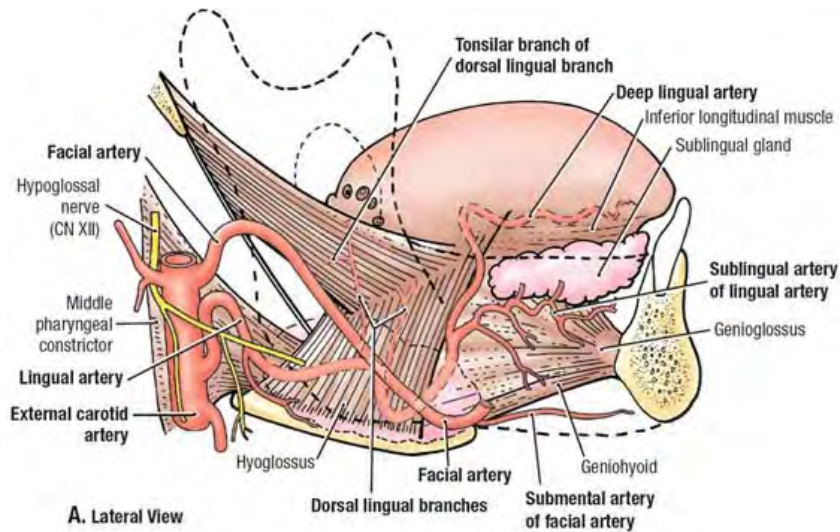
A. Course of the lingual artery. B. Inferior surface of the tongue and floor of the mouth.

In A :

- The dorsal lingual arteries supply the root of the tongue and palatine tonsil, the deep lingual artery supplies the body of the tongue, and the sublingual branch supplies the floor of the mouth.

In B :

- The inferior (sublingual) surface of the tongue is covered by a mucous membrane through which the underlying deep lingual veins can be seen.
- The sublingual caruncle, a papilla on each side of the frenulum, marks the location of the opening of the submandibular duct.



Extrinsic muscle of back (superior axioappendicular muscle)

Descending part of trapezius

Medial third of superior nuchal line; external occipital protuberance; nuchal ligament

Lateral third of clavicle and lateral aspect of acromion of scapula

Spinal accessory nerve (CN XI)



Elevates scapulae and works with other parts of muscle to retract scapulae; with shoulder fixed, contributes to extension of head, side bending (lateral flexion) of neck

Intrinsic muscles of back – superficial layer

Splenius

Nuchal ligament and spinous processes of C7 to T4 vertebrae

*Splenius capitis*: fibers run superolaterally to mastoid process of temporal bone and lateral third of superior nuchal line of occipital bone  
*Splenius cervicis*: Tubercles of transverse processes of C1 – C4 vertebrae

Posterior rami of spinal nerves

*Acting unilaterally*: laterally flex and rotate head to side of active muscle  
*Acting bilaterally*: extend head and neck

Intrinsic muscles of back – intermediate layer

Longissimus

Transverse processes of T1 – T5 vertebrae

*Longissimus capitis*: posterior mastoid process  
*Longissimus cervicis*: transverse processes of C2 – C6

Posterior rami of spinal nerves

Extends vertebral column; longissimus capitis turns face ipsilaterally

Intrinsic muscles of back – deep layer

Semispinalis

Transverse processes of C4-T5 vertebrae

*Semispinalis capitis*: Superior nuchal line of occipital bone

*Semispinalis cervicis*: Spinous processes of cervical vertebrae

*Acting unilaterally*: contribute to contralateral rotation;

*Acting bilaterally*: extend head and Neck

Multifidus of cervical region

Transverse processes of T1 – T3

Articular processes of C4 – C7 vertebrae

Spinous processes 2 – 4 segments inferior to attachment

Posterior rami of spinal nerves

Stabilizes vertebrae during local movements of vertebral column

Rotatores

Transverse processes



Junction of lamina and transverse process, or spinous process of vertebra immediately (brevis) or two segments (longus) superior to origin

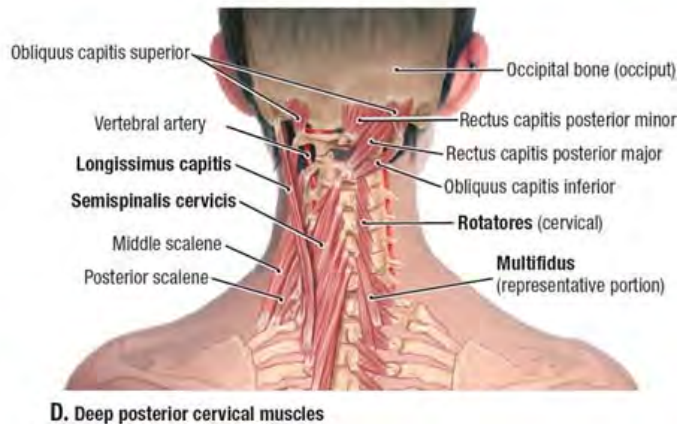
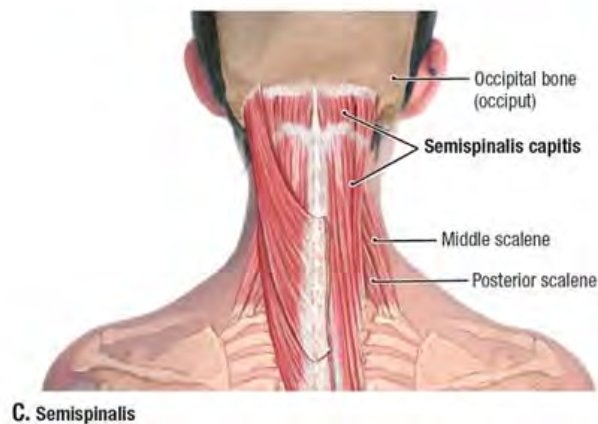
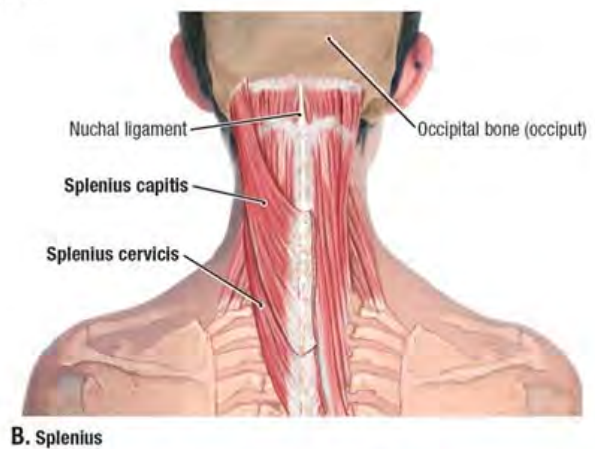
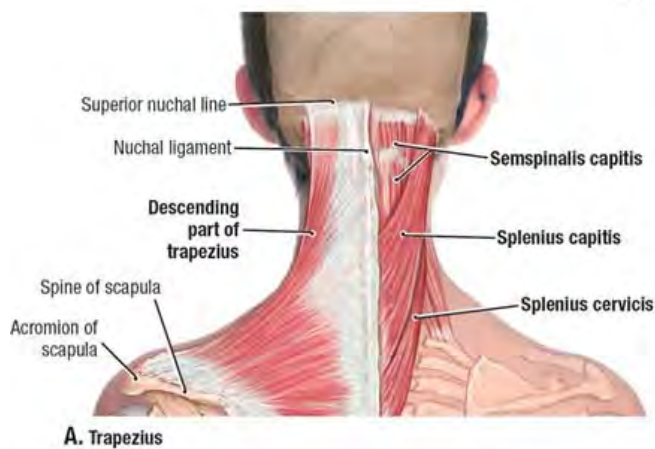
Stabilize, assist with local extension and rotatory movements; may function as proprioceptive organs

Muscle    Superior Attachment    Inferior Attachment    Innervation    Main Action

Table 8.8 Muscles of Posterior Cervical Region

P.784

Posterior Views



Authors: Agur, Anne M.R.; Dalley, Arthur F.

Title: *Grant's Atlas of Anatomy, 12th Edition*

Copyright ©2009 Lippincott Williams & Wilkins

> Table of Contents > Chapter 8 - Neck > 8.21 Suboccipital region

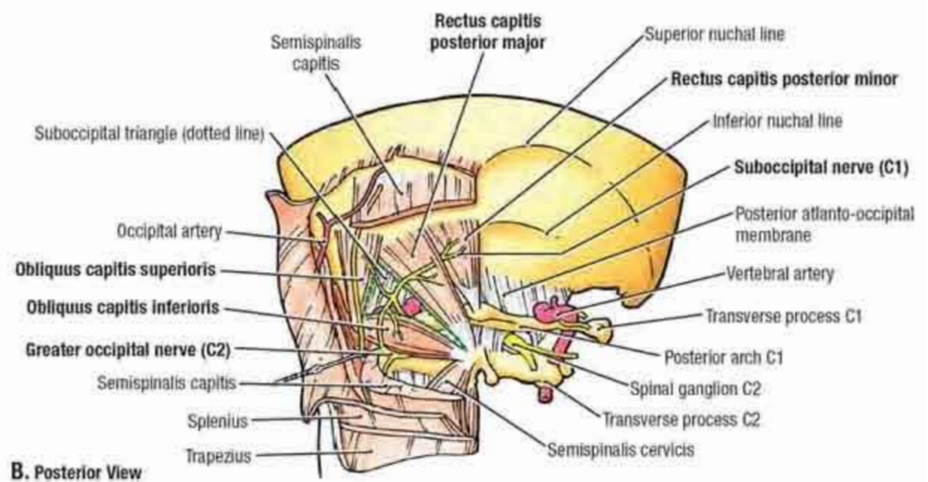
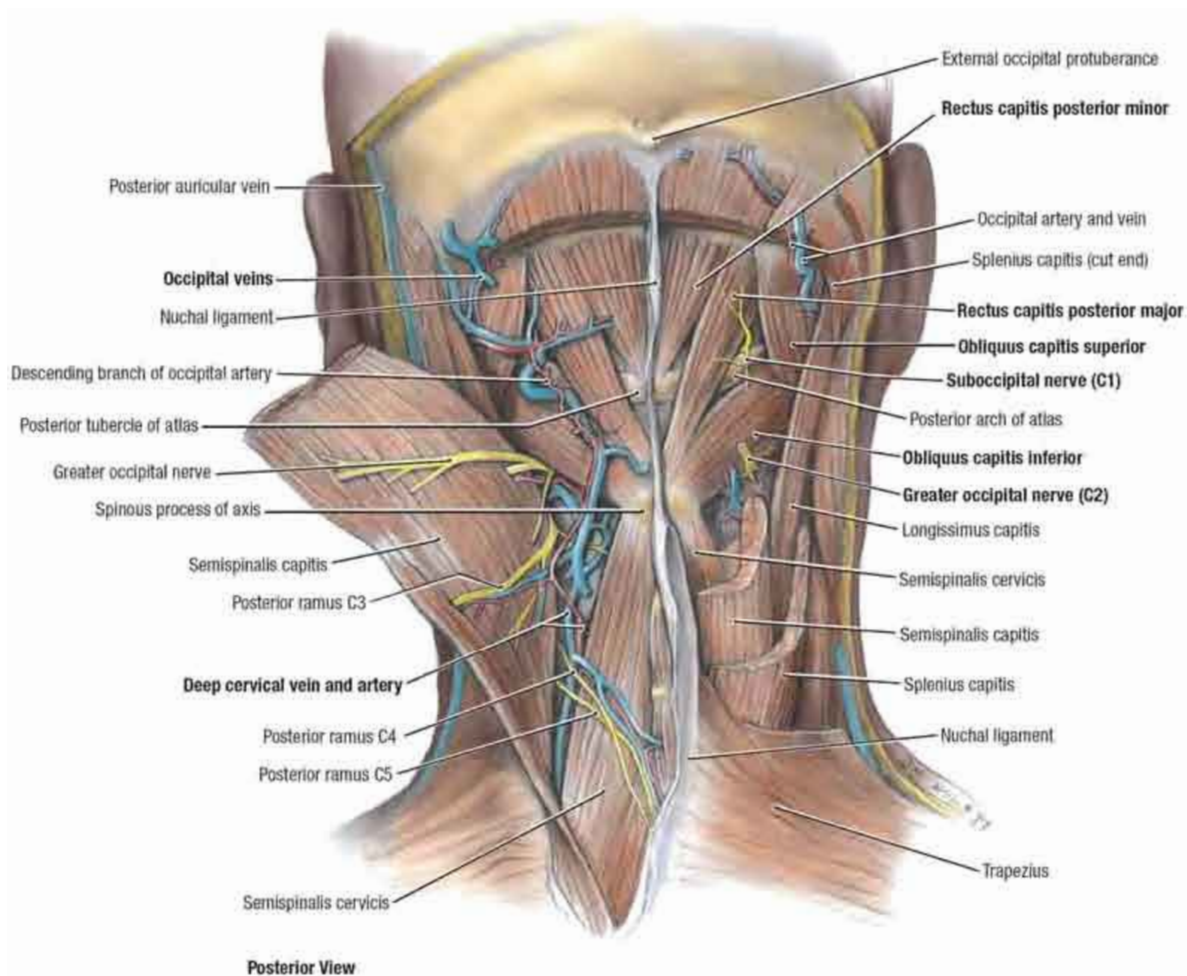
---

## 8.21 Suboccipital region

*Part of* "Chapter 8 - Neck "

A. Dissection. B. Schematic illustration.

- The suboccipital triangle is bounded by three muscles: obliquus capitis inferior and superior, and rectus capitis posterior major.
- The suboccipital nerve (posterior ramus of C1) emerges through the suboccipital triangle to innervate the muscles forming the triangle.



Authors: Agur, Anne M.R.; Dalley, Arthur F.

Title: *Grant's Atlas of Anatomy, 12th Edition*

Copyright ©2009 Lippincott Williams & Wilkins

> Table of Contents > Chapter 8 - Neck > 8.22 Posterior cervical regionâ€”base of skull and transverse section

---

## 8.22 Posterior cervical regionâ€”base of skull and transverse section

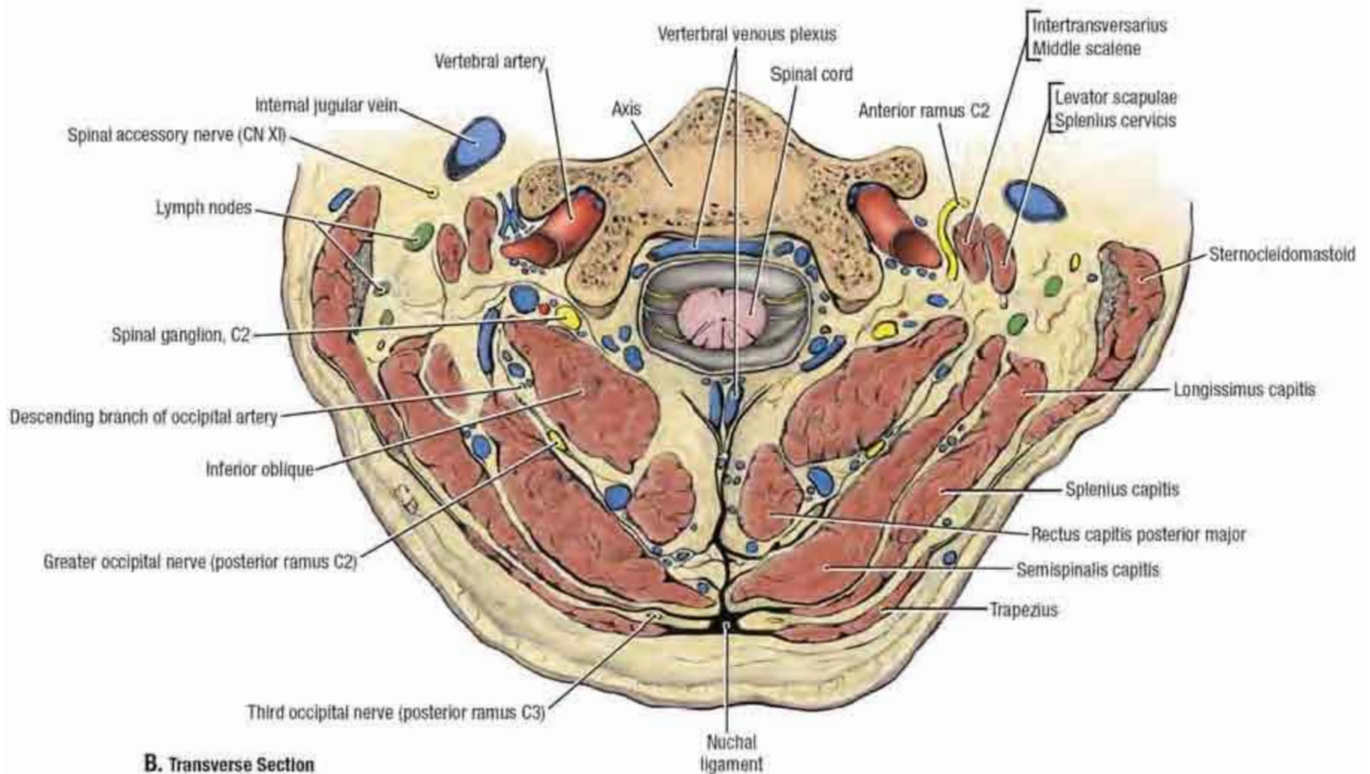
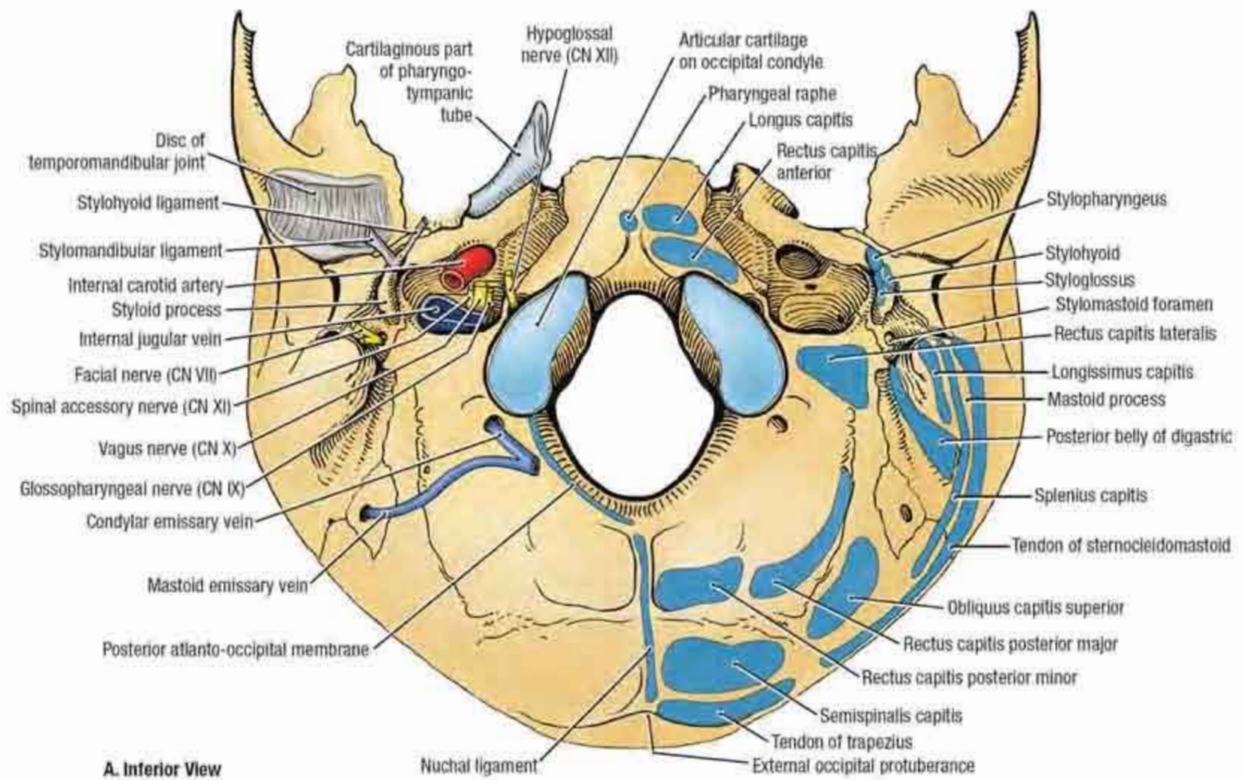
*Part of* "Chapter 8 - Neck "

A. Muscular attachments to and neurovascular relationships at the base of the skull. B. Transverse section through the axis (C2).

---

P.786







Authors: Agur, Anne M.R.; Dalley, Arthur F.

Title: *Grant's Atlas of Anatomy, 12th Edition*

Copyright ©2009 Lippincott Williams & Wilkins

> Table of Contents > Chapter 8 - Neck > 8.23 External pharynx

---

## 8.23 External pharynx

*Part of* "Chapter 8 - Neck"

A. Illustration of a dissection similar to B. The sympathetic trunk (including the superior cervical ganglion), which normally lies posterior to the internal carotid artery, has been retracted medially.

- The pharyngobasilar fascia, between the superior pharyngeal constrictor muscle and the base of the skull, attaches the pharynx to the occipital bone and forms the wall of the noncollapsible pharyngeal recesses.
- As they exit the jugular foramen, CN IX lies anterior to CN X, and CN XI; CN XII, exiting the hypoglossal canal, lies medially.

Authors: Agur, Anne M.R.; Dalley, Arthur F.

Title: *Grant's Atlas of Anatomy, 12th Edition*

Copyright ©2009 Lippincott Williams & Wilkins

> Table of Contents > Chapter 8 - Neck > 8.23 External pharynx II

---

## 8.23 External pharynx II

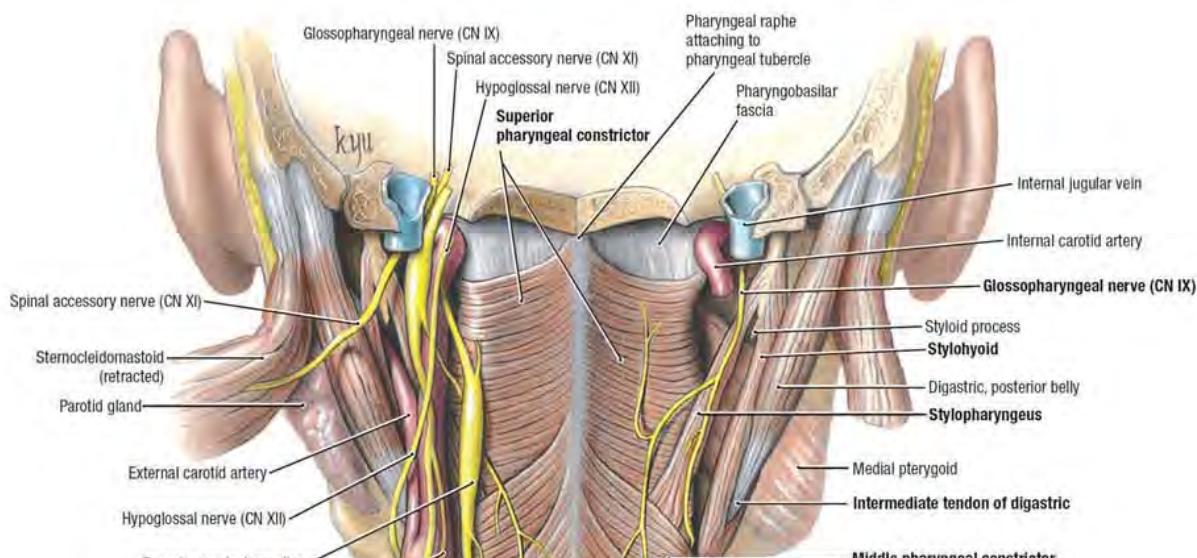
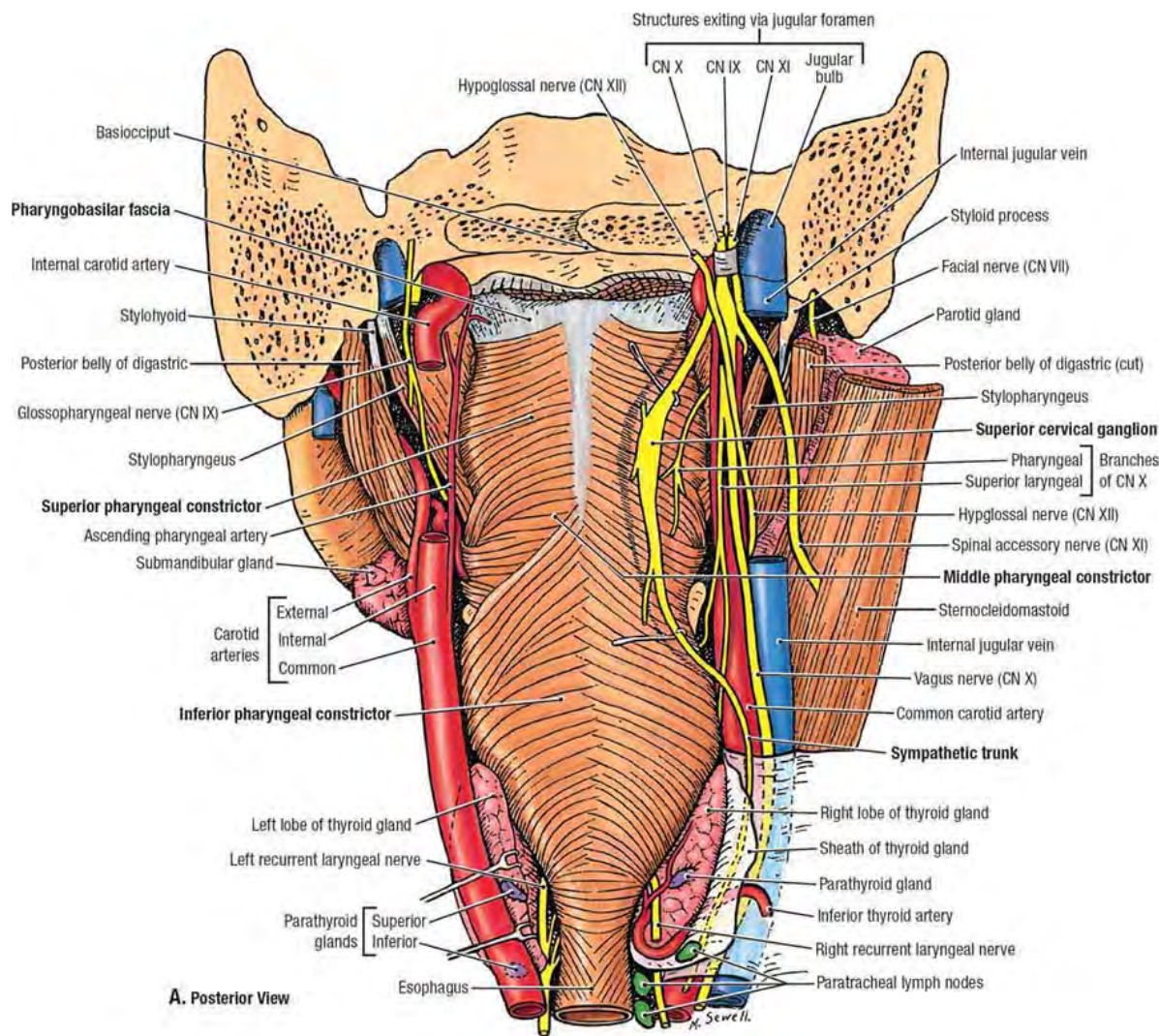
*Part of* "Chapter 8 - Neck "

---

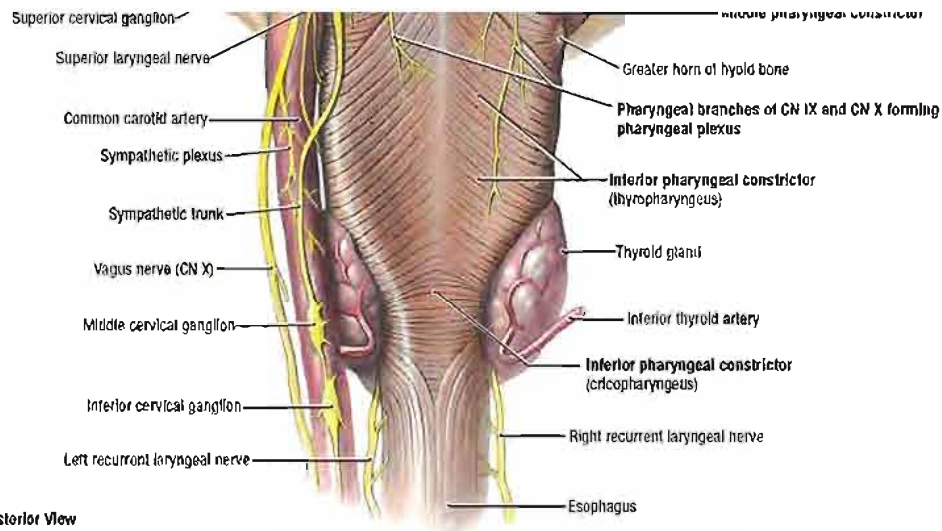
P.787

B. Dissection. A large wedge of occipital bone (including the foramen magnum) and the articulated cervical vertebrae have been separated from the remainder (anterior portion) of the head and cervical viscera at the retropharyngeal space and removed.

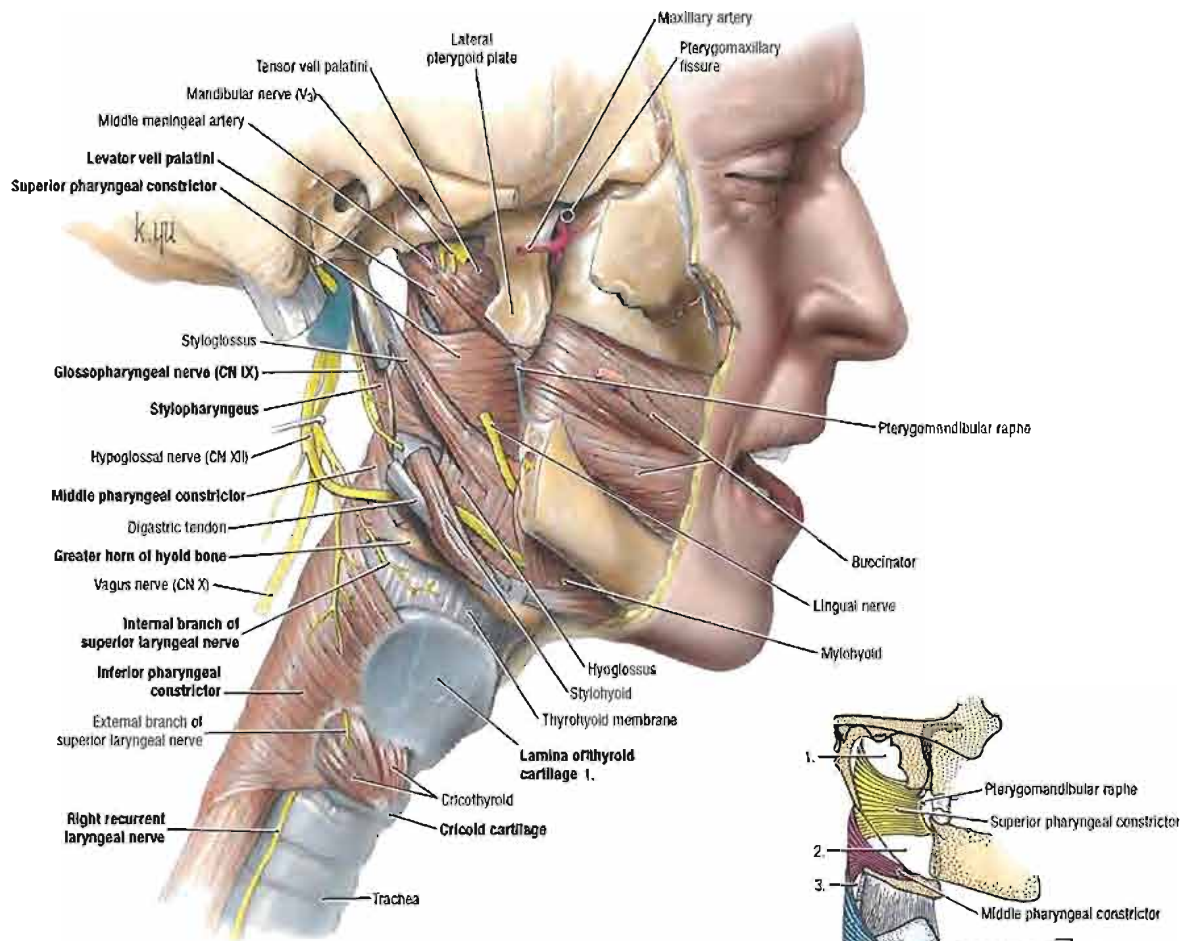
- The pharynx is a unique portion of the alimentary tract, having a circular layer of muscle externally and a longitudinal layer internally.
  - The circular layer of the pharynx consists of the three pharyngeal constrictor muscles (superior, middle, and inferior), which overlap one another.
  - On the right side of the specimen, the stylopharyngeus muscle and glossopharyngeal nerve (IX) pass from the medial side of the styloid process anteromedially through the interval between the superior and middle pharyngeal constrictor muscles to become part of the internal longitudinal layer. The stylohyoid muscle passes from the lateral side of the styloid process anterolaterally and splits on its way to the hyoid bone to accommodate passage of the intermediate tendon of the digastric.
  - Pharyngeal branches of the glossopharyngeal nerve (CN IX) and the vagus nerve (CN X) form the pharyngeal plexus, which provides most of the pharyngeal innervation. The glossopharyngeal nerve supplies the sensory component, while the vagus supplies motor innervation.
-



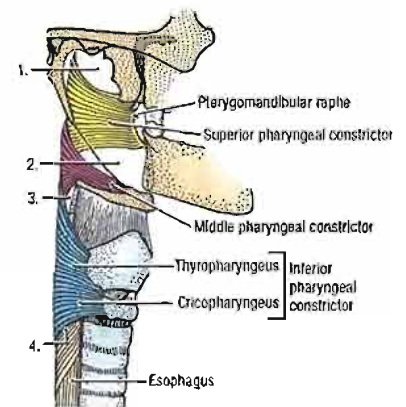




B. Posterior View



C. Lateral View



D. Lateral View

Superior pharyngeal constrictor

Pterygoid hamulus, pterygo-mandibular raphe, posterior end of mylohyoid line of mandible, and side of tongue

Pharyngeal raphe

Pharyngeal and superior laryngeal branches of vagus (CN X) through pharyngeal plexus

Constrict wall of pharynx during swallowing

Middle pharyngeal constrictor

Stylohyoid ligament and superior (greater) and inferior (lesser) horns of hyoid bone

Inferior pharyngeal constrictor

Thyropharyngeus

Cricopharyngeus

(see Fig. 8.20B )

Oblique line of thyroid cartilage

Side of cricoid cartilage

Contralateral side of cricoid cartilage

Pharyngeal and superior laryngeal branches of vagus (CN X) through pharyngeal plexus + external laryngeal plexus

Serves as superior esophageal sphincter

Palatopharyngeus (see Fig. 8.21B )

Hard palate and palatine aponeurosis

Posterior border of lamina of thyroid cartilage and side of pharynx and esophagus

Pharyngeal and superior laryngeal branches of vagus (CN X) through pharyngeal plexus

Elevate pharynx and larynx during swallowing and speaking

Salpingopharyngeus (see Fig. 8.21B )

Cartilaginous part of pharyngotympanic tube

Blends with palatopharyngeus

Stylopharyngeus

Styloid process of temporal bone

Posterior and superior borders of thyroid cartilage with palato-pharyngeus

Glossopharyngeal nerve (CN IX)

Muscle	Origin	Insertion	Innervation	Main Action(s)
--------	--------	-----------	-------------	----------------

---



Table 8.9 Muscles of Pharynx

Authors: Agur, Anne M.R.; Dalley, Arthur F.

Title: *Grant's Atlas of Anatomy, 12th Edition*

Copyright ©2009 Lippincott Williams & Wilkins

> Table of Contents > Chapter 8 - Neck > 8.23 External pharynx " III

---

## 8.23 External pharynx " III

*Part of* "Chapter 8 - Neck "

---

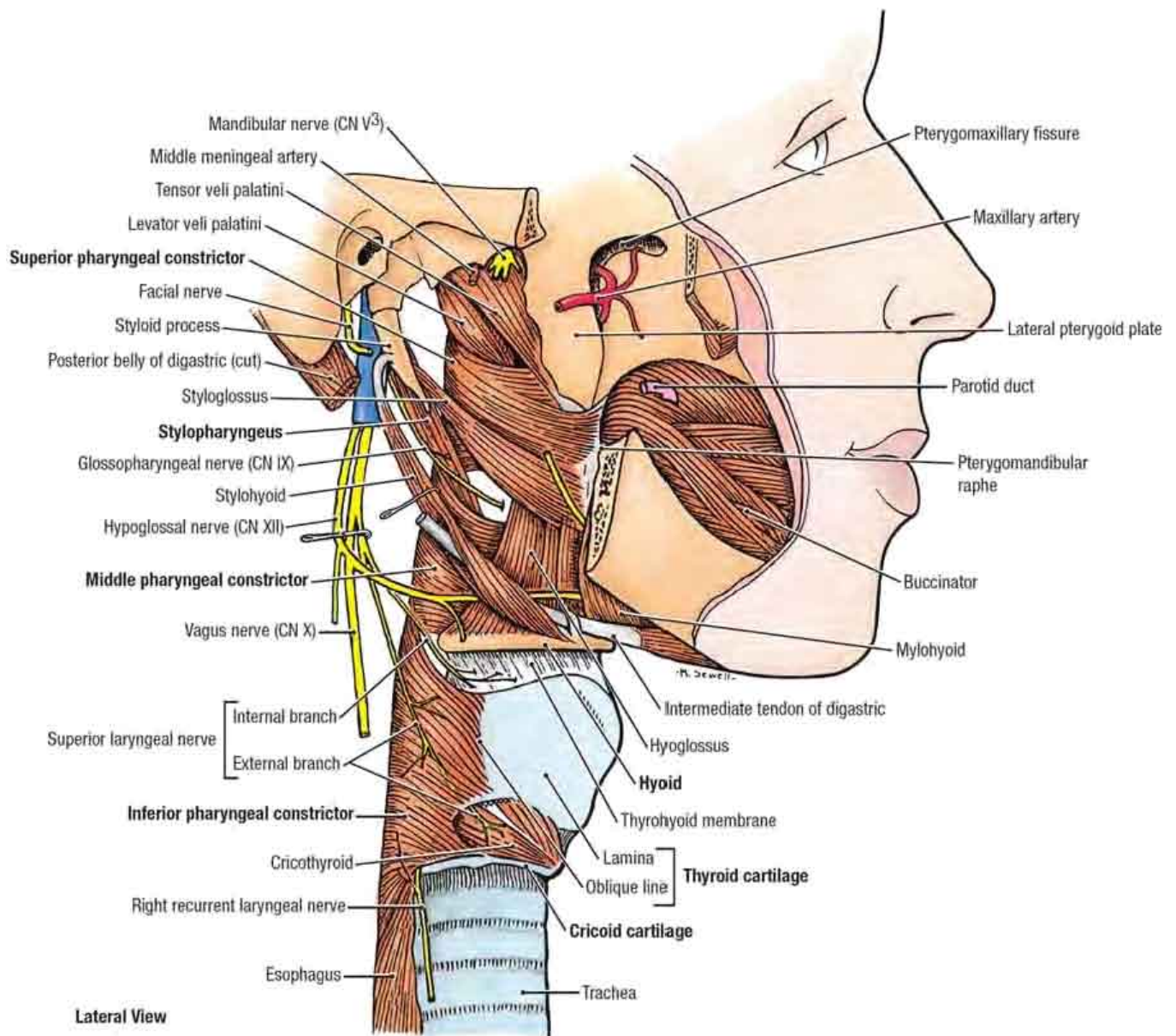
P.789

C and D. Observe that there are gaps in the pharyngeal musculature (1 " 4 in D ) allowing the entry of structures:

- Superior to the superior constrictor muscle: levator veli palatini muscle and pharyngotympanic (auditory) tube (see Fig. 8.24B )
- Between the superior and middle constrictors: stylopharyngeus muscle, CN IX, and stylohyoid ligament
- Between the middle and inferior constrictors: internal branch of superior laryngeal nerve and superior laryngeal artery and nerve (not shown)
- Inferior to the inferior constrictor muscle: recurrent laryngeal nerve

---

P.790



Authors: Agur, Anne M.R.; Dalley, Arthur F.

Title: *Grant's Atlas of Anatomy, 12th Edition*

Copyright ©2009 Lippincott Williams & Wilkins

> Table of Contents > Chapter 8 - Neck > 8.24 Internal pharynx

---

## 8.24 Internal pharynx

*Part of* "Chapter 8 - Neck"

A. Dissection. The posterior wall of the pharynx has been split in the midline and the halves retracted laterally to reveal the internal aspect of the anterior wall of the pharynx, occupied by communications that define three parts of the pharynx: (1) the nasal part (nasopharynx), superior to the level of the soft palate, communicates anteriorly through the choanae with the nasal cavities; (2) the oral part (oropharynx), between the soft palate and the epiglottis, communicates anteriorly through the isthmus of the fauces with the oral cavity; and (3) the laryngeal part (laryngopharynx), posterior to the larynx, communicates with the vestibule of the larynx through the inlet of (aditus to) the larynx. The pharynx extends from the cranial base to the inferior border of the cricoid cartilage. Inferiorly, it is narrowed by the encircling cricopharyngeus.

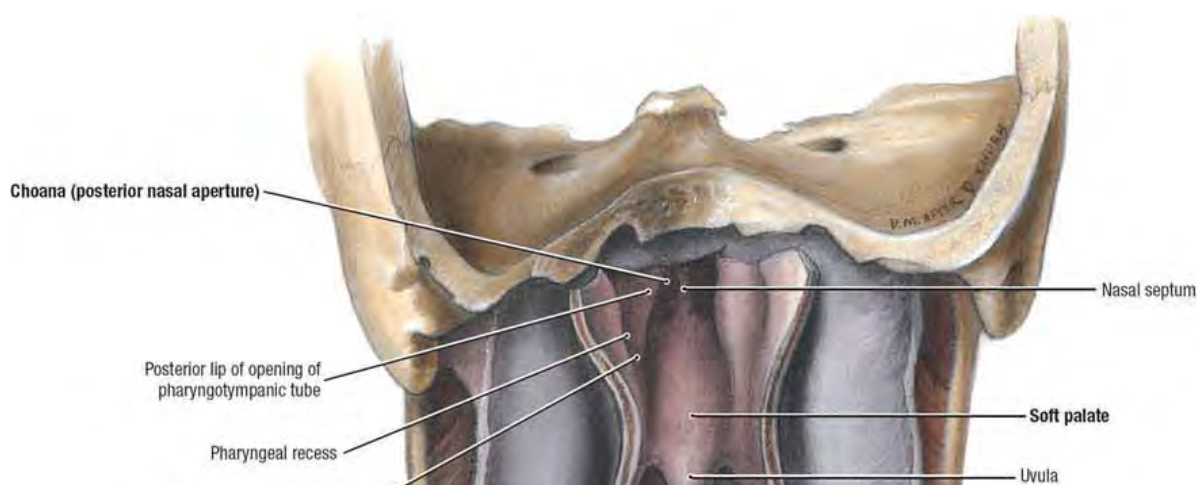
## 8.24 Internal pharynx " II

Part of "Chapter 8 - Neck "

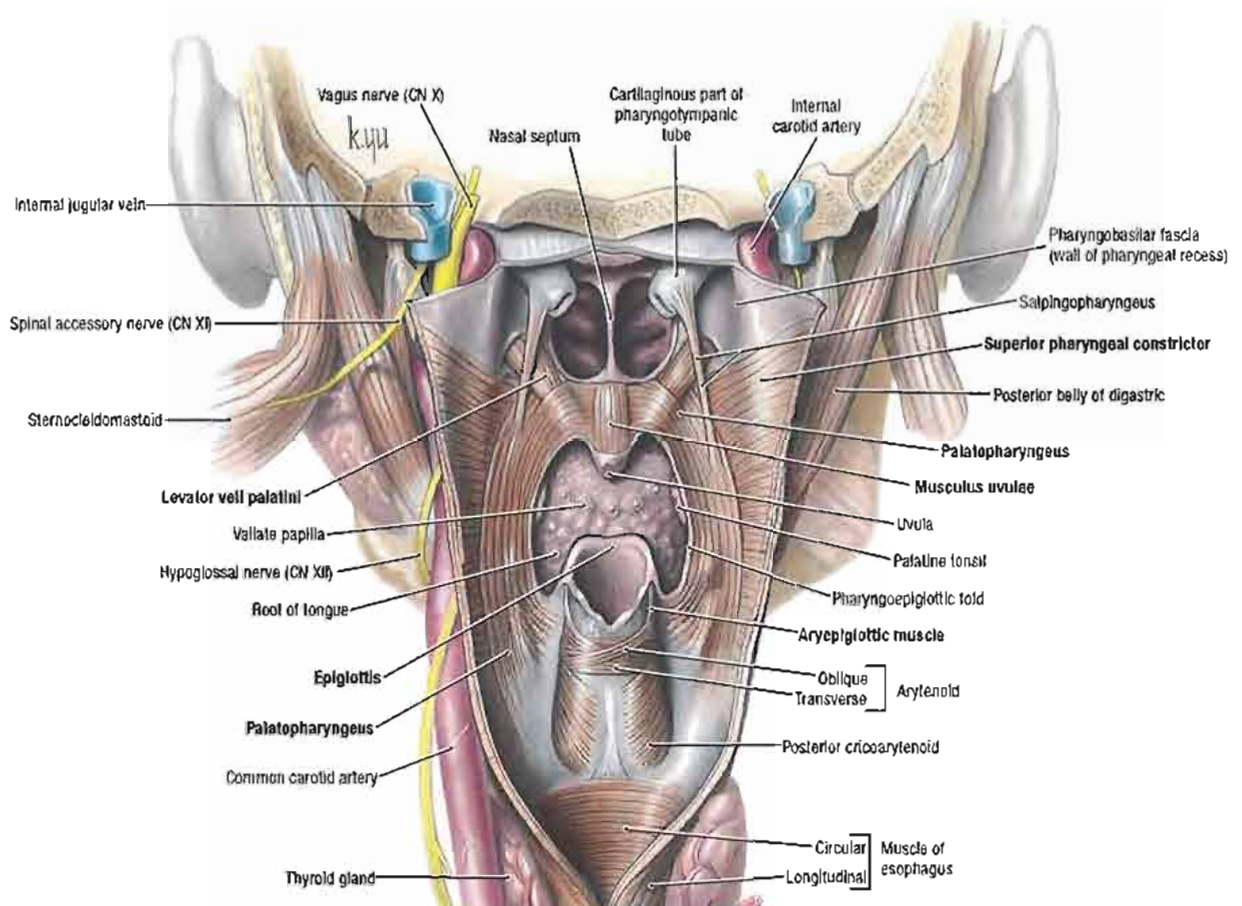
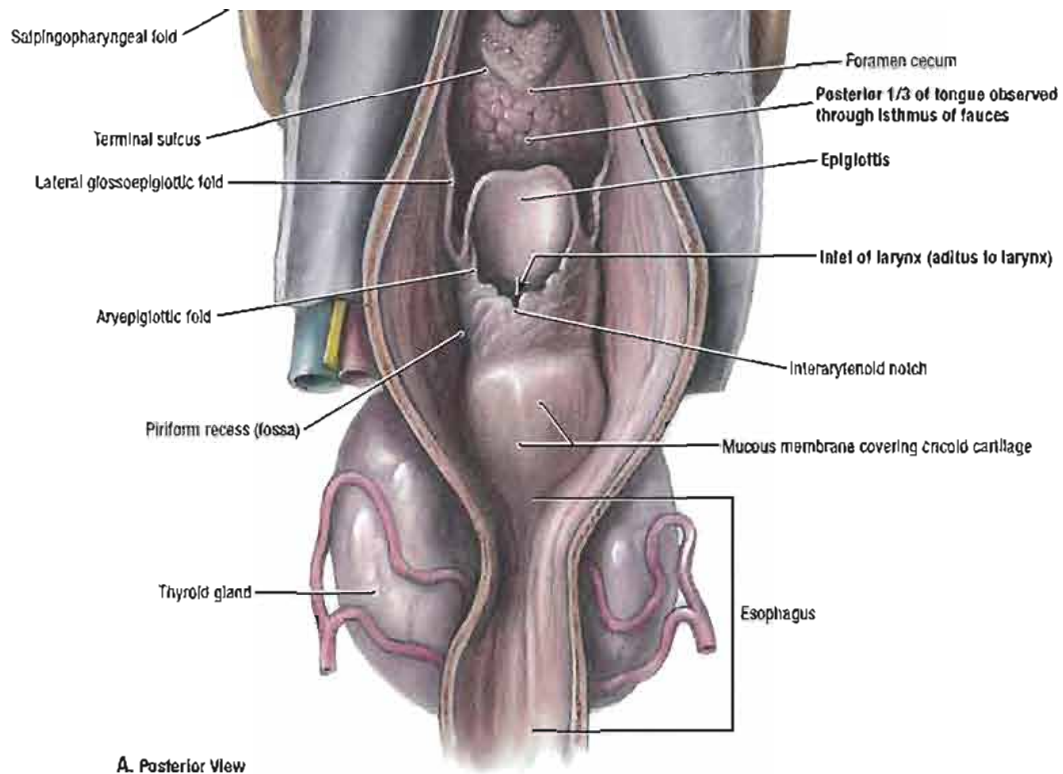
P.791

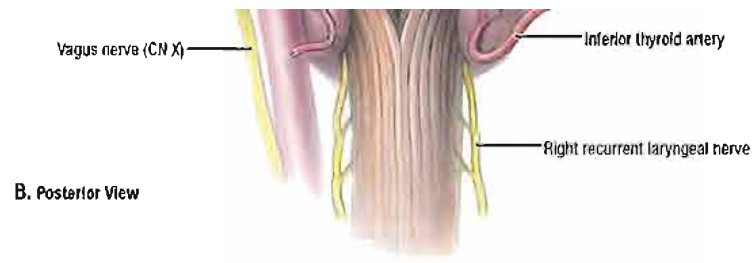
B. Illustration. The posterior wall of the pharynx has been split in the midline and reflected laterally as in A ; then, the mucous membrane was removed to expose the underlying musculature. The muscles of the soft palate, pharynx, and larynx work together during swallowing, elevating the soft palate, narrowing the pharyngeal isthmus (passageway between the nasal and oral parts of the pharynx) and laryngeal inlet, retracting the epiglottis, and closing the glottis, to keep food and drink out of the nasopharynx and larynx as they pass from oral cavity to esophagus. At other times, as when blowing one's nose, the palatopharyngeus muscles, partially encircling the opening to the oral cavity, constrict this opening and depress the soft palate, working with placement and expansion of the posterior tongue to direct expired air through the nasal cavity.

P.792









Authors: Agur, Anne M.R.; Dalley, Arthur F.

Title: *Grant's Atlas of Anatomy, 12th Edition*

Copyright ©2009 Lippincott Williams & Wilkins

> Table of Contents > Chapter 8 - Neck > 8.25 Surface anatomy of isthmus of the fauces  
(oropharyngeal isthmus)

---

## 8.25 Surface anatomy of isthmus of the fauces (oropharyngeal isthmus)

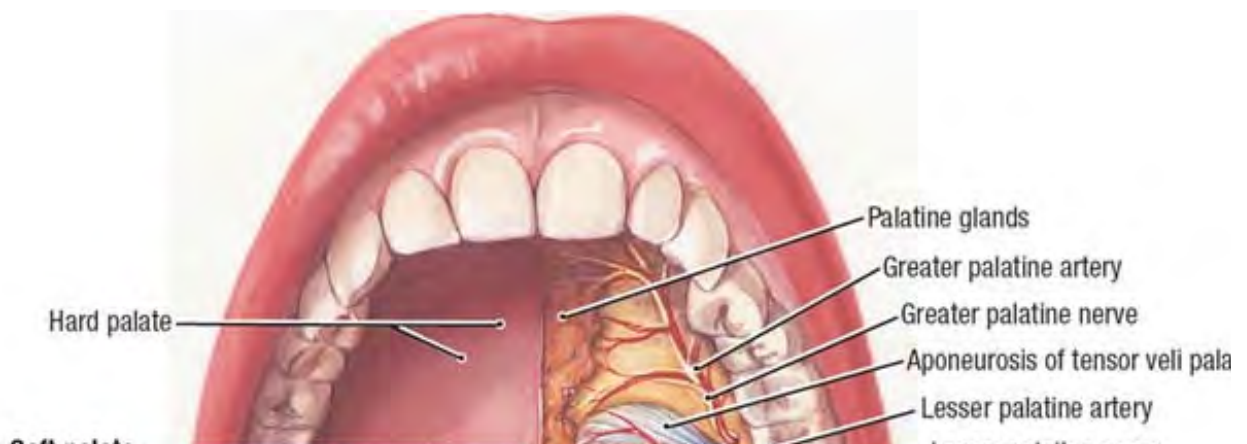*Part of* "Chapter 8 - Neck "

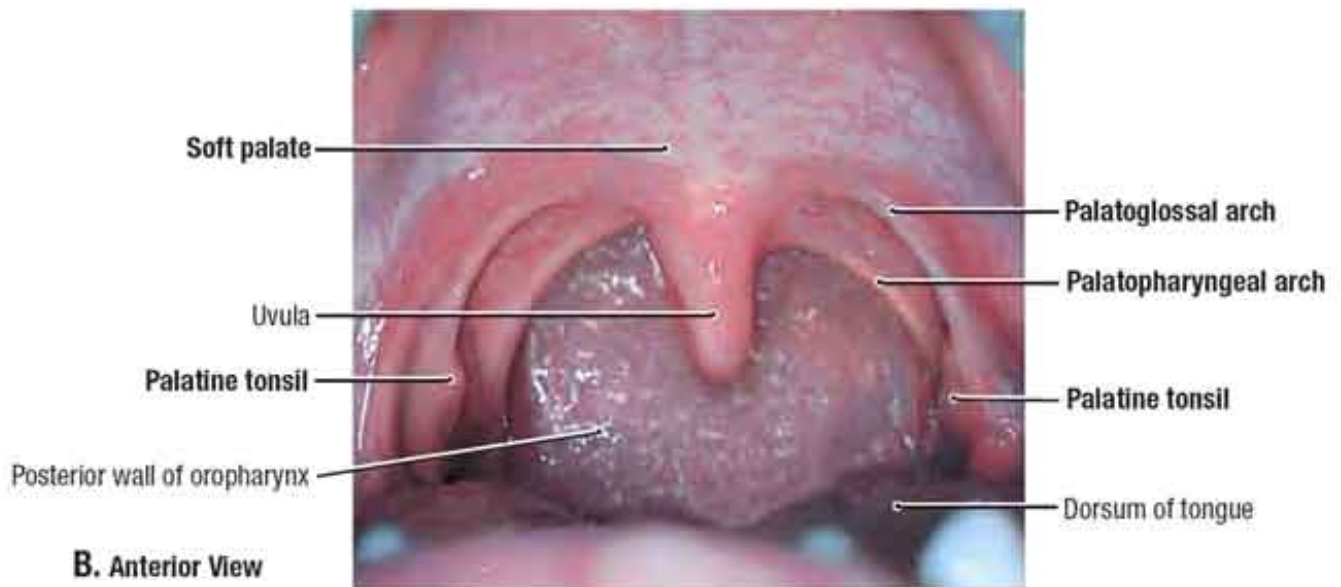
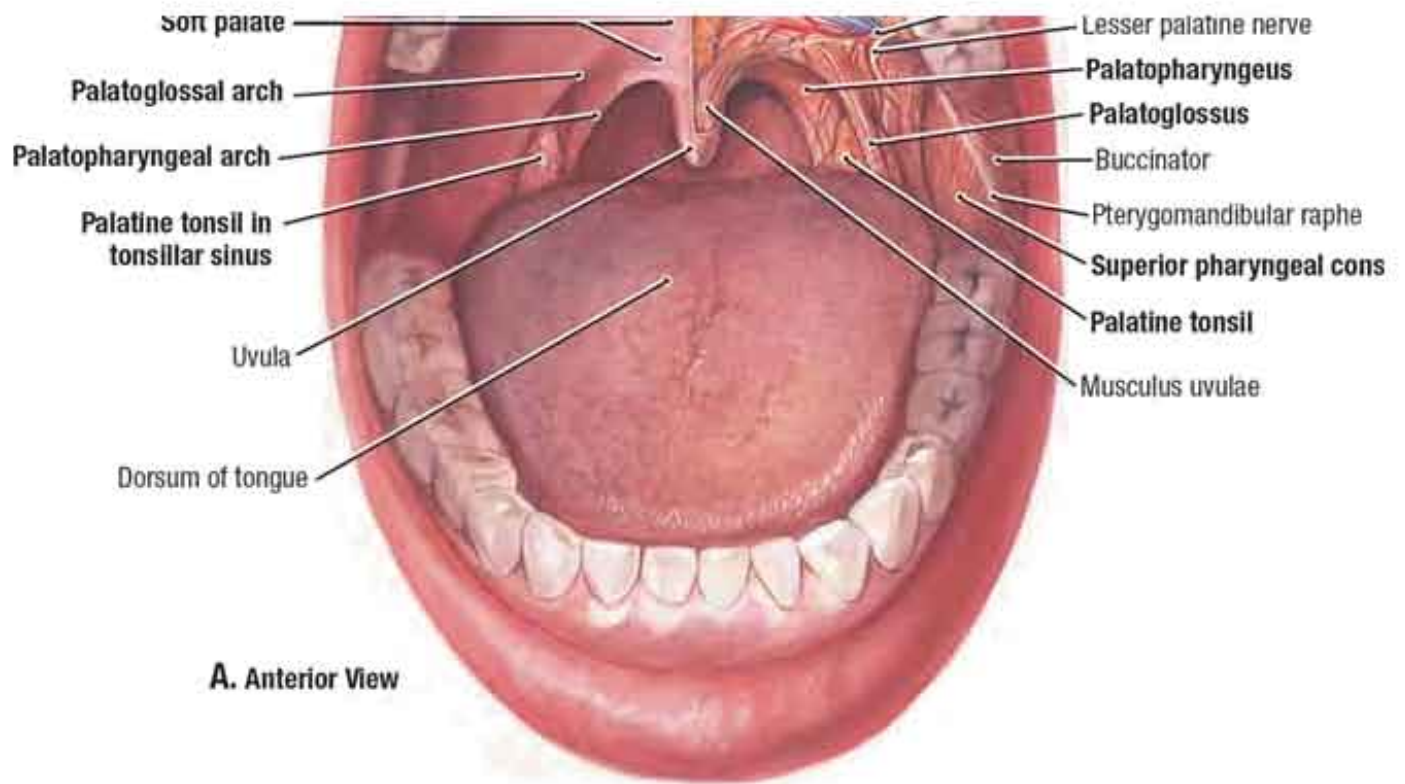
A. Oral cavity and isthmus demonstrating the sinus (bed) of the tonsils. B. Tonsillar sinuses, palatine tonsils in situ, and oropharynx.

- The fauces (throat), the passage from the mouth to the pharynx, is bounded superiorly by the soft palate, inferiorly by the root (base) of the tongue, and laterally by the palatoglossal and palatopharyngeal arches.
- The palatine tonsils are located between the palatoglossal and palatopharyngeal arch formed by mucosa overlying the similarly named muscles; the arches form the boundaries, and the superior pharyngeal constrictor the floor, of the tonsillar sinuses.

---

P.793





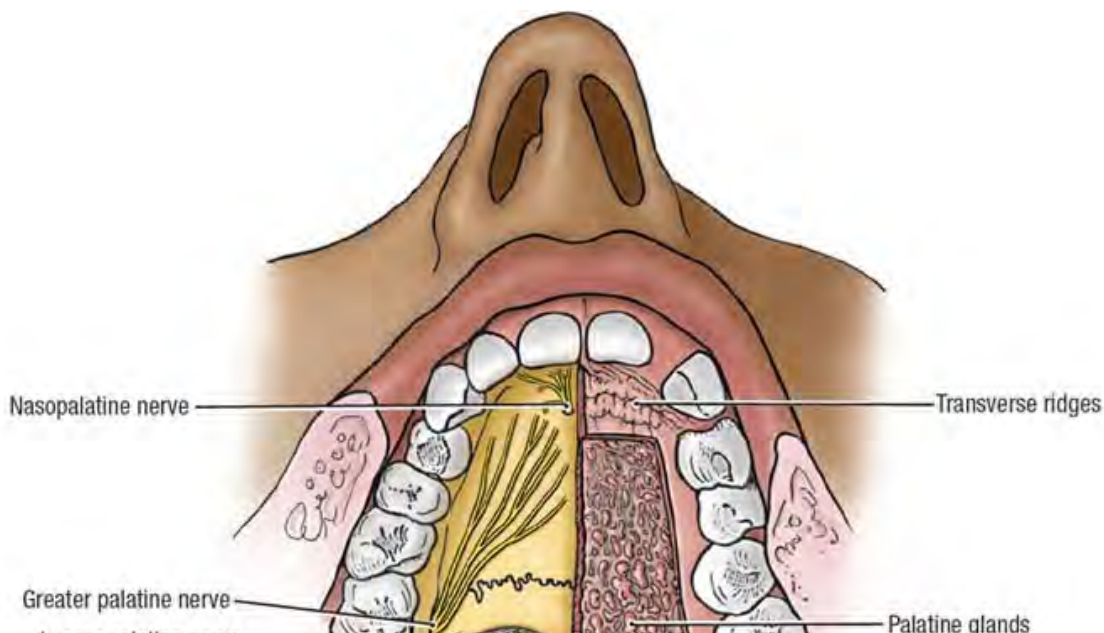
## 8.26 Palatine tonsil

*Part of "Chapter 8 - Neck "*

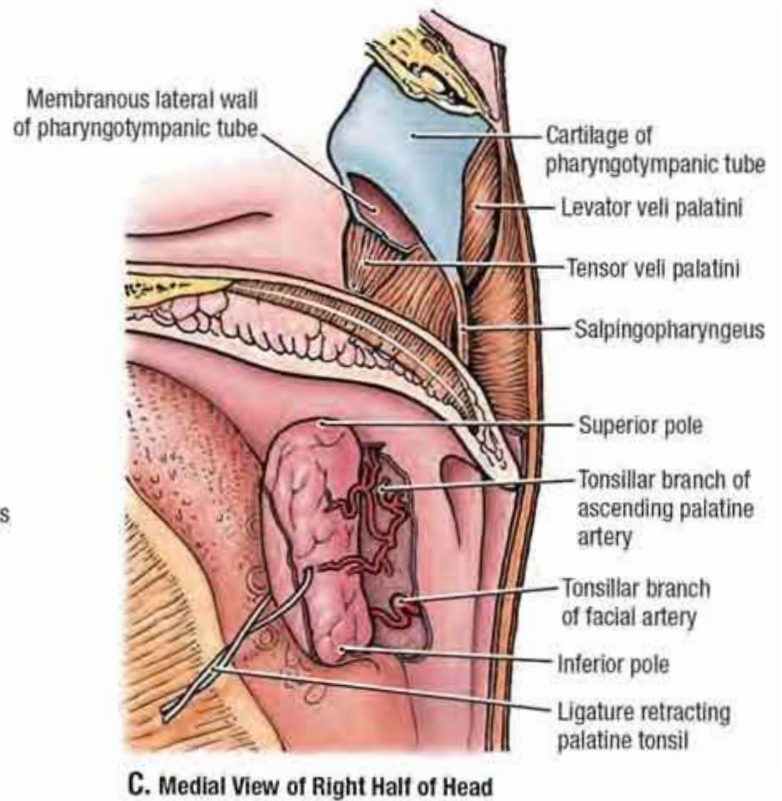
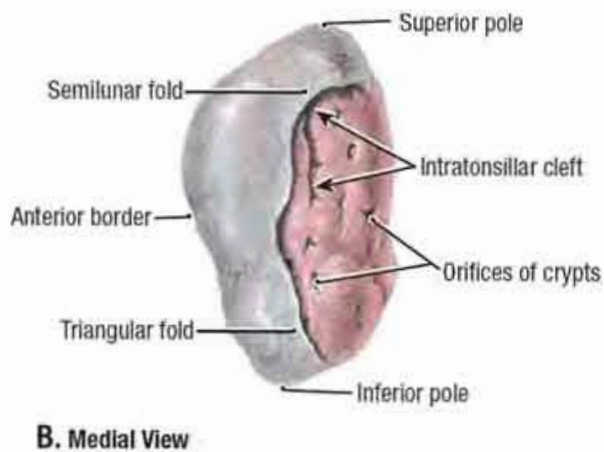
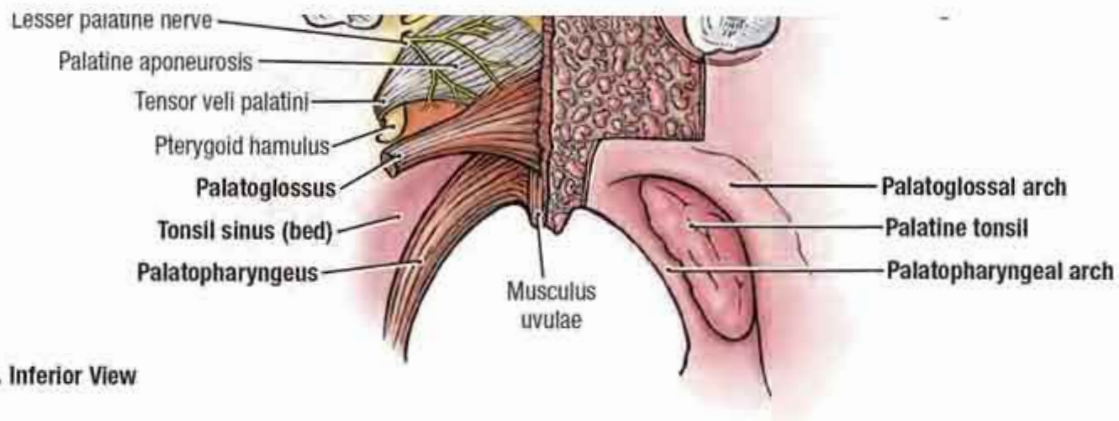
A. Left side: Palatine tonsil in situ and glands of palatine mucosa. Right side: Palatine mucosa and tonsils removed demonstrating palatine nerves and muscles. B. Isolated palatine tonsil. C. Tonsillectomy. The procedure involves removal of the tonsil and the fascial sheet covering the tonsillar sinus. Because of the rich blood supply of the tonsil, bleeding commonly arises from the large external palatine vein or less commonly from the tonsillar artery or other arterial twigs. The glossopharyngeal nerve accompanies the tonsillar artery on the lateral wall of the pharynx and is vulnerable to injury because this wall is thin. The internal carotid artery is especially vulnerable when it is tortuous, as it lies directly lateral to the tonsil.

---

P.794







Authors: Agur, Anne M.R.; Dalley, Arthur F.

Title: *Grant's Atlas of Anatomy, 12th Edition*

Copyright ©2009 Lippincott Williams & Wilkins

> Table of Contents > Chapter 8 - Neck > 8.27 Serial dissection of isthmus of fauces and lateral wall of nasopharynx

---

## 8.27 Serial dissection of isthmus of fauces and lateral wall of nasopharynx

*Part of "Chapter 8 - Neck"*

- The pharyngeal opening of the pharyngotympanic tube is located approximately 1 cm posterior to the inferior concha.
- The numerous pinpoint orifices of the ducts of the mucous glands can be seen in the mucosa of the torus.
- The pharyngeal tonsil lies in the mucous membrane of the roof and posterior wall of the nasopharynx.
- The palatine glands lie in the soft palate.
- The palatine tonsil lies in the tonsillar sinus between the palatoglossal and palatopharyngeal arches.
- Each lingual follicle has the duct of a mucous gland opening onto its surface; collectively, the follicles are known as the lingual tonsil.

Authors: Agur, Anne M.R.; Dalley, Arthur F.

Title: *Grant's Atlas of Anatomy, 12th Edition*

Copyright ©2009 Lippincott Williams & Wilkins

> Table of Contents > Chapter 8 - Neck > 8.27 Serial dissection of isthmus of fauces and lateral wall of nasopharynx€"II

---

## 8.27 Serial dissection of isthmus of fauces and lateral wall of nasopharynx€"II

*Part of*"Chapter 8 - Neck"

---

P.795

Muscles underlying tonsillar sinus and wall of nasopharynx. The palatine and pharyngeal tonsils and mucous membrane have been removed. The pharyngobasilar fascia, which attaches the pharynx to the basilar part of the occipital bone was also removed, except at the superior, arched border of the superior pharyngeal constrictor.

Authors: Agur, Anne M.R.; Dalley, Arthur F.

Title: *Grant's Atlas of Anatomy, 12th Edition*

Copyright ©2009 Lippincott Williams & Wilkins

> Table of Contents > Chapter 8 - Neck > 8.27 Serial dissection of isthmus of the fauces and lateral wall of nasopharynx€" III

---

## 8.27 Serial dissection of isthmus of the fauces and lateral wall of nasopharynx€" III

*Part of* "Chapter 8 - Neck"

---

P.796

Neurovascular structures of tonsillar sinus and longitudinal muscles of the pharynx.

- In this deeper dissection, the tongue was pulled anteriorly, and the inferior part of the origin of the superior pharyngeal constrictor muscle was cut away.
- The glossopharyngeal nerve passes to the posterior one third of the tongue and lies anterior to the stylopharyngeus muscle.
- The tonsillar branch of the facial artery sends a branch (cut short here) to accompany the glossopharyngeal nerve to the tongue; the submandibular gland is seen lateral to the artery and external palatine (paratonsillar) vein.

Authors: Agur, Anne M.R.; Dalley, Arthur F.

Title: *Grant's Atlas of Anatomy, 12th Edition*

Copyright ©2009 Lippincott Williams & Wilkins

> Table of Contents > Chapter 8 - Neck > 8.27 Serial dissection of isthmus of the fauces  
lateral wall of nasopharynx " IV

---

## 8.27 Serial dissection of isthmus of the fauces lateral wall of nasopharynx " IV

Part of "Chapter 8 - Neck "

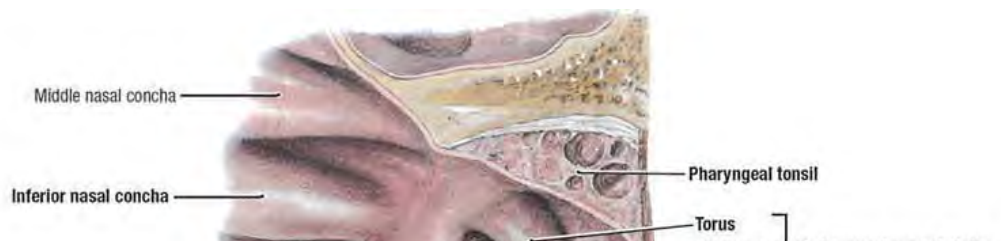---

P.797

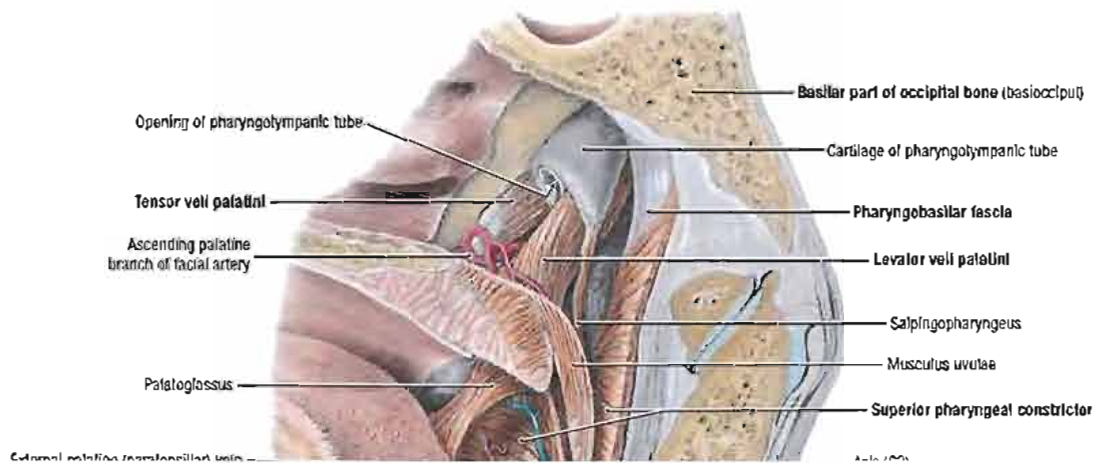
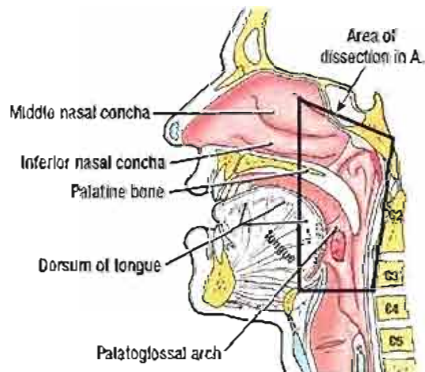
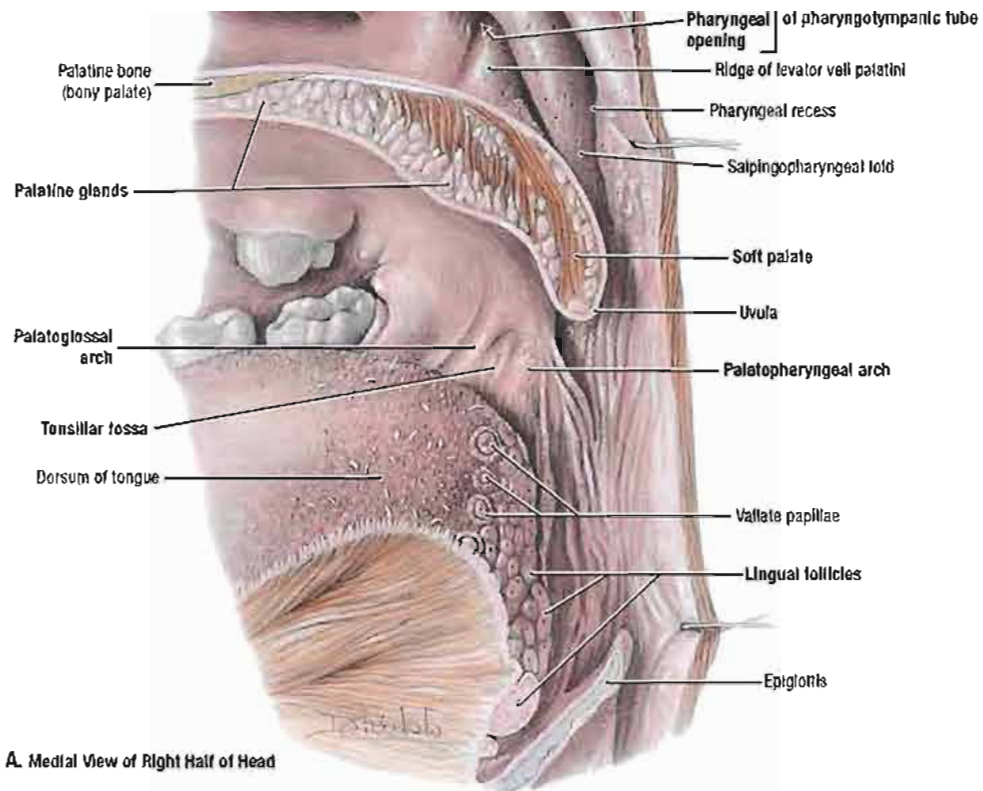
- The superior pharyngeal constrictor muscle arises from (a) the pterygomandibular raphe, which unites it to the buccinator muscle; (b) the bones at each end of the raphe, the hamulus of the medial pterygoid plate superiorly and the mandible inferiorly; and (c) the root (posterior part) of the tongue.
- The middle pharyngeal constrictor muscle arises from the angle formed by the greater and lesser horns of the hyoid bone and from the stylohyoid ligament; in this specimen, the styloid process is long and, therefore, a lateral relation of the tonsil.
- The lingual nerve is joined by the chorda tympani, disappears at the posterior border of the medial pterygoid muscle, and reappears at the anterior border to follow the mandible.

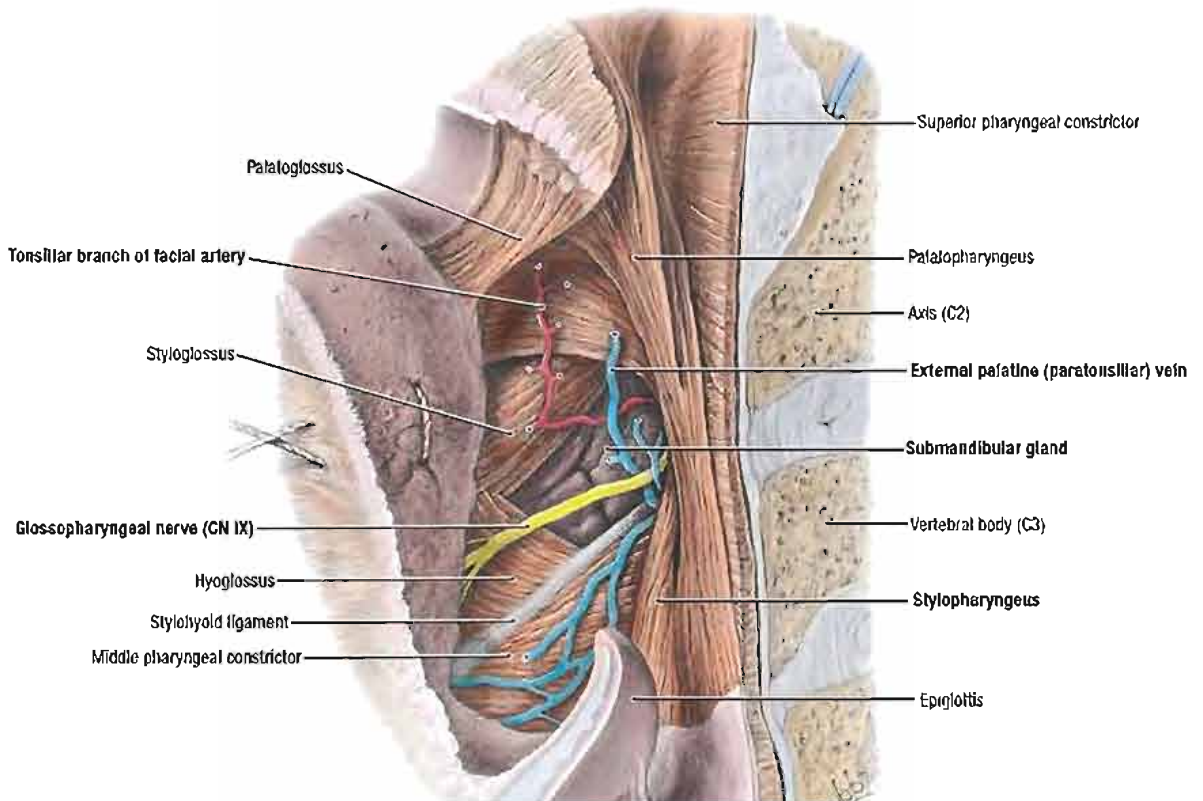
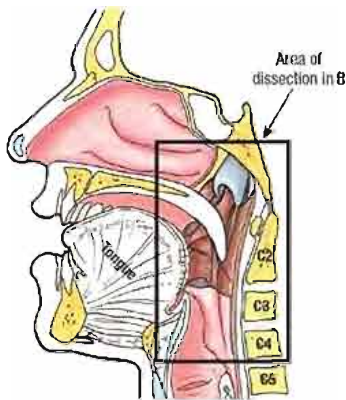
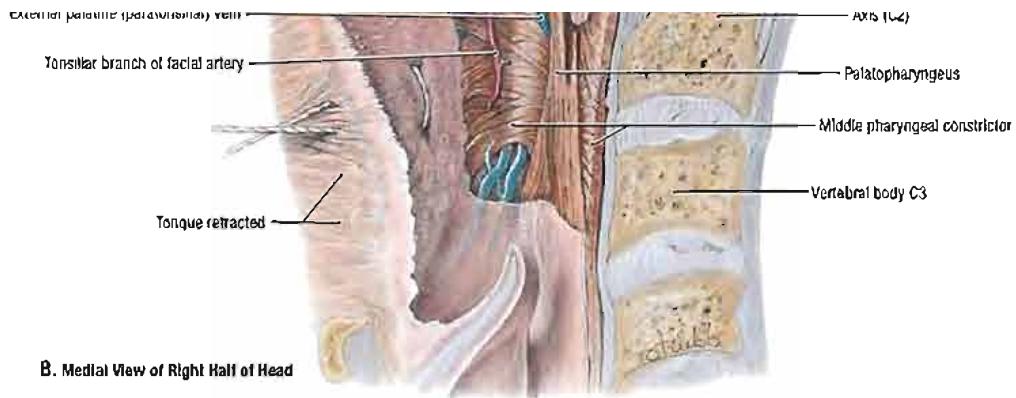
---

P.798

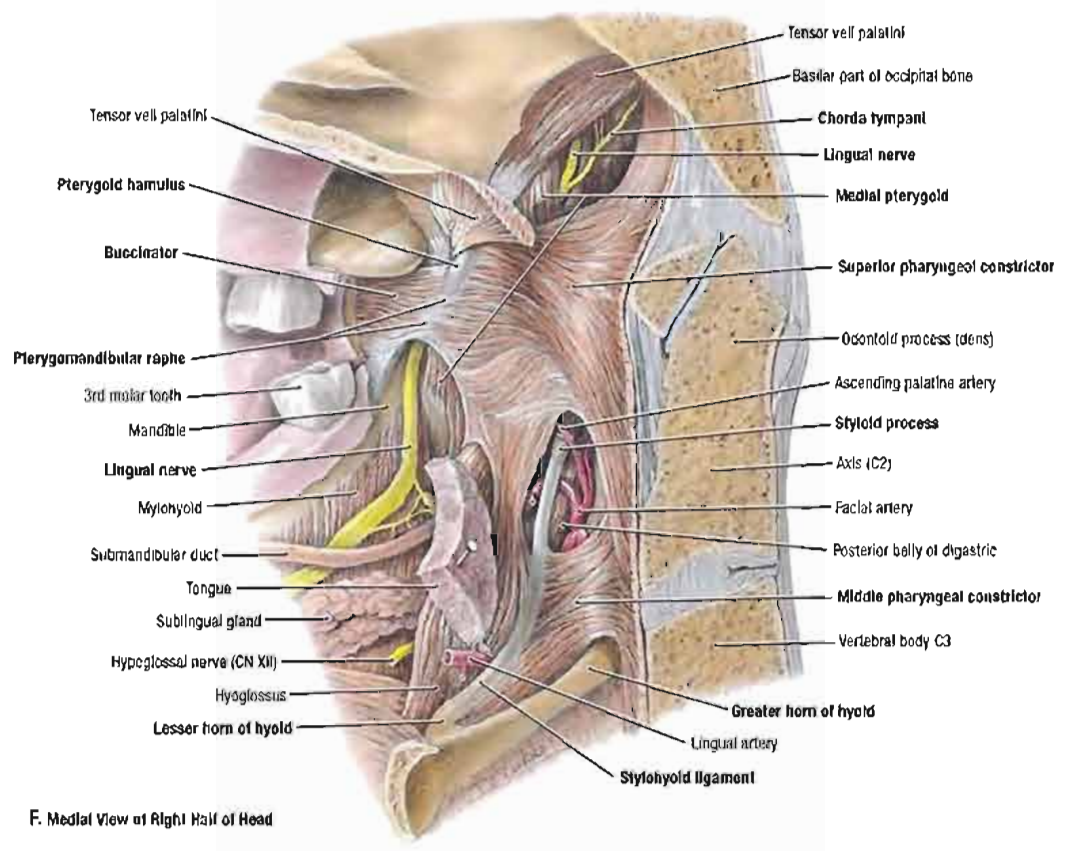
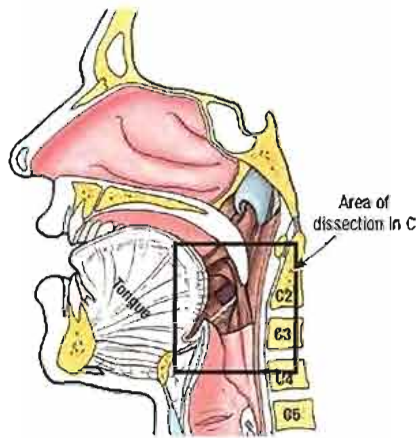






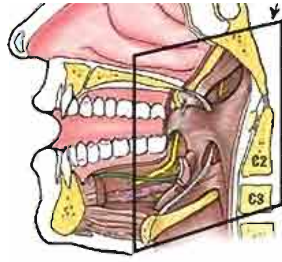


C. Medial View of Right Half of Head



F. Medial View of Right Half of Head





Authors: Agur, Anne M.R.; Dalley, Arthur F.

Title: *Grant's Atlas of Anatomy, 12th Edition*

Copyright ©2009 Lippincott Williams & Wilkins

> Table of Contents > Chapter 8 - Neck > 8.28 Cartilages of the laryngeal skeleton

---

## 8.28 Cartilages of the laryngeal skeleton

Part of "Chapter 8 - Neck "

---

P.799

A, B , and E. Articulated laryngeal skeleton. C and D. Cartilages disarticulated and separated. F. Epiglottis and hyoepiglottic ligament. G. Conus elasticus and rima glottidis.

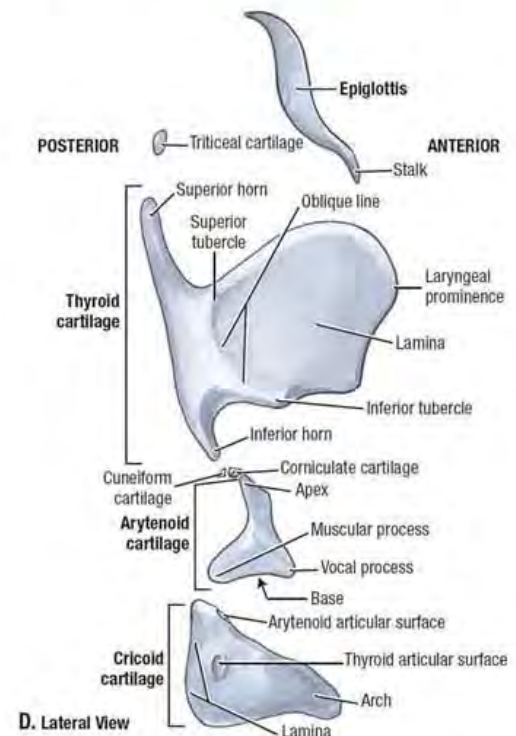
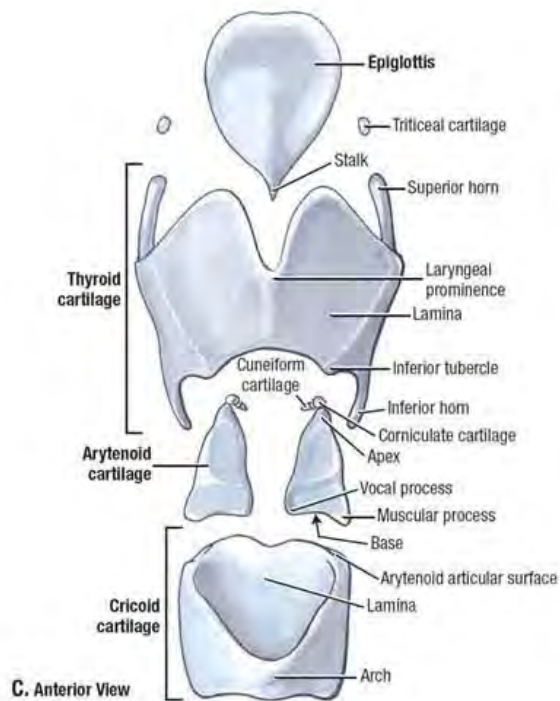
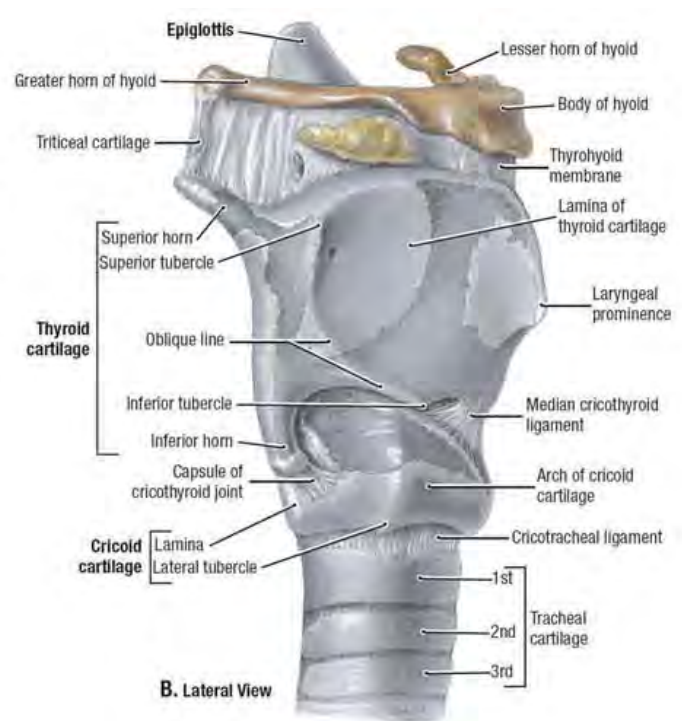
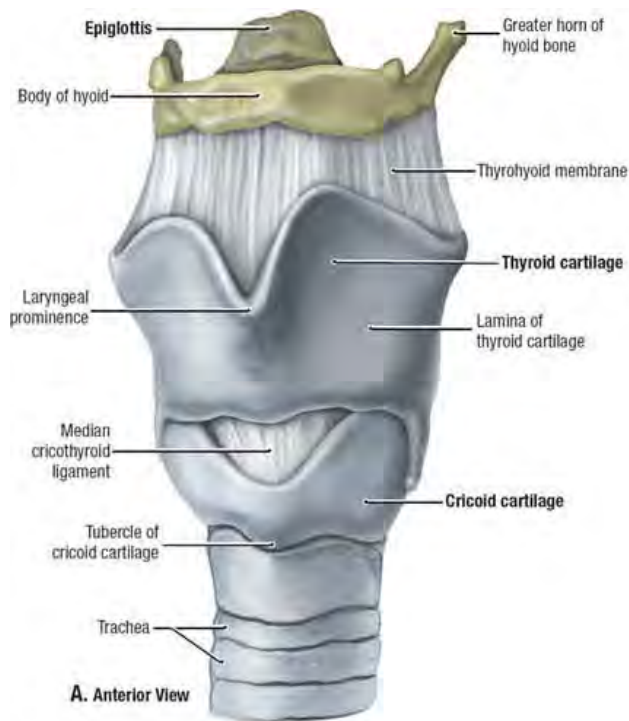
- The larynx extends vertically from the tip of the epiglottis to the inferior border of the cricoid cartilage. The hyoid bone is generally not regarded as part of the larynx.
- The cricoid cartilage is the only cartilage that totally encircles the airway.
- The rima glottidis is the aperture between the vocal folds. During normal respiration, it is narrow and wedge shaped; during forced respiration, it is wide. Variations in the tension and length of the vocal folds, in the width of the rima glottidis, and in the intensity of the expiratory effort produce changes in the pitch of the voice.

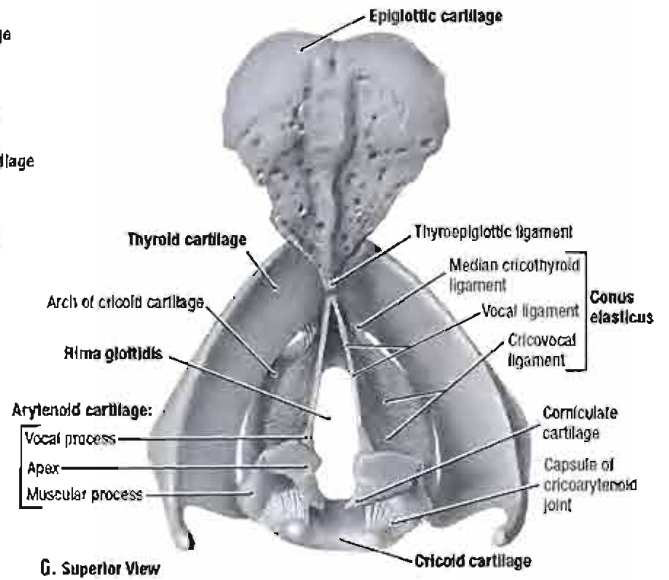
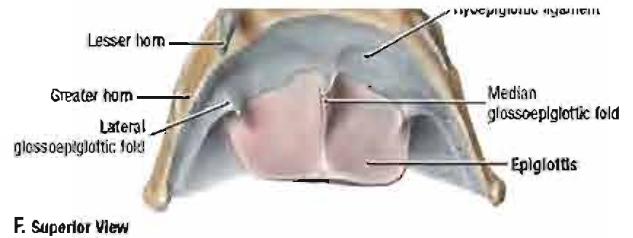
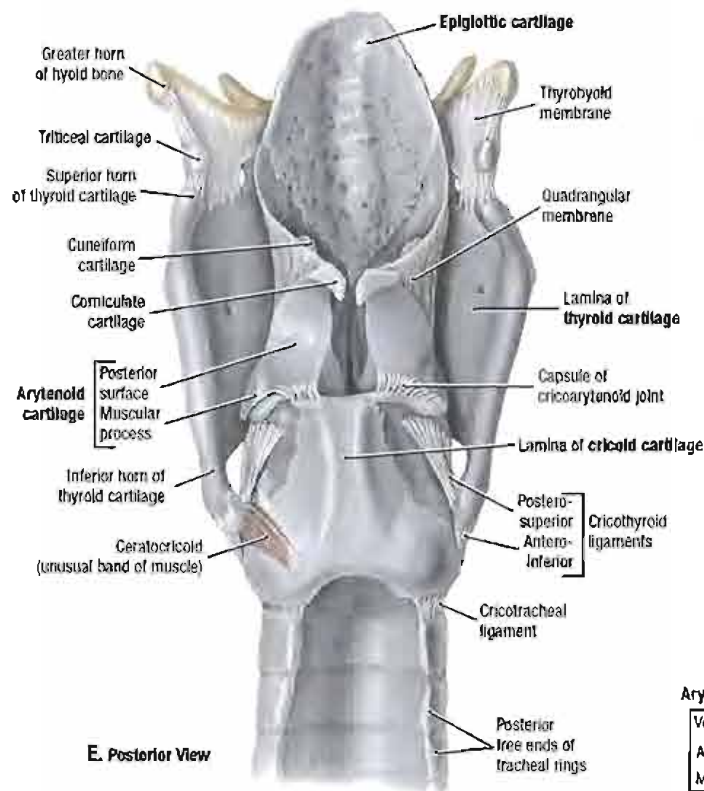
- Laryngeal fractures may result from blows received in sports such as kickboxing and hockey or from compression by a shoulder strap during an automobile accident. Laryngeal fractures produce submucous hemorrhage and edema, respiratory obstruction, hoarseness, and sometimes a temporary inability to speak. The thyroid, cricoid, and most of the arytenoid cartilages often ossify as age advances, commencing at approximately 25 years of age in the



# thyroid cartilage.

P.800





Authors: Agur, Anne M.R.; Dalley, Arthur F.

Title: *Grant's Atlas of Anatomy, 12th Edition*

Copyright ©2009 Lippincott Williams & Wilkins

> Table of Contents > Chapter 8 - Neck > 8.29 External larynx and laryngeal nerves

---

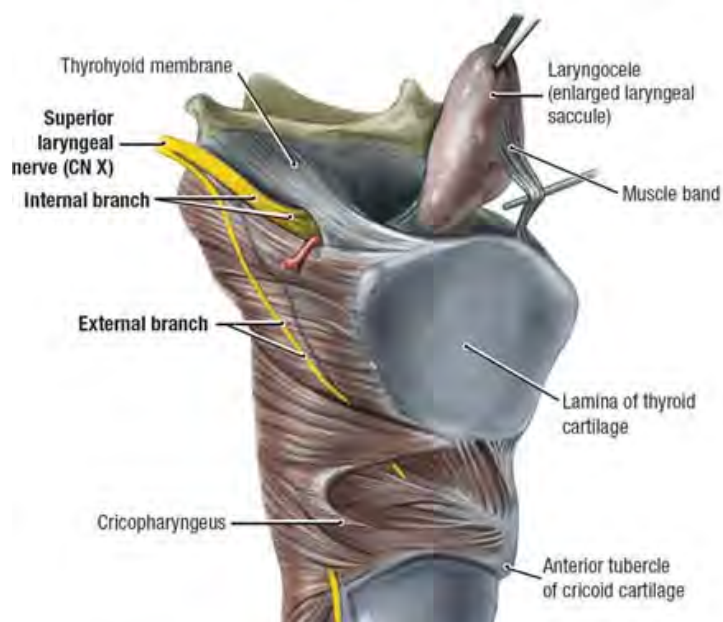
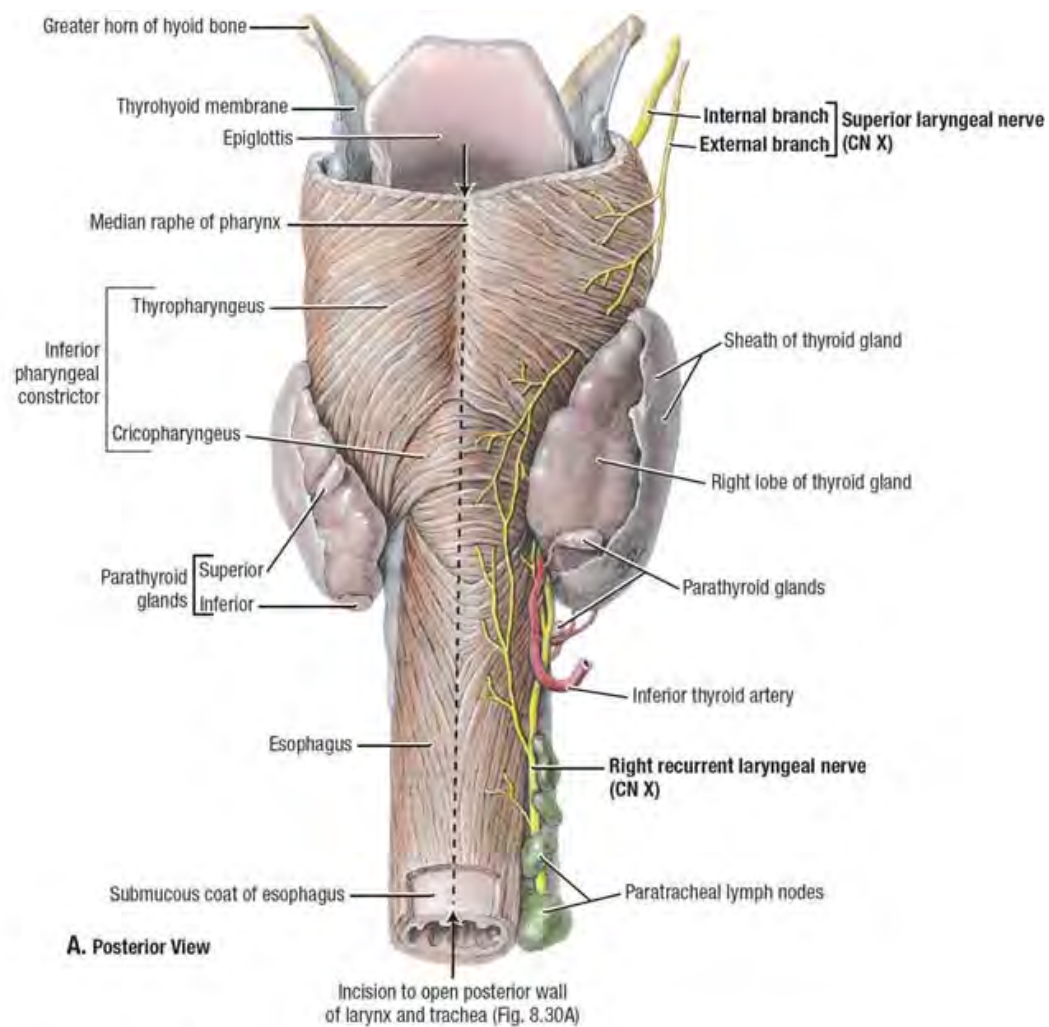
## 8.29 External larynx and laryngeal nerves

*Part of* "Chapter 8 - Neck "

A. Posterior aspect.

- The internal branch of the superior laryngeal nerve innervates the mucous membrane superior to the vocal folds, and the external laryngeal branch supplies the inferior pharyngeal constrictor and cricothyroid muscles.
- The recurrent laryngeal nerve supplies the esophagus, trachea, and inferior pharyngeal constrictor muscle. It supplies sensory innervation inferior to the vocal folds and motor innervation to the intrinsic muscles of the larynx, except the cricothyroid.

B. Laryngoceles. A laryngocoele (enlarged laryngeal sacculle) projects through the thyrohyoid membrane and communicates with the larynx through the ventricle. This air sac can form a bulge in the neck, especially on coughing. The inferior laryngeal nerves are vulnerable to injury during operations in the anterior triangles of the neck. Injury of the nerve results in paralysis of the vocal fold. The voice is initially poor because the paralyzed fold cannot adduct to meet the normal vocal fold. In a bilateral paralysis, the voice is almost absent. Injury to the external branch of the superior laryngeal nerve results in a voice that is monotonous in character because the cricothyroid muscle is unable to vary the tension of the vocal fold. Hoarseness is the most common symptom of serious disorders of the larynx.



**B. Lateral View Before  
Removal of the Right  
Thyroid Cartilage**





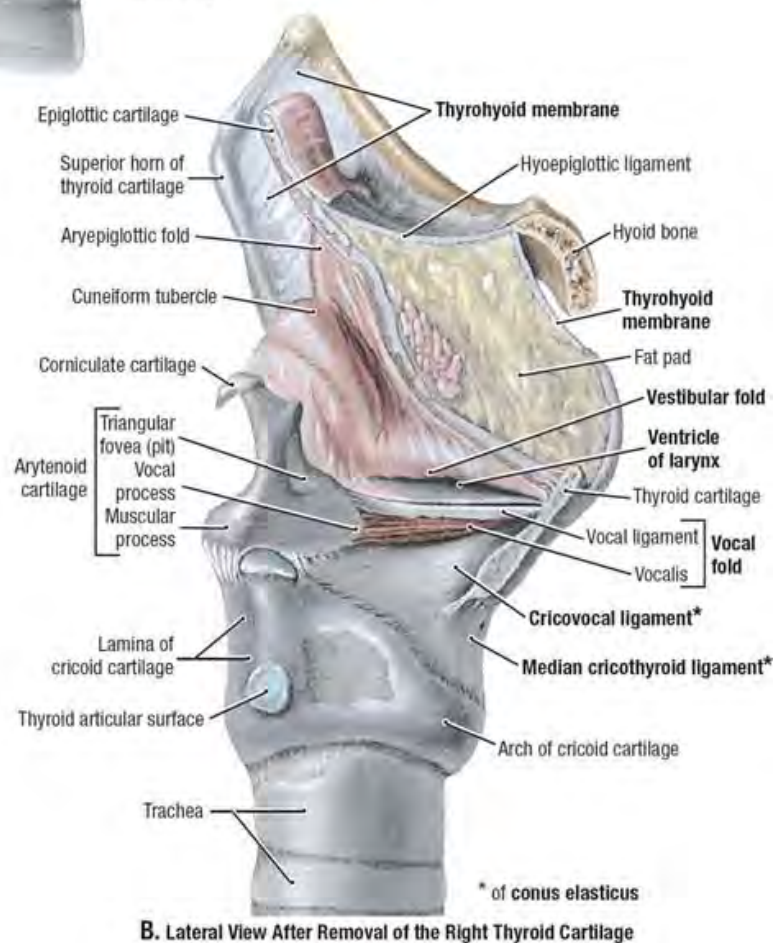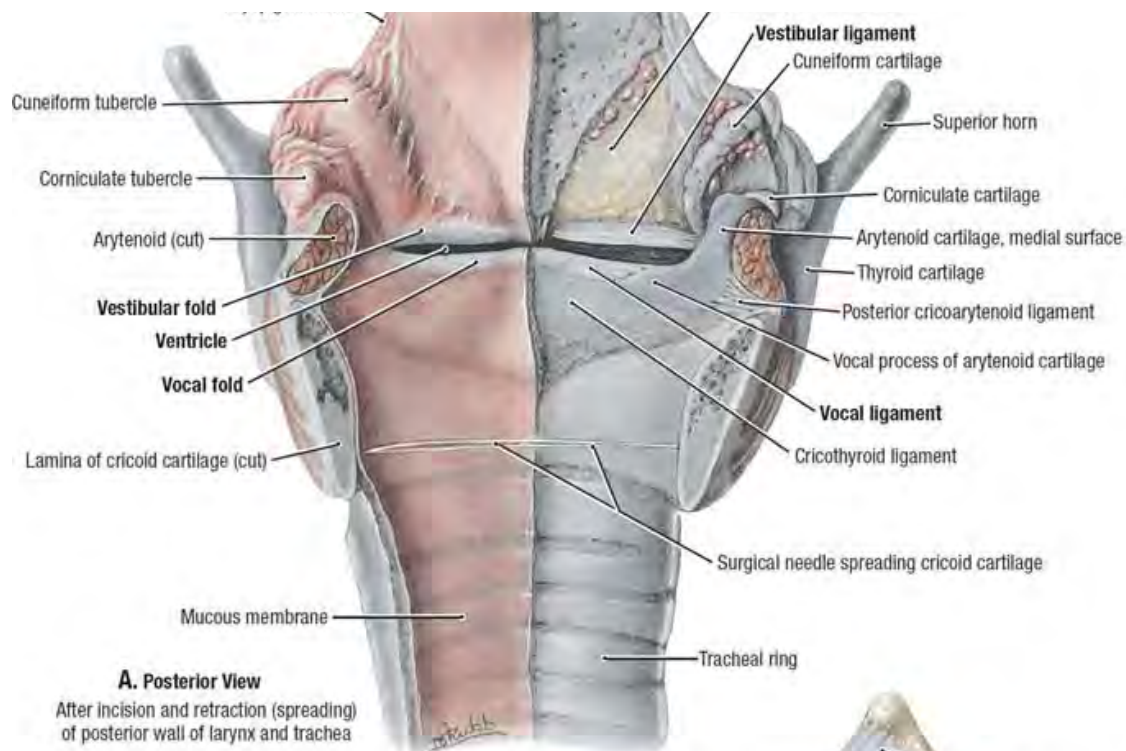
## 8.30 Internal larynx

Part of "Chapter 8 - Neck "

A. The posterior wall of the larynx was split in the median plane (see Figure 8.29A ), and the two sides held apart. On the left side of the specimen, the mucous membrane, which is the innermost coat of the larynx, is intact; on the right side of the specimen, the mucous and submucous coats were peeled off, and the next coat, consisting of cartilages, ligaments, and fibroelastic membrane, was uncovered. B. Interior of the larynx superior to the vocal folds. The larynx was sectioned near the median plane to reveal the interior of its left side. Inferior to this level, the right side of the intact larynx was dissected. The thyrohyoid membrane is intact; there is no laryngocele.

- The three compartments of the larynx are (a) the superior compartment of the vestibule, superior to the level of the vestibular folds (false cords); (b) the middle, between the levels of the vestibular and vocal folds; and (c) the inferior, or infraglottic, cavity, inferior to the level of the vocal folds.
- The quadrangular membrane underlies the aryepiglottic fold superiorly and is thickened inferiorly to form the vestibular ligament. The cricothyroid ligament (conus elasticus) begins inferiorly as the strong median cricothyroid ligament and is thickened superiorly as the vocal ligament. The lateral recess between the vocal and vestibular ligaments, lined with mucous membrane, is the ventricle.



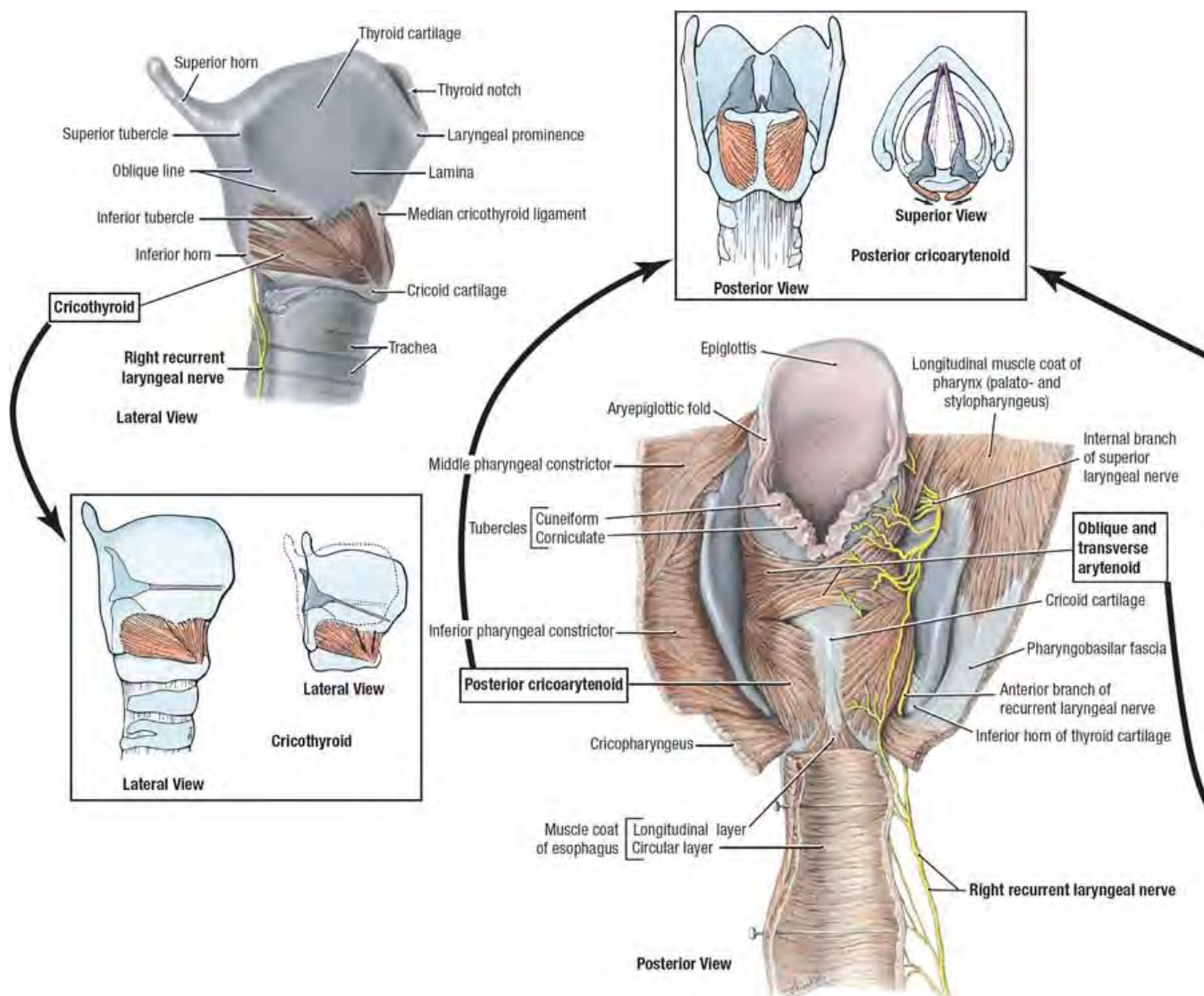


Cricothyroid

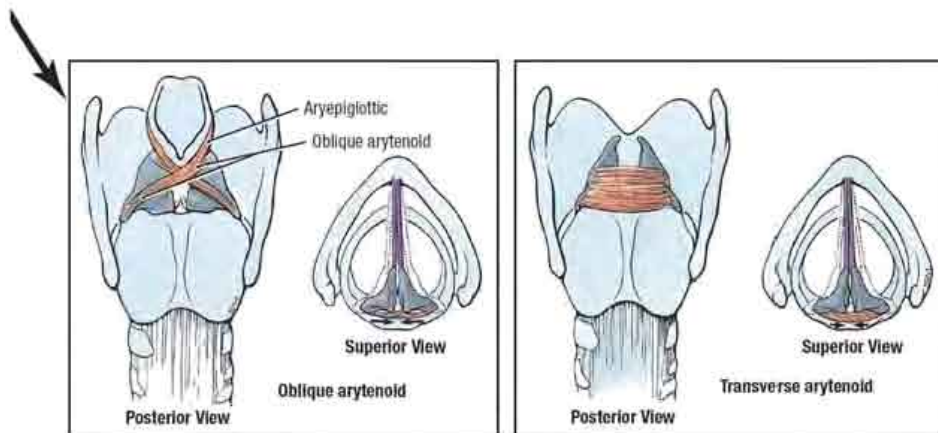
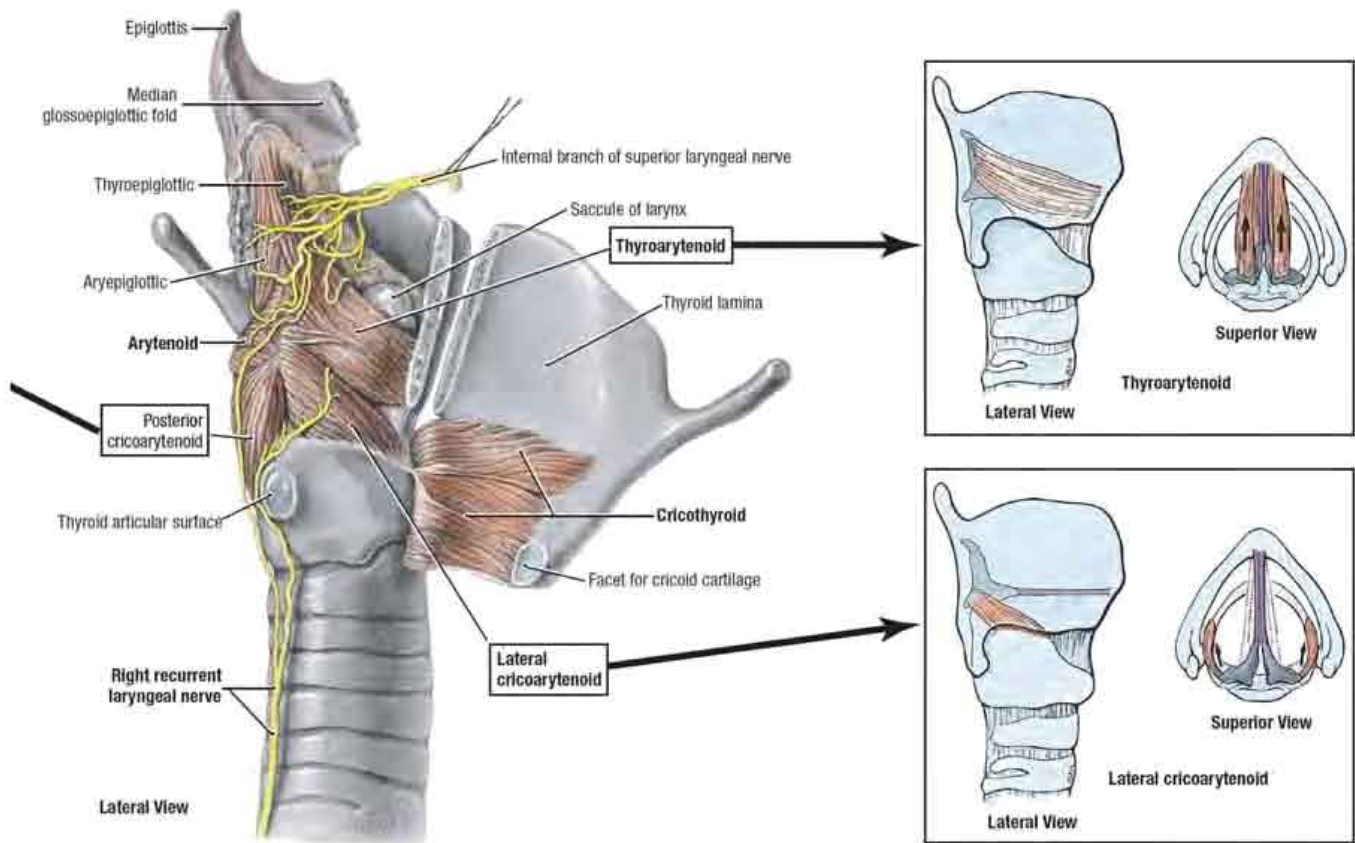
Anterolateral part of cricoid cartilage  
 Inferior margin and inferior horn of thyroid cartilage  
 External branch of superior laryngeal nerve (CN X)  
 Tenses vocal fold  
 Posterior cricoarytenoid  
 Posterior surface of laminae of cricoid cartilage  
 Muscular process of arytenoid cartilage  
 Recurrent laryngeal nerve (CN X)  
 Abducts vocal fold  
 Lateral cricoarytenoid  
 Arch of cricoid cartilage  
 Adducts vocal fold  
 Thyroarytenoid<sup>a</sup>  
 Posterior surface of thyroid cartilage  
 Relaxes vocal fold  
 Transverse and oblique arytenoids<sup>b</sup>  
 One arytenoid cartilage  
 Opposite arytenoid cartilage  
 Close inlet of larynx by approximating arytenoid cartilages  
 Vocalis<sup>c</sup>  
 Angle between laminae of thyroid cartilage  
 Vocal ligament, between origin and vocal process of arytenoid cartilage  
 Alters vocal fold during phonation  
<sup>a</sup>Superior fibers of the thyroarytenoid muscle pass into the aryepiglottic fold, and some of them reach the epiglottic cartilage. These fibers constitute the thyroepiglottic muscle, which widens the inlet of the larynx.  
<sup>b</sup>Some fibers of the oblique arytenoid muscle continue as the aryepiglottic muscle.  
<sup>c</sup>This slender muscular slip is derived from inferior deeper fibers of the thyroarytenoid muscle.

Muscle	Origin	Insertion	Innervation	Main Action(s)
--------	--------	-----------	-------------	----------------

Table 8.10 Muscles of Larynx
------------------------------









Authors: Agur, Anne M.R.; Dalley, Arthur F.

Title: *Grant's Atlas of Anatomy, 12th Edition*

Copyright ©2009 Lippincott Williams & Wilkins

> Table of Contents > Chapter 8 - Neck > 8.31 Laryngoscopic examination and MRI imaging of larynx

---

## 8.31 Laryngoscopic examination and MRI imaging of larynx

*Part of "Chapter 8 - Neck "*

### A. Laryngoscopic examination.

Laryngoscopy is the procedure used to examine the interior of the larynx. The larynx may be examined visually by indirect laryngoscopy using a laryngeal mirror or it may be viewed by direct laryngoscopy using a tubular and endoscopic instrument, a laryngoscope. The vestibular and vocal folds can be observed.

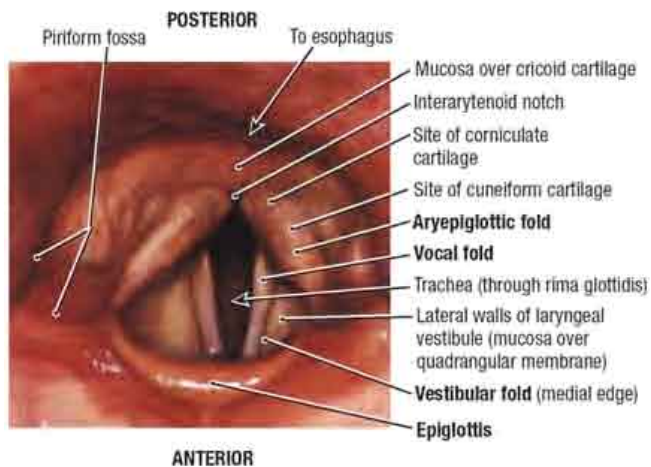
### B. Vocal folds and rima glottidis.

The inlet, or aditus, to the larynx is bounded anteriorly by the epiglottis; posteriorly by the arytenoid cartilages, the corniculate cartilages that cap them, and the interarytenoid fold that unites them; and on each side by the aryepiglottic fold, which contains the superior end of the cuneiform cartilage.

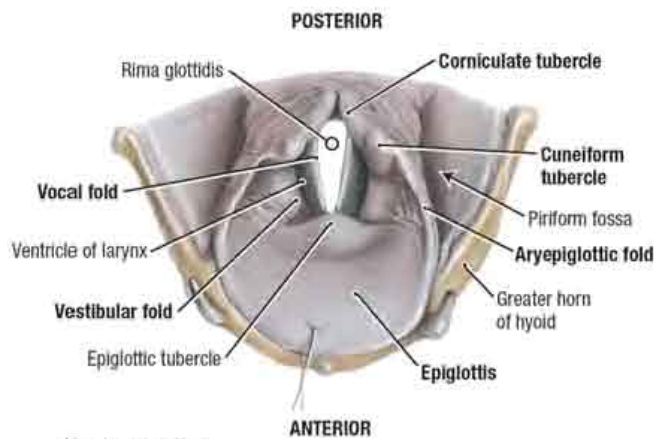
C. Coronal MRI. D. Coronal section. Numbers in parentheses on diagram refer to numbered structures on MRI.

A foreign object, such as a piece of steak, may accidentally aspirate through the laryngeal inlet into the vestibule of the larynx, where it becomes trapped superior to the vestibular folds. When a foreign object

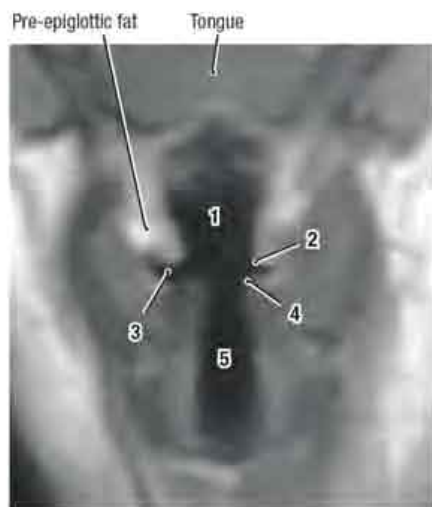
enters the vestibule, the laryngeal muscles go into spasm, tensing the vocal folds. The rima glottidis closes and no air enters the trachea. Asphyxiation occurs, and the person will die in approximately 5 minutes from lack of oxygen if the obstruction is not removed. Emergency therapy must be given to open the airway. The procedure used depends on the condition of the patient, the facilities available, and the experience of the person giving first aid. Because the lungs still contain air, sudden compression of the abdomen (Heimlich maneuver) causes the diaphragm to elevate and compress the lungs, expelling air from the trachea into the larynx. This maneuver may dislodge the food or other material from the larynx.



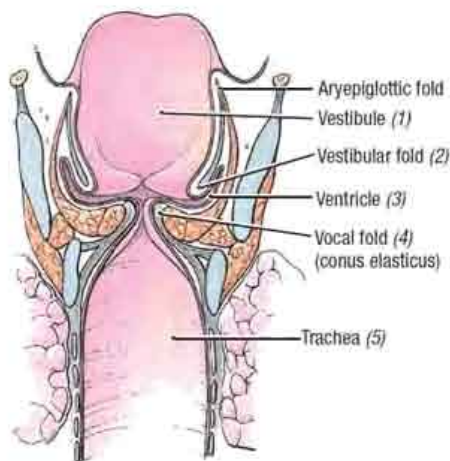
**A. Laryngoscopic Examination**



**B. Superior View**



**C. Coronal MRI**



**D. Posterior View**

**Authors:** Agur, Anne M.R.; Dalley, Arthur F.

**Title:** *Grant's Atlas of Anatomy, 12th Edition*

Copyright ©2009 Lippincott Williams & Wilkins

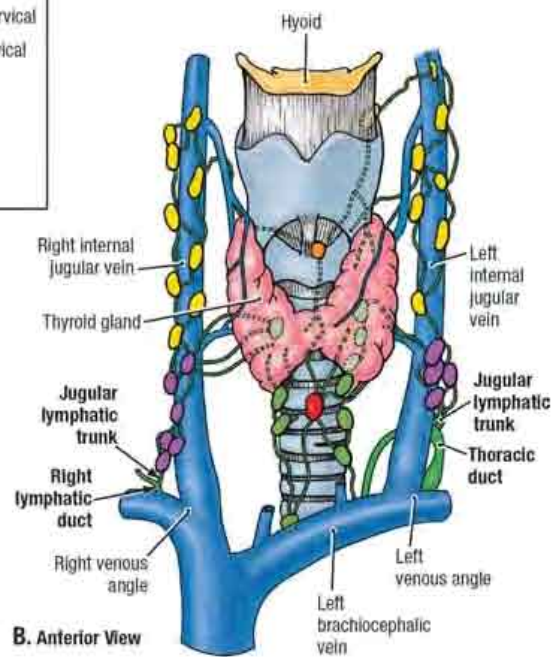
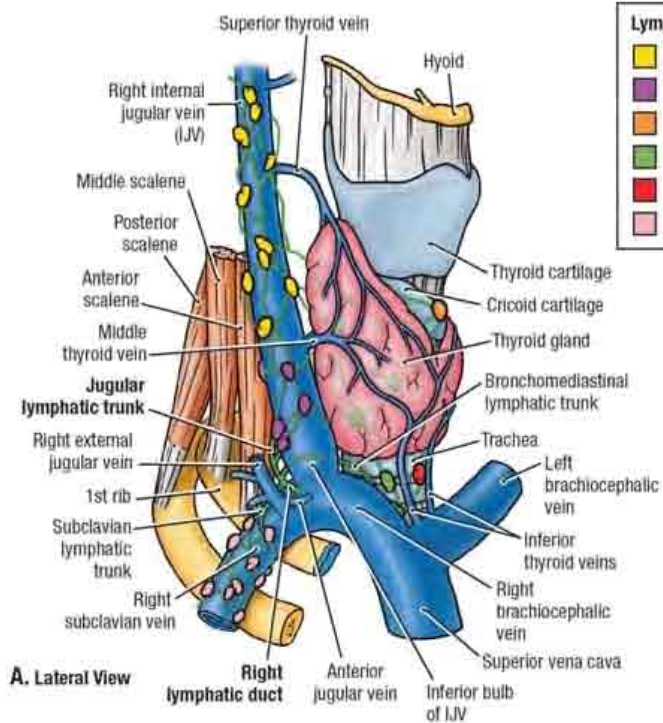
> Table of Contents > Chapter 8 - Neck > 8.32 Lymphatic drainage of thyroid gland, larynx, and trachea

---

## 8.32 Lymphatic drainage of thyroid gland, larynx, and trachea

*Part of* "Chapter 8 - Neck "

Radical neck dissections are performed when cancer invades the lymphatics. During the procedure, the deep cervical lymph nodes and the tissues around them are removed as completely as possible. Although major arteries, the brachial plexus, CN X, and the phrenic nerve are preserved, most cutaneous branches of the cervical plexus are removed. The aim of the dissection is to remove all tissue that contains lymph nodes in one piece.





Authors: Agur, Anne M.R.; Dalley, Arthur F.

Title: *Grant's Atlas of Anatomy, 12th Edition*

Copyright ©2009 Lippincott Williams & Wilkins

> Table of Contents > Chapter 8 - Neck > 8.33 Sympathetic trunk and sympathetic periarterial plexus

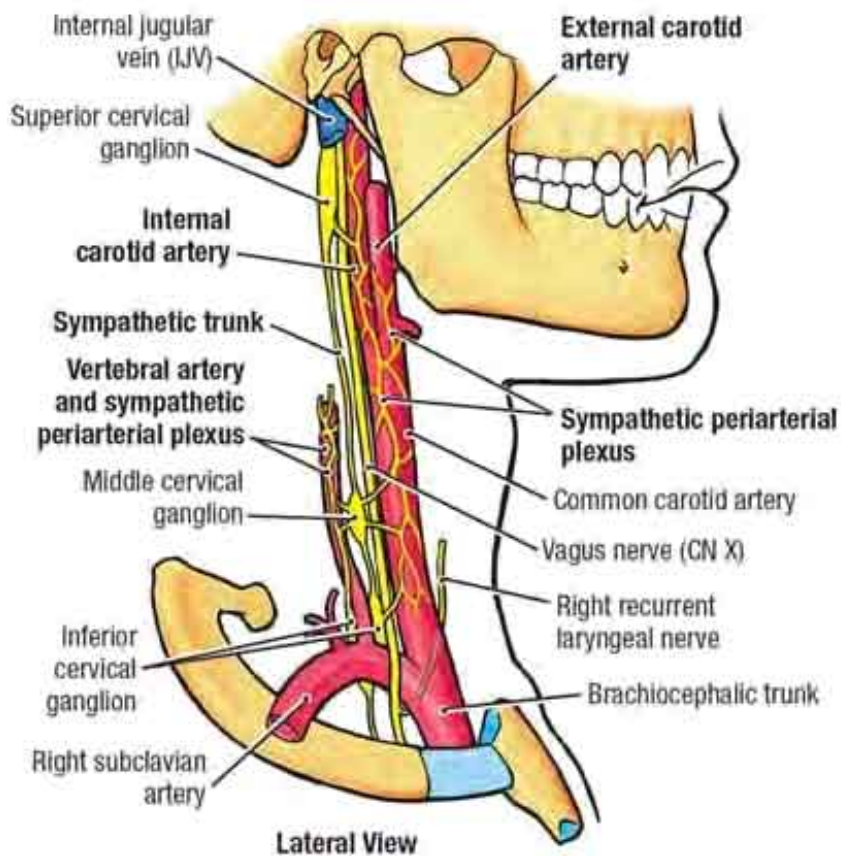
---

## 8.33 Sympathetic trunk and sympathetic periarterial plexus

*Part of* "Chapter 8 - Neck"

A lesion of a sympathetic trunk in the neck results in a sympathetic disturbance called Horner syndrome, which is characterized by

- Pupillary constriction resulting from paralysis of the dilator pupillae muscle
- Ptosis (drooping of the superior eyelid), resulting from paralysis of the smooth (tarsal) muscle intermingled with striated muscle of the levator palpebrae superioris
- Sinking in of the eyeball (enophthalmos), possibly caused by paralysis of smooth (orbitalis) muscle in the floor of the orbit
- Vasodilation and absence of sweating on the face and neck (anhydrosis), caused by a lack of sympathetic (vasoconstrictive) nerve supply to the blood vessels and sweat glands



Authors: Agur, Anne M.R.; Dalley, Arthur F.

Title: *Grant's Atlas of Anatomy, 12th Edition*

Copyright ©2009 Lippincott Williams & Wilkins

> Table of Contents > Chapter 8 - Neck > 8.34 Transverse MRIs of neck

---

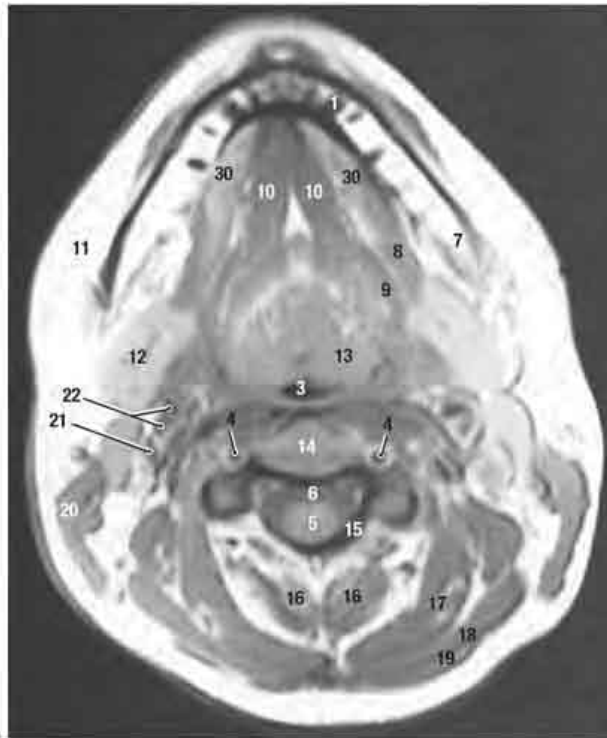
## 8.34 Transverse MRIs of neck

*Part of* "Chapter 8 - Neck "

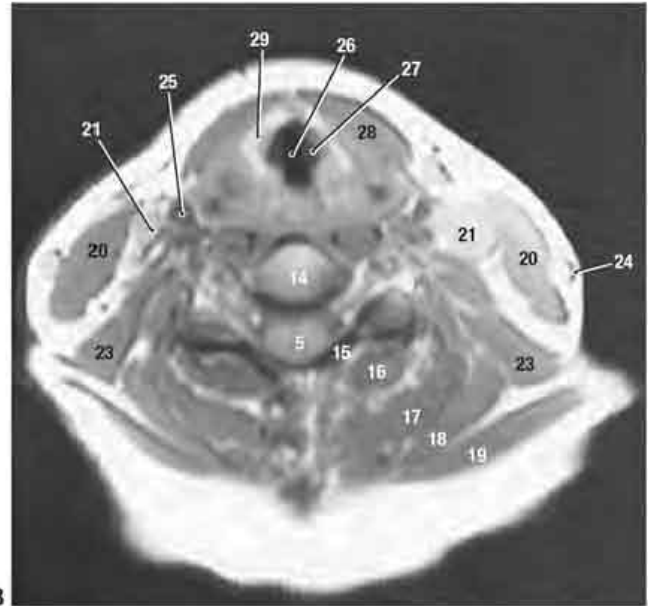
The orientation figure indicates the vertebral level of the MRI sections.

---

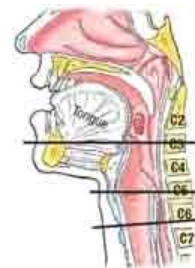
P.807



A

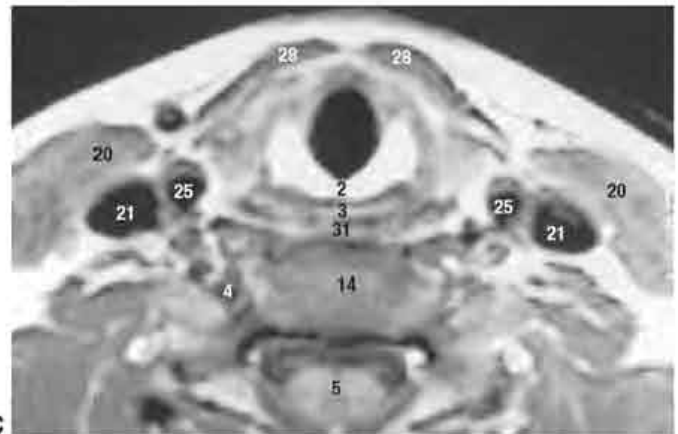


B



Inferior Views

- |   |   |
|---|---|
| 1 Tooth                                     | 16 Semispinalis cervicis                |
| 2 Cricoid cartilage                         | 17 Semispinalis capitis                 |
| 3 Pharynx                                   | 18 Splenius capitis                     |
| 4 Vertebral artery                          | 19 Trapezius                            |
| 5 Spinal cord                               | 20 Sternocleidomastoid                  |
| 6 Cerebrospinal fluid in subarachnoid space | 21 Internal jugular vein                |
| 7 Body of mandible                          | 22 Bifurcation of common carotid artery |
| 8 Mylohyoid                                 | 23 Levator scapulae                     |
| 9 Hyoglossus                                | 24 External jugular vein                |
| 10 Genioglossus                             | 25 Common carotid artery                |
| 11 Buccal fat pad                           | 26 Rima glottidis                       |
| 12 Submandibular gland                      | 27 Vocal fold                           |
| 13 Intrinsic muscles of tongue              | 28 Strap muscles                        |
| 14 Vertebral body                           | 29 Thyroid cartilage                    |
| 15 Lamina of vertebra                       | 30 Sublingual gland                     |
|   | 31 Inferior pharyngeal constrictor      |



C

Authors: Agur, Anne M.R.; Dalley, Arthur F.

Title: *Grant's Atlas of Anatomy, 12th Edition*

Copyright ©2009 Lippincott Williams & Wilkins

> Table of Contents > Chapter 8 - Neck > 8.35 Transverse anatomical sections of neck

---

## 8.35 Transverse anatomical sections of neck

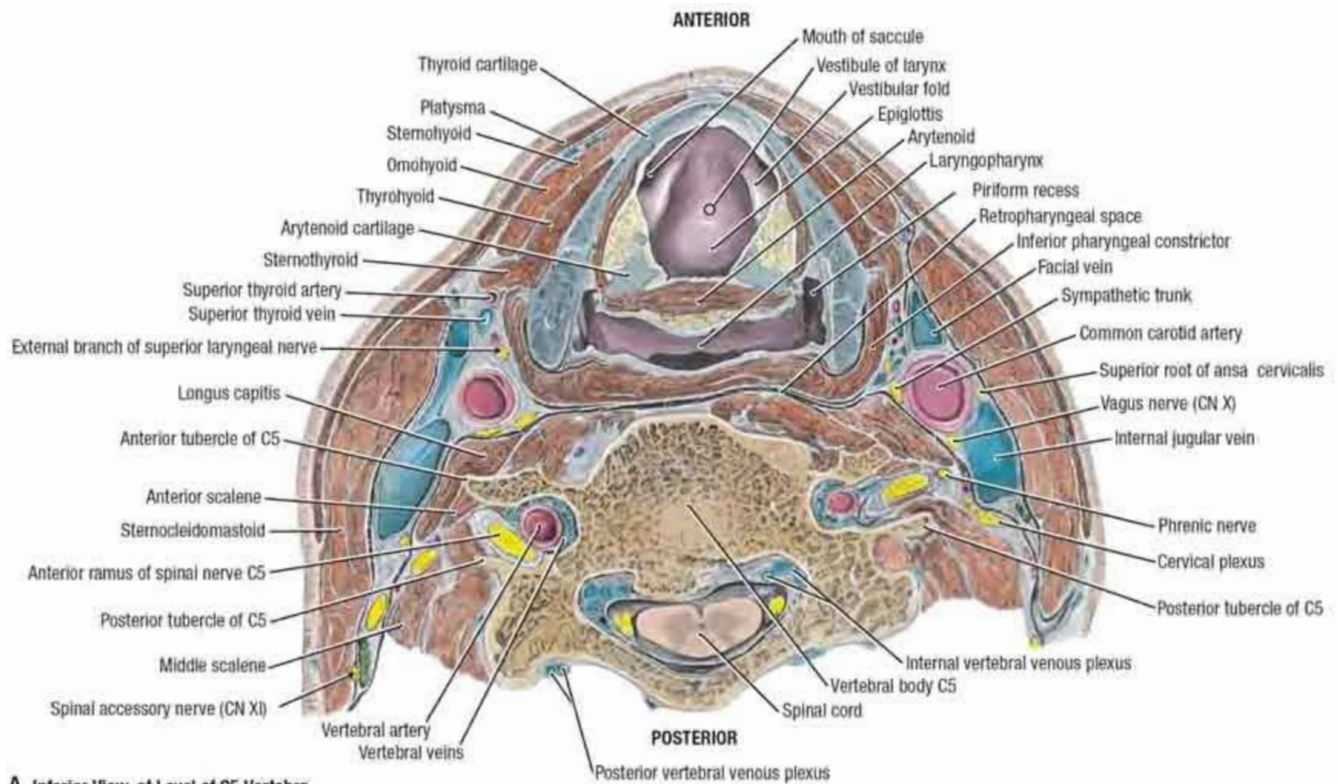
*Part of* "Chapter 8 - Neck "

Level of C7 Vertebra

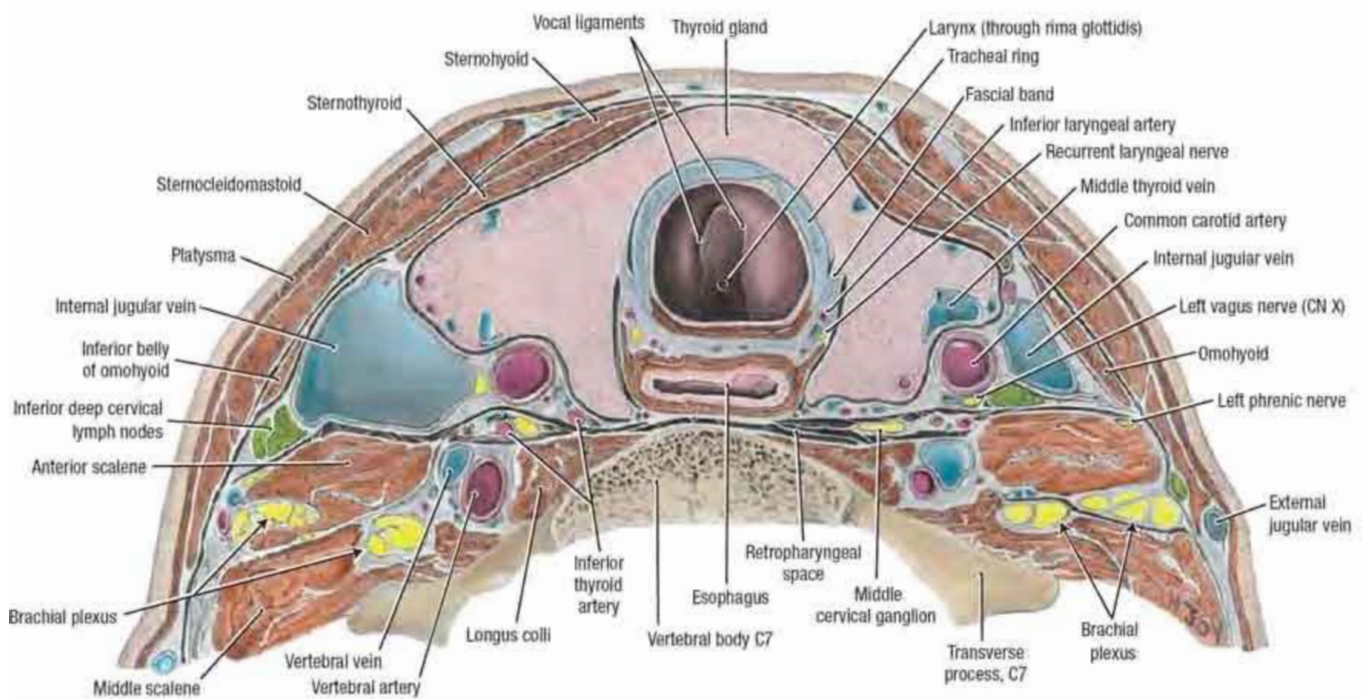
---

P.808





**A. Inferior View, at Level of C5 Vertebra**



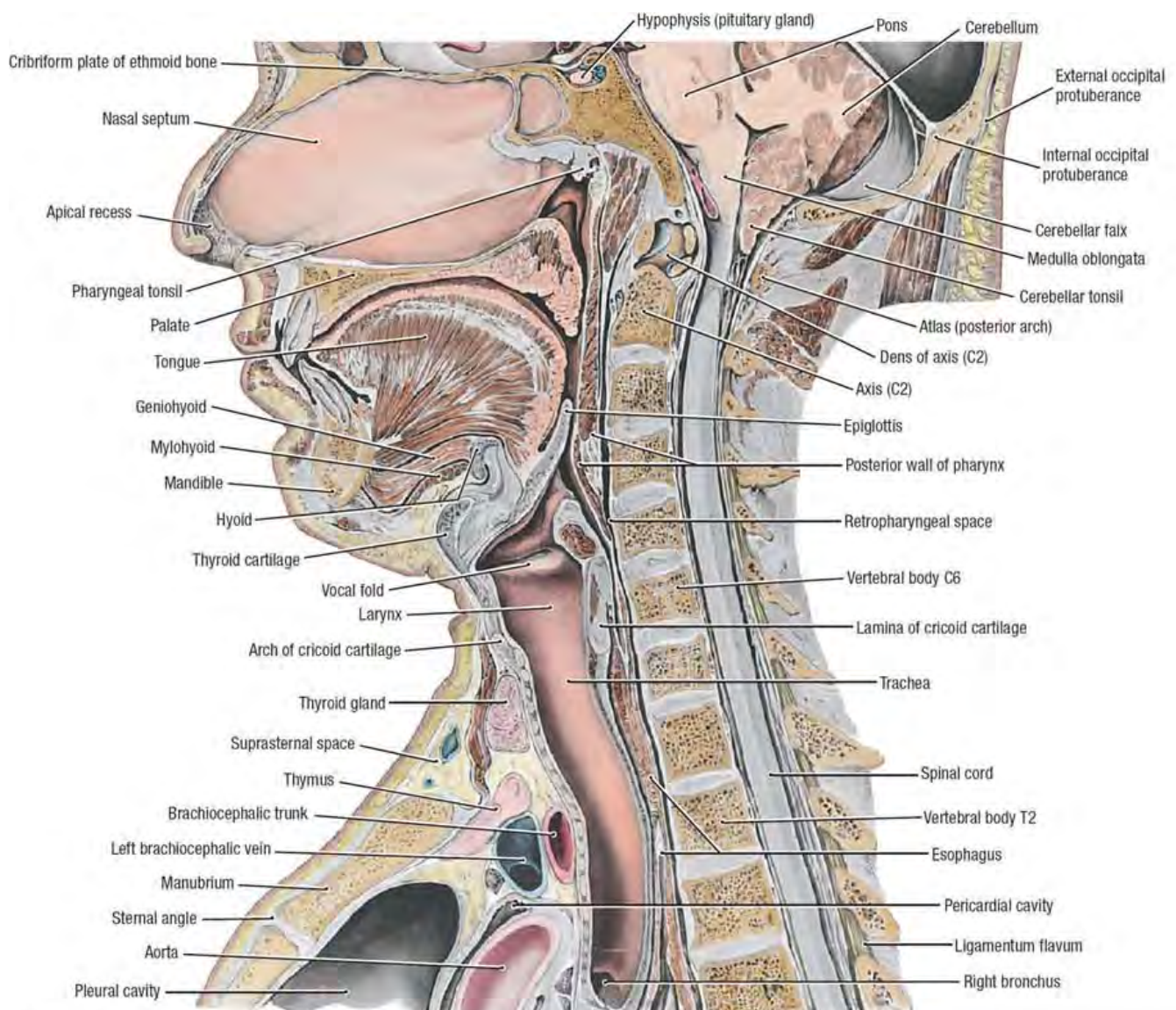
**B. Inferior View, at Level of C7 Vertebra**

Authors: Agur, Anne M.R.; Dalley, Arthur F.  
Title: *Grant's Atlas of Anatomy, 12th Edition*  
Copyright ©2009 Lippincott Williams & Wilkins

> Table of Contents > Chapter 8 - Neck > 8.36 Median section and MRI scan of head and neck

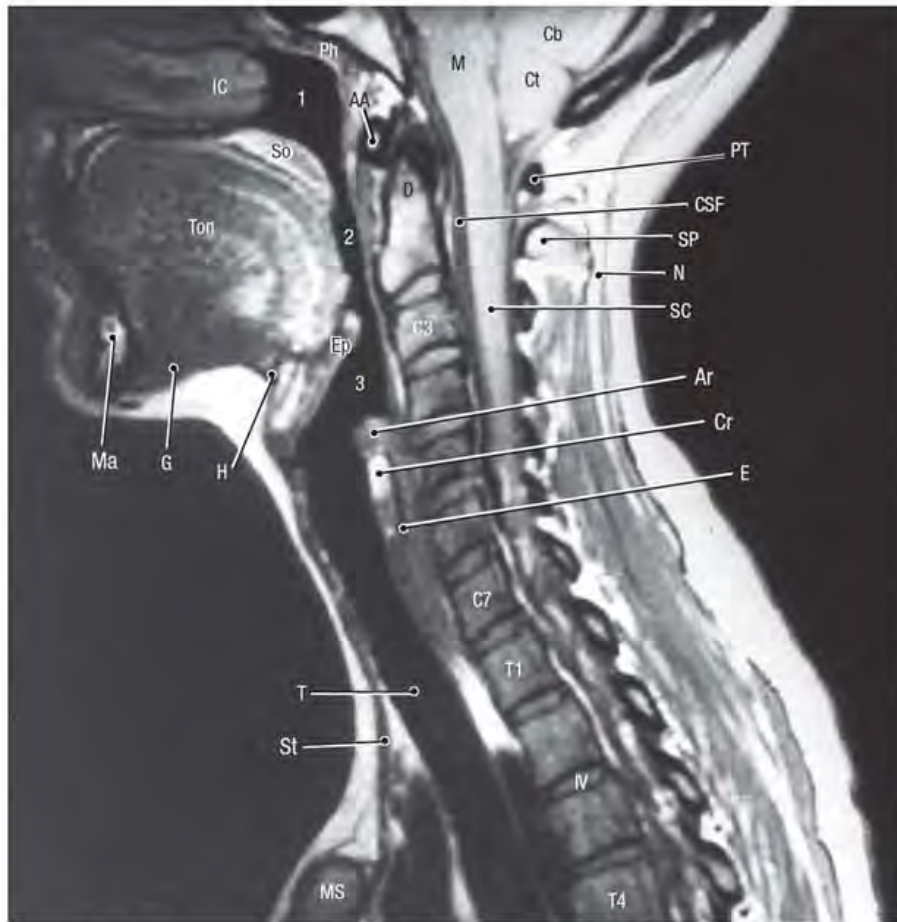
## 8.36 Median section and MRI scan of head and neck

Part of "Chapter 8 - Neck "





# A. Median Section

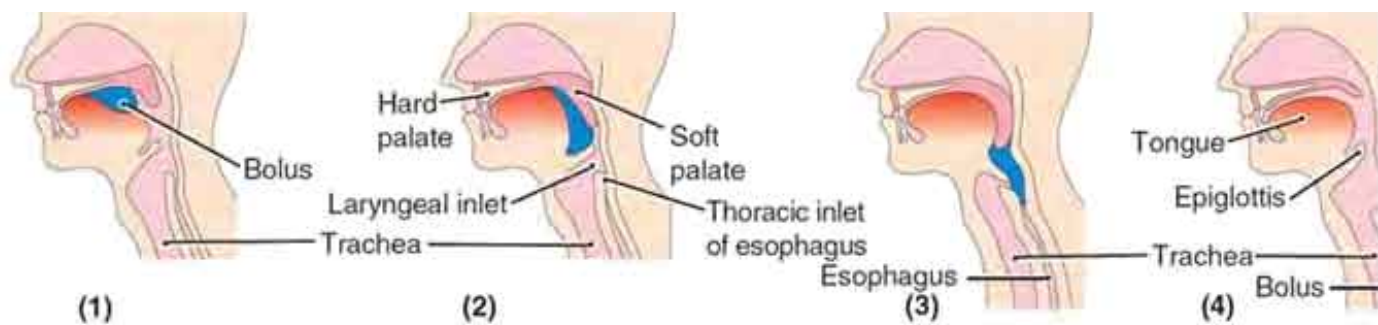


B. Median MRI Scan

1	Nasopharynx
2	Oropharynx
3	Laryngopharynx
AA	Anterior arch of C1
Ar	Arytenoid cartilage
C3-T4	Vertebral bodies
Cb	Cerebellum
Cr	Cricoid cartilage
CSF	Cerebrospinal fluid in subarachnoid space
Ct	Tonsil of cerebellum
D	Dens
E	Esophagus
Ep	Epiglottis
G	Genioglossus
H	Hyoid
IC	Inferior concha
IV	Intervertebral disc
M	Medulla oblongata
Ma	Mandible
MS	Manubrium of sternum
N	Nuchal ligament
Ph	Pharyngeal tonsil (adenoid)
PT	Posterior tubercle of C1
SC	Spinal cord
So	Soft palate
SP	Spinous process
St	Strap muscles
T	Trachea
Ton	Tongue

## A. Median anatomical section.

Swallowing. (1) The bolus of food is squeezed to the back of the mouth by pushing the tongue against the palate. (2) The nasopharynx is sealed off, and the larynx is elevated, enlarging the pharynx to receive food. (3) The pharyngeal sphincters contract sequentially, squeezing food into the esophagus. The epiglottis deflects the bolus from but does not close the inlet to the larynx and trachea. (4) The bolus of food moves down the esophagus by peristaltic contractions.



Authors: Agur, Anne M.R.; Dalley, Arthur F.

Title: *Grant's Atlas of Anatomy, 12th Edition*

Copyright ©2009 Lippincott Williams & Wilkins

> Table of Contents > Chapter 8 - Neck > 8.37 Doppler US color flow study of carotid artery

---

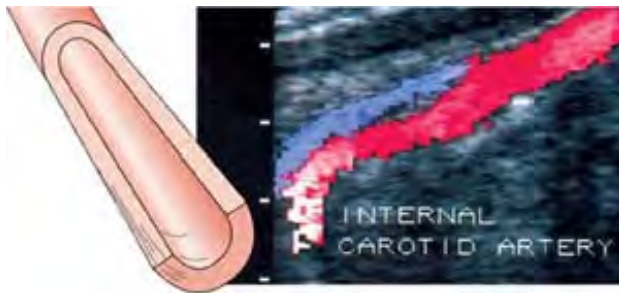
## 8.37 Doppler US color flow study of carotid artery

*Part of* "Chapter 8 - Neck"

---

P.809

Ultrasonography is a useful diagnostic imaging technique for studying soft tissues of the neck. Ultrasound provides images of many abnormal conditions noninvasively, at relatively low cost, and with minimal discomfort. Ultrasound is useful for distinguishing solid from cystic masses, for example, which may be difficult to determine during physical examination. Vascular imaging of arteries and veins of the neck is possible using intravascular ultrasonography. The images are produced by placing the transducer over the blood vessel. Doppler ultrasound techniques help evaluate blood flow through a vessel (e.g., for detecting stenosis [narrowing] of a carotid artery).





Authors: Agur, Anne M.R.; Dalley, Arthur F.

Title: *Grant's Atlas of Anatomy, 12th Edition*

Copyright ©2009 Lippincott Williams & Wilkins

> Table of Contents > Chapter 9 - Cranial Nerves > Chapter 9 - Cranial Nerves

---

## Chapter 9

# Cranial Nerves

- 9.1 Cranial nerves in relation to the base of the brain
- 9.2 Cranial nerves in relation to the internal aspect of the cranial base
- 9.3 Cranial nerve nuclei
- 9.4 Visual pathway
- 9.5 Overview of muscles and nerves of orbit
- 9.6 Transverse MRIs through head, showing cranial nerves
- 9.7 Coronal MRIs through head, showing cranial nerves

Authors: Agur, Anne M.R.; Dalley, Arthur F.

Title: *Grant's Atlas of Anatomy, 12th Edition*

Copyright ©2009 Lippincott Williams & Wilkins

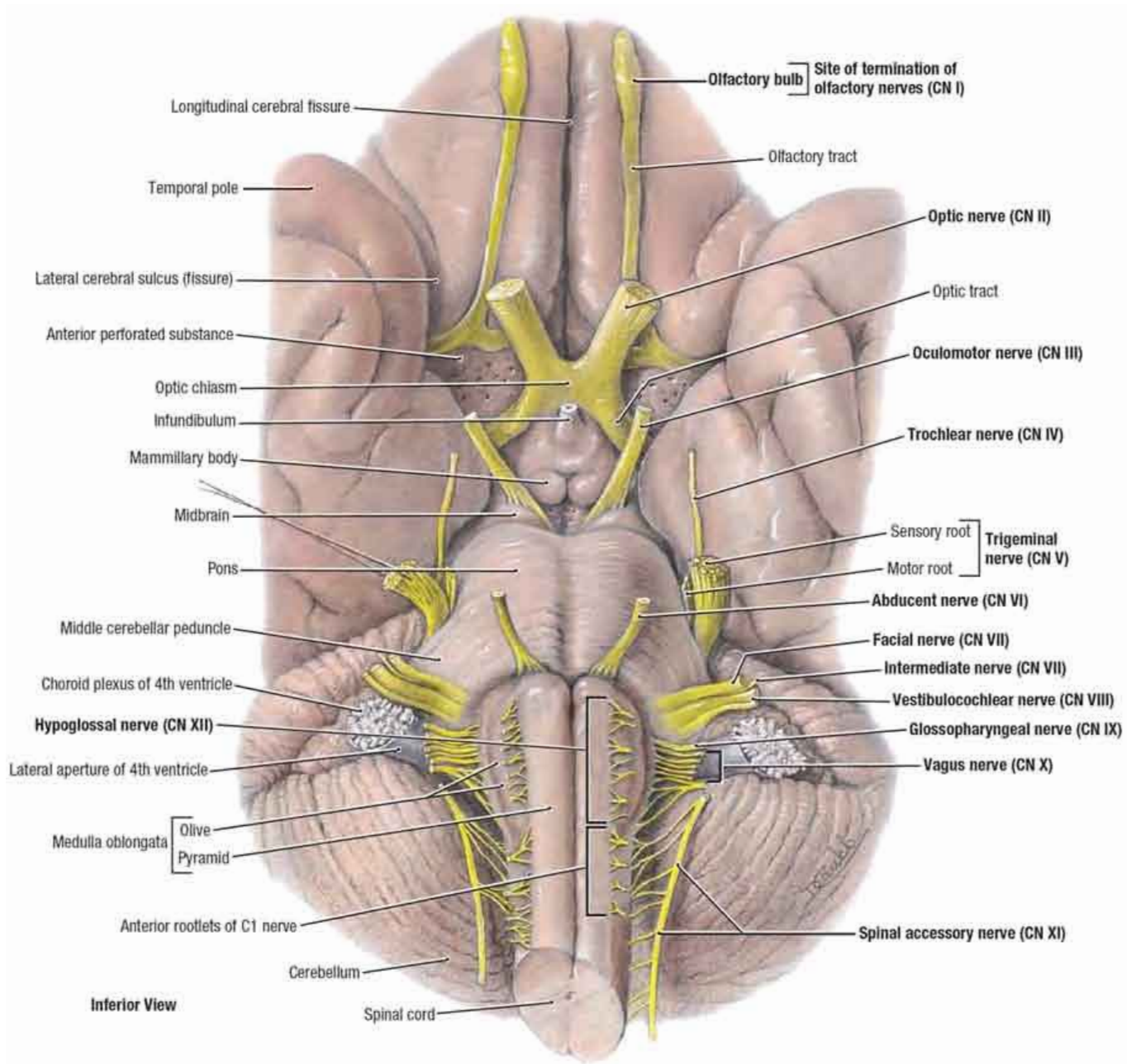
> Table of Contents > Chapter 9 - Cranial Nerves > 9.1 Cranial nerves in relation to the base of the brain

---

## 9.1 Cranial nerves in relation to the base of the brain

*Part of* "Chapter 9 - Cranial Nerves "

Cranial nerves are nerves that exit from the cranial cavity through openings in the cranium. There are 12 pairs of cranial nerves that are named and numbered in rostrocaudal sequence of their superficial origins from the brain, brainstem, and superior spinal cord. The olfactory nerves (CN I, not shown) end in the olfactory bulb. The entire origin of the spinal accessory nerve (CN XI) from the spinal cord is not included here; it extends inferiorly as far as the C6 spinal cord segment.



Authors: Agur, Anne M.R.; Dalley, Arthur F.

Title: *Grant's Atlas of Anatomy, 12th Edition*

Copyright ©2009 Lippincott Williams & Wilkins

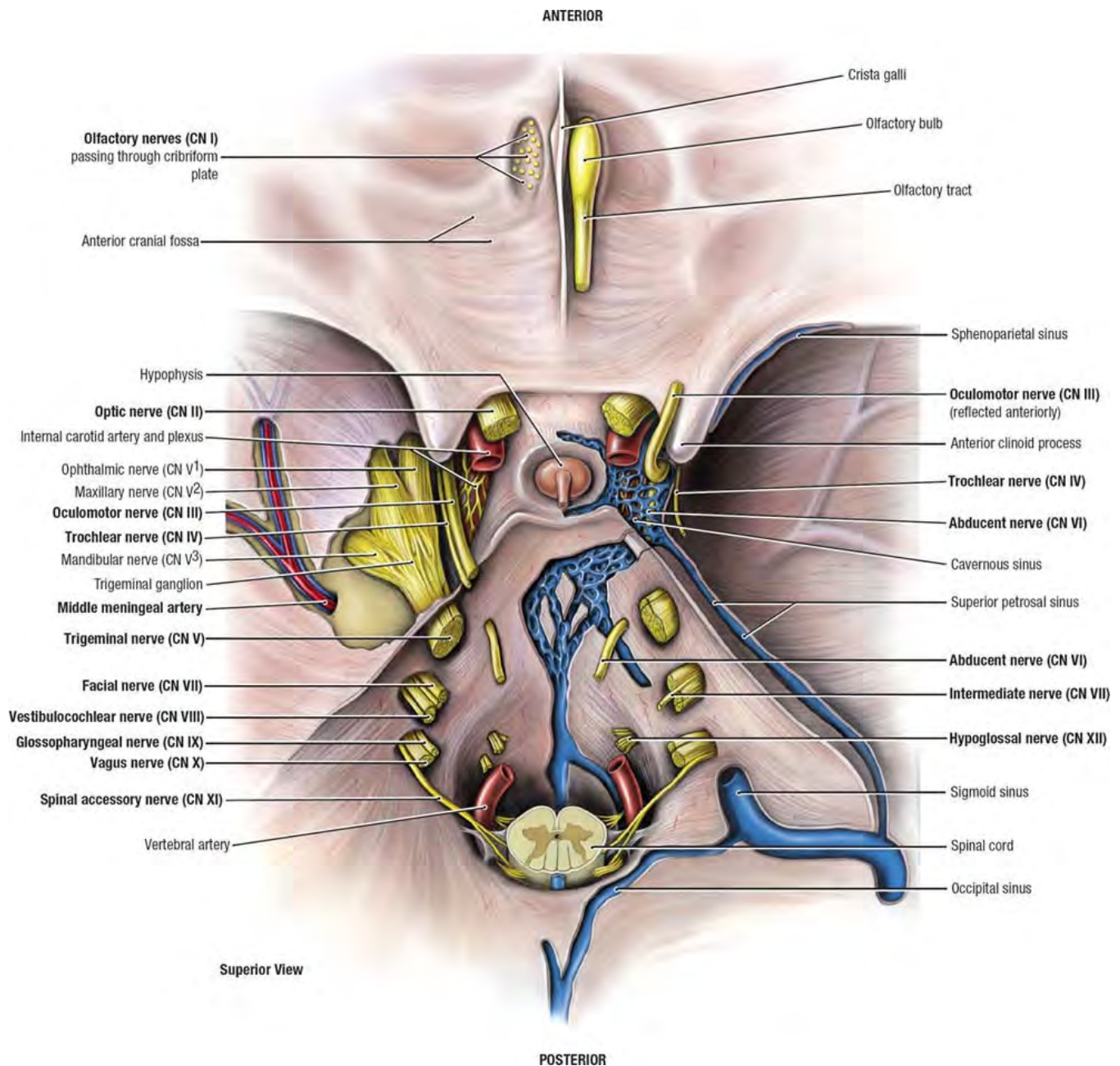
> Table of Contents > Chapter 9 - Cranial Nerves > 9.2 Cranial nerves in relation to the internal aspect of the cranial base

---

## 9.2 Cranial nerves in relation to the internal aspect of the cranial base

*Part of* "Chapter 9 - Cranial Nerves "

The venous sinuses have been opened on the right side. The ophthalmic division of the trigeminal nerve (CN V<sup>1</sup> ), and the trochlear (CN IV) and oculomotor (CN III) nerves have been dissected from the lateral wall of the cavernous sinus.



P.815

Olfactory (CN I)

Special sensory

Olfactory epithelium (olfactory cells)

Foramina in cribriform plate of ethmoid bone

Smell from nasal mucosa of roof of each nasal cavity, superior sides of nasal septum and superior concha



Optic (CN II)

Special sensory

Retina (ganglion cells)

Optic canal

Vision from retina

Oculomotor (CN III)

Somatic motor

Midbrain

Superior orbital fissure

Motor to superior, inferior, and medial rectus, inferior oblique, and levator palpebrae superioris muscle that raise upper eyelid and rotates eyeball superiorly, inferiorly, and medially

Visceral motor (parasympathetic)

Presynaptic: midbrain; Postsynaptic: ciliary ganglion

Secretomotor to sphincter pupillae and ciliary muscles that constrict pupil and accommodate lens of eye

Trochlear (CN IV)

Somatic motor

Midbrain

Motor to superior oblique that assists in rotating eye inferolaterally

Trigeminal (CN V)

Ophthalmic division (CN V<sup>1</sup> )

Maxillary division (CN V<sup>2</sup> )

Mandibular division (CN V<sup>3</sup> )

General sensory

Trigeminal ganglion

Sensation from cornea, skin of forehead, scalp, eyelids, nose, and mucosa of nasal cavity and paranasal sinuses

General sensory

Trigeminal ganglion

Foramen rotundum

Sensation from skin of face over maxilla including upper lip, maxillary teeth, mucosa of

nose, maxillary sinuses, and palate

Branchial motor

Pons

Foramen ovale

Motor to muscles of mastication, mylohyoid, anterior belly of digastric, tensor veli palatini, and tensor tympani

General sensory

Trigeminal ganglion

Sensation from the skin over mandible, including lower lip and side of head, mandibular teeth, temporo-mandibular joint, and mucosa of mouth and anterior two thirds of the tongue

Abducent (CN VI)

Somatic motor

Pons

Superior orbital fissure

Motor to lateral rectus that rotates eye laterally

Facial (CN VII)

Branchial motor

Pons

Internal acoustic meatus, facial canal, and stylo-mastoid foramen

Motor to muscles of facial expression and scalp; also supplies stapedius of middle ear, stylohyoid, and posterior belly of digastric

Special sensory

Geniculate ganglion

Taste from anterior two thirds of tongue, floor of mouth, and palate

General sensory

Sensation from skin of external acoustic meatus

Visceral motor (parasympathetic)

Presynaptic: pons; Postsynaptic: pterygo-palatine ganglion and submandibular ganglion

Secretomotor to submandibular and sublingual salivary glands, lacrimal gland, and glands of nose and palate

Vestibulocochlear (CN VIII)

Vestibular

Cochlear

Special sensory

Vestibular ganglion

Internal acoustic meatus

Vestibular sensation from semicircular ducts, utricle, and saccule related to position and movement of head

Special sensory

Spiral ganglion

Hearing from spiral organ

Glossopharyngeal (CN IX)

Branchial motor

Medulla

Jugular foramen

Motor to stylopharyngeus that assists with swallowing

Visceral motor (parasympathetic)

Presynaptic: medulla; Postsynaptic: otic ganglion

Secretomotor to parotid gland

Visceral sensory

Inferior ganglion

Visceral sensation from parotid gland, carotid body and sinus, pharynx, and middle ear

Special sensory

Superior ganglion

Taste from posterior third of tongue

General sensory

Inferior ganglion

Cutaneous sensation from external ear

Vagus (CN X)

Branchial motor

Medulla

Motor to constrictor muscles of pharynx, intrinsic muscles of larynx, muscles of palate (except tensor veli palatine), and striated muscle in superior two thirds of esophagus

Visceral motor (parasympathetic)

Presynaptic: medulla; Postsynaptic: neurons in, on, or near viscera

Motor to smooth muscle of trachea, bronchi, and digestive tract, moderates cardiac pacemaker and vasoconstrictor of coronary arteries

Special sensory

Inferior ganglion

Visceral sensation from base of tongue, pharynx, larynx, trachea, bronchi, heart, esophagus, stomach, and intestine

General sensory

Superior ganglion

Sensation from auricle, external acoustic meatus, and dura mater of posterior cranial fossa

Somatic motor

Medulla

Motor to striated muscles of soft palate, pharynx, and larynx

Spinal accessory nerve (CN XI)

Somatic motor

Cervical spinal cord

Motor to sternocleidomastoid and trapezius

Hypoglossal (CN XII)

Somatic motor

Medulla

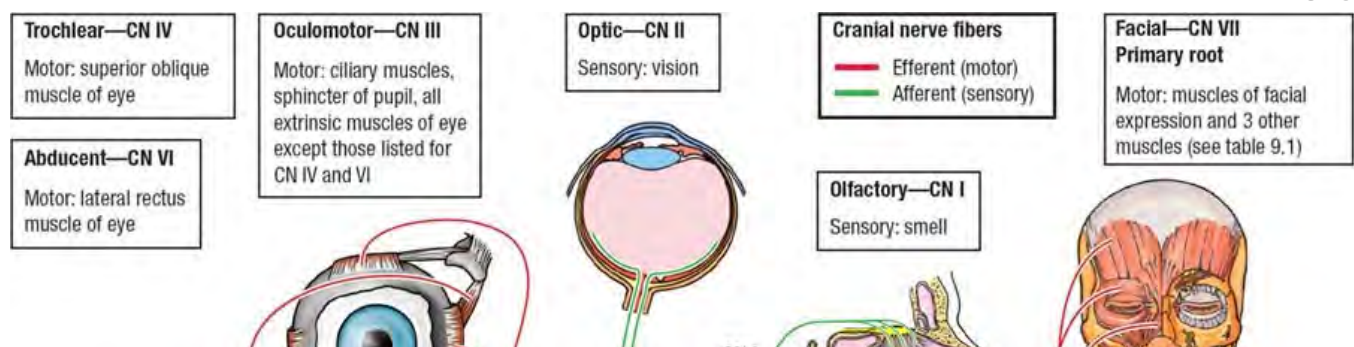
Hypoglossal canal

Motor to muscles of tongue (except palatoglossus)

Nerve	Components	Location of Nerve Cell Bodies	Cranial Exit	Main Action
-------	------------	-------------------------------	--------------	-------------

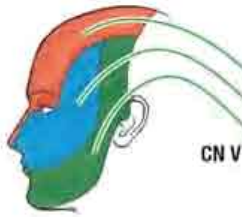
Table 9.1 Summary of Cranial Nerves

P.816



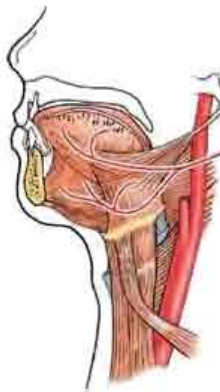
**Trigeminal—CN V  
Sensory root**

Sensory: skin of face;  
oral, nasal and sinus  
mucosa; and teeth



**Trigeminal—CN V  
Motor root**

Motor: muscles of  
mastication and 4 other  
muscles (see table 9.1)

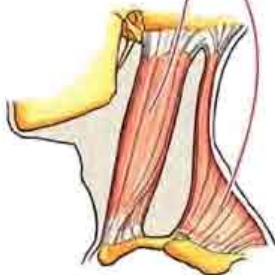


**Hypoglossal—CN XII**

Motor: all intrinsic and  
extrinsic muscles of tongue  
(excluding palatoglossus—  
a palatine muscle)

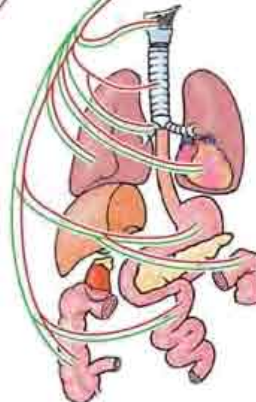
**Spinal accessory—CN XI**

Motor: sternocleidomastoid  
and trapezius



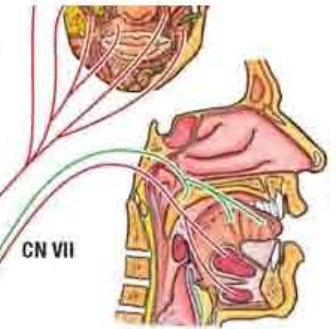
**Vagus—CN X**

Motor: palate, pharynx,  
larynx, trachea, bronchial  
tree, heart, GI tract to left  
colic flexure  
Sensory: pharynx, larynx;  
reflex sensory from tracheo-  
bronchial tree, lungs, heart,  
GI tract to left colic flexure



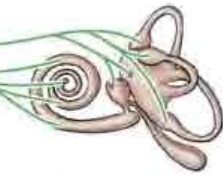
**Facial—CN VII  
Intermediate nerve**

Motor: lacrimal, nasal, palatine,  
submandibular, and sublingual  
glands  
Sensory: taste to anterior two  
thirds of tongue, soft palate



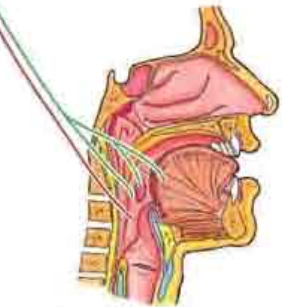
**Vestibulocochlear—CN VIII**

Vestibular nerve, sensory:  
orientation, motion  
Cochlear nerve, sensory:  
hearing



**Glossopharyngeal—CN IX**

Motor: stylopharyngeus,  
parotid gland  
Sensory (taste): posterior  
third of tongue; general  
sensation: pharynx, tonsillar  
sinus, pharyngotympanic  
tube, middle ear cavity





## 9.3 Cranial nerve nuclei

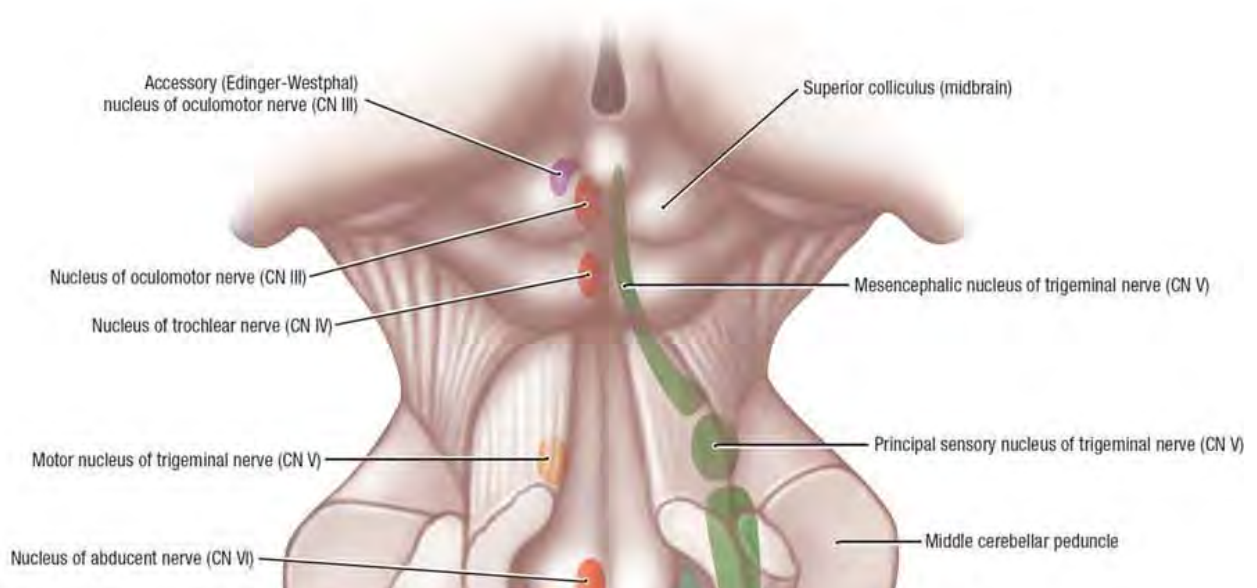
*Part of* "Chapter 9 - Cranial Nerves "

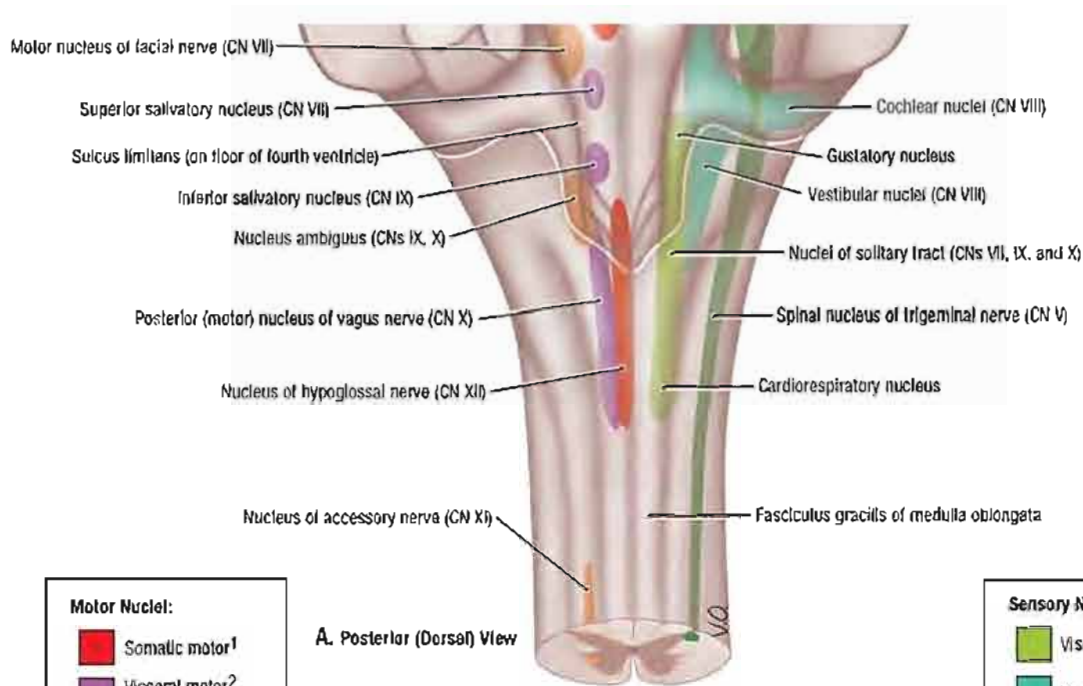
The fibers of the cranial nerves are connected to nuclei (groups of nerve cell bodies in the central nervous system), in which afferent (sensory) fibers terminate and from which efferent (motor) fibers originate. Nuclei of common functional types (motor, sensory, parasympathetic, and special sensory nuclei) have a generally columnar placement within the brainstem, with the sulcus limitans demarcating motor and sensory columns.

P.817

<sup>1</sup> General somatic efferent (GSE); <sup>2</sup> general visceral efferent (GVE); <sup>3</sup> special visceral efferent (SVE); <sup>4</sup> special/general visceral afferent (SVA/GVA); <sup>5</sup> special somatic afferent; <sup>6</sup> general somatic afferent (GSA).

P.818



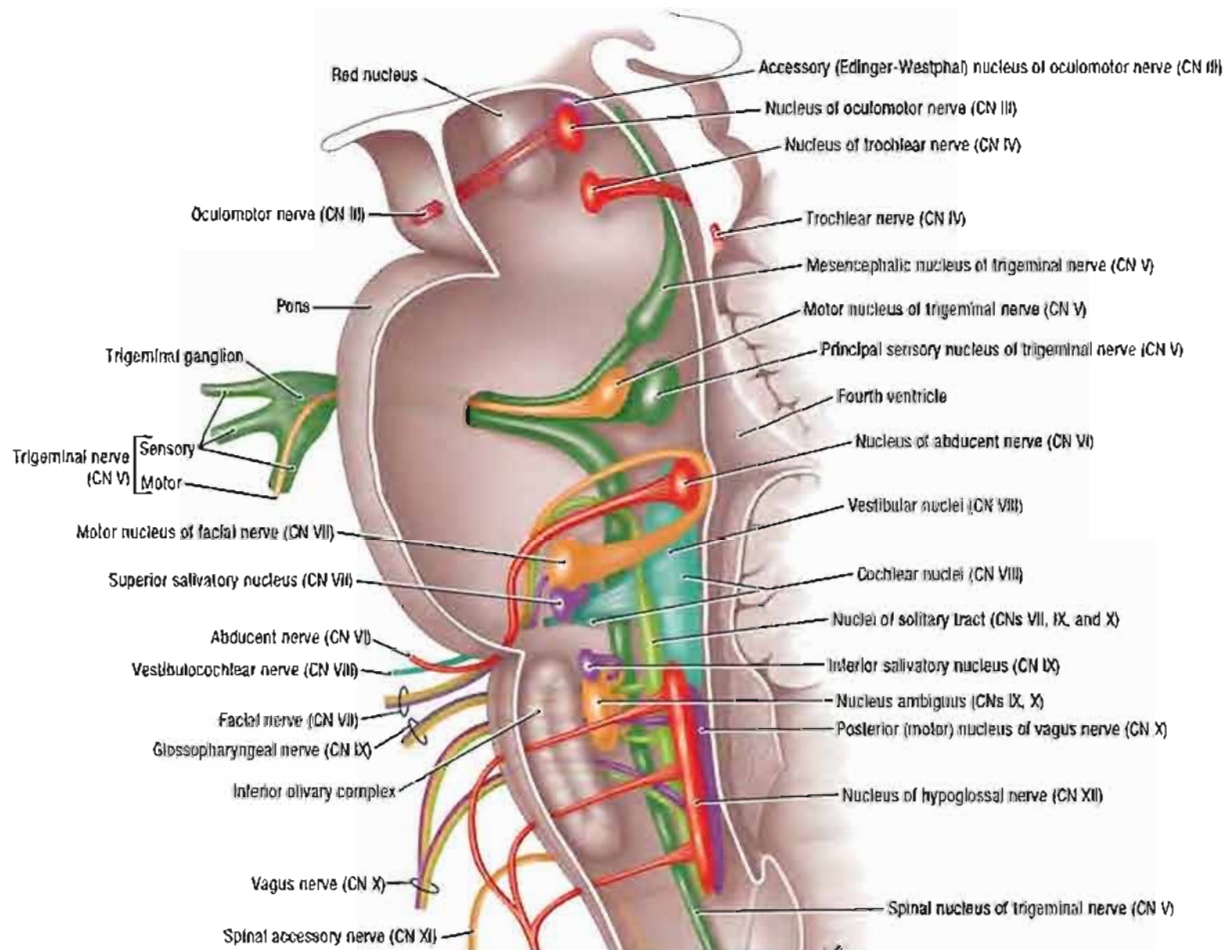


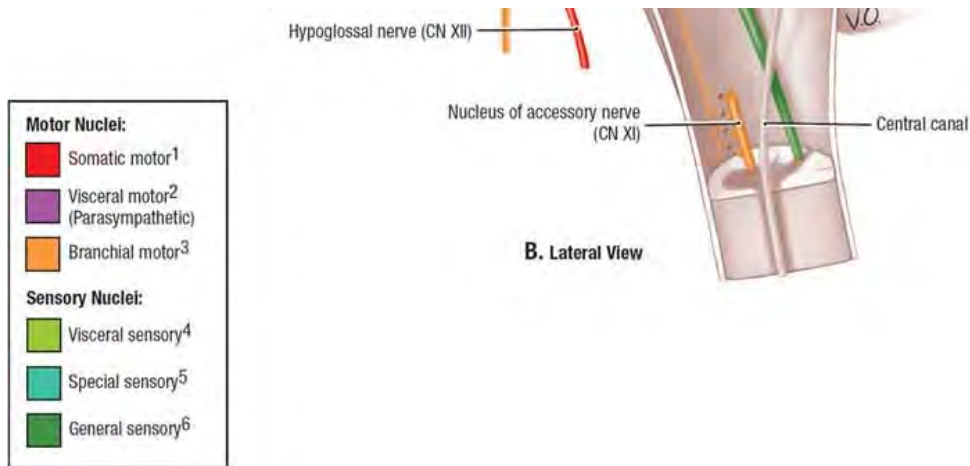
**Motor Nuclei:**

- Somatic motor<sup>1</sup>
- Visceral motor<sup>2</sup> (Parasympathetic)
- Branchial motor<sup>3</sup>

**Sensory Nuclei:**

- Visceral sensory<sup>4</sup>
- Special sensory<sup>5</sup>
- General sensory<sup>6</sup>





Olfactory

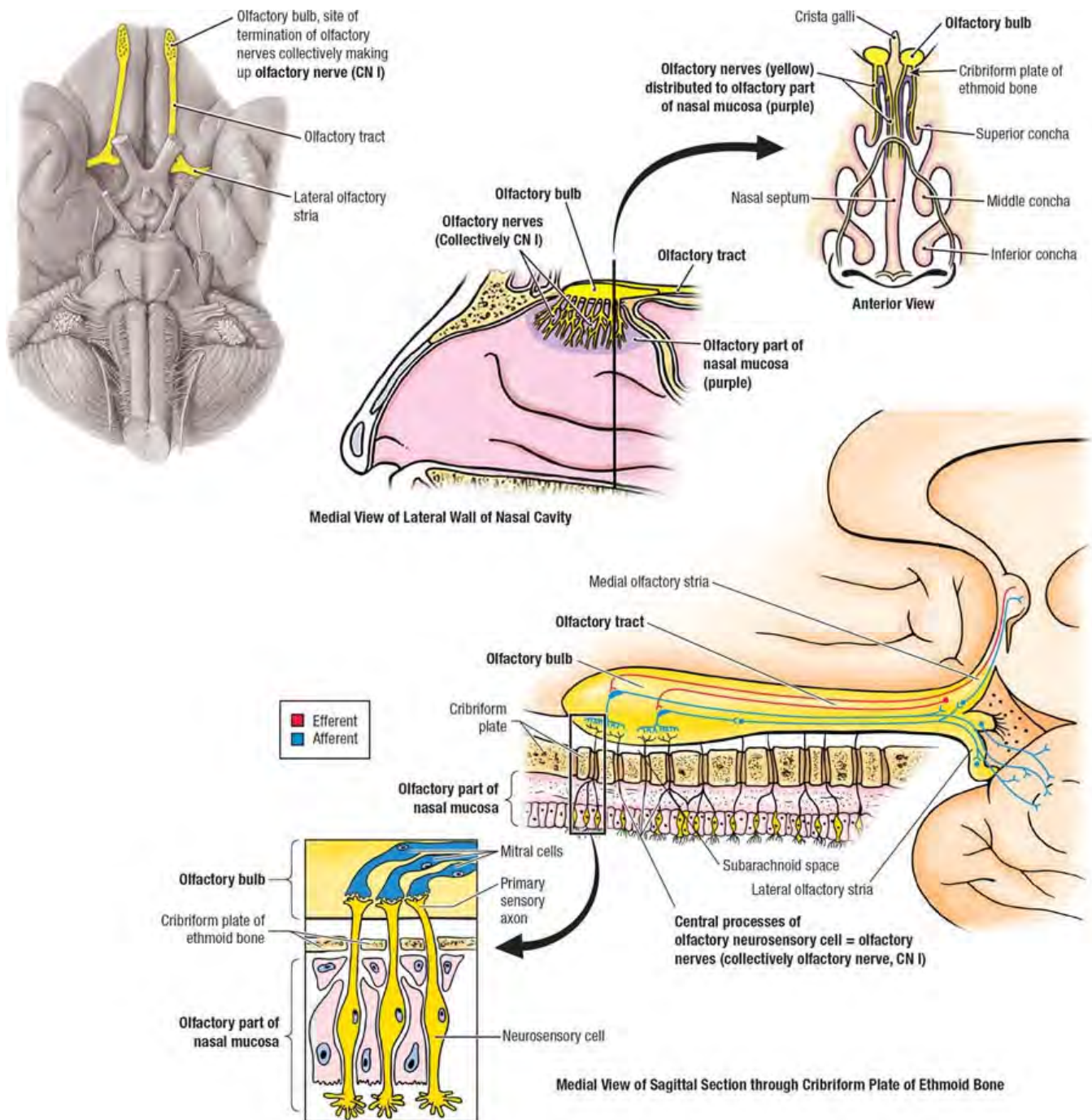
Special sensory

Olfactory epithelium (olfactory cells/olfactory bulb)

Foramina in cribriform plate of ethmoid bone

Smell from nasal mucosa of roof and superior sides of nasal septum and superior concha of each nasal cavity

Nerve	Functional Components	Cells of Origin/Termination	Cranial Exit	Distribution and Functions
Table 9.2 Olfactory Nerve (CN I)				



Optic

Special sensory

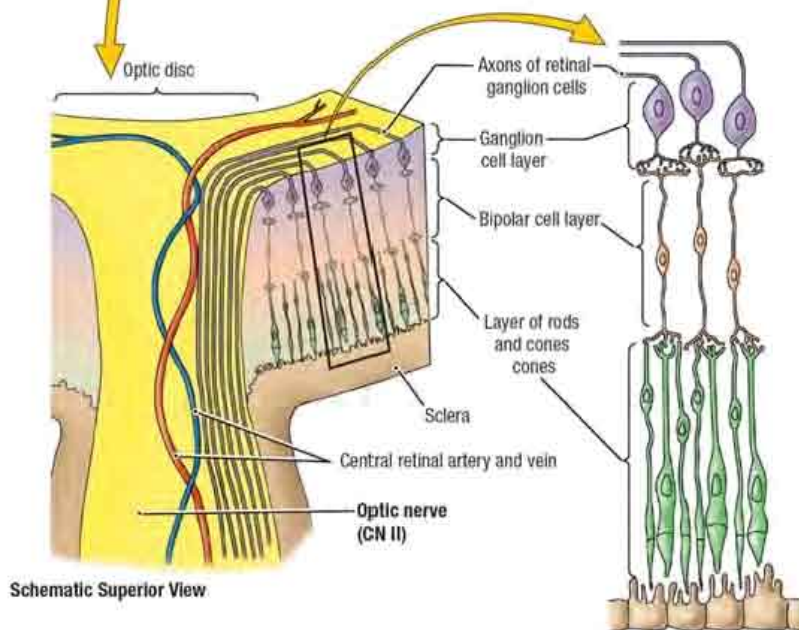
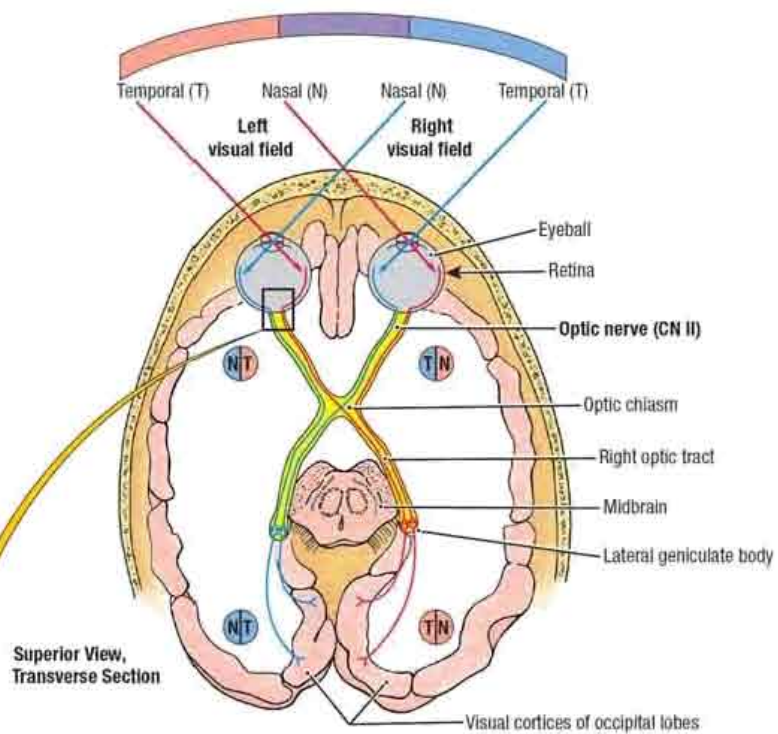
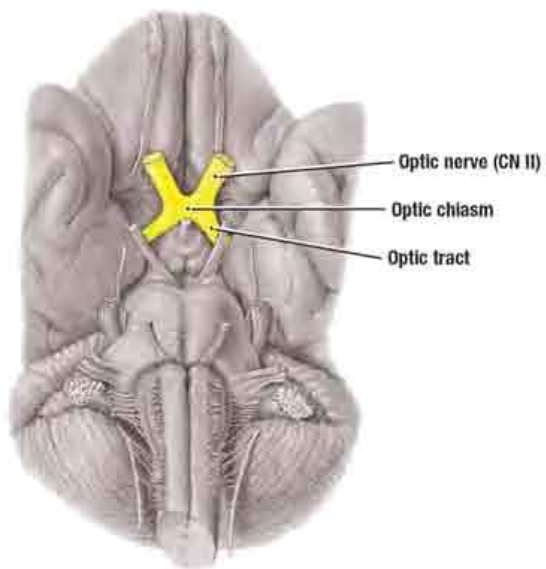
Retina (ganglion cells)/lateral geniculate body nucleus)

Optic canal

Vision from retina

Nerve	Functional Components	Cells of Origin/Termination	Cranial Exit	Distribution and Functions
Table 9.3 Optic Nerve (CN II)				





Authors: Agur, Anne M.R.; Dalley, Arthur F.

Title: *Grant's Atlas of Anatomy, 12th Edition*

Copyright ©2009 Lippincott Williams & Wilkins

> Table of Contents > Chapter 9 - Cranial Nerves > 9.4 Visual pathway

---

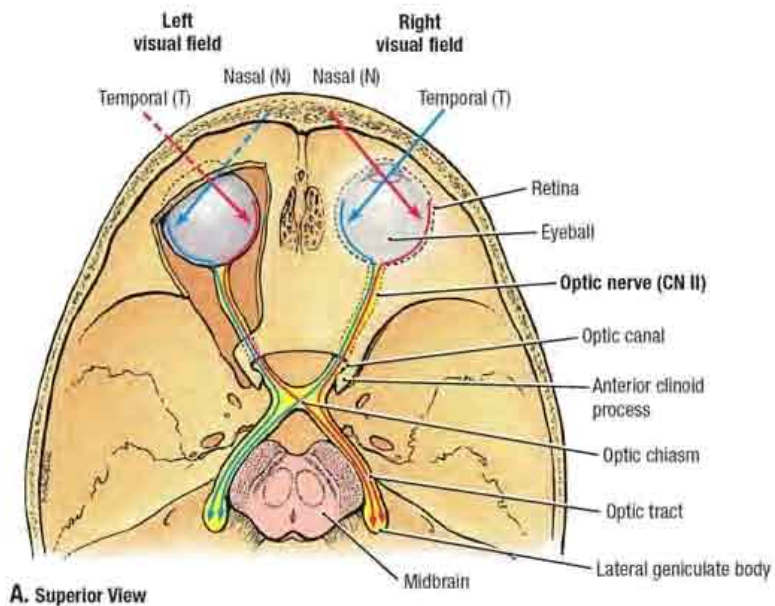
## 9.4 Visual pathway

*Part of* "Chapter 9 - Cranial Nerves "

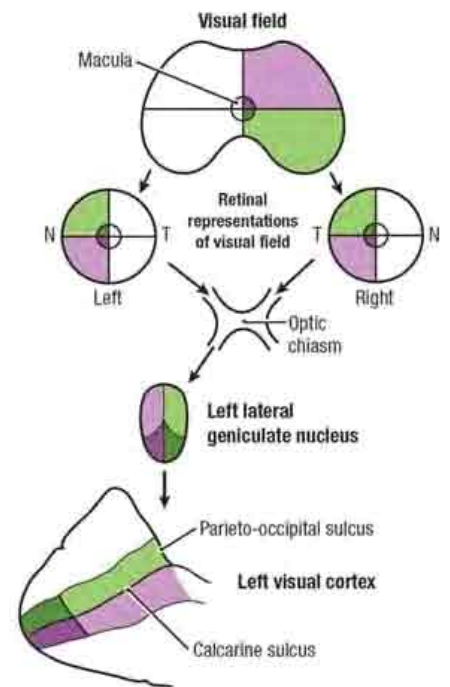
A. The visual pathway in situ. B. Visual field representation on retinae, lateral geniculate nucleus, and visual cortex. C–E. Schematic illustrations of lesions of the visual pathway.

---

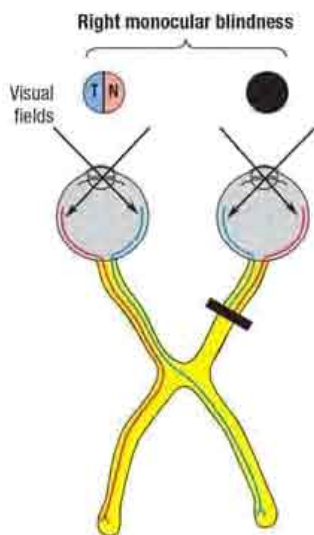
P.821



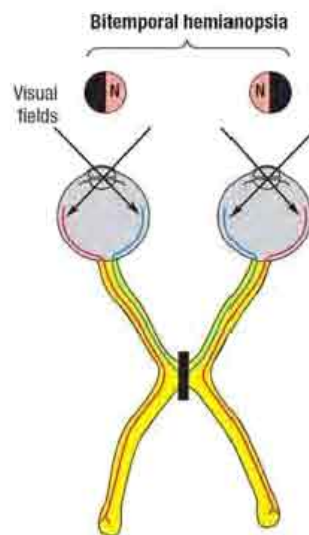
**A. Superior View**



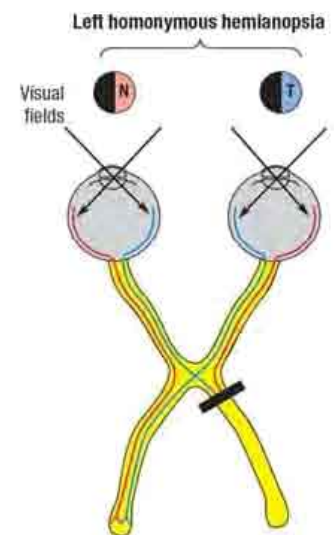
**B**



**C. Section of Right Optic Nerve**



**D. Section of Optic Chiasm**



**E. Section of Right Optic Tract**

Authors: Agur, Anne M.R.; Dalley, Arthur F.

Title: *Grant's Atlas of Anatomy, 12th Edition*

Copyright ©2009 Lippincott Williams & Wilkins

> Table of Contents > Chapter 9 - Cranial Nerves > 9.5 Overview of muscles and nerves of orbit

---

## 9.5 Overview of muscles and nerves of orbit

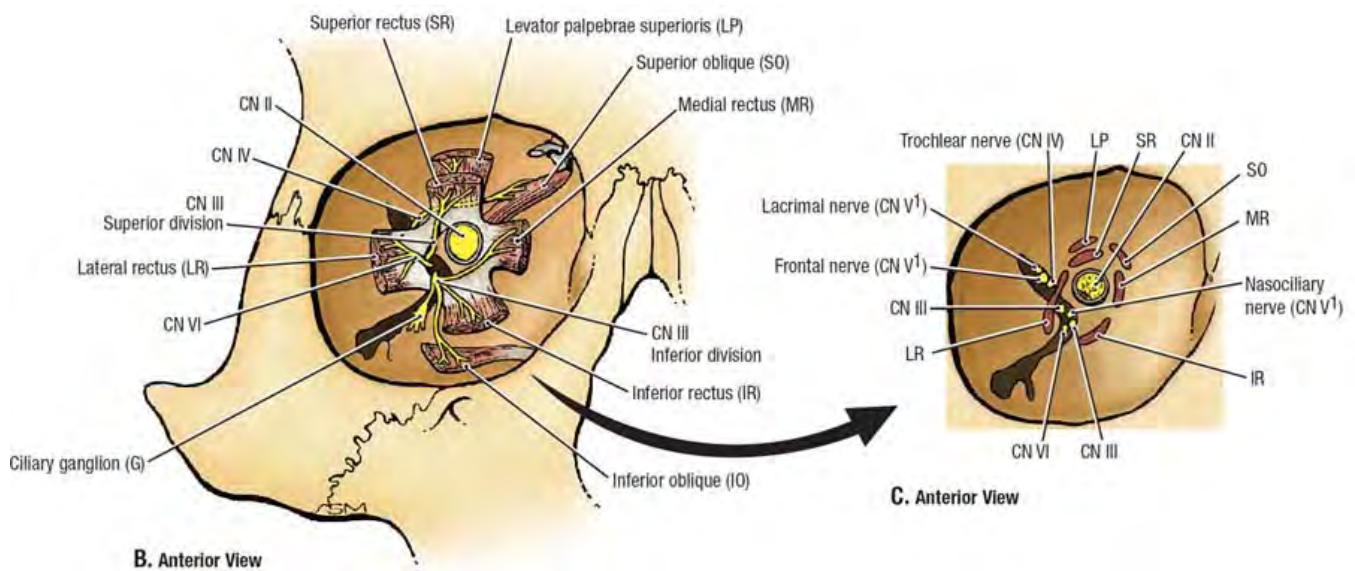
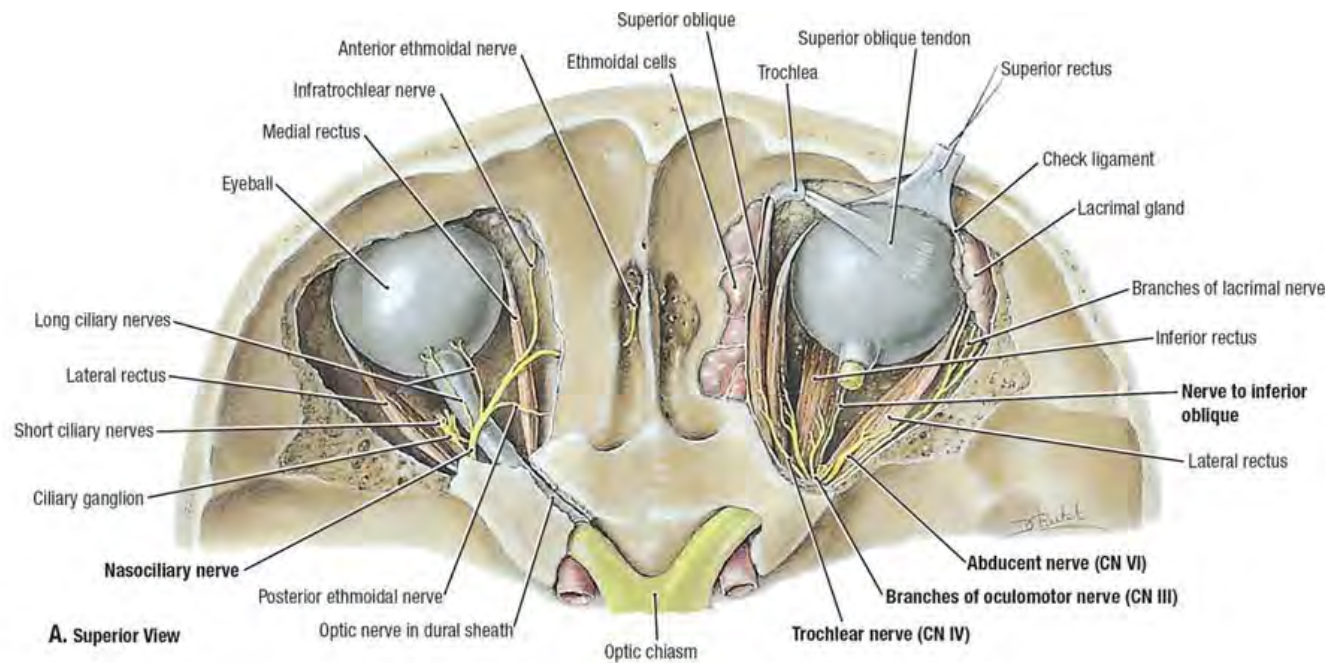
*Part of* "Chapter 9 - Cranial Nerves "

A. Orbital cavities, dissected from a superior approach. B. Structures of apex of orbit. C. Relationship of muscle attachments and nerves at apex of orbit.

---

P.822





Oculomotor

Somatic motor

Oculomotor nucleus

Superior orbital fissure

Motor to superior, inferior, and medial recti, inferior oblique, and levator palpebrae superioris muscles; raises upper eyelid; rotates eyeball superiorly, inferiorly, and medially



Visceral motor (parasympathetic)

Presynaptic: midbrain (Edinger-Westphal nucleus);

Postsynaptic: ciliary ganglion

Motor to sphincter pupillae and ciliary muscle that constrict pupil and accommodate lens of eyeball

Trochlear

Somatic motor

Trochlear nucleus

Motor to superior oblique that assists in rotating eyeball inferolaterally

Abducent

Somatic motor

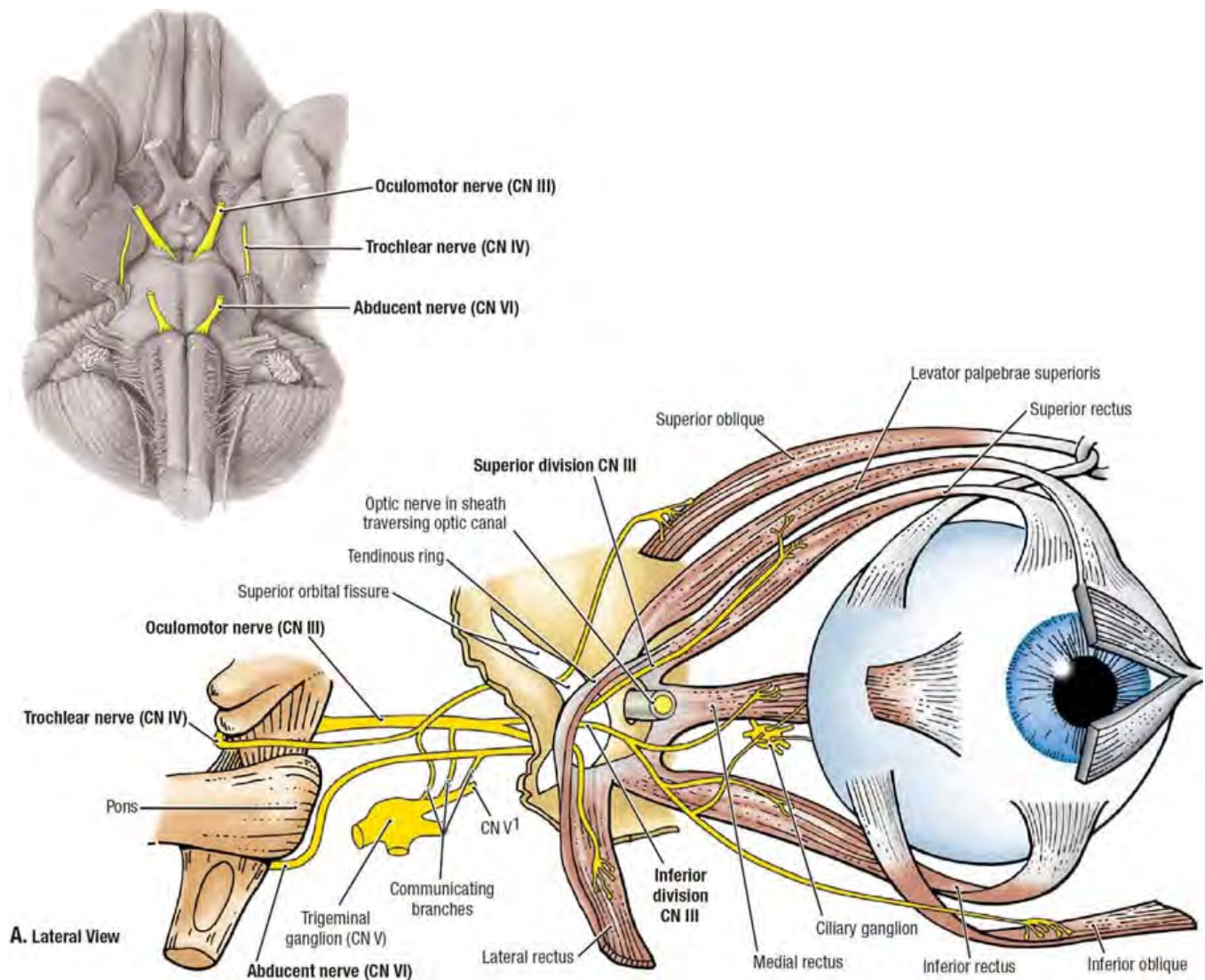
Abducent nucleus

Motor to lateral rectus that rotates eyeball laterally

Nerve	Functional Components	Cells of Origin/Termination	Cranial Exit	Distribution and Functions
Table 9.4 Oculomotor (CN III), Trochlear (CN IV), and Abducent (CN VI) Nerves <sup>a</sup>				

P.823

P.824



Ophthalmic division (CN V<sup>1</sup>)

General sensory

Trigeminal ganglion/spinal, principal and mesencephalic nucleus of CN V

Superior orbital fissure

Sensation from cornea, skin of forehead, scalp, eyelids, nose, and mucosa of nasal cavity and paranasal sinuses

Maxillary division (CN V<sup>2</sup>)

Foramen rotundum

Sensation from skin of face over maxilla including upper lip, maxillary teeth, mucosa of nose, maxillary sinuses, and palate

Mandibular division (CN V<sup>3</sup>)

Foramen ovale

Sensation from the skin over mandible, including lower lip and side of head, mandibular tee temporomandibular joint, and mucosa of mouth and anterior two thirds of tongue

Branchial motor

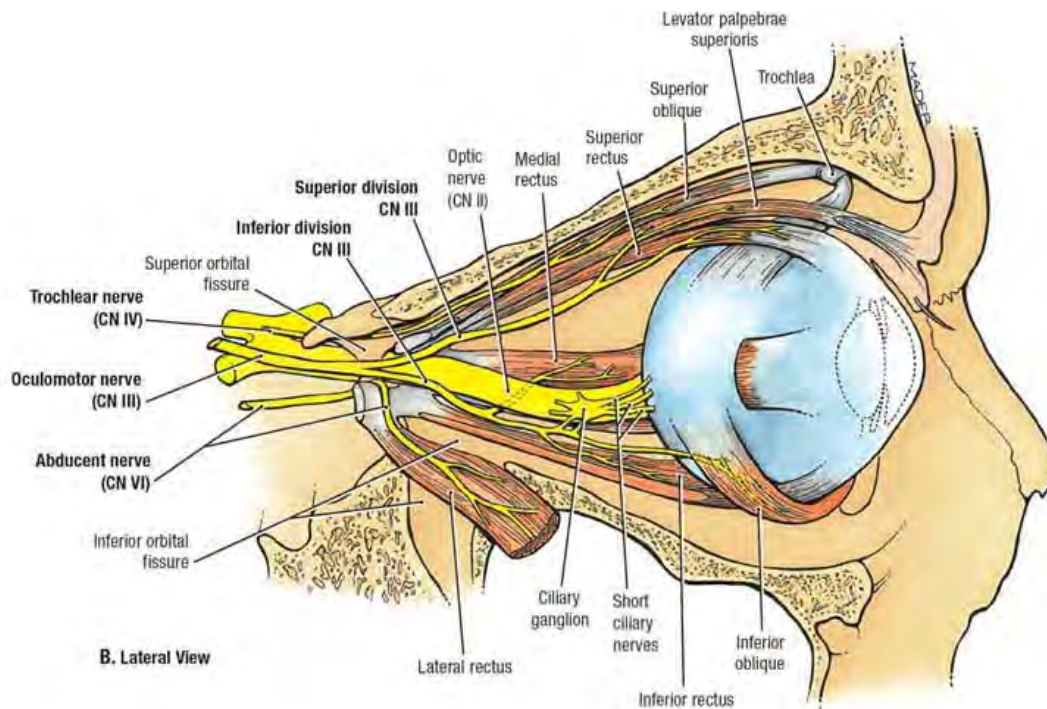
Trigeminal motor nucleus

Motor to muscles of mastication, mylohyoid, anterior belly of digastric, tensor veli palatini, tensor tympani

Nerve	Functional Components	Cells of Origin/Termination	Cranial Exit	Distribution and Functions
-------	-----------------------	-----------------------------	--------------	----------------------------

Table 9.5 Trigeminal Nerve (CN V)

P.825



B. Lateral View

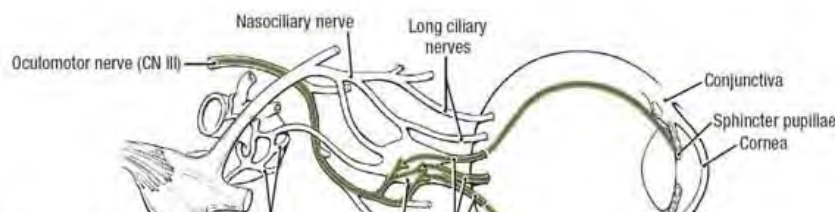
CN II contains parasympathetic fibers originating from nerve cell bodies of the accessory (Edinger-Westphal) nucleus of the oculomotor nerve



Fibers synapse in the ciliary ganglion, consisting of post-synaptic parasympathetic nerve cell bodies associated with CN V<sup>1</sup>



Short ciliary nerves (CN V<sup>1</sup>)





**C. Parasympathetic (visceral motor)  
Innervation of Eyeball, Lateral View**

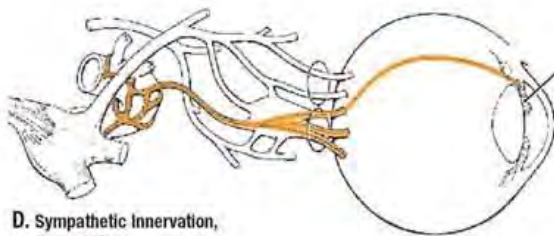
Internal carotid  
(sympathetic) plexus

Ciliary ganglion

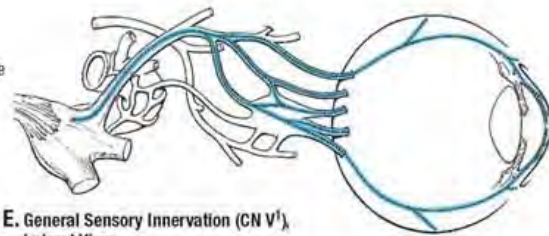
Short ciliary nerves

Ciliary muscle

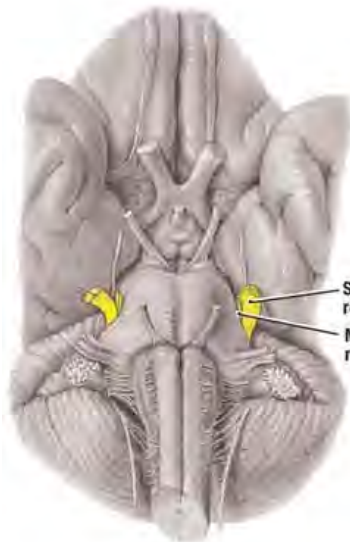
carry post-synaptic para-  
sympathetic fibers to the  
ciliary and constrictor pupillae  
muscles.



**D. Sympathetic Innervation,  
Lateral View**

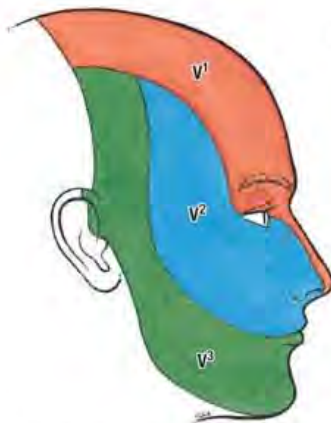


**E. General Sensory Innervation (CN V<sup>1</sup>),  
Lateral View**

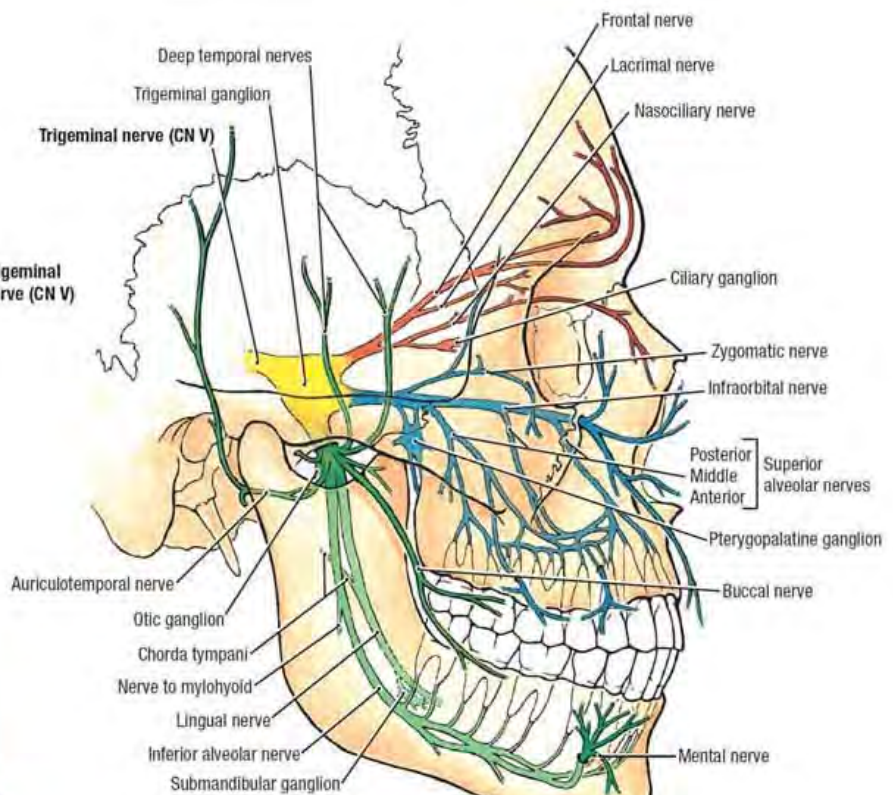


Sensory root  
Motor root

Trigeminal nerve (CN V)



**Cutaneous Innervation, Lateral View**



**Overview of Divisions, Lateral View**

**Nerves:**

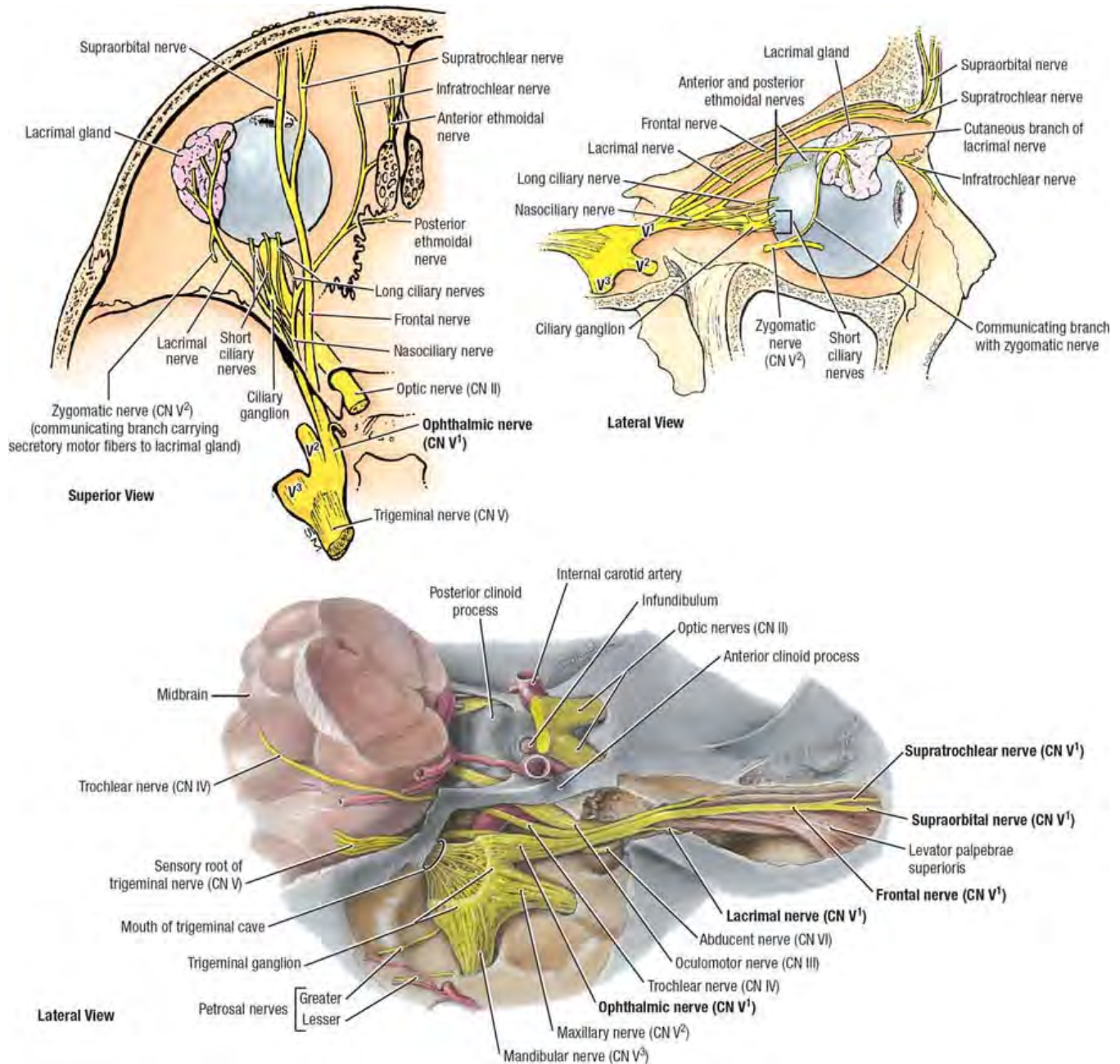
- Ophthalmic (CN V<sup>1</sup>)
- Maxillary (CN V<sup>2</sup>)
- Mandibular (CN V<sup>3</sup>)

The ophthalmic nerve is a sensory nerve passing through the superior orbital fissure that supplies the eyeball and conjunctiva, lacrimal gland and sac, nasal mucosa, frontal sinus, external nose, upper eyelid, forehead, scalp, and central dura mater of anterior cranial fossa.

Lacrimal nerve  
Frontal nerve  
    Supraorbital nerve  
    Supratrochlear nerve  
Nasociliary nerve  
    Short ciliary nerves  
    Long ciliary nerves  
    Infratrochlear nerve  
    Anterior and posterior ethmoidal nerves  
  
Function    Branches

Table 9.6 Branches of Ophthalmic Nerve (CN V <sup>1</sup> )
---





The maxillary nerve is a sensory nerve passing through the foramen rotundum that supplies sensation to the face, upper teeth and gums, mucous membrane of the nasal cavity, palate roof of the pharynx, maxillary, ethmoidal, and sphenoidal sinuses, and secretory fibers from pterygopalatine ganglion, which pass with the zygomatic and lacrimal nerves to the lacrimal gland

Meningeal branch

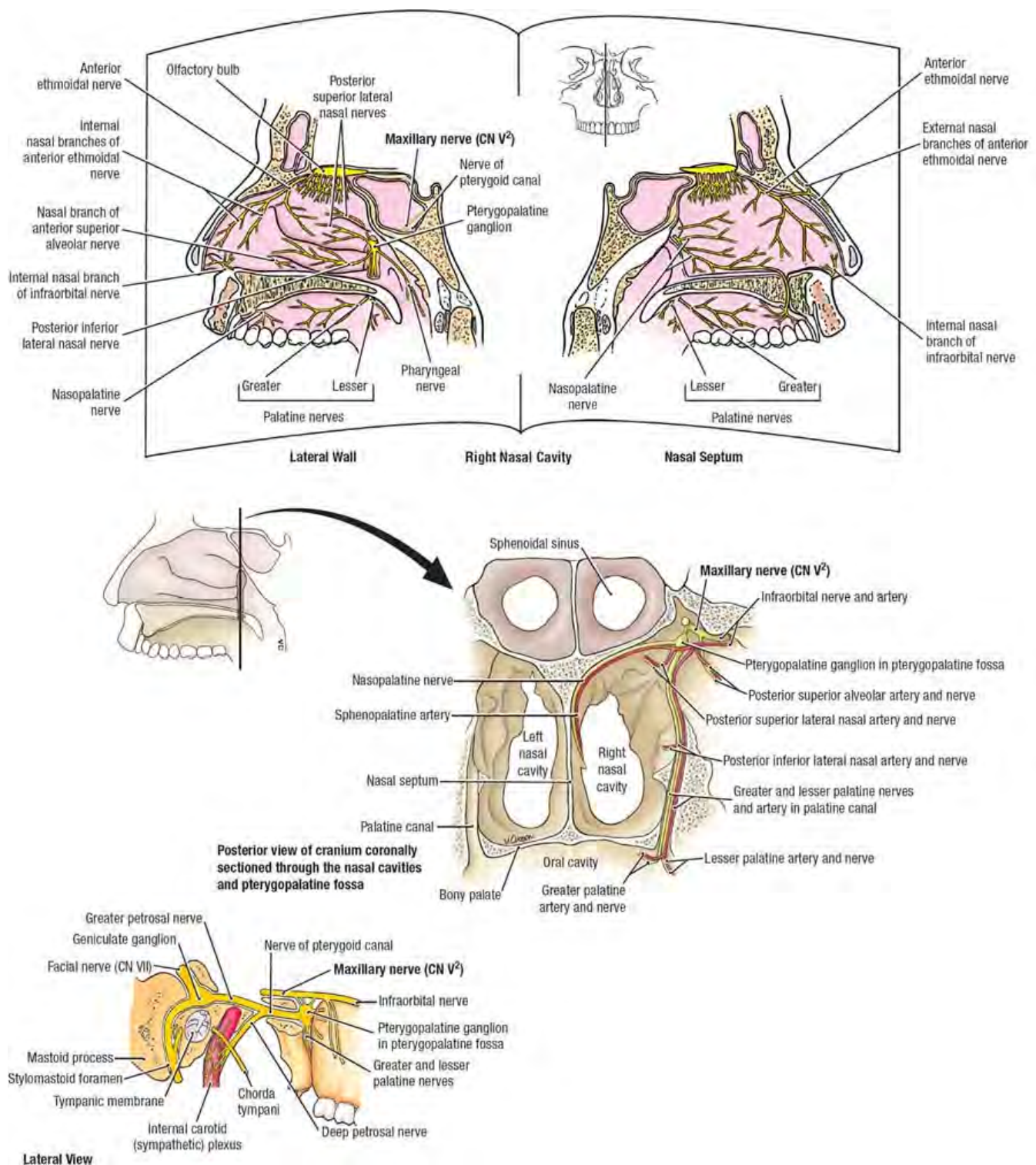
Zygomatic nerve

- Zygomaticofacial nerve
- Zygomaticotemporal nerve
- Posterior superior alveolar nerves
- Infraorbital nerve
  - Anterior and middle superior alveolar nerves
  - Superior labial branches
  - Inferior palpebral branches
  - External and internal nasal branches
- Greater palatine nerve
  - Posterior inferior lateral nasal branches
- Lesser palatine nerve
  - Posterior superior lateral nasal branches
- Nasopalatine nerve
- Pharyngeal nerve
- Function    Branches

Table 9.7 Branches of Maxillary Nerve (CN V<sup>2</sup> )







The mandibular nerve is a sensory and motor nerve passing through the foramen ovale. Gen sensory branches supply the lower teeth, gums, lip, auricle, external acoustic meatus, outer surface of tympanic membrane, cheek, anterior two thirds of tongue, and floor of mouth. C

also conveys secretory fibers from the otic ganglion to the parotid gland. Taste from the anterior two thirds of the tongue and presynaptic secretomotor fibers to the submandibular ganglion are conveyed to the nerve by the chorda tympani. Postsynaptic fibers from the submandibular ganglion pass to the submandibular and sublingual glands

Meningeal branch

Buccal nerve

Auriculotemporal nerve

Inferior alveolar nerve

Inferior dental nerves

Mental nerve

Incisive nerve

Lingual nerve

Motor branches supply the muscles of mastication and other muscles derived from the first branchial arches

Masseter

Temporalis

Medial and lateral pterygoids

Tensor veli palatini

Mylohyoid

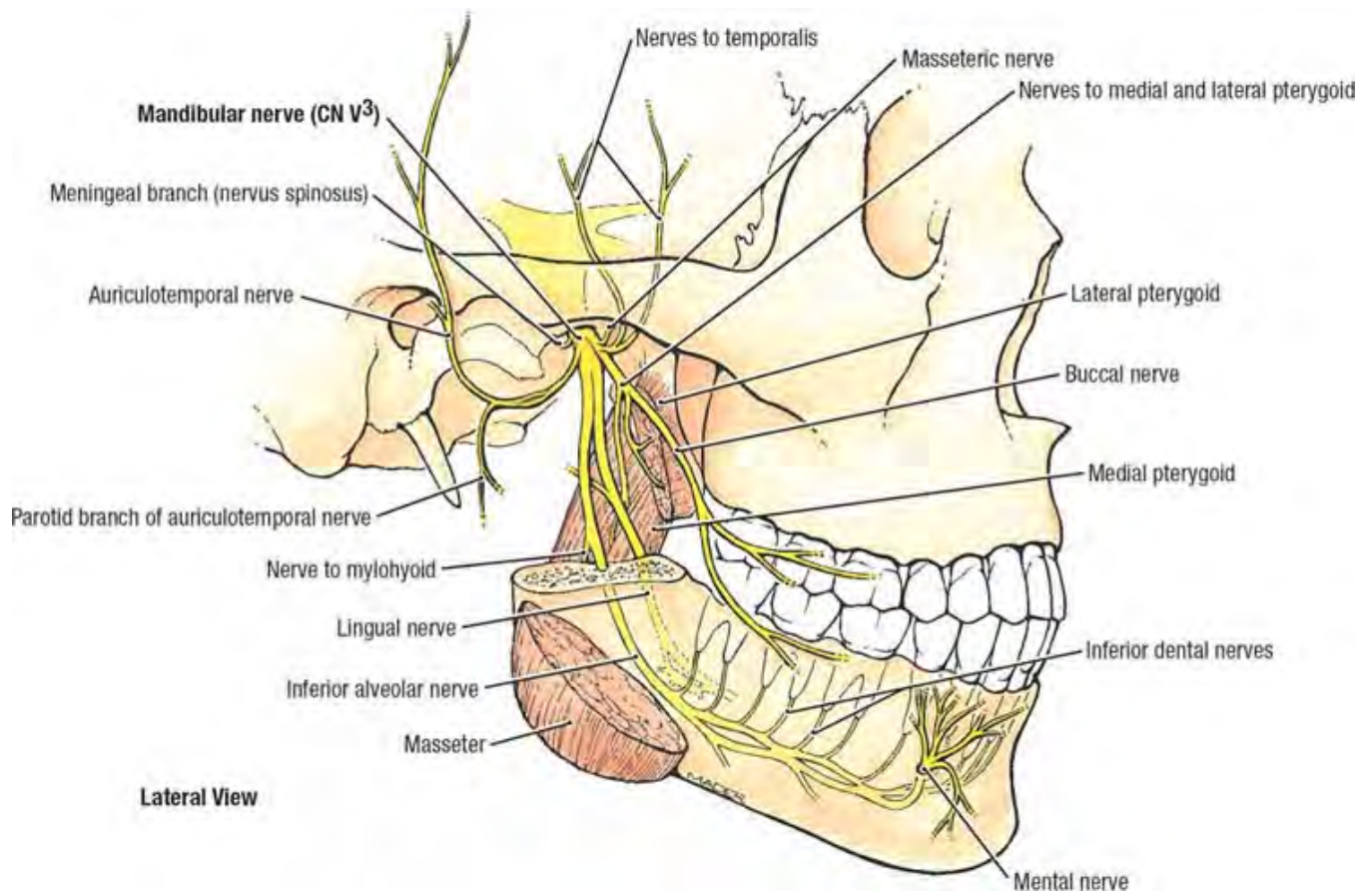
Anterior belly of digastric

Tensor tympani

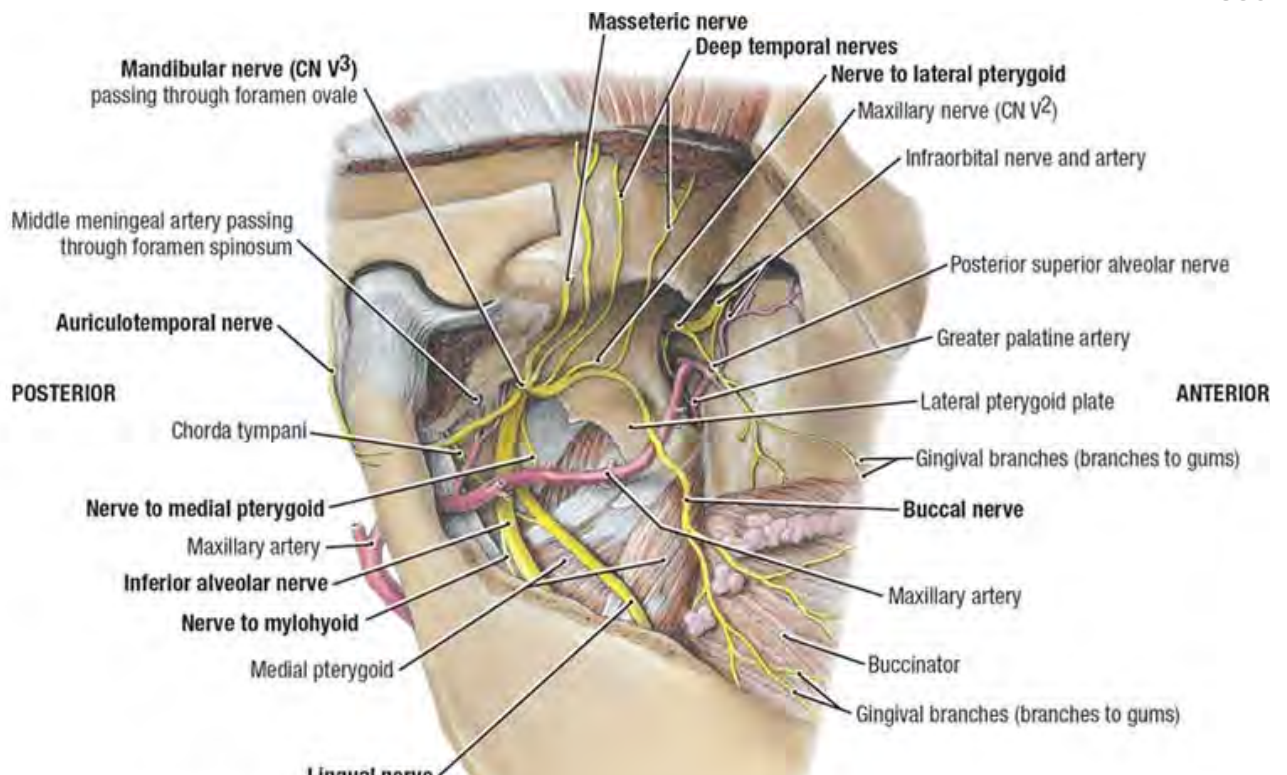
Function    Branches

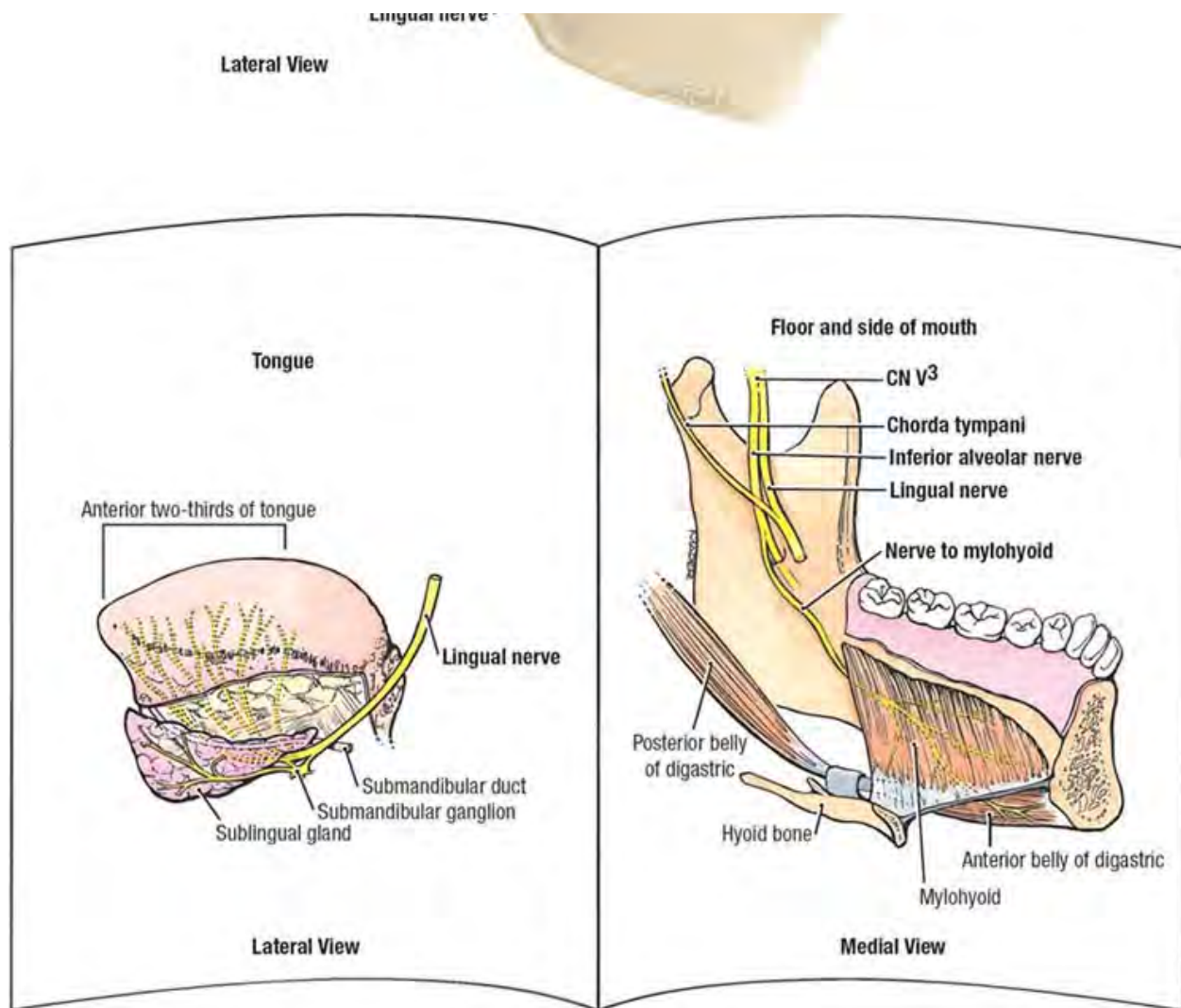
Table 9.8 Branches of Mandibular Nerve (CN V<sup>3</sup> )





P.830





Temporal, zygomatic, buccal, mandibular, cervical, and posterior auricular nerves, nerve to posterior belly of digastric, nerve to stylohyoid, nerve to stapedius

Branchial motor

Facial motor nucleus

Stylomastoid foramen

Motor to muscles of facial expression and scalp; also supplies stapedius of middle ear, stylohyoid, and posterior belly of digastric

Intermediate nerve through chorda tympani

Special sensory

Geniculate ganglion/solitary nucleus

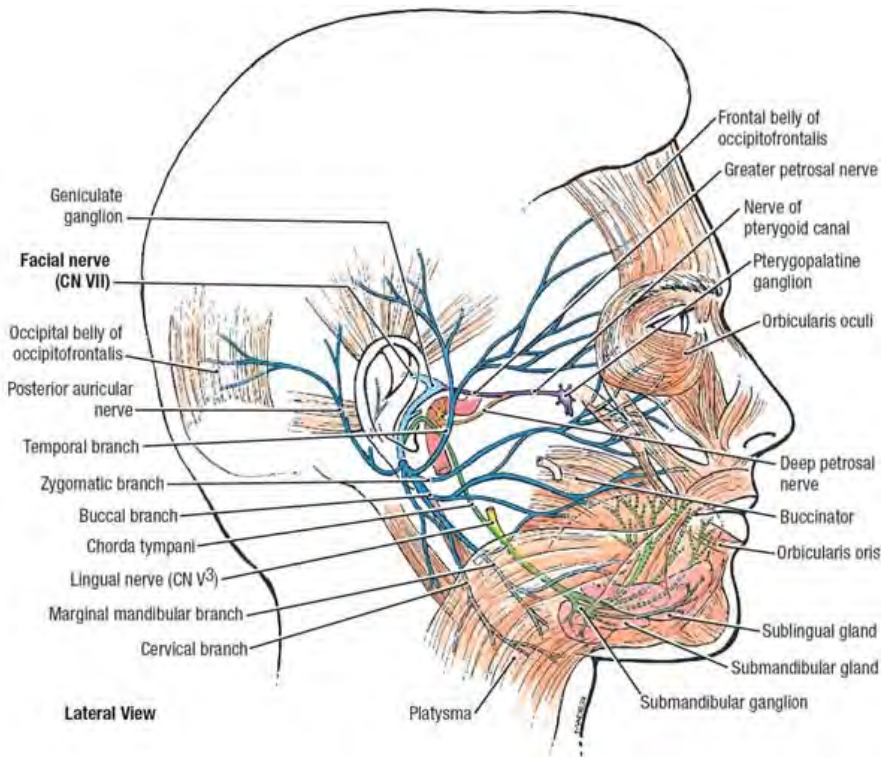
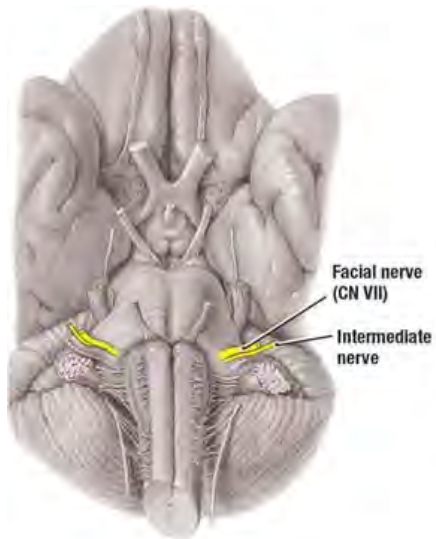
Internal acoustic meatus/facial canal/petro-tympanic fissure

Taste from anterior two thirds of tongue, floor of mouth, and palate

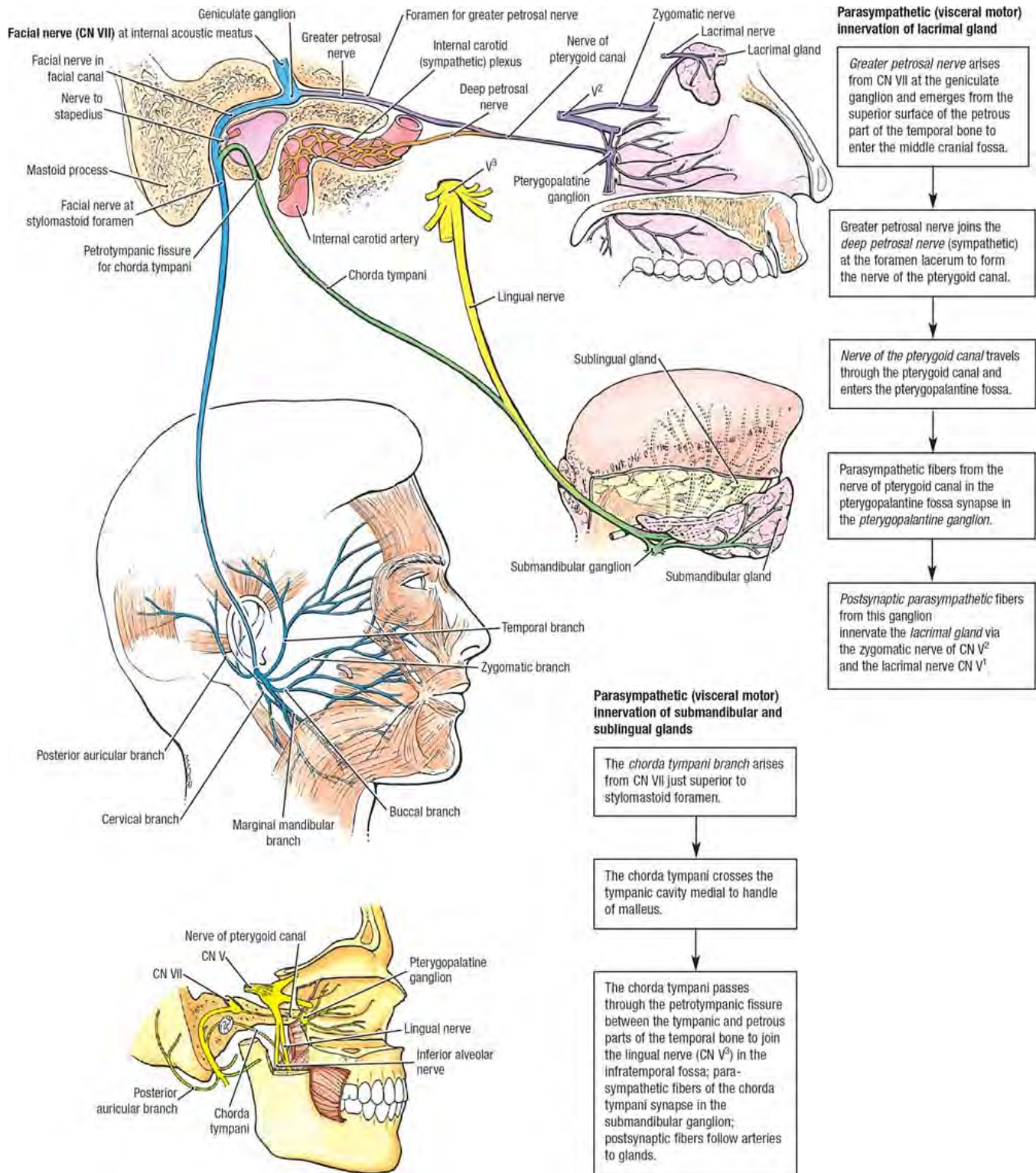
Intermediate nerve  
 General sensory  
 Geniculate ganglion/spinal trigeminal nucleus  
 Internal acoustic meatus  
 Sensation from skin of external acoustic meatus  
 Intermediate nerve through greater petrosal nerve  
 Visceral sensory  
 Solitary nucleus  
 Internal acoustic meatus/facial canal/foramen for greater petrosal nerve  
 Visceral sensation from mucous membranes of nasopharynx and palate  
 Greater petrosal nerve Chorda tympani  
 Visceral motor (parasympathetic)  
 Presynaptic: superior salivatory nucleus;  
 Postsynaptic: pterygopalatine ganglion (greater petrosal nerve) and submandibular ganglion (chorda tympani)  
 Internal acoustic meatus/facial canal/foramen for greater petrosal nerve, (greater petrosal nerve) petrotympanic fissure (chorda tympani)  
 Secretomotor to lacrimal gland and glands of the nose and palate (greater petrosal nerve); submandibular and sublingual salivary glands (chorda tympani)

<sup>a</sup> See also Table 9.15 .

Nerve	Functional Components	Cells of Origin/Termination	Cranial Exit	Distribution and Functions
Table 9.9 Facial Nerve (CN VII), Including Motor Root and Intermediate Nerve <sup>a</sup>				







Vestibular nerve  
Special sensory  
Vestibular ganglion/vestibular nuclei



Internal acoustic meatus

Vestibular sensation from semicircular ducts, utricle, and saccule related to position and movement of head

Cochlear nerve

Special sensory

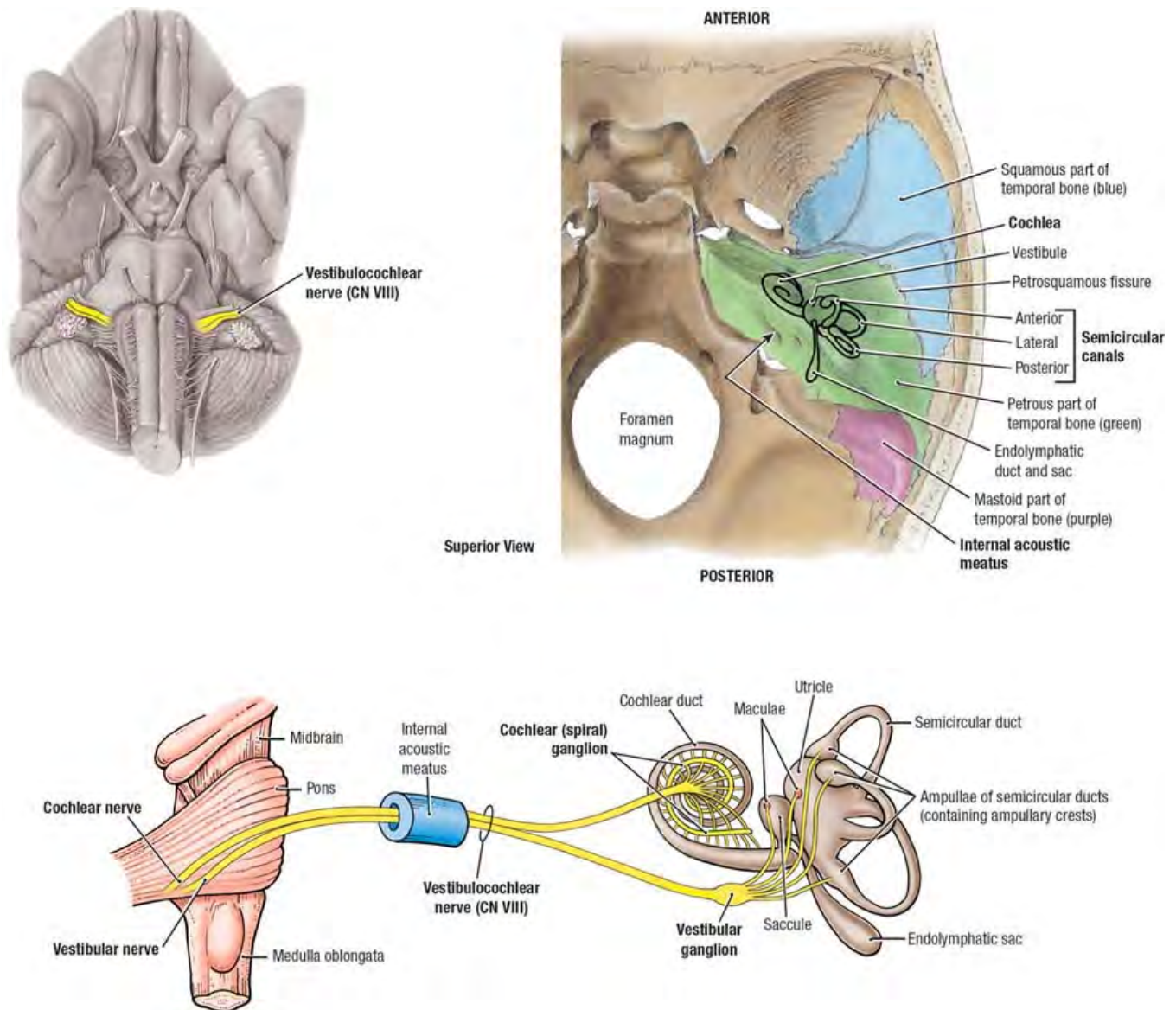
Spiral ganglion/cochlear nuclei

Internal acoustic meatus

Hearing from spiral organ

Part of Vestibulocochlear Nerve	Functional Components	Cells of Origin/Termination	Cranial Exit	Distributio and Functio
---------------------------------------	--------------------------	--------------------------------	-----------------	----------------------------

Table 9.10 Vestibulocochlear Nerve (CN VIII)

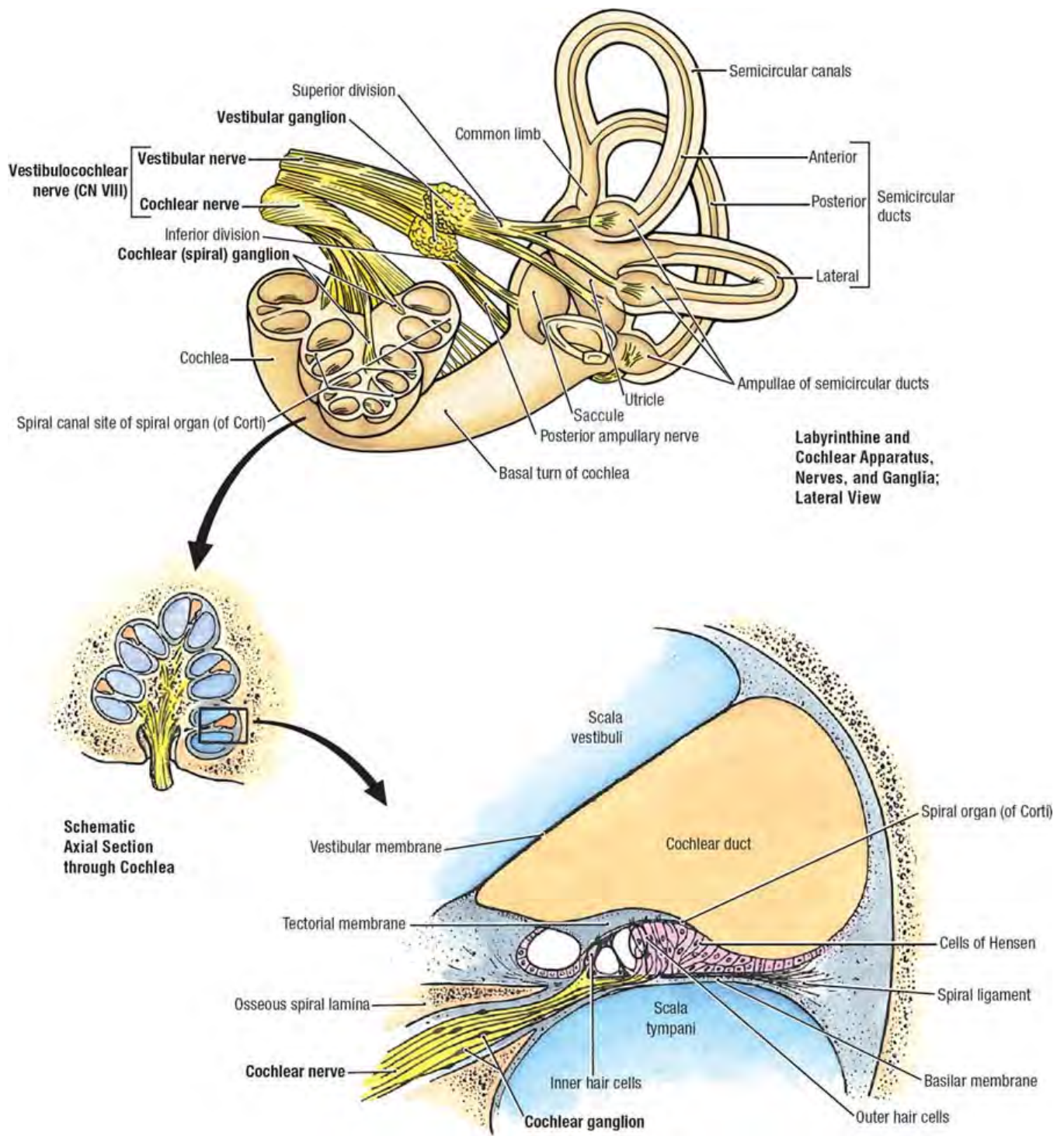


Observe in the lower diagram:

- The cochlear duct is a spiral tube fixed to the internal and external walls of the cochlear canal by the spiral ligament.
- The triangular cochlear duct lies between the osseous spiral lamina and the external wall of the cochlear canal.
- The roof of the cochlear duct is formed by the vestibular membrane and the floor by basilar membrane and osseous spiral lamina.
- The receptor of auditory stimuli is the spiral organ (of Corti), situated on the basilar

membrane; it is overlaid by the gelatinous tectorial membrane.

- The spiral organ contains hair cells that respond to vibrations induced in the endolymph by sound waves.
- The fibers of the cochlear nerve are axons of neurons in the spiral ganglion; the peripheral processes enter the spiral organ (of Corti).

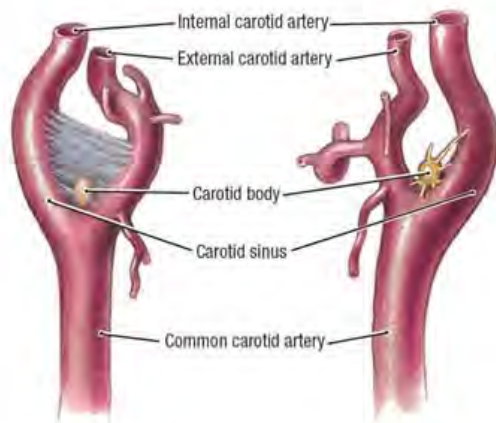
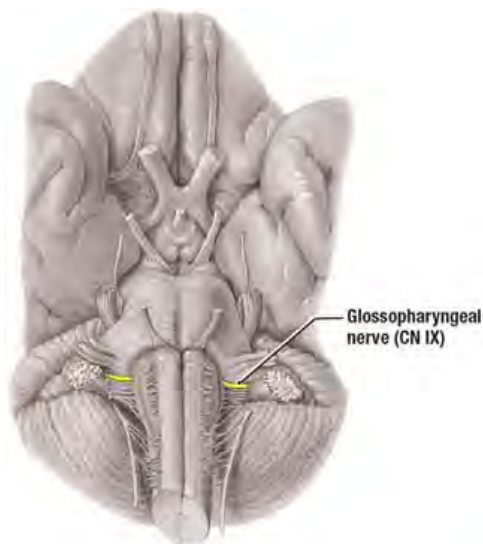


Glossopharyngeal  
 Branchial motor  
 Nucleus ambiguus  
 Jugular foramen

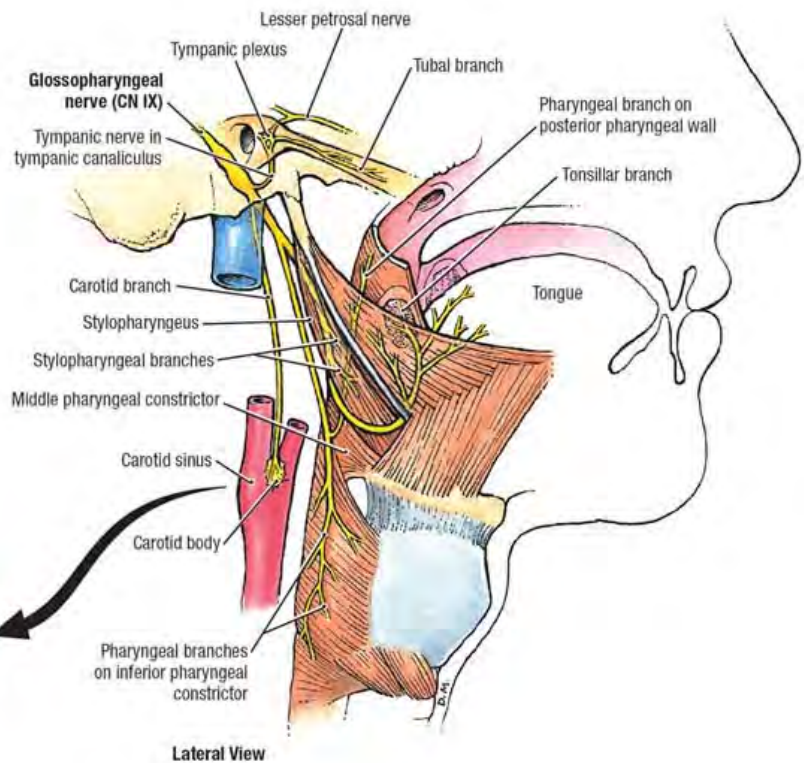
Motor to stylopharyngeus that assists with swallowing  
 Visceral motor (parasympathetic)  
 Presynaptic: inferior salivatory nucleus; postsynaptic: otic ganglion  
 Secretomotor to parotid gland  
 Visceral sensory  
 Solitary nucleus, spinal trigeminal nucleus/inferior ganglion  
 Visceral sensation from parotid gland, carotid body, carotid sinus, pharynx, and middle ear  
 Special sensory  
 Solitary nucleus/inferior ganglion  
 Taste from posterior third of tongue  
 General sensory  
 Spinal trigeminal nucleus/superior ganglion  
 Cutaneous sensation from external ear  
<sup>a</sup> See also Table 9.15 .

Nerve Functions	Functional Components	Cells of Origin/Termination	Cranial Exit	Distribution and Functions
Table 9.11 Glossopharyngeal Nerve (CN IX) <sup>a</sup>				





Posterior View



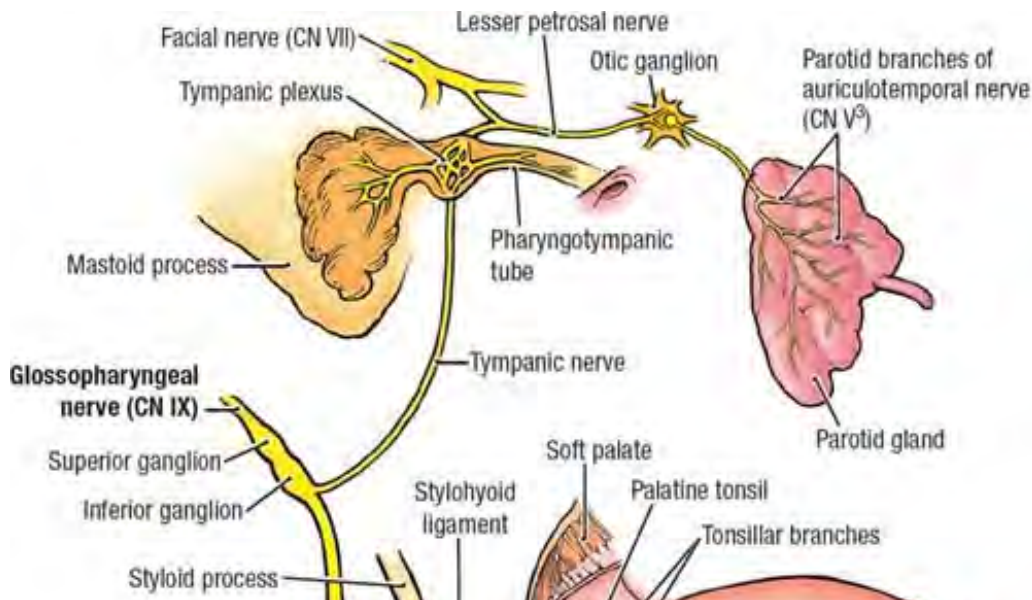
P.836

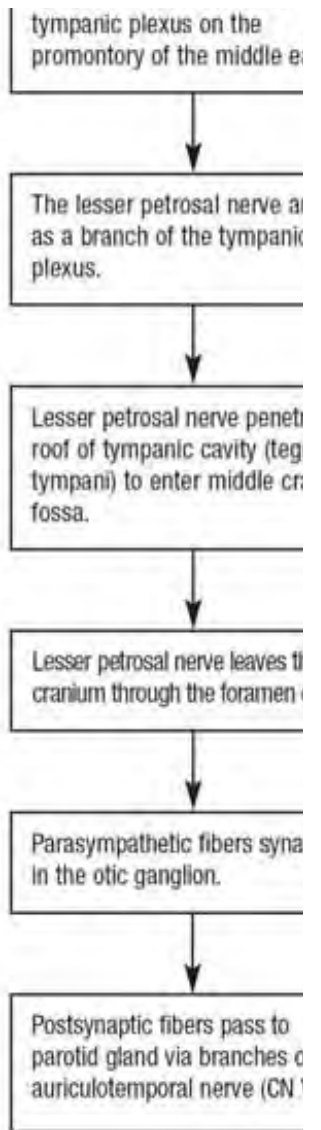
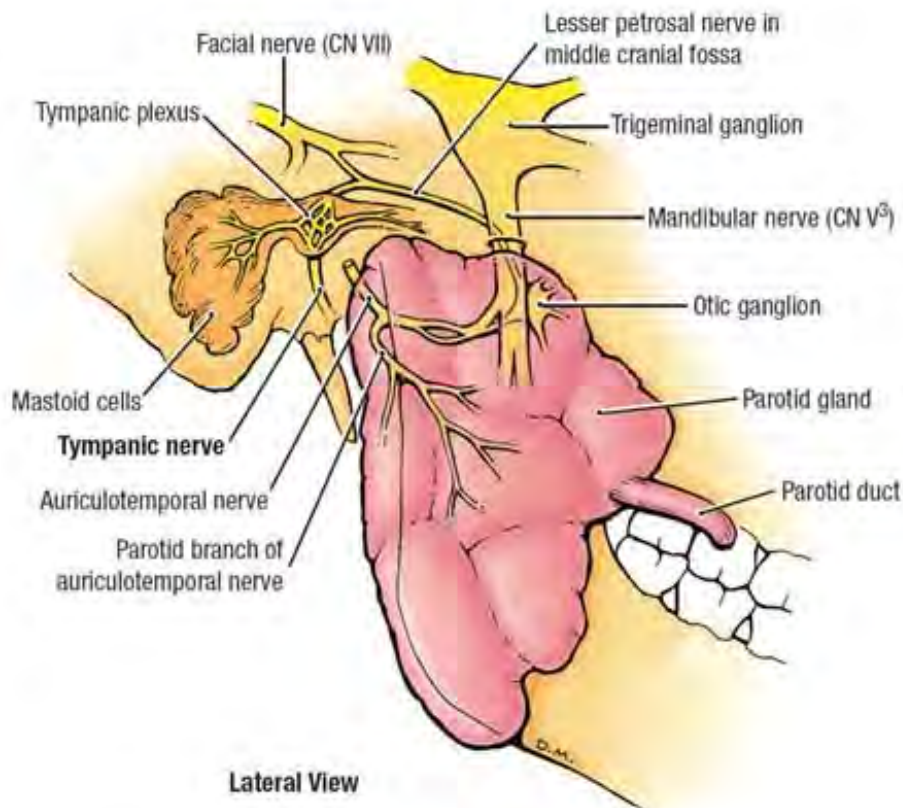
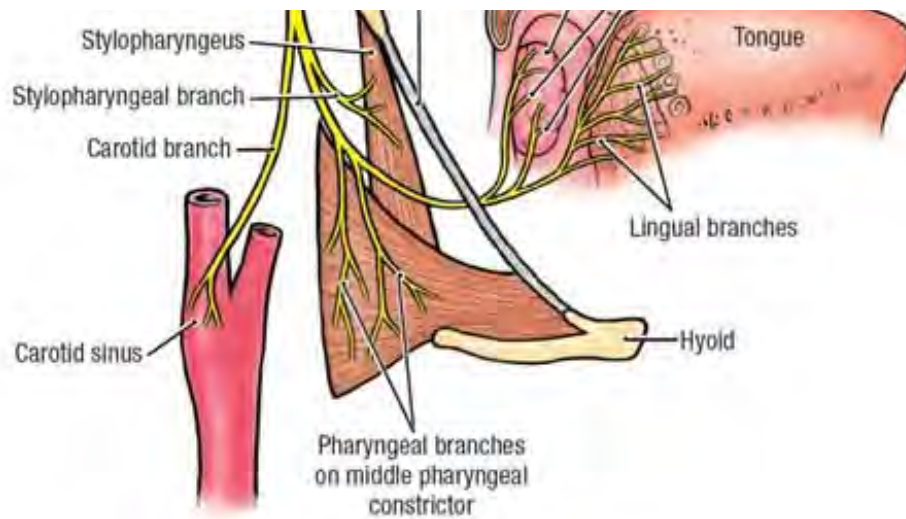
### Parasympathetic (visceral) innervation of parotid gland

Tympanic nerve arises from CN IX and emerges with it from the jugular foramen.

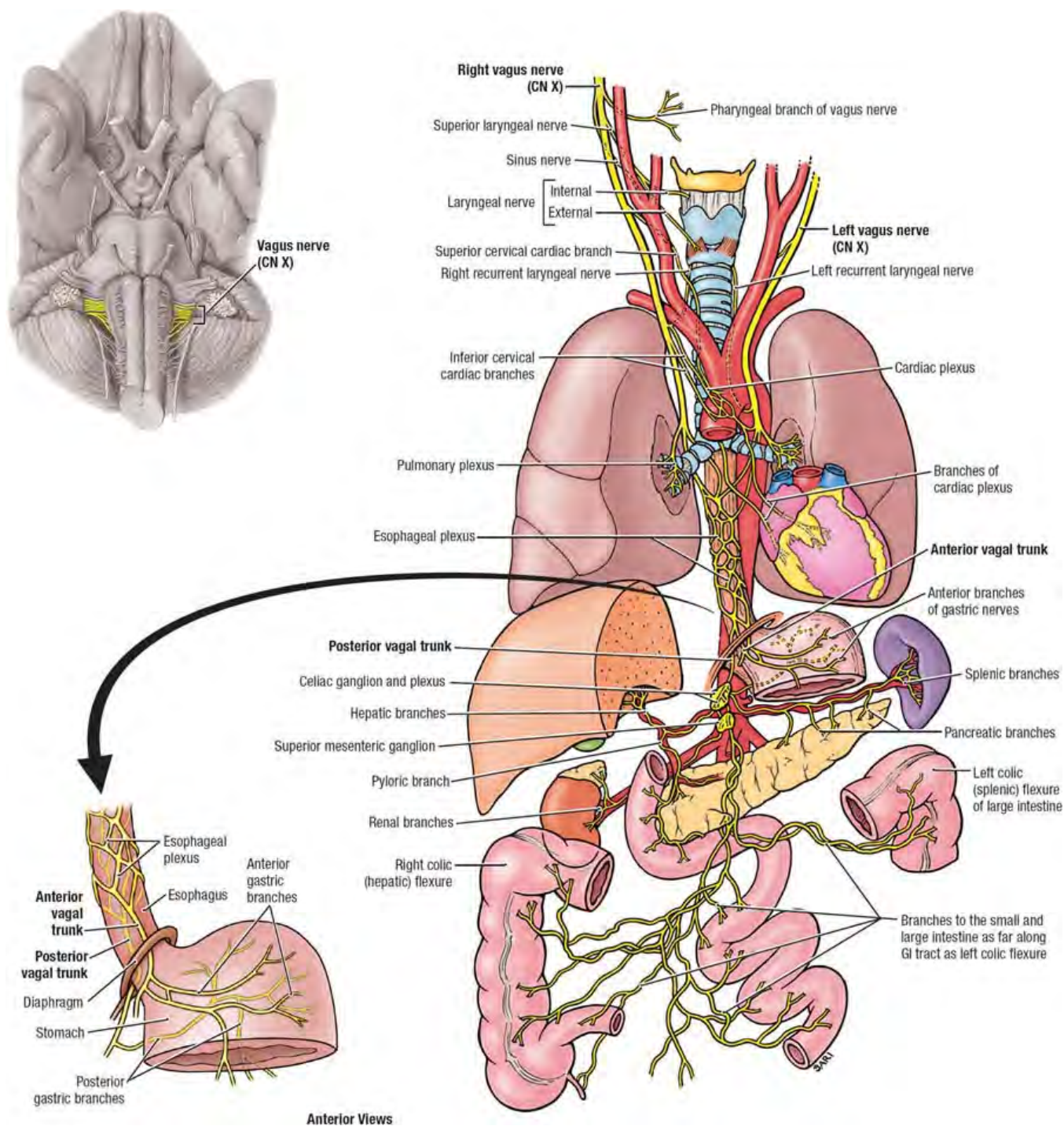
Tympanic nerve enters the middle ear via the tympanic canaliculus in the petrous part of the temporal bone.

Tympanic nerve forms the









Vagus

Branchial motor

Nucleus ambiguus

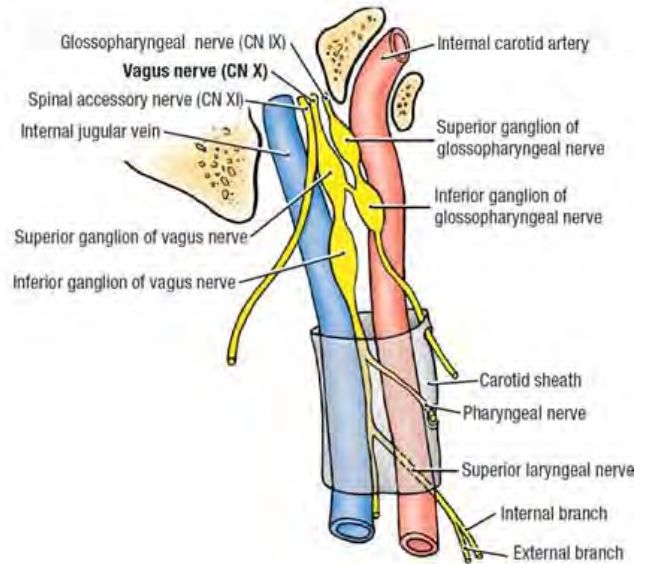
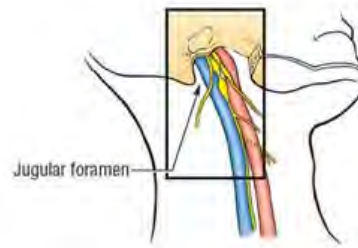
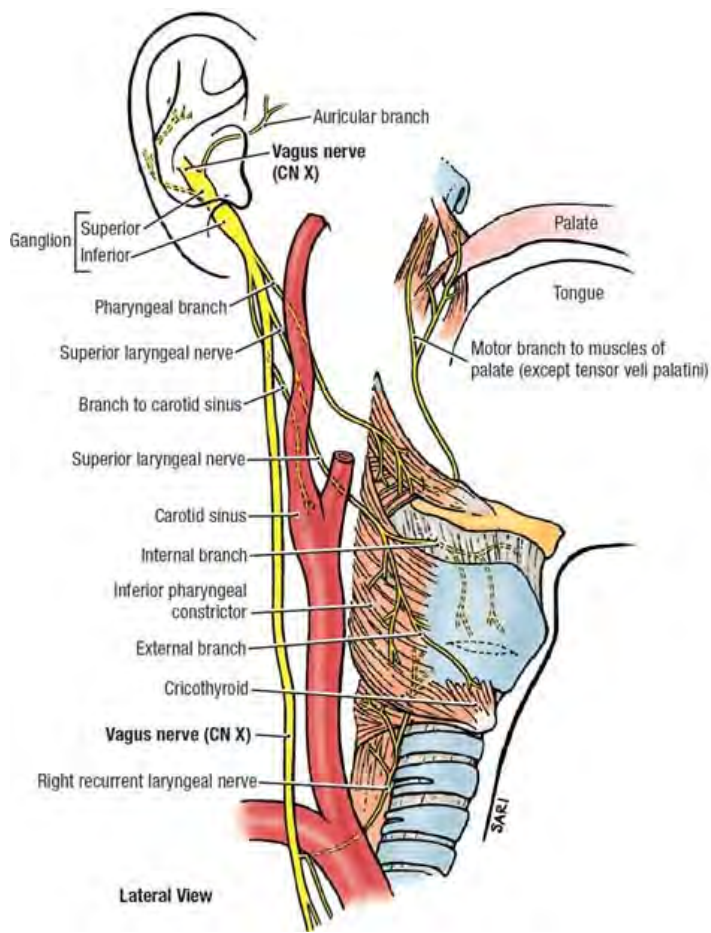
Jugular foramen

Motor to constrictor muscles of pharynx, intrinsic muscles of larynx, muscles of palate (exce

tensor veli palatini), and striated muscle in superior two thirds of esophagus  
 Visceral motor(parasympathetic)  
 Presynaptic: dorsal vagal nucleus;  
 Postsynaptic: neurons in, on, or near viscera  
 Motor to smooth muscle of trachea, bronchi, and digestive tract; moderates cardiac pacemaker and vasoconstrictor of coronary arteries  
 Visceral sensory  
 Solitary nucleus, spinal trigeminal nucleus/inferior ganglion  
 Visceral sensation from base of tongue, pharynx, larynx, trachea, bronchi, heart, esophagus, stomach, and intestine  
 Special sensory  
 Solitary nucleus/inferior ganglion  
 Taste from epiglottis and palate  
 General sensory  
 Spinal trigeminal nucleus/superior or inferior ganglion  
 Sensation from auricle, external acoustic meatus, and dura mater of posterior cranial fossa

Nerve Functions	Functional Components	Cells of Origin/Termination	Cranial Exit	Distribution and Functions
-----------------	-----------------------	-----------------------------	--------------	----------------------------

Table 9.12 Vagus Nerve (CN X)



Spinal accessory

Somatic motor

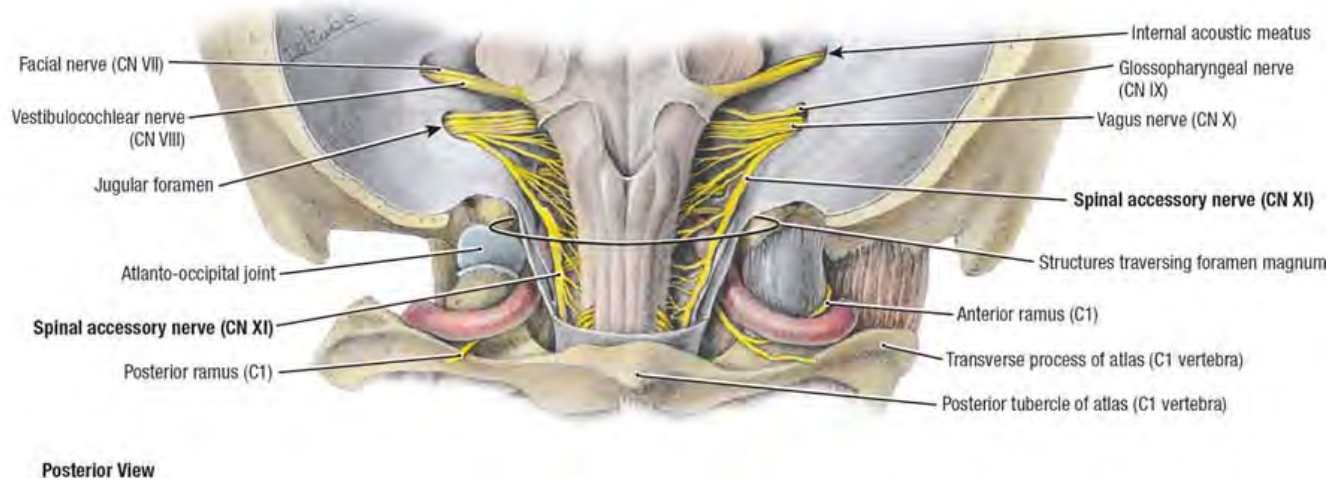
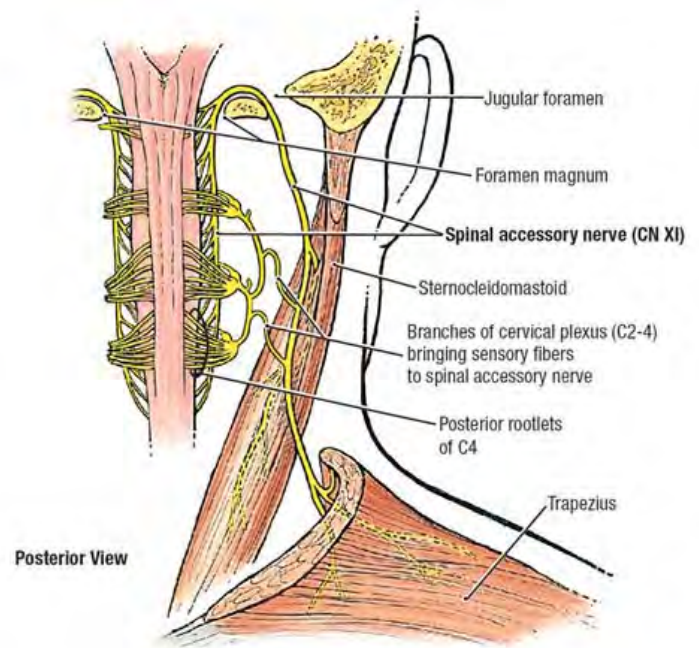
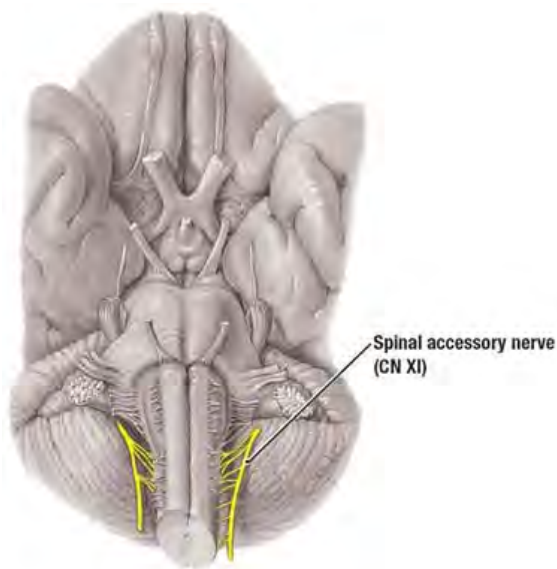
Accessory nucleus of spinal cord

Jugular foramen

Motor to sternocleidomastoid and trapezius

Nerve	Functional Components	Cells of Origin/Termination	Cranial Exit	Distribution and Functions
Table 9.13 Spinal Accessory Nerve (CN XI)				



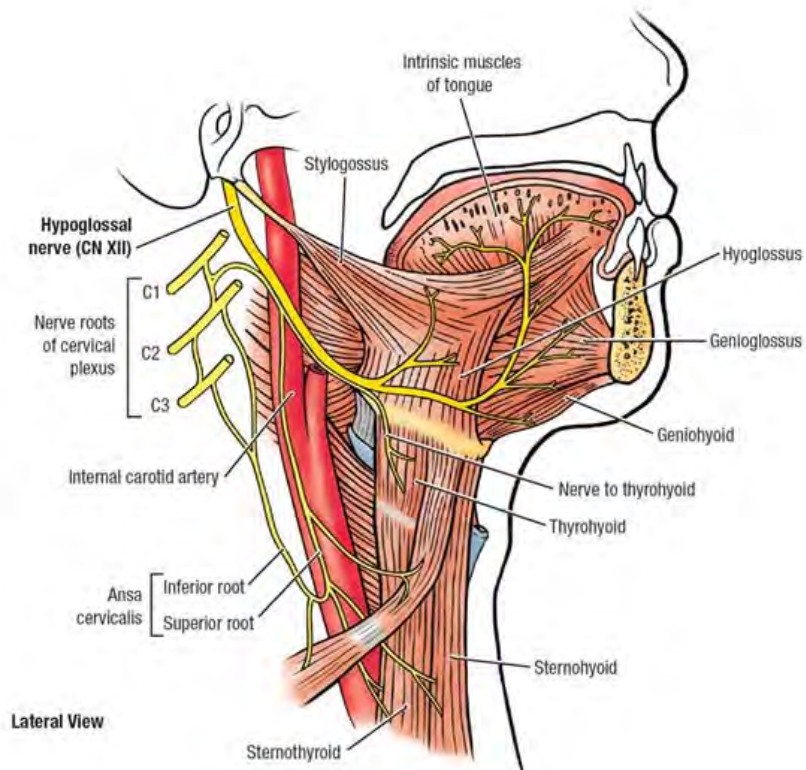
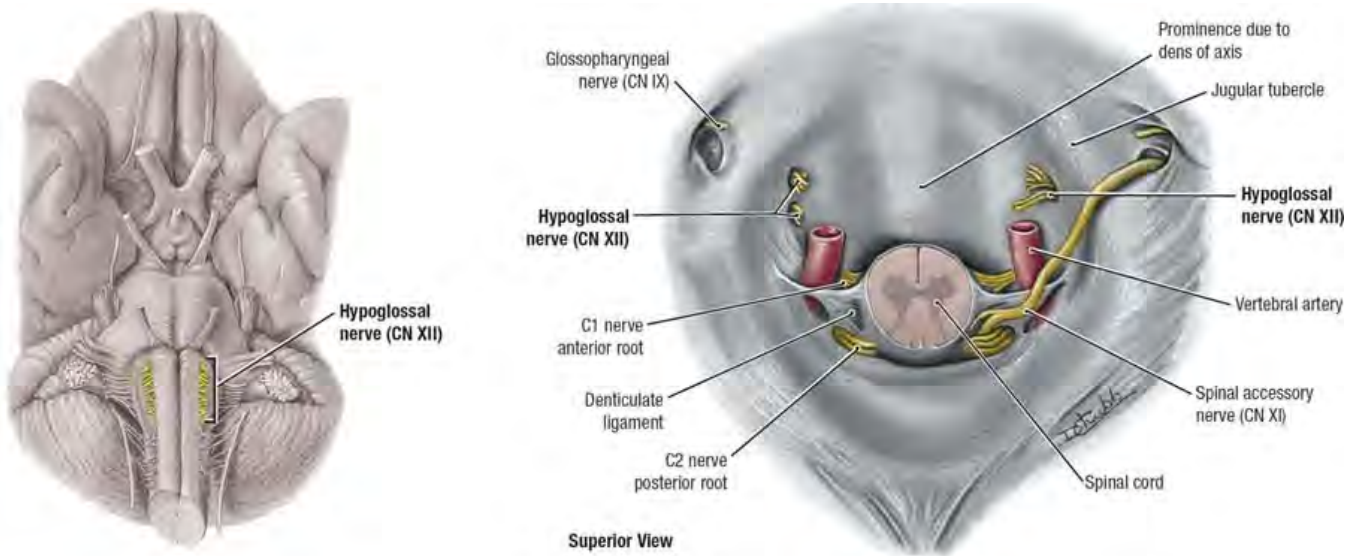


Hypoglossal  
Somatic motor  
Hypoglossal nucleus  
Hypoglossal canal  
Motor to muscles of tongue (except palatoglossus)

Nerve	Functional Components	Cells of Origin/Termination	Cranial Exit	Distribution and Functions
-------	-----------------------	-----------------------------	--------------	----------------------------

Table 9.14 Hypoglossal Nerve (CN XII)

P.840



Ciliary

Between optic nerve and lateral rectus, close to apex of orbit

Inferior branch of oculomotor nerve (CN III) (Edinger-Westphal nucleus)

Branch from internal carotid plexus in cavernous sinus

Parasympathetic postsynaptic fibers from ciliary ganglion pass to ciliary muscle and sphincter pupillae of iris; sympathetic postsynaptic fibers from superior cervical ganglion pass to dilator pupillae and blood vessels of eye

Pterygopalatine

In pterygopalatine fossa, where it is attached by pterygopalatine branches of maxillary nerve located just anterior to opening of pterygoid canal and inferior to CN V<sup>2</sup>

Greater petrosal nerve from facial nerve (CN VII) (superior salivatory nucleus)

Deep petrosal nerve, a branch of internal carotid plexus that is continuation of postsynaptic fibers of cervical sympathetic trunk; fibers from superior cervical ganglion pass through pterygopalatine ganglion and enter branches of CN V<sup>2</sup>

Parasympathetic postsynaptic fibers from pterygopalatine ganglion innervate lacrimal gland through zygomatic branch of CN V<sup>2</sup>; sympathetic postsynaptic fibers from superior cervical ganglion accompany branches of pterygopalatine nerve that are distributed to the nasal cavity, palate, and superior parts of the pharynx

Otic

Between tensor veli palatini and mandibular nerve; lies inferior to foramen ovale

Tympanic nerve from glossopharyngeal nerve (CN IX); tympanic nerve continues from tympanic plexus as lesser petrosal nerve (inferior salivatory nucleus)

Fibers from superior cervical ganglion travel via plexus on middle meningeal artery

Parasympathetic postsynaptic fibers from otic ganglion are distributed to parotid gland through auriculotemporal nerve (branch of CN V<sup>3</sup>); sympathetic postsynaptic fibers from superior cervical ganglion pass to parotid gland and supply its blood vessels

Submandibular

Suspended from lingual nerve by two short roots; lies on surface of hyoglossus muscle inferior to submandibular duct

Parasympathetic fibers join facial nerve (CN VII) and leave it in its chorda tympani branch, which unites with lingual nerve (superior salivatory nucleus)

Sympathetic fibers from superior cervical ganglion travel via the plexus on facial artery

Postsynaptic parasympathetic fibers from submandibular ganglion are distributed to the sublingual and submandibular glands; sympathetic fibers from superior cervical ganglion supply sublingual and submandibular glands

<sup>a</sup> For location of nuclei, see Figure 9.3 .

Ganglion	Location	Parasympathetic Root (Nucleus of Origin) <sup>a</sup>	Sympathetic Root	Main Distribution
----------	----------	---	------------------	-------------------

## Table 9.15 Autonomic Ganglia of the Head

P.841

### CN I

Fracture of cribriform plate

Anosmia (loss of smell); cerebrospinal fluid (CSF) rhinorrhea (leakage of CSF through nose)

### CN II

Direct trauma to orbit or eyeball; fracture involving optic canal

Loss of pupillary constriction

Pressure on optic pathway; laceration or intracerebral clot in temporal, parietal, or occipital lobes of brain

Visual field defects

Increased CSF pressure

Swelling of optic disc (papilledema)

### CN III

Pressure from herniating uncus on nerve; fracture involving cavernous sinus; aneurysms

Dilated pupil, ptosis, eye rotates inferiorly and laterally (down and out), pupillary reflex on side of the lesion will be lost

### CN IV

Stretching of nerve during its course around brainstem; fracture of orbit

Inability to rotate adducted eye inferiorly

### CN V

Injury to terminal branches (particularly CN V<sup>2</sup>) in roof of maxillary sinus; pathologic processes (tumors, aneurysms, infections) affecting trigeminal nerve

Loss of pain and touch sensations/paresthesia on face; loss of corneal reflex (blinking when cornea touched); paralysis of muscles of mastication; deviation of mandible to side of lesion when mouth is opened

### CN VI

Base of brain or fracture involving cavernous sinus or orbit

Inability to rotate eye laterally; diplopia on lateral gaze

CN VII

Laceration or contusion in parotid region

Paralysis of facial muscles; eye remains open; angle of mouth droops; forehead does not wrinkle

Fracture of temporal bone

As above, plus associated involvement of cochlear nerve and chorda tympani; dry cornea and loss of taste on anterior two thirds of tongue

Intracranial hematoma (â€œstrokeâ€•)

Weakness (paralysis) of lower facial muscles contralateral to the lesion, upper facial muscle not affected because they are bilaterally innervated

CN VIII

Tumor of nerve

Progressive unilateral hearing loss; tinnitus (noises in ear); vertigo (loss of balance)

CN IX<sup>a</sup>

Brainstem lesion or deep laceration of neck

Loss of taste on posterior third of tongue; loss of sensation on affected side of soft palate; loss of gag reflex on affected side

CN X

Brainstem lesion or deep laceration of neck

Sagging of soft palate; deviation of uvula to unaffected side; hoarseness owing to paralysis of vocal fold; difficulty in swallowing and speaking

CN XI

Laceration of neck

Paralysis of sternocleidomastoid and superior fibers of trapezius; drooping of shoulder

CN XII

Neck laceration; basal skull fractures

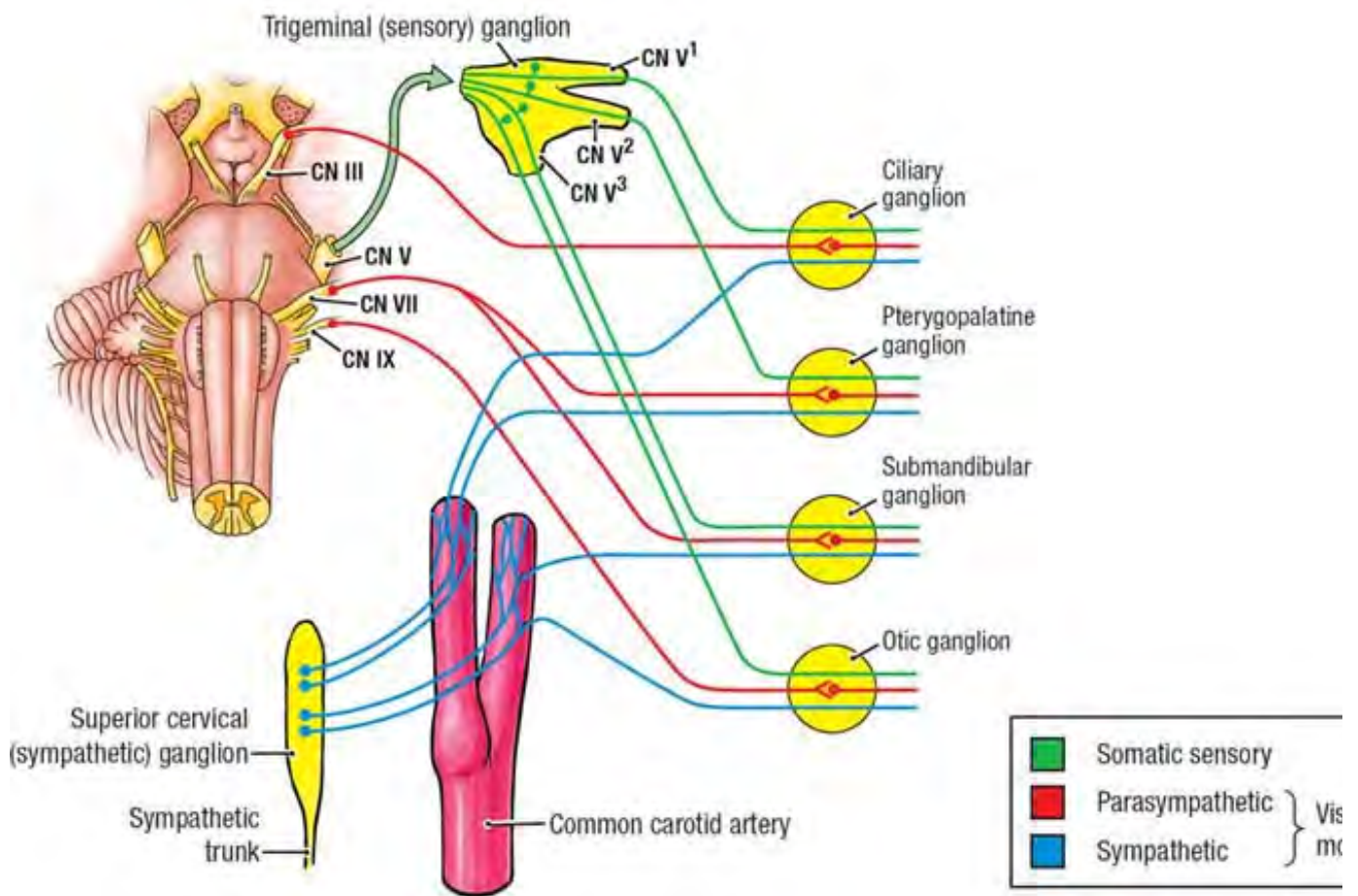
Protruded tongue deviates toward affected side; moderate dysarthria (disturbance of articulation)

<sup>a</sup> Isolated lesions of CN IX are uncommon; usually, CN IX, X, and XI are involved together as they pass through the jugular foramen.

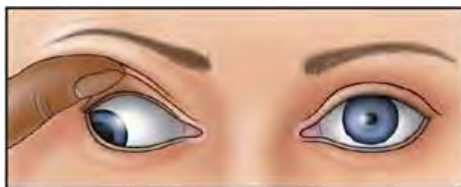Nerve	Lesion Type and/or Site	Abnormal Findings
-------	-------------------------	-------------------

Table 9.16 Summary of Cranial Nerve Lesions
---



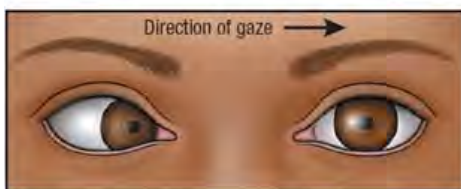

P.842

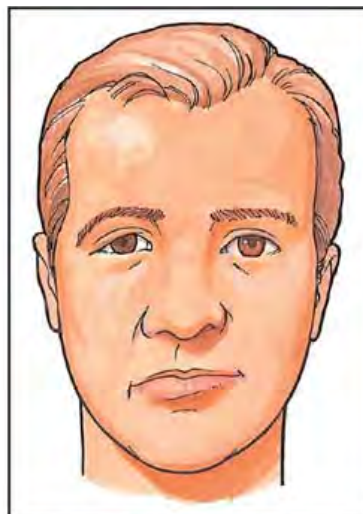


Right eye: Downward and outward gaze, dilated pupil, eyelid manually elevated due to ptosis

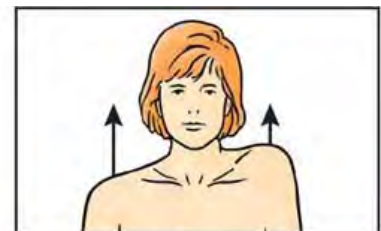Right oculomotor (CN III) nerve palsy



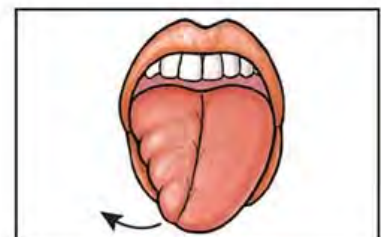
Left eye: Does not abduct  
Left abducent (CN VI) nerve palsy



Right facial (CN VII) palsy (Bell palsy)



Right CN XI lesion



Right CN XII lesion

Authors: Agur, Anne M.R.; Dalley, Arthur F.

Title: *Grant's Atlas of Anatomy, 12th Edition*

Copyright ©2009 Lippincott Williams & Wilkins

> Table of Contents > Chapter 9 - Cranial Nerves > 9.6 Transverse MRIs through head, showing cranial nerves

## 9.6 Transverse MRIs through head, showing cranial nerves

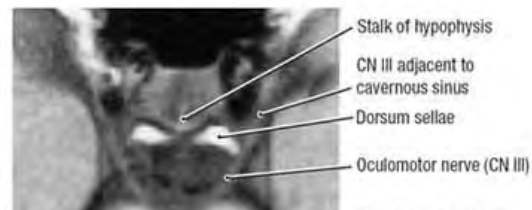
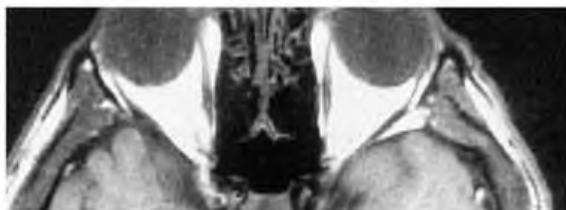
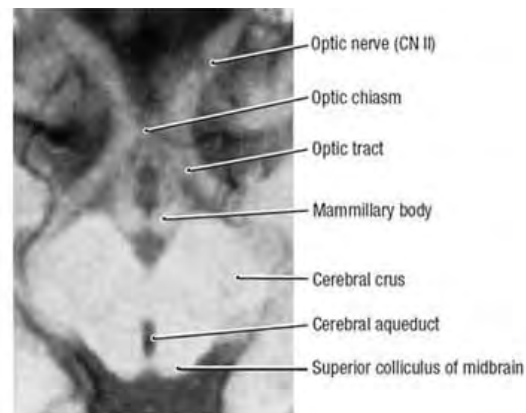
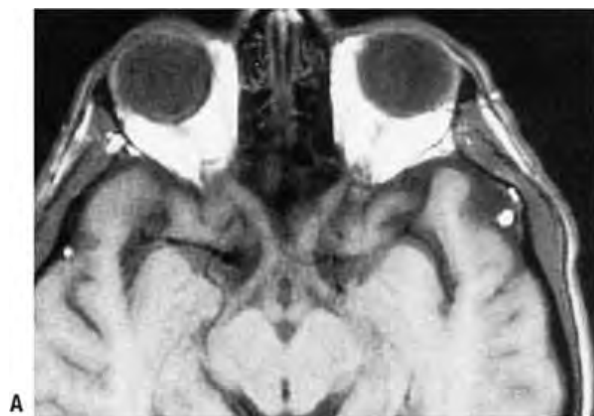
Part of "Chapter 9 - Cranial Nerves"

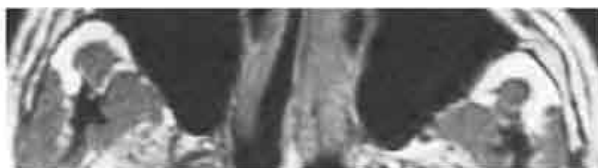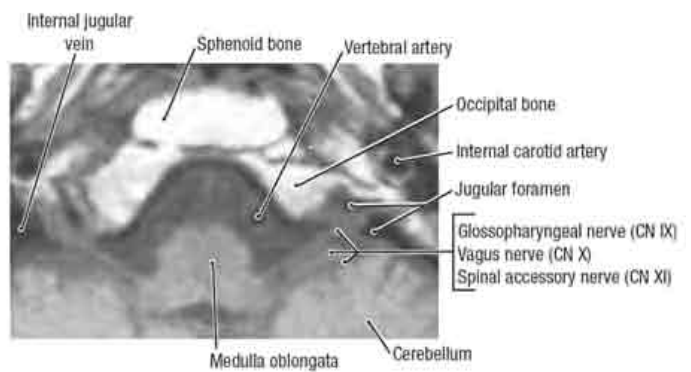
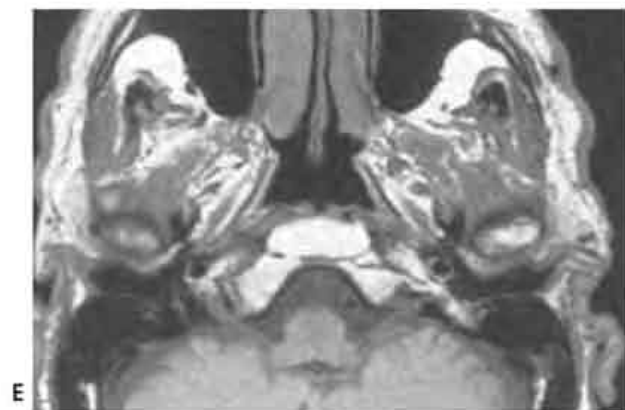
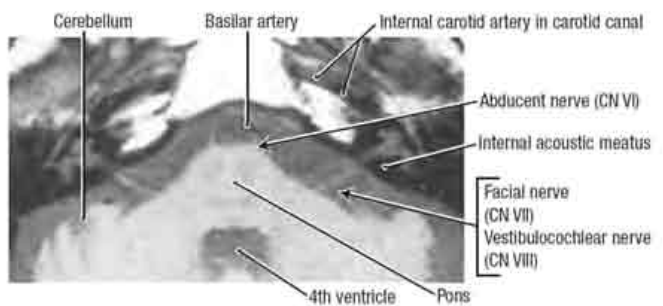
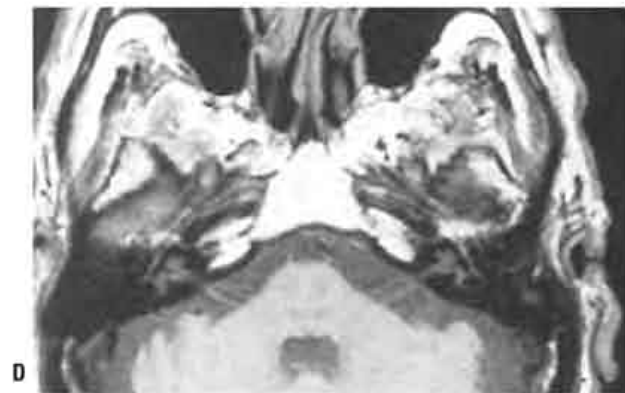
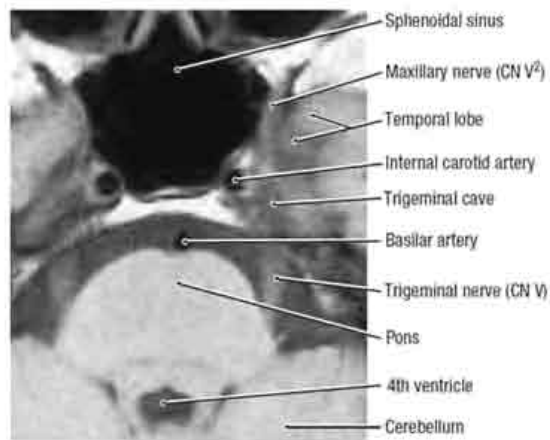
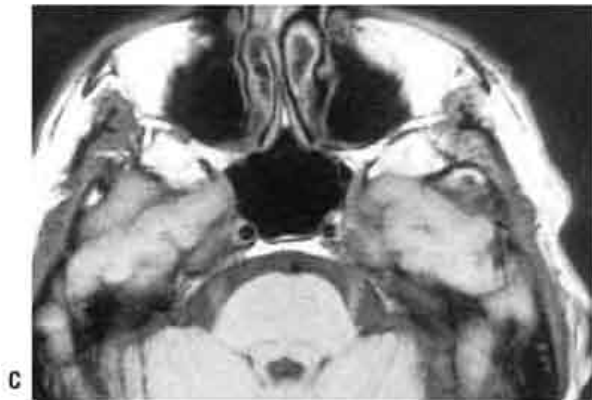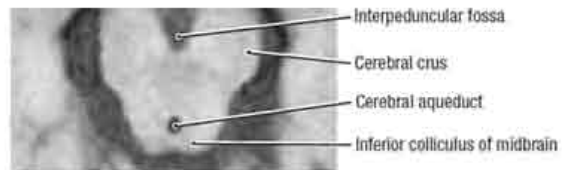
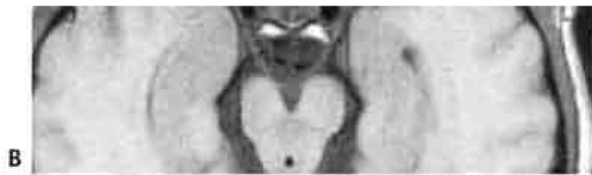A. Optic nerve (CN II). B. Oculomotor nerve (CN III). C. Trigeminal nerve (CN V).

P.843

D. Abducent (CN VI), facial (CN VII), and vestibulocochlear (CN VIII) nerves. E. Glossopharyngeal (CN IX), vagus (CN X), and spinal accessory (CN XI) nerves. F. Hypoglossal nerve (CN XII).

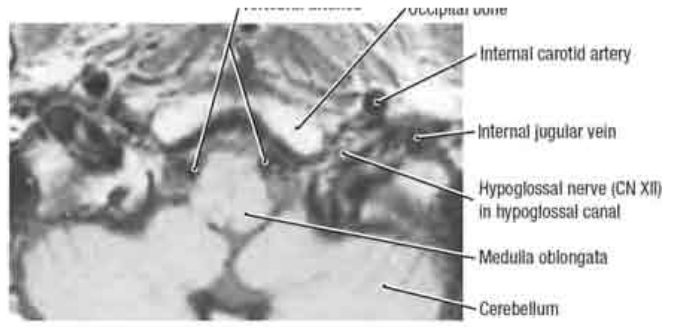
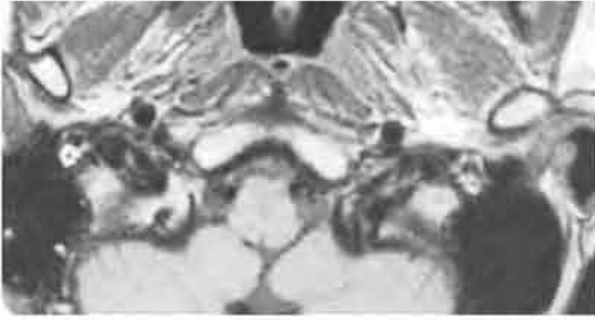
P.844





Vertebral arteries      Occipital bone

F



Authors: Agur, Anne M.R.; Dalley, Arthur F.

Title: *Grant's Atlas of Anatomy, 12th Edition*

Copyright ©2009 Lippincott Williams & Wilkins

> Table of Contents > Chapter 9 - Cranial Nerves > 9.7 Coronal MRIs through head, showing cranial nerves

---

## 9.7 Coronal MRIs through head, showing cranial nerves

*Part of* "Chapter 9 - Cranial Nerves "

A. Olfactory bulb. B. Trigeminal (CN V) nerve. C. Oculomotor (CN III) and trigeminal (CN V) nerves.



